

Clinical and Ultrasonographic examinations in cattle with empty rectum

M. Saravanan^{*1}, M. Ranjithkumar¹, S. Yogeshpriya², R. Ravi³ and K. Kannan

Veterinary Clinical Complex Veterinary College and Research Institute,

Tamil Nadu Veterinary and Animal Sciences University, Orathanadu-614 625, Thanjavur, TamilNadu, India.

Received: 14-08-2018

Accepted: 01-11-2018

DOI: 10.18805/ijar.B-3713

ABSTRACT

Ultrasonography helps in early diagnosis of large animal digestive disorders especially in cattle with empty rectum and also to initiate early therapeutic and surgical management. The study was undertaken to elicit GI disturbances in cattle at TVCC, VCRI, Orathanadu during 2015-16. Animals with history of absence of feces and or empty rectum were selected for this study. In total twenty nine cattle were found to be affected with various GI disorders. The incidence of GI disturbances was more (65.52 %) in cross bred Jersey cow. The common clinical signs were absence of feces (65.52 %), anorexia (58.62 %), scant/tarry/mucous coated foul smelling feces (34.48 %), arched back (24.14 %) and abdominal distention (24.14 %). All selected 29 animals were subjected to abdominal ultrasonography which revealed peritonitis (31.03 %), paralytic ileus with peritonitis and pericarditis in each 10.34 %, uroabdomen, intussusceptions, caecal dilatation, abomasal dilatation and peritonitis with intussusceptions in each 6.90 % and diaphragmatic hernia, reticular abscess, omasal impaction and peritonitis with pericarditis in each 3.45 %. Based on this study, clinical and ultrasonographic examinations were found to be a useful tool for the diagnosis of GI disorders of cattle with empty rectum.

Key words: Abdominal disorders, Bovine, Empty rectum, Scant feces, USG.

INTRODUCTION

Gastrointestinal disorders are extremely important in cattle, in which gradual reduction followed by the absence of feces is a major concern in bovine internal medicine. The common conditions causing GI emptying disturbances in cattle are due to traumatic reticulopericarditis/pericarditis, peritonitis/pericarditis, abomasal displacement, ileus, cecal dilation, intussusceptions and uroabdomen (Braun, 2009). The clinical signs suggestive of various abdominal disturbances are intermittent or recurrent bloat, anorexia, edematous swelling of brisket and mandible, jugular distention, scant or mucoid feces, absence of feces and anuria. Rectal examination, rumen impacted or bloated, distended intestinal loops, intussusceptions mass and variable color and consistency of dung were reported. GI system disturbance can be identified based on clinical signs and physical examination, but it's difficult to identify the location of the lesions. The signs evident are not specific and radiographic examination of the bovine abdomen has limitations. Transabdominal ultrasound helps in early diagnosis of GI disorders in large animal practice (Scott, 2012) by lesion localization and facilitates early therapeutic and surgical intervention. Even it provides prognosis of the GI disturbance. Hence the study was undertaken to evaluate cattle with empty rectum by clinical and ultrasonographic examination.

MATERIALS AND METHODS

The study was conducted in the clinical cases presented at Teaching Veterinary Clinical Complex (TVCC), Veterinary College and Research Institute, Orathanadu, Thanjavur during 2015-16. The animals with gradual reduction of dung and mucoid or scant and absence of feces were selected for this study. In the study animals breed, age, sex, parity, pregnancy and lactation status, duration and onset of clinical signs were also recorded. All the selected cows were subjected to detailed physical and rectal examinations.

Ultrasound examination: Ultrasonographic examination was performed in non-sedated standing cattle as given by Braun (2009) using 2.5-5 MHz convex probe (Esaote Color Doppler, Germany). Examination area heart, reticulum, abomasum, omasum and intestine were examined transcutaneously and urinary bladder per rectal using rectal probe. Criteria used for the ultrasonographic evaluation are organ location, activity, motility, lumen diameter, wall thickness and presence of fluid or mass.

RESULTS AND DISCUSSION

In the present study on ultrasonography, twenty nine cattle were found to be affected with various GI disorders like peritonitis, pericarditis, paralytic ileus, uroabdomen, intussusceptions, caecal dilatation, abomasal dilatation, diaphragmatic hernia, reticular abscess and omasal impaction (Table 1). The incidence was more in cross bred Jersey cows

*Corresponding author's e-mail: sara82vet@yahoo.com

¹Department of Veterinary Clinical Medicine, Madras Veterinary College, Chennai-600 007, India.

²Department of Veterinary Medicine, Veterinary College and Research Institute, Orathanadu-614 625, India.

³Department Veterinary Clinical Medicine, Veterinary College and Research Institute, Namakkal-637 002, India.

(65.52 %) followed by cross bred HF (13.79%), non-descriptive cattle (13.79%), Kangayam (3.45%) and Umbalacheri (3.45%).

The common clinical signs recorded were absence of feces/ no defecation, anorexia, scant feces, abdominal distension, arched back, bloat, colic, edema, jugular vein distension and anuria (Table 2), similar clinical features were reported previously for diaphragmatic hernia (Mohindroo *et al.*, 2007), caecal dilation (Ranjithkumar *et al.*, 2017), uroabdomen (Saravanan *et al.*, 2017), pericarditis (Kumar *et al.*, 2012), peritonitis (Abdelaal and Floeck, 2015), intestinal obstruction (Tharwat, 2011), ileus (Braun, 2006), omasal impaction (Toor and Saini, 2008) and abomasal displacement (Braun *et al.*, 1993a).

Table 1: Ultrasonographic findings recorded in the empty rectum cattle (n=29).

	No. of animals	Percent (%)
Peritonitis	9	31.03
Pericarditis	3	10.34
Ileus with Peritonitis	3	10.34
Uroabdomen	2	6.90
Intussusceptions	2	6.90
Caecal dilatation	2	6.90
Abomasal dilation	2	6.90
Peritonitis with Intussusceptions	2	6.90
Diaphragmatic hernia	1	3.45
Reticular abscess	1	3.45
Omasal impaction	1	3.45
Peritonitis with Pericarditis	1	3.45

Table 2: Clinical signs recorded in the empty rectum cattle (n=29).

	No. of animals	Percent (%)
Pregnant	4	13.79
Absence of feces / no defecation	19	65.52
Anorexia	17	58.62
Scant feces	10	34.48
Abdominal distension	7	24.14
Arching back	7	24.14
Bloat	4	13.79
Colic	4	13.79
Edema	4	13.79
Jugular vein distension	4	13.79
Absence of urination	2	6.90

The incidence was more in females (89.66%) than males (10.34%). 13.9 % of pregnant cattle were empty rectum. 44.83 % of the lactating cows had higher incidence, followed by heifers (41.38%), bulls (10.34%) and calf (3.45%). Most of the animals per-rectally there was scant and or absence of feces (29/29), dilated intestinal loops (6/29), distended rumen (4/29), pregnant (4/29) and fluid thrill (2/29).

Peritonitis, ileus: Anechoic fluid and fibrinous adhesions (Fig 1) were observed in 9 animals and along with peritonitis with ileus (3/29), peritonitis with intussusceptions (2/29) and peritonitis with pericarditis (1/29) were also recorded. Anechoic fluid filled structure were observed in between the intestines (Fig 2), surrounding the pericardium and along with fibrinous adhesions surrounding the reticulum. These findings correlated with Braun (2005) who recorded echogenic bands of fibrin in the fluid, and fibrinous deposits attached to the peritoneum and adjoining internal organs. Braun (2006) reported that dilated loops of intestine in the cranial part of the abdomen indicate an ileus in the cranial part of the small intestine. Multiple dilated loops of small intestine in the entire right side of the abdomen indicate an ileus in the caudal part of the small intestine. The diagnosis of ileus is supported by the transrectal palpation of dilated loops of intestine and absence of feces in the rectum or feces containing blood, mucus, or fibrin (Braun, 2005).

Pericarditis: Pericardial effusions i.e. anechoic fluid noticed in pericardial sac (3/29) and fibrinous adhesions and hyper echoic thick fluid (small granule like materials) were also recorded (Fig 3). Braun (2009a) reported hypoechoic contents in pericardial sac corresponding to pus which is considered as suppurative pericarditis and echogenic bands between the hypoechoic thick pericardium as fibrinous pericarditis (Abdelaal *et al.*, 2009).

Cecal dilation: Dilated cecum (2/29) was confirmed by rectal examination and on ultrasonography with luminal diameter of 12.4 cm and wall thickness of 4.6mm (Fig 4). These findings correlated with Ranjithkumar *et al.* (2017) and Braun *et al.* (2012) also confirmed caecal dilatation in 56 cows by USG, which were not diagnosed via rectal palpation.

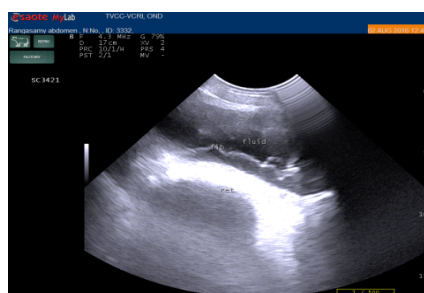


Fig 1: USG - Cattle - Left ventral - Peritonitis with fibrin adhesion.

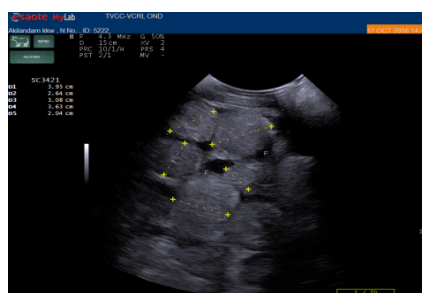


Fig 2: USG -Cattle - Right lateral - Peritonitis with dilated intestinal loops.

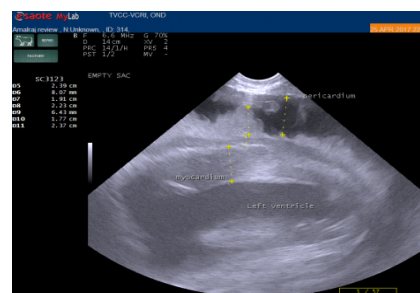

Fig 3: USG - Cattle - Heart - Left - Pericardial effusion with fibrin adhesion.

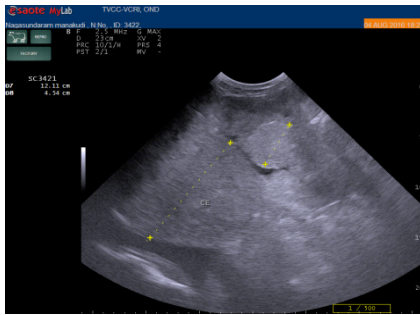


Fig 4: USG - Cattle - Right flank - Dilated cecum.

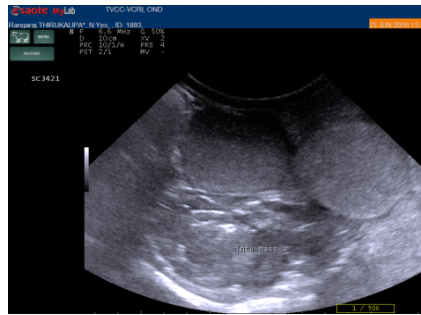


Fig 5: USG - Cattle - Right lateral - Dilated intestine and Intussusceptions.

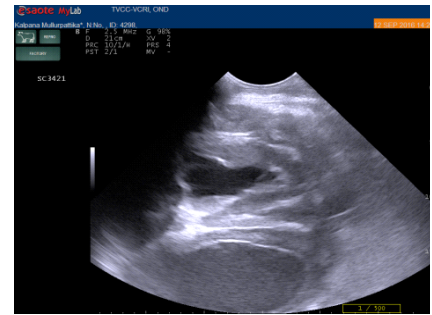


Fig 6: USG - Cattle - Left lower thorax - Reticular abscess.

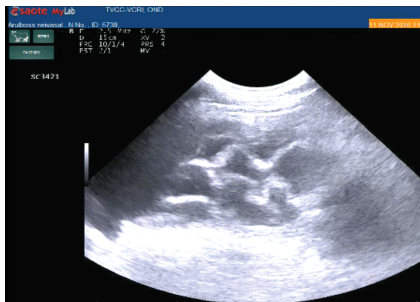

Fig 7: USG - Cattle - Dilated abomasum with floating abomasal folds.

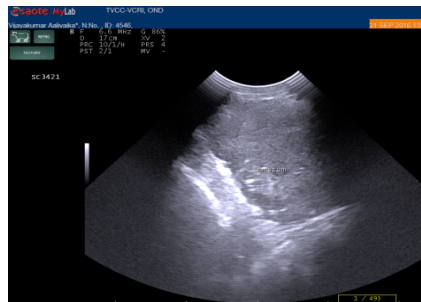


Fig 8: USG - Cattle - Right - Omasal impaction.

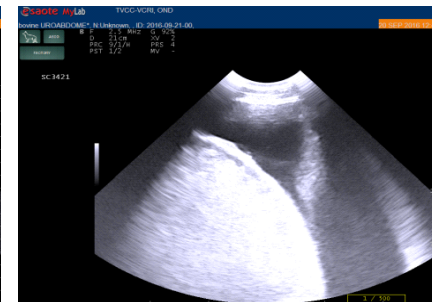


Fig 9: USG - Cattle – Uroabdomen.

Intussusceptions: Dilated intestinal loops, anechoic fluid between intestinal loops and mass (6 cm) noticed at caudal abdomen in the right flank (Fig 5; 2/29). The dilated intestinal segments with luminal content movement was observed proximal to the intussusceptions and followed by no motility caudal to the mass which indicates presence of obstruction or mass in the intestine. These findings correlated with Braun (2006).

Reticular abscess: Demarcated anechoic structure anterior to reticulum with attachment of reticulum (Fig 6) was recorded in one case. Kumar *et al.* (2012) reported that irregular thickened reticular wall with reduced amplitude of the reticular contractions indicates reticulitis and reticular adhesions in all the animals diagnosed with pericarditis.

Diaphragmatic hernia: Hyperechogenicity of reticular wall and reticular contractions was noticed (1/29) at 4th & 5th intercostal space and these findings correlated with that of Mohindroo *et al.* (2007).

Dilatation of abomasal & omasum: Dilated abomasum with anechoic fluid and folds floating within the contents at the level of left side 7-9th intercostals space (Fig 7) were recorded (2/29). Braun *et al.* (1993a) reported that USG is useful diagnostic tool for the diagnosis of abomasal displacement.

Distended omasum was noticed with echogenic contents (Fig 8; 1/29).

Uroabdomen: Trans-rectal ultrasonographic examination revealed collapsed urinary bladder with wall thickening (5.6 mm). On trans-abdominal ultrasonography, severe fluid accumulation was observed (Fig 9). Ozturk *et al.* (2007) and Saravanan *et al.* (2017) reported large amount of fluid accumulation in the peritoneal cavity which was confirmed as uroabdomen based on USG and serum-peritoneal creatinine levels.

CONCLUSION

Based on this study, clinical sign of cattle with empty rectum due to various GI disturbances were confirmed by the ultrasonography. Hence, it can be concluded that ultrasonography is found to be useful diagnostic imaging tool to localize the lesions of the cattle with empty rectum. Further in large animal practice, thoracic and abdominal ultrasonography plays an important role in the diagnosis of thoraco-abdominal disturbances in cattle.

ACKNOWLEDGEMENT

The Authors are grateful to The Director of Clinics, TANUVAS, Chennai and Professor and Head, VCC VCRI, Orathanadu to provide all the facilities for carrying out this study.

REFERENCES

- Abdelaal, A. and Floeck, M. (2015). Clinical and sonographical findings in buffaloes (*Bubalus bubalis*) with traumatic reticuloperitonitis. *Veterinarski Arhiv*. **85** (1): 1-9.
- Abdelaal, A.M., Floeck, M., Maghawry, S.E. and Baumgartner, W. (2009). Clinical and ultrasonographic differences between cattle and buffaloes with various sequelae of traumatic reticuloperitonitis. *Veterinari Medicina*. **54**: 399-406.

- Braun, U. (2003). Ultrasonography in gastrointestinal disease in cattle. *Veterinary Journal*. **166**: 112–124.
- Braun, U. (2005). Ultrasound as a decision-making tool in abdominal surgery in cows. *Veterinary Clinics: Food Animal Practice*. **21**: 33-5.
- Braun, U. (2006). Therapeutic decision in acute abdominal disorders of the cow. World Buiatrics Congress - Nice, France. DOI: <http://www.ivis.org/proceedings/wbc/wbc2006/braun.pdf?LA=1>
- Braun, U. (2009). Ultrasonography of the Gastrointestinal Tract in Cattle. *Veterinary Clinics: Food Animal Practice*. **25**: 567–590.
- Braun, U. (2009a). Traumatic pericarditis in cattle: clinical radiographic and ultrasonographic findings. *Veterinary Journal*. **182**: 176–86.
- Braun, U., Beckmann, C., Gerspach, C., Hassig, M., Muggli, E., Knubben-Schweizer, G. and Nuss, K. (2012). Clinical findings and treatment in cattle with caecal dilatation. *BMC Veterinary Research*. **8**:75.
- Braun, U., Steiner, A. and Gotz, M. (1993a). Clinical signs, diagnosis and treatment of duodenal ileus in cattle. *Schweiz. Arch. Tierheilkd*. **135**: 345–355.
- Kumar, A., Narinder, S.S., Mohindroo, J. and Sood, N.K. (2012). Ultrasonographic features of normal heart and liver in relation to diagnose pericarditis in bovine. *Indian Journal of Animal Sciences*. **82** (12): 1489–1494.
- Mohindroo, J., Kumar, M., Kumar, A. and Singh, S.S. (2007). Ultrasonographic diagnosis of reticular diaphragmatic hernias in buffaloes. *Veterinary Record*. **161**: 757-758.
- Ozturk, S., Kilic, E., Aksoy, O., Ozaydin, I. and Yayla, S. (2007). Ultrasound diagnosis and surgical treatment of bladder ruptures in cattle. *Indian Veterinary Journal*. **84**: 509-511.
- Ranjithkumar, M., Saravanan, M., Ravi, R., Krishnakumar, S., Kannan, K. and Kavitha, S. (2017). Cecal dilatation and distention and it's management in a cow and a kangeyam Bullock. *Indian Veterinary Journal*. **94** (5): 68 – 70.
- Saravanan, M., Kavitha, S., Ranjithkumar, M. and Ravi, R. (2017). Uroabdomen in a Kangayam Bullock-A Case Report. *Indian Veterinary Journal*. **94** (05): 70 - 71
- Scott, P. (2012). Abdominal ultrasonography as an adjunct to clinical examination – 2 Cattle. *In Practice*. **34**: 66-72.
- Tharwat, M. (2011). Diagnostic ultrasonography in cattle and buffaloes with intestinal obstruction. *Journal of Agricultural and Veterinary Sciences*. **4**(1): 67-80.
- Foor, A.S. and Saini, N.S. (2008). Diagnostic and prognostic indicators of omasal impaction in buffaloes (*Bubalus bubalis*). *Veterinary Record*. **162**(9): 275-7.