

# Bovine Visceral Schistosomosis- An Insidious Debilitating Disease

N Jeyathilakan and Shivani Mamane

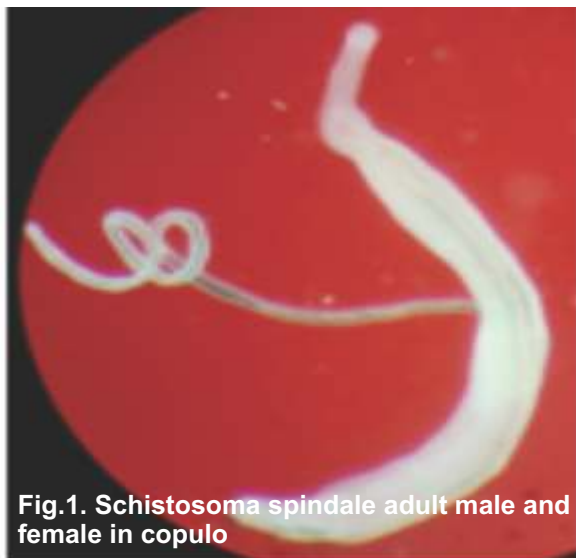Dept. of Veterinary Parasitology, Madras Veterinary College, TANUVAS, Chennai, Tamil Nadu.

## Introduction

Bovine Visceral or hepatointestinal schistosomosis is one of the most common neglected parasitic disease of cattle commonly caused by two species of blood flukes namely *Schistosoma spindale* and *Schistosoma indicum*. These two flukes are occurring all over India, south and southeast asia and often cause subclinical disease with high economic losses due to morbidity and mortality. The affected animals are showing impaired growth, chronic debility and decreased productivity (1). All age groups, especially, adult cattle and buffalo are mainly affected by blood flukes residing in portal and mesenteric veins. These blood flukes cause chronic wasting illness, hemorrhagic diarrhea, emaciation and anemia similar to existing bovine bacterial disease, Johne's disease. They are also attributed to reduced milk yield and mortality with outbreaks leading to high death rates in cattle.

## Biology of Schistosome Flukes

The sexes of schistosome flukes are separate. Generally the female flukes are long and slender. The male is broad and flat with the sides of the body curved inwards to form a gutter like groove known as gynecophoric canal in which the female is present in copulo. The size of the adult worms varies depending on the species of schistosomes. Male *S. spindale* measures 5.6 - 13.5 mm and female worm measures 7.2 - 16 mm (Fig.1)



**Fig.1. Schistosoma spindale adult male and female in copulo**

whereas male *S. indicum* measures 5 - 19 mm and female measures 6 - 22 mm (2).

Life cycle is indirect with snail *Indoplanorbis exustus* acting as intermediate host for both schistosomes. The adult schistosomes deposit eggs in portal and mesenteric veins and are passed in faeces of cattle. The eggs are containing the first larval stage miracidium. When the eggs came to contact with fresh water, they hatch and liberate miracidium. The miracidium penetrate the intermediate host snail and transforms into next stage sporocysts. The daughter sporocyst produces the cercaria with forked tail. Up to several thousand to millions of cercaria may be produced from single miracidia inside the snail. The cercaria penetrate the skin of the cattle coming to water bodies and transform into schistosomulum. This schistosomulum enters the lymphatic and vascular capillaries of dermis and reaches the systemic circulation through heart and lungs. Finally it reaches the hepatic portal system and settles in the liver. The schistosome grows in liver to reach juvenile and adult flukes. The adult male and female flukes form pairs and migrate to the hepatic portal vein and branches of the superior and inferior mesenteric veins where they lay eggs. Eggs appear in the dung of cattle from 4 weeks after infection and easily identified by their characteristic morphology.

## Clinical Signs

*S. spindale* affected cattle pass loose faeces with blood and mucus six to ten times a day, loss of condition, nonfebrile persistent diarrhea, dyspepsia, progressive anaemia, emaciation and death in severe cases. *S. indicum* affected cattle show gradual weakness, anorexia with passing blood tinged diarrheic faeces from 80 days post infection, with decrease in haemoglobin, PCV and TEC. The level of serum SGPT, SGOT and Alkaline phosphate is decreased. The clinical signs are almost similar to Johne's disease. But the characteristic eggs of *S. spindale* and *S. indicum* in the faeces confirms bovine visceral Schistosomosis.

## Diagnosis

Diagnosis of bovine visceral schistosomosis caused by *S. spindale* and *S. indicum* is difficult based on clinical signs (4). However, the symptoms of intermittent diarrhea with blood, emaciation and

weakness coupled with history of access to water bodies infected with snails may confirm the diagnosis. Faecal examination of eggs is used for confirmatory diagnosis on the basis of characteristic morphology. *S. spindale* eggs are 160-400 µm X 70-90 µm in size, Napoleon hat shaped with a terminal spine at one end and miracidia inside (Fig.2). *S. indicum* eggs are 90-140 µm X 42-72 µm in size, oval shape with a terminal




Fig.2 *Schistosoma spindale* egg

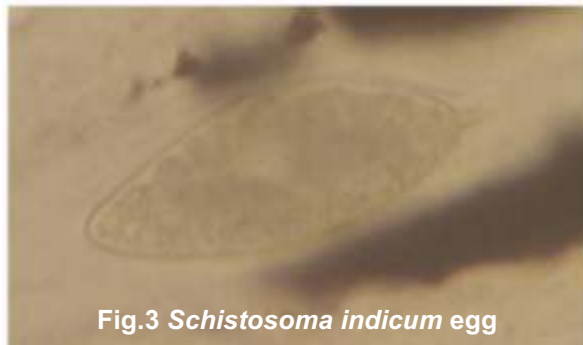


Fig.3 *Schistosoma indicum* egg

spine at one end and well-developed miracidia inside (Fig.3).

Examination of faeces directly collected from dorsal part of rectum(rectal pinch method) is giving better yield of eggs. Sedimentation method of faecal examination reveals typical schistosome eggs. Faeces mixed with 5-10% sodium hydroxide instead of water will prevent hatching of miracidia from eggs. Examination of rectal scrapings stained with malachite green reveals better detection of eggs(5). Egg output in Schistosomes is very low in chronic infection. Hence use of miracidial hatching test (hatching of eggs present in the faeces) is advised.

### Treatment

Several antimony compounds are tried for the treatment of visceral schistosomiasis of bovines with varying results. Several doses of Anthiomaline (Lithium antimony thiomalate) or two courses with 8 weeks apart are required for *S. spindale* infection in cattle(6). Praziquantel is reported to be highly effective against both *S. spindale* and *S. indicum* and completely cleared the flukes from cattle(7, 8).

### Control

Preventive measures mostly depend on disrupting the biological cycle of flukes by following ways

- Treatment of animals for removing adult parasites.
- Extermination of intermediate host snail by using molluscicides and modification of their habitat.
- Niclosamide, Copper sulphate and Sodium pentachlorophenate are used as molluscicides(9). Plant extracts from *Balanites aegyptica*, *Sapindus emarginatus*, *Datura*, *Neem*, *Mahua* and *Deodar* oil are showing promising molluscicide effects (10). Foraging of ducks in water bodies will eliminate the snail population.
- Preventing the animals to access snail and cercaria contaminated water sources by creating a barrier around water bodies.
- Avoid collecting water from ponds, rivers and lakes with snail population for drinking purposes.
- Educating the livestock owners regarding mode of disease transmission and control measures.

### References

1. Lefevre, P. C., Blancou, J., Chermette, R. and Uilenberg, G. (2010). Infections and parasitic diseases of Livestock, Lavoisier, Paris. 1699.
2. Jeyathilakan, N., Latha, B. R. and Basith, S. A. (2008). *Schistosoma spindale* in ruminants at Chennai. Tamilnadu J. Vet. Anim. Sci. 4: 135.
3. Agrawal, M. C. (2012). Schistosomes and Schistosomiasis in south Asia. Springer India publication.
4. Shivane mamane, Jeyathilakan, N., Bhaskaran Ravi Latha Senthilkumar, T. M. A. and N.Pazhanivel. (2021). Histopathological changes in Visceral Schistosomiasis caused by *Scistosoma spindale* in cattle. Indian J. Vet. Anim. Sci. Res. 50:75.
5. Pholpark, M., Upatom, N and Srihakim, S. (1996). Studies on *Schistosoma spindale* in cattle and buffaloes in the North east of Thailand. 4.Rectum mucosa scraping for diagnosis of bovine schistosomiasis. Thai.J.Vet.Med. 26:75.
6. Mohanty, D. N., Mohanty, R. K., Ray, S. K. and Mohanty K. M. (1984). A note on *Schistosoma spindale* infection in cattle and its successful treatment. Livestock adv. 9:37.
7. Upatoom, N., Hoerchner, F. and Leid, K. (1988). Therapy against *Schistosoma spindale* infestation in cattle and buffalo. Vet. Med. Rev. 59:171.
8. Giri, D. K., Kashyap, D. K. and Ramteke, R. C. (2018). Diagnosis and Management of *Schistosoma indicum* Infestation in a Calf. Intas Polivet. 19: 334.
9. Anantaraman, M. (1955). Biological control of aquatic snail. Indian J. Vet.Sci. 25: 65.
10. Koshy, T. J. and Alwar, V. S. (1974). Laboratory trials with the molluscicides. Copper sulphate, Sodium pentachlorophenate and baylucide against *Indoplanorbis exustus*. Cheiron.3: 170.