EVALUATION OF A BIOIMPLANT IN FRACTURE HEALING IN CALVES

THESIS

By

VINAY KUMAR

Submitted to

HIMACHAL PRADESH KRISHI VISHVAVIDYALAYA

PALAMPUR - 176062 (H.P.) INDIA

IN

Partial fulfilment of the requirements for the degree

OF

MASTER OF VETERINARY SCIENCE
(VETERINARY SURGERY AND RADIOLOGY)

1996

DEDICATED

TO MY

BELOVED PARENTS AND CHILDREN

CERTIFICATE I

Certified that this thesis entitled, "**Evaluation of a Bioimplant in fracture healing in calves**" submitted in partial fulfilment of the requirements for the award of the degree of **Master of Veterinary Science** in the subject of **Veterinary Surgery and Radiology** of the Himachal Pradesh Krishi Vishvavidyalaya, Palampur, is the bonafide research work carried out by **Mr. Vinay Kumar** (V-94-30-09) s/o Sh. Bishan Dass under my supervision and that no part of this thesis has been submitted for any other degree.

The assistance and help received during the course of this investigation have been fully acknowledged.

Place: Palampur
Dated: 31July, 1996.

(A.C. Varshney)
Chairman
Advisory Committee

CERTIFICATE II

This is to certify that the thesis entitled, "**Evaluation of a Bioimplant in fracture healing in calves**" submitted by **Mr. Vinay Kumar** (V-94-30-09) s/o Sh. Bishan Dass to the Himachal Pradesh Krishi Vishvavidyalaya, Palampur (H.P.), India, in partial fulfilment of the requirements for the degree of **Master of Veterinary Science** in the subject of ***Veterinary Surgery and Radiology*** of College of Veterinary and Animal Sciences has been approved by the Student's Advisory Committee after an oral examination of the same in collaboration with an external examiner.

14/12/96
Major Advisor

12/12/96
External Examiner

12-12-96
Member

12/12/96
Member

12-12-96
Member

12/12/96
Member

Head
Department of Veterinary
Surgery & Radiology

23.12.96
Dean, P.G

[illegible]

ACKNOWLEDGEMENTS

I take this opportunity to extend my heartfelt gratitude, obligation, appreciation and sincere thanks to Dr. A.C. Varshney, Head, Department of Surgery & Radiology, the chairman of my advisory committee, for his benevolent guidance, meticulous planning, sustained encouragement, healthy criticism and valuable suggestions throughout the tenure of this investigation.

Indeed the words of command are not adequate to convey my gratitude to Dr. D.N. Sharma, Professor & Head, Department of Anatomy & Histology for his deep and constant association, prompt help, support and keen guidance during this investigation and writing of this manuscript I shall always remain indebted to him for his personal affection to me.

I owe much to the members of advisory committee, Dr. S.P. Singh, Professor and Head, Department of Veterinary Physiology, Dr. M.S. Kanwar, and Dr. S.K. Sharma, Assistant Professors , Department of Surgery & Radiology for their readily help, valuable suggestions and constant encouragement during the course of this study.

I am grateful to Prof. J.M. Nigam, Dean, College of Veterinary & Animal Sciences, HPKV, Palampur for his scholarly guidance, untiring efforts and staunch commitment for ultimate welfare of students and providing necessary facilities for completion of this manuscript.

A very special thanks are conveyed to Dr. R. C. Katoch, Head, Department of Veterinary Microbiology, Dr. L.S. Sudhakar, Associate Professor and Dr. R.L. Bhardwaj, Assistant Professor, Department of Anatomy & Histology., Dr. A.K. Sharma, Assistant Professor Clinics, Dr. M.M. Singh, Assistant professor, Department of Gynaecology and Obstetrics, Dr. R.S. Kishtwaria, Assistant Professor, clinics and Dr. B. Prasad, Professor and Head, Department of Medicine and Dr. V.K. Gupta, Assistant Professor , Department of Pathology for their kind co-operation in rendering technical acumen and ready to help attitude.

I am thankful to Govt. of Jammu & Kashmir for allowing me to carry out the study at HPKV as an inservice candidate.

I also thank Dr. J.L. Raina Director and Dr. I.D. Bakshi, Ex-Director of Animal Husbandry, Jammu & Kashmir state; Dr. B.L. Sharma, Dr. K.L. Gupta and Dr. G.C. Gupta Chief Animal Husbandry Officers of J&K for their help and co-operation.

I am highly grateful to Dr. T.P. Sastry, Scientist, Biproduct Laboratory, Central leather Research Institute, Adyar, Madras, for providing the bioimplants utilized in the experimentation.

I express my heartfelt appreciation for the timely help of my friends, Drs Rajesh Rajput, Surinder Gupta, Rubinder Adarsh. Archna and Shalini.

The diligence and incessant attitude of Sarva Shri Amar Chand, Ved Parkash, Kishan, Vinod, Ram Swarup, Chaman, Kamaljit, A.S. Masand, Amar Nath, Anil, Jagat Ram, Hoshiar Singh, Ravinder, Harjit, Surjit, Purshotam is highly acknowledged.

I also wish to snatch the opportunity to express my deepest sense of gratitude to my wife 'Pawan' for her patience and inspirations which have lead me to join and fulfil the desire of completing post-graduation.

I have but to apologise to my loving children, 'Easily' and 'Hithanshu' who had to bear the neglect and separation from my part.

Thanks are due to Scottish Computers, Palampur for providing computer facilities for the preparation of manuscript in its present form.

And last but not the least is my indebtedness and gratitude to my respected parents and all members of my family for their encouragement and moral and financial support throughout the period of study.

Palampur

Dated: 31st July, 1996

Vinay Kumar

CONTENTS

LIST OF FIGURES

LIST OF TABLES

CHAPTER 1

INTRODUCTION

Among all the surgical ailments recorded at the Himachal Pradesh Krishi Vishvavidyalaya Veterinary Clinics, Palampur, the fracture of limb bones ranked number one. The metatarsal and metacarpal bones were the most commonly involved. Volumes of literature have accumulated on the fracture repair in experimental and other mammals. But very few studies have been made on the repair of fracture in bovines.

Earlier, casts and splints were the only devices available for the limb fracture immobilization. Casts were also useful in maintaining internal fixation.

The metallic implants had limited value due to the discomfort to the patient, and associated surgical risk, morbidity and cost. Osteopenia due to the alteration in vascularity beneath the implants could hamper the healing process.

Bone grafts provided the mechanical support but the vascularization was slow and formation of bone was less extensive when compact bone graft was used. The cancellous bone grafts improved the vascular response. Autogenous bone grafts because of their superior osteoinductive property, rapid incorporation and lack of immunogenic problem were preferred for healing the osseous defects (Brown and Cruess, 1982 and Scunderi *et al.*, 1991). Allogenic and xenogenic grafts were not preferred because of obvious reasons *viz.* any systemic disease to the donor, unsterile harvested grafts and complexity of host-graft relationship.

In order to overcome the above constraints certain bioimplants which resembled in structure and composition to the bone, were used for repair of fracture (Holmes, 1976). Aluminium calcium phosphorus pentoxide (ALCAP) proved best compatibility with gradual replacement of ceramic material with endogenous bone (Freeman, 1981). Tricalcium phosphate, a biodegradable bone implant showed promising results in repair of fracture (Auer *and Schenk* 1989). But the less tensile strength , brittle nature and impact resistance limited its application in stressful circumstances (Hollinger and Battistone, 1986). Hydroxyapatite was used in correcting the bone defects of mandibles, maxillae and long bones (deGroot, 1960). It was reported to be a suitable **BONE GRAFT SUBSTITUTE** in bone surgery. The collagen present in the bone, provided the necessary nucleus as well as adenosine triphosphate activity for early mineralization of the bone (Franklin, 1968).

Hydroxyapatite and fibrillar collagen which formed the major portion of the bone were tested for ectopic bone induction in mice (Takaoka, *et al.*, 1988). These implants were used successfully in the fracture repair of dog (Sastry *et al.*, 1995). The literature on the use of this implant in bovine is not traceable.

The present study was therefore, undertaken in calves with the following objectives:

(i) to evaluate the osteogenic properties of bioimplant on the basis of clinical, haematological, biochemical radiographic, angiographic and histological examinations after experimentally induced fractures in metetarsal bone.

(ii to assess the efficacy of bioimplant in the clinical cases of fractures in bovines.

The idea of assessing the effectivity of the said implant had been to provide the required scaffolding for quick migration of the reparative cells and thus reducing the healing time. The results achieved in the investigation will be highly useful to the field veterinarians; since the bioimplants have been recently introduced in our country.

REVIEW OF LITERATURE

Transplantation of bone has a long history in the annals of orthopaedic science. Various types of bone grafts and implants have been used in the reconstruction of bone. Abundant literature have accumulated on various aspects of this topic. The literature has been reviewed under following headings:-

1. Bone Grafts
2. Biodegradable/Bioresorbable Implants
3. Methods of Evaluation

2.1 Bone Grafts

Bone grafting represents one of the earliest desired reconstructive approaches to the musculo-skeletal system and is the most commonly used orthopaedic procedure. The pioneer work on the use of homogenous grafts was practiced in a boy by Macewen (1878). Subsequently, transplantation of the whole or hemijoint was adapted to replace the damaged knee (Lexer, 1925). Schroeder (1938) reported the use of bone grafts in veterinary orthopaedics. The use of bone banks was strongly advocated in veterinary orthopaedics (Newton and Nunamaker, 1985). The grafts were stored deep frozen in sterile containers and used successfully upto 2 years (Tomford *et al.*, 1983).

The cancellous or cortical bone grafts have been observed to be an adjunct to any orthopaedic procedure where rapid bone formation or bone union was desired (Stevenson, 1985). Autogenous cancellous bone grafts were essential for treatment of fracture complications such as osteomyelitis, delayed union or non union (Meyre *et al.*, 1975). The cortical bone graft was not as frequently used but had a role in replacement of massive cortical defects in fracture repair (Henry and Wardsworth, 1981; Alexander, 1983 and Vasseur, 1987). Autogenous cortical bone graft provided strength and was slowly incorporated at the recipient site than cancellous grafts (Harvey *et al.*, 1990). The grafted cortical bone was gradually removed and replaced by bone from recipient bone whereas autologous cancellous bone enhanced its incorporation at the recipient site (Bacher and Schmidt, 1980 and Alexander, 1983). Friedlaender and Mankin (1981) reported homogenous or allogenous bone as an alternative to an autogenic transplantation.

The allograft or homograft overcame the limitations associated with the procurement of autograft. However, it provoked immunological response. It has poor osteogenic and osteoinductive activities as compared to fresh autograft. Delayed remodelling response were common disadvantages associated with this grafts (Burwell, 1969 and Bonfiglio, 1976).

Extensive studies have been carried out to preserve the osteoinductive and osteogenic properties and to reduce antigenicity of allogenic bone grafts (Burwell, 1969; Stabler *et al.*, 1985 and Tomford *et al.*, 1986). Burwell (1969) preserved the bone by way of boiling, autoclaving, deproteinizing, merthiolating, declacifying, freezing and freeze drying. But by these methods osteoinduction capacity was reduced (Ross, 1966 and Burwell, 1969). Use of autoclaved segments in neoplastic and traumatized bone has been documented (Burwell, 1969 and Coupland, 1969). Singh *et al.* (1977) reported slower rate of resorption and poor bone formation with autoclaved grafts. Decalcified allogenic bone grafts were preferred over boiled, autoclaved, deproteinized and merthiolated grafts (Stevenson, 1985). The decalcified grafts possessed little strength, hence lacked weight bearing capacity.

Urist (1965) reported that histocytes, foreign body giant cells and inflammatory connective tissue cells were stimulated by degraded products of dead bone matrix to grow in and repopulate the area at the site of a decalcified bone implant . Dissolution of the bone matrix took place due to transfer of collagenolytic activity to the substrate by the histocytes . This was subsequently followed by new bone formation by autoinduction.

The bone matrix of the grafted tissue also influenced the reconstructive properties of the host bone by the process of assimilative induction (Hyatt and Butler, 1960). It was further established that higher cellular grafts (cancellous) with low matrix proportion received less opportunity for healing as compared to low cellular grafts along with high matrix protein (cortical).

Urist and Iwata (1973) reported that the organic matrix of bone and dentin even in the absence of living cells possessed bone induction principle which was termed as bone morphogenetic protein (BMP). The bone morphogenetic protein, being chemotactic protein, played an important role in the migration of osteoprogenitor cells to the site of bone repair. The early response involved the appearance and proliferation of mesenchymal cells at the site of implantation followed by cartilage and bone formation (Somerman *et al.*, 1983).

Decalcified bone grafts had been used in horses and other animals (Fakelman *et al.*, 1981; Einhorn *et al.*, 1984 and Gepstein *et al.*, 1987) and these grafts were found to be superior to autogenous bone grafts as regards to their osteogenic potential. Parsanalli (1988) observed that deep frozen bone grafts were rapidly resorbed and replaced by new bone. Use of decalcified and undecalcified freeze dried grafts had been reported in dogs with varying degree and rate of bone formation (Sudheer Kumar, 1989). Decalcified bovine bone had been reported to possessed osteoinductive properties when transplanted in dogs, through, the observations were not consistent (Shukla, 1989).

The graft of demineralized bone matrix that had been treated with autologous plasma was called plasma coated demineralized bone matrix or augumented plasma coated demineralized bone matrix (Weiss and Reddy, 1981). Demineralized bone matrix treated either with citrated plasma or fibronectin accelerated the bone formation (Bolander and Balian, 1986). When the healing process of plasma coated demineralized bone matrix graft was compared with the autogenous cancellous bone grafts in rabbits.

Impregnation of various types of bone graft with autologous red bone marrow has been reported experimentally for allograft bone (Burwell, 1966; Boyne, 1970 and Nade, 1970) and for xenograft bone (Salama and Weissman, 1978). Ashton *et al.* (1980) and Hirano and Urist (1981) suggested that during transplantation of bone marrow, the haemopoeitic cells died shortly and there was an overgrowth of fibroblasts which differentiated and redifferentiated to form bone. Salama and Weissman (1978) reported an accelerated rate of osteogensis at the beginning of healing process with viable autologous marrow cells and demineralized autologous compact bone graft.

2.2 Biodegradable/Bioresorbable Implants

Due to inherent drawbacks like surgical risk and non-availability of sufficient autografts and immunogenic reaction of allografts, search for synthetic materials started. The resorable, inorganic, alloplastic materials such as plaster of Paris, argonite, beta whitelockite and various combinations of calcium phosphate ceramics have been investigated (Hollinger and Battistone, 1986). The use of plaster of Paris to fill bone defects had been described as it exhibited little or no tissue reaction and was resorbed and replaced with new bone (Calhoun *et al.*, 1967 and Frame, 1980). However, plaster of Paris was not considered a good biodegradable material as it showed poor mechanical strength because of its faster resorption rate than that of bone in growth rate (Peltier, 1961). Graves *et al.*, (1971) suggested that the resorbable ceramics could be made porous so as to replace these pores by endogenous bone due to ingrowth of osteon in the pores to establish firm binding (Hulbert *et al.*, 1971). Cheroff *et al.* (1975) used organic material from the genius Porities coral as implant material in the femora and tibiae of dogs with pore size of ranging 140-160 μm in diameters and observed that there was complete resorption of the coral skeleton after one year. The coral structure was reported to be more organised than the random porosity produced in synthetic biomaterials. Klawitter and Hulbert (1971) determined that 100 μm was the optimum pore size for effective bone ingrowth.

Studies in rats showed that 60% of the calcium presented in the implanted porous calcium aluminate ceramic was resorbed by the rat's body within 75 days and 32% was replaced in next 75 days (Carvalho *et al.*, 1975 and 1976). Graves *et al.* (1971) tested both monophasic and polyphasic calcium aluminate ceramics in rhesus monkeys and suggested that polyphasic resorbable calcium aluminate ceramics were more suitable for replacing bone segments. Addition of phosphate to calcium aluminate ceramics increased the resorbability without lowering the strength (Graves *et al.*, 1975).

Aluminium calcium phosphorus pentoxide (ALCAP) had the best compatibility with gradual replacement of the ceramic material with endogenous bone (Wyatt *et al.*, 1976 and Freeman *et al.*, 1981). The porous nature of aluminium calcium phosphorus ceramic allowed induction of new bone growth into the implanted ceramics (Bajpai *et al.*, 1976 and Freeman *et al.*, 1980). Pore size range from 75 to 150 μm in diameter was reported to be optimum for bone ingrowth, vascularization and adequate oxygen supply (Skinner, 1979).

Phosphate biomaterials were biodegradable beta tricalcium phosphate (TCP) and hydroxyapatite (Bhaskar *et al.*, 1971; Cameron *et al.*, 1977 and Hollinger and Battistone, 1986). The most consistent and desirable property of TCP as well as other calcium phosphate ceramics was biocompatibility (Cutright *et al.*, 1972 and Ferraro, 1979). Themost remarkable property of such ceramics was their ability to bind directly with the bone. Ingrowth of connective tissue into peripheral pores of TCP implant was reported to be so rapid that it was difficult to separate the implant from the surrounding tissue (Bhaskar *et al.*, 1971). The TCP when impregnated into the medullary cavity immediately prior to final reduction showed promising results in equines (Auer *and Schenk*, 1989). Tortorelli and Posey (1981) applied porous TCP in block form with some success in mandibular discontinuities in dogs. Comparably less tensile strength of TCP to that of cancellous bone, brittle nature and low limpact resistence limited the application of TCP implants (Jarcho, 1981). However, use of TCP as a bone expander in combination with a bone graft or implant showed benificial results (Hollinger and Battistone, 1986).

Hydroxyapatite a phosphate biomaterial, was used in correcting the bone defects in mandible, maxillae and some other long bones (Jarcho *et al.*, 1977; Signs *et al.*, 1979 and deGroot, 1980). Being porous, readily penetrable by bone ingrowth and osteons formation was preceeded by ingrowth of blood vessels into gaps (Schenk, 1987). Implantation of hydroxyapatite into bone marrow cavities of rabbit femoral and tibial bone produced new bone formation (Kawamura *et al.*, 1987). They also reported a further increase in new bone deposition with bone morphogenetic proteins bound hydroxyapatite.

Use of hydroxyapatite along with demineralized bone matrix has been advocated in the treatment of fractures in dogs (Suresh Kumar, 1994). Excellent ossification was observedwithout any rejection or foreign body reaction has been reported in dogs (Sastry *et al.*, 1995). Jarcho (1981) suggested that hydroxyapatite was one of the most clinically applicable biocompatible materials. The superior histocompatibility of porous hydroxyapatite had been demonstrated following implantation of hydroxyapatite in rabbit spine (Flatley *et al.*, 1983) and dog femora (Hoogendoorn *et al.*, 1984). Composite bone grafts of marrow cells and hydroxyapatite in dog femoral defect, proved that hydroxyapatite did not inhibit new bone formation (Boyne *et al.*, 1978). On the other hand, porous hydroxyapatite was considered brittle and, mechanically weak as compared to dense hydroxyapatite (Jarcho, 1981).

Collagen is the principal organic constituent of bone tissue (Bourne, 1956) to supply the necessary nucleation centres as well as adenosine triphosphatase activity which in turn helped in a early mineralization (Franklin, 1968). A possible correlation of collagen was observed during calcification process (Udupa, 1966). Impaired collagen formation might result in mechanically inferior tissue of metaphysis (Grunsschober *et al.*, 1982). Collagen was found to have a strong influence on the nature and site of mineral crystal growth in bone matrix by Howell (1971). He also noticed an accelerated rate of mineralization in the presence of collagen. Varshney *et al.* (1991) observed a marked organisation of bone trabeculae, pronounced osteogenic reactions and mineralization of bone trabeculae and early reappearance of normal bone architecture by use of local enriched collagen therapy during resolution phase of osteomyelitis. Collagen extract prepared from ligamentum nuchae/Achille's tendon when injected at the fracture site enhanced osteosynthesis (Singh, 1978).

Bone is a two-phase composite tissue consisting of an organic material (collagen) impregnated with an inorganic crystalline material (hydroxyapatite) (Whitson, 1963). The use of collagen along with porous hydroxyapatite was reported for ectopic bone induction in mice (Takaoka *et al.*, 1988). There has been a close relationship between the molecular structural formation of collagen fibril and the crystal growth of apatite of calcium phosphate (Engstrom, 1960). Sastry *et al.* (1995) used osteoinductive and bone filling material. "Maxibloc" containing hydroxyapatite and fibrillar collagen for filling the bone gaps in orthopaedic and maxillofacial surgery in dogs. They observed complete ossification within 4 to 6 weeks.

2.3 Methods of Evaluation

2.3.1 Clinical Observation

The return of weight bearing capacity of the fractured limb was reported one week after implantation of segmental cortical bone graft in the tibia of goats by Bisla *et al.* (1991). They reported that weight bearing was seen earlier in the fresh autogenous cortical graft as compared to fresh allograft and autoclaved xenograft. Varying degree of lameness was observed upto 2 months in animals with autografts and allografts and upto 3 months in the animals with xenografts. Muscular atrophy was, however, the common feature observed in all affected limbs of such cortical bone grafted animals.

Rectal temperature, respiration and pulse rate did not alter during pre and post operative phages following calcium hydroxyapatite ceramic implants in segmental tibial defects in canine (Das and samanta, 1995).

2.3.2 Haematological observations

Fracture in femur bone treated with intramedullary metallic implants along with ultrasonography did not lead to any effect on various haematological parameters (Singh *et al.*, 1994b). Similarly inflammatory cells remained within normal physiological limits following treatment of tibial defects with calcium hydroxyapatite ceramics in dogs (Das and Samanta, 1995).

2.3.3 Radiographic observations

Radiography is an adjunct in assessment of fracture reduction, fixation and progressive evaluation of fracture healing (Newton and Nunamaker, 1985). Bisla *et al.* (1991) observed the periosteal reaction as early as on 15th post implantation day in adult goats with fresh cortical autograft whereras extent of periosteal reaction was less in fresh allografted and autoclaved xenografted animals. An extensive periosteal reaction with complete encasing of the graft was observed on 30th day following implantation of autograft and allograft. On the basis of roentgenological observations Singh *et al.* (1977) graded the different types of transplants in order of their merit as frozen, fresh, autoclaved and merthiolated cortical bone transplants. They further noted that the bone slot having no implant showed more new bone formation than the slots receiving any one of the implants. These observations were further confirmed by Parsanalli and Singh (1990) as they reported that the deep frozen grafts were replaced by new bone more rapidly as compared to autoclaved and decalcified allogenic bone grafts till 90 post operative day. Almost similar conclusion was drawn by Friedlaender *et al.* (1976) and Ulemale and Kulkarni (1992) with use of deep frozen bone grafts. However De-Bruyn and Kabisch (1955) reported poor bone formation with frozen transplants and opined that it might be due to destruction of living cells and consequent abscence of osteogenic cells. Singh (1978) observed complete bridging of fracture gap after 4 weeks following repair with homogenous bone plates.

Following radiography obtained at different intervals, Kramer *et al.* (1964) and Killey *et al.* (1966) recommended that anorganic bone grafts did not satisfy any of the properties of an ideal bone graft. Aithal *et al.* (1993) evaluated grafts viz. autogenous cortical, cancellous, frozen decalcified with autogenous marrow and ALCAP impregnated autogenous marrow and observed an early osseous union between autogenous cortical bone graft and the host bone on the basis of radiographic observations. Sastri *et al.* (1995) observed osseous union within 4-6 weeks in tibial defects of dogs following implantation with hydroxyapatite and fibrillar collagen.

2.3.4 Angiographic Observations

The blood supply to the healing bone is one of the important factors which influences the rate of healing with varying degree of vascularization at different stages of bone repair. Marchand (1901) seemed to be the first to study the vessels in the transplanted bone. Wray and Lynch (1959) established that periosteal and surrounding soft tissue vessels played an important role in the early stage of fracture healing. These vessels served an immediate source to early periosteal callus formation (Gothman, 1961). A sudden increase in the existing arterioles was reported in undisplaced fracture of radio ulna in dogs (Rhinelander and Bragery, 1962). Further, improvement of medullary and periosteal circulation resulted in rapid fracture healing (Kokenberg, 1963).

Deleu and Trueta (1965) reported a direct relationship between vascular supply and successful organisation of primary callus as well as its further development till the final stage of fracture repair. The organisation of callus was much greater with periosteal vessels than endosteal vessels.

Afferent vascular changes were studied for evaluation of fracture repair after bone transplantation (Sharma *et al.*, 1977). Singh *et al.* (1978) performed angiography in the metatarsal bone in bovine by infusing 15 to 20 ml of sodium iothalamate (70%) into the anterior tibial artery. Parsanalli (1988) carried out the angiography in the metatarsal and metacarpal of calves immediately after euthnesia by infusing freshly prepared lead oxide suspension (20%) in the metatarsal and metacarpal arteries respectively for better visualization of major and minute vascular branching.

Blood flow at the fracture site reached its maximum on tenth day and then gradually ebbed but not returned to normalcy at 120th day in the tibial fracture of canine (Paradis and Kelley, 1975). However near normal blood supply and reunion of medullary vessels was shown at six weeks after fracture of tibia in dogs (Pandiya *et al.*, 1977). Sharma *et al.* (1977) observed a state of hyperaemia upto 10th week following immobilization of tibial fracture of buffalo with metal or bone implants supported with plaster cast. The process of proliferation and reorganisation of medullary vessels was faster in fractures treated with bone plates than those immobilized with plaster of Paris alone (Singh, 1978).

Microangiographic technique demonstratred the dialatation and proliferation of periosteal/vascular network, derived mainly from torn soft tissue vessels in the vicinity of fracture during first week of fracture healing in dogs (Rhinelander, 1968 and Singh, 1976). Thereafter, the medullary circulation increased rapidly in both fracture fragments and played a major role in the blood supply of callus. Similarly early restoration of disturbed medullary circulation was observed in case of well reduced and immobilized fracture (Rhinelander, 1974).

When the different types of grafts were compared on the basis of success of revascularization, they were graded in order of merit as frozen, fresh, autoclaved and merthiolated preserved homogenous bone fraft (Singh *et al.*, 1978). Stringa (1957), Zeiss *et al.* (1960), Kingma and Hampe (1964) and Rhinelander (1972) reported slow vascularization in cortical bone grafted fractures. Fresh homografts revascularized more slowly than autografts of bone (Zeiss *et al.*, 1960 and Deleu and Trueta, 1965). Chalmers (1959) reported early vascularization of autografts in rats than in guinae-pigs.

2.3.5 Biochemical Studies

2.3.5.1 Blood Biochemistry

The serum concentration of calcium and phosphorus in normal adult cattle has been reported as 9-12 mg/100 ml and 4-12 mg/100 ml respectively (Banerjee, 1978). There was no alteration in the concentration of serum calcium between young and adult animals however serum organic phosphorus was quite variable in young animals (Kaneko, 1980). Observations of Parfitt (1965) suggested a decrease of about 15% in the level of serum phosphorus and about 3% in mean serum calcium concentration during treatment of osteoporosis with stilbestrol.

Lemaire (1966) and Laurnen and Kelly (1969) did not observe any change in serum calcium level during fracture healing in rats and dogs respectively. Henderson and Noble (1926) and Soliman and Hasan (1964) reported a low level of calcium and high level of phosphorus in serum in the days immediately following fracture. Ulemale and Kulkarni (1992) reported no considerable variations in the levels of calcium, inorganic phosphorus and alkaline phosphatase following implantation of deep frozen allogenic bone grafts in metacarpal fractures of calves at different time intervals till 28 days. Suresh Kumar (1994) did not record any significant rise in serum inorganic phosphorus and calcium during fracture repair of femoral defects with demineralized bone matrix, tricalcium phosphate, hydroxyapatite and cancellous bone grafts.

Serum alkaline phosphatase (ALP) acts as a good indicator of osteogenic activity in early stages of bone repair (Varshney *et al.*, 1991; Aithal *et al.*, 1995). Alkaline phosphatase enzyme activity was reported to be responsible for hydrolysis of phosphate esters resulting in a local increase of phosphate ions deposition of calcium phosphate ions in the bone matrix (Ali, 1980) removal of inhibitors of mineralization (Lewinson *et al.*, 1982). Aithal et al. (1995) observed increased serum alkaline phosphatase following metatarsal fracture repair with autogenous cancellous bone grafts in goats. A significant increase in serum concentration of alkaline phosphatase occured at 7 and 14 post implantation days during Cerosium ceramic repair of ulnar defects in dogs (Singh *et al.*, 1976). Similar observations were also recorded by Shirfin (1970) and Klein *et al.* (1964) in human beings. Suresh Kumar (1994) observed a significant increase in alkaline phosphatase values during femoral defect with demineralized bone matrix implants in canines. The peak value was observed at 3 weeks following fracture (Volpin *et al.*, 1986) in rats. On contrary, Botterell and King (1935) did not find any change in level during fracture repair in rabbits.

2.3.5.2 Tissue Calcium and Phosphorus.

The extent of mineralization has been related to the increased level of local tissue calcium in the bone (Reddy and Huggins, 1972). Bernick *et al.* (1989) observed a gradual increase in tissue calcium upto 16 weeks after implantation of demineralized bone in the subcutaneous sites in rats. However, they found a faster rate of calcium deposition between 2 to 4 weeks. In a study for the treatment of radio-carpal arthrodesis in dogs with the help of autogenous cancellous and allogenic demineralized bone matrix-hydroxyapatite-polyglycidyl methacrylate-gentamycin (ADBM-HA-PGMA-G) grafts, tissue calcium and phosphorous was significantly increased as compared to the control group where no grafts were applied (Naryanan 1993). Sastry (1989) measured a much higher calcium contents at the graft site between 4 to 6 weeks in demineralized bone matrix-hydroxyapatite-polyglycidyl methacrylate-gentamycin (DMB-HA-PGMA-G) grafts as compared to hydroxyapatite polyglycidyl methacrylate-Gentamycin (HA-PGMA-G) grafts.

2.3.5 Histological Changes

Bone biopsy is an invaluable asset for confirmatory diagnosis (Singh, 1967 and Harari, 1984) and evaluating the progress of bone healing (Narayanan *et al.*, 1995 and Vasanth and Ramakrishna, 1995) and orthopaedic diseases (Hierholzer *et al.*, 1974 and Walker *et al.*, 1975).

Malinin (1977) noticed fibroblastic and osteoblastic proliferation from periosteum along with irregularly formed thin cartilagenous plates in animals where no graft was used.

Braden and Brinker (1976) studied the fracture healing in dog and stated that cartilage formation occurred when cellular proliferation outpaced vascular regeneration. They further stated that the differentiation of primordial cells lining the endosteum and osteogenic cells depended on the rigid immobilization of the fracture fragments.

Charnley (1970) and Singh *et al.* (1981) used acrylic bone cement for healing of fracture in man and small ruminants, respectively. They observed a thick fibrous layer between the bone and the graft. There was no sign of bone resorption or any other inflammatory reaction at the site.

Ulemale and Kulkarni (1992) observed well developed bony tissue, deposition of osteoid matrix by osteoblasts, establishment of Haversian system and marked proliferation of osteoblasts and chondroblasts adjacant to the bone at 28 days following implantation of deep frozen allogenic bone grafts in metacarpal fracture of calves.

Mukherjee and Sahay (1992) observed marked cellularity with increased thickness of the newly formed bone trabeculae at 6 weeks following placement of the autologous bone marrow in the metacarpal fracture of goats. They further noticed increase in the compact substance due to increase of the Haversian system subsequently.

CHAPTER 3

MATERIALS AND METHODS

The present study was conducted in 18 apparently healthy corss bred male cow calves in the age group of 8 to 12 months with body weight ranging 60 to 90 Kg. The animals were stall fed and maintained under uniform managemental conditions during entire period of observation. All the animals were dewormed with fenbendazole* @ 5 mg/kg body weight prior to conduct of experiments. These animals were divided randomly into 2 groups of nine animals each to serve as control and treated (implanted) groups. In all the experimental animals simple complete midshaft transverse fractures of metatarsal bone were created.

3.1 Creation of Fracture and Management

After overnight fasting, the animals were sedated with intravenous infusion of 6% chloral hydrate @ 6 gm/ 50 kg body weight. They were secured in the left lateral recumbency. The site between hock and fetlock joints of the left limb was thoroughly scrubbed and shaved. Under local infilteration analgesia with 2% lignocaine hydrochloride, about 6 cm long incision was made on the medial aspect of metatarsal region taking all the aspetic precautions. The skin edges were retracted on either side exposing the bone. An incision was made on the periosteum and the same was retracted on either side. With an

---

* Panacur, Hoechst India Limited, Bombay, India.

embryotome wire, a complete midshaft transverse metatarsal fracture was created (Fig 1). The fractured edges of the bone were cleaned with normal saline and 3 cm long bioimplant* comprising of hydroxyapatite and fibrillar collagen was introduced after sterilizationinto the medullary cavity in the animals of group II, whereas no implant was used in the animals of control group 1.

The periosteum and subcutaneous tissue were sutured in continuous pattern using chromic catgut No. 2-0 and finally skin was closed with mattress sutures using black braided silk No.2. The fractured fragments of the metatarsus were immobilized by using plaster of Paris cast supported with aluminium splints on the anterior and posterior aspects of the limb. The hock and pastern joints were included in the plaster cast (Fig 2). The plaster was retained for 1 to 3 months depending upon the evaluation protocol. Postoperatively from the first day streptopenicillin 1 gm i/m was given daily for 7 days. Concentrates and green/ dry fodder and water were given to animals ad libitum.

The animals of group I and II were further subdivided into group A, B and C of 3 animals each for different studies at 15 and 30, 45 and 60 and 75 and 90 post operative days respectively.

3.2 Clinical Observations

Animals were clinically monitored for their general health condition,

---

* Maxibloc, Central Leather Research Institute, Madras.

Fig. 1 Photograph showing the creation of transverse fracture in the midshaft of metatarsal bone in calf.

Fig.2 Photograph showing the posture of the operated limb after immobilization of the fracture with plastic cast in calf.

feed intake and weight bearing capacity. The extent of weight bearing was categorised as - when there was flexion of hock without foot touching the ground, + when toe touched the ground with no weight bearing, ++ when sole touched the ground with slight weight bearing and +++ when foot touched the ground and exhibited no signs of lameness and were designated as nil, partial, moderate and complete weight bearing capacity respectively.

Rectal temperature, respiration and cardiac rates were recorded before and after 15, 30, 45, 60, 75 and 90 days of fracture in group I and II.

3.3 Haematological Studies

About 5 ml of blood was collected from external jugular vein in heparinised rinsed vials before and after 15, 30, 45, 60, 75 and 90 days of fracture in the animals of group I and II. Half of the blood was immediately analysed for total erythrocyte count (TEC), total leucocyte count (TLC) and differential leucocyte count (DLC) as per the methods described by Jain (1986). For DLC, the slides were stained with Leishman's stain.

Rest half of the blood was used for separation of plasma for biochemical analysis (vide infra).

3.4 Radiographic Studies

Plain radiographs of the fractured limb were taken in mediolateral and dorsoplantar views at 0, 15, 30, 45, 60, 75 and 90 days after fracture in group I and II with constant exposure factors of 10mAs, 72 kVp and 90 cm FFD. The radiographs were studied for evaluation of periosteal, cortical and endosteal callus formation, soft tissue density, bridging of fracture gap, status of dissolution of graft and infection, if any, around the fracture site etc.

3.5 Angiographic Studies

Angiograms of the operated limb were obtained at 0, 30, 60 and 90 days after the fracture in the animals of group I and II to evaluate the course, number, contour and calibre of the arterial vessels supplying the fractured area to assess the amount of blood supply at the site. Angiogram of normal limb was also taken to compare the study with the normal vascular pattern.

For angiographic study, a skin incision about 4 to 5 cm long was made on the medial aspect of thigh under chloral hydrate sedation with local infilteration of 2% lignocaine hydrochloride. The deep femoral artery in the proximal two thirds on the medial aspect of thigh (femur) was identified, exteriorised and canulated with the help of IV Canula before clamping the femoral artery. The plastic canula was pushed downward into the artery and a tight ligature was applied around the artery and the canula so as to prevent any leakage of blood from the artery. An elastic torniquette was applied in the proximal part of thigh to prevent retrograde flow of the contrast medium. A syringe containing 20 ml sodium iothalamate* (70%) was connected with the canula. The contrast material was infused with a regular gentle digital pressure

---

* Conray 420, Rhone Poulene (India) Ltd., Bombay, India.

and dorsoplanter and mediolateral radiographic views were exposed immediately at constant exposure factors 10 mAs, 72 kVp and 90 cm FFD. Torniquette was released and then the canula was removed and the punctured part was sutured using 4-0 chromic catgut. Both ligature and clamp placed earlier, were removed from the femoral artery and skin wound was closed.

For better visualization of arteries, one test limb from each group was perfused with lead oxide soap suspension (20% w/v) in the similar manner. The animal was euthenised and disposed off after collection of material for detailed histopathological evaluation.

3.6 Biochemical Studies

3.6.1 Blood Biochemistry

Remaining blood (vide supra) after utilizing the haematological parameters, was subjected to centrifugation for separation of plasma at 2000 revolution per minute (rpm) for 5 minutes.

Plasma was collected in glass vials and stored at -20°C until analysis within fortnight. The plasma alkaline phosphatase (u/l), calcium (mg/dl) and phosphorus (mg/dl) were estimated with the help of semi-auto analyzer* using standard diagnostic kits**.

3.6.2 Estimation of Tissue Calcium and Phosphorus

Following angiography of the limb; a full thickness bone piece of 1 cm (circumference) x 1/2 cm (width) was collected from the fractured site under

---

* SEAC CH-100 Semi-auto blood analyzer, Miles India Ltd. Baroda, India.
** Miles India Ltd., Baroda, India.

local infiltration analgesia (or immediately after euthenasia) on 30, 60 and 90 days of fracture in group I and II. The tissue was directly transferred to 10% neutral bufferred formalin for estimation of tissue calcium and phosphorus (and histological processing). Tissue was washed and blotted dry. Then 100 mg of bone tissue was collected and dissolved completely in 5-10 ml of hydrochloric acid (HCl) by boiling. After complete digestion the samples were diluted to 100 ml by adding deionised water and used for analysis of calcium and phosphorous by semi-auto analyser using standard diagnostic kits. The results were expressed in milligram/gram of bone (mg/gm).

3.7 Histological Studies

Tissue already preserved in formalin was washed . The bone tissues were decalcified using electrolytic method (Luna, 1968), processed for paraffin sectioning. Ten micron thick sections were obtained and stained with Haemotoxylin and Eosine method (H & E).

3.9 Statistical analysis

The data were analysed at 5% level of significance by using Paired 't' test to compare the results between the groups and within the group respectively (Snedecor and Cochran, 1967).

3.10 Clinical Evaluation of Bioimplant

Two female calves of 9 months and 1 year age respectively, were presented to the College Clinics with history of fresh complete oblique midshaft metatarsal fracture. These fractures were managed by open reduction under 6% chloral hydrate sedation and local infiltration analgesia with 2% lignocaine hydrochloride. A 3 cm long hydroxyapatite-fibrillar collagen implant was placed in the medullary cavity at fracture site. External immobilization of the fractured limb and therapeutic protocol, thereafter, remained same as adopted in the animals of experimental groups.

CHAPTER 4

EXPERIMENTAL RESULTS

4.1 Clinical Observations

The weight bearing capacity was initially affected in the animals of both groups after fracture repair. Immediately after fracture immobilization of fractured limb, all the animals required physical assistance for getting up and they were reluctant to move. The animals of both the groups were unable to bear weight on affected limb. The weight bearing returned partially after 15 days of fracture repair in the animals of group I and II (Table 1). After fracture immobilization, all animals of the group I showed partial to moderate weight bearing of affected limb upto 75th day, however, the same extent of weight bearing was noticed upto 45th day in group II animals. In one animal of group II, complete restoration of weight bearing was achieved on 60th day of fracture repair, whereas, it was observed in one of the animals of control group on 90th day. The remaining two animals of group I and group II showed moderate lameness till 90 and 60 days of fracture respectively. All animals of implanted group II restored complete weight bearing on 90th day of fracture repair. A slight to moderate muscular atrophy was evident after removal of plaster cast at 90 days in the animals of implanted and control group.

The mean values of rectal temperature, respiration rate and cardiac rate at different time intervals in group I and II are presented in Table 2. The rectal temperature remained within normal range (101.2 ± 0.30 to 102.07 ± 0.27 °F) throughout the period of observation in the animals of control group I.

Table 1. Weight bearing capacity during fracture repair with and without hydroxyapatite-fibrillar collagen implants in calves (Mean ± SE)

Animals	Before fracture	Days after fracture					
	0 Day	15	30	45	60	75	90
Group I							
1	+++	+	+	+	++	++	++
2	+++	+	++	++	++	++	+++
3	+++	+	++	++	++	++	++
Group II							
1	+++	+	++	++	+++	+++	+++
2	+++	+	+	++	++	+++	+++
3	+++	+	++	++	++	++	+++

Group I - Control
Group I - Treated with hydroxyapatite - fibrillar collagen implant

+	Partial weight bearing
++	Moderate weight bearing
+++	Complete weight bearing

However, the maximum value was recorded at 75 post fracture day. A similar trend was observed in the animals of implanted group II except at 75 days where the rectal temperature significantly increased as compared to before fracture value. No significant variation was noticed on comparative basis between group I and II.

Respiration rate did not show significant variation at any stage of observation though there was tendency to increase at 75 and 90 post fracture days in the animals of group I. In group II, the values of respiration rate did not vary significantly during post fracture period from that of 0 day value and remained within normal physiological limits. However, slightly higher values of respiration rate were recorded at 45 and 90 post fracture days. Both the treatments were found to be equally effective on the basis of respiration rate at different intervals of observation.

Cardiac rate did not reveal any significant alteration in the animals of group I and group II at any of the post fracture intervals when compared to 0 day value. Similarly on comparative basis, no significant variation in heart rate was observed following fracture repair in the animals of group I and II. General condition and feed intake remained normal throughout the period of experimentation in the animals of group I and group II.

4.2 Haematological Observations

The values (Mean ± SE) of total erythrocyte count (TEC), total leucocyte count (TLC) and differential leucocyte count (DLC) following

Table 2. Rectal temperature, respiration rate and cardiac rate during fracture repair with and without hydroxyapatite-fibrillar collagen implants in calves (Mean ± SE)

	Parameters	Group	Before fracture	Days after fracture					
			0 Day	15	30	45	60	75	90
1	Rectal Temperature (°F)	I	101.4 ± 0.35	101.4 ±0.30	101.2 ±0.30	102.0 ±0.30	101.5 ±0.13	102.0 ±0.29	101.3 ±0.27
		II	100.6 ±0.30	101.7 ±0.18	101.4 ±0.50	101.5 ±0.37	101.7 ±0.18	101.9 ±0.13^{b}	101.4 ±0.12
2.	Respiration rate (per minute)	I	20.0 ±2.31	20.67 ±1.76	19.33 ±0.67	19.33 ±1.76	20.0 ±1.15	22.0 ±2.0	24.67 ±2.40
		II	19.33 ± 2.40	21.33 ±1.33	19.33 ±1.76	21.33 ±0.67	19.0 ±1.00	19.33 ±1.33	21.33 ±0.67
3.	Cardiac rate (per minute)	I	74.67 ± 7.06	77.33 ±5.81	78.0 ±5.03	78.67 ±3.53	74.0 ±3.46	72.67 ±4.37	74.0 ±4.16
		II	75.33 ±4.67	78.67 ±5.81	74.67 ±5.81	73.33 ±2.90	78.0 ±5.29	72.67 ±2.90	70.67 ±1.33

Group I - Control
Group I - Treated with hydroxyapatite - fibrillar collagen implant
$b < 0.05$ within group when compared to 0 day value
Values differ significantly when bearing different superscripts

Table 3. Total erythrocyte count, total leucocyte count and differential leucocyte count during fracture repair with and without hydroxyapatite-fibrillar collagen implants in calves (Mean ± SE)

S. N.	Parameters	Group	Before fracture 0 Day	Days after fracture 15	30	45	60	75	90
1.	Total erythrocyte count (10^6/cmm)	I	7.16 ±1.46	5.06 ±0.46	4.87 ±0.32	6.37 ±0.82	5.84 ±0.38	6.84 ±0.42	5.77 ±0.15
		II	6.29 ±0.35	6.49 ±1.18	5.48 ±0.39^{b}	5.18 ±0.28	5.17 ±1.02	4.95 ±0.09^{by}	5.24 ±0.07
2.	Total leucocyte count (10^3/cmm)	I	9.03 +0.71	11.30± 1 43	8.88 ±0.61	9.60 ±0.44	9.2 ±1.40	8.8 ±0.33	8.93 ±0.59
		II	8.65 ±1.09	8.40 ±1.14	9.43 ±1.08	8.23 ±1.20	8.5 ±1.1	9.65 ±0.96	8.92 ±0.44
3.	Differential leucocyte count								
a)	Lymphocyte (%)	I	84.67 ±6.36	83.67 ±2.03	80.0 ±2.08	73.0 ±3.21	80.67 ±1.20	69.33 ±1.45	79.0 ±2.52
		II	85.33 ±4.33	81.67 ±5.49	73.0 ±4.62	79.67 ±2.40	79.67 ±2.03	76.0 ±2.0	75.67 ±4.91
b)	Neutrophils (%)	I	13.0 ±7.37	14.0 ±0.58	18.67 ±2.18	25.0 ±3.51	16.0 ±1.45	29.0 ±1.53	19.33 ±2.33
		II	13.67 ±3.76	18.0 ±5.20	24.33 ±5.78	18.67 ±1.45	18.33 ±1.86	21.67 ±0.67	23.0 ±4.04
c)	Eosinophils (%)	I	1.0 ±1.0	0.0 ±0.0	0.33 ±0.33	0.67 ±0.67	0.33 ±0.33	1.1.0	1.0 ±0.98
		II	0.0 ±0.0	0.0 ±0.0	1.33 ±1.33	0.67 ±0.33	1.67 ±0.33	1.0 ±0.0	0.33 ±0.33
d)	Basophils (%)	I	0.0 ±0.0	0.33 ±0.33	0.0 ±0.0	0.0 ±0.0	0.33 ±0.33	0.67 ±0.6	0.0 ±0.0
		II	0.0 ±0.0	0.33 ±0.33	0.67 ±0.67	0.67 ±0.67	1.67 ±0 33	0.67 ±0.67	0.0 ±0.0
e)	Monocytes (%)	I	1.33 ±0.88	0.0 ±0.0	1.0 ±0.58	1.0 ±0.58	0.67 ±0.33	0.0 ±0.0	1.0 ±0.58
		II	1.0 ±0.58	0.0 ±0.0	0.67 ±0.33	0.33 ±0.33	0.0 ±0.0	0.67 ±0.67	1.0 ±0.58

Group I - Control

Group I - Treated with hydroxyapatite - fibrillar collagen implant

b< 0.05 within group when compared to 0 day value

y < 0.05 Between groups at respective intervals

Values b differ significantly when bearing different superscripts fracture repair with and without hydroxyapatite - fibrillar implant are presented in Table 3. A constant decreasing trend was noticed in the TEC values upto 75 days, thereafter the values slightly increased. TEC values were decreased significantly at 30 and 75 days. However these values did not deviate from the normal physiological limits.The TEC value had been significantly lower in group II than group I on 75 days after the repair of fracture.

Total leucocyte count (TLC) remained within normal range in animals of group I (8.80 ± 0.33 to 11.3 ± 1.43 thousand/mm^3) and group II (8.23 ± 1.20 to 9.65 ± 0.95 thousand/ mm^3) at different time intervals before and after repair of fracture. These values remained although unaltered at various time intervals in both the groups

Post fracture repair values of lymphocyte in group I and II remained non-significantly lower throughout the period of experimentation when compared to before fracture lymphocyte value. The decrease in lymphocyte count was maximum at 75 and 30 days in group I and II respectively. The lymphocyte count at different time intervals in group I and II did not significantly alter. Almost reverse pattern of the neutrophil values was observed. The intensity of neutrophilia was more on 75 and 30 days in group I and II respectively as compared to 0 day value. The minor lymphopenia and neutrophilia which occured however did not cross the normal physiological limits. Eosinophil, Basophil and monocyte counts remained nonsignificantly varied when compared to respective 0 day values within the group as well as between the groups at different time intervals.

4.3 Radiological Changes

At 15 days, the fractured segments of metatarsi were in opposition but the fracture gap was discernible with hazy appearance (Fig 3). However, mild periosteal and endosteal reactions were evident in animals of group I. In group II, the radiographs revealed perfect alignment of proximal and distal metatarsal segments (Fig 4). Periosteal and endosteal reactions at the fracture site were comparatively more evident than control. The fracture gap was reduced. The radio-opaque graft was visible in the medullary cavity at the fracture site.

At 30 days, the two fragments of fractured metatarsal were found to be perfectly aligned without any angulation in animals of both control and implanted groups. Areas of increased density were elicited slightly at the periphery of the periosteal and endosteal surfaces and inbetween the cortices at the fractured site in the animals of group I (Fig 5). The radiolucent fracture line was visible. In implanted group of animals, there was a marked evidence of periosteal, cortical and endosteal reactions at the fracture site. A line of increased density was visible along the opposite ends of the fractured bone. The radio-opacity of graft was visible in the medullary cavity at the fracture site (Fig 6).

At 45 days, intercortical callus with reduction of fracture gap was noticed in group I (Fig 7). Areas of increased density were more marked along the endosteal surfaces as compared to the periosteal surfaces at the fracture site. The radiolucent fracture line was still visible. In animals of group II, the fracture gap was completely bridged and the extent of endosteal callus (Fig 8) was more than that of periosteal callus. Implant had started to be resorbed.

At 60 days, the osseous callus along the periosteal and endosteal surfaces was evident in group I (Fig 9). The two bone segments were in perfect alignment. However, fracture line was faintly visible. The animals of group II showed increased density at the fracture site with formation of periosteal and endosteal osseous callus (Fig 10). The medullary cavity was found to have started maintaining its continuity. The thickening of the cortex at the fracture site was more as a result of osseous callus. The process of issolution and fragmentation of hydroxyapatite-fibrillar collagen implant continued at this stage with radiolucency of the medullary canal at the fracture site.

At 75 days, the fracture line was faintly visible in one animal of control group on one side of the cortex (Fig 11) whereas in rest of the two animals, the fracture union was complete and the fractured ends of the apposed cortex were bridged with intercortical callus. The two fragments of bone were in opposition. Periosteal and endosteal calluses were discernible. The animals of implanted group revealed complete healing of fracture gap with endosteal and intercortical osseous callus (Fig 12). There was thickening of the cortex at the fracture site. Graft was found to be completely resorbed. Restoration of continuity of medullary cavity was achieved.

At 90 days, there was complete osseous union in the animals of control group as formation of callus was evident by radiodense area in the midshaft region at the fracture site (Fig 13). The extra callus had not started

Fig.3 Mediolateral radiograph of metatarsal of calf at 15 days showing mild periosteal and endosteal reaction (Control).

Fig.4 Dorsoplantar radiograph of metatarsal of calf at 15 days depicting proper alignment of the fracture, fragments periosteal and endosteal reaction. The implant is also visilble in the medulary cavity. (Implanted)

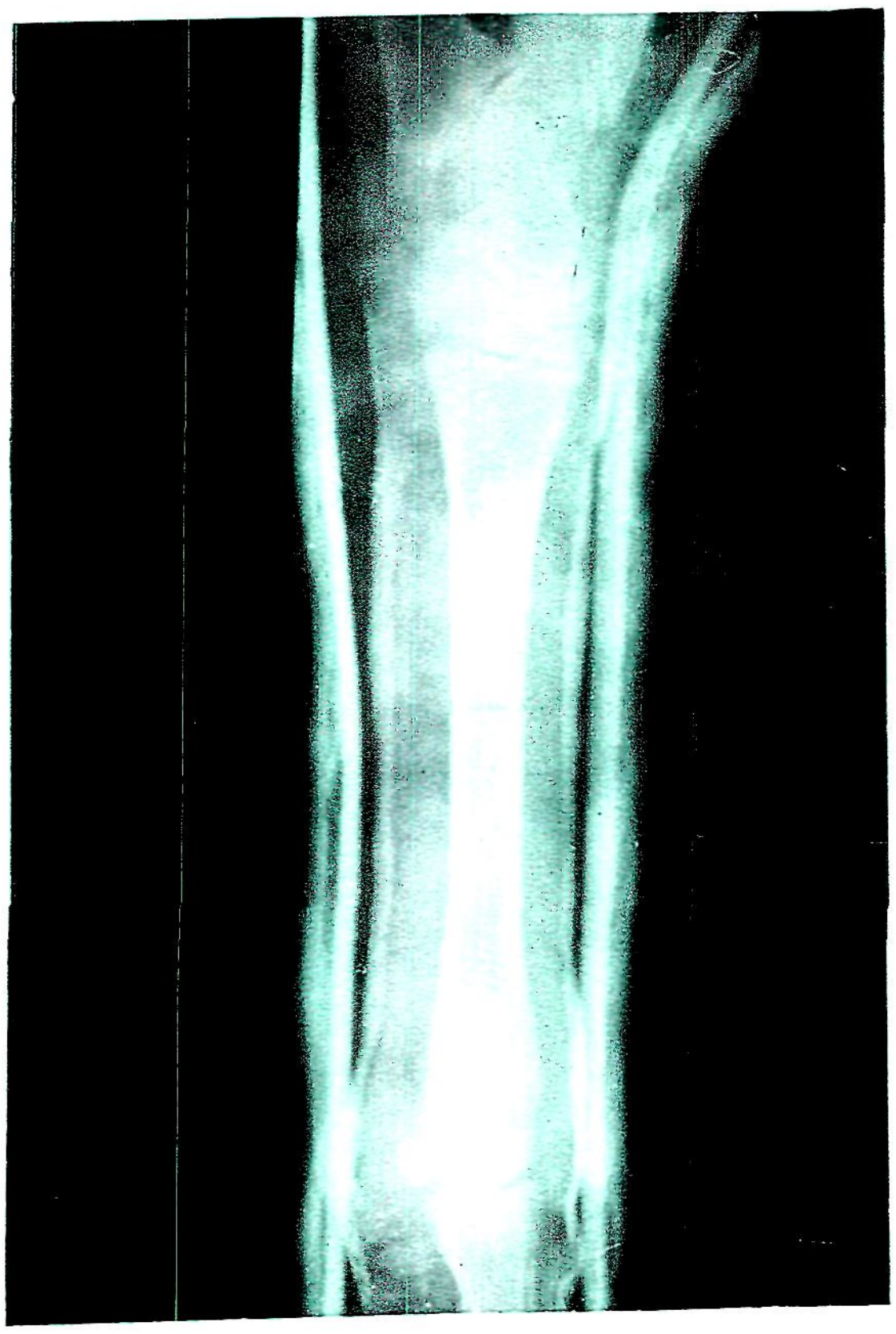

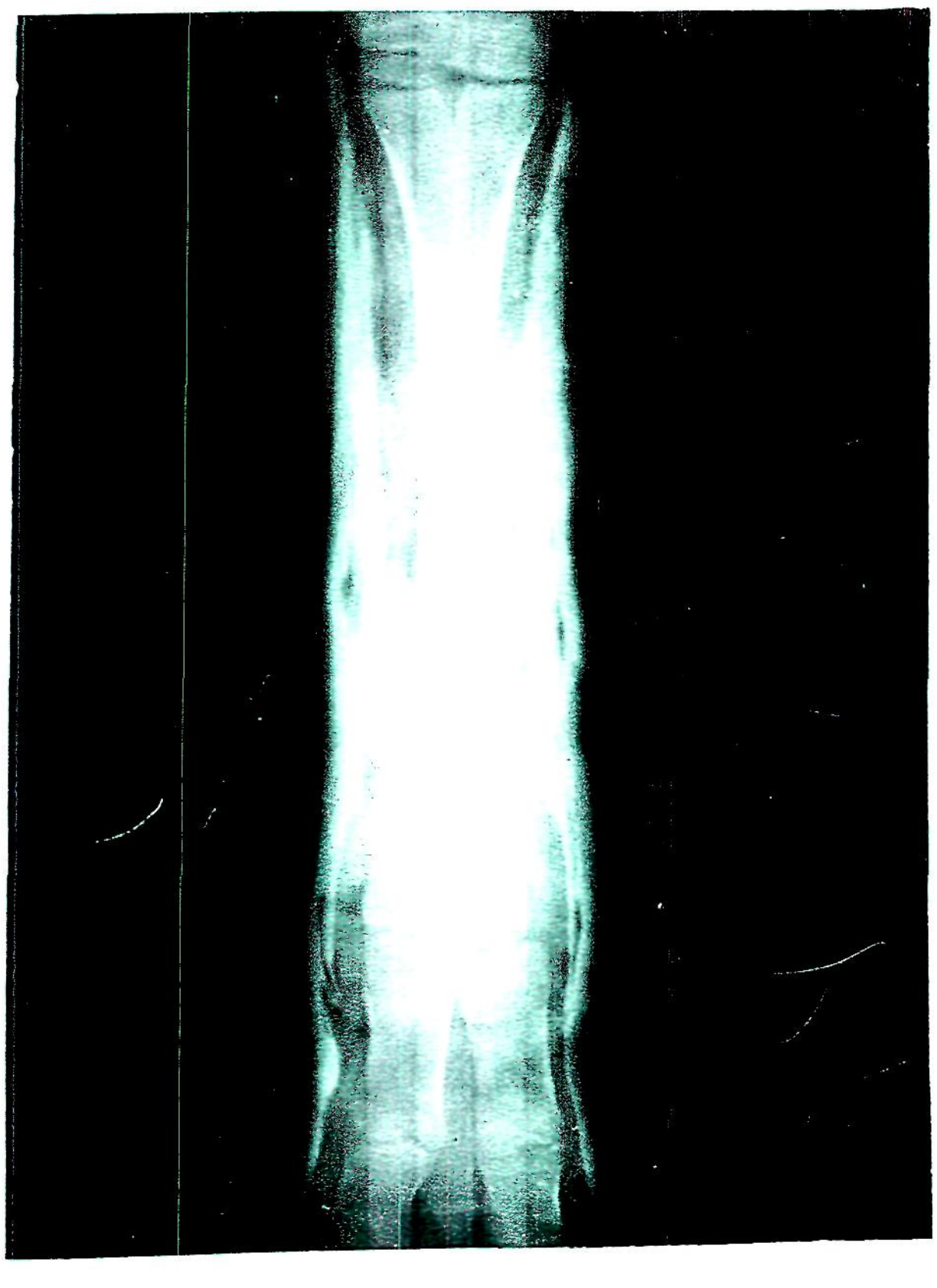

Fig.5 Dorsoplantar radiograph of metatarsal of calf at 30 days eliciting areas of increased density at the periphery of periosteal, endosteal and in between the cortics. (Control)

Fig.6 Mediolateral radiograph of metatarsal of calf at 30 days showing periosteal, cortical and endosteal reactions at the fracture site. The implant is discernible.(Implanted)

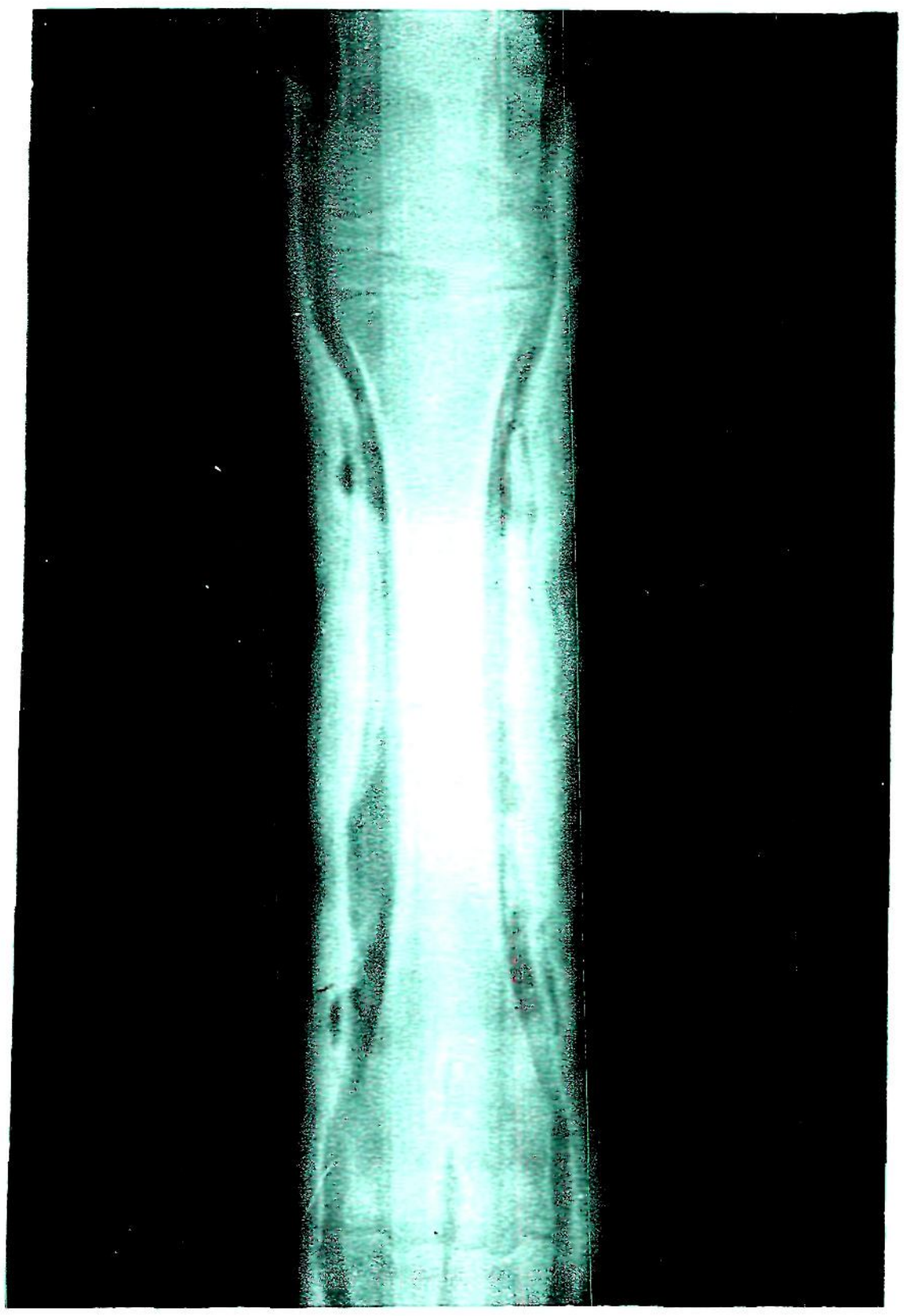

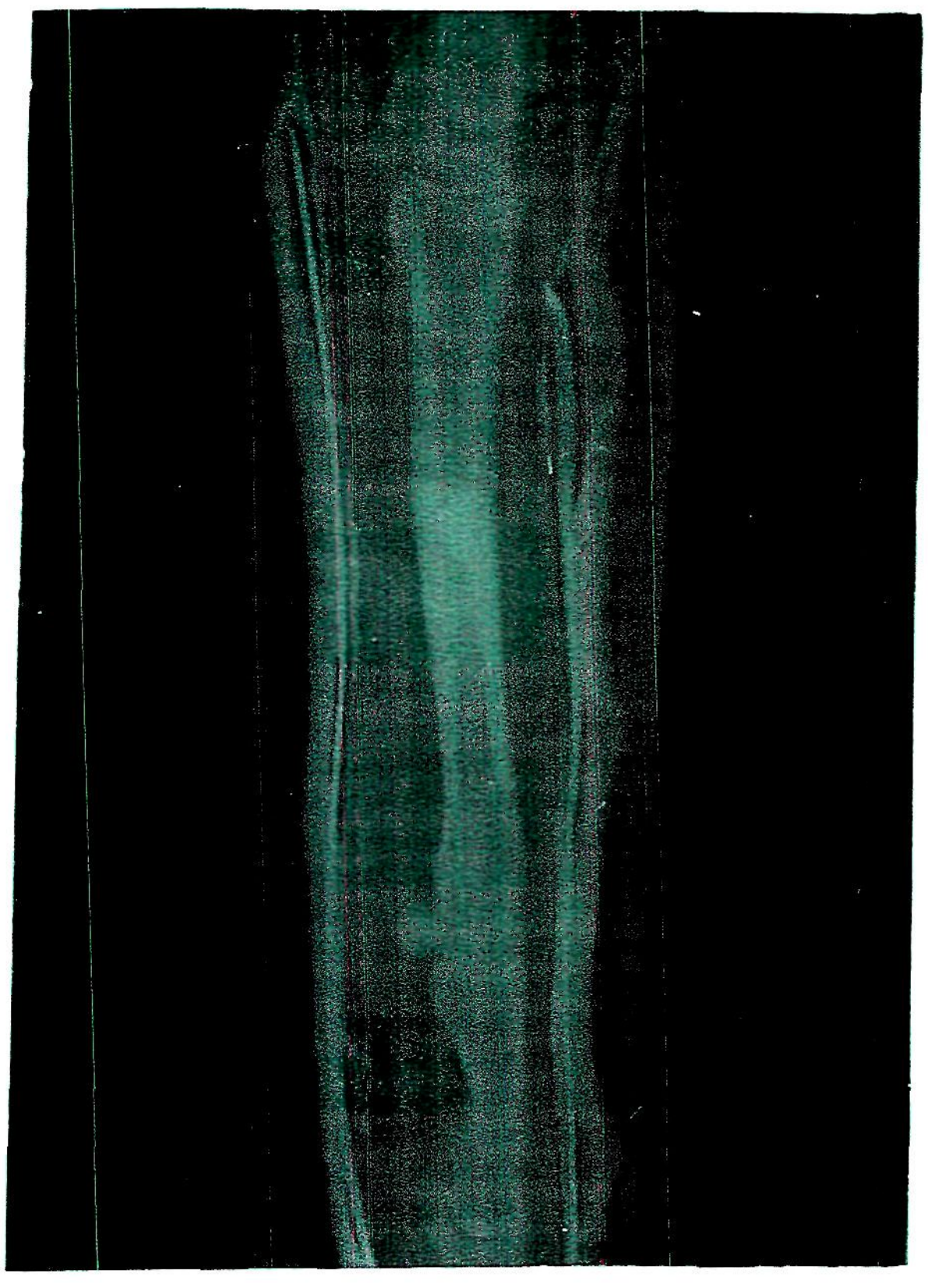

Fig. 7 Dorsoplantar radiograph of metatarsal of calf at 45 days depicting areas of increased density along the endosteal surface but fracture line is visible. (Control)

Fig. 8 Dorsoplantar radiograph of metatarsal of calf at 45 days showing complete bridging of the fracture gap with periosteal and endosteal calluses and the implant has started absorbing. (Implant)

Fig.9 Dorsoplantar radiograph of metatarsal of calf at 60 days showing formation of periosteal and endosteal osseous calluses. Faint fracture line is evident. (Control)

Fig.10 Mediolateral radiograph of metatarsal of calf at 60 days depicting the bridging of fracture gap with osseous callus, the cortex at the fracture site is thickened, the medullary cavity has started retaining continuity. (Implanted)



Fig. 11 Dorsoplantar radiograph of metatarsal of calf at 75 days, elicting the bridging of the fractured fragments with intercortical callus. (Control)

Fig. 12 Mediolateral radiograph of metatarsal of calf at 75 days depicting complete resorption of the implant, bridging of the fracture gap and restoration fo continuity of the medullary cavity.(Implanted)

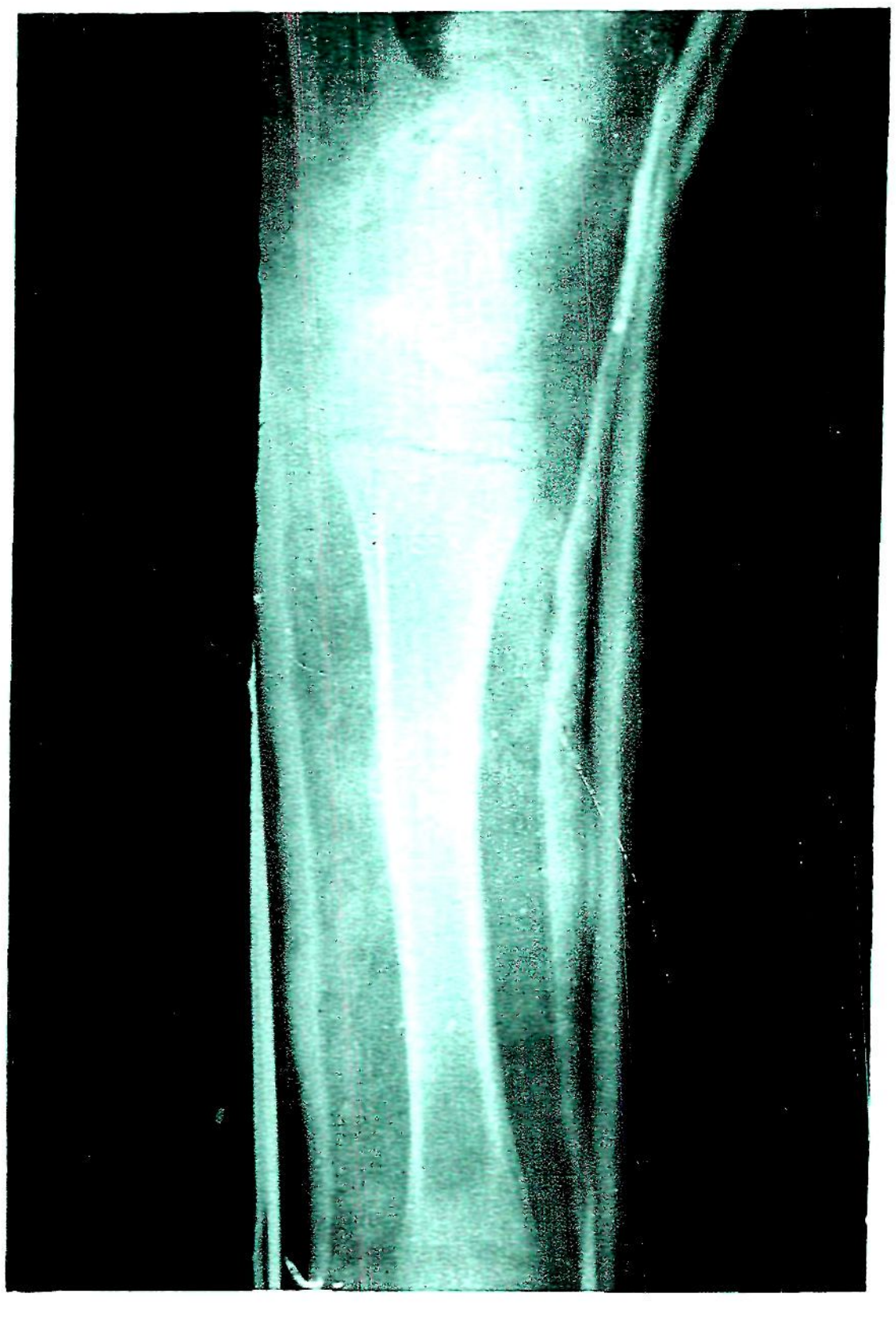

Fig. 13 Dorsoplantar radiograph of metatarsal of calf at 90days showing radiodense area in the mid shaft region, the cortex at the fracture site is thickened.(Control)

Fig. 14 Mediolateral radiograph of metatarsal of calf at 90 days eliciting the initiation of remodelling process. The thickness of the cortex is decreased to its normal contour at the fracture site. (Implanted)

remodelling. The thickness of the cortex at the fracture site was more marked. The continuity of medullary canal was partially obliterated with the presence of endosteal callus at the fracture site. In group II, the endosteal and periosteal callus had started the process of remodelling and the thickness of the cortex had decreased to its normal contour at the fracture site (Fig 14).

4.4 Angiographic Observations

Normal Control Angiogram

The metatarsal region of the pes showed dorsal metatarsal, superficial plantar metatarsal and deep plantar metatarsal arteries. The perforating branches of the dorsal metatarsal joined the deep plantar metatarsal in the proximal epiphyseal and distal metaphyseal regions. From the proximal perforating artery intramedullary arteries supplied the spongy substance of the proximal metaphysis and diaphysis. A number of minute branches emanated from the dorsal metatarsal supplied to soft tissue including skin and the subcutis of the area. On the plantar aspect two plantar metatarsal arteries lay parallel antero-posteriorly along the plantar aspect of the metatarsal bone separated by means of a small gap. Fine branches emanating from two arteries formed anastomosing channel into the soft tissue in between. Superficial soft tissue including skin were principally received arterial flow through fine channels arising from superficial plantar metatarsal artery (Fig 15).

Control 30 days

Major vascular channels described in the normal contour were maintained. The notable feature was the increased fibrovascular reaction (soft tissue and vascular proliferation) at the site of fracture (Fig 16). The periosteum was extremely thickened with increased vascularity. Microvascular pattern of the periosteum revealed minute extravasation of the injection material in the periosteum. The vascular reaction was more prominent in the proximal fragment of the fracture than in the distal one. A mild increased density along the periphery of the fracture site with variable opacities indicated the accumulation of the temporary callus which were duly vascularised. Intramedullary vessels in the proximal segment of the fractured bone became very prominent. They showed character of dilatation and proliferation. In the distal segment of the fracture, however, the vessels appeared thinner, less prominent and less branching as compared to the proximal segment more or less stellate but for in the region of metepiphysis where fine vascular channels appeared to have increased over the normal control group.

Fracture Treated 30 days

In the angiogram of treated pes of the animals of 30 days after implant, the general picture simulated with the control group as described. The distinctive feature, however, included the extravasation of injection fluid at the site of implant and growth of collateral circulation from the dorsal metatarsal artery in the proximal stump of the fracture. The fibrovascular proliferative reaction was not as prominent as in the control group. Intramedullary channel of the proximal stump compared with normal control group. In the distal metepiphyseal region, however there were few minute sites of injection material diffusion indicating the course of neovasculogenesis. Very minute vascular channel could be demarcated along the endosteal channel particularly near the site of implant (Fig 17). Periosteal vasculature formation was discernible at the graft site along the opposing segments of the fractured metatarsal. The graft site was identifiable as 3 cm long slightly radio-opaque area against the marrow density in which very fine capillarization and droplet extravasation of the fluid was identified (in the mid shaft region). A small area of increased density along the apposite ends of the bone revealed establishment of small callus and minute extravasation of injection fluid revealed establishment of vascular channels into the implant and the apposing ends of the fracture.

60 days Control

Major vascular channels remained intact. The intramedullary channels of the proximal stump were very prominently discernible. Vascular channels within the spongy bone of metepiphysis and diaphysis region of the proximal segment were marked with proliferated vascular channels some of which were newly formed as indicated by extravasated injection fluid. Periosteal and endosteal vessels were sharply marked. The periosteal swelling observed at 30 days had subsided. Rather the compact substance of the bone appeared to have grown slightly. Cortical vasculature was very clearly marked particularly at the fracture site and above it (Fig 18). Intra and extra medullary channels of distal segment showed reduced crisscrossing as compared to 30 day group revealing a reduced vascular proliferative reaction in the distal segment.

60 days (Treated)

The treated specimen revealed increased vascular proliferative reaction in the intramedullary endosteal, cortical and periosteal regions. The fine net work of the periosteal region were highly significant observation at this stage. A complex network of the vascular channel proximal to the implant site, at the implant site and distal to the implant site were the notable features. The implant site was clearly observed as radiolucent area in the metatarsal shaft (Fig 19). The implant was also in the process of dissolution and fragmentation. The metatarsal septum was identifiable in the proximal and distal metaphysis but in the midshaft region it appeared to have been dissolved. Instead the implant which was extremely vascularised at the site was a distinctive feature in 60 day angiograph.

90 days (Control)

Angiograms revealed the extrametatarsal and intrametatarsal vasculature as in normal control. The periosteal vasculature was clearly evident in the proximal (more) and distal (slightly less) segments of the fractured bone. The callus formation was evident as a radio-dense area in the midshaft region (Fig 20). Vascularization of the callus was also evident. Endosteal vasculature was comparatively deficient on either side of the callus. Minute extravasations were also seen in the cortical tissue at the point of fracture.

Fig.15 Positive angiogram (Mediolateral View) of metatarsal region of calf.

Normal-control

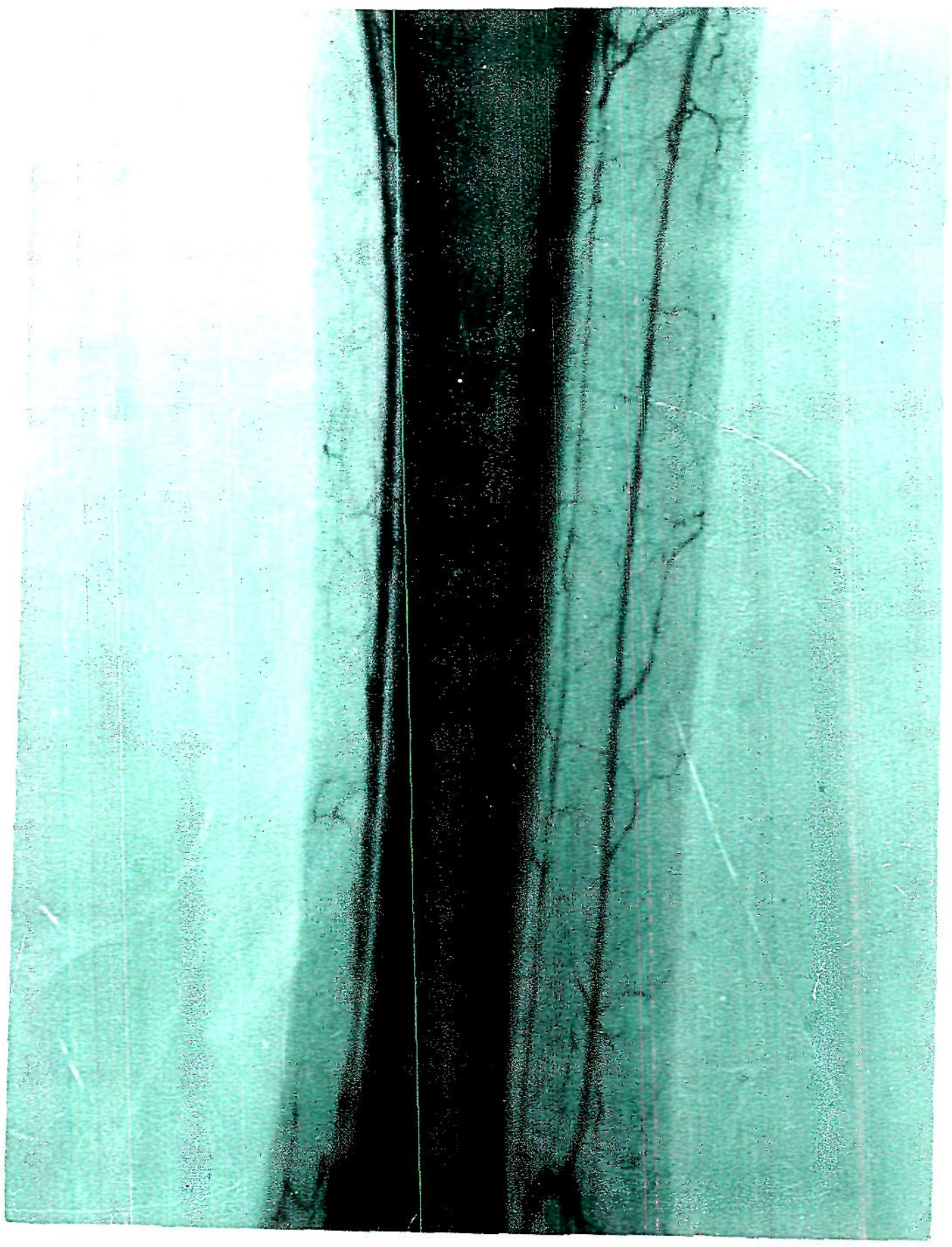

Fig. 16 Positive angiogram (dorsoplantar View) of metatarsal region of calf.

Fracutred control-30 days

Fig. 17 Positive angiogram (mediolateral view) of metatarsal region of calf.

Fratured Treated-30 days

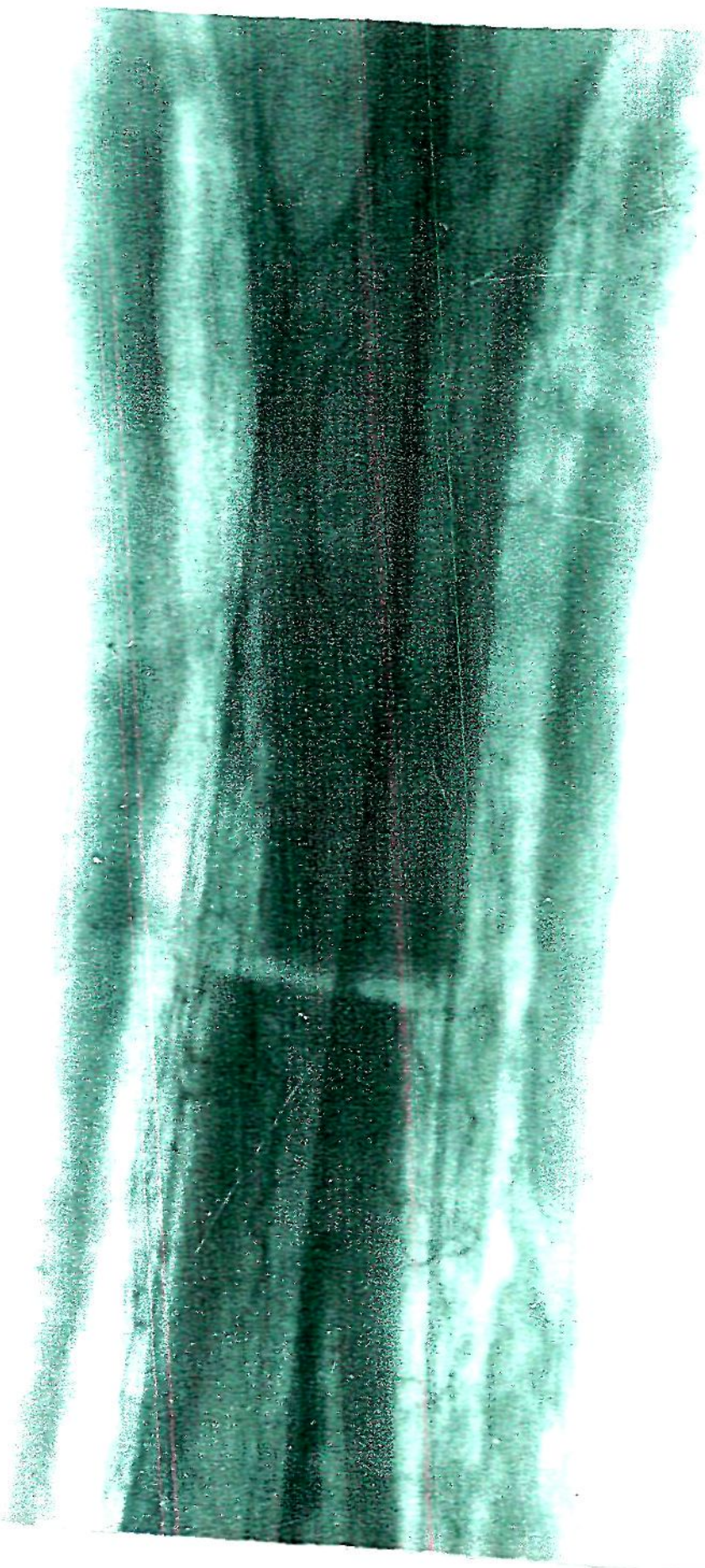



Fig. 18 Positive angiogram (dorsoplantar view) of metatarsal region of calf.

Fractured treated -60 days

Fig. 19 Positive angiogram (dorsoplantar view) of metatarsal region of calf.

Fractured control-60 days



Fig.20 Positive angiogram (mediolateral view) of metatarsal region of calf.

Fractured control-90 days

Fig.21 Positive angiogram (mediolateral view) of metatarsal region of calf.

Fractured Treated-90 days



90 days (Treated)

The angiograms revealed the established vascular pattern of the metatarsal region of the limb. Intraosseous and extraosseous vasculatures were well established. Periosteal, endosteal, intramedullary channels were well formed and clearly discernible without the extravasation of fluid. Fracture site was, however, slightly more dense as compared to its proximal and distal segments. Metepiphyseal vasculature was particularly well marked. Endosteal channels were continuous. At the fracture site, the collateral circulation was well established, highly branching arterial tree spread up into the periosteum, cortices, endosteum in the grafted area (Fig 21). However, some fine branches showed a little beaded appearance probably indicative of weakness in the wall of the newly formed channels.

4.5 Biochemical Findings

4.5.1 Blood Biochemistry

The mean values of plasma inorganic calcium, inorganic phosphorus and alkaline phosphatase (ALP) following fracture repair with and without hydroxyapatite-fibrillar collagen implant are presented in Table 4 and Fig 22. The inorganic calcium values after fracture repair in group I remained nonsignificantly higher than before fracture value (0 day) at different time intervals except at 90 days where the calcium level was slightly lower than that of 0 day level. The maximum concentration of calcium was recorded at 30th day following fracture repair in animals of group I. In the animals of group II,

Table 4. Plasma calcium, phosphorus and alkaline phosphatase levels during fracture repair with and without hydroxyapatite-fibrillar collagen implants in calves (Mean ± SE)

	Parameters	Group	Before fracture 0 Day	Days after fracture					
				15	30	45	60	75	90
1	Calcium (mg/dl)	I	7.93 ±0.94	9.30 ±0.42	10.5 ±0.21	9.27 ±0.30	9.07 ±0.59	8.20 ±0.40	7.5 ±0.
		II	8.63 ±2.12	7.90 ±2.27	6.40 $\pm0.66^{y}$	9.50 ±0.40	9.43 ±0.64	9.10 ±1.01	9.3 ±0.
2	Phosphorus (mg/dl)	I	4.07 ±0.66	4.90 ±0.99	4.73 ±0.47	5.56 ±1.36	6.17 ±1.86	4.03 ±0.73	3.7 ±0.
		II	4.17 ±1.27	4.85 ±0.70	5.93 $\pm1.38^{y}$	4.62 ±0.90	4.42 ±0.16	4.07 ±0.27	4.0 ±0.
3	Alkaline phosphatase (u/l)	I	113.67 ±35.31	89.0 ±15.5	113.33 ±15.98	120.0 ±17.62	127.0 ±20.82	82.0 ±2.31	91. ±7.
		II	87.33 ±12.13	96.33 ±46.19	91.66 ±3.93	72.0 ±25.81	79.33 ±11.86	88.33 ±9.67	89. ±0.

Group I - Control
Group I - Treated with hydroxyapatite - fibrillar collagen implant
$y < 0.05$ Between groups at respective intervals
Values differ significantly when bearing different superscrips

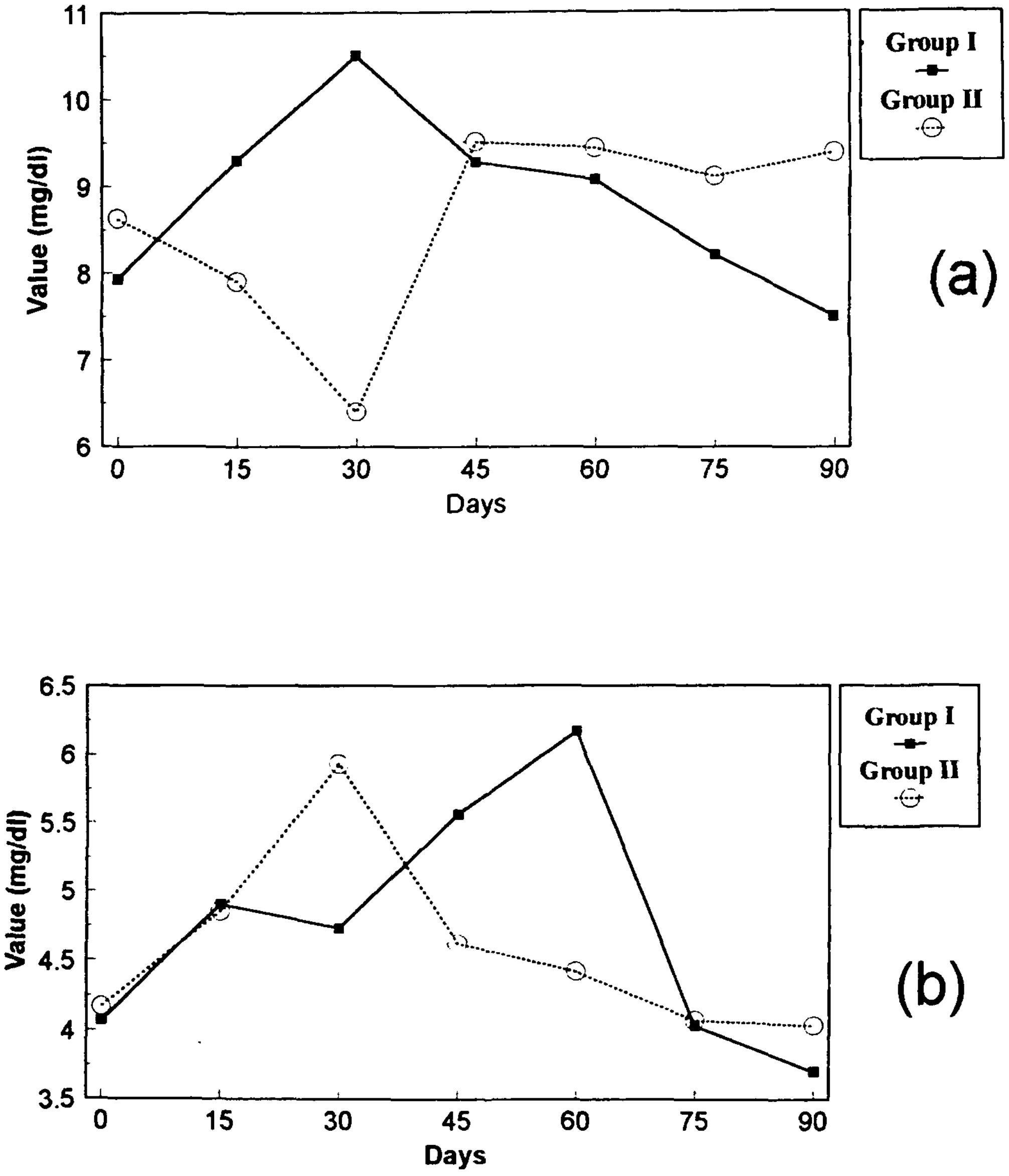

Fig.22 Plasma calcium (a) and phosphorus (b) levels during fracture repair with and without hydroxyapatite fibrillar collagen implant in calves.

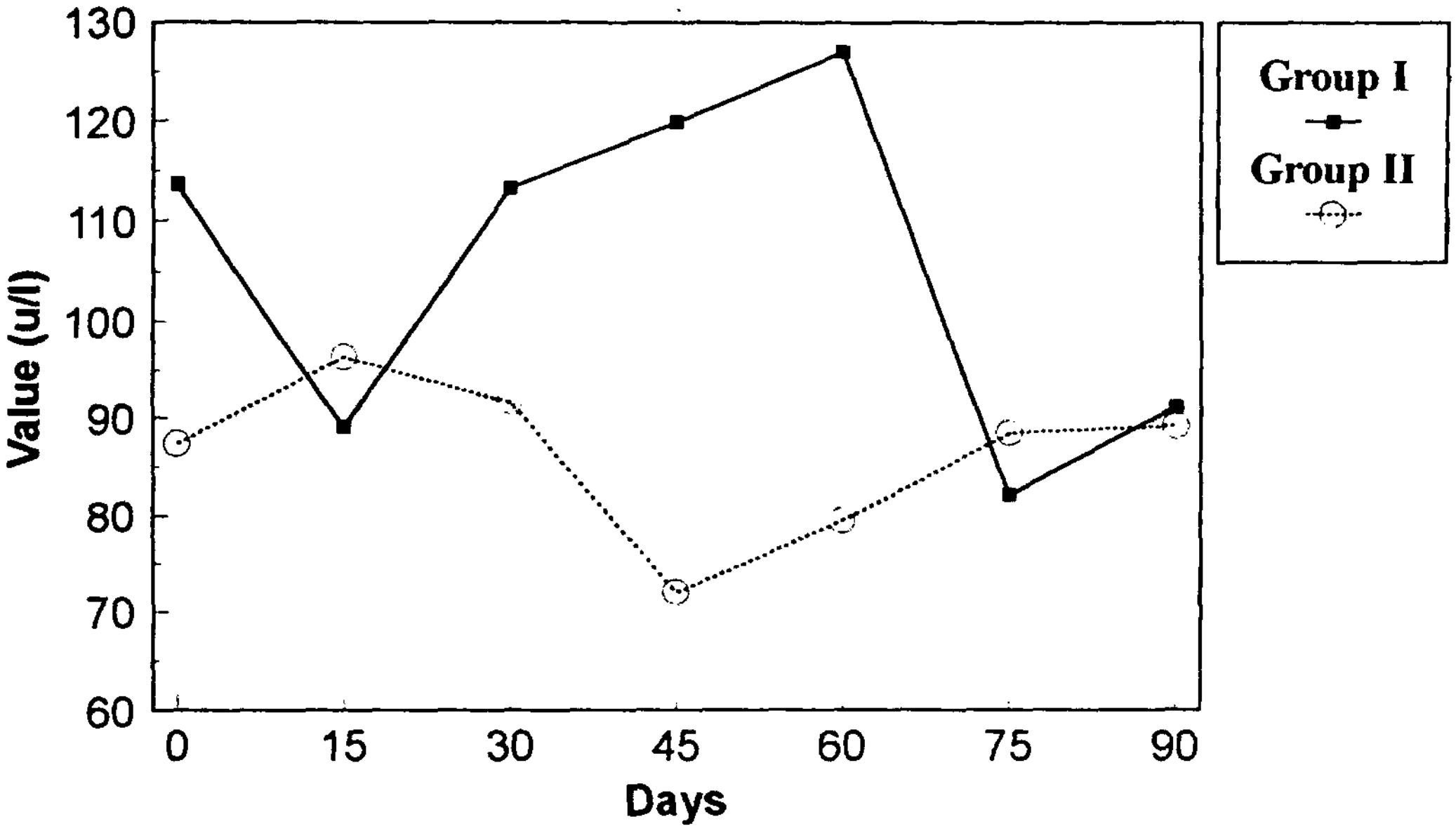

Fig.23 Plasma alkaline phospatase level during fracture repair with and without hydroxyapatite fibrillar collagen implant in calves.

the calcium level was decreased on 15th and 30th day. Thereafter the plasma calcium concentration remained nonsignificantly higher till 90 day. On comparative basis between the groups, a significant decrease in the concentration of calcium was recorded on 30th post fracture day in group II than group I. However, calcium values remained higher between 45 to 90 post immobilization days in group II as compared to the values of group I.

Plasma inorganic phosphorus values increased non-significantly upto 60th immobilization day as compared to 0 day value, thereafter the value decreased nonsignificantly till 90th day of fracture repair in both groups. The maximum concentration of inorganic phosphorus was observed on 60 days in group I, whereas this was maximum on 30 days in group II (Table 4). No significant variations were recorded in phosphorus values between the groups at various time intervals except on 30 days when a significant increase in phosphorus concentration was recorded in group II as compared to group I animals (Fig 22).

Plasma alkaline phosphatase values in group I decreased nonsignificantly on 15th day of fracture repair followed by an increase upto 60th day. Thereafter ALP concentration remained low till 90th day from that of before fracture concentration. A nonsignificant increase in ALP concentration was recorded upto 30th day of immobilization in group II as compared to 0 day value (Table 4). The ALP concentration remained low on 45 and 60 days and thereafter it approached to the level of 0 day concentration. The maximum concentration of ALP was recorded between 45 to 60 days and 15 to 30 days in group I and group II respectively (Fig 23).

4.5.2 Tissue Calcium and Phosphorus

The mean concentrations of tissue calcium following fracture repair with and without hydroxyapatite fibrillar collagen implant are presented in Table 5. A significant decrease was noticed in the concentration of tissue calcium on 30 and 60 days of fracture repair in animals of control group. This concentration remained lower even on 90th day although nonsignificantly as compared to 0 day value. In hydroxyapatite-fibrillar collagen implant group, a decrease in concentration of calcium at fracture site was observed at 30 day followed by a nonsignificant increase on 60th and 90th day of fracture repair when compared to 0 day level (Table 5). On comparative basis between the groups, there was significant increase in the calcium concentration in implanted group at different intervals till 90 days as compared to control group (Fig 24).

Almost similar trend was observed in bone tissue phosphorus concentration at fracture site in the animals of control and implanted groups. During the fracture repair, a gradual increase wasrecorded in phosphorus level till 90 days in group I, however the level did not achieve 0 day value (Table 5). A significant increase in tissue phosphorus concentration was recorded on 60th and 90th day in the animals of implanted group as compared to 0 day phosphorus concentration. A significant increase in bone tissue phosphorus concentration was observed in group II on 30 and 60 days of fracture repair when compared to group I values (Fig 24).

Table 5. Bone tissue calcium and phosphorus during fracture repair with and without hydroxyapatite-fibrillar collagen implants in calves(Mean ± SE)

	Parameters	Group	Before fracture 0 Day	Days after fracture		
				30	60	90
1	Calcium (mg/gm)	I	83.0 ±2.1	23.0 $\pm2.3^{b}$	47.0 $\pm2.6^{b}$	67.7 ±2.3
		II		57.7 $\pm2.6^{by}$	97.0 $\pm6.1^{y}$	95.0 $\pm4.0^{y}$
2	Phosphorus (mg/gm)	I	40.0 ±2.1	16.7 $\pm2.6^{b}$	22.7 $\pm3.3^{b}$	39.7 ±7.6
		II		37.3 $\pm2.0^{y}$	56.7 $\pm4.3^{by}$	64.3 $\pm4.1^{b}$

Group I - Control
Group II- Implanted with hydroxyapatite - fibrillar collagen
b < 0.05 Within group when compared to 0 day value
y < 0.05 Between groups at respective intervals
Values differ significantly when bearing different superscripts

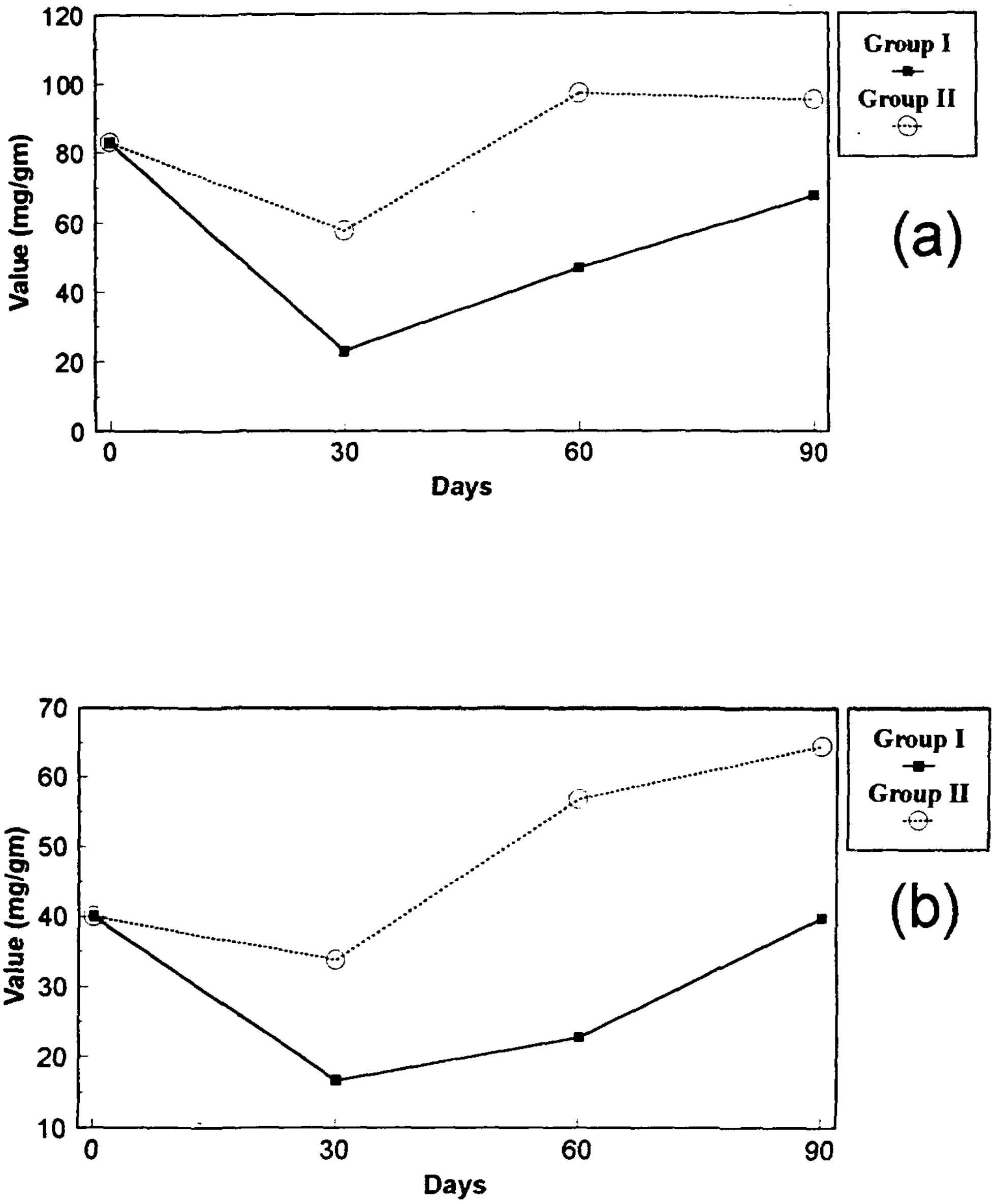

Fig. 24 Bone tissue calcium (a) and phosphorus (b) during fracture repair with and without hydroxyapatite fibrillar collagen implant in calves.

4.7 Histological Observations

30 Days

Control section showed organisation of primary callus with osteoid formation,fragmentation and resorption of clotvascular channelization of the osteoid and peripheral fibrovascular organisation (Fig 25 and 26).

Treated slides (Fig 27and 28) revealed condensation of the fibrovascular reaction along the periosteal side, inlaying of the cartilage and highly active osteoblastic reaction. Vascular organisations in the chondroid revealed the process of resorption of cartilage. Hypertrophic and degenerative cartilagenous cells, alignment of the collagen and initiation of bone formation were also evident.

60 Days

Control slides revealed a picture similar to that indicated above for 30 days treated samples (Fig 29). Vascular organisation, osteoclastic reaction, chondroid resorption and initiation of lamellar organisation to form Haversian lamellae etc. for bone formation were observed.

The treated sections (Fig 30) depicted condensation of collagen, strong lamellar organisation forming clear-cut Haversian system. The mineralization had also started as revealed by retracted processes and star shaped structure of osteocytes indicating formation of lacunae and canaliculae. In other areas, fragmented bundles of the collagen of the implant were being resorbed. These were spread between the Haversian and interstitial lamellae.

90 Days

Control slides at many places still revealed cartilaginous plaques (Fig 31) without any ossification. At other places, the development of lamellar bone (Fig 32) was evidenced. However a compact nature of the bone was not established.

The treated slides revealed typical bone formation with characteristic Haversian systems, separated by cementing line from the interstitial lamellae and the adjacent Haversian systems (Fig 33).

4.8 Evaluation of Bioimplants in Clinical Cases

In both the animals (clinical cases), satisfactory healing progressed as was evidenced by bridging of the fractured gap with radiodense periosteal, intercortical and endosteal callus at 60 days after immobilization. A moderate periosteal reaction at the proximal and distal ends of bone fragments was observed. At 90 days, the fracture gap in both the cases was completely filled and extraperiosteal and endosteal calluses started remodelling (Fig 34). However, continuity of the medullary cavity could not be restored upto 90 days. The animals started putting weight on the affected limbs by 60 days and complete weight bearing was restored on 90 days.

Fig.25 Disorganisation of the clot, growth of blood vessels and chondroid inlay at 30 days control. H & E x100

Fig.26 A cartilagenous plaque being invaded by blood vessels, some hydropic cartilage cells are also seen indicating initiation of bone formation at 30 days control. H & E x100

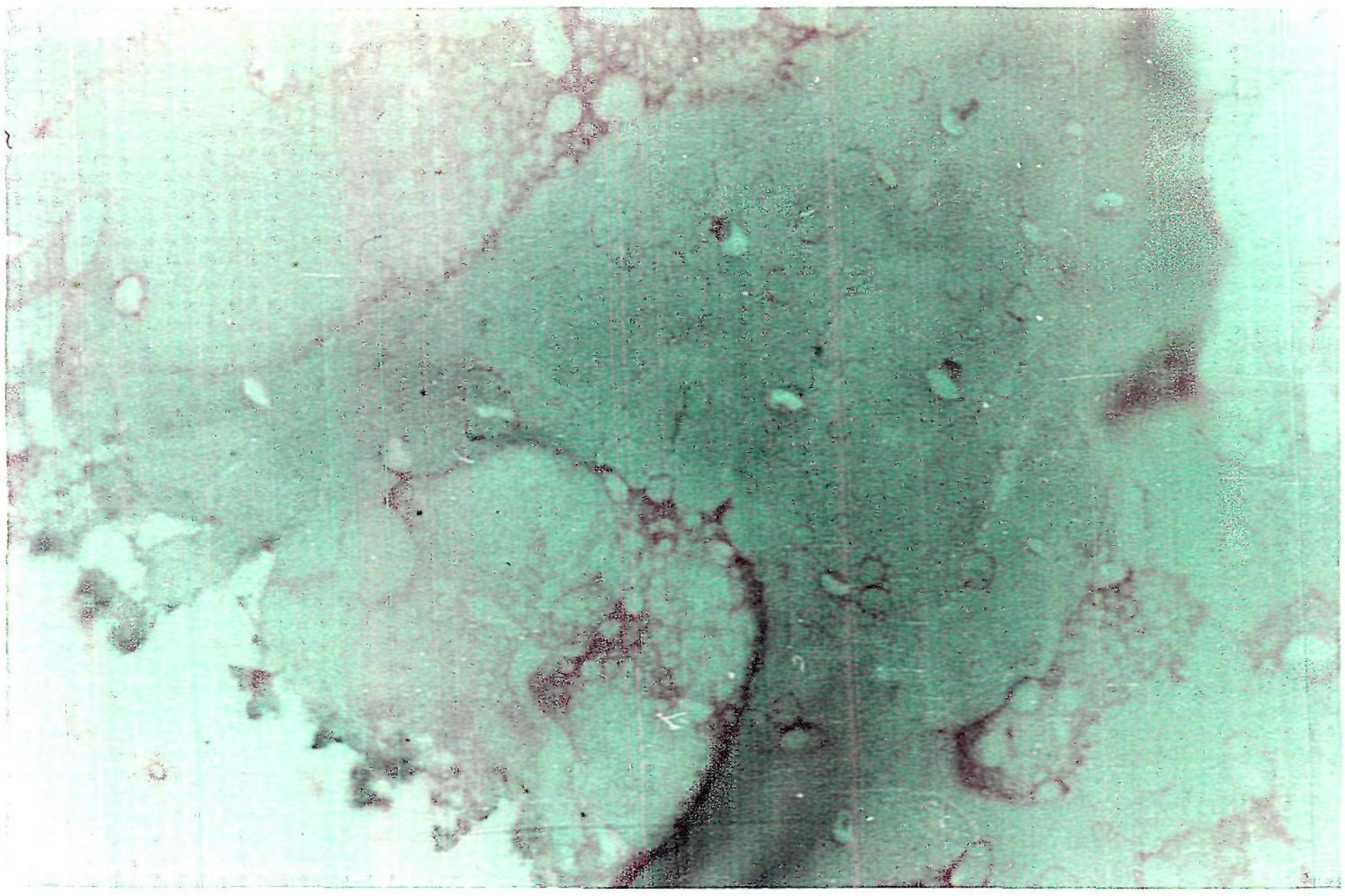

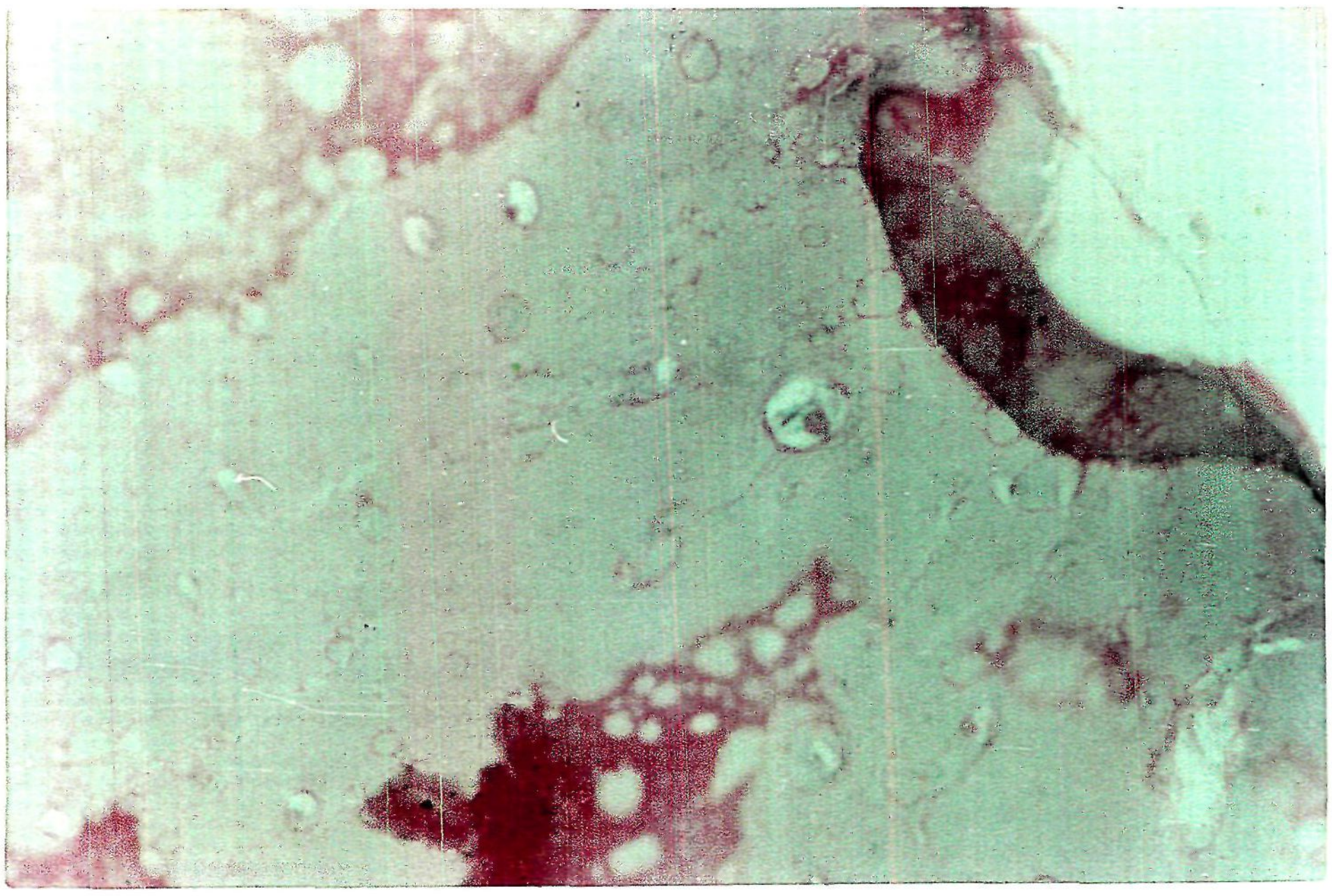

Fig.27 Proliferation and condensation of fibroblasts of the periosteum. Cartilage being invaded with blood vessels. Collagen condensation and signs of calcification are also at 30 days treated. H & E x100

Fig.28 Cartilage being converted into osseous tissue. Cartilage cells are showing degradation whereas initiation of osteon formation has started at 30 days treated. H & E x100

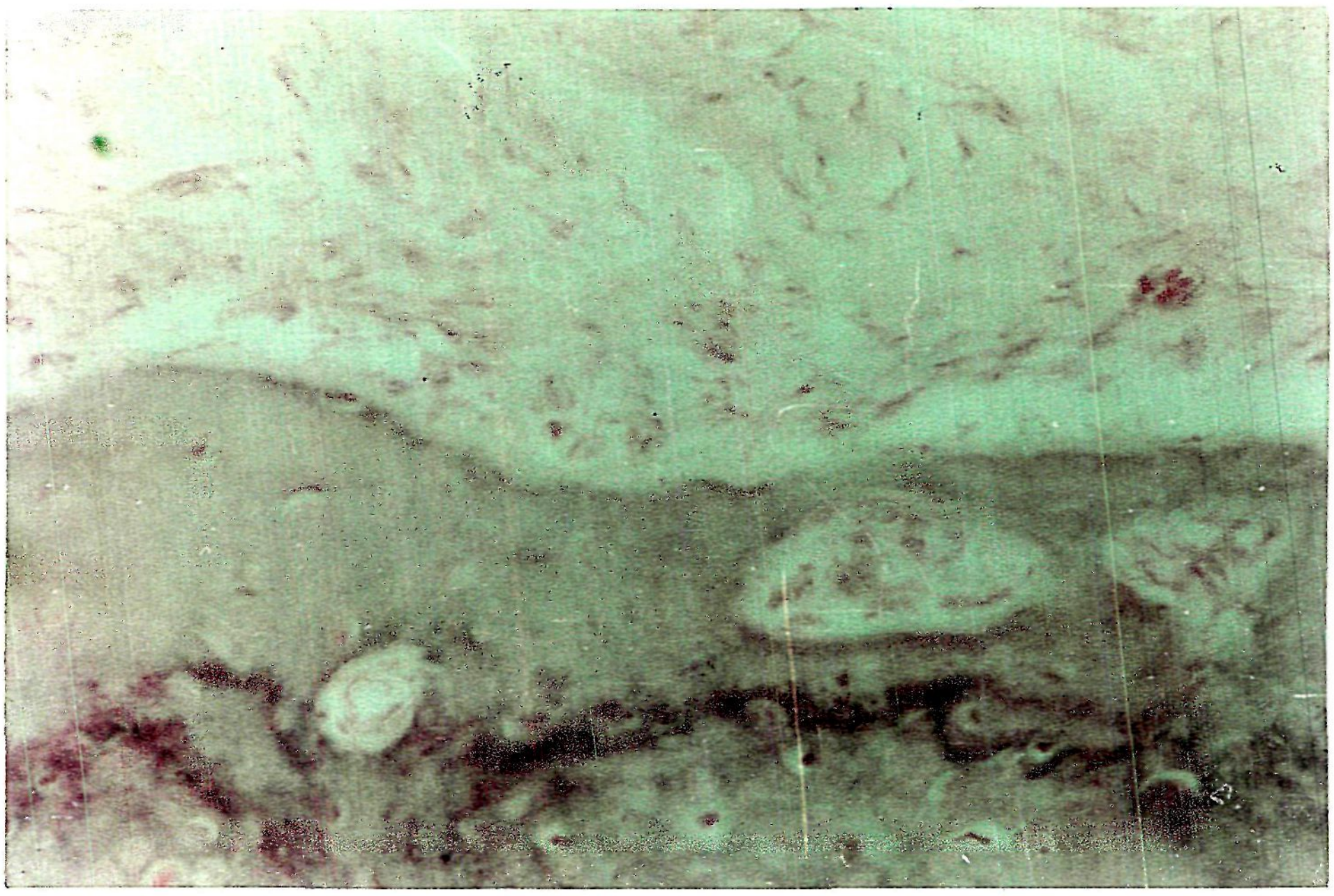

Fig.29 Vascularization fo the cartilage, condensation of collagen, reorganisation of osteoblasts and osteocytes to form an osteon at 60 days control. H & E x100

Fig.30 Longitudional section of the bone tissue revealing Haversian lamellae, Haversian canal, interstitial lamellae with number of osteocytes along the lamellae. Haversian canal reveals organisation of blood vessels at 60 days treated. H & E x100

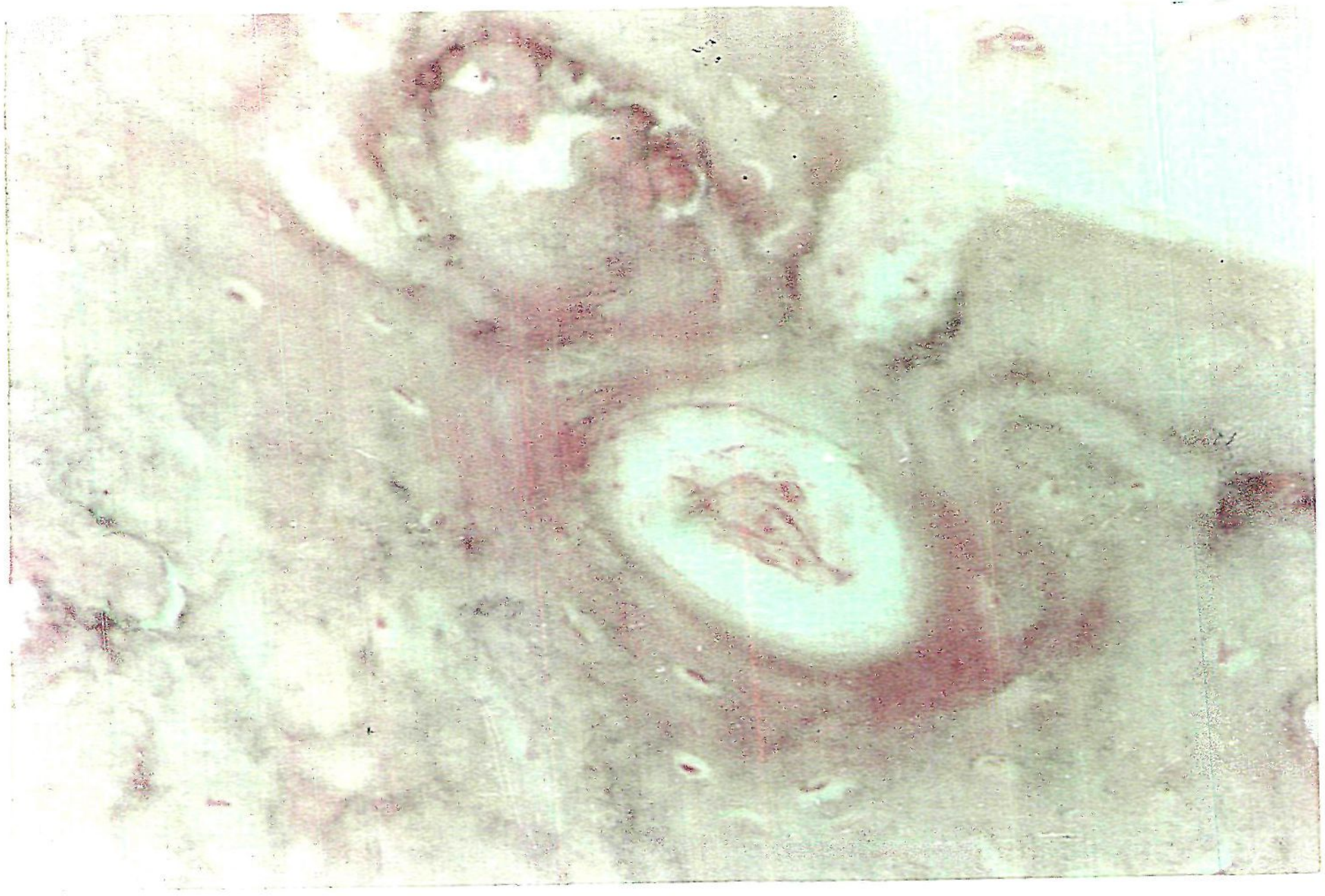

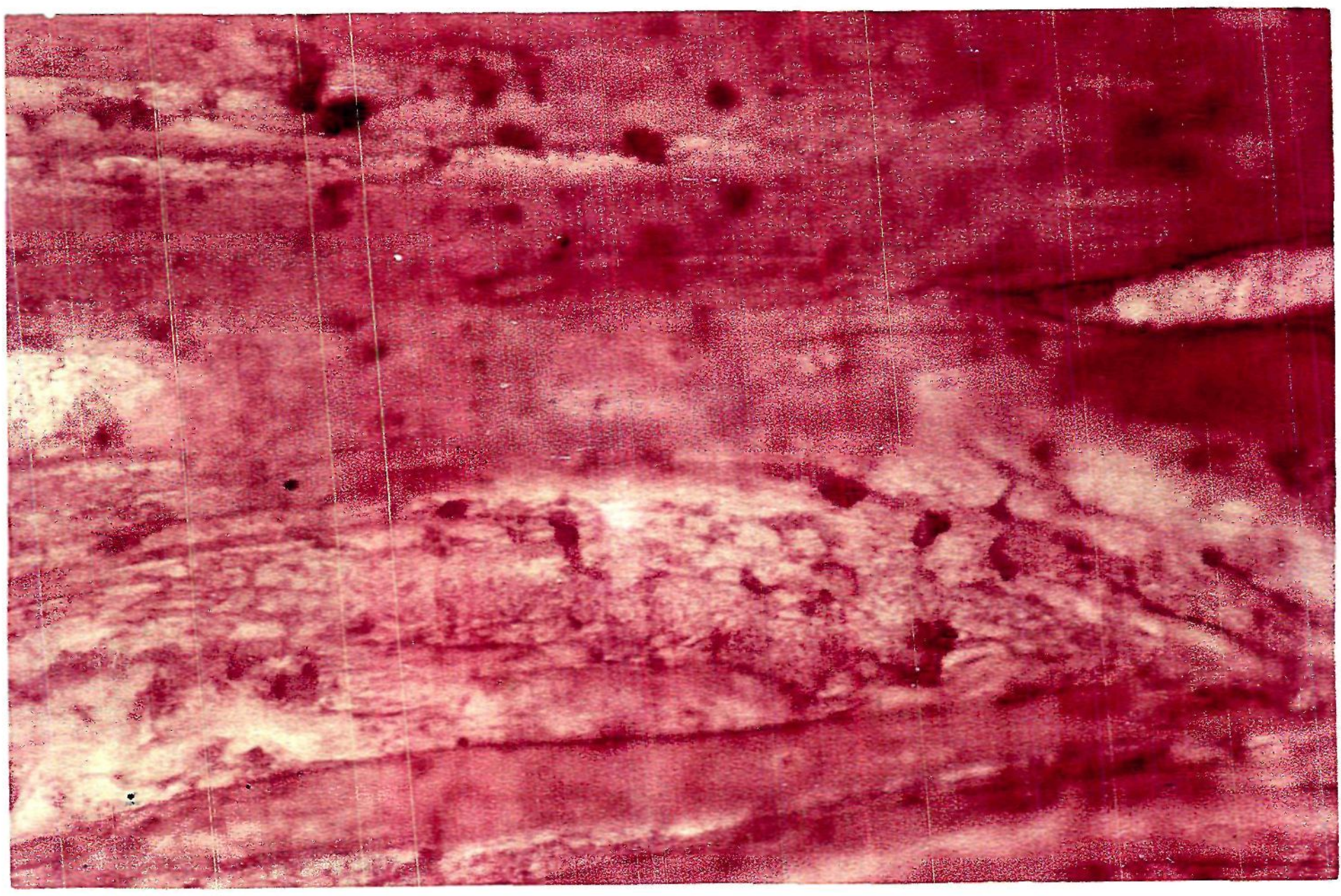

Fig.31 Cartilage tissue at the fracture site at 90 days control. H & E x100

Fig.32 Hyaline cartilage along with vascular channels (Volkman's canal) leading to Haversian canal in the process of develpoping bone at the site of fracture at 90 days control. H & E x100

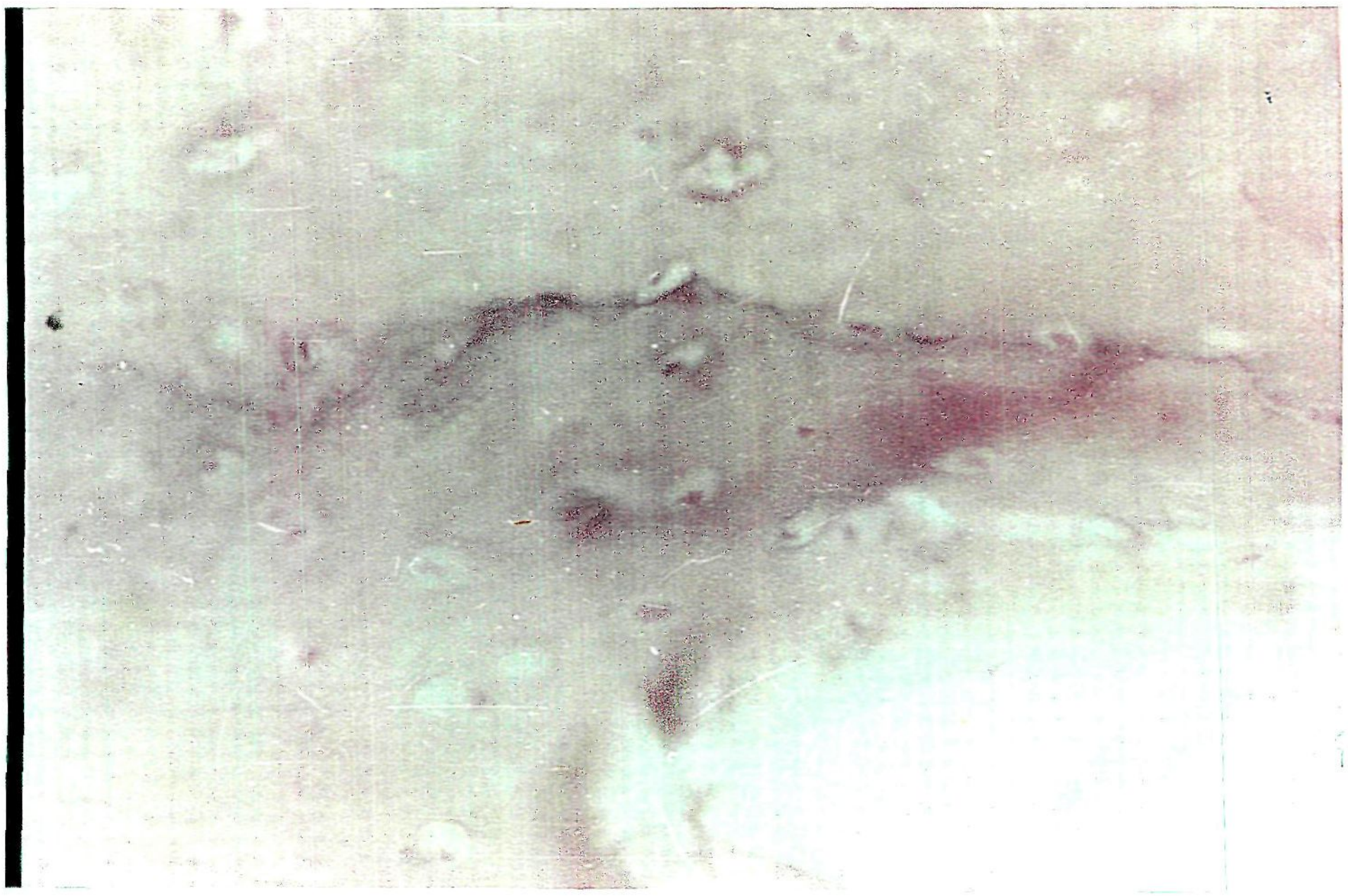

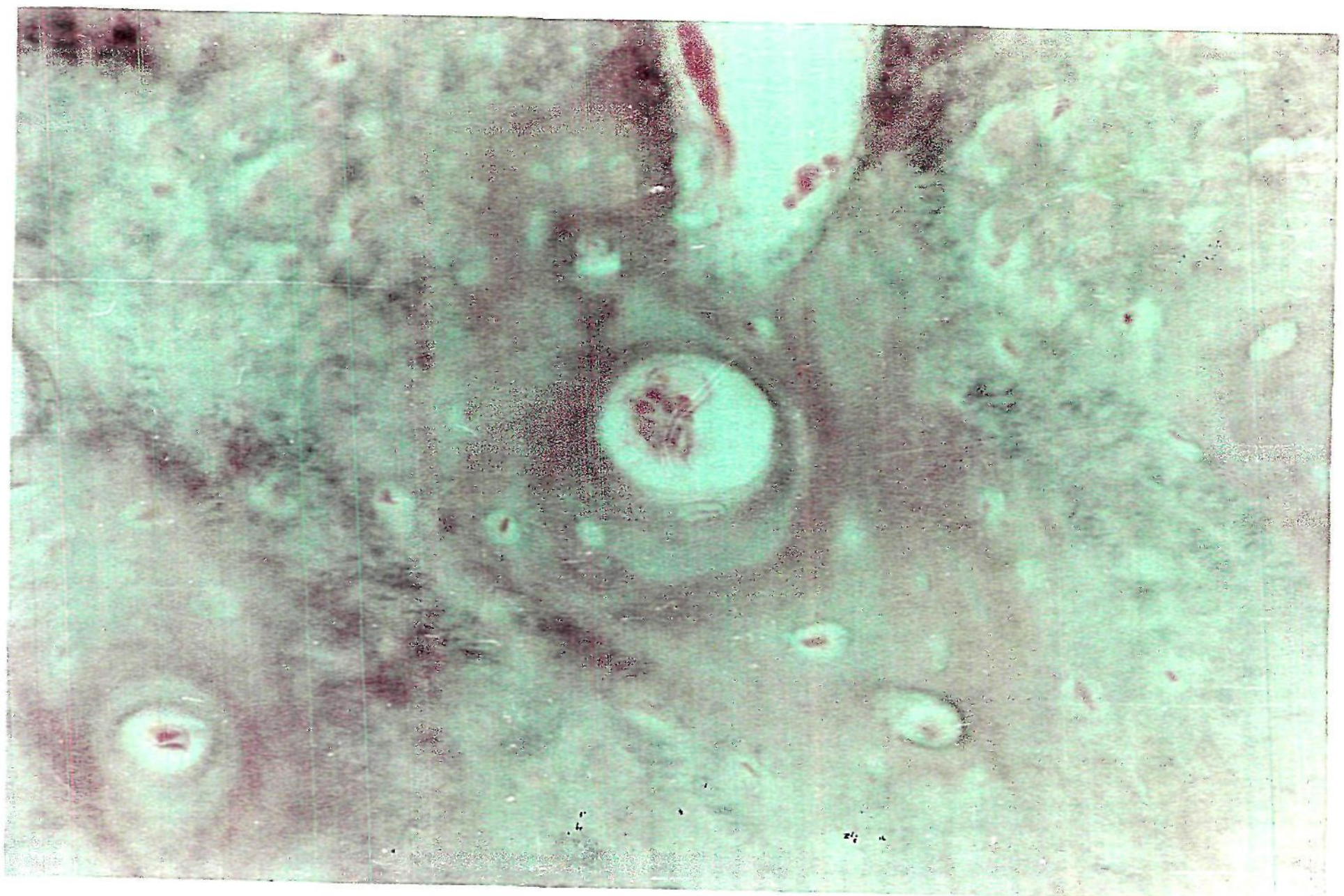

Fig.33 Typical compact bone formation at the site of implant with characterstic Haversian canal, Haversian lamellae, interstitial lamellae demarcated by cementing lines at 90 days treated.

H & E x100

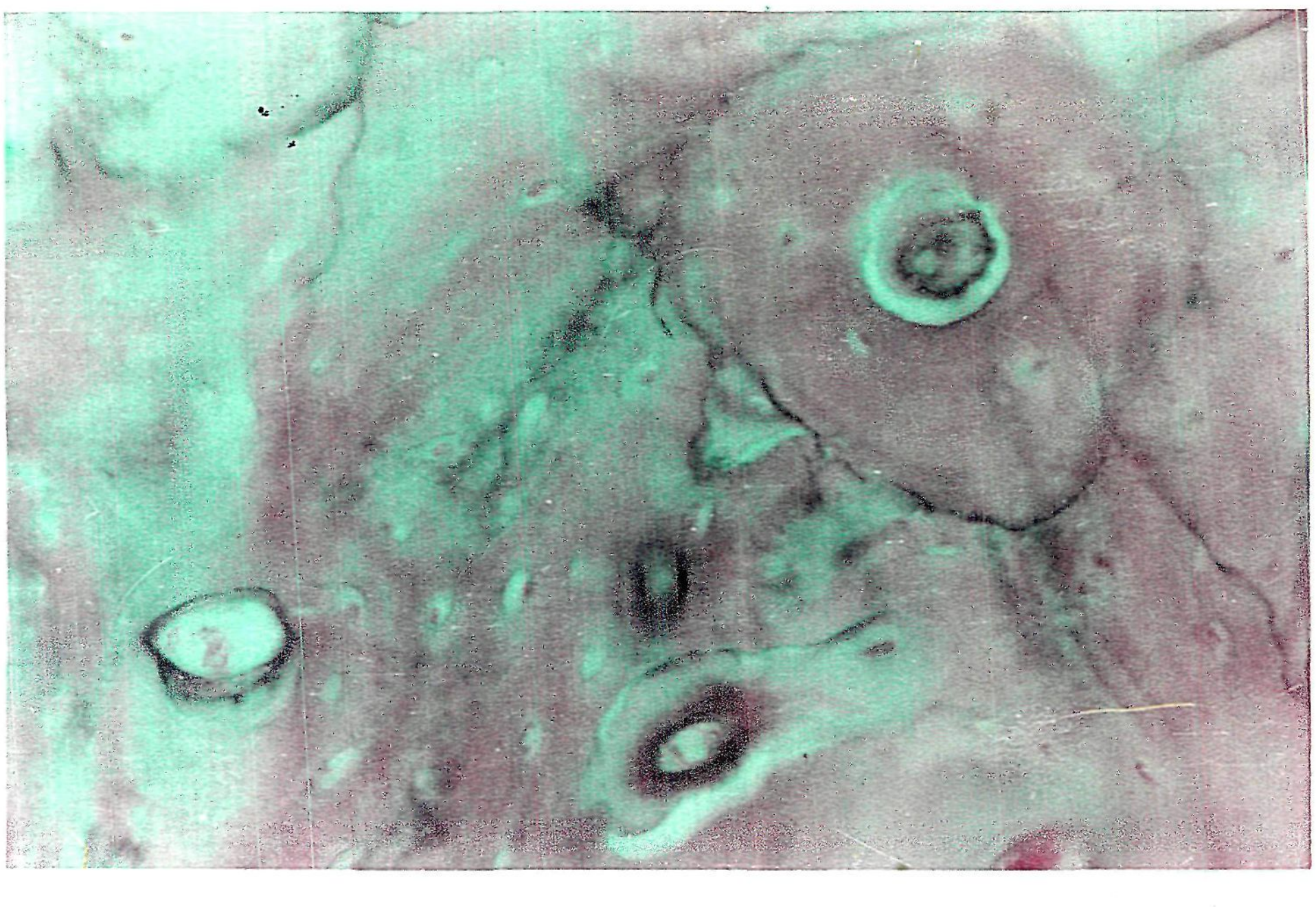

Fig.34 Mediolateral radiograph of metatarsal of calf at 90 days depicting complete bridging of the fracture gap, dissolution and resorption of implant. (Clinical case)

CHAPTER 5

DISCUSSION

The main aim of the present investigation has been to evaluate the efficacy of hydroxyapatite-fibrillar collagen bioimplant in the treatment of long bone fractures in calves on the basis of clinical, haematological radiological, angiographical, biochemical and histological studies.

Chloral hydrate sedation and local infiltration analgesia with 2% lignocaine hydrochloride provided the safe and satisfactory anaesthetic protocol for the entire experimental surgical procedure for creation of metatarsal fracture in calves. In none of the animals, any complication due to anaesthesia was observed. Similar anaesthetic regimen has been adopted by Singh *et al.* (1977), Singh (1978), Thakur *et al* (1987) and Mistry *et al* (1992) for creation of metatarsal /metacarpal fractures in bovine. Parasanalli and Singh (1990) used chloral hydrate anaesthesia for creation of metacarpal and metatarsal fractures. The transverse fracture was created in the midshaft of metatarsal with an embryotome wire under aspetic conditions. The blood clots formed during the process of creation of fractures were removed as has been recommended by Schiller (1988). The two edges of the fractured bone fragments were washed with sterilised cold normal saline to prevent necrosis of the cut edges of the host bone as has been suggested by Newton and Nunamaker (1985). An autoclaved (3 cm long) bone implant was impregnatged in the medullary cavity. The medial surface of the metatarsal region provided adequate space for carrying out the operative procedures. The limb was immobilized using plaster of Paris cast supported with aluminium splint on the anterior and posterior aspects to provide rigid immobility to the bone fragments. The immobilization techniques used in this study compared with the procedure described in metatarsal fracture repair by Singh (1978) and Tyagi and Singh (1993) in bovine.

The weight bearing capacity of the fractured limb remained impaired in the early phases of fracture repair in all the animals of group I and II. A partial to moderate weight bearing in operated limbs was observed in animals of both groups from 15th to 60th day. All the animals of treated (implanted) group restored normal weight bearing on 90th day whereas it could not be achieved in 2 animals of control group till then as they remained lame at this period. The early restoration of weight bearing in implanted animals was attributed to complete osseous union between the fractured fragments earlier than in the animals of control group. This is in agreement with the findings of Sastry *et al.* (1995). The complete restoration of weight bearing capacity of implanted animals versus control animals has been confirmed radiographically also. No abnormality in gait was observed on 90 days of fracture repair, indicating complete healing of fractured metatarsal. Singh (1978) observed that there was no problem of weight bearing during walking on 8th week following fracture repaired with metallic or bone plates along with plaster cast as compared to plaster cast alone in bovine. A slight to moderate muscular atrophy of the operated limb observed following removal of plaster cast after 90 days might be due to the disuse of the limb for the time being. Such observations are in accordance with the findings of Oehme and Prier(1974) and Bisla *et al.* (1991).

The clinical parameters such as rectal temperature, respiration and cardiac rates remained within normal physiological limits in all the animals of group I and II throughout the period of experimentation. This is in general agreement with the observations of Das and Samanta (1995) following fracture repair with calcium hydroxyapatite. Even ultrasonic therapy along with internal fixation in the fracture repair did not alter the physiological parameters in terms of respiratory and rectal temperature (Singh *et al.*, 1994a and b). No increase of temperature beyond the physiological limit indicated that complete asepsis was maintained throughout surgical manoeuver. This was further supported by progressive improvement of weight bearing capacity of the operated limb.

Haematological parameters viz. total erythrocyte,total leucocyte and differential leucocyte counts did not deviate from the standard physiological limits in the animals of control and hydroxyapatite-fibrillar collagen implant treated groups. Such observations further suggested that there was no evidence of infection at fracture site or rejection of implant at any stage of study. These findings are in conformity with the observations of Singh *et al.* (1994a and b) and Das and Samanta (1995).

Roentgenographically the periosteal and endosteal reactions appeared earlier in the animals treated with hydroxyapatite-fibrillar collagen implants than in those of the control group during the initial phase of fracture repair i.e. on 15 days. The osteogenic properties at the periosteal, intercortical and endosteal surfaces further improved at 30 days in the implanted group. An early appearance of periosteal and endosteal reaction during secondary bone healing has been reported by Schilling (1991). Singh (1978) observed the periosteal reactions as early as 2 weeks following implantation of homogeneous onlay bone plates in metatarsal fractures in buffalo calves. The formation of callus between 30 and 60 days intervals was better visualized in group II as compared to group I which could be attributed to the osteogenic property of the hydroxyapatite fibrillar collagen implant as has been well correlated with the angiographic studies of present investigation where the medullary vessels reorganised earlier and played a dominant role (Schiller, 1988). These findings corresponded with the observations of Sastry *et al.* (1995) after implantation of hydroxyapatite-fibrillar collagen in the fracture repair in canine. Narayanan *et al.* (1994) reported early callus formation in arthodesis of radiocarpal joint in dogs treated with allogenic demineralized bone matrix-hydroxypatite-polyglycidyl methaarylate-gentamycin graft (ADBM -HA-PGMA-G). A gradual resorption of the graft till 45 days without any dislodgement was evidenced radiographically. It might be due to holding of surrounding tissue and obvious ingrowth of callus into the pores of the implant. Similar findings have been reported by Uchida (1990). Klawitter and Hulbert (1971) and Kawamura *et al.* (1987) suggesting that hydroxyapatite with a mean pore size of 200 μm was effective for new bone formation. The pore size (and porosity) determined the mechanical strength of the implants. Hoogendoorn *et al.* (1984) reported an increased density of the calcium hydroxyapatite implant upto 6th week followed by blending of the implant with the surrounding bone tissue.

Complete bridging of the fracture gap with osseous callus was noticed at 60 to 90 days of immobilization in the hydroxyapatite-fibrillar collagen implanted animals. The thickening of the bone adjacent to the bone grafts might be due to multiplication of osteoblasts which intern laid down the osseous tissue that compared with the process of normal fracture healing. The medullary cavity of the proximal and distal fragment of the bone started resuming its continuity which was not evident in the control group. After 90 days of fracture immobilization the endosteal and periosteal callus started remodelling; as the thickness of the bone cortex decreased to its normal contour in the implanted animals. Although osseous union in the control group had started, yet the medullary canal did not achieve its continuity. The cortex was thick at the fracture site and the process of remodelling had not started till 90 days. An early appreciation of the radiographic features following calcium hydroxyapatite implant has been reported by Kawamura *et al* (1987) and Das and Samanta (1995) . The amount of periosteal, endosteal and intercortical uniting callus was minimum in the present study reflecting accurate reduction and rigid fixation of the fractured fragments. This is in conformity with the observations of Rhinelander (1985), Bucholz *et al.* (1987) and Das and Samanta (1995)

Osteogenic induction of bone has been reported to be associated with collagen fibrils (Friedman, *et al.*,1968). The collagen and proteoglycans had fixed charge and behaved as electrets to increase the rate of bone formation (Mascarenhas, 1973). The collagen might act as delivery system for bone morphogenetic protein (BMP) and prevent outward diffusion and loss of BMP molecules (Takaoka *et al.*, 1988). When the concentration of BMP in presence of collagen remained high at interfaces between implants and host, the responding cells came into contact with BMP molecules long enough to initiate the bone formation. BMP being chemotactic protein had a significant role in the migration of osteoprogenitor cells to the site of bone repair Somerman *et al.*, 1983). Boyne *et al.* (1978) reported that composite grafts of marrow cells and hydroxyapatite used in dog femoral defect did not inhibit the new bone formation. Porous hydroxyapatite was one of the most clinically applicable biocompatible materials (Jarcho, 1981) which could be used as an alternative to autogenous cancellous bone as a spacer for bony defects, because new bone was formed rapidly inside its pores after implantation into bony defects (Flately *et al.*, 1987 and Hoogendoorn *et al.*, 1984). Kawamura *et al.* 1987 observed that crude BMP combined with hydroxyapatite exhibited chondroosteogenetic ability without loosing its biologic properties. They further established that multiporous hydroxyapatite provided a suitable scaffold for quicker formation of new bone when placed at the fracture site. The osteoinductive and osteoconductive properties of hydroxyapatite-BMP implants have been established by Jarcho (1981) and Kawamura *et al.* (1987). Collagen being biodegradable played an important role as a carrier of BMP which in turn improved new bone formation (Kawamura *et al.*, 1987).

Vascularization at the fracture site is rated as one of the important factors relating to bone healing (Sharma *et al.*, 1977 and Singh *et al.*, 1978).

Critical evaluation of the angiograms at 30 days revealed periosteal vascular formation in both the groups. Macnab and deHass (1974), Singh (1978) and Rhinelander (1985) reported that extraosseous (periosteal) blood supply developed from the surrounding soft tissue immediately following disruption of nutrient arteries in long bone fractures. These new vessels aided in the construction of extraosseous callus which eventually united the fracture (Schiller, 1988). Minute vascular channels were well demarcated in the endosteum channel near the site of implant in group II. The graft site was identified with very fine capillarization and droplet extravasation of the injection fluid. The distal metepiphyseal region showed minute areas of diffusion of injection material indicating the course of neovasculogenesis. But the fibrovascular proliferation was more prominent in the animals of control than that of implanted group. The hyperaemia was not only limited to the site of the fracture but also to the whole bone. These observations are in concurrence with the findings of Kokenberg (1963) and Sharma *et al.* (1977) . An alternation in the blood supply observed in response to fracture has been reported to be the local enhancement of three primary components of the different vascular system *i.e.* primary nutrient artery, metaphyseal arteries and periosteal arteries (Schelling, 1991). Due to the partial obliteration of bone marrow by implant, the large neonutrient arteries from the surrounding periosteal callus perforated the cortex and arborized within the medullary cavity. Similar observations have been suggested by Wilson (1991) after intramedullary fixation of fracture in repair. Macnab and de Hass (1974) reported that the blood supply of the periosteum was maintained on both sides of fracture line as the periosteal vessels run transverse to the long axis of the bone. They further established that periosteal vessels were important in reestablishing the endosteal circulation in the distal fragment.

The dilatation of periosteal, endosteal and cortical vasculature was evident in the animals of both groups after 60 days of fracture. However, a complex network of the vascular channels was observed proximal and distal to the implant site in group II. The implant was found to have entered the stage of dissolution and fragmentation. It clearly indicated that the state of hyperaemia though decreased yet persisted upto 60 days. Similar observations were made by Kokenberg (1963) and Sharma *et al.* (1977). A rapid growth of developing pattern of blood vessels was correlated with the organisation and calcification of the callus. The intact periosteum in the fracture permitted the periosteal vessels to penetrate into the cortex and reestablish the endosteal circulation right at the fracture site (Macnab and deHass, 1974).

Fracture gap was bridged by mass of tissue composed of new blood vessels, fibrous tissue, cartilage and woven bone (Ham and Carmack, 1979 and Brand and Rubin, 1987). The tissues in the callus were derived by the proliferation of mesenchymal cells in the osteogenic layer of periosteum endosteum and marrow cavity (Sissons, 1979; Jee, 1988 and Schiller, 1988). The differentiation of these pleuripotential mesenchymal cells was affected by among other factors, oxygen tension. Variations in oxygen tension undoubtedly lead to the formation of either bone or cartilage. The cartilage has formed in low oxygen tension due to the distance of cells from its blood supply (Rhinelander and Baragry, 1962). In rigid fixation, the medullary vasculature played a dominant role in the fracture healing as these vessels oriented perpendicular within the gap and bone was deposited directly without the formation of fibrocartilage.

The periosteal vessels were visible more in the proximal segment as compared to distal fracture segment of the bone in the animals of control group after 90 days of fracture. The callus was poorlyvascularized with endosteal vasculature on either side of the callus. Cortical tissue at the fracture site showed extravasated injection fluid. In implanted group of animals, the periosteal, endosteal and intramedullary channels were well established. The collateral circulation was evident as highly branching arterial tree spreading up into the periosteum, cortices and endosteum in the grafted area. A rapid growth of developing pattern of blood vessels was clearly visible in the implanted group of animals compared to non implanted group. The revascularization of medullary cavity by regeneration of nutrient artery and metaphyseal arteries has also been noticed during later phase of fracture repair with intramedullary fixation by Wilson (1991). An early organisation of medullary vessels was observed in hydroxyapatite-fibrillar collagen implanted group. Udupa (1966) and Varshney *et al.* (1994) observed a significant correlation of collagen during calcification process. Impaired collagen formation resulted in inferior bony tissue (Grunsschober *et al.*, 1982). The vascularization at the fracture site gradually progressed suggesting that there was no immunogenic reaction due to hydroxyapatite-fibrillar collagen graft. Singh *et al.* (1978) suggested that immune reaction following homgeneous cortical graft during fracture repair in bovine resulted in slow vascularization at the graft site.

Conray 420 proved to be a good contrast medium for study of vascularization (of arterial vessels) in fracture healing. Sharma *et al.* (1977), Singh (1978), Singh *et al.* (1978) and Varshney *et al.* (1994) also used this medium for the visualization of afferent vascular pattern. Though the visualization of the arteries was better with lead oxide than Conray 420 the former was used only when the animals were sacrificed. Parsanalli (1988) used lead soap suspension for visualization of arterial system in the metacarpal region of goats. An immediate radiographic exposure was obtained when Conray 420 was used as there was danger of venous drainage of the contrast medium when the procedure was delayed.

Biochemical turnover either in terms of calcium and phosphorus ions or alkaline phosphatase enzyme has been considered to be highly efficient in bone and its intensity of further altered under various bone disorders (Udupa, 1966). Plasma calcium concentration remained non significantly higher to 75 days of fracture repair in control group whereas in implanted group the concentrations was higher between 45 to 90 days as compared to before fracture value. These findings are in accordance with the observations of Singh *et al.* (1976) and Suresh Kumar (1994). Calcium concentration was lower between 15 to 30 post immobilization days and higher between 45 to 90 days in group II as compared to group I on these intervals. A transitory decrease in the blood calcium was considered to be the result of sequestration of calcium phosphate in bone and soft tissue (Newton and Nunamaker, 1985). The subsequent increase in the blood calcium level might be due to direct interaction of parathyroid hormone with osteoblasts, osteocytes and osteoclasts. This change as well as adrenal involvement could be the important effect of stimulation of periosteal and endosteal proliferation (Russel *et al.*, 1983 and 1984)

The plasma inorganic phosphorus values remained slightly higher upto 60th day following fracture immobilization in the animals of control and implanted group. This rise during fracture repair might be attributed to the increased mineralization during the period. These observations are in conformity with the findings of Singh *et al.* (1976), Singh *et al.* (1994a and b), Suresh Kumar (1994) and Das and Samanta (1995). On contrary, Kumar *et al.* (1992) reported a declining trend in plasma inorganic phosphorus following fracture repair.

Plasma alkaline phosphatase (ALP) was slight decreased at 15th day followed by an increase upto 60th post immobilization day in group I as compared to before fracture callus whereas in implanted group the ALP concentration remained higher upto 30 days of fracture repair, thereafter the values approached to before fracture level between 15 to 90 days. The showing a slight declining trend between 45 to 60 days. The increase in ALP concentration was attributed to increased osteoblastic and osteogenic activities at and around the implant during initial phase of fracture healing after hydroxyapatite-fibrillar collagen implant and also related to abundant fibrous tissue formation (Shifrin , 1970; Singh *et al.* 1976; Suresh Kumar, 1994 and Aithal *et al.*, 1995). During early phase of mineralization, osteoblasts secreted larger quantity of ALP enzyme as it was considered to be good indicator of the rate of bone formation (Guyton, 1976). Alkaline phosphate was reported to release inorganic phosphate from phosphoric esters with consequent precipitation of a compound of calcium and phosphorus in the matrix at the *fracture site (Ali, 1980 and Volpin et al., 1986). Participation of ALP in the* transfer of phosphate groups to the organic matrix or removal of inhibitors of mineralization has also been hypothesised (Lewinson *et al.*, 1982). An increase in ALP activity occurred during osteoblastic metastasis, multiple fracture healing, normal growth and wide spread osteosarcoma where there was always an increased production of fibrous tissue (Shifrin, 1970). On contrary, no significant variations were observed in ALP levels following fracture repair in bovine (Ulemale and Kulkarni, 1992) and canine (Singh *et al.*, 1994a and b and Das and Samanta, 1995).

Glimcher and Krane (1968) established that first stage of mineralization of bone matrix or calcification of carlilage depended on the synthesis of specialized organic matrix consisting principally of collagen. ALP played an important role in the synthesis of collagen (Bourne, 1956). The e-amino group of lysine or hydroxyproline in collagen polypeptides has been reported to play some role in regulation of initial mineral nucleation (Wuthier *et al.*, 1968). Engstrom (1960) observed a close relationship of (molecular structural) formation of collagen fibril and crystal growth of apatite of calcium phosphate.

The increased osteoblastic activity in the implanted group might be due to the availability of collagen fibril in the implant. These findings are well correlated with the histological observations of the present study.

The tissue calcium concentration at the fracture site remained higher in the implanted group when compared to control group at different intervals till 90 days of fracture repair. These observations are in general agreement with the findings of Sastry (1989) and Narayanan (1993). The increase in calcium concentration suggested that hydroxyapatite-fibrillar collagen implant had superior osteoindunctive property as correlated with radiographic, angiographic and histological observations of the present study. Bernick (1989) recorded a gradual increase in calcium concentration upto 16 weeks following demineralized bone matrix implants.

A significant increase in phosphorous concentration was observed in the hydroxyapatite-fibrillar collagen implanted animals at various stages following fracture repair than the control group suggesting that the mineralization at the fracture site was more in the implanted group. These observations are in conformity with the findings of Narayanan (1993).

Wendeberg (1961) reported sequence pattern of biochemical events during fracture repair. A higher level of glycosaminoglycans was present early in the reparative phase followed by a gradual increase in the concentration ofcollagen with finally accumulation of calcium hydroxyapatite crystals. The collagen contents return to normal levels after complete mineralization at the fracture site. Fitten-Jackson (1956) established that internal appearance of mineralization in the spaces of collagen fibrils occurred as a result of interaction between metastable solutions of calcium and phosphate and specific amino acid chains. As such the mineralization resulted into more rigid immobilization of fracture fragments (Cruess and Dumount, 1975).

The histological studies of the metatarsals revealed initiation of bone formation by endochondral ossification process right from 30 days when the hydroxyapatite-fibrillar collagen implants were used. There were big plaques of cartilages which were highly vascularized. Even initiation of development of Haversian canals was revealed.

By 60 days, complete resorption of implant with typical lamellar organisation of the bone was accomplished when the above implants were used and by 90 days typical bone was established.

Control slides depicted osteoids even at 90 days, although many osteons which started developing at 60 days had nearly developed by 90 days. But typical organisation of compact bone was not revealed.

Singh *et al.* (1986) while using intramedullary pinning technique for repair of femoral fracture of calves observed proliferation of periosteum at 3 weeks, fibroblasts and osteoblasts at 6 weeks and development of Haversian system by 9 weeks. These finding while corroborated with the present study also indicated that proper immobilization of fracture hastened the repair. Mukherjee and Sahay (1992) recorded the development of Haversian system (compact bone) at 6 weeks when they attempted repair of metatarsal fracture by placement of autologous bone marrow at the fracture site. Ulemale and

Kulkarni (1992) have also reported the establishment of Haversian system by 28 days following repair of metacarpal fracture by application of frozen allogenic bone grafts. Although the chronology of bone development did not match date wise in the present study from those cited above, the sequence of repair of the fracture was the same. Further the repair wasquicker and stronger when hydroxyapatite-fibrillar collagen implants were used. Development of typical lamellar bone with complete resorprion of implant observed in the histopathological slides confirmed the radiographic and angiographic studies.

The efficacy of hydroxyapatite-fibrillar collagen bioimplant was also evaluated clinically in two calves suffering from complete oblique midshaft metatarsal fracture. The fracture healing was monitored clinically and radiographically at monthly intervals till 90 days. The normal weight bearing capacity was restored at 60 days and radiographs revealed the secondary callus formation. Regular compact bone formation with radiodense cortical picture was revealed at the fracture site in the radiographs of 90 days thereby indicating total effectiveness of bioimplant in repair of fracture in field/clinical cases.

CHAPTER 6

SUMMARY

The present study was carried out in 18 apparently healthy male cross bred calves of 8 to 12 months age. The animals were randomly divided into two groups of nine animals each. Complete midshaft transverse fracture was created in the left metatarsal bone under 6% chloral hydrate and local infiltration analgesia with 2% lignocaine hydrochloride. Group I served as control where as in Group II, a 3 cm long sterilized hydroxyapatite-fibrillar collagen bioimplant was placed in the medullary cavity of fractured metatarsal. The periosteum and subcutaneous tissue were sutured separately. The operated limb was immobilized by plaster cast supported with aluminium splints on the anterior and posterior aspects of the limb after proper reduction. Postoperatively, 1 gm streptopenicillin was administered for 7 days.

The bioimplant was evaluated on the basis of clinical, haematological, radiographic, angiographic, biochemical and histological observations at different stages, till 90 days of fracture repair.

Clinically the weight bearing capacity of the operated limb was affected in all the animals following fracture. Partial to moderate weight bearing was observed upto 60 days in the animals of group I and group II except in one animal of group II where the weight bearing was restored completely on 60th day. All the animals showed complete weight bearing without exhibiting signs of lameness on the operated limb by 90th day in group II. The lameness persisted in two animals even at this stage, in group I. Slight to moderate muscular atrophy was noticed in the animals after removal of the cast after 90 days. Rectal temperature , respiration rate and cardiac rate remained within normal physiological range throughout the period of experimentation.

Total erythrocyte counts (TEC) showed an erratic pattern in group I at various stages of fracture healing whereas in group II, the TEC values were slightly lower than those before fracture. However these values remained well within normal physiological limits in both the groups. The total leucocyte count did not alter much in any of the groups. A slight decrease in the lymphocyte and increase in the neutrophil counts was observed after fracture at various time intervals as compared to before fracture in both control and implanted groups. Eosinophils, basophils and monocyte counts did not alter much.

Radiographically, the periosteal and endosteal reactions were relatively more marked at 15 and 30 post fracture days in the implanted group than in the control group. Radiolucent implant was visible at the fracture site in the early stages of fracture healing in group II. The fracture gap was completely filled in implanted group at 45 days whereas the fracture line was still discernible at this stage in control group. At this stage the implant started fragmentation and resorption. At 60 days, the implant wascompletely resorbed. The osseous union was complete between 60 to 90 days in the implanted animals. The fracture line was still visible on one side of the cortex in one of the animals of control group at this stage. In group II, complete bridging of fracture gap with osseous callus, continuity of medullary cavity and normal contour of the cortex at the fracture site with the initiation of the remodelling process by resorbing extra endosteal and periosteal calluses was achieved at 90th day. Complete (osseous) union with thickened cortex was observed in group I. The continuity of the medullary cavity was partially obliterated due to the presence of endosteal callus.

The angiographic features at 30 days of fracture healing revealed the presence of very minute vascular channels along the endosteal channels near the site of the implant in group II. The implant site exhibited very fine capillarization and droplet extravasations of the injection fluid indicating neovasculogenesis there. The fibrovascular proliferation was more prominent in group I with hyperaemia at the fracture site as well as in the whole bone. By 60 days, the periosteal, endosteal and intercortical vascularization was resumed at the fracture site in both the groups. A complete network of vascular channel around the implant was discernible. The state of hyperaemia though decreased from 30 days still persisted. Periosteal vascularization was more marked in the proximal stump than the distal one in group I at 90 days. The callus was vascularized with poor endosteal vasculature at the fracture site. Cortical vascularization was also evident at the site of fracture. In group II, the periosteal, endosteal and intramedullary vessels were well established. Thecontinuity of the endosteal channels was also established. The collateral circulation was well evidenced at the implant site.

The concentration of plasma calcium and phosphorus remained slightly higher upto 75 and 60 days of fracture repair respectively, in control group; whereas in implanted group the concentration of plasma calcium remained elevated between 45 to 90 days and phosphorus upto 60 days when compared to prefracture values. The plasma alkaline phosphatase (ALP) concentration was higher between 45 to 60 days in group I and 15 to 30 days in group II. In rest of the intervals, the values of ALP in both groups remained low from that of 0 day value.

A marked increase in tissue calcium and phosphorus was recorded in the hydroxyapatite-fibrillar collagen implanted tissue as compared to control at various time intervals till 90 days.

Use of hydroxyapatite-fibrillar collagen implant initiated the osteoid formation at 30 days, osteon formation accompanied with resorption of the implant at 60 days and establishment of Haversian system (compact bone) at 90 days revealing a faster pace of healing with the use of the implant.

Evaluation of bioimplants were attempted in two clinical cases (calves aged 9 months and 1 year respectively) which were suffering from complete oblique midshaft metatarsal fracture. The fractures healed uneventfully by 90 days providing normal weight bearing capacity to the animals. The results were confirmed radiographically.

On the basis of experimental and clinical studies, it can therefore be well concluded that the use of hydroxyapatite-fibrillar collagen implant in fracture repair provided better osteoinductive and osteoconductive properties and reduced the period of fracture healing by way of improved osteogenesis. And hence, the use of implants can be safely recommended for fracture repair in field cases.

REFERENCES

Aithal, H.P., Mogha, I.V. and Singh, G.R. (1993). Clinical and radiographic evaluation of bone grafts and 'ALCAP' used in the management of fractures with bone loss in goats. *Indian J. Vet. Surg.* **14** : 16-20.

Aithal, H.P., Mogha, I.V., Singh, G.R., Swarup, D. (1995). Serum acid and alkaline phosphatase activities following bone grafting in goats. *Indian J. Vet. Surg.* **16** : 47-49.

Alexander, J.W. (1983). Use of combination of cortical bone allografts and cancellous bone autografts to replace massive bone loss in fresh fractures and selected non unions. *J. Am. Anim. Hosp. Assoc.* **19** : 671-687.

Ali, S.Y. (1980). Mechanism of calcification. In Scientific Foundation of Orthopaedics and Traumatology. R. Owen, J.Good fellow, and P. Bullough,.(eds). Heinman Medical, London.

Ashton, B.A., Allen, T.D., Howlett, C.R., Eaglesom, C.C., Hattori, A. and Owen, M. (1980). Formation of bone and cartilage by marrow stromal cells in diffusion chambers *in vivo*. *Clin. Orthop.* **151** : 294-298.

Auer, A.J. and Schenk, R. (1989). The application of tricalcium phosphate cylinders in articular and cortical defects in the horse. *Vet. Surg.* **18**: 73.

Bacher, J.D. and Schmidt, R.E. (1980). Effects of autogenous cancellous bone on healing of homogenous cortical bone grafts. *J. Small Anim. Pract.* **21** : 235.

Bajpai, P.K., Wyatt, D.F., Gilles, N.M., Stull, P.A. and Graves, G.A. (1976). Use of calcium-aluminate phosphorus pertoxide ceramics as bone substitute. *Clin. Res.* **27** : 524.

Banerjee, G.C. (1978). Feeds and Principles of Animal Nutrition. Mohan Primalani, New Delhi.

Bernick, S., Ertl, D., Nishimoto, S.K. and Nimmi, M.E. (1989). Cellular events associated with the induction of bone by demineralized bone. *J. Orthop. Res.* **7** : 1-11.

Bhaskar, S.N., Brady, J.M., Getter, L., Gerower, M.F. and Driskell, T.D. (1971). Biodegradable ceramic implants in bone. *Oral Surg.* **32** : 336.

Bisla, R.S., Singh, K., Singh, J. and Chawla, S.K. (1991). Clinical and radiographic studies on evaluation of entire segment cortical bone grafts in goats. *Indian J. Anim. Sci.* **61** : 699-701.

Bolander, M.E. and Balian, G. (1986). The use of demineralized bone matrix in the repair of segmental defects. *J. Bone Jt. Surg.* **68** : 1264-1274.

Bonfiglio, M. (1976). Transplantation of massive bone allografts. *New England J. Med.* **294** : 1285-1286.

Botterell, E.H. and King, E.J. (1935). *Lancet* **228**: 1267 (fide Singh *et al.*, 1976).

Bourne, G.H. (1956). The Biochemistry and Physiology of Bone. Academic Press, New York.

Boyne, P.J. (1970). Autogenous cancellous bone and marrow transplants. *Clin. Orthop.* **73**: 109-209.

Boyne, P.J., Flamming, B.D., Walsh, R. and Jarcho, M. (1978). Evaluation of ceramic hydroxyapatite in femoral defects. *J. Dent. Res.* **57** : 178.

Braden, T.D. and Brinker, W.O. (1976). Radiographic and gross evaluation of bone healing in the dog. *J. Am. Vet. Med. Assoc.* **169** : 1318-23.

Brand, R.A. and Rubin, C. T. (1987). Fracture healing. In The Scientific Basis of Orthopaedics.J.A. Albright, and R.A. Brand, (eds.). C.T. Norwalk, Appleton and Lange.

Brown, K.L.B. and Cruess, R.L. (1982). Bone and cartilage transplantation in orthopaedic surgery. *J. Bone Jt. Surg.* **64A**: 270.

Bucholz, W., Cartton, A. and Holmes, R.E. (1987). *Orthop. Clin. American* **18**: 328 (fide Das and Samanta, 1995).

Burwell, R.G. (1963). Studies in the transplantation of bone (V). The capacity of fresh and treated homograft - autograft of bone to evoke transplantation immunity. *J. Bone Jt. Surg.* **45** : 386-401.

Burwell, R.G. (1966). Studies in the transplantation of bone (VIII). Treated composite homograft - autografts of cancellous bone. *J. Bone Joint Surg.* **48** : 532-566.

Burwell, R.G.(1969). The fate of bone grafts. In Recent Advances in Orthopaedics. A.G. Apley (ed.)., Wiliams and Wilkins, Baltimore.

Calhoun, N.R., Neiders, M.E. and Greene, G.W. (1967). Effects of plaster of Paris in surgical defects of mandibular alveolar processes of dogs. *J. Oral. Surg.* **25** : 122.

Cameron, H.U., Macnab, I. and Pillar, R.M. (1977). Evaluation of a biodegradable ceramic. *J. Biomed. Mater. Res.* **11** : 179.

Carvalho, B.A., Graves, G.A. and Bajpai, P.K. (1975). Calcium and inorganic phosphate contents of implanted resorbable porous calcium aluminate ceramics. *IRCS Med. Sci.* **3** : 185.

Carvalho, B.A., Bajpai, P.K. and Graves, G.A. (1976). Effect of resorbable calcium aluminate ceramics on regulation of calcium and phosphorus in rats. *Biomedicine* (*Express*) **25** : 130-133.

Chalmers, J. (1959). Transplantation immunity in bone homografting. *J. Bone. Jt. Surg.* **41** : 160-179.

Charnley, J. (1970). The reaction of bone to self curing acrylic cement. A long term histological study in man. *J. Bone Jt. Surg.* **52-B** : 340-353.

Cheroff, R.T., White, E.W., Weber, J.N. and Roy, D.M. (1975). Tissue ingrowth of replamineform implants. *J. Biomed. Mater. Res.* **6** : 29.

Coupland, B.R. (1969). Experimental bone grafting in the canine : The use of autoclaved autogenous normal tibial bone. *Can. Vet. J.* **10** : 170.

Cruess, R.L. and Dumount, J. (1985). Healing of Bone. In Text Book of Small Animal Orthopaedics. - C D. Newton and D M.Nunamaker (eds.). Lippincott Company, Philadelphia.

Cutright, D.E., Bhaskar, S.N., Brady, J.M., Getter, L. and Posey, W.R. (1972). reaction of bone to tricalcium phosphate pellets. *Oral Surg.* **33** : 850.

Das, D. and Samanta, P.K. (1995). Evaluation of ceramic implants in bone surgery in dogs. *Indian Vet. J.* **72**: 1286-1288.

De-Bruyn, P.P.H. and Kabisch, W.T. (1955). Bone formation by fresh, frozen, autogenous and homogenous transplants of bone, bone marrow and periosteum. *Am. J. Anat.* **96** : 345-417.

de Groot, K. (1980). Bio-ceramics consisting of calcium phosphate salts. *Biomaterials* **1** : 47-50.

Deleu, J. and Trueta, J. (1965). Vascularization of bone grafts in the anterior chamber of eye. *J. Bone Jt. Surg.* **47** : 319-329.

Einhorn, T.A., Lane, J.M., Burstein, A.H., Kopman, C.R., and Vigorita, V.J. (1984). The healing of segmental bone defects induced by demineralized bone matrix - A radiographic and histochemical study. *J. Bone Joint Surg.* **66** : 274-279.

Engstrom, A. (1960). The structure of bone. An excursion of molecular biology. *Clin. Orthop.* **17** : 34.

Fackelman, G.E., Rechenberg, B.V. and Felter, A.W. (1981). Decalcified bone grafts in the horse. *Am. J. Vet. Res.* **42** : 943-948.

Fitten-Jackson, S. (1956). The fine structure of developing bone in the embryonic fowl. *Proc. Soc.Biol.* **146**: 270.

Flately, T.J., Lynch, K.L. and Benson, M. (1983). Tissue response to implants of calcium phosphate ceramics in the rabbit spine. *Clin. Orthop.* **179** : 246.

Ferraro, J.W. (1979). Experimental evaluation of ceramic calcium sulphate as a substitute for bone grafts. *Plast. Reconstr. Surg.* **63** : 634.

Frame, J.W. (1980). A composite of porous calcium sulphate dihydrate and cyanoacrylate as a substitute for autogenous bone. *J. Oral. Surg.* **38** : 251.

Franklin, C.M. (1968). Trends in the theory of calcification. *J. Bone Joint Surg.* **50** : 826-827.

Freeman, M.J., Bajpai, P.K., Graves, G.A. and McCullum, D.E. (1980). ALCAP ceramics for rebuilding the mandible. *Ohio. J. Sci.* **80** : 42.

Freeman, M.J., McCullum, D.E., Wolf, D. and Bajpai, P.K. (1981). Reconstruction of mandibular bone with ALCAP ceramics. Transaction of the VII Annual Meet. of the Society for Biomaterials. **4** : 109.

Freidlaender, G.E., Strong, D.M. and Sell, K.W. (1976). Studies on the antigenicity of bone (I). Freeze-dried and deep frozen bone allografts in rabbits. *J. Bone Joint Surg.* **58** : 854.

Freidlaender, G.E. and Mankin, H.J. (1981). 'Bone Banking'. In American Academy of Orthopaedic Surgeons. St. Louis. C.V. Mosby. **30** : 36-55.

Friedman, B., Heiple, K.G. Vessely, J.C. and Hanaoka, H. (1968). Ultrastructural investigation of bone induction by an osteosarcoma, using diffusion chambers. *Clin. orthop.* **59**: 39.

Gepstein, R., Weiss, R.E., Saba, K. and Hallal, T. (1987). Bridging large defects in bone by demineralized bone matrix in the form of powder. *J. Bone Joint Surg.*-**69** : 984-992.

Glimcher, M.J. and Krane, S.M. (1968). The organisation and structure of bone, and the mechanism of calcification. In Treatise on Collagen. Vol. IIb. B.S. Gould and G.N.Ramachandran (eds.), Academy Press, New York.

Gothman, L. (1961). Vascular reaction in experimental fractures. Microangiographic and radioisotopic studies. *Acta. Chir. Scand.(Suppl.).* **284** : 1-30.

Graves, G.A., Hentrich, R.L., Stein, H.G. and Bajpai, P.K. (1971). Resorbable ceramic implants. *J. Biomed. Mater. Res. Symp.* **2** (Part I) : 91-115.

Graves,.G.A., Noyes, F.K. and Villanueva, A.R. (1975). The influence of compositional variations on bone ingrowth of implanted porous calcium aluminate ceramics. *J. Biomed. Mater. res.* **9** : 17-22.

Grunsschober, F., Niebauer, G.W. and Punzet, G. (1982). Moeller-Barlow's disease in a puppy (case report). *Klein tierpraxis. 27* : 111-116 (fide *Vet. Bull.* 1982. **52** : 5701).

Guyton, A.C. (1976). Text Book of Medical Physiology. W.B. Saunders & Co., Philadelphia, London, Toronto.

Ham, A.W. and Cormack, D.H. (1979). Bone and bones. In Histology A.W. Ham and D.H. Cormack, (eds). (ed. 8). P.A. Lippincott, Philadelphia.

Harari, J. (1984). Osteomyelitis. *J. Am. Vet. Med. Assoc.* **184** : 101-102.

Harvey, C.E., Newton, C.D. and Schwartz, A. (1990). Small Animal Surgery. J.B. Lippincott Company, Phildelphia, USA.

Henderson, M.S. and Noble, T.P. (1926). Serum calcium levels in humans following fracture. *J. Bone Jt. Surg.* **8**: 6Q7-611.

Henry, W.B. Wardsworth, P.L. (1981). Diaphyseal allografts in the repair of long bone fractures. *J. Am. Anim. Hosp. Assoc.* **17** : 525-534.

Hierholzer, G., Rehn, J., Knothe, H. and Masterson, J. (1974). Antibiotic therapy of chronic post-traumatic osteomyelitis. *J.Bone Jt. Surg.* **56**-B : 721-729.

Hirano, H. and Urist, M.R. (1981). Bone forming and bone resorbing cell lines derived from bone marrow in tissue culture. *Clin. Orthop.* **154**. 234-248.

Hollinger, J.D. and Battistone, G. (1986). Biodegradable Bone Repair Materials. *Clin. Orthop.*. **207** : 290-303.

Holmes, R.E. (1976). Bone regeneration within a corralline hydroxyapatite implant. *Plast. Reconst. Surg.* **63**: 626.

Hoogendoorn, H.A., Renooij, W., Akkermans, L.M.A., Visser, W. and Wittebol, P. (1984). Long term study of large ceramic implants (Porous hydroxyapatite) in dog femora. *Clin. Orthop.* **187** : 281.

Howell, D.S. (1971). Current concepts of calcification. *J. Bone Jt. Surg.* **53-A** : 250-258.

Hulbert, S.F., Klawitter, J.J. and Leonard, R.B. (1971). Compatibility of bioceramics with the physiological environment. *Mater. Sci. Res.* **5** : 417.

Hyatt, G.W. and Butler, M.C. (1960). The bone hemograft-experimental and clinical applications. Symposium on bone graft surgery. *Amer. Acad. Orthop. Surgeons. Instruct. Course. Lect.* **17** : 133.

Jain, N.C. (1986). Schalm's Veterinary Haematology. Lea and Febiger, Philadelphia, USA.

Jarcho, M., Kay, J.F., Gumaer, K.I., Doremus, R.H. and Drobeck,H.P. (1977). Tissue, cellular and subcellular events at a bone-ceramic hydroxyapatite interface. *J. Bioeng.* **1** : 79.

Jarcho, M. (1981). Calcium phosphate ceramics as hard tissue prosthetics. *Clin. Orthop.* **157** : 259.

Jee, W.S.S. (1988). The skeltal tissues. In Text Book of Histology. L. Weiss, (ed.). M.D.Baltimore, & Urban Switzerland.

Kaneko, J.J. (1980). Clinical Biochemistry of Domestic Animals. Academic Press, New York.

Kawamura, M., Iwata, H., Sato, K. and Miura, T. (1987). Chondroosteogenetic response to crude bone matrix proteins bound to hydroxyapatite. *Clin. Orthop. Res.* **217** : 281-292.

Killey, H.C., Kramer, I.R.H. and Wright, H.C. (1966). The effects of implanting heterogenous compact and cancellour anorganic bone into the long bones of rabbits. *Archieves Oral Biology* **11** : 1117.

Kingma, M.J. and Hampe, J.F. (1964). The behaviour of blood vessels after experimental transplantation of bone. *J. Bone Jt. Surg.* **46-B** : 141-150.

Klawitter, J.J. and Hulbert, S.F. (1971). Application of porous ceramics for the attachment of load bearing orthopaedic applications. *J. Biomed. Mater. res.* **2** : 161.

Klein, L.R., Curtiss (Jr.), P.H. and Jacobs, R.C. (1964). Urinary hydroxyproline, calcium and serum alkaline phosphatase levels following fracture in man. *J. Bone Jt. Surg.* **46** : 919.

Kokenberg, L.T.L. (1963). Vascularization in Healing of Fractures.Charles C. Thomas, Springfield.

Kramer, I.R.H., Killey, H.C. and Wright,H.C. (1964). The pattern of healing following implantation of heterogenous anorganic compact bone in sheep. *Archieves Oral Biology* **13** : 17.

Kumar, R., Gill, P.S., Singh, R., Setia, M.R. and Rattan, P.J.S. (1992). Plasma electrolyte changes during fracture healing in dogs. *Indian Vet. J.* **69**: 476-477.

Laurnen, E.L. and Kelly, P.J. (1969). Blood flow, oxygen consumption, CO_2 production and blood calcium and pH in tibial fracture in dog. *J. Bone. Jt. Surg.* 51 : 298.

Lemaire, R.G. (1966). *J. Bone. Jt. Surg.* **48A**: 1156. (fide Singh *et al.*, 1976)

Lewinson, D., Toister, Z. and Silberman, M.(1982). Quantitative and distributional changes in the activity of alkaline phosphatase during the maturation of cartilage. *J. Histochem. Cytochem.* **30** : 261-269.

Lexer, E. (1925). Joint transplantation and arthoplasty. *Surg. Gynae. Obstet.* **40** : 782.

Luna, G. (1968). Manual of Histological Staining Methods of the Armed Forces Institute of Pathology. The Blakiston Division, McGraw Hill Book Co., New York.

Macewen, W. (1878). The osteogenetic factors in the development and repair of bone. *Ann. Surg.* **6** : 289.

Macnab, I. and De Hass, W.G. (1974). The role of periosteal blood supply in the healing of fractures of tibia. *Clin. Orthop.* **105**:27-33.

Malinin, T.I. (1977). Cadaver bone allograft. In Orthopaedics Principles and Their Application. S.L. Turek, Philadelphia.

Marchand, F. (1901). Der Process der Wundheilung mit Einschluse der Transplantation. Stuttgart, Ferdinand Enke. . (fide Singh et al.,1978).

Mascarenhas, S. (1973). In the Electret Effect in Bone and Biopolymers and Bound Water Problem. New York., the Electrochemical Society of New York, p. 650.

Meyre, S., Weiland, A.J. and Wellenegger, H. (1975). The treatment of infected non-union of fractures of long bones. *J. Bone Jt. Surg.* **57** : 836-840.

Mistry, J.N. , Tadkod, D.M. and Panchamukhi, B.G. (1992). Histomorphological and biochemical observations in fracture repair of metacarpal bone with stainless steel plates and horn plates in male buffalo calves. *Indian J. Vet. Surg.* **13**: 22-23.

Mukherjee, R. and Sahay, P.N. (1992). Histomorphological studies of compound fracture healing with biological osteoinducers in goats. *Indian Vet. J.* **69** : 721-724.

Nade, S. (1970). Bone graft surgery reappraised : The contribution of the cell to ultimate success. *Brit.J. Surg.* 57 : 752-756.

Naryanan, M.K. (1993). A study on the effect of radiocarpal arthrodesis using different bone grafts for radial paralysis in dogs. M.V.Sc. Thesis submitted to Tamil Nadu University of Veterinary and Animal Sciences, Madras-7.

Naryanan, M.K., Ganesh, T.N. and Sastry, T.P. (1994). Radiocarpal arthrodesis using different bone grafts for radial paralysis - a radiological and pathological study. 18th Annual Congress, Indian Society for Veterinary Surgery, Dec. 7-9, Tirupati (A.P.).

Newton, C.D. and Nunamaker, D.M. (1985). Text Book of Small Animal Orthopaedics. J.B. Lippincott Company, Phildelphia, USA.

Oehme, F.W. and Prier, J.E. (1974). Text Book of Large Animal Surgery. Williams and Wilkins, Baltimore.

Pandiya, S.C., Singh, H. and Kumar, A. (1977). Roentgenological and angiographic observation in canine tibial fractures. *Pantnagar J. Res.* **2**: 185-187.

Paradis, G.R. and Kelley, P.J. (1975). Blood flow and mineral deposition in canine tibial fracture. *J. Bone. Jt. Surg.* 57 : 220-225.

Parfitt, A.M. (1965). Changes in serum calcium and phosphorus during stilbestrol treatment of osteoporosis. *J. Bone Jt. Surg.* 47-B : 137-139.

Parsanalli, B. (1988). A comparative study on the osteoinductive property, healing process and fate of decalcified, autoclaved, deep forzen and organic allogenic bone grafts in bovines. M.V.Sc. thesis submitted to Deemed University, IVRI, Izatnagar (UP).

Parsanalli, B. and Singh, G.R. (1990). Different types of allogenic bone grafts in bovines. 1. Radiological evaluation. *Indian J. Anim. Sci.* **60** : 519-525.

Peltier, L.F. (1961). The use of plaster of Paris to fill defects in bone. *Clin. Orthop.* **21** : 1.

Reddi,A.H. and Huggins, C.B. (1972). Biochemical sequence in the transformation of normal fibroblasts in adolescent rats. *Proc. Nat. Acad. Sci. USA.* **69** : 1601-05.

Rhinelander, F.W. and Baragry, R.A. (1962). Microangiography in bone healing. 1. Undisplaced closed fractures. *J. Bone Jt. Surg.* **44-A** : 273-298.

Rhinelander, F.W. (1968). The normal micro-circulation of diaphyseal cortex and its response to fracture. *J. Bone Jt. Surg.* **50** : 784-790.

Rhinelander, F.W. (1972). Circulation in bone. In Biochemsitry and Physiology of Bone (Vol.II). Bourne Academic Press, New York.

Rhinelander, F.W. (1974). Tibial blood supply in relation to fracture healing. *Clin. Orthop.* **105** : 34-81.

Rhinelander, F.W. (1985). Vascular response to fracture or other injury. In Text Book of Small Animal Orthopaedics. C.D. Newton, and D.M. Nunamaker, (eds.). Lippincott Company, Philadelphia.

Ross, G.E. (1966). Effect of diethyl stilbestrol, prednisolone and isoniazid on the healing rate of bone defects filled with certain bone grafting material. *Am. J. Vet. Res.* **27** : 1745.

Russel, J.E., Simmons, J.D., Huber, B. and Roos, B.A. (1983). Meal timing as a Zeitgeber for skeltal DNA and collagen synthesis rhythms. *Endocrinology* **113**: 2035.

Russel, J.E., Walker, W.W. and Simmons, J.D (1984). Adrenal/parathyroid regulation of DNA, collagen and protein synthesis in rat epiphyseal cartilage and bone. *J. Endocrinol.* **103**: 49.

Salama, R. and Weissman, S.L. (1978). The clinical use of combined xenografts of bone and autologous red marrow. *J. Bone Jt. Surg.* **60** : 111-115.

Sastry, T.P. (1989). Development and evaluation of collagen based biomaterials. Ph.D. thesis submitted to Madras University, Madras.

Sastry, T.P., Rao, N.M. and Sarma, S. (1995). Maxibloc - A noble osteoinductive material in orthopaedic and maxillofacial surgery. X National Symposium, Indian Assoc. Vet. Anat. June 7-9, Palampur (HP).

Schelling, S.H. (1991). Secondary (classical) bone healing. *Seminars in Vet. Med. Surg. (Small Animal)* **6**: 16-20.

Schenk, R.K. (1987). Mikroskopiche Utersuchwogen uber Gewbe - und knochenrektion. *Proc. Ceros Symposium R. Mathys Co.*, Bettlach.

Schiller, A.L. (1988). Bones and joints. In Pathology. E. Rubin, J.L. Farber (eds.). P.A., Lippincott, Philadelphia.

Schroeder, E.F. (1938). Intramedullary pegging of femoral fractures with beef bone. *J. Am. Vet. med. Assoc.* **93** : 109.

Scunderi, G.R., Install, J.N., Haas, S.B., Becker-Fluegel, W.W. and Windsor, R.E. (1989). Inlay autogenous bone grafting. *J.Clin. Orthop. Res.* 248: 93-97.

Sharma, A., Singh, H., Singh, A.P., Pandiya, S.C. and Kumar, A. (1977). Angiographic studies in metatarsal fractures in buffaloes. *Indian J. Anim. Sci.* **47** : 625-629.

Shifrin, L.Z. (1970). Correlation of serum alkaline phosphatasem with bone formation rates. *Clin. Orthop.* **70** : 212-215.

Shukla, B.P. (1989). A comparative evaluation of fresh autogenous vis-a-vis freeze-dried and declacified freeze-dried segmental xenogenous bone grafts in dogs. M.V.Sc. Thesis, I.V.R.I., Izatnagar, UP.

Signs, S.A., Bajpai, P.K. and Pantano, G.C (1979). *In vitro* dissolution of synthos ceramics in an acellular physiological environment : *Biomat. Med. Dev. Art. Org.* 7 : 183-190.

Singh, I. (1967). Bone biopsy : A must prior to treatment. *J. Bone Jt. Surg.* **49**-A : 203.

Singh, A.P. (1976). A study on the osteogenic property of homogenous bone grafts in bovine. Ph.D. thesis. HAU, Hisar.

Singh, H., Lovell, J.E., Schiller, A.G. and Kenner, G.H. (1976). Serum calcium, phosphorus and alkaline phosphatase levels in dogs during repair of experimental ulnar defects. *Indian Vet. J.* **53** : 862-865.

Singh, A.P., Nigam, J.M. and Singh, G.R. (1977). Roentgenological studies on experimental allogenic bone transplantation in buffaloes (*Bubalis bubalis*). *Haryana Agric. Univ. J. Res.* 7 : 149-154.

Singh, A.P., Nigam,J.M. and Singh, G.R. (1978). Allogenic bone transplantation in bovines : An angiographic study. *Indian J. Anim. Sci.* **48** : 374-380.

Singh, H. (1978). Surgical studies on grafting materials for better osteogenesis in animals. Final ICAR Report. Deptt. of Surgery and Radiology, College of Vet. Sciences, GBPAU, Pantnagar (UP).

Singh, G.R., Singh, A.P. and Bhargava, A.K. (1981). Use of methyl methacrylate as an adjunct to intramedullary fixation in small ruminants. *Indian J. Anim. Sci.* **51** : 83-89.

Singh, P., Singh, J., Singh, A.P. and Peshin, P.K. (1986). Repair of femoral fractures in calves. *Indian J. Anim. Sci.* **56**: 494-497.

Singh, M., Sobti, V.K. and singh, K.I. (1994a). Effect of ultrasonic therapy on healing of humerus fracture repaired by intermedullary pinning in dogs. *Indian Vet. J.* **71**: 360-364.

Singh, M., Sobti, V.K. and Singh, K.I. (1994b). Clinical, haematological and radiological effects of therapeutic ultrasound on the healing of femur fracture in dogs. *Indian Vet. J.* **71**: 1117-1119.

Sissons, H.A. (1979). Bones. In Systemic Pathology. W. Symmers (ed.). N.Y. Churchill-Livingstone, New York.

Skinner, H.B. (1979). Analysis of oxygen supply to porous implants in bone. *Med. Inform.* **4** : 43.

Somerman, M., Hewitt, A.T.,Varner, H.H., Shiffman, E., Termine, J. and Reddi, A.H. (1983). Identification of a bone matrix derived chemotactic factor. *Calcif. Tissue. Int.* **35** : 481-485.

Soliman, F.A. and Hassan, S. Y.S. (1964). *Nature, Lond.* **204**: 693. (fide Singh *et al.*, 1976).

Stabler, C.L., Eismont, F.J., Brown, M.D., Green, B.A. and Malinin, T.J. (1985). Failure of posterior cervical fusions using cadaveric bone grafts in children. *J. Bone Joint Surg.* **67** : 215-226.

Stevenson, S. (1985). "Bone Grafting". In Text book of Small Animal Surgery. D.H.Slatter (ed.) P.A. Saunders, Philadelphia.

Sudheer Kumar, Y, (1989). Freeze dried and declacified freeze-dried allogenic vis-a-vis fresh autogenous cortical segmental bone grafts - A comparative study in dog. M..V.Sc. Thesis, IVRI, Izatnagar, UP.

Stringa, C. (1957). Studies in vascularization of bone grafts. *J. Bone Jt. Surg.* **39** : 395-420.

Suresh Kumar, R.V. (1994). Biochemical changes during femoral defect healing with demineralized bone matrix implants in canines. Part of Ph.D. thesis. A.P. Agricultural university Hydrabad.

Takaoka, K., Nakhara, H., Yoshikawa, H., Masuhara, K., Tsuda, T. and Ono, J. (1988). Ectopic bone induction on and in porous hydroxyapatite combined into collagen and bone morphogenetic protein. *Clin. Orthop.* **234** : 250-254.

Thakur, S.B., Tadkod, D.M., Vyas, K.N., Prasania, R.R. and Mannari, M.N. (1987). Effect of electrical stimulation of fracture healing in buffalo calves - an experimental study. *Indian J. Vet. Surg.* **8**: 84-90.

Tomford, W.W., Dopplet, S.H., Mankin, H.J. et al. (1983). Bone Bank Procedures. *Clin. Orthop. Rel. Res.* **174** : 15.

Tomford, W.W., Ploetz, J.E. and Mankin, H.J. (1986). Bone allografts of femoral heads: Procurement and storage. *J. Bone Jt. Surg.* **68**:534-537.

Tortorelli, A.F. and Posey, W.R. (1981). Bone ingrowth and replacement of ceramic in mandibular continuity defects. *J. Dent. Res.* **60** (Special issue A) : 601 (Abstract).

Tyagi, R.P.S. and Singh, J. (1993). Ruminant Surgery (1st ed.). CBS Publishers and distributers New Delhi.

Uchida, A., Araki, N., Shinto, Y., Yoshikawa, H., Huiski, E. and One, K. (1990). *J. Bone Jt. Surg.* **72B**: 298. (fide Das and Samanta, 1995)

Udupa, K.N. (1966). Biology of fracture healing. Supplement 1 to the Quarterly Journal of Surgical Sciences. Banaras Hindu University, Varanasi.

Ulemale, A.H. and Kulkarni, P.E. (1992). A note on the treatment of segmental bone defects using allogenic bone grafts. *Indian J. Vet. Surg.* **13** : 32-33.

Urist, M.R. (1965). Bone: formation by autoinduction. *Science* **150**: 893.

Urist, M.R. and Iwata, H. (1973). Preservation and biodegradation of the morphogenetic property of bone matrix. *J. Theo. Biol.* **38** : 155.

Varshney, A.C., Singh, H. and Prakash P. (1991). Enriched collagen as coadjuvant therapeutic agent in expermental osteomyelitis in dogs. *Indian J. of Exp. Bio.* **29** : 35-38.

Varshney, A.C., Singh, H. and Kumar, A. (1994). Angiographic studies on experimental osteomyelitis in dogs. *Indian J. Vet. Surg.* **15** : 74-77.

Vasanth, M.S. and Ramakrishna, O. (1995). Histopathological studies on the effects of shortwave diathermy during femoral fracture healing in canines. 18th Annual Congress, Indian Society for Veterinary Surgery, Dec.7-9, 1995, Tirupati (AP).

Vasseur, P. (1987). Limb preservation in dogs with primary bone tumors. *Vet. Clin. North Am. Small Anim. Pract.* **17** : 889-903.

Volpin, G., Rees, J.A., Ali, S.Y. and Bentley, G. (1986). Distribution of alkaline phosphatase activity in experimentally produced callus in rats. *J. Bone Jt. Surg.* **68** : 629-634.

Walker, M.A., Lewis, R.E., Knelter, S.K., Thrall, D.E.and Losonsky, J.M. (1975). Radiographic signs of bone infections in small animals. *J. Am. Vet. Med. Assoc.* **166** : 908-910.

Weiss, R.E. and Reddi, A.H. (1981). Appearance of fibronectin during the differentiation of cartilage, bone and bone marrow. *J. Cell Biol.* **88** : 630-636.

Wendeberg, B. (1961). Mineral metabolism of fractures of the tibia in man studied with external counting of strontium 85. *Acta Orthop. Scand.* **52**(Suppl.): 1.

Whitson, S.W. (1963). Tight junction formation lin the osteon. *Clin. Orthop.* **86** : 206.

Wilson, J.W. (1991). Vascular supply to normal bone and healing fractures. *Seminars in Vet. Med. Surg. (Small animals)* **6**: 26-38.

Wray, J.B. and Lynch, C.J. (1959). The vascular response to fracture of the tibia in the rat. *J. Bone Jt. Surg.* **41**(A) : 143-148.

Wuthier, R.E., Cotmore, J.M. and Maron, S.S. (1968). The reaction of 1-Fluro-2,4-dinitro benzene with bone of different ages. Changes in Relationship between collagen and Bine Mineral. Calcif. Tissue Res. 1: 288-297.

Wyatt, D.F., Bajpai, P.K., Graves, G.A. and Stull, P.A. (1976). Remodelling of calcium - aluminate phosphorus pentoxide implants in bone. *IRCS Med. Sci.* **4** : 421.

Zeiss, I.M., Nischet, N.W. and Heslop, B.F. (1960). Studies on transference of bone. 2. Vascularisation of autogenous and homogenous implants of cortical bone in rats. *Br. J. Exp. Path.* **41** : 345-363.