

# **PREVALENCE AND PATHOLOGY OF BRAIN DISORDERS IN CATTLE**

**By**

**BALASUBRAMANIAN. M.**



**THESIS**

**Submitted in partial fulfilment of the  
requirement for the degree of**

**Master of Veterinary Science**

**Faculty of Veterinary and Animal Sciences  
Kerala Agricultural University**

**Centre of Excellence in Pathology  
COLLEGE OF VETERINARY AND ANIMAL SCIENCES  
MANNUTHY, THRISSUR - 680651  
KERALA, INDIA**

**2003**

## DECLARATION


I hereby declare that this thesis entitled **“PREVALENCE AND PATHOLOGY OF BRAIN DISORDERS IN CATTLE”** is a bonafide record of research work done by me during the course of research and that the thesis has not previously formed the basis for the award to me of any degree, diploma, associateship, fellowship or other similar title, of any other University or Society.

Mannuthy

  
BALASUBRAMANIAN .M.

## CERTIFICATE

Certified that the thesis entitled **“PREVALENCE AND PATHOLOGY OF BRAIN DISORDERS IN CATTLE”** is a record of research work done independently by **Dr. Balasubramanian .M.**, under my guidance and supervision and that it has not previously formed the basis for the award of any degree, fellowship or associateship to him.




**Dr. N. Divakaran Nair**  
(Chairman, Advisory Committee)  
Assistant Professor (Sel. Gr.)  
Centre of Excellence in Pathology  
College of Veterinary and  
Animal Sciences, Mannuthy


Mannuthy

## CERTIFICATE

We, the undersigned members of the Advisory Committee of **Dr. Balasubramanian .M.**, a candidate for the degree of Master of Veterinary Science in Veterinary Pathology, agree that the thesis entitled **“PREVALENCE AND PATHOLOGY OF BRAIN DISORDERS IN CATTLE”** may be submitted by Dr. Balasubramanian .M., in partial fulfilment of the requirement for the degree.




**Dr. N. Divakaran Nair**  
Assistant Professor (Sel. Gr.)  
(Chairman, Advisory Committee)  
Centre of Excellence in Pathology  
College of Veterinary and Animal Sciences, Mannuthy



**Dr. K. V. Valsala**  
Professor and Head  
Centre of Excellence in Pathology  
(Member)



**Dr. N. Vijayan**  
Associate Professor  
Centre of Excellence in Pathology  
(Member)



**Dr. A.M. Chandrasekharan Nair**  
Associate Professor  
Department of Pharmacology & Toxicology  
(Member)



**External Examiner**

*(Faint handwritten text)*

## ACKNOWLEDGEMENT

*I would like to express my sincere gratitude and indebtedness to my outstanding mentor **Dr. N. Divakaran Nair**, Assistant Professor (Sel. Gr), Centre of Excellence in Pathology and Chairman of the advisory committee for his meticulous guidance, valuable suggestions and unstinted support. It was indeed a great fortune to get an opportunity to work under the potential guidance of a dynamic and versatile academician of the caliber and acumen. I am overwhelmed by his expertise and brilliance.*

*I am deeply touched by the keen interest, affectionate guidance, personal care, persuasion and incessant help and support extended in all possible ways throughout the course of the study by **Dr. K.V. Valsala**, Professor and head, Centre of Excellence in Pathology.*

*I owe my deep sense of gratitude to **Dr. N. Vijayan**, Associate Professor, Centre of Excellence in Pathology and **Dr. A.M. Chandrasekharan Nair**, Associate Professor, Department of Pharmacology and Toxicology for their scrupulous navigation, patient and timely correction of the thesis.*

*I am much obliged to my respected teachers **Dr. T. Sreekumaran**, **Dr. C.R. Lalithakunjamma**, **Dr. Mammen J. Abraham**, **Dr. Koshy Varghese** and **Dr. P.K. Ismail** for their support.*

*I place on record my reverence and gratefulness to **Dr. A. Rajan** (Dean, Retd.). I admire him for his infectious charisma and pragmatism.*

*With great devotion I would like to express my sincere gratitude and indebtedness to my respected teachers back home **Dr.K.C. Varshney**, **Dr. M. Gopalakrishna Nair**, **Dr. Kumar** and **Dr. Avinash** for the encouragement and moral support given by them.*

*I duly acknowledge the cooperation and help rendered by **Dr. J. Abraham**, **Dr. George T. Oommen** and all the staff of Meat Technology Unit for the collection of the brain samples.*

*My sincere thanks are due to **Mr. Chandran**, **Mr. Gangadharan**, **Mr. Krishnankutty** and **Rosekutty Chechi** for their help and moral support.*

*It gives me immense pleasure to record my sincere and heartfelt thanks to my friends **Yuvaraj, Vimal, Paul, Rajendran, Chintu, Deepa, Binduraj, Babitha and Bindu .P.** for their perennial support, love and affection.*

*Special thanks to **Potti, Koushik, Israel Sir** and my beloved juniors **Vivek, Mama, Sekar, Sakthi, Hari, Madan, Elayaraja, Fakrudeen, Giri, Sadasivan, Gerald, Arun and Renjith** for their cheerful kindness.*

*I gratefully acknowledge the timely help rendered by **Suresh** in scanning of the photographs. He made a difficult task look much easier.*

*I am cordially obliged to my respected and reverent seniors **Dr. Sakthivel, Dr. Kantharaj, Dr. Sentilkumar, Dr. Rajkumar, Dr. Muraly, Dr. Reddy, Dr. Madhukumar, Dr. Viji and Dr. Vijayabharathi** for their guidance and encouragement.*

*I owe a great deal to **Rony Chechi, Suraj, Bisi, Pradeep, Sivakumar, Smitha, Rekha, Chitra, Dhanya and Kalaiselvan** for their presence. made life much lively in the department.*

*I owe a special word of thanks with great fondness to **Dr. P.X. Antony** who inspired me not only as an outstanding pedagogue but also as a good friend.*

*I am much indebted to **Sajitha, Lakshmi and Prasanna** for everything they did without which this work would not have been a reality. I am also indebted to my friends **Bala, Vinoth, Rana and Gayathri** for their moral support, encouragement, love and affection across the miles. I wish to remain in their debt throughout my life.*

*I thank the **Dean** for providing me the facilities to conduct the research.*

*I thank the **KAU** for providing me with the Fellowship for my PG programme.*

*My sincere thanks are due to **Mr. O.K. Ravindran, C/o Peagles, Mannuthy** for tireless efforts in effective execution of this thesis.*

*Above all I bow my head to the **Almighty** for the blessing showered on me ..... for all the things I have and don't ..... for helping my small boat find the shore safely ..... through the love and prayers of my **Parents, Sister and Friends**.*

**BALASUBRAMANIAN .M.**

# CONTENTS

Chapter	Title	Page No.
1	INTRODUCTION	1
2	REVIEW OF LITERATURE	4
3	MATERIALS AND METHODS	25
4	RESULTS	27
5	DISCUSSION	56
6	SUMMARY	68
	REFERENCES	72
	ABSTRACT	



## LIST OF FIGURES

Figure No.	Description	Page No.
1	Meningeal congestion	45
2	Traumatic injury – stunning	45
3	Meningeal congestion and subdural haemorrhage – H&E x 160	45
4	Corticomedullary region - Haemorrhage, haemosiderosis and congestion – H&E x 160	45
5	Subependymal region - Haemorrhage – H&E x 160	46
6	Haemorrhage, neuronal shrinkage – H&E x 250	46
7	White matter – intramyelinic edema exhibited as wide interfascicular spaces – H&E x 400	46
8	Congestion and vacuolations around the neurons and glial cells – H&E x 250	46
9	Molecular layer of cerebellum – Neovascularisation, Purkinje cell degeneration – H&E x 250	47
10	Cerebrum – Neovascularisation and gliosis - H&E x 250	47
11a	Cerebrum - Perivascular sclerosis and congestion - H&E x 250	47
11b	Perivascular sclerosis and congestion – PTAH x 160	47
12	Collapse of capillaries, perivascular space dilatation progressing to cavitation - H&E x 100	48
13	Neuronal degeneration and satellitosis - H&E x 250	48
14	Gray matter - Loss of neurons in the cortex – Cresyl echt violet x 250	48
15	Mid brain – motor neurons showing Nissl clumping and homogeneity of the nucleus – Cresyl echt violet x 1000	48

16	Cerebral cortex – loss of granularity of Nissl substance and dilated perineuronal space with neuronal remnants – Cresyl echt violet x 1000	49
17a	Congestion, endothelial swelling and fibrinoid degeneration of the blood vessel - H&E x 400	49
17b	Congestion, endothelial swelling and fibrinoid degeneration of the blood vessel - H&E x 1000	49
18	Cerebellum – Purkinje cells appearing as eosinophilic remnants - H&E x 250	49
19	Mid brain - Perivascular cuffing and gliosis - H&E x 250	50
20	Inflammatory cell infiltration in the meninges - H&E x 250	50
21	Cerebrum – Perivascular cuffing and gliosis - H&E x 160	50
22	Impression smear – Negri body in the Purkinje cell – Seller’s stain x 1000	50
23	Cerebellum – Negri body with halo around in the Purkinje cell - H&E x 1000	51
24	Cerebellum – Magenta coloured Negri body in the Purkinje cell – Massignani Magferrari stain x 1000	51
25	Cerebellum – Intracytoplasmic inclusions of varying size in the Purkinje cell - H&E x 1000	51
26	Cerebrum – Intracytoplasmic inclusions in the neurons - H&E x 1000	51
27	Intracytoplasmic inclusion in the glial cell - H&E x 1000	52
28a	Cerebrum – perivascular vacuolations, perineuronal cavitation - H&E x 400	52
28b	Perineuronal vacuolations - H&E x 250	52
29	Mid brain – intraneuronal cytoplasmic vacuolation - PTAH x 250	52

30	Linear vacuolations along the course of the nerve fibres in the white matter, myelinated areas appear blue -- Luxol fast blue x 1000	53
31	Demyelination and congestion - normal areas appear blue, demyelinated areas appearing colourless – Luxol fast blue x 160	53
32	Cerebrum – meningeal congestion, haemorrhage and dark neurons - H&E x 160	53
33a	Cerebrum – Neuronal degeneration, gliosis and binucleated neurons - H&E x 250	53
33b	Cerebrum – Binucleated neurons - H&E x 1000	54
34	Mid brain – gliosis - H&E x 250	54
35	Gemistocytes around the blood vessel - H&E x 400	54
36	Cerebrum - Irregular vacuolations, eosinophilic cells, autolytic changes and gliosis - H&E x 250	54
37	Cerebrum – Amorphous bodies (mucocytes) - H&E x 250	55
38	Melanin pigmentation around the blood vessel wall in the meninges - H&E x 250	55
39	Sinus tumour – presence of calcification – Alizarin red x 1000	55
40	Sinus tumour – haemorrhage and siderophages in the affected area - H&E x 1000	55

# *Introduction*

---



## 1. INTRODUCTION

Brain is one of the vital organs of the body and remains in an exalted position, protected within the cranial cavity, cushioned by cerebrospinal fluid and security cover being provided by the blood brain barrier and perivascular space. It functions to dictate actions to all parts of the body by accepting and co-ordinating input information from sensory receptors into the nervous system resulting in output information to muscles and glands.

Neurological disorders in animals though were recognised as early as the seventeenth century; Veterinary neuropathology has but a brief history. By the late nineteenth century, the neuroscience was a well-developed field in human medicine and physicians conducted some of the earliest neuropathological studies in animals, as when Gowers reported on canine distemper myelitis in 1877. Neuropathology has always tended to be set apart as an arcane specialist area to be entered by only a select few, as the nervous tissue is highly specialized and structurally complex. The main cell types of pathological significance in the nervous system are: neurons, astrocytes- which act as specialized support cells, oligodendrocytes which form myelin, and microglia which are resident cells of the monocyte/macrophage type. The compact anatomy of the nervous system means that even mild lesions may produce severe functional disturbances.

There are some significant neurologic diseases in which dramatic clinical disturbances are not matched by equivalent morphological alterations in

the nervous tissue. For instance, toxins that interfere with synaptic function can have fatal consequences; yet leave neurons normal in appearance to routine examination. Botulism, tetanus and strychnine toxicosis are well known examples. Inflammation in the central nervous system is the area of neuropathology that is of much veterinary significance because it embraces many of the transmissible highly fatal infections of animals.

Rabies is an ancient disease that is still endemic in many parts of the world. Eradication is difficult as the disease is established in multiple host systems. There is seldom anything even suggestive in the general postmortem unless examined microscopically.

Many of the terms applicable to the pathological changes in the extra neural organs find no place in neuropathology. Fatty change or cloudy swelling can describe changes in the liver, kidney and heart, but central nervous system has unique population of cells and neuropathology requires its own language. Capillary vessels in the CNS are specialized by the virtue of the blood brain barrier. Also in contrast to other extra neural tissues, areas of CNS necrosis and liquefaction do not heal by vascular proliferation and fibroplasia and so a cyst or cavity remains.

Lack of ability to determine from the clinical history and neurological examination of different brain areas is probably the main factor leading to poor quality neuropathological studies in domestic animals. The inaccessibility of the CNS is a significant deterrent to its routine examination in the course of a

necropsy. Part of the appeal for studying the nervous system is that disordered structures and functions are highly correlated.

The rapid advancement of neuroscience over the last decade has added enormously to the understanding of the pathological mechanisms and further exciting and interesting progress can be expected. Thus an attempt is made to provide a contemporary basis for such a general appreciation in the phase of continuing rapid expansion of the knowledge.

Therefore, it is imperative that earnest efforts should be made to delineate the disease problems associated with the brain, so that a plan of action can be stream-lined to prevent and control the brain disorders in cattle. This has been a neglected area and hence a study in this direction is relevant.

Hence, the present study has been taken up with the objective to assess the prevalence and magnitude of the brain lesions in cattle and to screen for the emerging disorders like Bovine Spongiform Encephalopathy.

# *Review of Literature*

---

## 2. REVIEW OF LITERATURE

### 2.1 Prevalence of brain disorders

Four bovine meningeal tumours from a total of fourteen brain tumours were recorded in the files of the Ontario veterinary college and Ontario veterinary laboratory services branch from the years 1966-1984 (Josephson and Little, 1990).

Hamlen *et al.* (1993) reported PEM with specific lesions of cerebro-cortical necrosis in eleven of one hundred and ten mature cattle on pasture in central Saskatchewan.

McGill and Wells (1993) made some neuropathological observations in two hundred clinically suspected cases of Bovine Spongiform Encephalopathy in which pathognomonic vacuolar changes were absent.

A survey into the prevalence of infection in aborted and still born foetuses by the MAFF veterinary investigation service in 1992-93 confirmed the presence of brain lesions due to *Neospora* in 4.2 percent of one hundred and ninety foetuses. Histopathology showed mild non-suppurative encephalitis with multifocal gliosis. Immuno-histochemistry confirmed the presence of *Neospora* spp. (Dannatt *et al.*, 1995).

Burnes *et al.* (1997) reported an outbreak of bovine rabies that occurred in cattle when bitten by vampire bats. Microscopic lesions showed non-suppurative encephalitis with intracytoplasmic inclusion bodies.

Theil *et al.* (1998) recorded 51 cases of sporadically occurring non-suppurative encephalitis diagnosed over a period of ten years.

Intra cranial nervous system tumours were diagnosed in **four** of one thousand and ninety two bovine necropsy specimens submitted to the department of veterinary pathology, Obihiro university between April 1983 and March 1996 (Yamada *et al.*, 1998).

## **2.2 Congenital anomalies**

Madarame *et al.* (1990) observed the agenesis of cerebellar vermis, absence of caudal half of the cerebellum and cystic dilatation of the fourth ventricle in Dandy walker malformation in a Japanese black calf.

Kwiecien *et al.* (1995) reported congenital axonopathy in a brown swiss calf that was characterised by the presence of axonal spheroids and large thickenings along the course of axons throughout the brain.

Balasubramanian *et al.* (1997) reported congenital internal hydrocephalus in a calf. Careful examination revealed a grossly enlarged foetal cranium with visible distortion. Trocarization resulted in serous fluid of 1.6 litres and subsequent collapse of the cerebral tissues.

## **2.3 Vascular disturbances affecting the brain**

Schulman (1968) observed hyperplasia of the vascular endothelial cells, proliferation and dilatation of capillaries in hypoxic injury to the brain. He regarded the sprouting of capillaries as simply reactive to the intense parenchymal degeneration.

Hatzios (1973) reported systemic aspergillosis in a calf. Vascular thrombosis, haemorrhagic infarction and numerous hyphae were found in the cerebrum.

Haughey (1975) found meningeal haemorrhage and congestion in perinatal mortality of beef calves.

Kitching *et al.* (1985) diagnosed thrombo-embolic meningo encephalitis in Natal. Brown necrotic foci with haemorrhagic borders were observed in the brain. Histology revealed focal areas of vasculitis, thrombosis, infarction and neutrophil infiltration in the neuropil.

Thompson *et al.* (1987) discussed thrombo-embolic meningo encephalitis caused by *Haemophilus somnus* infection in a bull calf. Focal haemorrhagic necrosis, neutrophilic infiltration, fibrin thrombi and colonies of gram-negative bacteria within the small blood vessels were the histological lesions.

Wellde *et al.* (1989) experimentally infected cattle with *Trypanosoma brucei rhodesiense*. Vascular changes were characterised by swollen endothelium, infiltration of vascular wall by inflammatory cells and perivascular edema.

Sprouting of new capillaries was the predominant change noticed in many of the intra cerebral tumours and also in the repair site of cerebral infarcts by Storts (1992).

Summers *et al.* (1995) reported fine vacuolations in ischemic neurons resulting from swelling of the mitochondria and endoplasmic reticulum and they also suggested intra myelinic edema as a reason for the spongiosis.

## **2.4 Reaction of the brain cells to injury**

### **2.4.1 Neurons**

Granular cell degeneration in the cerebellum was noticed in hypoxic brain injury. The neurons and the glial cells appeared much eosinophilic and surrounded by vacuoles. Degeneration and loss of Purkinje cells occurred in hypoxia and ischemic cell damage (Hager, 1968 and Netsky, 1968).

Binucleated neurons were reported by Lumsden (1968). An amitotic nuclear division along with the cytoplasmic cleavage during the process of cell division caused the binucleations.

Loss of neurons was recorded in Alzheimer's disease and aging process in animals by Selkoe *et al.* (1987).

Jubb and Huxtable (1991) observed dark neurons in ischemic brain injury and also in perfused brains. They observed swelling of neurons, peripheral displacement of nucleus and comparative loss of Nissl substance and chromatolysis.

Summers *et al.* (1995) described the histological features of neurons in degeneration as pyknotic nuclei, shrunken cell body, eosinophilic cytoplasm along with chromatolysis. The Purkinje cells appeared condensed, elongated and acidophilic.

### 2.4.2 Glial cells

Gitter cells were found to be present in sodium chloride poisoning in cattle. Gitter cells were found in the brain wounds, allergic encephalitis, in central wallerian degeneration and in infarction of the brain. Gitter cells appeared as large round cells with eccentric nucleus and a pale foamy cytoplasm without cell processes found within the perivascular space and adventitia of the blood vessels (Luse, 1968).

Astrocytosis was a feature following myelin degeneration and injury to the axons (Jubb and Huxtable, 1991). These astrocytes appeared as glassy pink in colour with haematoxylin and eosin staining. Microglial reaction was characteristic in conditions of neuronal loss, traumatic injury and infections. In these cases they infiltrated the brain tissue and appeared in clusters as microglial nodules and glial stars. Often they were seen encircling and invading the damaged neurons. They also reported the degeneration and loss of oligodendrocytes and myelin in infections that involved the white matter and also in the cerebral infarcts.

The common astrogliotic response to CNS injury was manifested by the development of visible cytoplasm in the cell. Typically this took the form of a broad, polygonal shape with the nucleus at the margin. Such large reactive astrocytes were deemed gemistocytes (Summers *et al.*, 1995). They also reported satellitosis and neuronophagia as an inflammatory reaction to any type of injury to the neuron.

## 2.5 Necrosis

Summers *et al.* (1995) stated that areas of CNS necrosis and liquefaction do not heal by vascular proliferation and fibroplasia, and so a cyst or cavity remains.

## 2.6 Demyelination:

Raine and Cross (1989) recorded demyelination in cattle in multiple sclerosis and autoimmune encephalomyelitis.

Storts (1992) described demyelination as the destruction of the normally formed myelin sheath leaving the axon naked but otherwise unscathed.

In animals, myelin injury was characteristic of hepatic encephalopathy, amino-acidopathy maple syrup urine disease, intoxication caused by rodenticide bromethalin or hexachlorophene and in globoid cell leuko-dystrophy in which condition a substrate accumulated which was toxic to the oligodendrocytes (Summers *et al.*, 1995).

## 2.7 Pigmentation

Neuromelanin closely resembled lipofuscin (Merighi and Peirone, 1985 and Bianchi and Merighi, 1986).

Neuromelanin accumulated as fine brownish granules in the cytoplasm of certain neurons (Cozzi *et al.*, 1988).

## 2.8 Bacterial infections

Yamasaki *et al.* (1991) described the chronic lesions of thrombo-embolic meningo encephalomyelitis in calves that were characterised histologically by multiple minute foci of malacia and Perivascular microgliosis throughout the central nervous system. *Haemophilus sommus* was reported to be the etiology.

Brain lesions in experimental *Clostridium chauvoei* infection in hill bulls were studied by Singh *et al.* (1992). It revealed congestion of meningeal blood vessels and presence of mononuclears all over the brain. In addition, occasional haemorrhages, perivascular cuffing and glial cell proliferation were noticed.

Weinstock *et al.* (1995) recorded the lesions caused by *Listeria monocytogenes*. Micro abscesses in the brain stem were the characteristic lesions. The diagnosis of the causative agent was done by immunohistochemistry in the formalin fixed brain tissue.

Meningo-encephalitis due to *Salmonella typhimurium* was described by Pandey *et al.* (1996). Grossly, the brain was congested and edematous. Purulent fibrinous meningitis was observed histologically. The bacterium was isolated from the CSF.

Sorden and Radostits (1996) studied the multifocal meningo encephalitis induced by barley spikelet clusters in a two-year-old heifer. Multiple abscesses in the left cerebral cortex especially in the graymatter and

leptomeninges were observed. *Actinomyces pyogenes* was isolated from the brain.

Clinico-pathology of meningo-ventriculitis due to *Streptococcus bovis* infection in neonatal calves revealed congestion, petechiae and cloudy areas in the meninges. Histologically, it was characterised by the presence of fibrinous exudate and inflammatory cells like neutrophils, macrophages and lymphocytes, which were limited to the meninges (Seimiya *et al.*, 1997).

Brain abscesses in buffaloes were studied by Tanwar (1997). Gross examination of the brain revealed abscesses of 2-5 centimetres in each case in the cerebrum at the middle and caudal parts of the left cerebral hemisphere involving meninges too. Cultural examination revealed *Corynebacterium pyogenes* infection.

## 2.9 Viral infections

Liggitt and Demartini (1980) described lymphocytic vasculitis in the meninges as a pathognomonic lesion of malignant catarrhal fever.

Power *et al.* (1990) found Aujeszky's disease in a cow. Non-suppurative encephalitis accompanied by intranuclear inclusions in the neurons was observed in the brain.

McGee *et al.* (1992) reported eastern equine encephalomyelitis in an adult cow. No gross lesions were found. <sup>Microscopic</sup> lesions were chiefly seen in the midbrain and the pons which included severe lympho-histiocytic perivascular cuffing and scattered microglial nodules.

Rift valley fever virus induced encephalomyelitis and hepatitis in calves were described by Rippy *et al.* (1992). Histological changes like diffuse perivascular infiltration, multifocal meningitis, and areas of neuronal necrosis were seen throughout the brain.

Belknap *et al.* (1994) conducted experimental infection of neonatal calves with neuro virulent bovine herpes virus type 1.3. Histological lesions in the brain consisted of widespread non-suppurative meningo encephalitis characterised by neuronal necrosis, gliosis, disruption of neuropil and lymphocytic perivascular cuffing.

Caplazi *et al.* (1994) reported a case of Borna disease in cattle. Nonpurulent meningo-encephalitis, perivascular cuffs containing lymphocytes, macrophages and plasma cells were the characteristic histological lesions.

Rabies induced spongiform change and encephalitis in a heifer were recorded by Foley and Zachary (1995). The thalamus and cortex had severe spongiform change. Perivascular cuffing and lymphocytic meningo-encephalitis associated with extensive spongiform change affecting the neuropil and neuronal cell bodies were detected.

Singh (1995) conducted experimental studies on rabies in buffalo calves. Histopathologically, non-suppurative encephalitis with characteristic Negri bodies, lymphocytic cuffing, neuronal degeneration, gliosis, cytoplasmic vacuolation, neuronophagic nodules and meningitis were observed in various parts of the brain.

Vampire bat transmitted rabies in cattle was studied by Burnes *et al.* (1997). Microscopic lesions showed a non-suppurative encephalitis with intracytoplasmic inclusion bodies.

Noda *et al.* (1998) detected Aino virus antigen in the brain lesions of a naturally aborted bovine fetus. A severe necrotizing encephalopathy was noted. The antigen was demonstrated in neuroglial cells within the brain lesion.

Neuropathological and etiological studies of sporadic non-suppurative meningo-encephalomyelitis of cattle was conducted by Theil *et al.* (1998). Lesions of non-suppurative meningo encephalomyelitis with neuronophagia were suggestive of a viral cause.

Noda *et al.* (2001) demonstrated the Akabane virus antigen using immuno-histochemistry in naturally infected newborn calves. Non-suppurative encephalomyelitis was localized in the midbrain and the spinal cord. Akabane virus antigen was demonstrated in the neuro glial cells in the brain stem and neuronal cells in the ventral horn of the spinal cord.

Lee *et al.* (2002) reported encephalomyelitis associated with Akabane virus infection in adult cows. Typical lympho-histiocytic inflammation characterised by perivascular mononuclear cell infiltration, gliosis, neuronophagia and neuronal loss was observed in the pons and medulla. Akabane virus antigen was demonstrated in the degenerating neurons and glial cells of the brain and spinal cord.

Perez *et al.* (2002) studied the primary infection, latency and reactivation of the bovine herpes virus type 5 in the bovine nervous system. Gross findings included softening of the cerebrum, meningeal haemorrhages and oedema. Histologic lesions included meningitis, mononuclear perivascular cuffing, neuronophagia, satellitosis, gliosis, haemorrhage, necrosis and oedema.

## 2.10 Parasitic infection

Dubey *et al.* (1987) investigated the encephalitis caused by *Sarcocystis* like organism in a steer. Histology revealed multifocal granulomatous meningo encephalitis with focal malacia.

Gupta and Singh (1988) mentioned *Sarcocystis* in the brain of a rabid cow. Histopathology revealed Negri bodies in the neurons and a single sarcocyst was observed in the gray matter of the cerebrum. No inflammatory reaction was detected around the parasite.

Gardiner *et al.* (1989) described the haemorrhagic lesions resulting from *Trypanosoma vivax* infection in Ayrshire cattle. Clots of fibrin were found in the ventricles of the brain. Also mild meningo-encephalitis was observed.

Barr *et al.* (1990) associated bovine foetal encephalitis and myocarditis with protozoal infections. Scattered foci of microglia, perivascular cuffing and protozoal clusters could be observed in brain.

Clinical Neosporosis in a four-week-old Hereford calf was reported by Dubey *et al.* (1992). *Neospora caninum* tachyzoites were detected in the brain.

A large focus of necrotizing encephalitis in the pons, neovascularization and Perivascular cuffing were observed.

Neosporosis was recorded in the aborted foetus and newborn calf by Ogino *et al.* (1992). Brain histology revealed multifocal necrosis and protozoal encephalitic lesions.

Boulton *et al.* (1995) studied bovine Neospora abortion in northeastern new south Wales. Multifocal non-suppurative and necrotizing encephalitis was observed. Necro-granulomas were observed in the foetal brains.

Dannatt *et al.* (1995) reviewed abortion due to neospora spp in a dairy herd. Brain of the foetus showed a mild non-suppurative encephalitis with multifocal gliosis.

A cross Canada disease report stated Neospora abortions in eastern Ontario dairy herds. ~~fifteen~~ 80 cows in a dairy herd aborted. Histopathology of foetal brain revealed multifocal non-suppurative encephalitis (Duivenvoorden and Lusi. 1995).

Abortion caused by neosporosis in cattle was stated by Obendorf *et al.* (1995). On histopathological examination, all eleven fetuses showed a multifocal granulomatous encephalitis.

Spontaneous sarcocystosis in the brain of hill bullocks were screened by Singh and Parihar (1996). Banana shaped bradizoites were found in the graymatter parenchyma and appeared basophilic. The cyst wall remained unstained. No inflammatory reaction around the cysts was detected.

Tuntasuvan *et al.* (1997) described the cerebral trypanosomiasis in native cattle. Trypanosomes could be isolated from the cerebrum, cerebellum, pons and spinal cord. *Trypanosoma evansi* was isolated from CSF.

*Neospora caninum* identification in an aborted bovine foetus in Spain was recorded by Fondevila *et al.* (1998). *Neospora caninum* tachyzoites were identified in areas of the cerebrum with lesions of non-suppurative encephalitis.

Neosporosis associated bovine abortion in Pennsylvania was investigated by Hattel *et al.* (1998). Microscopically, encephalitis was noticed.

### **2.11 Rickettsial infections**

Encephalitis related to *Chlamydia psittaci* infection in a 14-week-old calf was recorded by Piercy *et al.* (1999). Edema, scattered focal haemorrhages, perivascular cuffing, multicentric focal gliosis with astrocyte swelling and leptomeningitis were detected.

### **2.12 Fungal infections**

Hatzios (1973) reported systemic aspergillosis in a calf. Histology revealed vascular thrombosis, haemorrhagic infarction and numerous hyphae in the cerebrum.

Bovine cranial zygomycosis caused by *Saksenaea vasiformis* was first mentioned by Hill *et al.* (1992). Histopathology showed subdural thickening consisting of fibrous granulation tissue. There were multiple pyo-granulomatous foci composed of a central mass of degenerating granulocytes

surrounded by macrophages. Fungal hyphae could be demonstrated in the granulomatous foci.

### **2.13 Genetic causes**

Wada *et al.* (1995) studied Wilson's disease like lesion in a calf. Marked spongiform change was predominant in the white matter. The vacuoles appeared empty and were bounded by thin myelin lamellae and frequently crossed by myelin lamellae. Astrocytes appeared swollen.

### **2.14 Inclusions**

Cummings *et al.* (1993) described eosinophilic intracytoplasmic inclusion bodies in degenerating neurons in equine motor neuron disease.

O'Toole *et al.* (1993) documented the ubiquitinated inclusions in the brain from calves with beta-mannosidosis. The lesions were associated with axonal spheroids and some vacuolated neurons.

Summers *et al.* (1995) found lightly acidophilic inclusions of viral origin in the nucleus or cytoplasm of neurons and in the near by astroglia.

An encephalopathy with argyrophilic inclusions in a Holstein Friesian cow was reported by Nakamura *et al.* (2000). Many oval shaped cytoplasmic inclusions were observed in the neurons of the hippocampus.

## 2.15 Bovine Spongiform Encephalopathy

Dawson *et al.* (1990) recorded primary parenteral transmission of bovine spongiform encephalopathy to pig.

Jeffery (1992) conducted a neuro pathological survey of brains submitted under the bovine spongiform encephalopathy orders in Scotland. Histology revealed bilateral vacuolations of the substantia nigra, hippocampal sclerosis with brain stem neuronal chromatolysis and necrosis, focal symmetrical encephalomalacia and meningo-angiomas.

Jeffery and Wilesmith (1992) conducted a study on idiopathic brain stem neuronal chromatolysis and hippocampal sclerosis. These changes were in association with the profuse vacuolations seen in bovine spongiform encephalopathy.

McGill and Wells (1993) investigated the neuropathology in cattle in clinically suspected cases of bovine spongiform encephalopathy which could be confirmed histologically. Pathognomonic vacuolar changes in the mid brain were absent. Listeriosis was diagnosed in a few cases.

Wells *et al.* (1994) examined the correlation between the results of a histopathological examination and detection of abnormal brain fibrils in the diagnosis of BSE. The restriction of the histological examination to a single section of medulla oblongata was considered acceptable for the statutory diagnosis of BSE. Detection of fibrils was not affected by autolysis.

Encephalopathy in cattle experimentally infected with scrapie agent was reviewed by Clark *et al.* (1995). Neuro-histologic changes included moderate astrocytosis with sparse rod cells, some neuronal degeneration, few vacuolated neurons and a scant spongiform change.

Experimental infection of cattle with the agents of transmissible mink encephalopathy and scrapie was compared by Robinson *et al.* (1995). Encephalopathy was severe in TME than in scrapie.

Chen *et al.* (1996) identified BSE in a cow imported to Canada from the United Kingdom. The diagnosis was based on histological demonstration of neuronal vacuolation in the central nervous system which was highly specific and considered to be pathognomonic.

Haldow and Hamilton (1999) reviewed the reflections on transmissible spongiform encephalopathies.

Race (2000) documented the trouble with transmissible degenerative encephalopathy agents.

Taylor (2000) reviewed the inactivation of transmissible degenerative encephalopathy agents.

Pathak *et al.* (2001) studied the bovine spongiform encephalopathy. Profuse vacuolations were detected in both gray and white matter of the brain. Neuro parenchymal vacuolation in certain anatomical nuclei of the medulla oblongata at the level of the opex provided a valid means of diagnosis.

### 2.15 Polioencephalomalacia

Verdura and Zamora (1970) reported that 15 percent of cattle fed with a diet based upon molasses and urea in a large Cuban feedlot developed PEM during a six-month period.

Sagar *et al.* (1990) discussed the clinical and biochemical alterations in calves with nutritionally induced polioencephalomalacia. Grossly evident cerebro-cortical lesions consisted of linear areas of cavitation.

Hamlen *et al.* (1993) investigated polioencephalomalacia in a herd of cattle consuming water with elevated sodium sulphate levels. Diagnosis was confirmed by histopathological evidence of cerebrocortical necrosis with micro-vascular fibrinoid necrosis predominantly in the thalamic region of the brain.

Cerebral lesions in PEM were characterised by congestion, oedema, microcavitation, laminar cortical necrosis, increased perineuronal and perivascular spaces, neuronal degeneration with shrunken angular and triangular neurons, foci of malacia, extravasation of erythrocytes, gliosis, satellitosis, perivascular cuffing and prominence of capillary endothelium confined to the cerebral cortex (Lonkar and Prasad, 1994).

Singh *et al.* (2000) compared the clinical and haemato-biochemical studies in experimental polioencephalomalacia in calves. Aberration of thiamine metabolism was attributed as the cause.

## 2.16 Metabolic causes

Clinico-biochemical and pathological aspects of experimental hypomagnesaemia in crossbred calves were studied by Sarode *et al.* (1991). Grossly, petechiae and ecchymosis were seen in the brain. Brain revealed focal haemorrhages and spinal cord showed perineuronal edema microscopically.

A preliminary pathological, microbiological and biochemical findings were recorded in still birth/ perinatal weak calf syndrome by Smyth *et al.* (1992). Histology revealed perivascular haemorrhage in the brain.

Waage (1992) reported haemorrhages in the brain of cattle and attributed it to the low plasma levels of calcium.

Yanai *et al.* (1994) found spontaneous vascular mineralization in the brains of cows. They appeared as basophilic deposits in the arterial walls and were accompanied by intimal edema or fibrous thickening. Excess of calcium, phosphorous and zinc were attributed as the causes.

Stewart (1997) reported idiopathic brain stem neuronal chromatolysis in cattle characterised by severe neuronal degeneration and vacuolations.

Shibahara *et al.* (1999) demonstrated auto fluorescent substance and neurocyte necrosis in thiamine deficient cattle. Degeneration of neurocytes, perivascular reaction finally causing necrosis and atrophy of neurocytes were detected. Gitter cells often infiltrated around the blood vessels.

## 2.17 Toxicities

Truceman and Clague (1978) observed vacuolation and neuronal necrosis in the middle and deep layer of the cerebral cortex, thickening of arterial walls and subsequent necrosis followed by infiltration of neutrophils and edema of white matter in sodium chloride poisoning in cattle.

Nair *et al.* (1985) conducted experimental studies on chela leaf (*Ficus tsiela* *Retz.*) poisoning in calves. Loss of glistening appearance, swelling of the gyri and flattening of the sulci were the gross lesions observed. Neuronal necrosis, perivascular edema and demyelination of the white matter were the histological lesions in the brain.

Hepatic vasculopathy and encephalopathy in Brahman type calves were studied by Gill and Townsend (1993). They observed spongiform changes and gliosis of white matter of cerebrum and scattered foci of vacuoles in the granular layer of the cerebellum. The cause was attributed to chemicals and photo toxins affecting liver.

Myburgh *et al.* (1994) described a nervous disorder in cattle, caused by the plants *Ficus ingens* var *ingens* and *Ficus cordata* subspecies *salicifolia*. Histopathology revealed edema of the CNS, focal demyelination in localized areas of the brain and the spinal cord.

Neeraja *et al.* (1999) described the pathological changes in the nervous system in monocrotophos (nuvacron) toxicity in calves. Histopathological examination showed meningeal congestion, haemorrhages in graymatter,

perivascular cuffing, gliosis, satellitosis, neuronophagia and decreased cellularity in the granular layer of the cerebellum, loss of Purkinje cells in most folia and presence of a few ghost cells in the cerebellum.

### **2.18 Heavy metals**

Abrens (1993) studied the effects of lead on glucose metabolism, ion flux and collagen synthesis in cerebral capillaries of calves. No histologic changes were observed in the brain of lead treated calves when examined by light microscopy.

### **2.19 Neoplasia**

Josephson and Little (1990) described meningeal tumours in four bovines. The tumours were invasive and were classified as a fibroblastic meningioma. Neoplastic cells had oval vesicular nuclei containing numerous cytoplasmic invaginations.

Yamada *et al.* (1998) conducted histopathological and immuno-histochemical studies of intracranial nervous system tumours in four cattle. Based on the examination, they classified the tumours as intracranial malignant peripheral nerve sheath tumour (MPNST), Choroid plexus papilloma, differentiated fibrillary astrocytoma and anaplastic malignant astrocytoma.

Psammomatous cerebral intra ventricular meningioma in a bull was reported by Eroksuz *et al.* (1999). Gross lesions were a solid, grey, ovoid mass in the caudal left ventricle. Histologically, two cell populations were detected: in one, the cells had abundant eosinophilic cytoplasm and round, vesicular

nuclei and were arranged in loose whorls, composed of one or two rows. The other cell type had elongated, spindle shaped nucleus and formed bundles around the former cells. Psammoma bodies were present throughout the tumour.

# *Materials and Methods*

---

### **3. MATERIALS AND METHODS**

The present study was conducted at the Centre of Excellence in Pathology, College of Veterinary and Animal sciences, Mannuthy to investigate the prevalence and pathology of brain disorders in cattle.

#### **3.1 Prevalence study**

The prevalence of brain disorders in cattle during 1998 to 2002 were assessed by screening the autopsy records maintained at the Centre of Excellence in Pathology, College of Veterinary and Animal sciences, Mannuthy. The lesions were classified and the prevalence was assessed.

#### **3.2 Sample collection**

Fifty-two samples of bovine brains collected at random from the cattle slaughtered at the meat technology unit, College of Veterinary and Animal sciences, Mannuthy and from the cattle slaughtered at the municipal slaughter house, Thrissur as well as from the carcasses brought for autopsy at the Centre of Excellence in Pathology, College of Veterinary and Animal sciences, Mannuthy were utilized for the study. Animals of all age group varying from young to adult were utilized for the study.

#### **3.3 Gross examination**

The whole brain was carefully removed from the cranial cavity. The brain was subjected to detailed gross examination for any changes like congestion, haemorrhage, abnormalities in shape and size, encephalomalacic changes, autolytic changes and for any inflammatory conditions. The brain after

separation from the cranial cavity was preserved immediately by immersion in 10 percent buffered neutral formalin. After 24 hours of fixation, sections were sliced across all the brain tissue to ensure examination of wide range of neuro-anatomical structures and to detect the presence of any cyst, tumour, fluids and abscesses. Several regions of the brain including the olfactory, middle and caudal parts of both left and right cerebrum, cerebellum, midbrain through rostral colliculi, and medulla through caudal cerebellar peduncles were further fixed in buffered formalin.

### **3.4 Histopathology**

Representative samples of tissues from the olfactory, middle and caudal parts of both the left and right cerebrum, cerebellum, midbrain through rostral colliculi, and medulla through caudal cerebellar peduncles were collected and preserved in 10 percent neutral buffered formalin. The tissues were processed by routine paraffin embedding techniques (Sheehan and Hrapchack, 1980). Sections were cut at four-micron thickness and stained with routine haematoxylin and eosin stain (Bancroft and Stevens, 1996) for histopathological studies. Special stains like Toluidine blue, phosphotungstic acid -haematoxylin (PTAH), Kluver-barrera method for myelin and nerve cells, Cresyl echt violet for nissl substance, Alizarin red for calcium deposits and Maignani and Magferrari method for rabies inclusions (Luna, 1968) were employed whenever required to further elucidate the neuro pathological changes. The stained sections were subjected to detailed examination under the light microscope and the lesions were classified.

# *Results*

---

## **4. RESULTS**

### **4.1 Prevalence study**

During the past five-year period (1998-2002), a total number of 99 bovine carcasses of different age groups were autopsied at the Centre of Excellence in Pathology, College of Veterinary and Animal Sciences, Mannuthy. Out of 99 cases examined, 33 carcasses (33.33 per cent) showed various brain lesions. The lesions were classified and the prevalence was assessed. The highest incidence was of rabies (20.20 per cent) and the least incidence was oedema of the brain (3.03 per cent). The other lesions recorded were congestion of varying degrees (7.07 per cent) and sinus tumour (5.05 per cent).

### **4.2 Field cases**

Brains from 52 bovines were collected and examined. Thirty cases were collected from the autopsy room of Centre of Excellence in Pathology, College of Veterinary and Animal Sciences, Mannuthy. Ten cases were from the municipal slaughterhouse, Thrissur and twelve cases were from meat technology unit, College of Veterinary and Animal Sciences, Mannuthy.

### **4.3 Gross pathology**

#### **4.3.1 Vascular changes**

##### **4.3.1.1 Congestion**

Seventy per cent of the cases revealed varying degree of meningeal congestion (Fig.1). The vessels appeared engorged with blood.

##### **4.3.1.2 Haemorrhage**

Haemorrhages were very prominent in animals, which were stunned before slaughter. Haemorrhages varied from subdural haematomas to very extensive areas of suffusions. Contre-coup haemorrhages were observed. Haemorrhagic clots were seen in different segments of the brain (Fig.2).

##### **4.3.1.3 Edema**

Of the cases in which necropsy was performed, the majority showed mild internal hydrocephalus, otherwise there were no notable lesions of the CNS elsewhere. Swelling of the gyri were observed in a few cases. When sliced, the presence of fluid could be detected.

#### **4.3.2 Discolouration**

Focal areas of black discolouration were observed in a few cases and most often the discolouration was seen at the olfactory part of the cerebral hemispheres. The meningeal covering also appeared blackened.

### **4.3.3 Autolysis**

Few cases revealed autolytic changes. Whole of the brain appeared liquefied and was fluid in nature.

## **4.4 Histopathology**

### **4.4.1 Vascular changes**

#### **Congestion**

Congestion (Fig.17a, 17b and 31) was noticed in different areas of the brain in the slaughterhouse cases and was of varying intensity. Majority of them occurred in the mid brain region. It varied from multifocal to diffuse in distribution. The vessels in and around the meninges and the intersulcal capillaries were highly engorged with blood (Fig.8, 11a and 32). In a few cases, the meningeal congestion (Fig.3) alone was present without the involvement of other areas of the brain while in a few, there was diffuse congestion of various areas like cerebral cortex, cerebellum, midbrain, pons and medulla oblongata.

#### **4.4.2 Haemorrhage**

The degree of haemorrhage varied widely. It was focal and confined to meninges (Fig.32) in some cases, whereas it was very extensive involving all the different layers of the cerebrum, cerebellum and midbrain (Fig.6) of others. In certain haemorrhagic areas, hemosiderosis (Fig.4) could be observed. In addition, a few autopsy cases revealed the haemorrhages throughout the brain parenchyma (Fig.5). Haemorrhage was confined to the meninges in slaughterhouse cases. Majority of them appeared as subdural haematomas,

encircling the molecular layer. Blood clots were observed in the meninges. Few cases revealed sub-dural haemorrhages (Fig.3). Haemorrhages were found to be present extensively in the midbrain (Fig.6). A few cases revealed the presence of erythrocytes around the blood vessel in the perivascular spaces.

#### **4.4.3 Edema**

Edema appeared as several areas of spongy transformation uniformly distributed throughout the cerebral cortex. A few cases revealed pericapillary edema, which were manifested as wide spaces around the capillaries. Edema was seen to be present in both white and gray matter of the cerebrum, cerebellum and the midbrain. It was exhibited as wide interfascicular spaces in the white matter (Fig.7). No stainable material of any intensity could be detected, but appeared as clear spaces. In the graymatter it appeared as wide spaces surrounding the nervous tissue.

#### **4.4.4 Neovascularisation**

Sprouting of capillaries engorged with blood could be observed both in slaughterhouse cases as well as in the autopsy cases. They were seen widely distributed in the areas of cerebrum (Fig.10), cerebellum (Fig.9) and the midbrain. The capillaries were thin walled and smaller when compared with the other capillaries. Unusually large numbers of such capillaries were recorded in a few cases. Marked diffuse vascular proliferation occurred mostly in areas of the affected gyri in which perineuronal cavitation had not occurred.

#### **4.4.5 Blood vessel thickening**

Thickening of the blood vessel wall (Fig.11a and 11b) was recorded in 3.85 per cent of cases. The degree of thickening varied greatly. These thickened vessels were distributed widely in different areas of the brain. The endothelial cells appeared to be swollen in a few cases. The thickening was well appreciated by special staining with phosphotungstic acid -haematoxylin (PTAH) method (Fig.11b). The adventitia of the thickened blood vessel appeared red in colour and the erythrocytes appeared blue coloured. Moderate prominence of capillary endothelial cells and pale staining swollen astrocytes were seen in some cases and were predominant in the cerebral cortex. Intersulcal and meningeal vessels appeared thickened. The adventitia of most of the thickened vessels appeared loosened and showed the presence of swollen astrocytes within and outside the adventitia. A fibrinoid change within the vessel wall was observed in a case. Condensed, homogenous, eosinophilic stained structures within the adventitia were observed (Fig.17a and 17b).

#### **4.4.6 Blood vessel damage**

Capillary damage was seen in 1.92 per cent of the cases. There was discontinuity in the endothelial lining and moderate swelling of the endothelium was observed. This change was found to be present in the cortical and medullary regions of the various segments of the brain.

#### **4.4.7 Blood clot**

Occlusion of blood vessel with clotted blood was observed in 7.70 per cent of the cases. These clots were not attached to the vessel wall. This was observed mostly in the slaughtered animals. Such clots were found to be present more towards the meninges in the intersulcal capillaries and even extending into the parenchyma.

#### **4.4.8 Cystic dilatation of capillaries**

Dilatation of capillaries was observed in 7.70 per cent of the cases. Collapse of capillaries, perivascular space dilatation progressing to cavitation (Fig.12) was observed in various segments and such cavities in certain areas were crowded with gemastocytic astrocytes.

#### **4.5 Neuronal degeneration**

Neuronal degeneration (Fig.13 and 33a) accounted to 38.46 per cent of the total cases. The degenerative change varied from multifocal to diffuse involving the different cortical laminae and white matter. Diffuse neuronal degeneration (Fig.13) could be seen in 70 per cent of the cases while the remaining 30 per cent of the cases revealed focal areas of neuronal degeneration (Fig.13). Swelling of the cell body, dispersion of Nissl substance and peripheral displacement of the nucleus appeared in some. Cell body appeared shrunken (Fig.6) and the cytoplasm stained highly eosinophilic in a few cases. In some other cases nucleus was triangular, pyknotic and eosinophilic. The nucleolus was not discernible in some cases. Neurons

appeared completely chromatolysed in some cases. The cytoplasm was eosinophilic and was surrounded by the glial phagocytic cells. These degenerated neurons were found to be present amidst normal neurons. Some of them appeared highly condensed and were seen surrounded by potential unstained space. Swelling, vesiculation of the nucleus and cytoplasm condensed to the nucleus in the form of a ring were seen amidst normal neurons in certain areas.

#### **4.5.1 Satellitosis**

Satellitosis was exhibited as the crowding of the glial cells around the damaged or the necrosed neurons. It was mostly confined to the gray matter (Fig.13). Grouping of the glial cells around the damaged neurons formed the glial nodules in a few cases. The cells involved were chiefly microglia and oligodendroglia. Satellitosis was recorded in 21.5 per cent of the cases.

#### **4.5.2 Neuronophagia**

Neuronophagia was exhibited as the invasion and the phagocytosis of the damaged neurons. It was encountered in the gray matter of the cerebrum and few areas of the cerebellum.

The neurons were not detected in these areas, instead, the remnants of the neurons only could be observed which appeared condensed and eosinophilic. This change was encountered in 1.92 per cent of the cases.

### **4.5.3 Neuronal swelling**

Neuronal swelling was observed as large sized neurons in the cerebral cortex. Vacuolations were observed around the swollen neurons. Few neurons appeared chromatolysed and the nuclear details had been lost. The cytoplasm appeared granular and eosinophilic too. The nuclei of the swollen neurons appeared highly vesicular with no structures inside. This change accounted to 5.77 per cent of the cases.

### **4.5.4 Loss of neurons**

Few areas of the cerebral cortex revealed the loss of neurons in some cases. This loss was indicated by the presence of only scanty neurons in the various segments of the cerebral cortex (Fig.14). In the areas where the loss was observed, the glial cells predominated. It was recorded in 1.92 per cent of the cases.

### **4.5.5 Chromatolysis**

Disappearance of neuronal nucleus and Nissl substance was observed in some whereas in others the cytoplasm remained with condensed contents and the nucleus completely disappeared. Granularity of the Nissl substance was not maintained and in completely chromatolysed regions, only a space remained with remnants of the neurons which appeared blue on staining with cresyl etch violet (Fig.16). The neurons appeared rounded with eosinophilic cytoplasm. This change was recorded in 5.77 per cent of the cases. It was seen mostly in the motor neurons of the mid brain (Fig.15) and to some extent in the neurons

of the cerebral cortex. This change was demonstrated by special staining with cresyl etch violet staining method.

#### **4.6 Purkinje cell changes**

##### **4.6.1 Purkinje cell degeneration**

The degeneration of the purkinje cells (Fig.9) could be detected in 7.70 per cent of the cases. The nuclear details had been lost and the cytoplasm appeared granular and eosinophilic. The nucleus had already undergone chromatolytic change. This degeneration was mainly observed in the cases brought for autopsy. The granular layer below the Purkinje cell layer in some of the above cases revealed reduced cellularity and loss of glomerular pattern of arrangement of the cells. Discontinuity of the Purkinje cell layer and presence of eosinophilic remnants of the damaged cells were seen in some cases (Fig.18).

##### **4.6.2 Purkinje cell loss**

The Purkinje cell appeared larger in size when compared to the other neurons and were arranged in linear pattern along the folia in normal cases. They were intact in the neuropil. In few cases, the loss of these cells was encountered which accounted to 3.85 per cent of all the cases.

#### **4.7 Necrosis**

A few cases revealed the presence of necrotic neurons and the necrosis was at the cellular level and not manifested as liquefactive necrosis. It was observed in about 7.70 per cent of the cases. The neurons of the cerebrum,

cerebellum, midbrain, pons and the medulla oblongata revealed such changes. The nuclear details were lost and the cytoplasm appeared eosinophilic and granular. Many neurons particularly in certain areas of the brain appeared ballooned with virtually no cytoplasmic architecture. Nucleus appeared centrally placed with prominent nucleolus. In some the nuclear chromatin appeared condensed in the form of a ring. Central chromatolysis was prominent as revealed by Cresyl eth violet stain. Neurons appeared condensed and homogenous without discernible nucleolus and cytoplasmic structures. The lesions were located at the gyral tips.

## **4.8 Inflammation**

### **4.8.1 Meningitis**

Abnormally large number of glial cells and mononuclears were found to be present in the space around the meningeal vessel walls in the leptomeninges (Fig.20). It was found extensive throughout the meninges. Meningitis accounted to 11.92 per cent of the cases. It could be observed chiefly in the cases brought for autopsy. Several affected meningeal arterioles revealed vasculitis and diffuse fibrinoid necrosis.

### **4.8.2 Meningo-encephalitis**

Perivascular cuffing in the brain was manifested as accumulation of cells in the Virchow robin space around the capillaries. There was involvement of both meninges and the brain parenchyma, both showed the presence of inflammatory cells. The cells observed varied from gemastocytic astrocytes,

plasma cells and mononuclears. Varying degree of cuffs was noticed in different layers of the brain. The cuffs were chiefly concentrated in the molecular layer and cortico-medullary layer of the cerebrum. In addition, varying layers of cuffs were observed in the granular layer of the cerebellum and the midbrain (Fig.19). The cuffs appeared either single layer thick or multilayered. In some cases, the dilated Virchow robin space was virtually filled with glial cells and in such cases, infiltration extended into the parenchyma (Fig.21). The perivascular cuffing accounted for 9.62 per cent of the total cases. They were mainly observed in the cases brought for autopsy and not in the slaughtered healthy animals.

#### **4.9 Inclusions**

##### **4.9.1 Negribodies**

Negribodies could be detected in the Purkinje cells of the cerebellum (Fig.23) in 1.92 per cent of the cases. It was subjected to special staining as per Maignani Magferrari method and the Negribodies were demonstrated as round eosinophilic intracytoplasmic inclusions (Fig.24). They varied from small sized to a size as big as the nucleus of the cell and their number within a cell varied from 1-2. However, in these cases, the Negribodies could not be detected in the impression smear of the cerebellum, stained with Seller's stain. In 1.92 per cent of the cases the impression smear revealed the inclusions but histopathological sections did not reveal the inclusions (Fig.22). However, there were no inflammatory changes associated with it. Negribodies could not be observed in

the other regions of the brain both in the impression smear examination and also in histopathology.

#### **4.9.2 Other inclusions**

Inclusions in the neuronal perikaryon accounted to 5.77 per cent of the total cases. These inclusions were detected in the cytoplasm of almost all the neurons (Fig.26) and the glial cells (Fig.27) of the cerebrum, the cerebellum and also the Purkinje cells (Fig.25). Even they were seen free within the axoplasm and dendrites of Purkinje cells. The size of the inclusions varied from pinhead size to very large (as large as the nucleus). They were ovoid to roughly triangular in shape and appeared eosinophilic in routine haematoxylin and eosin staining. Few of the inclusions revealed hollow at the centre. The number of inclusions varied from 1-3 within the perikaryon. These inclusions were not found to be Negri bodies on special staining and also were PAS negative.

#### **4.10 Spongiform changes**

Spongiform change in the brain was manifested as vacuolations (Fig.28a and 28b). These vacuolations were widely distributed in different layers of the brain. The molecular layer of the cerebrum revealed much of the vacuolations. The vacuoles appeared round and circumscribed. They were seen around the neurons too (perineuronal vacuolations) (Fig.8 and 28b) in the gray matter distributed in the parenchyma. It was widely distributed in the white matter and appeared as circumscribed to linear vacuolations along the course of the fibres. Special staining with Kluver Barrera luxol fast blue method confirmed it to be

the areas of demyelination. Few neurons of the mid brain region especially the motor neurons revealed intra neuronal circumscribed vacuolations having no visible, stainable internal contents. Most of such cells revealed only one vacuole in the perikarya (Fig.29). The nucleus appeared displaced. Encephalomalacic changes were exhibited as vacuoles and spongy appearance in the white matter of the brain. Such changes were found around the capillaries too. Spongiform changes were evident in 1.92 per cent of the cases. In majority of the cases the spongiform change was confined to the white matter region.

#### 4.11 Demyelination

In a few normal cases, the fibres were intact and no derangement was seen. The oligodendroglia were found to be present along the course of the fibres. In a few cases, the regular running of the fibres was deranged especially the one which was diagnosed as Theilirisosis on blood smear examination. There were spongiosis in between the nerve fibres (Fig.30). These areas of demyelination in the white matter were demonstrated by special staining with kluver Barrera luxol fast blue method. The demyelinated areas appeared colourless whereas the normal fibres appeared blue in colour (Fig.31). Such change accounted to 3.85 per cent of the cases. The demyelination was evident in the white matter of both cerebrum and cerebellum and also in the midbrain areas. Oligodendroglia appeared damaged and crowded in certain areas where demyelination was observed.



## **4.12 Cellular reactions**

### **4.12.1 Dark neurons**

Dark basophilic neurons were found to be present mainly in the slaughterhouse cases. The large pyramidal cells of the cerebrum, close to the meninges were affected mostly. The neurons appeared elongated, condensed and shrunken (Fig.32). It accounted to 19.23 per cent of the cases. These types of neurons were abundant over the crest of the cerebral gyri. Both the nucleus and the cytoplasm of the neurons appeared shrunken and stained deeply. There was moderate contraction of the neuronal cell body; dense basophilic staining of the cytoplasm usually obscured the nucleus. A single or a few dark neurons were seen within an otherwise normal appearing brain.

### **4.12.2 Binucleated neurons**

Binucleated neurons accounted to 1.92 per cent of the total cases. This was seen amidst the normal neurons of the cerebral cortex (Fig.33a and 33b).

## **4.13 Gliosis**

Gliosis (Fig.10, 21 and 33a) was exhibited as the increased number of the glial cells in a microscopic field. Abnormally large number of glial cell population could be detected in a few cases. This was widely distributed in different areas of both gray and the white matter of the cerebrum, cerebellum, midbrain (Fig.19 and 34), pons and medulla oblongata. Wide spread diffuse gliosis with occasional associated neuronal degeneration throughout the brain particularly in the cerebral cortex occurred in some of the cases. Mostly, gliosis

was a diffuse change all throughout the brain. It was very prominent in the cortico-medullary region in most of the cases. Among the glial cell population, the microglia and the oligodendroglia were found to be in larger proportion when compared to the few astrocytes. Gliosis accounted to 28.85 per cent of the cases.

#### **4.13.1 Glial nodules**

The degenerated neurons were invaded and phagocytosed by the glial cells. A few cases revealed more number of glial cells around the damaged neuron (Fig.34) to form a glial nodule. Only neuronal remnant could be seen. The nodule contained chiefly the microglial cells, which were small, dark and elongated. The glial nodules recorded to 5.77 per cent of the cases.

#### **4.14 Sub ependymal accumulations**

Abnormally large number of cellular accumulations was detected in the subependymal region of the ventricle. They were chiefly neurons and glial cells crowding in that area. They appeared to be dark and elongated. In addition, inflammatory cells were present amidst of the neurons. Such accumulations accounted to 3.85 per cent of the cases.

#### **4.15 Astrocytosis**

An increase in the number of astrocytes when compared to the normal could be detected in a few cases. The number of astrocytes was found to be more per microscopic field. They appeared elliptical and vesicular. They were

chiefly found in the gray matter of the brain. Such changes accounted to 5.77 per cent of the cases.

#### **4.15.1 Gemistocytes**

These were observed as swollen astrocytes in the perivascular area (Fig.35). They appeared larger than the astrocytes with eccentric nucleus and foamy eosinophilic cytoplasm. These cells were found to be present amidst the inflammatory cells around the blood vessels along with other glial cells in the cerebral cortex as well as in the white matter region of the cerebellum. Also, they were distributed in the parenchyma close to the neurons undergoing degenerative changes and the vessels undergoing similar changes. Some were found in the adventitia of the vessels and also crowding around the vessels in the perivascular space. These swollen astrocytes accounted to 9.62 per cent of the cases.

#### **4.16 Axonal swelling**

Swollen axons appeared as round, eosinophilic bodies in the parenchyma. They were chiefly confined to the cerebral cortex. Such swollen axons were observed in 5.77 per cent of the cases.

#### **4.17 Gitter cells**

Gitter cells appeared moderately bigger than the microglia and the oligodendroglia. They were seen around the blood vessel in the perivascular cuffs. These cells accounted to 3.85 per cent of the cases. These cells were found to be present amidst the inflammatory cells.

#### **4.18 Cystic spaces**

Abnormally large spaces were found to be present in the white matter of cerebrum and cerebellum in a few cases. The areas adjacent to the cystic spaces appeared normal. This change was not seen in the gray matter. Such changes accounted to 1.92 per cent of the total cases.

#### **4.19 Autolysis**

Diffuse irregular vacuolations were detected in the neuropil of the gray matter and along the course of the nerve fibres (Fig.36) in a few cases. The cells and the fibres appeared more eosinophilic. Loss of tissue was also seen to be present in some of the cases. These changes were mostly observed in the cases brought for autopsy. This accounted to 7.70 per cent of the cases. Wide separation of the cells of the granule layer of the cerebellum along with uniform separation of fibres also indicated autolysis.

#### **4.20 Mucocytes**

Mucocytes (Buscaino bodies) appeared as irregular pale blue gray amorphous bodies and were detected in the cerebral cortex region (Fig.37). They were PAS positive and metachromatic. It was seen in 1.92 per cent of the cases.

#### **4.21 Melanin pigments**

Unusually, high deposits of melanin appearing as dark brown granules crowding the cells were seen in the intersulcal areas and the leptomeninges (Fig.38). In 3.85 per cent of the cases, this was prominent.

#### 4.22 Sinus tumour

In one case of sinus tumour a portion of the tumour was found invading the brain after lysing the ethmoid bone and pressing the brain. The meninges appeared very much thickened and the area of the brain appeared depressed. Histologically, very great thickening of the meninges was observed. The fibres appeared thickened and sclerotic. Calcification of spicules of the bone was observed in the dura and the pia-arachnoid which was confirmed by staining with Alizarin Red (Fig.39). Squamous cells were seen as sheets in the pia-arachnoid. Extensive haemorrhage along with siderophages (Fig.40) was seen in the affected area. The neurons close to this appeared condensed. Invasion and infiltration of the cells to the gray matter was limited.

Fig.1 Meningeal congestion

Fig.2 Traumatic injury – stunning

Fig.3 Meningeal congestion and subdural haemorrhage – H&E x 160

Fig.4 Corticomedullary region - Haemorrhage. haemosiderosis and congestion – H&E x 160

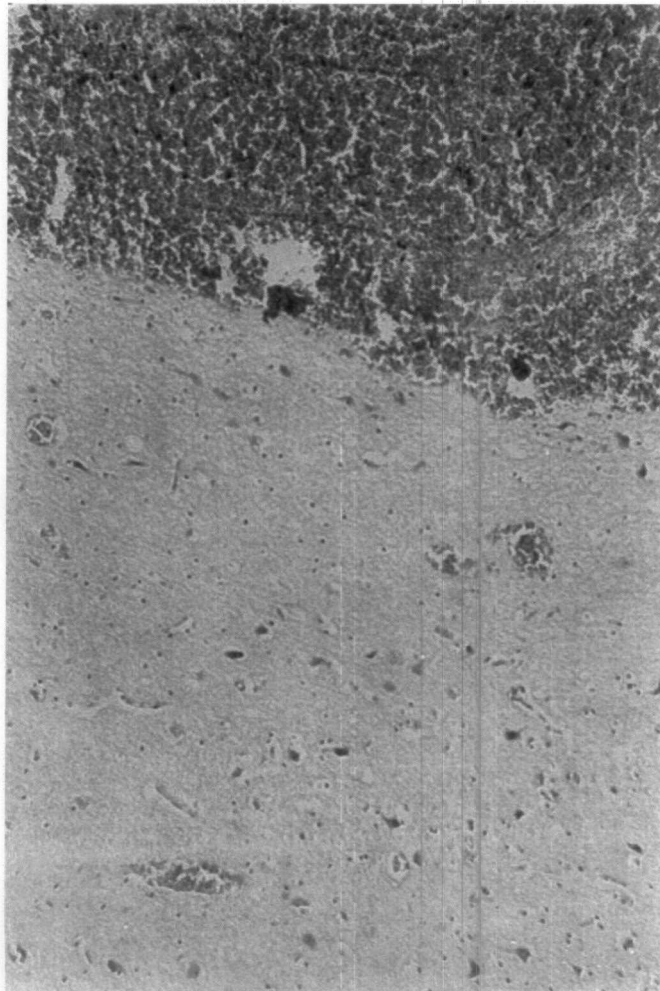
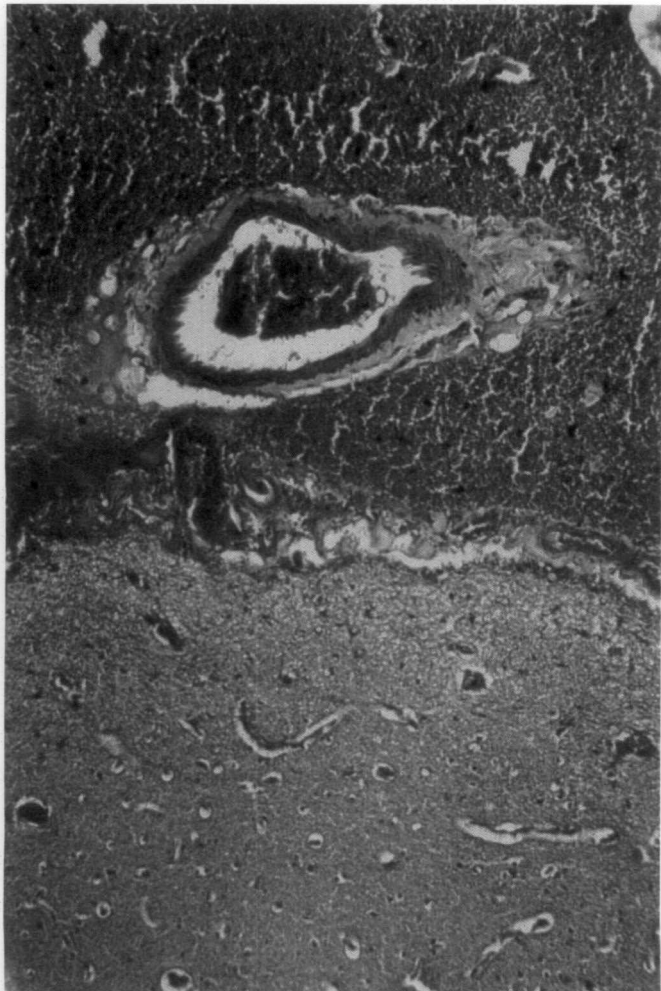
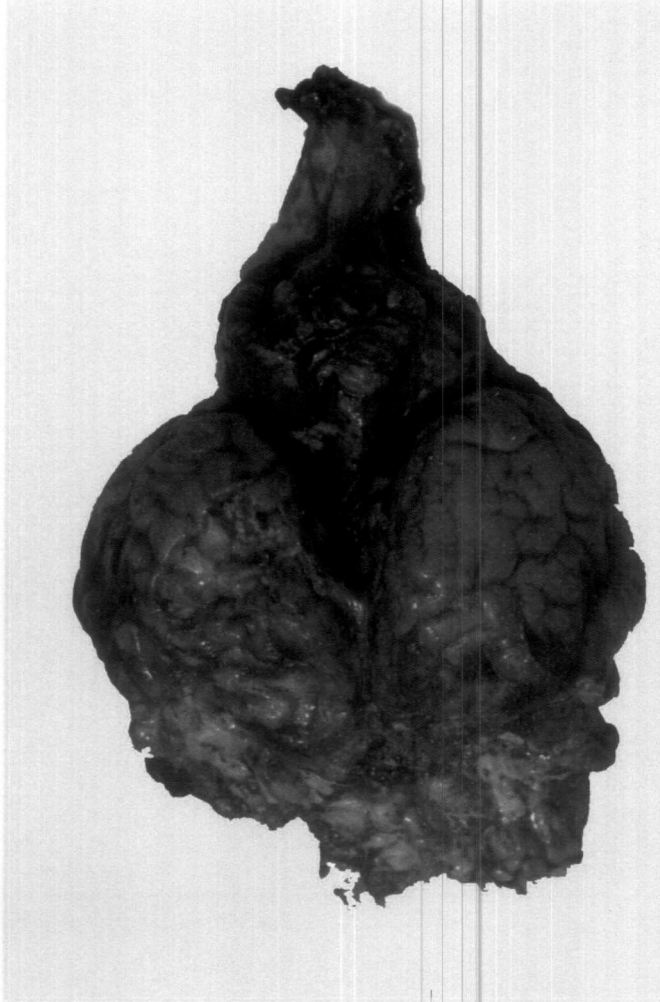
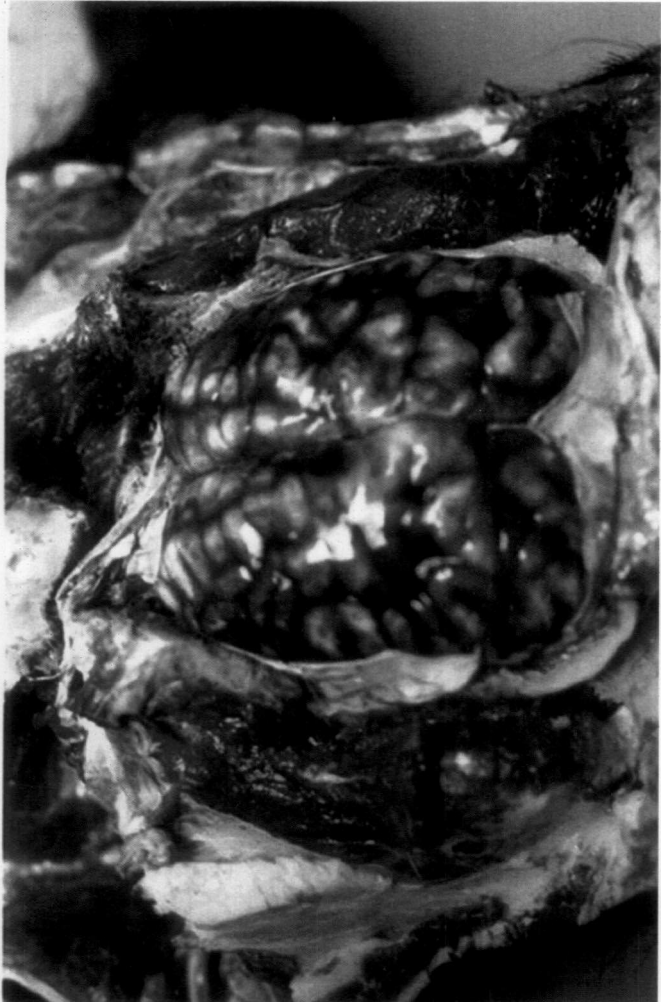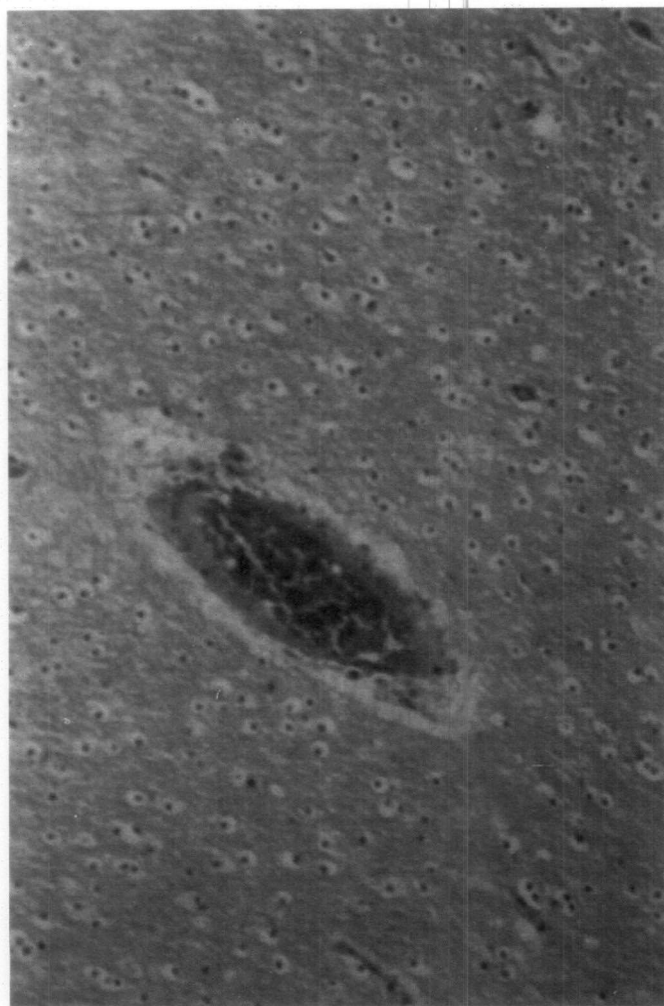
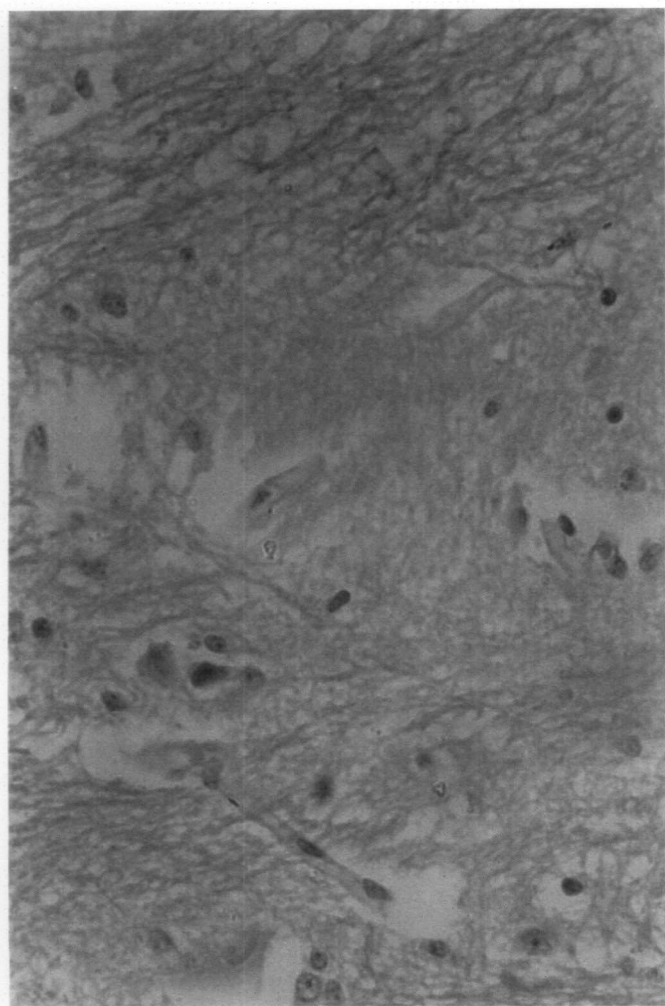
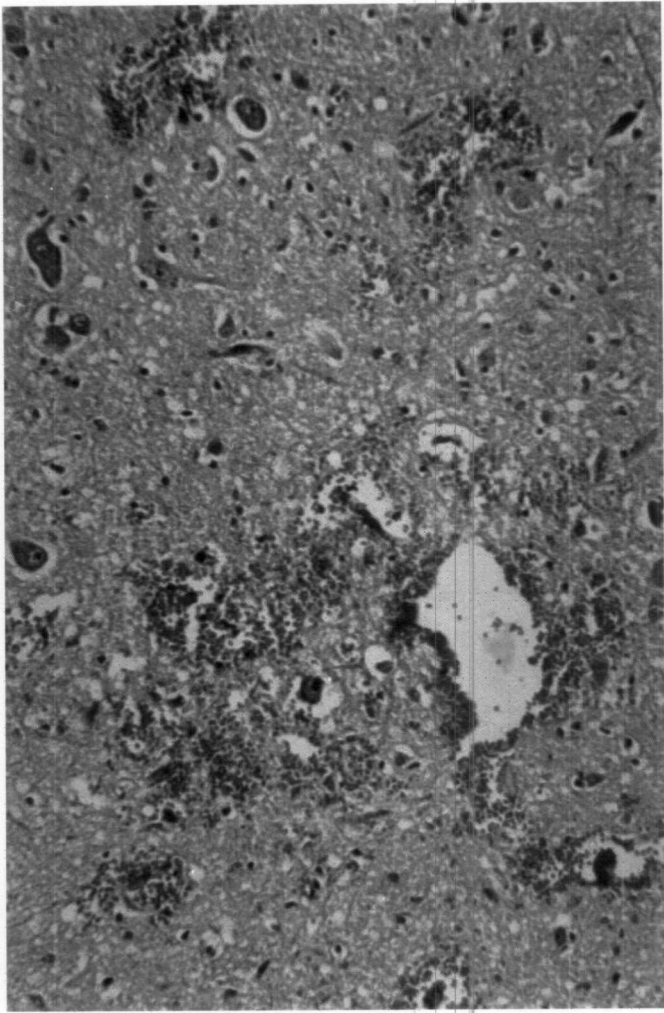



Fig.5 Subependymal region - Haemorrhage – H&E x 160

Fig.6 Haemorrhage, neuronal shrinkage – H&E x 250

Fig.7 White matter – intramyelinic edema exhibited as wide interfascicular spaces – H&E x 400

Fig.8 Congestion and vacuolations around the neurons and glial cells – H&E x 250



47

Fig.9 Molecular layer of cerebellum – Neovascularisation,  
Purkinje cell degeneration – H&E x 250

Fig.10 Cerebrum – Neovascularisation and gliosis - H&E x 250

Fig.11a Cerebrum - Perivascular sclerosis and congestion - H&E, x  
250

Fig.11b Perivascular sclerosis and congestion – PTAH x 160

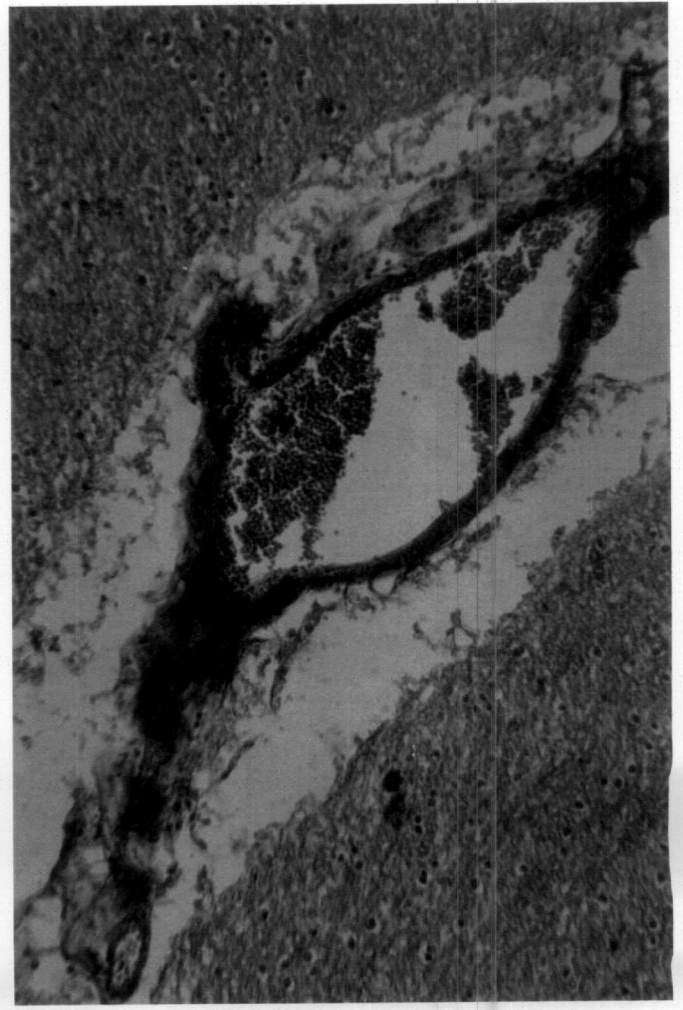
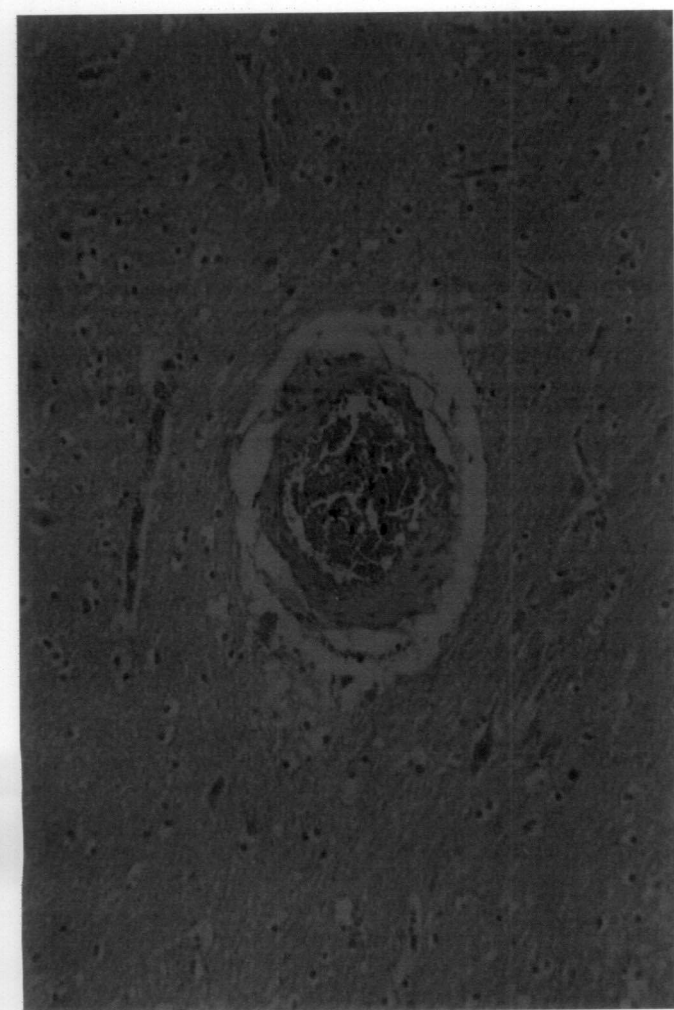

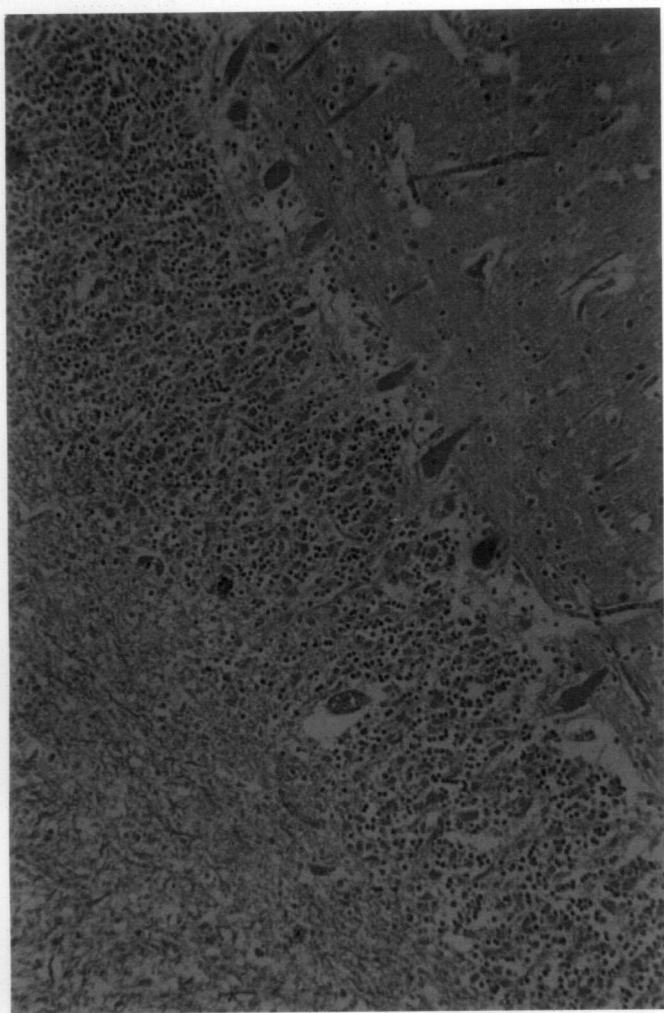


Fig.12 Collapse of capillaries, perivascular space dilatation progressing to cavitation - H&E x 100

Fig.13 Neuronal degeneration and satellitosis - H&E x 250

Fig.14 Gray matter - Loss of neurons in the cortex - Cresyl echt violet x 250

Fig.15 Mid brain - motor neurons showing Nissl clumping and homogeneity of the nucleus - Cresyl echt violet x 1000

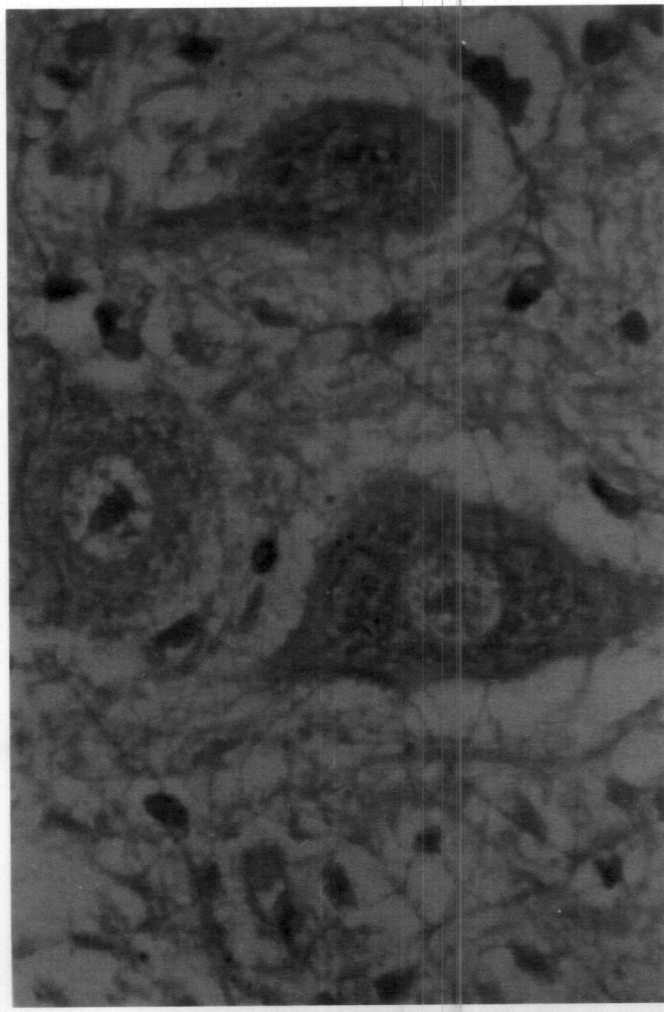
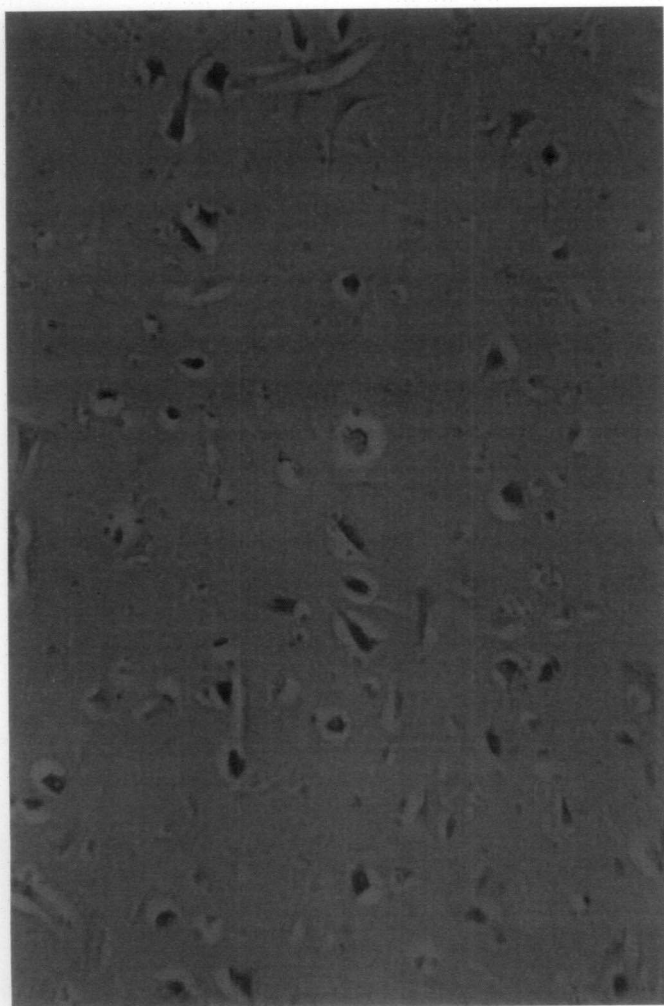
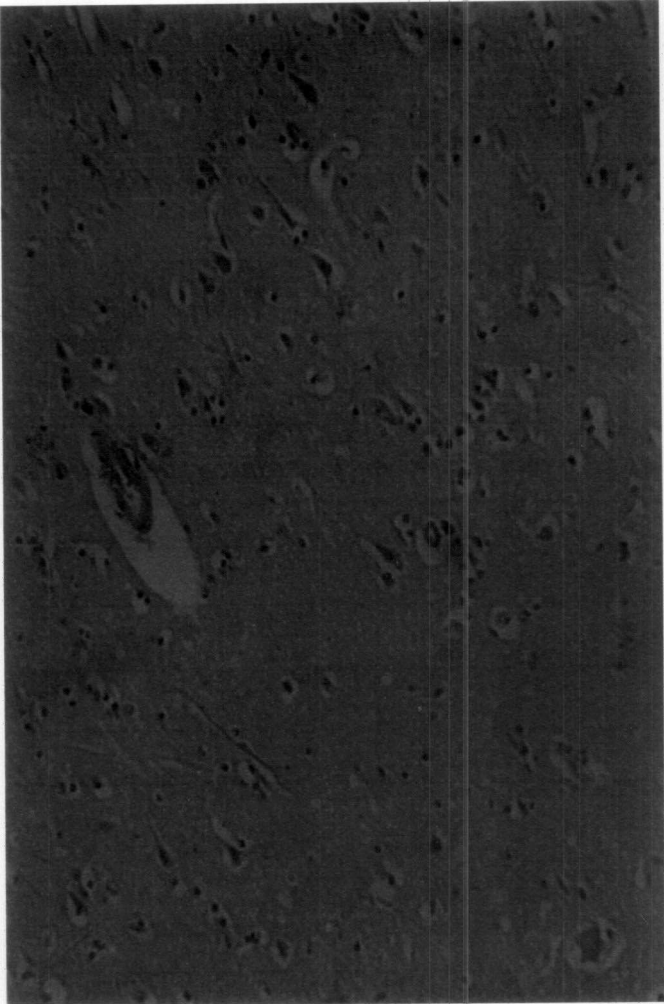
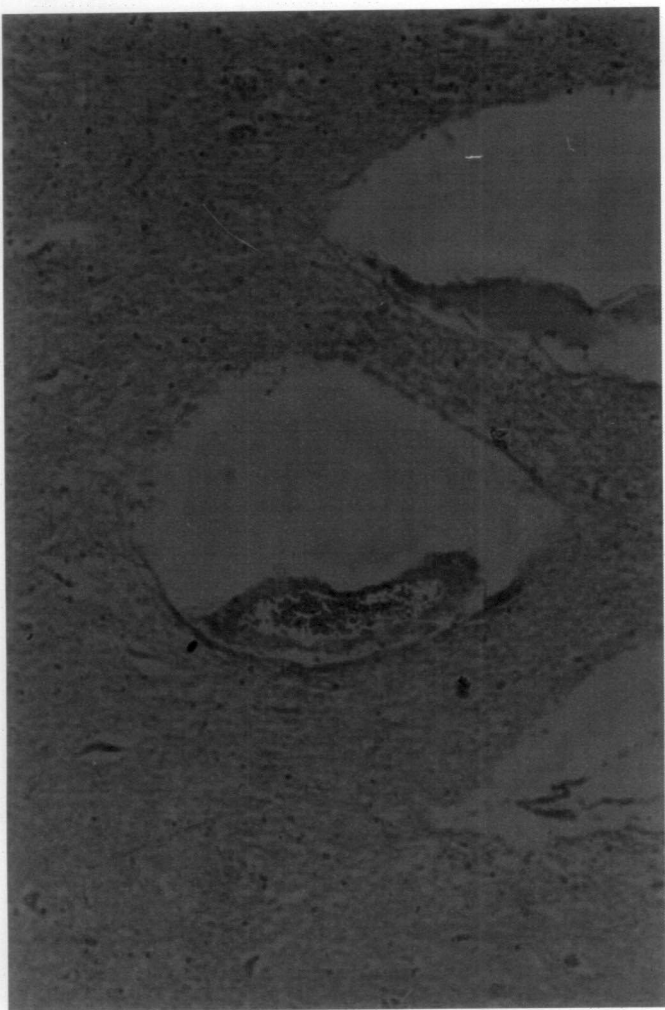


Fig.16 Cerebral cortex – loss of granularity of Nissl substance and dilated perineuronal space with neuronal remnants – Cresyl echt violet x 1000

Fig.17a Congestion, endothelial swelling and fibrinoid degeneration of the blood vessel - H&E x 400

Fig.17b Congestion, endothelial swelling and fibrinoid degeneration of the blood vessel - H&E x 1000

Fig.18 Cerebellum – Purkinje cells appearing as eosinophilic remnants - H&E x 250

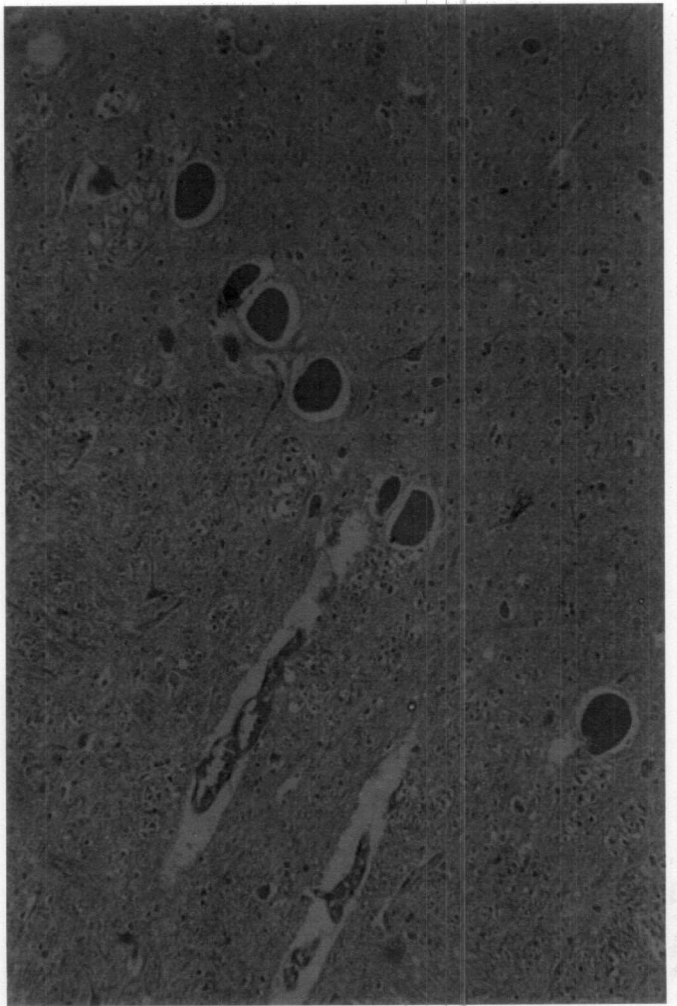
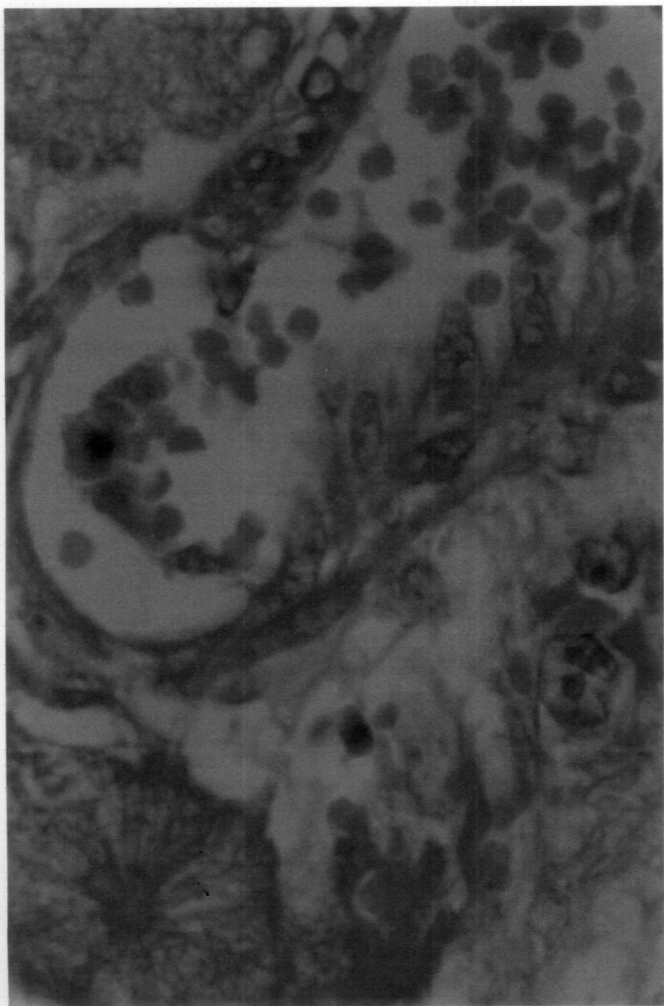
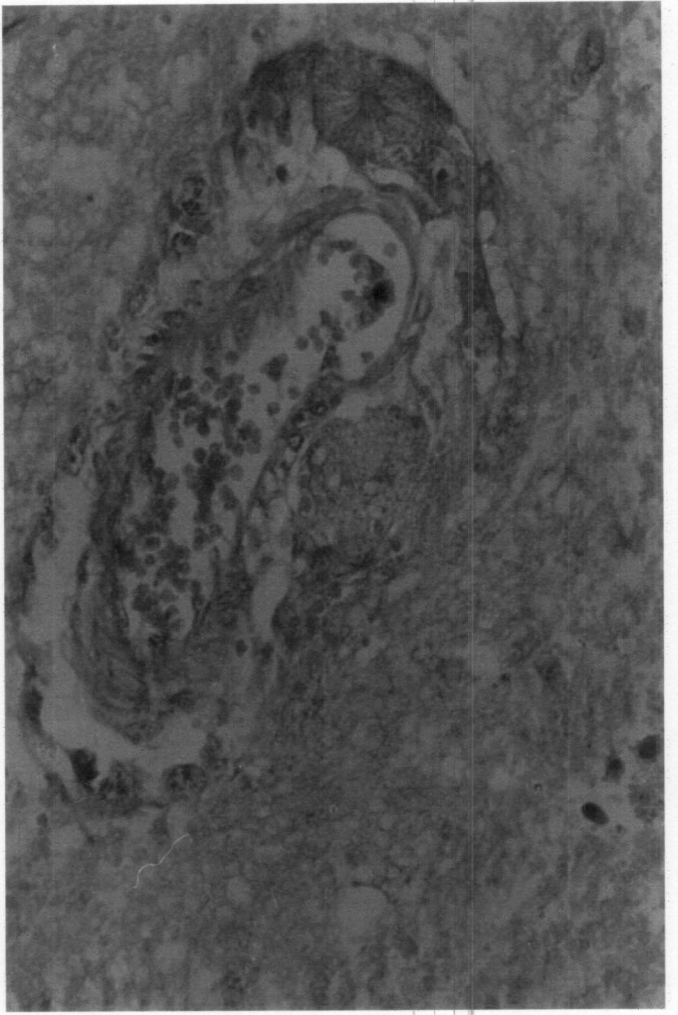
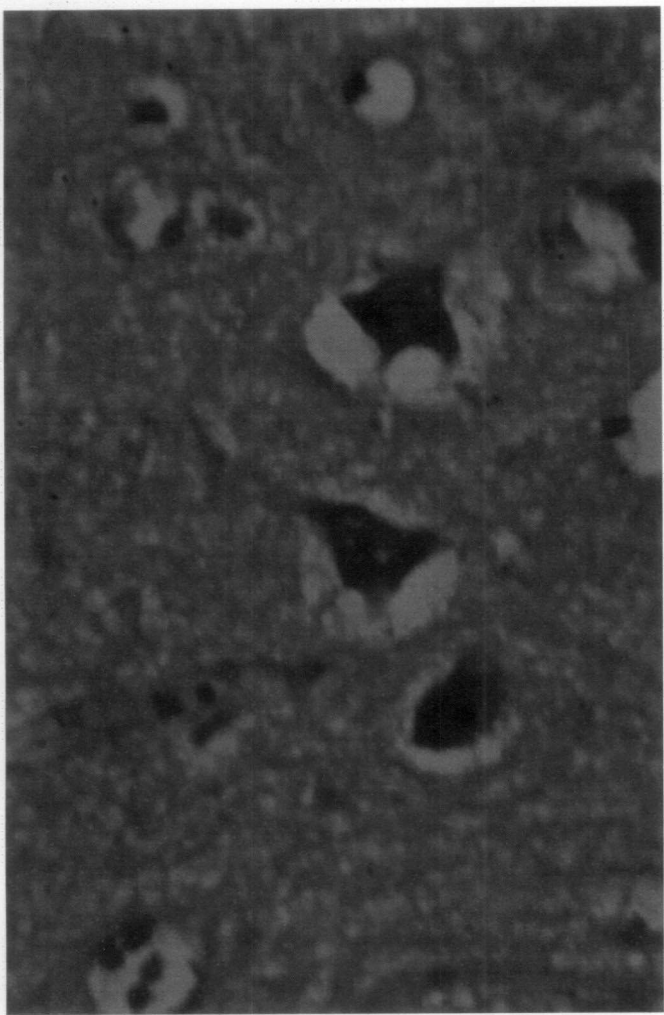


Fig.19 Mid brain - Perivascular cuffing and gliosis - H&E x 250

Fig.20 Inflammatory cell infiltration in the meninges - H&E x 250

Fig.21 Cerebrum - Perivascular cuffing and gliosis - H&E x 160

Fig.22 Impression smear - Negribody in the Purkinje cell -  
Seller's stain x 1000

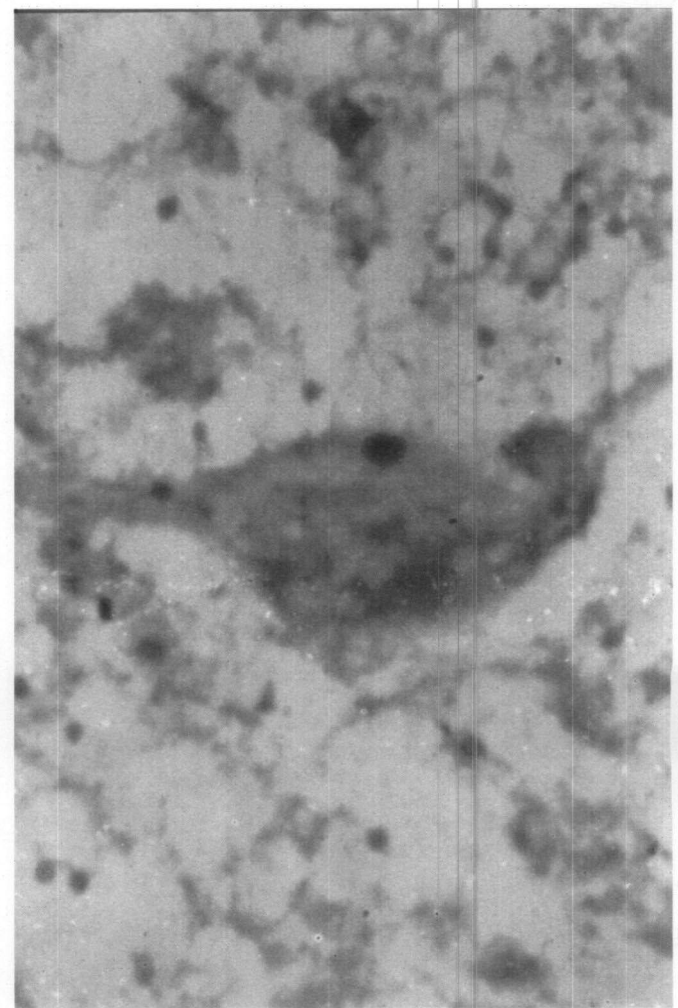
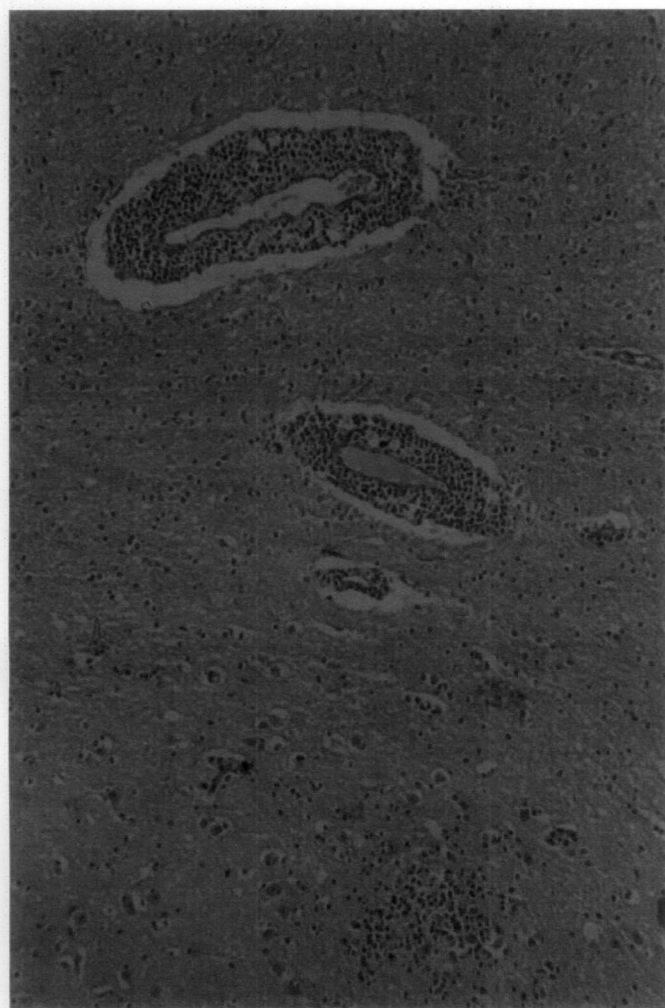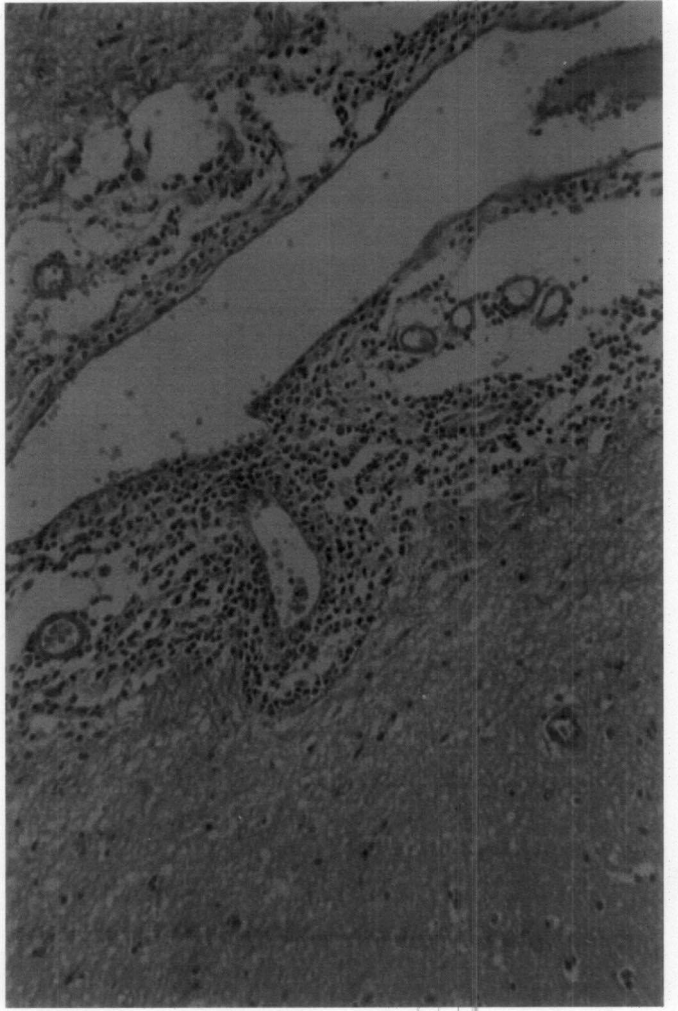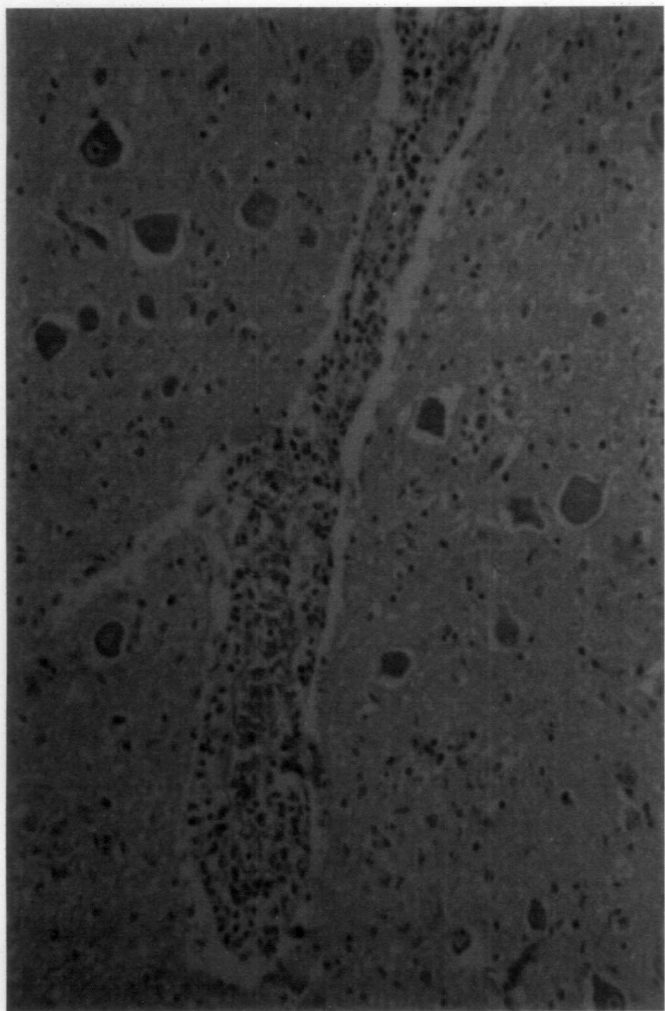


Fig.23 Cerebellum – Negribody with halo around in the Purkinje cell - H&E x 1000

Fig.24 Cerebellum – Magenta coloured Negribody in the Purkinje cell – Massignani Magferrari stain x 1000

Fig.25 Cerebellum – Intracytoplasmic inclusions of varying size in the Purkinje cell - H&E x 1000

Fig.26 Cerebrum – Intracytoplasmic inclusions in the neurons - H&E x 1000

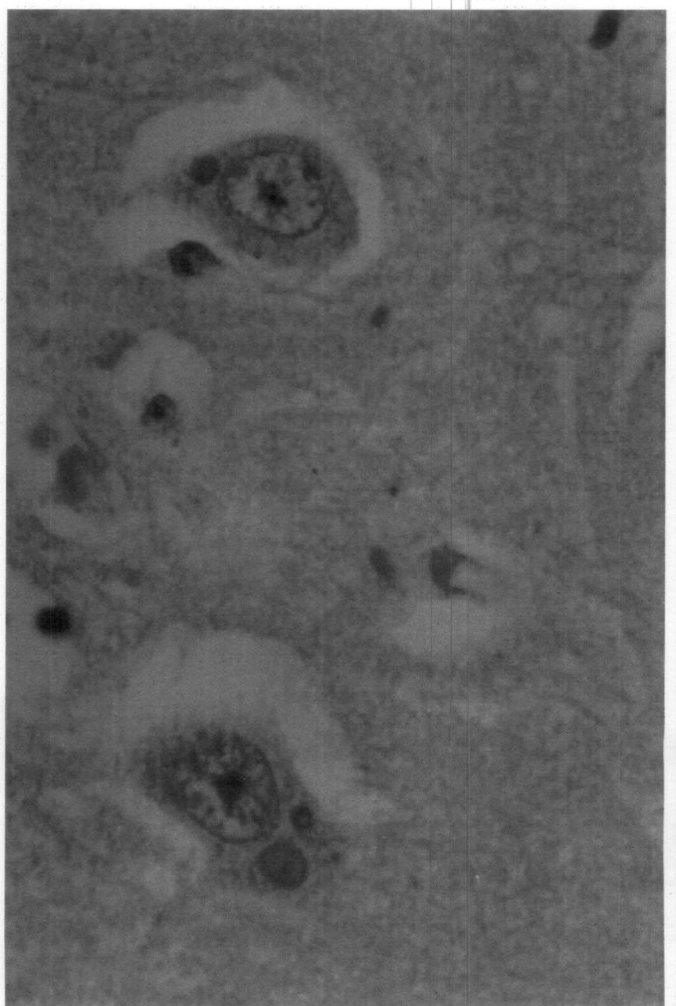
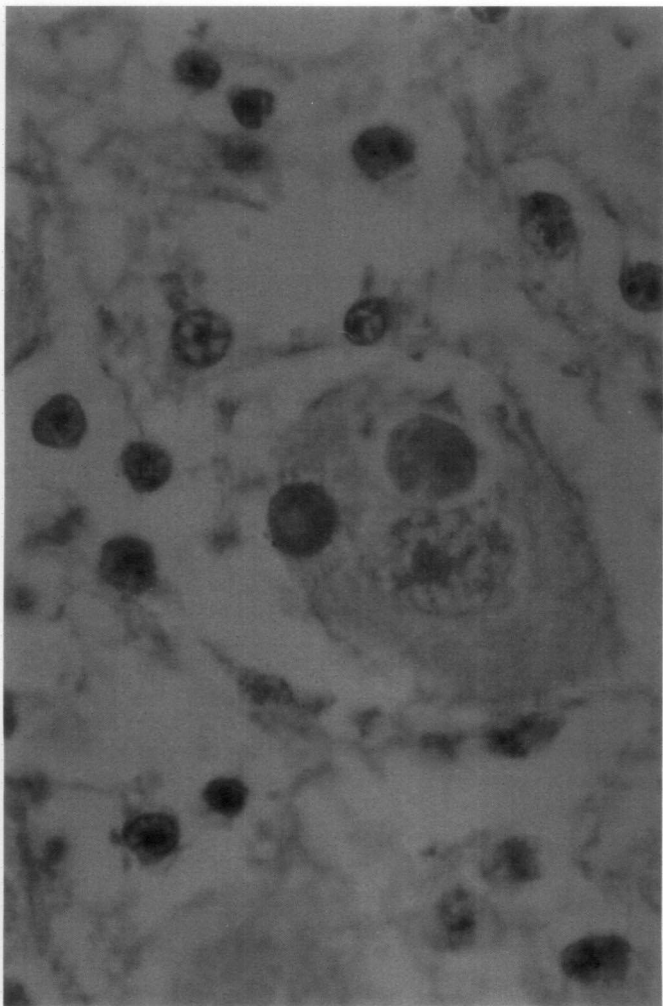
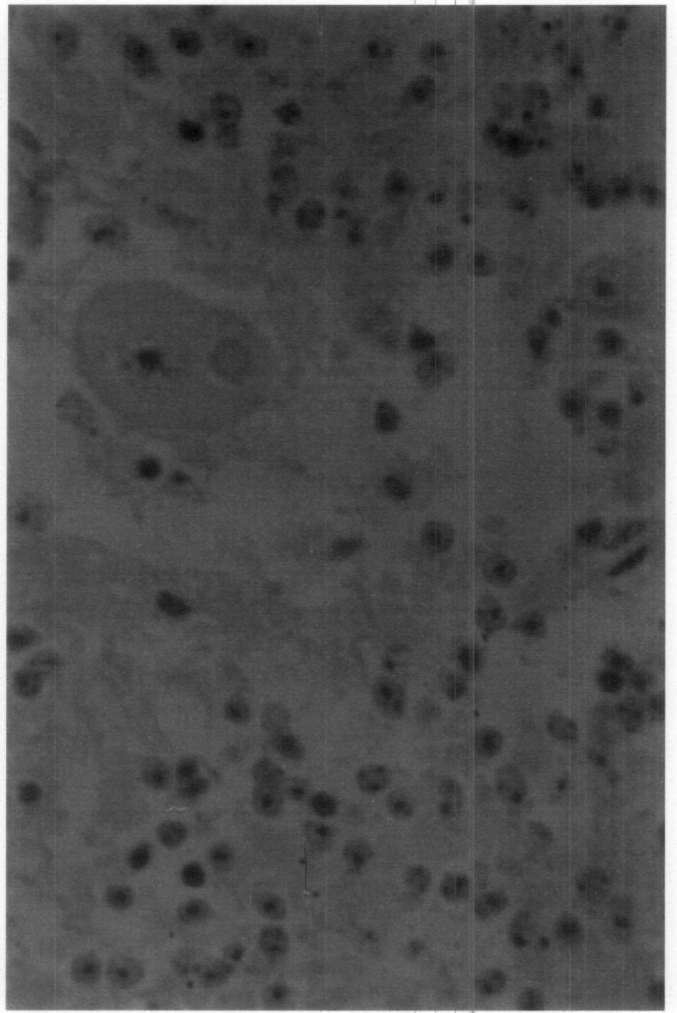
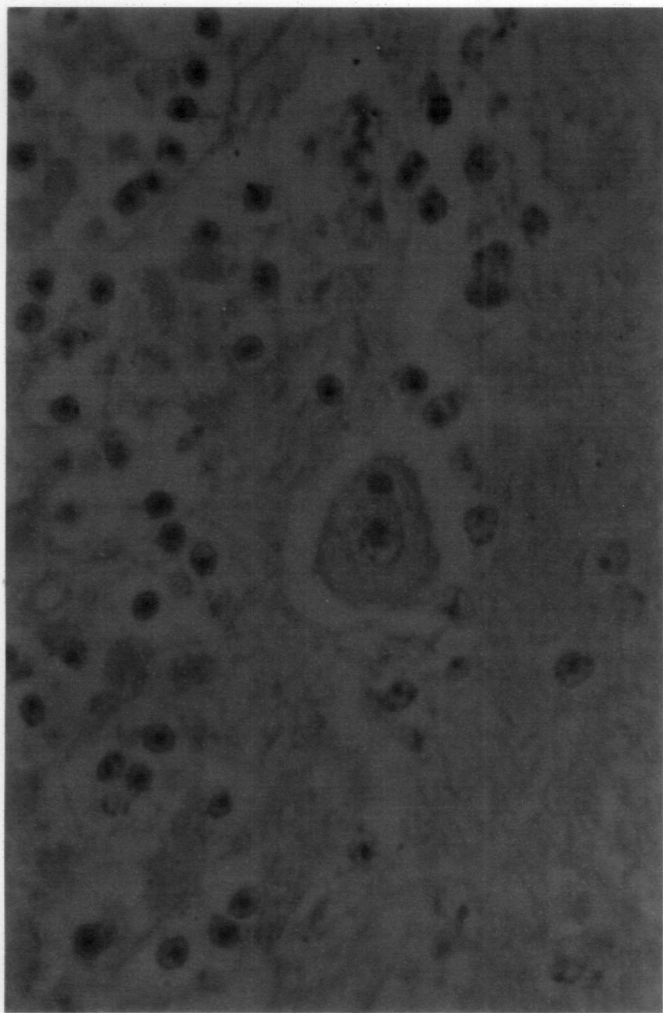


Fig.27 Intracytoplasmic inclusion in the glial cell - H&E x 1000

Fig.28a Cerebrum – perivascular vacuolations, perineuronal cavitation - H&E x 400

Fig.28b Perineuronal vacuolations - H&E x 250

Fig.29 Mid brain – intraneuronal cytoplasmic vacuolation – PTAH x 250

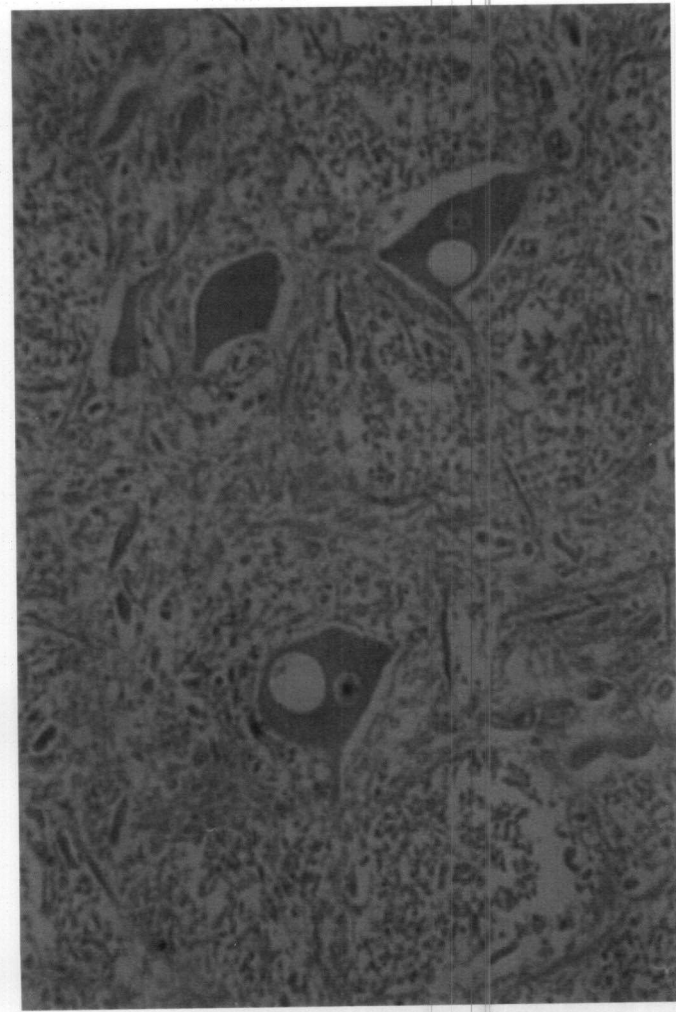
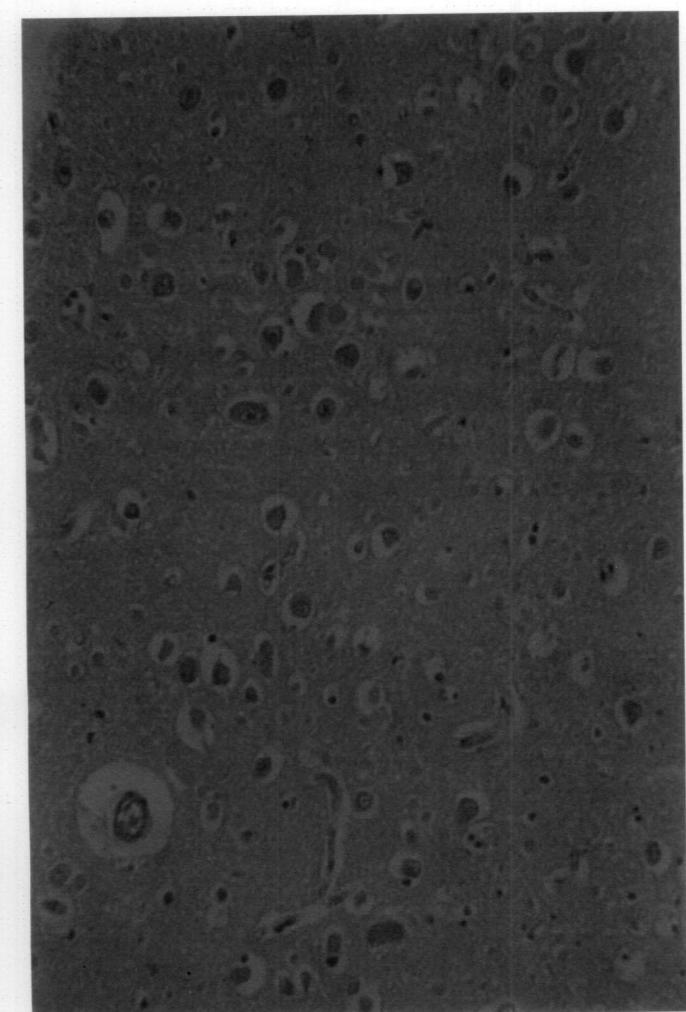
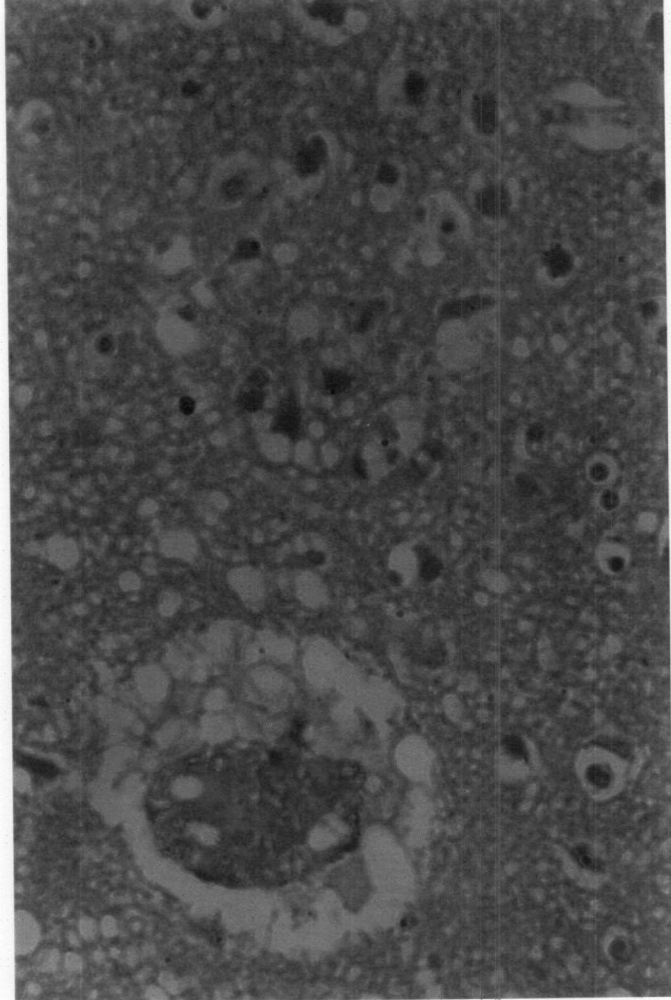
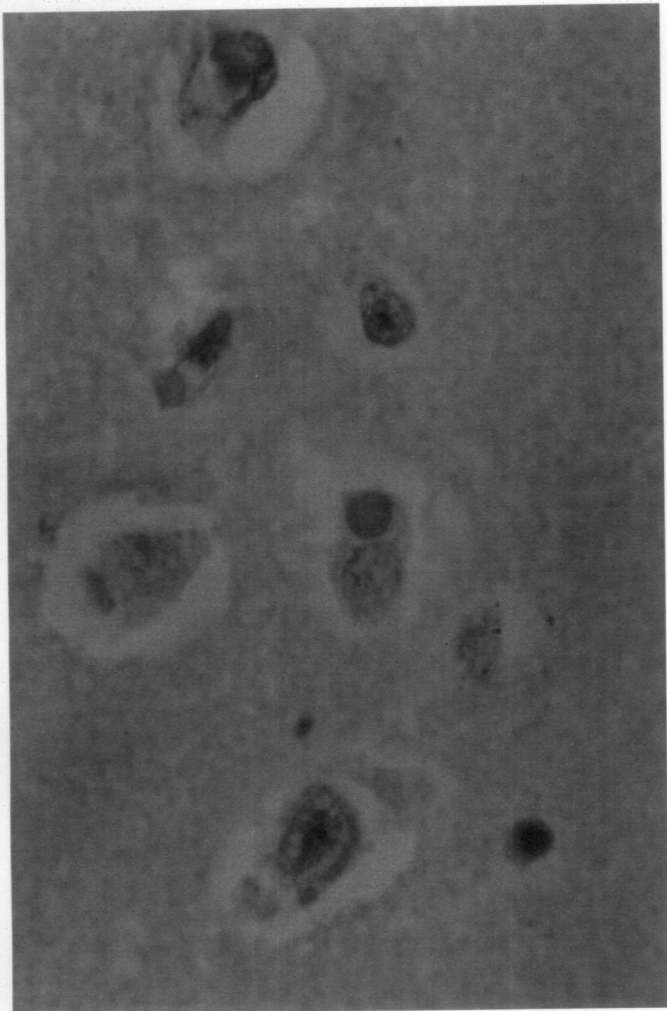

Fig.30 Linear vacuolations along the course of the nerve fibres in the white matter, myelinated areas appear blue – Luxol fast blue x 1000

Fig.31 Demyelination and congestion - normal areas appear blue, demyelinated areas appearing colourless – Luxol fast blue x 160

Fig.32 Cerebrum – meningeal congestion, haemorrhage and dark neurons - H&E x 160

Fig.33a Cerebrum – Neuronal degeneration, gliosis and binucleated neurons - H&E x 250

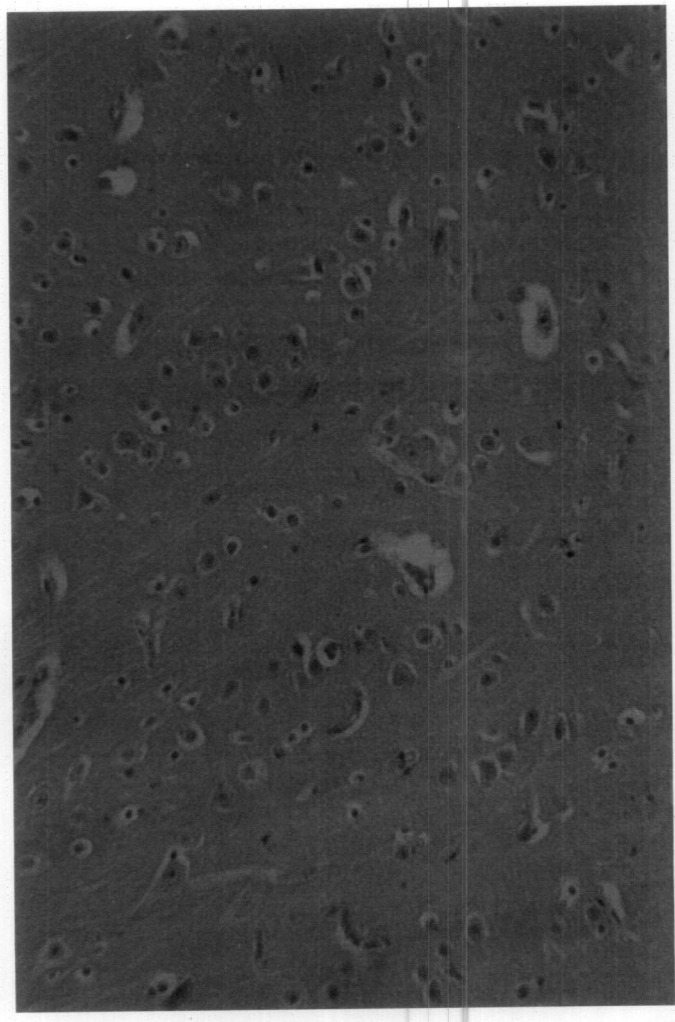
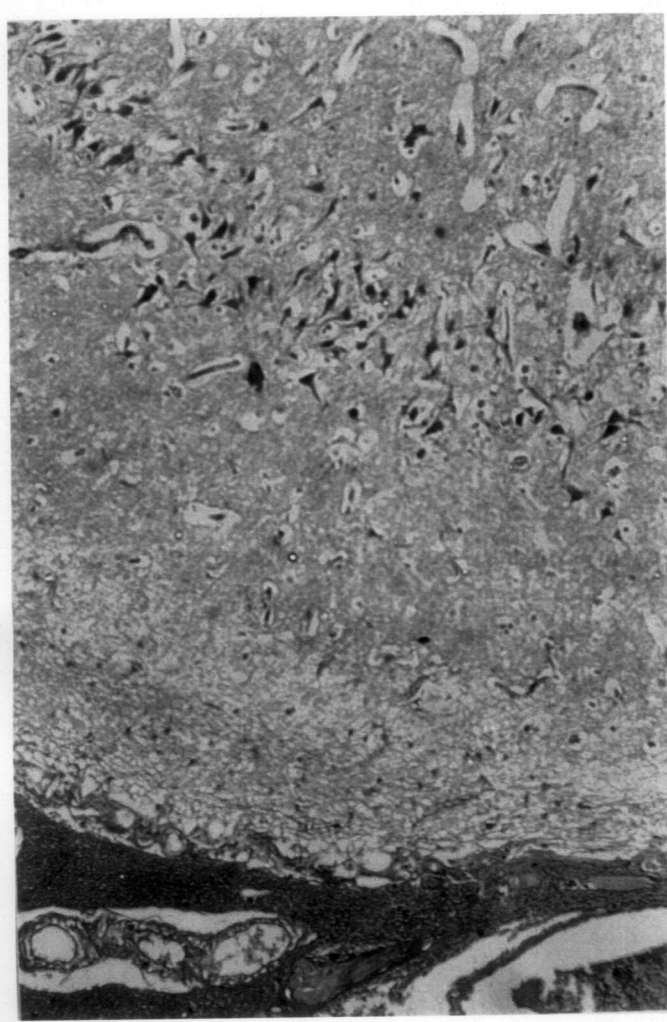
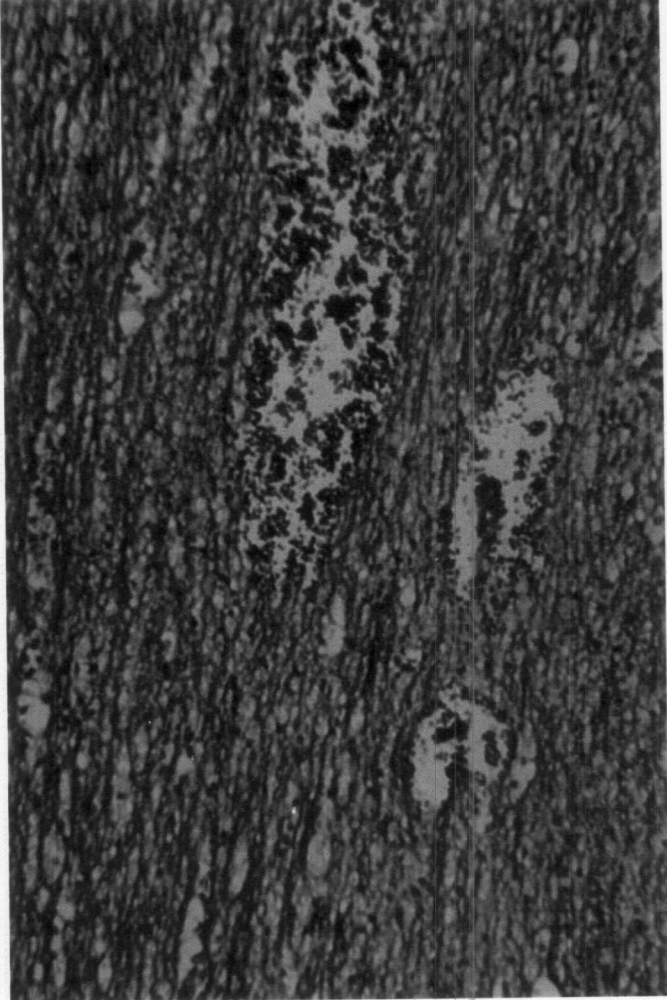
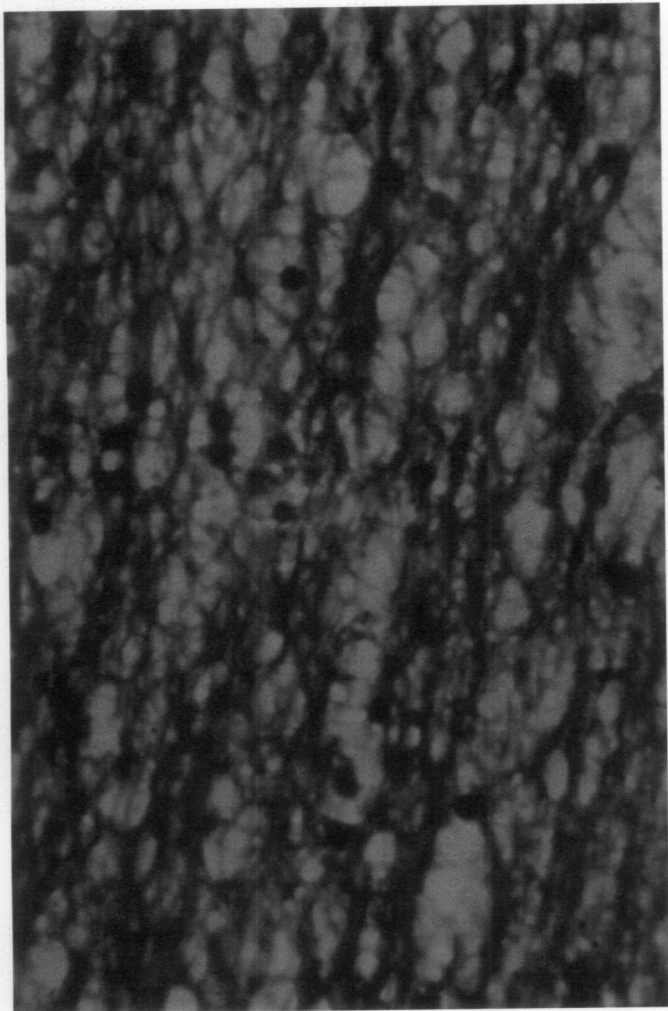


Fig.33b Cerebrum – Binucleated neurons - H&E x 1000

Fig.34 Mid brain – gliosis - H&E x 250

Fig.35 Gemistocytes around the blood vessel - H&E x 400

Fig.36 Cerebrum - Irregular vacuolations, eosinophilic cells, autolytic changes and gliosis - H&E x 250

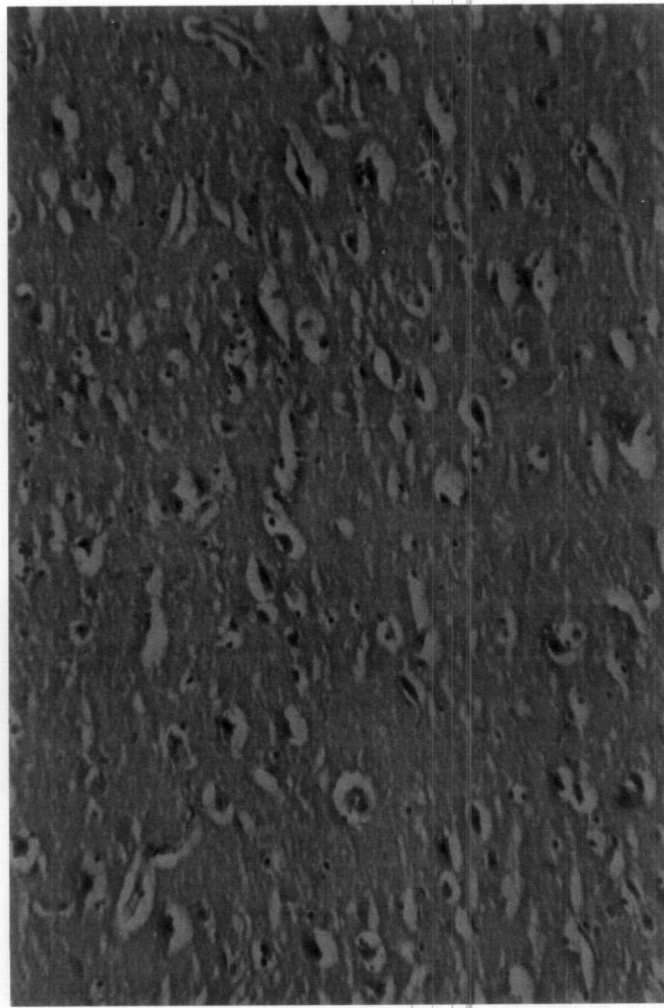
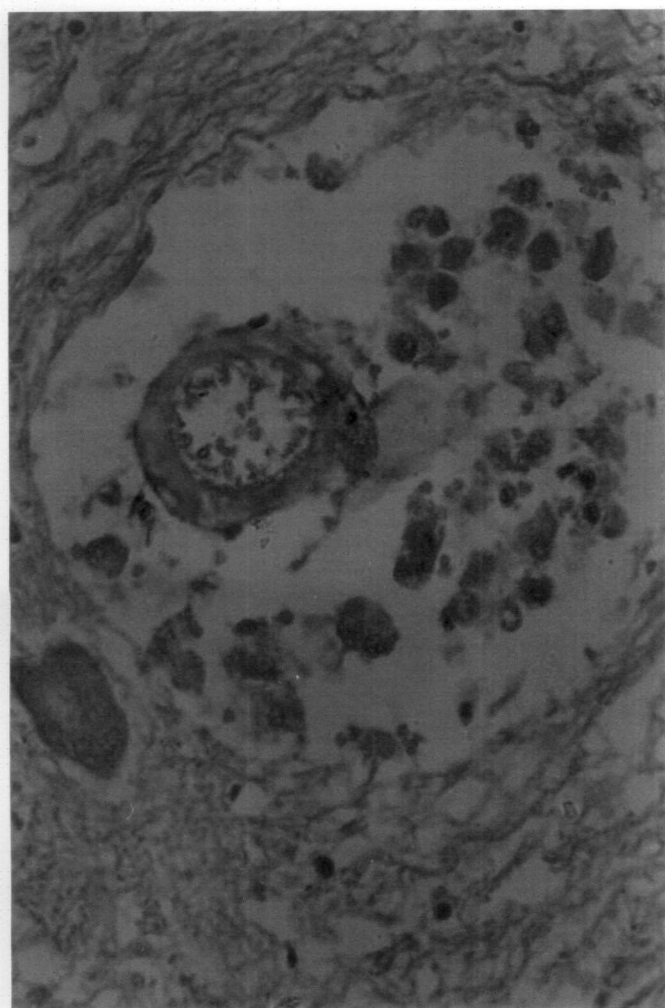

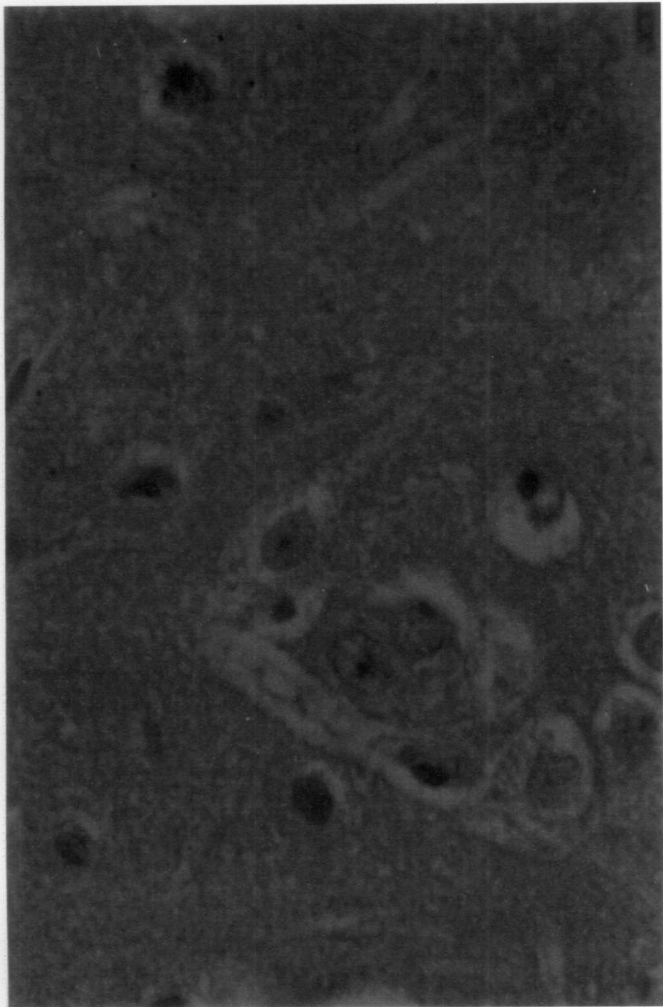
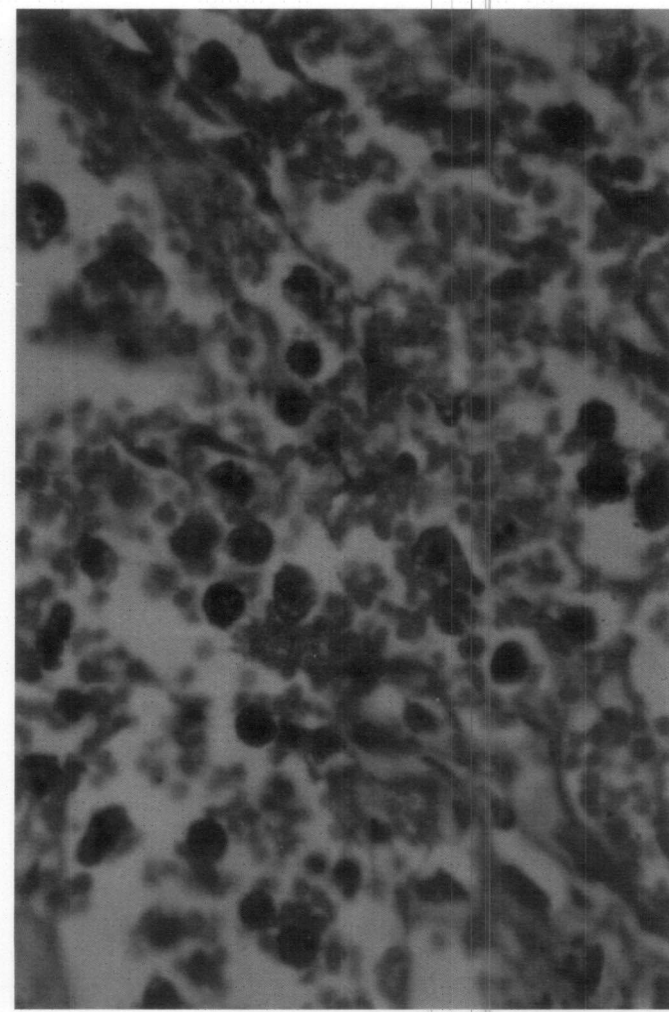
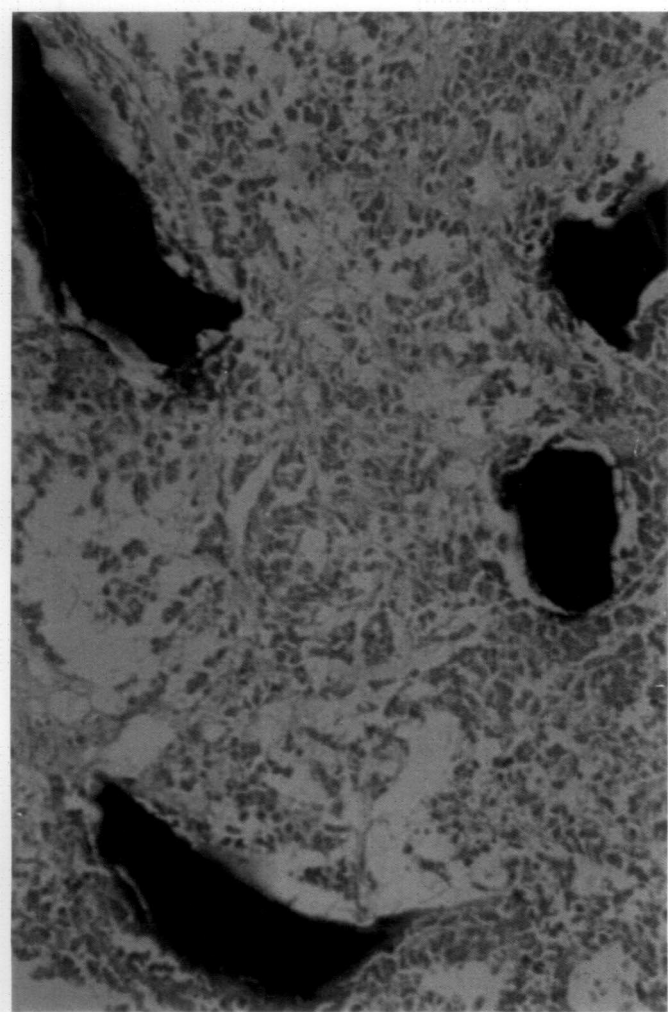
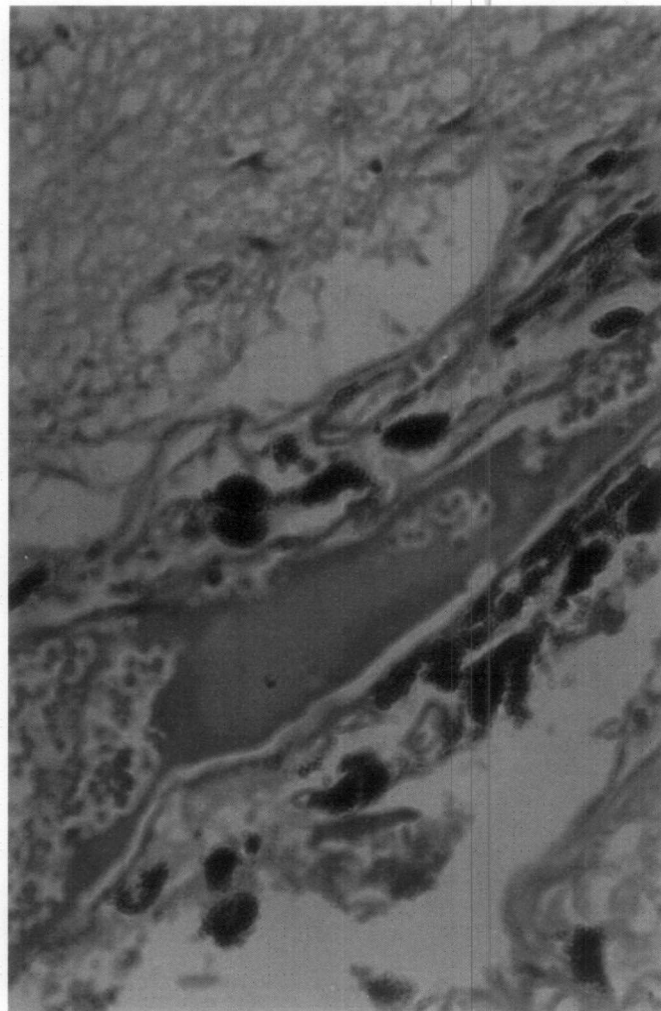
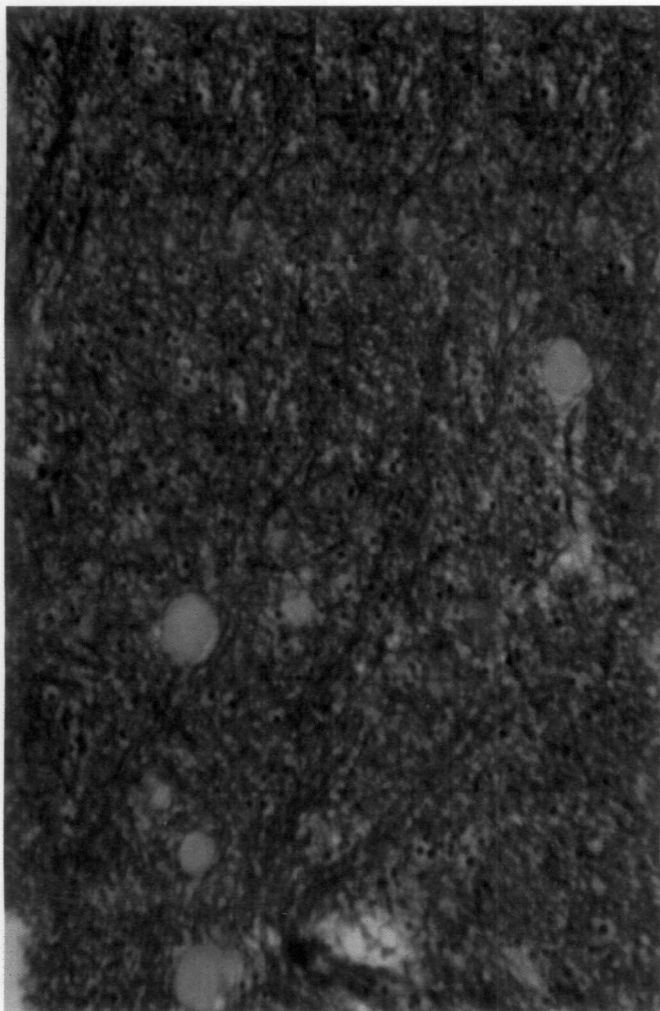


Fig.37 Cerebrum – Amorphous bodies (mucocytes) - H&E x 250

Fig.38 Melanin pigmentation around the blood vessel wall in the meninges - H&E x 250

Fig.39 Sinus tumour – presence of calcification – Alizarin red x 1000

Fig.40 Sinus tumour – haemorrhage and siderophages in the affected area - H&E x 1000



## *Discussion*

---

## 5. DISCUSSION

The present study was undertaken to investigate the prevalence and pathology of brain disorders in cattle and special attention to rule out the presence of Bovine Spongiform Encephalopathy by histopathological examination.

The data collected from the autopsy records maintained at the centre of Excellence in Pathology, gross and histopathological features of the samples collected from both the slaughtered cattle and the necropsy cases formed the materials for the study.

Analysis of the data collected from the autopsy record revealed 33 percent occurrence of various brain disorders in bovine for the past five years. On the other hand, the present investigation during the period from January 2001 to October 2002 revealed 72 percent prevalence of brain disorders. This significant increase in the disorders of the brain could be attributed to the small sample size, short duration of the period of the study as well as lack of examination of brain during routine autopsies in the previous years. There was marked difference in the prevalence of brain lesions among the animals brought for autopsy and those observed at slaughter. The higher incidence of lesions was noticed in the samples brought for autopsy, which invariably had suffered some disease and indicated the underlying systemic involvement. Unfortunately, the whole carcasses were not available for detailed systematic examination to correlate the findings in all the cases. Often the head was made

available for examination to rule out rabies, which limited the scope for systematic correlation of the lesions encountered in histopathology. Therefore, this observation necessitates the insistence of complete examination of the carcass during routine autopsy in all cases showing some form of nervous disorder. The disorders were limited in slaughtered animals, as they were apparently healthy at the time of slaughter. There was no significant difference between the sexes in the prevalence of brain disorders.

The various brain lesions were categorised and catalogued based on the gross and histopathological features. It is worthy to note that not all animals reported to have shown nervous signs before death brought for autopsy revealed histopathological lesions. At the same time some of those having no nervous signs revealed considerable lesions in the brain. The reason may be that the changes might have occurred at the biochemical level and thus no lesion could be appreciated at the light microscopic level. Samples from the slaughterhouse revealed chiefly the vascular changes like meningeal congestion and haemorrhage that could be attributed to the effect of stunning before slaughter.

Histopathologically, the lesions varied from congestion, haemorrhage, degeneration, and necrosis to inflammation, which could be associated with hypoxic injuries, infection and toxicities. It is also noteworthy to mention that, some of the cases that showed histological lesions of degeneration and inflammation had no gross lesions in the brain.

Sprouting of capillaries engorged with blood could be seen in the cerebrum, cerebellum and areas of the midbrain in a few cases. Schulman (1968) regarded these vascular changes as simply reactions to the intense parenchymal degeneration. Sprouting of capillaries in the cerebral cortex and prominence of them was described in PEM by Lonkar and Prasad (1994). However, in these cases, no lesions suggestive of PEM could be observed. Meningeal and meningeal sulcal vessels appeared engorged with blood and thickened in a few cases which indicated primary injury to the blood vessel wall. There was discontinuity in the vessel wall, endothelial swelling and necrosis. Truceman and Clague (1978) found thickening of arterial walls and attributed the cause to sodium chloride poisoning in cattle. Dilatation of capillary bed leading to cavitation and focal proliferation of endothelial cells and swollen astrocytes were seen in the vicinity of such capillaries in a few cases. Capillary bed dilatation, proliferation of endothelial cells along with sprouting and formation of new vessels, swollen astrocytes, haemorrhage, formation of cavities and preservation of neurons were due to altered capillary permeability (Schulman, 1968). Perivascular space dilatation, progressing to cavitation and crowding of gemistocytes were found in a few cases. This space formed may be due to hypoxia and edema. Similar findings were reported by Nair *et al.* (1985) in *Ficus tsiela Roxb* poisoning in calves, *Trypanosoma brucei rhodesiense* infection in cattle (Wellde *et al.*, 1989) and in PEM (Lonkar and Prasad, 1994).

Degenerative and necrotic changes observed in the neurons were diffuse and seen both in autopsy cases and the slaughtered animals. In some cases, the neurons appeared condensed and dark indicating hypoxic injury. Neuronal degeneration and necrosis were common findings observed in various conditions such as salt poisoning, BSE, PEM, thiamine deficiency and bovine herpes virus type 5 infection (Truceman and Clague, 1978; Jeffery, 1992, Lonkar and Prasad, 1994, Shibahara *et al.*, 1999 and Perez *et al.* 2002). Abnormally large spaces were found in the white matter of the cerebrum and cerebellum in a few cases, which could be attributed to the necrosis and liquefaction process. The area adjacent to this was normal and free of cellular accumulations. In contrast to many extra neural tissues, areas of CNS necrosis and liquefaction do not heal by vascular proliferation and fibroplasia and so a cyst or cavity remains (Summers *et al.*, 1995). Degeneration and loss of Purkinje cells could be observed in a few cases. The cells were condensed, homogenous, angular and eosinophilic. Hager (1968) observed these types of changes in hypoxia and subacute ischemic cell damage. Neeraja *et al.* (1995) observed similar changes in the brain of calves with monocrotophos (nuvacron) toxicity.

Focal to diffuse neuronal degenerative and necrotic changes were seen in various segments of the brain in which the cell body appeared shrunken and the cytoplasm was highly eosinophilic with pyknotic nucleus. Similar changes were reported in bovine cranial zygomycosis, BSE, Aujeszky's disease and ischemic injury, Rabies, idiopathic brain stem neuronal degeneration and

thiamine deficiency (Hill *et al.*, 1992; Jeffery and Wilesmith, 1992; Summers *et al.*, 1995; Singh, 1995; Stewart, 1997 and Shibahara *et al.*, 1995). Satellitosis and neuronophagia were also observed in many cases. Summers *et al.* (1995) suggested it to be an inflammatory reaction to any type of injury to the neuron. Neuronophagic nodules were observed in PEM, rabies, nuvacron toxicity, Akabane virus infection and bovine herpes virus 5 infection (Lonkar and Prasad, 1994; Singh, 1995; Neeraja *et al.*, 1999; Lee *et al.*, 2002 and Perez *et al.* 2002).

Loss of neurons and dark neurons were found in the cerebral cortex in a few cases. The loss of neurons could be due to the aging process. Selkoe *et al.* (1987) and Lee *et al.* (2002) observed this in Akabane virus infection. Dark neurons, chiefly found in the pyramidal cell layer of the cerebral cortex could be due to ischemic change and immediate removal of perfused brain from the skull (Summers *et al.*, 1995). Also, Lonkar and Prasad (1994) reported dark neurons in PEM. The dark neurons found in the pyramidal layer of cerebral cortex in a sinus tumour case indicated hypoxic damage, as there was compression of the brain by the growth obliterating the capillaries. A few cases revealed binucleated neurons. An amitotic nuclear division during the process of cell division may produce such neurons where in the cytoplasmic cleavage causes the binucleations (Lumsden, 1968).

Perivascular cuffing within the brain was observed in a few cases that indicated inflammation. The cuffs contained gemistocytic astrocytes, plasma cells and mononuclears. In a few cases which were confirmed as rabies on the

basis of the finding of intracytoplasmic inclusions, no cuffing with infiltratory cells was observed. Cuffing of varying degree was observed in a variety of conditions like neosporosis, rift valley fever, *Clostridium chauvoei* infection, borna disease, PEM, rabies, Chlamydiosis, Akabane virus infection and bovine herpes virus type 5 infection (Dubey *et al.*, 1992; Rippey *et al.*, 1992; Singh *et al.*, 1992; Caplazi *et al.*, 1994; Lonkar and Prasad, 1994; Foley and Zachary, 1995; Piercy *et al.*, 1999; Lee *et al.*, 2002 and Perez *et al.*, 2002). Abnormally large number of glial cells and mononuclears were found to be present in the space around the meningeal vessels in some cases, which were attributed to the inflammation of the meninges. Liggitt and Demartini (1980) reported lymphocytic vasculitis as a pathognomonic lesion in malignant catarrhal fever. Multifocal meningitis in rift valley fever, meningo-encephalitis in neurovirulent bovine herpes virus type 1.3 infection and lymphocytic meningo-encephalitis in rabies were observed by Rippey *et al.*, 1992; Belknap *et al.*, 1994 and Foley and Zachary, 1995. A non-suppurative meningo-encephalitis in cattle was observed by Theil *et al.* (1998), which was also observed by Gardiner *et al.* (1989) and Piercy *et al.* (1999) in *Trypanosoma vivax* and *Chlamydia psittaci* infection respectively.

Gliosis was seen in many cases, which was more evident in the white matter region. It could be due to the inflammatory reaction to any injury of the brain. The etiology of these changes could not be classified as the study was confined to histopathological examination. Therefore, for better understanding it is essential to undertake cultural examination of the brain tissue. Gliosis was

observed in *Haemophilus somnus* infection, *Clostridium chauvoei* infection, neuro virulent bovine herpes virus type 1.3 infection, PEM, neosporosis, monocrotophos toxicity, *Chlamidia psittaci* infection in a 14 week old calf and Akabane virus infection in adult cows (Yamasaki *et al.*, 1991; Singh *et al.*, 1992; Belknap *et al.*, 1994; Lonkar and Prasad, 1994; Dannatt *et al.*, 1995; Neeraja *et al.*, 1999; Piercy *et al.*, 1999 and Lee *et al.*, 2002). Glial nodules were observed in a few cases. Similar findings were reported by McGee *et al.* (1992) and Singh (1995) in Eastern Equine Encephalomyelitis in adult cow and Rabies in cattle.

Abnormally large numbers of cellular accumulations were detected in the subependymal region. This may be an inflammatory response to the ventriculitis, as the ependymal surface offers much less resistance such that a ventriculitis will also involve the immediate subependymal zone of the brain (Summers *et al.*, 1995). But in this case ventriculitis was not observed.

Intracytoplasmic eosinophilic Negribodies were found in the Purkinje cells of the cerebellum. Burnes *et al.* (1997) reported vampire bat transmitted rabies in cattle and described non-suppurative encephalitis with intracytoplasmic inclusion bodies. However, in this case, no encephalitis was observed. A few cases revealed inclusions of varying sizes in the neuronal cytoplasm in the cerebral cortex, which were not found to be rabies inclusions on special staining with Maignani Magferrari method. They also appeared PAS negative proving that these inclusions were not developed in the process of aging and indicated that the animal had contracted the viral infection and

subsequently it might have recovered. Summers *et al.* (1995) found light acidophilic viral inclusions near by astroglia. Eosinophilic cytoplasmic inclusions were found in the degenerating neurons in the equine motor neuron disease (Cummings *et al.*, 1993). However in this case, the inclusions were found in all most all the glial cells and the neurons. Faintly eosinophilic and homogenous intracytoplasmic inclusions of shape varying from round to oval or crescentic were found in an encephalopathy with argyrophilic inclusions in a Holstein- Friesian cow (Nakamura *et al.*, 2000).

Demyelination is the destruction of a normally formed myelin sheath leaving the axon naked but otherwise unscathed. It was observed in a few cases and it was confirmed by special staining with luxol fast blue technique. Raine and Cross (1989) attributed this to multiple sclerosis and autoimmune encephalomyelitis. Summers *et al.* (1995) observed demyelination as characteristic lesion in hepatic encephalopathy, amino-acidopathy maple syrup urine disease, intoxication caused by rodenticide bromethalin and hexachlorophene and in globoid cell leukodystrophy in which condition a substrate accumulates which is toxic to the oligodendrocytes. The demyelination was found in chela leaf poisoning in calves, *Ficus ingens* var *ingens* and *Ficus chordata* sub.sp. *salicifolia* poisoning and Wilson's disease like lesion in a calf (Nair *et al.*, 1985; Myburgh *et al.*, 1994 and Wada *et al.* 1995). However, it was not possible to associate the demyelination in any of these conditions except in one which was found associated with Theileriosis.

Status spongiosis with multiple vacuolations were seen in the gray matter and white matter. One case revealed large single intra neuronal cytoplasmic vacuolation in the midbrain area. The vacuole had no stainable material inside and had a regular circumscribed appearance. It is also worth mentioning that vacuolation of neurons occur at all levels of the brain but it is pronounced in certain types of neurons or in certain well defined nuclear groups (Summers *et al.*, 1995). However, the area was not a particular nuclear region. Multiple intra neuronal cytoplasmic vacuolation in the midbrain region is suggestive of BSE. Pathak *et al.* (2001) described profuse vacuolation in both gray and the white matter and attributed it to BSE. Summers *et al.* (1995) described fine neuronal vacuolations in the ischemic neurons due to mitochondrial swelling and also suggested intra myelinic edema as a reason for spongiosis. Severe spongiform change in the thalamus and cortex was observed in rabies by Foley and Zachary (1995). Also, vacuolated neurons were observed in beta mannosidosis by O'Toole *et al.* (1993). A few cases revealed encephalomalacic changes which exhibited as vacuoles and spongy appearance in the white matter of the brain. Yamasaki *et al.* (1991) observed foci of malacia and perivascular microgliosis throughout the CNS in *Haemophilus somnus* infection. But, in this case there was no perivascular microgliosis. Focal area of malacia in Sarcocystis infection in a steer was described by Dubey *et al.* (1987) while Jeffery (1992) described focal symmetric encephalomalacia in BSE. Also, Sagar *et al.* (1990) described linear area of cavitation and cerebrocortical

necrosis in calves in PEM. Diffuse irregular vacuolations were observed in the brain parenchyma in a few cases. The neurons and the glial cells appeared much eosinophilic and surrounded by vacuoles. This may be attributed to the activation of lysosomal hydrolytic enzymes, which increase the cell permeability and thus make it appear swollen and acidophilic. (Hager, 1968). Granular cell degeneration was seen in the cerebellum. Netsky (1968) also suggested this as an autolytic change.

Gitter cells were observed in a few cases around the blood vessels in the brain parenchyma. These are large rotund cells with eccentric nucleus and a pale foamy cytoplasm without cell processes found within the perivascular space and the adventitia of the vessels. They are found in brain wounds, allergic encephalitis, cerebral wallerian degeneration and infarction of the brain ((Luse, 1968). This finding was in agreement with Truceman and Clague (1978) who observed these in sodium chloride poisoning in cattle. Gemistocytes could be observed in a few cases, around the blood vessels, amidst the inflammatory cells. The common astrogliotic response to CNS injury is manifested by the development of visible cytoplasm in the cell, which typically, takes the form of a broad, polygonal shape with the nucleus at the margin. Such large reactive astrocytes are deemed gemistocytes (Summers *et al.*, 1995), where cytoplasm is eosinophilic. Astrocytosis was seen in a few cases, which is an inflammatory response to any CNS injury. Clark *et al.* (1995) and Piercy *et al.* (1999) recorded astrocytosis in *Chlamydia psittaci* infection in a 14-week-old calf and encephalopathy caused by scrapie agent in cattle respectively.

A few cases revealed swollen axons, which appeared as round eosinophilic bodies occasionally in the neuropil in reaction to the injury to the neuron. Axonal spheroids were observed by O'Toole *et al.* (1993) in beta mannosidosis in calves, which could not be observed in the present study.

Brownish yellow granular pigmentation were observed in and around the walls of the meningeal blood vessels in a few cases. Cozzi *et al.* (1988) stated that neuromelanin, which closely resembled lipofuscin (Merighi and Peirone, 1985 and Bianchi and Merighi, 1986) accumulated as fine brownish granules in the cytoplasm of certain neurons. However, it was not the case in the present study.

In the present study it was proved that immersion fixation was equally good as perfusion fixation in routine examination of brain as the neurons and the other structures were found highly preserved and no artifactual changes could be observed in these cases.

The export of livestock and livestock products from India primarily depends on establishing a sound system for monitoring and diagnosis of all neurological disorders occurring in all species of animals and to differentiate it from BSE. A proper reporting of BSE will depend upon a systematic examination of the brain stem segments. Hence, this systematically conducted histopathological examination of the brain though extended to only a limited number of animals proved that the animals were free of BSE. Considerable efforts should be made to conduct examination of a large number of animals

from different localities and the results of histopathology should be correlated with other tests employed to detect BSE. Also, cases that were negative for rabies inclusion bodies in the direct impression smear revealed Negri bodies in the histological sections. Thus, this study proved that diagnosis of rabies by impression smear examination alone is not sufficient and needs examination by FAT or Immunoperoxidase techniques.

# *Summary*

---

## 6. SUMMARY

An investigation was carried out to study the prevalence and pathology of brain disorders in cattle. The prevalence of brain disorders for the past five years based on the analysis of the data collected from the autopsy records maintained at the Centre of Excellence in Pathology, Mannuthy was found to be 33 percent.

Fifty-two bovine brains collected from the carcasses brought for autopsy at the Centre of Excellence in Pathology, Mannuthy as well as from the cattle slaughtered at the Meat Technology unit, College of Veterinary and Animal sciences, Mannuthy and from Municipal Slaughterhouse, Thrissur were used for the study. The samples collected were subjected to detail gross as well as histopathological examination. Ten different areas from each brain were subjected to histopathological examination. The conditions encountered were clarified and pathological features were recorded and each lesion was explicated giving possible etiopathogenesis. The study revealed a high prevalence (72 per cent) of brain disorders in cattle. The major lesions encountered were vascular changes (70 per cent), neuronal degeneration and necrosis (38.46 per cent), purkinje cell changes (7.70 per cent), inflammatory changes (11.92 per cent), Negribodies (1.92 per cent) and other viral inclusions (5.77 per cent), spongiform changes (1.92 per cent), demyelination (3.85 per cent), gliosis (28.85 per cent), pigmentation (3.85 per cent) and Neoplasia (1.92 per cent). The lesions were not so evident grossly except for congestion and

haemorrhages in the slaughterhouse cases, which were due to stunning. It was seen that, not all animals reported to have shown nervous signs before death revealed histopathological lesions. At the same time, some of those having no nervous signs revealed considerable lesions in the brain. The reason may be that the changes might have occurred at the biochemical level and thus no lesion could be appreciated at the microscopic level.

Vascular changes included congestion, haemorrhage, edema, neovascularization, blood vessel thickening and cystic dilatation of capillaries. These changes were well appreciated all over the brain parenchyma. A few cases revealed neuronal degeneration, swollen neurons, satellitosis, neuronophagia and subsequently loss of neurons in the cerebrum. Also, a few cases showed **purkinje cell degeneration and subsequently their loss**. Neuronal necrosis though observed, was not so extensive to be manifested as liquifactive necrosis.

Inflammation of meninges as well as the brain parenchyma was well appreciated in 11.92 per cent of the cases. It was manifested as perivascular cuffing. Two cases revealed intra neuronal cytoplasmic inclusion bodies. One of this was confirmed as rabies and the other was attribute to be of viral origin.

Spongiform changes were observed in a few cases. It was manifested as potential spaces around the neurons in the gray matter and demyelination of nerve fibres in the white matter. Gliosis was a feature in almost all the cases.

One case revealed glial nodule in the pons region. It contained chiefly the microglial cells.

In a case of sinus tumour, a portion of the tumour was found invading the brain after lysing the ethmoid bone and pressing the brain. Thickening of meninges, calcification and infiltration of squamous cells into the brain tissue were the prominent histological features noted.

The other lesions encountered were dark neurons, binucleated neurons, subependymal microglial accumulations, astrocytosis, gemistocytes, Gitter cells and swollen axons. Also, cystic spaces and intra neuronal cytoplasmic vacuolation were a feature in few of the cases. A few cases revealed autolytic vacuoles, Mucocytes and melanin pigmentation.

The systematic investigation undertaken has helped to focus attention on the prevalence of various brain disorders in cattle. As believed, brain disorders in cattle were not less frequent. A high incidence of brain lesions could be recorded in autopsy cases and even in samples collected from slaughtered cattle, which were apparently healthy. Some of the conditions encountered in the study were of detrimental effect and result in the death of the animal. The findings suggest that many of the sudden death cases of unknown etiology in field conditions could probably be the result of underlying brain disorders. Lesions of BSE could not be observed in the present study. However, the sample size was very small. Thus, considerable efforts should be made to conduct examination of large number of animals from different localities and

the results of histopathology should be correlated with other tests to detect BSE. Also, cases that were negative for rabies inclusion bodies in the direct impression smear revealed negribodies in the histological sections. Thus, this study proved that diagnosis of rabies by impression smear examination alone is not sufficient and needs examination by FAT or Immunoperoxidase techniques. Therefore, it is imperative that earnest efforts should be made to delineate the disease problems associated with brain, so that a plan of action can be chalked out to prevent and control the brain disorders in cattle which had been a neglected field, has therefore, great relevance.

## *References*

---

## REFERENCES

- Abrens, F.A. 1993. Effect of lead on glucose metabolism, ion flux and collagen synthesis in cerebral capillaries of calves. *Am. Vet. Res.* **54**(5): 808-812
- Balasubramanian, S., Ashokan, S.A., Seshagiri, V.N and Pattabhiraman, S.R. 1997. Congenital internal hydrocephalus in a calf. *Indian. Vet. J.* **74**: 446-447
- Bancroft, J.D and Stevens, A. 1996. *Theory and practice of histological techniques*. Fourth edition. Churchill Livingstone. New York. p. 766
- Barr, B.C., Anderson, M.L., Blanchard, P.C., Daft, B.M., Kinde, H and Conrad, P.A.. 1990. Bovine fetal encephalitis and myocarditis associated with protozoal infections. *Vet. Pathol.* **27**: 354-361
- Belknap, E.b., Collins, J.K., Ayers, V.K and Schultheiss, P.C. 1994. Experimental infection of neonatal calves with neurovirulent bovine herpes virus Type 1.3. *Vet. Pathol.* **31**: 358-365
- \*Bianchi, M and Merighi, A. 1986. The relationship between lipofuscin and neuromelanin in some sites of the nervous system of the horse. *Exp Biol.* **46**: 89-99
- Boulton, J.G., Gill, P.A., Cook, R.W., Fraser, G.C., Harper, P.A.W and Dubey, J.P. 1995. Bovine neospora abortion in North eastern New South Wales. *Aust. Vet. J.* **72**(3): 119-120
- Burnes, J.M., Lopez, A., Medellin, J., Haines, D., Loza, E and Martinez, M. 1997. An outbreak of vampire bat transmitted rabies in cattle in northeastern Mexico. *Can. Vet. J.* **38**: 175-177
- Caplazi, P., Waldroget, A., Stitz, L., Braun, U. and Ehrensperger, F. 1994. Borna disease in naturally infected cattle. *J. Comp. Path.* **111**: 65-72

- Chen, S.S., Charlton, K.M., Balachandran, A.V., O'Connor, B.P and Jenson, C.C. 1996. Bovine Spongiform Encephalopathy identified in a cow imported to Canada from the United Kingdom- A case report. *Can. Vet. J.* **37**: 38-40
- Clark, W.W., Hourrigan, J.L and Heldow, W.J. 1995. Encephalopathy in cattle experimentally infected with the scrapie agent. *Am. J. Vet. Res.* **56**(5): 606-612
- \*Cozzi, B., Pellegrini, M and Droghi, A. 1988. Neuromelanin in the substantia nigra of adult horses. *Acta Anz.* **166**: 53-61
- \*Cummings, J.F., de Lahunta, A and Summers, B.A. 1993. Eosinophilic cytoplasmic inclusions in sporadic equine motor neuron disease: an electron microscopic study. *Acta Neuropathol(Berl)* **85**: 291-297
- Dannatt, L., Galy, F and Trees, A.J. 1995. Abortion due to neospora species in a dairy herd. *Vet. Rec* **137**: 566-567
- Dawson, M., Wells, G.A.H., Parker, B.N.J and Scott, A.C. 1990. Primary parental transmission of Bovine Spongiform Encephalopathy to the pig. *Vet. Rec.* **29**: 338
- Dubey, J.P., Perry, A and Kennedy, M.J. 1987. Encephalitis caused by a sarcocystis - like organism in a steer. *JAVMA* **191**(2): 231-232
- Dubey, J.P., Janovitz, E.B and Skowronek, A.J. 1992. Clinical neosporosis in a 4 week old hereford calf. *Vet Parasitol.* **43**: 137-141
- Duivenvoorden, J and Lusi, P. 1995. Neospora abortions in Eastern Ontario dairy herds. *Can. Vet. J.* **36**: 623
- Eroksuz, Y., Metin, N., Ozer, H., Yaman, I and Cervix, A. 1999. Psammomatous cerebral intra ventricular meningioma in a bull. *Aust Vet J.* **77**(6): 400

- Foley, G.L and Zachary, J.F. 1995. Rabies induced Spongiform change and encephalitis in a heifer. *Vet. Pathol.* **32**: 309-311
- Fondevila, D., Anor, S., Pumarola, M and Dubey, J.P. 1998. *Neospora caninum* identification in an aborted bovine fetus in Spain. *Vet. Parasitol.* **77**: 187-189
- Gardiner, P.A., Assoku, R.K.G., Whitelaw, D.D and Murray, M. 1989. Haemorrhagic lesions resulting from *Trypanosoma vivax* infection in Ayreshire cattle. *Vet. Parasitol.* **31**: 187-197
- Gill, P.A and Townsend, W.C. 1993. Hepatic vasculopathy and encephalopathy in Brahman type calves. *Aust. Vet. J.* **70**(2): 69
- Gupta, P.P and Singh, S.P. 1988. Sarcocystosis in the brain of a rabid cow. *Indian Vet. J.* **65**: 1130
- Hager, H. 1968. Electron microscopy of the nervous tissues. In *Pathology of the nervous system*. Vol I. (Ed. Minckler, J). McGraw-hill book company. Newyork. pp149-167
- Haldow, W.J and Hamilton, M.T. 1999. Reflections on the transmissible spongiform encephalopathies. *Vet. Pathol.* **36**: 523-529
- Hamlen, H., Clark, E and Janzen, E. 1993. Polioencephalomalacia in cattle consuming water with elevated sodium sulphate levels: a herd investigation. *Can. Vet. J.* **34**: 153-158
- Hattel, A.L., Casto, M.D., Gummo, J.D., Weinstock, D., Reed, J.A and Dubey, J.P. 1998. Neosporosis associated bovine abortion in Pennsylvania. *Vet. Parasitol.* **74**: 307-313
- Hatzios, B.C. 1973. Systemic aspergillosis in calves. *Bulletin of the Hellenic. Vet. Med. Society.* **24**(2): 75-86

- \*Haughey, K.G. 1975. Meningeal haemorrhage and congestion associated with the perinatal mortality of beef calves. *Aust. Vet. J.* **51**(1): 22-27
- Hill, B.D., Black, P.F., Kelly, M., Mur, D and Mc donald, W.A.J. 1992. Bovine cranial zygomycosis caused by *Saksenaea vasiformis*. *Aust. Vet. J.* **69**(7): 173-174
- Jeffery, M.1992. A neuropathological survey of brains submitted under the bovine spongiform encephalopathy orders in Scotland. *Vet. Rec.* **131**: 332-337
- Jeffery, M and Wilesmith, J.W. 1992. Idiopathic brain stem neuronal chromatolysis and hippocampal sclerosis: a novel encephalopathy in clinically suspect cases of bovine spongiform encephalopathy. *Vet. Rec.* **131**: 359-362
- Josephson, G.K.A and Little, J.P.B. 1990. Four bovine meningeal tumours. *Can. Vet. J.* **31**: 700-703
- Jubb, K.V.F and Huxtable, C.R. 1991. The nervous system in *Pathology of domestic animals* Vol.1 (Jubb,K.V.F., Kennedy,P.C and Palmer,N) 4th edition. Academic Press, INC , Newyork. pp 267-437
- \*Kitching, J.P., Bishop, G.C and Mapham, P.H. 1985. Thrombo embolic meningoencephalitis diagnosed in Natal. *J SA Vet Assoc.* **50**(2): 97-98
- Kwiecien, J.M., Staenmpfli, H.R., Lack, B., Mok, T and Runstedler, M. 1995. Congenital axonopathy in a brownswiss calf. *Vet. Pathol.* **32**: 72-75
- Lee, J.K., Park, J.S., Choi, J.H., Park, B.K., Lee, B.C., Hwang, W.S., Kim, J.H., Jean, Y.H., Haritani, M., Yoo, H.S and Kim, D.Y. 2002. Encephalomyelitis associated with akabane virus infection in adult cows. *Vet. Pathol.* **39**: 269-273

- \*Liggitt, H.D and Demartini, J.C. 1980. The patho morphology of Malignant catarrhal fever:I, generalised lymphoid vasculitis. *Vet Pathol.* **17**: 58-72
- Lonkar, P.S and Prasad, M.C. 1994. Pathology of amprolium induced CNN in goats. *Small Rum Res.* **13**(1): 85-92
- Lumsden, C.E. 1968. Tissue culture in neuropathology. In *Pathology of the Nervous system* vol I. (Ed. Minckler, J). McGraw Hill book company. Newyork pp 240-263
- Luna, L.G. 1968. *Mannual of histologic staining methods of the Armed forces institute of pathology.* McGraw-Hill book. Co., Newyork. 3rd edn. P 251
- Luse, S. 1968. Microglia. In *Pathology of the nervous system.* Vol I. (Ed. Minckler,J). McGraw-hill book company. Newyork. pp 531-538
- Madarame, H., Azuma, K., Nozuki, H., Numata, K and Konno, S. 1990. Dandy-walker malformation in a japanese black calf. *Vet. Pathol.* **27**: 296-298
- McGee, E.D., Littleton, C.H., Mapp, J.B and Brown, K.J. 1992. Eastern equine encephalomyelitis in an adult cow. *Vet. Pathol.* **29**: 361-363
- McGill, I.S and Wells, G.A.H. 1993. Neuropathological findings in cattle with clinically suspected but histologically unconfirmed Bovine Spongiform Encephalopathy (BSE). *J. Comp. Pathol.* **108**: 241-260
- \*Merighi, A and Peirone, S.M. 1985. Histochemical and ultrastructural features of neuronal pigment in some encephalic nuclei of ruminants. *Exp Biol.* **44**: 109-121

- Myburgh, J.G., Fourie, N., Vander, L.J.J., Kellerman, T.S., Cornelius, S.T., Ward, C and Lugt, V.T.S. 1994. A nervous disorder in cattle caused by the plants *Ficus ingens* var *ingens* and *Ficus cordata* subsp. *salicifolia*. *Ondersteport J. vet. Res.* **61**(2): 171-176
- Nair, N.D., Valsala, K.V., Ramachandran, K.M and Rajan, A. 1985. Experimental studies on chela leaf (*Ficus tsiela* Roxb) poisoning in calves. *Kerala J. Vet. Sci.* **16**(2): 94-99
- Nakamura, N., Yamaguthi, H., Furuoka, H and Matsui, T. 2000. An Encephalopathy with Agyrophilic inclusions in a Holstein-Friesian cow. *Vet. Pathol.* **37**: 462-464
- Neeraja, N., Gopalnaidu, N.R and Sriraman, P.K. 1999. Pathological changes in nervous system in Monocrotophos (Nuvacron) toxicity in calves. *Indian J. Vet. Path.* **23**: 68-69
- Netsky, M.G. 1968. Degenerations of the cerebellum and its pathways. In *Pathology of the nervous system*. Vol I. (Ed. Minckler, J). McGraw-hill book company. Newyork. pp 1163-1185
- Noda, Y., Uchinuno, Y., Shirakawa, H., Nagasue, S., Nagano, N., Ohe, R and Narita, M. 1998. Aino virus antigen in brain lesions of a naturally aborted bovine foetus. *Vet. Pathol.* **35**: 409-411
- Noda, Y., Yokoyama, H., Katsuki, T., Kurashige, S., Uchinuno, Y and Nirata, M. 2001. Demonstration of Akabane virus antigen usng immunohistochemistry in naturally infected Newborn calves. *Vet. Pathol.* **38**: 216-218
- Obendorf, D.L., Murray, N., Veldhuis, G., Munday, B.L and Dubey, J.P. 1995. Abortion caused by Neosporosis in cattle. *Aust. Vet. J.* **72**(3): 117-118

- Ogino, H., Watknabe, E., Watanabe, S., Agawah, H., Narita, M., Haritani, M and Kawashima, K. 1992. Neosporosis in the aborted foetus and new born calf. *J. Comp. Path.* **107**: 231-237
- O'Toole, D., Welch, V., Redland, K and Wiliams, E.S. 1993. Ubiquitinated inclusions in brains from salers calves with beta-mannosidosis. *Vet. Pathol.* **30**:381-385
- Pandey, G.S., Tuchili, L.M and Mimba, D.C. 1996. *Salmonella typhimurium* meningo encephalitis in a calf. *Indian. Vet. J* **73**: 1207-1210
- Pathak, A.K., Joshi, N and Joshi, R.K. 2001. Bovine spongiform encephalopathy. *Intas.Polivet.* **2**(1): 1-8
- Perez, S.E., Bretschneider, G., Leunda, M.R., Osorio, F.A., Flores, E.F and Odeon,A.C.2002. Primary infection, latency and reactivation of bovine nervous system. *Vet.Pathol.* **39**: 437- 444
- Piercy, D.W.T., Griffiths, P.C and Teale, C.J. 1999. Encephalitis related to *Chlamydia psittaci* infection in a 14-week-old calf. *Vet.Rec.***144**: 126-128
- Power, E.P., Conor, M.O., Donnelly, W.J.C. and Dolan, C.E. 1990. Aujeszky's disease in a cow. *Vet. Rec.* **126**:13-15
- Race, R.E. 2000. The trouble with transmissible degenerating encephalopathy agents. *Vet. J.* **159**:3-4
- \*Raine, C.S and Cross, A.H. 1989. Axonal dystrophy as a consequence of long term demyelination. *Lab. Invest.* **60**: 714-725
- Rippy, M.K., Topper, M.J., Mebus, C.A and Marrill, J.C. 1992. Rift valley fever virus- induced encephalomyelitis and hepatitis in calves. *Vet. Pathol.* **29**: 495-502


- Robinson, M.M., Hadlow, W.J., Knowles, D.P., Huff, T.P., Lacy, P.A., Marsh, R.F and Gorham, J.R. 1995. Experimental infection of cattle with the agents of transmissible mink encephalopathy and scrapie. *J. Comp. Path.* **113**: 241-251
- Sagar, R.L., Hamar, D.W and Gould, D.H. 1990. Clinical and biochemical alterations in calves with nutritionally induced polioencephalomalacia. *Am. J. Vet. Res.* **51**(12): 1969-1974
- Sarode, D.B., Paikne, D.L and Sapre, V.A. 1991. Clinico-biochemical and pathological aspects of experimental hypomagnesaemia in cross bred calves. *Indian. J. Vet. Med.* **11**(1,2): 12-15
- Schulman, S. 1968. Wilson's disease. In *Pathology of the nervous system*. Vol I. (Ed. Minckler, J). McGraw-hill book company. Newyork. pp 1139-1152
- Seimiya, Y., Ohshima, K., Itoh, H., Ogosawara, N., Okutomo, M and Tanaka, S. 1997. Clinicopathology of meningo ventriculitis due to *Streptococcus bovis* infection in neonatal calves. *J. Vet. Med. Sci.* **54**(5): 871-874
- \*Selkoe, D.J., Bell, D.S and Podlisny, M.B. 1987. Conservation of brain amyloid proteins in aged mammals and humans with Alzheimer's disease. *Science.* **235**: 873-877
- Sheehan, D.C and Hrapchack, B.B. 1980. *Theory and practice of histotechnology*. Mosby company Ltd. London. 2nd edition. p.481
- Shibahara, T., Harino, R., Taniguchi, T and Ando, Y. 1999. Auto-fluorescent substance and neurocyte necrosis in thiamine deficiency in cattle. *Aust. Vet. J.* **77**(5): 329-330
- Singh, C.K. 1995. Experimental studies on rabies in buffalo calves. Ph.D thesis, Punjab Agricultural University, Ludhiana, p.150

- Singh, K.P., Parihar, N.S and Tripathi, B.N. 1992. Brain lesions in experimental *Clostridium chauvoei* infection in hill bulls. *Indian. J. Vet. Pathol.* **16**(2): 79-82
- Singh, K.P and Parihar, N.S. 1996. Spontaneous Sarcocystosis in brain of hill bullocks. *Indian J. Vet. Pathol.* **20**(2): 153-154
- Singh, R.K., Sharma, S.N., Rao, R and Vashishtha, M.S. 2000. Clinical and haemato-biochemical studies in experimental polioencephalomalacia in calves. *Indian. Vet. J.* **77**: 216-218
- Smyth, J.A., Mc Namce, P.T., Kennedy, D.G., McCullough, S.J., Logan, E.F and Ellis, W.A. 1992. Still birth/ Perinatal weak calf syndrome : Preliminary pathological, microbiological and biochemical findings. *Vet. Rec.* **130**: 237-240
- Sorden, S.D and Radostits, O.M. 1996. Lingual arteritis, multifocal meningoencephalitis and uveitis induced by barley spikelet clusters in a two year old heifer. *Can. Vet. J.* **37**: 227-229
- Stewart, W.B. 1997. Idiopathic brain stem neuronal chromatolysis in cattle : two case studies. *Vet. Rec.* **140**: 260-261
- Storts, R.W. 1992. Central nervous system. *Thomson's special Veterinary pathology* (Eds. Carlton, W.N and McGavin, M.D). Mosby Newyork. pp 332-387
- Summers, B.A., Cummings, J.F., deLahunta, A. 1995. *Veterinary Neuropathology*. Mosby. Philadelphia. P.527
- Tanwar, R.K. 1997. Some observations on brain abscess in buffaloes. *Indian. Vet. J.* **74**: 703-704
- Taylor, D.M. 2000. Inactivation of transmissible degenerative encephalopathy agents: A review. *Vet. J.* **159**: 10-17

- Theil, D., Fatzer, R., Caplazi, T., Zurbriggen, A and Vandeveld, S. 1998. Neuropathological and etiological studies of sporadic non-suppurative meningo encephalomyelitis of cattle. *Vet. Rec.* **143**: 244-249
- \*Thompson, K.G., Vickers, M.C., Stevenson, B.J and Davidson, G.W. 1987. Thrombo embolic meningoencephalitis caused by *Haemophilus somnus* infection in a bull calf- a new disease in Newzealand. *NZ.Vet. J.* **35**: 1-2
- Truceman, K.F and Clague, D.C. 1978. Sodium chloride poisoning in cattle. *Aust. Vet. J.* **54**(2): 89-91
- Tuntasuvan, D., Sarataphan, N and Nishikawa, H. 1997. Central Trypanosomiasis in native cattle. *Vet. Parasitol.* **73**: 357-363
- \*Verdura, T and Zamora, I. 1970. Cerebrocortical necrosis in cuba in cattle fed with high levels of molasses. *Revista cubane de ciencias Agricolas.* **4**: 209-212
- Waage, S. 1992. Milk fever complications in cows. *Meieriposten.* **81**(14): 404-406
- Wada, Y., Kajiwar, W and Kato, K. 1995. Wilson's disease like lesion in a calf. *Vet. Pathol.* **32**: 538-539
- Weinstock, D., Horton, S.B and Rowland, P.H. 1995. Rapid diagnosis of *Listeria monocytogenes* by immuno-histochemisty in formalin fixed brain tissue. *Vet. Pathol.* **32**(2): 193-195
- \*Wellde, B.T., Reardon, M.J., Kovatch, R.M., Chumo, D.A., Williams, J.S., Boyle, W.L., Hockmeyer, W.T and Wykoff, D.E. 1989. Experimental infection of cattle with *Trypanosoma brucei rhodesiense*. *Annals. Trop. Med. Parasitol.* **83**(1): 209-220

- Wells, G.A.H., Scott, A.C., Wilesmith, J.W and Simmons, M.M. 1994. Correlation between the results of histopathological examination and the detection of abnormal brain fibrils in the diagnosis of bovine spongiform encephalopathy. *Res.Vet. Sci.* **56**: 346-351
- Yamada, M., Nakagawa, M., Yamamoto, M., Furuoka, H., Matsui, T and Taniyama, H. 1998. Histopathological and immunohistochemical studies of intracranial nervous system tumours in four cattle. **119**: 75-82
- Yamasaki, H., Umemura, T., Goryo, M and Itakura, C. 1991. Chronic lesions of thrombo-embolic meningo encephalomyelitis in calves. *J. Comp. Path.* **105**: 303-312
- Yanai, T., Masegi, T., Kawada, M., Ishikawa, K., Eukuda, K., Yamazoe, K., Iwassaki, T., Ueda, K and Goto, N. 1994. Spontaneous vascular mineralization in the brains of cows. *J. Comp. Path.* **111**: 213-219

\* Originals not consulted



# **PREVALENCE AND PATHOLOGY OF BRAIN DISORDERS IN CATTLE**

**By  
BALASUBRAMANIAN. M.**

## **ABSTRACT OF THE THESIS**

**Submitted in partial fulfilment of the  
requirement for the degree of**

## **Master of Veterinary Science**

**Faculty of Veterinary and Animal Sciences  
Kerala Agricultural University**

**Centre of Excellence in Pathology  
COLLEGE OF VETERINARY AND ANIMAL SCIENCES  
MANNUTHY, THRISSUR - 680651  
KERALA, INDIA  
2003**

## ABSTRACT

The present study was undertaken to assess the prevalence and pathology of various brain disorders in cattle. The data collected from the autopsy records maintained at the Centre of Excellence in Pathology, Mannuthy and fifty-two samples of brain obtained from both the slaughtered cattle and autopsy cases formed the basis of the study. Gross lesions were not so evident except for the meningeal congestion, which accounted to 70 per cent of the cases. Congestion and haemorrhages were found consistently in the slaughtered cattle, which could be attributed to stunning effect. The other major lesions were well appreciated by detailed histopathological examination of ten different areas of the brain in each of the cases. These included vascular changes, neuronal degeneration, inflammatory changes, gliosis, pigmentation and neoplasia. Two cases revealed intra neuronal cytoplasmic inclusions of which one was due to rabies and the other was attributed to viral etiology. Bovine spongiform encephalopathy was not found to be present in any of the cases in the present study. Based on the observations made here, it was suggested that diagnosis of rabies by impression smear examination alone is not sufficient and needs examination by FAT or Immunoperoxidase techniques. The incidence of pathological disorders encountered was relatively high. Thus, the need and scope for investigation into the pathological disorders of bovine brain were highlighted.