



Comparative Macroscopic Anatomy of Oropharyngeal Cavity of Turkey (*Meleagris gallopavo*), Chicken (*Gallus gallus domesticus*) and Japanese quail (*Coturnix coturnix japonica*)

S. Rajathi

Assistant Professor, Department of Veterinary Anatomy, VCRI, Tirunelveli, Tamil Nadu Veterinary and Animal Sciences University, Tamil Nadu, INDIA

*Corresponding Author: rajathis9936@gmail.com

How to cite this paper:

Shunmugam, R. (2020). Comparative Macroscopic Anatomy of Oropharyngeal Cavity of Turkey, Chicken and Japanese quail. *International Journal of Livestock Research*, 10(12), 116-122. doi: <http://dx.doi.org/10.5455/ijlr.20200922111035>

Received : Sep 22, 2020
Accepted : Nov 04, 2020
Published : Dec 31, 2020

Copyright © Rajathi, 2020

This work is licensed under the Creative Commons Attribution International License (CC BY 4.0). <http://creativecommons.org/licenses/by/4.0/>



Abstract

The present study was carried out on three different birds. The mouth and pharynx of all three birds lack a definite line of demarcation. However, in chicken, the mouth and pharyngeal cavity was well demarcated with dark red colour bands which was absent in Turkey and Japanese quail. The beak had broad base with pointed tip and slightly curved appearance in Turkey and strongly curved in Chicken and Japanese quail. Beaks of all three birds were covered with horny sheath. The roof of the oropharyngeal cavity was formed by the hard palate which was elongated, cream-coloured with some black patches in all the birds. The roof of the oropharyngeal cavity was more concave in Chicken than Turkey and less concave in Japanese quail. In Turkey, the median ridge was a continuous smooth line in cranial part but discontinuous line in the caudal part with 3-5 papillae was observed. However, in chicken, a single continuous part without any papilla was identified. In Japanese quail it consisted of only continuous cranial part. The two lateral longitudinal palatine ridges were observed. Choanal slit was consisted of a narrow cranial part and a broad caudal part. The infundibular slit was a continuous slit from the choanal slit to laryngeal inlet. The tongue was observed triangular shape in all these three birds. The filiform papilla was found caudal to the root of the tongue in all the birds. These mucous swelling were separated by a median ridge.

Keywords: Chicken, Oropharyngeal Cavity, Turkey and Japanese quail

Introduction

Anatomical understanding of oropharyngeal cavity of birds is essential to analyse the morphological structures that may influence nutrition, food intake and ingestion, and also forms the basis for clinical pathology and pharmacology. Previous research was done on the macroscopic study of oropharynx in different species of birds (Igwebuike and Anagor, 2013; Erdogan and Alan, 2012; Tivane *et al.*, 2011; Crole and Soley, 2008; Jackowiak and Godynicki, 2005, Saran *et al.*, 2019). Scanty literature is available on the comparative study of the oro-pharyngeal cavity in Turkey, Chicken and Japanese quail. The present study is to investigate the comparative morphology of the oropharyngeal cavity of Turkey, Chicken and Japanese quail.

Materials and Methods

The six each adult Turkey, Chicken and Japanese quail heads of both the sexes were used for this study and were procured from local retail shops in and around Tirunelveli, Tamil Nadu. The head region of all the birds were dissected and studied in terms of their size, shape, physical appearance and topographical relationships.

Results and Discussion

The mouth and pharynx of turkey, chicken and Japanese quail lack a definite line of demarcation and so it constituted a common oropharyngeal cavity. However, McLelland (1993) stated that the boundary between the mouth and pharynx in the duck was at the level of the caudal lingual papillae based on embryological study. In chickens, the mouth and pharyngeal cavity was well demarcated but not seen in Turkey and Japanese quail (Fig. 1).

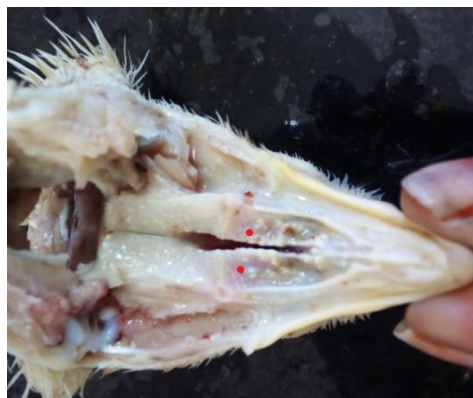

Figure 1: Photograph showing the upper jaw of chicken showing the light red colour area (Red spot) at the mouth and the pharyngeal cavity demarcation

In contrast to this, broad and shovel shaped beak in duck, pointed beak in pigeon (Nickel *et al.*, 1977). The bony part of upper beak was formed by premaxilla and that of lower beak is cranial part of mandible. Both parts beaks were covered by horny sheaths. But in ducks, the horny sheath of the upperbeak extended beyond the borders of the lower beak. In all the birds, the lower beak was covered by upper beak when the mouth was closed (Fig. 2). The shape of the beak varied in different birds viz. broad base and pointed tip with slightly curved in turkey and strongly curved in chicken (Fig. 2) and Japanese quail. The roof of the oropharyngeal cavity was formed by the hard palate, which was elongated with cream-coloured however, showed some black patches in all the birds (Fig. 3). In the present study, soft palate was absent. Similar finding was found in all birds according to McLelland (1993). The roof of the oropharyngeal cavity was more concave in chicken than turkey and less concave in Japanese quail. Similar observation was found in chicken and pigeon (Mohamedand Zayed, 2003) but in goose the cavity is concave transversely. A median palatine ridge which was a median longitudinal fold of mucous membrane and was found in the cranial two-third part of the hard palate. In turkey, the median ridge was continuous line in cranial part but discontinuous line in the caudal part with 3-5 papillae (Fig. 4).

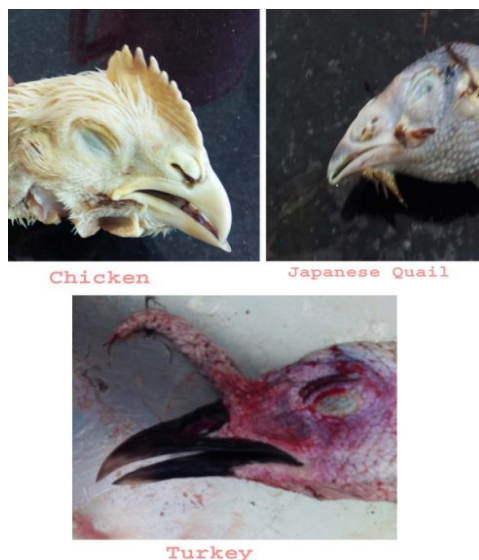

Figure 2: Photograph showing the shape of beak in chicken, Japanese quail and Turkey

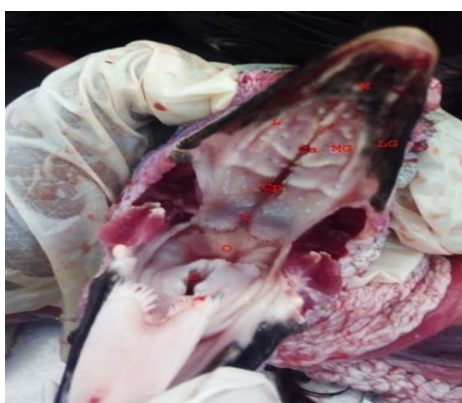

Figure 3: Photograph showing the roof of the oropharyngeal cavity of Turkey. M – Median palatine ridge, L – Lateral palatine ridge, LG – Lateral groove, MG – Median groove, Ca – anterior part of choanal slit, CP – Posterior part of choanal slit, I – Infundibular slit, O – Oesophagus and G – Glottis.

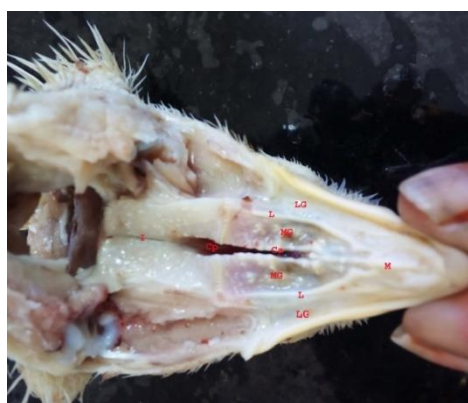

Figure 4: Photograph showing the roof of the oropharyngeal cavity of chicken. M – Median palatine ridge, L – Lateral palatine ridge, LG – Lateral groove, MG – Median groove, Ca – anterior part of choanal slit, CP – Posterior part of choanal slit and I – Infundibular slit.

In chicken it was a single continuous part without papilla (Fig. 4). In Japanese quail median ridge was consisted of only continuous cranial part and absence of caudal part (Fig. 5). Similar finding as turkey was found in ostrich (Tivane *et al.*, 2011). But dub shaped median ridge was found in pigeon (Igwebuike *et al.*, 2014). The present study showed that the length of the median palatine ridge was 3.5 cm, 1.1 cm and 0.3 cm behind the tip of the upper beak to the rostral end of the choanal slit in turkey, chicken and Japanese quail, respectively (Table 1). Similar results were observed in pigeon (Mohamed and Zayed, 2003) and ostrich (Tivane *et al.*, 2011). This median palatine ridge divided the anterior part into right and left sides. Similar observations were found in Muscovy duck (Igwebuike and Anagor, 2013) and Ostrich (Tivane *et al.*, 2011). In case of ducks, lateral borders of the hard palate had lamellae which was absent in the present study.

Table 1: Morphometric parameters of mouth anatomy of Turkey, chicken and Japanese quail in cm

S. No.	Parameters	Turkey	Chicken	Japanese quail
1	Upper beak length	5.7	3.7	2.2
2	Lower beak length	5.2	3.1	1.9
3	Medial palatine ridge length	3.5	1.1	0.3
4	Cranial part of median palatine ridge	2.2	0.9	0
5	Caudal part of median palatine ridge	1.3	1.2	0.3
6	Lateral Palatine ridge	3.9	2.2	1.6
7	Choanal slit	3.5	2.8	0.8
8	Cranial part of median palatine ridge	2.1	1.7	0.5
9	Caudal part of median palatine ridge	1.4	0.9	0.3
10	Infundibular slit	0.6	0.4	0.2
11	Median mandibular groove	2.5	0.8	0.4
12	Tongue length	3.3	2.5	1.2
13	Base width	1	0.9	0.5
14	Tip width	0.1	0.1	0.1

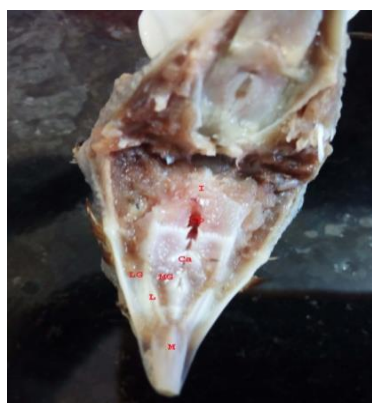

Figure 5: Photograph showing the roof of the oropharyngeal cavity of Japanese quail. M – Median palatine ridge, L – Lateral palatine ridge, LG – Lateral groove, MG – Median groove, Ca – anterior part of choanal slit, CP – Posterior part of choanal slit and I – Infundibular slit.

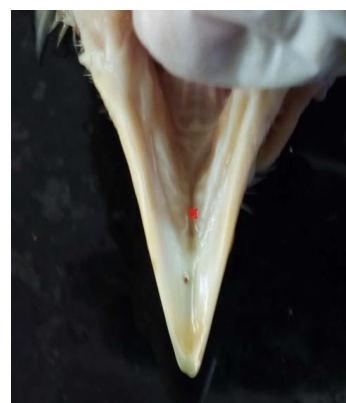

Figure 6: Photograph showing the floor of the oropharyngeal cavity of chicken showing median groove (M)

Extending from the medial palatine ridge were the two lateral longitudinal palatine ridges directed caudally on either side of the choanal slit. They began at the caudal tip of median palatine ridge in Japanese quail. But in Turkey and Chicken, they began at the middle of the median palatine ridge. The caudal part of median palatine ridge was 1.3 cm and 1.2 cm in turkey and chicken, respectively (Table 1). The caudal tip of lateral palatine ridge extended to the level of last row of transverse papilla. The lateral palatine groove was found between the beak border and the median and lateral palatine ridge (Fig. 6). The groove was deeper throughout the palate in chicken and Japanese quail but found to be deeper in the cranial part and shallow in the caudal part in turkey (Fig. 3, 4 & 5). The groove was of same width throughout the palate in chicken and Japanese quail and was broader in cranial part and narrow caudal part in turkey. Median and lateral grooves on either side of lateral ridge in chicken and pigeon as stated by (Mohamed and Zayed, 2003) were not found in the present study. Median palatine groove was found between the lateral ridges on either side and was concave in chicken than turkey and Japanese quail that extended to the level of the choanal slit (Fig. 3, 4 & 5). The median palatine groove would hold the seeds during husking process. The lateral palatine groove would contain the lower beak when the mouth was closed and also helped in holding the seed (McLelland, 1993).

Caudal one-third part of the hard palate consisted of an elongated oval depression called choanal slit. Choanal slit was consisted of a narrow cranial part and abroad caudal part (Fig. 4). The demarcation was indicted by the presence of three transverse ridges in turkey but no ridges in chicken (Fig. 3 & 4). In ducks, there were only two ridges which demarcated between the cranial and caudal part of choanal slit (Igwebuike and Anagor, 2013). In Japanese quail, the demarcation was not seen and three transverse ridges found. Inside the choanal slit, there was a median ridge which was separated the lumen into left and right parts and corresponded to left and right nasal cavities. Similar results were noted in duck (Igwebuike and Anagor, 2013) and ostrich (Tivane *et al.*, 2011) but in African pied crow showed no demarcation of two nasal cavities (Igwebuike and Anagor, 2013). On the edges of the choanal slit, caudally directed transverse row of papillae were found which were 4-6 in number in turkey, 4-5 numbers in chicken and 3-4 in Japanese quail (Fig 3, 4& 5). Small papilla was distributed in the roof of the oropharyngeal cavity and longer papilla was concentrated towards the borders. Similar papilla was found in all domestic birds (McLelland, 1993). But in duck hard palate lacks papilla and was found only at the edges of the choanal slit (Igwebuike and Anagor, 2013). The caudally directed papillae was absent in ostrich (Tivane *et al.*, 2011) and in pigeon (Igwebuike *et al.*, 2014). The papillae would assist in swallowing in one direction toward the oesophagus as soft palate was absent (McLelland, 1993).

The infundibular slit was appeared as a continuous one extending from the choanal slit cranially and laryngeal inlet opening caudally. It was found as a median longitudinal fissure in the centre of the roof of the oropharyngeal areas and had the common opening of the two eustachion tubes. The length of the infundibular slit was observed as 0.6 cm, 0.4 cm and 0.2 cm in Turkey, Chicken and Japanese quail, respectively (Table 1). A few small papilla was found on the rim of the infundibular slit. The slit was found to be wider than the choanal slit and the cranial and caudal commissures were broader when compared to the choanal slit in turkey and Japanese quail (Fig. 3&4). But in Chicken, it was found to be narrower and both cranial and caudal commissures were at acute angle than the choanal slit (Fig. 4). The floor of the oropharyngeal cavity in the present study had a concave surface between the rami of the mandible and enclosed the lower beak. The lateral border of the floor was smooth in all the birds studied but in case of duck which had orderly arranged rows of lamellae (Igwebuike and Anagor, 2013). In chicken and Japanese quail, 4-5 ridges were found similar to the shape of turkey with shallow median groove (Fig. 6). In Turkey, 6 non-overlapping ridges were found on either side of the deep median groove along the direction of the floor of the beak (Fig. 9).

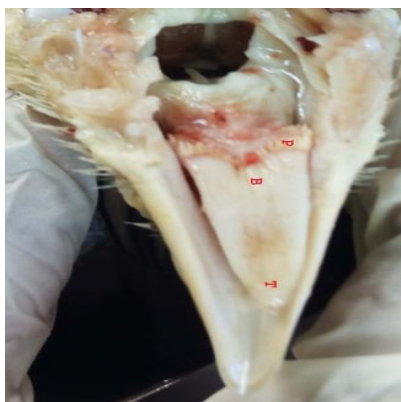


Figure 7: Photograph showing the tongue of chicken. P – Root, B – Base and T – Tip of the tongue

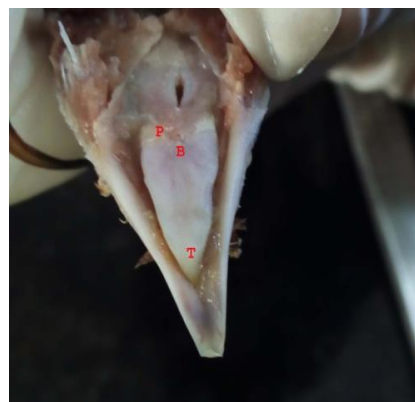

Figure 8: Photograph showing the tongue of Japanese quail. P – Root, B – Base and T – Tip of the tongue

The tongue of the Chicken, Japanese quail and Turkey were triangular shaped with different breadth and width (Fig. 7,8 & 9). It had root, body and tip. The tip of the tongue was found in the cranial part of the floor of the oropharyngeal cavity. In the present study, it was found within the floor of the oral cavity whereas in ducks, it extended to the full length of the floor of the oral cavity (Igwebuike and Anagor, 2013). The tip of tongue was pointed in all the birds studied but in contrary to this it was smooth, broad and shovel-shaped in ducks (Igwebuike and Anagor, 2013). The tongue body had a slight elevation which corresponded to the torus linguae in mammal but in ducks it was bell shaped and it had a prominent median sulcus on the dorsal surface of the organ and was absent in all the birds studied. Numerous long brush-like horny lingual papillae were situated at the lateral margins of the rostral half of the tongue body in duck (Igwebuike and Anagor, 2013). Caudal to the elevation, tongue possessed a row of caudally-pointed broad papillae, which was marked the caudal boundary of the tongue. In ducks, small lingual papillae at the cranial border of the bell-shaped elevation (Igwebuike and Anagor, 2013) were not found in the present work.

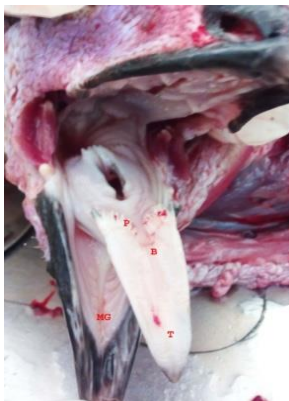


Figure 9: Photograph showing the tongue of Turkey. P – Root, B – Base, T – Tip of the tongue and MG – Median groove.

Filiform-like papilla was found on the two lateral mucous swellings caudal to the root of the tongue. These mucous swelling were separated by a median ridge. This medial ridge extended from the root of the tongue to the laryngeal mound. The median ridge separated into two ridges cranial to the laryngeal mound and formed two caudal processes located on the cranio-lateral margin of the laryngeal mound. Cranial part of laryngeal mound had a large round opening called glottis. Mucous membrane of laryngeal mound and caudal process of median ridge had caudally directed papilla.

Conclusion

It was clear from the present study that the mouth cavity of the turkey, chicken and Japanese quail showed similar morphological pattern of birds but differed from other birds and among the three species without any sex difference. The present study will form the basis for the determining the feed size for the above three species of commercial birds of south Tamil Nadu region.

Acknowledgement

The author is thankful to the Tamil Nadu Veterinary and Animal Sciences University, Chennai-51 and All India Coordinated Research Project on Post Harvest Engineering Technology, ICAR, New Delhi, for provision of funds and facilities required towards the successful conduct of Ph.D., research work.

Conflict of Interests

There is no conflict of interest.

Publisher Disclaimer

IJLR remains neutral concerning jurisdictional claims in published institutional affiliation.

References

1. Crole, M. R. and Soley, J. T. (2008). Histological structure of the tongue of the emu (*Dromaius novaehollandiae*). *Proceedings of the Microscopy Society of Southern Africa*. 38, 63.
2. Erdogan, S. and Alan, A. (2012). Gross anatomical and scanning electron microscopic studies of the oropharyngeal cavity in the European magpie (*Pica pica*) and the common raven (*Corvus corax*). *Microscopic Research Technology*. 75(3), 379-389.
3. Igwebuiké, U. M. and Anagor, T. A. (2013). The morphology of the oropharynx and tongue of the Muscovy duck (*Cairina moschata*) *Veterinarski Arhiv* 83 (6), 685-693.
4. Igwebuiké, U. M., Ugwuoke, W. I. and Udoumoh, A. F., (2014). Morphological features of the dorsal and ventral walls of the oropharynx in the common pigeon (*Columba livia*). *Animal Research International*. 11(2), 1970-1975.
5. Jackowiak, H. and Godynicki, S. (2005). Light and scanning electron microscopic study of the tongue in the

- white-tailed eagle (*Haliaeetus albicilla*, Accipitridae, Aves). *Annals of Anatomy*.187(3), 251-259.
6. McLelland, J. (1993). Digestive Apparatus. In: Handbook of Avian Anatomy: Nomina Anatomica Avium, Nuttall Ornithological Club, Cambridge, 301-328.
 7. Mohamed, S.A. and Zayed, A.E., (2003). Gross anatomical and scanning electron microscopical studies on palate of some birds. *Assiut Veterinary Medicine Journal*, 49,1-17.
 8. Nickel, R., Schummer, A., and Seiferle, E. (1977). Anatomy of the Domestic Birds. Vol. 5. Verlag Paul Parey, Berlin. pp. 40-50.
 9. Saran, D., Meshram, B., Joshi H., Singh G., and Kumar S. (2019). Gross Morphological Studies on the Digestive System of Guinea Fowl (*Numida meleagris*). *International Journal of Livestock Research*,9(2), 266-273.
 10. Tivane, C., Rodrigues, M. N., Soley, J. T and Groenewald H. B. (2011). Gross anatomical features of the oropharyngeal cavity of the ostrich (*Struthio camelus*). *Presq. Veterinary Brasilica*. 31, 543-550.
