

Sonographic Evaluation of Urinary Tract in Normal Domestic Short Haired Cats

V.Vijayanand¹, D.Sumathi and M.Balagangatharathilagar

Veterinary University Peripheral Hospital, Directorate of Clinics, Madhavaram Milk Colony, TANUVAS, Chennai - 600 051, Tamil Nadu.

(Received : August, 2018 296/18 Accepted : August, 2018)

Abstract

Ultrasonography of the urinary tract is a routine clinical investigation procedure which provides important information regarding the size, shape and internal architecture of the kidney, urinary bladder and its associated structures. The ultrasonographic examination technique of upper (Kidneys, ureters) and lower urinary tract (bladder, urethra) and the shape, ultrasonographic architecture and dimension of upper and lower urinary tract structures in domestic short haired cats is reported.

Key words : Ultrasonography, Urinary tract, cats

Ultrasonography of the urinary tract in cats is a routine clinical investigation procedure

¹Corresponding author : Email : drvjanand@gmail.com

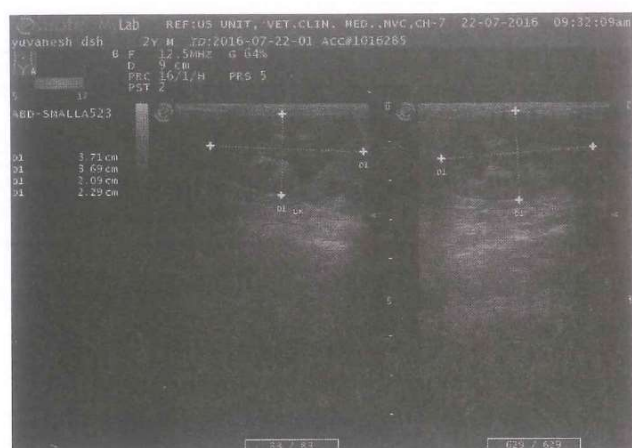which can provide important information regarding the size, shape and internal architecture of the kidney, urinary bladder and its associated structures (Nyland *et al.*, 2002). Ultrasonography is a versatile tool for evaluating the kidneys, urinary bladder and its associated structures as it is a quick, non-invasive and relatively sensitive diagnostic technique (Mantis, 2008).

Materials and Methods

The study was carried out at Small Animal out-patient unit of Madras Veterinary College Teaching Hospital and six adult (> 1 year) domestic short haired cats of either sex (Male : 4 and Female: 2) were included in the study. Hematological and serum biochemical investigation was carried out to assess their health status. The cats were then subjected to ultrasonographic examination to assess the shape,

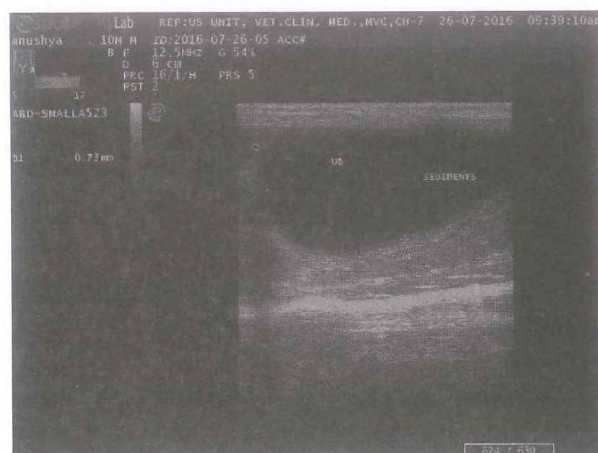
Table I: Mean \pm S.E. values of Hemoglobin, Packed Cell Volume, Red Blood Cells, White Blood Cells, Blood Urea Nitrogen and Serum Creatinine.

Sl.No.	Haemoglobin mg/dl	Packed Cell Volume %	Red Blood Cells X 10 ⁶ /cmm	White Blood Cells /cmm	Blood Urea Nitrogen mg/dl	Serum Creatinine mg/dl
1.	8.1	25.1	4.15	15,500	40.13	1.92
2.	8.5	18.1	3.60	26,600	44.85	1.91
3.	7.2	22.2	3.71	46,000	25.13	1.21
4.	7.5	24.7	3.76	21,700	30.12	1.41
5.	6.5	21.0	3.81	19,700	32.41	1.61
6.	7.4	22.2	3.51	18,900	33.42	1.71
Mean	7.53	22.22	3.75	24,733.33	34.34	1.63
\pm S.E.	\pm 0.28	\pm 1.04	\pm 0.09	\pm 4506.73	\pm 2.89	\pm 0.11

**Fig 1.** Sagittal plane image of normal kidneys in a domestic short haired cat.

architecture and dimension of upper and lower urinary tract structures.

Patient preparation for ultrasonographic evaluation of the urinary tract include clipping of the hair present on the ventral abdomen and application of acoustic coupling gel to the skin. A 12.5 MHz linear transducer was used for ultrasonographic evaluation with the cat positioned in dorsal recumbency with minimum manual restraint. For sagittal plane images the transducer was placed on the ventral abdomen caudal to the ribs and fanned medially and laterally. Both sagittal and transverse plane images were obtained and longitudinal and transverse measurement of both, right and left kidneys were measured as shown in Fig.1. Similarly, the urinary bladder and its associated structures were visualized and the bladder wall thickness was measured as shown in Fig. 2.

**Fig 2.** Sagittal plane image of normal urinary bladder in a domestic short haired cat.

Results and Discussion

Laboratory investigation of haematological and serum biochemical parameters were carried out to assess their health status and the results are furnished in Table I. The values were within normal range and the mean \pm S.E. values of haemoglobin (g/dl), packed cell volume (%), red blood cell (X10⁶/cmm), white blood cells (/cmm), blood urea nitrogen (mg/dl) and creatinine (mg/dl) were 7.53 \pm 0.28, 22.22 \pm 1.04, 3.75 \pm 0.09, 24733.33 \pm 4506.73, 34.34 \pm 2.89 and 1.63 \pm 0.11 respectively.

They were then subjected to ultrasonographic examination to assess the shape, architecture and dimension of upper and lower urinary tract structures and the details of which are furnished in Table II. In the present study, the length and width of left kidney ranged from 3.03 cm – 4.56 cm and 1.27cm – 2.56 cm while the length and width of right kidney ranged

Table II : Mean \pm S.E. values of Kidney length, width and Urinary bladder wall thickness.

Sl. No.	Left Kidney Length (cm)	Left Kidney Width (cm)	Right Kidney Length (cm)	Right Kidney Width (cm)	Urinary bladder wall thickness (mm)
1.	3.03	1.27	3.12	1.18	0.73
2.	4.56	2.56	4.15	2.46	0.59
3.	3.71	2.17	3.52	2.13	0.80
4.	3.59	1.82	3.48	1.70	0.60
5.	3.30	2.02	3.40	1.92	0.41
6.	3.71	2.09	3.61	2.13	0.59
Mean	3.65	1.99	3.55	1.92	0.62
\pm S.E.	\pm 0.21	\pm 0.17	\pm 0.14	\pm 0.18	\pm 0.06

from 3.12 cm – 4.15 cm and 1.18 cm – 2.46 cm, respectively. The urinary bladder appeared as anechoic pear shaped structure with a round cranial apex and tapering towards the bladder neck. The bladder neck appeared longer and cranial to the pelvis. The urinary bladder wall thickness was measured as shown in Fig 2, which ranged from 0.41 mm to 0.8 mm.

Normal feline kidneys measured 30 – 45 mm in length while the normal urinary bladder wall thickness varied from 1.3 – 1.7 mm (Finn-Bodner, 1995). Ultrasonography of the urinary tract in cats, a routine clinical investigation procedure provides important information regarding the size, shape and internal architecture of the kidney, urinary bladder and its associated structures (Nyland *et al.*, *loc. cit.*). Feline kidneys are shorter and rounder than that of dogs. The cortex have a very fine, uniform echotexture while the medulla appeared lobulated divided by fine radiating echogenic lines, quite dark and appeared almost anechoic. The cortex appeared more echogenic than the medulla. The renal pelvis appeared hyperechoic and renal veins were visualized near the hilus in some cats while the renal artery was too small.

The indications of ultrasonography of the kidneys in cats include gross and microscopic haematuria, pyuria, proteinuria, suspected urolithiasis, unilateral or bilateral renomegaly or renal mass, acute renal failure, congenital renal dysplasia or familial nephropathy, polyuria, polydipsia, loss of retroperitoneal details radiographically, chronic renal failure etc., (Graham, 2011) while indications for ultrasonography of urinary bladder and urethra include dysuria, haematuria, stranguria, acute, chronic/recur-

rent urinary tract infections, urinary incontinence, evaluation of suspected ectopic ureters, to assess bladder integrity following trauma and to obtain urine sample by cystocentesis (Barrett, 2011). Though changes in size, architecture and echogenicity of the urinary tract can be assessed by means of ultrasound, the renal function cannot be evaluated (Armbrust and Grauer, 2015).

Summary

Ultrasonography of the urinary tract in domestic short haired cats as a part of routine clinical investigation procedure provided important information regarding the size, shape and internal architecture of the kidney, urinary bladder and its associated structures.

References

- Armbrust, L. and Grauer, G.F. (2015) Imaging the urinary tract. Peer reviewed. *Clinician's brief*. pp. 85 – 94.
- Barrett, E. (2011) Bladder and urethra. In : *BSAVA Manual of Canine and Feline Ultrasonography*. (Eds) F. Barr and L.Gaschen. pp.155 – 164.
- Finn-Bodner, S.T. (1995) The urinary bladder. In : *Practical Veterinary Ultrasound*. (Ed) R.E. Cartee..Lea and Febiger, Philadelphia. pp. 210 – 235.
- Graham, J.P. (2011) Kidneys and proximal ureters. In : *BSAVA Manual of Canine and Feline Ultrasonography*. (Eds) F. Barr and L.Gaschen. pp.110 – 123.
- Mantis, P. (2008) Ultrasonography of the urinary and genital system of the dog and cat. *Iranian J. of Vet. Surgery. Supplement for the 2nd ISVS and 7th ISVSAR*. pp. 63 – 71.
- Nyland, T.G., Mattoon, J.S., Herrgesell, E.R. and Wisner, E.R. (2002) Urinary tract. In : *Small Animal Diagnostic Ultrasound*. 2nd edn. (Eds) T.G.Nyland and J.S.Mattoon. WB. Saunders, Philadelphia, pp. 158 – 195.