

T-232

**PATHOLOGY OF EXPERIMENTAL LEAD TOXICITY AND EFFECT OF *Plumbago zeylanica* IN FEMALE RATS (*Rattus norvegicus*) WITH SPECIAL REFERENCE TO REPRODUCTIVE ORGANS**

LIBRARY  
POST GRADUATE INSTITUTE OF  
VETERINARY AND ANIMAL SCIENCES  
(MAFVSU)

**THESIS**

NO. T 232  
DATE 15/01/2013  
PRICE

Submitted

In partial fulfillment of the requirements for the Degree of

**MASTER OF VETERINARY SCIENCE  
IN  
VETERINARY PATHOLOGY**

BY

**HINGADE SONAL SHAM**  
Enrollment No : V/09/269

Post Graduate Institute of Veterinary and Animal Sciences, Akola

**MAHARASHTRA ANIMAL AND FISHERY SCIENCES  
UNIVERSITY, NAGPUR - 440 001  
(INDIA)**

2011

## DECLARATION OF STUDENT

I hereby declare that the experimental Research work and interpretation of the thesis entitled "PATHOLOGY OF EXPERIMENTAL LEAD TOXICITY AND EFFECT OF *Plumbago zeylanica* IN FEMALE RATS (*Rattus norvegicus*) WITH SPECIAL REFERANCE TO REPRODUCTIVE ORGANS" or part there of has not been submitted for any other degree or diploma of any University, nor the data have been derived from any thesis/ publication of any University or scientific organization. The sources of materials used and all assistance received during the course of investigation have been duly acknowledged.

Place : Akola.


Date : 10/8/2011



Signature

(MISS. HINGADE SONAL SHAM)

Enrollment No. -V/09/269



Countersigned by

Dr. M.V. JOSHI

(Chairman, Advisory committee)

Place : Akola.

Date : 10/8/10


## DECLARATION OF ADVISORY COMMITTEE

HINGADE SONAL SHAM has satisfactorily prosecuted his course of research for period of not less than one semester (for M. V. Sc.) and that the thesis entitled "PATHOLOGY OF EXPERIMENTAL LEAD TOXICITY AND EFFECT OF *Plumbago zeylanica* IN FEMALE RATS (*Rattus norvegicus*) WITH SPECIAL REFERANCE TO REPRODUCTIVE ORGANS" submitted by her is the result of original research work and is of sufficiently high standard to warrant its presentation to the examination in the subject of VETERINARY PATHOLOGY for the award of MASTER OF VETERINARY SCIENCE degree by the Maharashtra Animal and Fishery Sciences University, Nagpur.

We also certify that the thesis or part there of has not been previously submitted by her for a degree of any other University.

Place : Akola.

Date : 10/8/04



Signature

(Dr. M.V. JOSHI)


Chairman, Advisory Committee.


### Advisory Committee


Name	Designation	Signature
1) Dr. M.V. Joshi	( Chairman)	
2) Dr. V.P. Pathak	(Member)	
3) Dr.S.W. Hajare	(Member)	
4) Dr.V.H.Kalbande	(Member)	
5) Dr. M.R. Wade	(Member)	

## CERTIFICATE

This is to certify that the thesis "PATHOLOGY OF EXPERIMENTAL LEAD TOXICITY AND EFFECT OF *Plumbago zeylanica* IN FEMALE RATS (*Rattus norvegicus*) WITH SPECIAL REFERANCE TO REPRODUCTIVE ORGANS" Submitted by HINGADE SONAL SHAM to Maharashtra Animal and Fishery Sciences University in partial fulfillment of the requirements for the degree of **MASTER OF VETERINARY SCIENCE** has been approved by the Student's Advisory Committee after oral examination in collaboration with the External Examiner.


  
13.5.11  
DR. M. SWAMY  
External Examiner

  
19/9/04  
Head,  
Deptt. Of Veterinary  
Pathology, PGIVAS, Akola

  
(Dr.M.V.Joshi)  
Chairman,  
Advisory Committee

### Advisory Committee

Name	Designation	Signature
1) Dr. M.V. Joshi	(Chairman)	
2) Dr. V.P. Pathak	(Member)	
3) Dr. S.W. Hajare	(Member)	
4) Dr. V.H. Kalbande	(Member)	_____
5) Dr. M.R. Wade	(Member)	

  
Signature with Seal  
Dean/Associate Dean

## ACKNOWLEDGEMENT

*This thesis is dedicated in the Memory of my beloved FATHER.*

*"Coming together is a beginning, keeping together is a progress,  
working together is a success"*

Traditional words are in plenty but their 'traditional use' has turned this pleasant duty into a formality. Behind every success of each person there are many known and unknown helping hands and it is always a matter of pleasure to remember and thank them at the end. I have encountered so many people at PGIVAS, who have made these years exciting and fun, besides making bits and pieces of invaluable contribution, of which this work is final outcome. Innumerable people have assisted me and guided me through out my journey. This will not project the picture of the volcano of feelings that is rumbling and struggling to burst out of me through words.

Words are inadequate to express my sincere and deepest feelings of gratitude originating from the innermost core of my heart for honorable teacher and research guide **Dr. M.V. Joshi**, M.V.Sc., Ph.D., Diplomat, ICVP, University Head and Professor, Department of Pathology, Post Graduate Institute of Veterinary and Animal Sciences, Akola for his Benevolent nature, succorable mentality, unflinching interest, relentless efforts, valuable advice, close supervision, stimulating discussion constructive counsel, hearty encouragement and generosity, and pain staking help during complete period of study and research work. *He is the person with outstanding caliber and always remembered for his wholehearted cooperation, ever freshness and sporting nature. With great respect I admit his Lion's share in successful completion of my research.* I forever will be thankful to have had this opportunity to work under his guidance.

*I take this opportunity to express deep sense of heartiest gratitude and sincere regards with respect to my beloved teacher Dr. V.P. Pathak, M.V.Sc., Ph.D., Professor (CAS) of Veterinary Pathology, P.G.I.V.A.S., Akola, for valuable suggestion and parental affection throughout my post graduation course. I always fascinated by his enthusiastic working capacity and keen interest in wildlife research activity.*

It gives me an immense pleasure to place on record the deepest sense of gratitude to **Dr. R. S. Ingole**, M.V.Sc., D.B.M, Assistant Professor, Department of Veterinary Pathology, PGIVAS, Akola for talented and inspiring guidance, keen and untiring interest and timely help throughout the course of present investigation.

I extend my sincere thanks indebtedness & take it my opportunity to pay off all my respects to members of my Advisory committee, **Dr S.W. Hajare** Assistant Professor of Department of Veterinary Pharmacology & Toxicology . For providing lab animal house facility during research work. **Dr. M.R. Wade** Assistant Professor of Department of Veterinary Poultry Science for his friendly approach . **Dr. V.H. Kalabande** Professor of Department of Veterinary Animal Nutrition for his inspiring valuable guidance and suggestion.

I wish to express my immense gratitude to **Dr. M.V. Joshi** Associate Dean PGIVAS Akola ( My Guide) for providing necessary facilities for the completion of this research work. His priceless recommendations were always there till the completion of the research.

I also express my great thankfulness to **Dr. Rajendra Patil** Director of Flair Labs, Surat, Gujarat for giving us lab animal training . Without his valuable guidance & Suggestion this research work was impossible.

I am also grateful to Gupta, Ayurvedic Bhandar , Nagpur for providing me the root powder of *Plumbago zeylanica* for the experimental use..

The special thanks goes to **Dr. Ramteke & Dr. Chandan Jaiswal** for having such nice

X-ray of my little Stuart girls.

My heartfelt thanks goes to my senior friends for their constant cooperation and timely precious advice Drs. **Manjusha Pundalik**, Sonali Meshram, Smita Ingle and Anjali Borghare,

I am highly oblige and appreciate the profound encouragement and invaluable cooperation rendered by my senior Drs. **Bahar sir**, **Priya mam**, **Pravin Raje**, **Pravin Bankar**, **Dev sir**, **Amit sir**, **Jaya mam**, **Anjali Gandhe mam**, & **Trupti mam**.

*It give me an immense pleasure to express my gratitude and sincere regards to those personalities who were given me encouragement and invaluable cooperation at every step of my post graduation course that persons were my Dr. friends **Rahul**, **Sachin**, **Suhas**, **Sagar**, **Mayur**, **Gopal**, **Jaffer**, **Naresh**, **Navarange sir**, **Mohasin Sir**, **Hemant 1**, **Hemant (mineral ka badasha)** & **Mool Sir**.*

The words "thank you" is not enough to express my indebtedness to my all favourite juniors **Bhau**, **Anand**, **Fella**, **Gaurav**, **Mahesh**, **Sarika**, **Sapna**, **Vikrant**, **Nakul**, **Nilesh**, **Urwashi** and **Sawarkar sir** for their help, love and affections and great moral support which never let me go depress of any moment of the struggle in my life.

Ocean cannot be put in nutshell, for me the world outside my home is the ever happening **VANguArd**, no words in any lexicon can express my feelings for **Gadolls group** (my 9 best friends) & **7\* group Sangu** (my **7yr room partner**), **Bara (swati)**, **Draling (Kavu)**, **Jodha(Vandana)**, **Suvarna**, **Rasika (Vrushali)** and **Mangya**, **Bapya** & **Akshya**. They are biggest support of my life. *Emotions are taking over the words to express the feelings towards these persons.*

A formal world of acknowledgement will fullfil the end of justice while expressing my deep sense of gratitude where emotions are involved pen and word cease. I may reduce relationships to formalities if I thank these people but since I am not able to keep myself from it. My endless thank to my family. **Pappa (Late Dr. Sham S. Hingade)** & **Mami Asha Sham Hingade** who have always been for me as pillars of strength and inspiration, blessings, painful dedication to make my dreams come true providing me with whatever foundation, it has taken me to come to this stage, never once denying me any facility throughout the course of student life. My gratitude's and love also goes to my affectionate brother **Harshal**.

At the outmost it is my duty to acknowledge the gratitude the generous help that I have received from Non-teaching staff **Bhaskar Kaka**, **Pradeep Bhau**, **Landge kaku**, **Sabe Kaka** And **Ingle kaka**.

I am very much thankful to **Milind & Anand Joshi (Skyline)** for his interest and skilled photographing & typing of Manuscript.

Lastly I am great heart to my little Stuart Girls for allowing my research work on them.

I apologize for faux pas of of the persons who have extended the help in the completion of this work in a way or other and deserved such thanks.

Above all I bow my head before the Almighty God for clarity of vision and for blessing me endurance and strength to overcome the difficulties that crossed my way in journey of life.

Place :- Akola

Date :- 10/8/2011

  
(Hingade Sonal Sham)

## TABLE OF CONTENTS

CHAPTER	CONTENTS	PAGE NO.
I	INTRODUCTION	1 - 4
II	REVIEW OF LITERATURE	5 - 26
III	MATERIALS AND METHODS	27 - 34
IV	RESULTS AND DISCUSSION	35 - 69
V	SUMMARY & CONCLUSIONS	70 - 73
A)	BIBLIOGRAPHY	I - X
B)	VITA	XI
C)	THESIS ABSTRACT	

### LIST OF TABLES

TABLE	TITLE	PAGE NO.
1	Average weekly feed consumption (g) in different groups.	37
2	Average weekly water consumption (mls) in different groups.	39
3	Average weekly body weights (gms) per rat in different groups.	41
4	Average weekly body weight gain (gms) per rat in different groups.	43
5	Hemoglobin (gm/dl), Packed Cell Volume (%), Total Erythrocyte Count ( $10^6$ /cumm), Mean Corpuscular Volume (fL), Mean Corpuscular Haemoglobin (pg) and Mean corpuscular Haemoglobin concentration (%) in different groups.	45
6	Total Leucocyte count ( $10^3$ /cumm) and Absolute Leucocytes count in different groups.	50
7	Plasma Calcium (mg/dl), Plasma Phosphorus (mg/dl), Plasma Creatinine, Plasma SGOT (AST) (IU/L), Plasma SGPT (ALT) (IU/L), Plasma Glucose (mg/dl) and Plasma Total Protein (gm/dl) in different groups.	54
8	Average organ weights (gms) in different groups.	60

## TABLE OF CONTENTS

CHAPTER	CONTENTS	PAGE NO.
I	INTRODUCTION	1 - 4
II	REVIEW OF LITERATURE	5 - 26
III	MATERIALS AND METHODS	27 - 34
IV	RESULTS AND DISCUSSION	35 - 69
V	SUMMARY & CONCLUSIONS	70 - 73
A)	BIBLIOGRAPHY	I - XIII
B)	VITA	XIV
C)	THESIS ABSTRACT	

## LIST OF PLATES

Plate No.	Particulars	After Page
1	<i>Plumbago zeylanica</i> plant grown in Nagarjuna Vanaoushadhi Udyan Dr. PDKV, Akola.	27
2	Dry root powder of <i>Plumbago zeylanica</i>	27
3	Cold ethanolic extract of <i>Plumbago zeylanica</i> of dry root powder	27
4	Control group rats (T <sub>1</sub> ).	29
5	Group II rats given 500 ppm lead acetate (T <sub>2</sub> ).	29
6	Group III rats given 100 mg/kg body weight ethanolic extract of <i>Plumbago zeylanica</i> (T <sub>3</sub> ).	29
7	Group IV rats given 500 ppm lead acetate + 100 mg/kg body weight ethanolic extract of <i>Plumbago zeylanica</i> (T <sub>4</sub> ).	29
8	Weighing machine used for weekly body weight	29
9	Variation in growth of different group animals.	29
10	Variation in carcass size of different group rats.	58
11	T <sub>3</sub> group rat showing congestion in uterus	58
12	Variation in size of uterus and ovary in different groups rats.	58
13	Radiograph of T <sub>1</sub> group rats.	58
14	Radiograph of T <sub>2</sub> group rats.	58
15	Radiograph of T <sub>3</sub> group rats.	58
16	Radiograph of T <sub>4</sub> group rats.	58
17	Section of liver from T <sub>1</sub> group rat showing normal hepatic parenchyma and central lobular vein (100x) H&E	63
18	Section of liver from control group rat showing normal hepatic parenchyma (400x) H&E	63
19	Section of liver from T <sub>2</sub> group rat showing dilated sinusoids and atrophic hepatic parenchyma (200x) H&E	63
20	Section of liver from T <sub>2</sub> group rat showing dilated sinusoids, atrophic parenchyma and hyperplasia of reticular cells (400x) H&E.	63
21	Section of liver from T <sub>3</sub> group rat normal hepatic parenchyma (100 x) H&E	63
22	Section of liver from T <sub>4</sub> group rat showing restoration of hepatic parenchyma (100 x) H&E.	63
23	Section of lung from T <sub>1</sub> (Control) group rat showing normal structure of Alveoli (100x) H&E.	64

Plate No.	Particulars	After Page
24	Section of lung from T <sub>3</sub> group rat showing congestion and round cell infiltration (200x) H&E	64
25	Section of heart from T <sub>2</sub> group rat showing myocardial congestion and haemorrhages (200x) H&E.	64
26	Section of heart from T <sub>4</sub> group rat showing normal parenchyma & myocardium (100x)H&E.	64
27	Section of kidney from T <sub>1</sub> (control) group rat showing normal tubular epithelium & glomeruli (100x)H&E.	64
28	Section of kidney from T <sub>2</sub> group rat showing desquamated epithelium in lumen & tubular nephrosis (200x) H&E	64
29	Section of kidney from T <sub>4</sub> group rat showing changes in tubular epithelium (200x) H&E.	65
30	Section of spleen from T <sub>1</sub> group rat showing normal lymphoid population (100x) H&E.	65
31	Section of spleen from T <sub>2</sub> group rat showing congestion and depopulation of lymphocyte (100 x) H&E.	65
32	Section of brain from T <sub>1</sub> (control) group rat showing normal parenchyma (100x) H&E.	65
33	Section of brain from T <sub>2</sub> group rat showing congestion and oedema (200x) H&E.	65
34	Section of pancreatic islet from T <sub>2</sub> group rat showing granular and degenerative changes (400x) H&E.	65
35	Under high power Section of pancreatic islet from T <sub>2</sub> group rat showing granular and degenerative changes (400x) H&E.	66
36	Section of pancreatic islet from T <sub>3</sub> group rat showing normal pancreatic islet and mild congestion (100x)H&E	66
37	Section of thyroid from T <sub>1</sub> (Control) group rat showing normal thyroid follicular structure (100x)H&E.	66
38	Section of thyroid from T <sub>2</sub> group rat showing colloid and resorbtion of colloid (200x) H&E.	66
39	Section of thyroid from T <sub>3</sub> group rat showing normal collid resorbtion and pale collid (100x)H&E.	66
40	Section of thyroid from T <sub>4</sub> group rat showing focal round cell infiltration (200x) H&E.	66
41	Section of ovary from T <sub>1</sub> (control) group rat showing developing follicles (100x) H&E.	67
42	Section of ovary from T <sub>1</sub> (control) group rat showing developing follicles (antrum) (400x)H&E.	67
43	Section of ovary from T <sub>2</sub> group rat showing severe congestion, haemorrhages and decrease number of follicles (100x) H&E	67

Plate No.	Particulars	After Page
44	Section of ovary from T <sub>3</sub> group rat showing sever congestion arrest of developing follicles (200x) H&E.	67
45	Section of ovary from T <sub>4</sub> group rat showing decrease number of developing follicle with severe congestion (200x) H&E	67
46	Section of uterus from T <sub>1</sub> (control) group rat showing myometrium along with glandular epithelium (100x) H&E	67
47	Section of uterus from T <sub>2</sub> group rat showing thinning of myometrium and congestion with proliferating endometrial glands (200x) H&E.	68
48	Section of uterus from T <sub>2</sub> group rat showing hyperplasia of endometrial gland (200x)H&E.	68
49	Section of uterus from T <sub>4</sub> group rat showing glandular hyperplasia (100x) H&E.	68
50	Section of vulva from T <sub>1</sub> (control) group rat showing normal stratified and pseudostratified epithelium layer (200x) H&E	68
51	Section of vulva from T <sub>3</sub> group rat showing stratified squamous epithelium (100x) H&E.	68
52	Section of vulva from T <sub>4</sub> group rat showing desquamation of cornification of mucosa and absence of gland (100x) H&E.	68

## LIST OF ABBREVIATIONS

%	Percent
&	And
µg	Microgram
@	at the rate of
ALT	Alanine aminotransferase
AST	Aspartate aminotransferase
ATSDR	Agency for toxic substances and disease registry
CD	Critical difference
CRD	Completely randomized design
Cumm	Cubic millimeter
DLC	Differential leucocyte count
<i>et al.</i>	Et alia (and others)
F-CRD	Factorial completely randomized design
Fig.	Figure
FI	Feltometer
g/gms	Gram
H & E	Hematoxyline and Eosin
Hb	Haemoglobin
IU/L	International unit per litre
Kg	Kilogram
MCH	Mean Corpuscular Haemoglobin
MCHC	Mean Corpuscular Haemoglobin Concentration
MCV	Mean Corpuscular Volume
MI	Milliliter
Mrna	Messenger ribonucleic acid
NS	Non significant
NSS	Normal saline solution
°C	Degree celcius
Pb	Lead
PCV	Packed cell volume
Pg	Picogram
ppm	Parts per million
RBC	Red blood cell
RBD	Randomized block design
SGOT	Serum glutamate oxalacetate transaminaenc
SGPT	Serum glutamate pyruvate transaminaenc
TEC	Total erythrocyte count
TLC	Total leucocyte count
WBC	White blood cell
WHO	World health organization



Chapter - I

# **Introduction**



## CHAPTER I

### INTRODUCTION

Human dominance over environment in recent years has assumed such enormous dimensions that nature's scheme of self-sustaining environment has been thrown out of gear. This has resulted in problems including pollution, which is defined as the presence of chemical, physical and biological factors in the environment capable of inducing injurious effects on human, plant or animal life or environment itself.

Environmental pollution is a major global problem posing serious threat to the health of man and animals. Most of the environmental pollutants are hazardous to surrounding living things. These pollutants include heavy toxic metals such as lead, arsenic, zinc, copper, mercury, nickel, chromium, vanadium, antimony, cobalt, beryllium, cadmium, manganese, tin etc. Globalization and modern industrialization has introduced these harmful metals by various means in the environment. These metals are particularly dangerous because they tend to bio-accumulate in the body tissues and organs (Luckey *et al.* 1975; Babalola *et al.* 2005). In recent years, lead has become a regulatory concern and subject of much interest among pharmacologists, environmental scientists and clinicians because of its widespread distribution in environment due to its continuous emission from industrial sources, automobile exhaust and its pharmacological behavior to remain bound to mammalian tissues for a long duration.

Lead is a ubiquitous and versatile metal which has been used by mankind for many years. It ranks as one of the most serious environmental poisons amongst the toxic heavy metals all over the world. Lead ranks second of the 275 substances on the ATSDR/EPA priority list of hazardous substances for 2003 (ATSDR, 2003). Lead is a common cause of poisoning of domestic animals throughout the world. It is a heavy, low melting, bluish-gray metal that occurs naturally in the Earth's crust. However, it is rarely found naturally as a metal. It is usually found combined with two or more other elements to form lead compounds. The important sources of lead exposure include gasoline additives, food can solder, lead-based paints, ceramic glazes, drinking water system, cosmetics and plastic recycling industries. It also occurs from burning of coal, air

born effluents smelters lead-plates in automotive batteries, fishing sinkers, lead shotgun pellets, sewage sludge and use of lead compound in different industrial processes. Research has also shown that lead is present in tobacco, cigarettes contain 2.4 µg of lead and 5% of this occurs in ash and side stream smoke (Mussalo-Rauhmaa et al., 1986).

Lead induces wide range of physiological, biochemical and behavioral dysfunctions. It is absorbed in the body following ingestion and inhalation exposure and distributed in soft tissues and bones via blood. The soft tissues that take up lead are liver, kidney and in small amount brain and muscles. It affects central nervous system and is also irritating, immunosuppressive, genotoxic, teratogenic, nephrotoxic and toxic to the haemopoetic, reproductive and urinary system. (Garge 2000) The condition caused by lead is known as 'plumbism'. It also affects bone and has been shown to be carcinogenic in rats and mice.

Toxicopathological investigation of lead in female rats conducted by Kale (2008) indicated its hepatotoxic, nephrotoxic effect and adverse effect on reproductive organs. Similar studies on quails and poultry have been conducted by Wagh(2006), Deshmukh (2006) and Raheman (2006) who observed its adverse effect on visceral organs.

Effect of lead on reproductive systems is also well documented. Lead is a male reproductive toxicant (Winder, 1989), the primary mechanism of the toxic action of lead appears to be a disruption of the hypothalamic control of pituitary hormone secretion and in turn, spermatogenesis (Sokol, 1987). Since male do not possess accessory reproductive organs, reproductive potential relates to three factors; sperm availability, quality and quantity (Tsuji and Karagatzides, 2001).In females, menstrual irregularities, preterm deliveries and still births have been reported (WHO, 1986).

Toxicologists, the scientists who help determine the limits for safe use of materials, use modern technological research methods, including tests on animals, to protect human and animal health and the environment. Toxicological research and testing helps us to live safely and to derive benefit from natural and synthetic substances while avoiding harm. Veterinarians have sworn an oath to protect animal health and relieve suffering in their patients. Yet they are equally committed to promoting public health and advancing medical knowledge about

animals as well as humans. The tension between these dual obligations is nowhere more profound than in the field of laboratory animal medicine. Although distribution of metals in the animal body has been studied in detail, much of the data refer to studies in laboratory animals, often with amounts of metals that result in acute or chronic toxicity.

Today, Ayurvedic, Homeopathic and Unani physicians utilize numerous species of medicinal plants that found their way a long time ago into the Hindu Materia medica (Rao, 1987). India has a long history in traditional health practices. In India around 20,000 medicinal plant species have been recorded recently (Dev, 1997), but more than 500 traditional communities use about 800 plant species for curing different diseases (Kamboj, 2000). Currently 80 % of the world population depends on plant-derived medicine for the first line of primary health care for human alleviation because it has no side effects (Veale *et al.*, 1992). Many medicinal plants are known for their protective role against liver and kidney damage.

*Plumbago zeylanica*, commonly known as "White Chitrak" (family:Plumbaginaceae) is a perennial herb grown cultivated extensively throughout India. Lead wort (Latin plumbago), a lead like ore alluding to historical use as a cure for lead poisoning has been described by Smith( 1753). It's an early belief that the plants could cure lead poisoning (Lledo 1998) which is also known as plumbism.

Administration of "*plumbagin*" isolate of *Plumbago zeylanica* showed anticancer, antibacterial as well as antifungal activities in wistar rat. (Krishanaswamy and Purshothaman, 1980) . A wide range of therapeutic effects of roots of *Plumbago zeylanica* including anti-atherogenic, cardiogenic, hepatoprotective, and neuro protective properties (Tilak *et al.* 2004).

Roots and root barks of this plant are the most frequently used plant parts which have plumbagin which closely resembles the vitamin K and the anticoagulant property of *P. zeylanica* might be similar to coumarin derivative, the hemorrhage may be due to the competitive inhibition of vitamin K activity, needed for the synthesis of clotting factors (Santhakumari *et al.*1978). The anticoagulant activity of the *P. zeylanica* was reported after an hour exposure and the effect of *P. zeylanica* on platelets and coagulation profile lead to the development of an

antithrombotic drug (Shah *et al.* 2004). The root of *P. zeylanica* has been reported in the literature for its biological activity such as antiparasitic (Ramachandra and Ravishankar, 2002) and insect antifeedant (Alluri and Rao, 2005).

The extract of some species of plumbaginales and also some isolated compounds reveals to be of great importance in the search of new drugs for the treatment of many diseases such as Leishmaniasis, Chagas' disease, Malaria, and Cancer (Selma *et al.* 2003). Roots, bark and seeds of the plants are known for promoting digestion, stimulation of central nervous system, treatment of skin diseases, chicken pox, influenza, Black water fever in Ethiopia.

Present studies on pathology of experimental lead toxicity and effect of *Plumbago zeylanica* were conducted in adult non pregnant female wistar rats to evaluate its histotoxic effect with special emphasis on reproductive organs. As very less information is available regarding this plant, the experiment was planned with following objectives

- 1) Toxicopathology of lead acetate @ 500 ppm level in drinking water in female rats (*Rattus norvegicus*).
- 2) Effect on general performance, haematological and biochemical parameter.
- 3) To evaluate effect of dry root powder extract of *Plumbago zeylanica* 100 mg/kg body weight in female rats given lead acetate at 500ppm levels on the basis of gross and histopathological alteration in visceral organs.



Chapter - II

***Review of Literature***



## CHAPTER II

### REVIEW OF LITERATURE

Lead is a ubiquitous and versatile metal which has been used by mankind for many years. It ranks as one of the most serious environmental poisons amongst the toxic heavy metals all over the world.

Lead is a cumulative poison and exposure even to small amounts can raise the body's content to toxic levels with negative effects on general health, reproduction, behavior, and potentially leading to death.

After Pb enters the body, it can travel along several pathways depending on its source and, by extension, its bioavailability. The fraction of Pb that is absorbed depends mainly on the physical and chemical form, particularly particle size and the solubility of the specific compound. Other important factors are specific to the exposed subject, such as age, sex, nutritional status and, possibly, genetic background. Once absorbed into the blood it has a mean biological half-life of about 40 days in adult males. The half life in children and in pregnant women was reported to be longer, because of bone remodelling (Barbosa *et al.*, 2005).

Lead has very high affinity for red blood cells, it has been shown that lead inhibits the enzymes  $\delta$ -aminolevulinic acid dehydratase (ALAD) and ferrochelatase of the heme synthetic pathway thus preventing conversion of ALA to porphobilinogen and inhibits incorporation of iron into the protoporphyrin respectively. This results in reduced heme synthesis and elevated levels of the precursor  $\delta$ -aminolevulinic acid (ALA), which is a weak gamma-aminobutyric acid (GABA) agonist that decreases GABA release by presynaptic inhibition (Babalola *et al*, 2010).

The toxicity of high-dose lead exposure affects the reproductive function in female. Female workers at high dose lead exposure had reported an increase in the frequency of miscarriages and stillbirths. Increased prevalence of menstrual disturbances, spontaneous abortion and threatened abortion were reported to occur among lead exposed women. Lead acetate is, however, reported to arrest growth and maturation of the ovarian follicles upon oral administration to mice (Jabeen *et al*, 2010)

Herbal products are extensively used globally for the treatment of many diseases where allopathic fails or has severe side effects. Psycho neural drugs are also have very serious side effects like physical dependence, tolerance, deterioration of cognitive function and affect on respiratory, digestive and immune system. So in this contest the treatment through natural source is seen with the hope that they have the lesser side effects than that observed with synthetic drugs. *Plumbago zeylanica* L. commonly known as white chitrak (family: plumbaginaceae) is a perennial herb that is grown in most parts of India and is used in the traditional system of Indian medicine against a number of ailments including skin diseases, diarrhea and leprosy .( Vishanukant *et al*, 2010 )

*Plumbago* is a genus of 10-20 species of flowering plants in the family Plumbaginaceae, native to warm temperate to tropical regions of the world. Common names include plumbago and leadwort (names which are also shared by the genus *Ceratostigma*). The name *Plumbago* is derived from Latin *plumbum* ("lead"), either from the lead-blue flower colour of some species (OED), or from the plant at one time being a supposed cure for lead poisoning. (Huxley 1992).

The active principle 'Plumbagin' of *Plumbago zeylanica* responsible for many therapeutic effects. Plant preparations are used for treatment of arthritis, epilepsy, hysteria and disease of nervous system. It also possesses antibacterial, antifungal, anticarcinogenic and radiomodifying properties.( Krishnaswamy and Purushothaman1980 and Bopaiah 2001)

Kantha *et al.* (2010) showed that *Plumbago zeylanica* is important medicinal plant which are used for anti-inflammatory, antimicrobial diseases.

The *Plumbago zeylanica* root extract is hypoglycemic, hepatoprotective in nature mentioned by Zarmouh (2010)

The latin *Plumbago* word indicates a lead like ore alluding to its historical use as cure for lead poisoning mentioned by Smith (1753)

Considering medicinal properties of *Plumbago zeylanica* during lead toxicity literature reviewed during present studies is grouped under following head.

- 2.1 Effect of Lead toxicity
  - 2.1.1 General performance and clinical sings
  - 2.1.2 Hematological Investigations
  - 2.1.3 Biochemical Investigations
  - 2.1.4 Gross Pathological Observations
  - 2.1.5 Histopathological Observations
    - (A) Visceral Organs
    - (B) Reproductive organs
- 2.2 Medicinal Properties of *Plumbago zeylanica*
- 2.3 *Plumbago zeylanica* in Lead Toxicity

## 2.1 Effect of Lead Toxicity

### 2.1.1 General Performance and Clinical Sings

Various authors have described general performance and clinical symptoms in experimental and accidental poisoning during lead toxicity in various animals

Vodella *et al.* (1997) studied the effect of drinking water contaminant (arsenic, cadmium, lead, benzene and trichloroethylene) on reproductive performance, egg quality and embryo toxicity in broiler breeders. They concluded that drinking water containing a mixture of five chemicals resulted in lower reproductive performance as indicated by decreased egg production, decreased egg weight, decreased hatchability and increased embryonic mortality

Garg (2000) described the prominent signs of lead toxicosis as anorexia, ataxia, loss of condition, wing and leg weakness, anemia and gastrointestinal abnormalities.

Ozcelik *et al.* (2003) studies effect of lead on performance of chicks due to its accumulation in body tissues. Day old chicks were divided in to two groups as experimental and control. Experimental group birds were given lead acetate @ 300mg/ kg in for four weeks. They observed significant lower live mean weight of experimental group than that of control group birds.

Vijaykumar *et al.* (2006) carried out experimental lead acetate intoxication @ 500ppm in feed from 2 week onward. They observed that the silent signs observed in lead acetate fed group were dullness depression, anemia, ruffled feather greenish diarrhea in broilers.

Deshmukh (2006) studied pathology of experimental lead toxicity in broilers for a period of six weeks. Group I birds serve as control where as group II, III, IV birds were given lead acetate at 100, 200 and 300ppm. Clinical symptom of greenish watery diarrhoea was evident in group II,III and IV birds (40, 61.90 and 70.00 percentage birds respectively) other clinical symptoms described were respiratory distress, deformities of claws, pale discoloration of shanks and dose dependent decrease in feed consumption. Birds from group III and IV reveled significant decrease in body weights, and feed consumption per kg weight gain

Rahman (2006) studied effect of lead toxicity on growth and performance of broilers . The effect of lead toxicity on general performance of broilers was evaluated on the basis of feed consumption, average weekly body weights, body weight gain and feed conversion ratio. The minimum feed intake & lower average weights was observed in group III i.e. birds receiving 400 ppm lead acetate in drinking .

Ghule (2007) described clinical symptoms of weakness, lameness, debility and loss of feathers in lead treated group. Highest feed consumption with better feed conversion efficiency was recorded in control group as compared to treatment group. Treatment group birds revealed dose dependent decrease in average weekly body weights and weekly body weight gain when compared with

control group.

In rats , Brahmarkar (2008) studied effect of lead acetate at 500, 700, 1000 ppm in drinking water for 4 weeks period pesty dark brown colour faces and dose dependent decrease in average feed consumption, water consumption and body weights .

Kale (2008) conducted a experiment on forty adult female rats given 100, 250, 500 ppm lead acetate in drinking water for four weeks. Lead treated group rats reveals decrease in feed consumption, water consumption and body weight .

Gongale (2009) conducted their studies on avian species viz. quails to evaluate effect of feeding lead acetate on general performance and clinical signs. They reported weakness, lameness, debility, loss of feathers, greenish watery diarrhea, deformalities of claws, reduction in feed consumption, average body weight and body weight gain.

Meshram (2009) described clinical symptoms of greenish watery diarrhoea, respiratory distress, deformities of claws, pale discoloration of shanks and dose dependent decrease in feed consumption. There was significant decrease in body weights and feed consumption per kg weight gain in quails receiving 200 ppm lead acetate.

Suradkar (2009) studied on 48 wistar rats giving lead acetate at 100,1000 ppm in drinking water for 28 days revealed toxic symptoms like weakness, lethargy, pale mucous membrane and diarrhoea along with respiratory distress were noticed in some of the male and female rats.

Chandra *et al.* (2010) studied clinical symptoms in rats receiving lead acetate at 600ppm & 100ppm and observed anorexia, reduced body weight, poor fur condition, restlessness, mild diarrhoea, increased thirst, incoordination, ataxia, tremors, extreme nervousness, hypersensibility, ascending paralysis of hind legs followed by foreleg.

## 2.1.2 Hematological Investigations

Hematological observations during lead toxicity has been studied by various workers.

Garg (2000) reported that lead influence the synthesis of haem by inhibiting  $\delta$ -aminolevulinic acid dehydratase enzyme, conversion of caproporphyrinogen III to protoporphyrin IX and inhibition of haem synthesis which is required to incorporate iron in the haem molecule. Anemia develops due to inhibition of haem synthesis and depressant action of lead deposition in bone marrow.

Mugahi *et al.* (2003) studied effects of chronic lead acetate intoxication at 1 per cent lead acetate solution in deionised drinking water for 12 week in rats. They reported decreased RBC, increased leukocyte count, monocytosis, eosinopenia, neutrophilia, thrombocytosis along with Howell-Jolly bodies and basophilic stippling. They also reported nonsignificant reduction in hemoglobin and hematocrit values.

Cetin *et al.* (2004) studied the effect of chronic lead intake on hematological parameters in mice administered through drinking water at the dose rate of 1000 ppm. Mice showed significantly lower erythrocyte count, hematocrit and hemoglobin, MCV and MCH values than control mice. Additionally platelet counts, total leukocyte counts and lymphocyte ratios were significantly lower in lead treated mice than the control animals whereas neutrophil ratios was significantly elevated in lead treated group.

In broilers significant decrease in Hb, PCV, TEC, TLC and non-significant decrease in MCV, MCH and MCHC was revealed by Deshmukh (2006) and Wagh (2006) given lead acetate at 100 200 and 300ppm levels in drinking water.

Raheman (2006) showed significant decrease in Hb, PCV, TEC, TLC and dose dependent decrease in MCV, MCH, ad MCHC in treatment group birds receiving 200,400,600 and 1000 ppm lead in feed 4<sup>th</sup> & 6<sup>th</sup> weeks when compared with control group birds. DLC indicated significant decrease in

lymphocyte count and relative increase in heterophil count.

Ashour *et al.* (2007) investigated the effect of lead in rats @ 1000 and 2000 ppm through deionised drinking water. They recorded significant decrease in red cell count, hemoglobin concentration and packed cell volume at 20, 40 and 60 days.

Ghule (2007) studied hematology at 6<sup>th</sup> weeks in broilers given lead acetate at 250 and 400ppm levels in drinking water. Hb, PCV, TEC, TLC and MCH values showed significant decrease where as MCV and MCHC values showed non significant decrease. Treatment group birds revealed significant decrease in total lymphocyte and relative increase in heterophil count.

Brahmankar (2008) studied hematology in male rats given lead acetate at 500, 700, 1000 ppm in drinking water for a period of four weeks. Significant decrease in average Hb, PCV, TEC, TLC and MCV values and non significant decrease in MCH values

Kale (2008) studied toxicopathology of experimental lead toxicity in female rats at 100,250 and 500 ppm and observed significant decrease in Hb, PCV, TEC, TLC and dose dependent decrease in MCV, MCH, and MCHC values indicating toxic effect on hemopoietic system causing anemia.

Toxic effect of lead was studied by Ajayi *et al.* (2009) on experimental induction of lead toxicity in rats lead acetate was given to rats @ 100  $\mu$  mol/kg of body weight intraperitoneally for period of seven days and recorded significant increase in packed cell volume and non significant increase in hemoglobin concentration as compared to normal rats.

Gongale (2009) studied pathology of experimental lead toxicity (Lead acetate @ 300 ppm) and protective effect of *Plumbago zeylanica* in Japanese quails for a period of four weeks. On the basis of haematological parameters lead acetate treated groups birds revealed significant decrease in Hb, PCV, TEC, TLC and non-significant decrease in MCV, MCH and MCHC.

Toxic effect of lead @ 750ppm was studied by Ingale (2009) with protective effect of *Plumbago zeylanica* @ 50 mg/kg body wt & 100mg/kg body wt. given to the 42 rats for the period of 42 days. On the basis of haematological

parameters lead acetate treated group rats revealed significant decrease in Hb, PCV, TEC and increased TLC count.

Meshram (2009) studied toxicopathology of lead acetate and protective effect of *Plumbago zeylanica* in japanese quails for a period of four weeks. Finding indicated increase concentration of lead in blood of lead treated groups with decrease in Hb, PCV, TEC, TLC and non-significant decrease in MCV, MCH and MCHC.

Suradkar *et al.* (2009) studied haemato-biochemical alterations induced by lead acetate toxicity in wistar rats. 48 Wistar rats of either sex, divided uniformly into four different groups. The rats of group I received only deionised water as control while, group II, III and IV were given lead acetate @ 1 PPM, 100 PPM and 1000 PPM, in drinking deionised water respectively for 28 days. In group III and IV dose dependant significant ( $P < 0.05$ ) reductions in TEC, Hb, PCV and TLC which revealed microcytic hypochromic anemia. were observed. No significant change was observed in neutrophil, eosinophil, basophil and monocyte count in any treatment groups, whereas the lymphocyte count decreased significantly.

Chandra *et al.* (2010) studied the effect of chronic lead intake on hematological parameters in rats administered orally @ 600ppm & 100ppm, and restored significantly decreased in erythrocyte count, hematocrit and hemoglobin, MCV, MCH & MCHC values than control mice. Platelet counts, total leukocyte counts and lymphocyte ratios were significantly lower in lead treated rats than the control animals whereas neutrophil ratios were significantly elevated in lead treated rats.

Autade (2010) studied effect of *Allium sativum linn.* powder in experimentally induced lead toxicity in japanese quails for a period of four weeks. Birds receiving lead acetate(@ 300 ppm) showed significant decrease in Hb, PCV, TEC, TLC and non-significant decrease in MCV, MCH and MCHC.

Deshmukh (2010) studied effect of *Embllica officinals* fruit powder in experimentally induced lead toxicity(@ 300 ppm in japanese quails for a period of 42 days and showed significant decrease in Hb, PCV, TEC, TLC and dose dependent decrease in MCV, MCH, ad MCHC values indicating toxic effect on hemopoitic system causing anemia.

### 2.1.3 Biochemical Investigations

Upasani and Balaraman (2001) reported that there was increase in the levels of cholesterol, triglyceride and phospholipid in the liver, lung, heart and kidney of rats exposed to lead.

Tatjana et al. (2003) investigated in vivo effect of Captopril on lead induced liver injury in rats. The rats were treated with lead acetate (25 mg/kg b.wt. i.p.) and Captopril (100 mg/kg b.wt. i.p.). Five days exposure of lead treatment resulted in significant increase in the activity of alkaline phosphatase while significant decrease was found in the levels of plasma total protein and albumin.

Saly et al. (2004) observed that there were decreased levels of blood calcium and increased level of blood phosphorus, ALP, ALT, AST in lead treated layers as compared to control birds. Values of calcium, phosphorus, ALP, ALT, AST in lead treated layers were found to be  $4.31\text{mmol.l}^{-1}$ ,  $1.965\text{mmol.l}^{-1}$ ,  $19.30\text{ }\mu\text{kat.l}^{-1}$ ,  $0.102\text{ }\mu\text{kat.l}^{-1}$  and  $1.63\text{ }\mu\text{kat.l}^{-1}$  respectively when compared with values of control group  $4.85\text{mmol.l}^{-1}$ ,  $1.497\text{mmol.l}^{-1}$ ,  $8.45\text{ }\mu\text{kat.l}^{-1}$ ,  $0.050\text{ }\mu\text{kat.l}^{-1}$  and  $1.539\text{ }\mu\text{kat.l}^{-1}$  respectively.

Deshmukh (2006) observed significant increase in AST values and non significant increase in uric acid and creatinine levels in birds given lead acetate at 100,200 and 300ppm levels in drinking water for period of 6 weeks. Values of AST, uric acid and creatinine in birds given 300ppm lead acetate were found to be 249.08 IU/dl, 14.04 and 1.84 mg/dl, respectively when compared with values of control group 190.17 IU/dl, 8.36 and 0.59mg/dl respectively.

Rahman and Sultana (2006) evaluated chemo preventive activity of glycyrrhizin on lead acetate mediated hepatic oxidative stress and its hyper proliferative activity in wistar rats. There was significant decrease in SGPT, SGOT and LDH levels in animals pretreated with glycyrrhizin.

Ashour et al. (2007) observed significant increase in serum urea, uric acid and creatinine. When lead acetate, given orally through drinking water @ 1000 and 2000 ppm in rats and reported decrease in serum glucose value. Values of serum urea, uric creatinine and serum glucose in lead treated rat is 56.8 mg/dl, 2.48 mg/dl, 0.86 mg/dl.75.5 mg/dl respectively as compare to control

group rat 38.5 mg/dl, 1.75 mg/dl, 0.55 mg/dl, 107.2 mg/dl respectively.

Ghule (2007) observed significant decrease in serum proteins, calcium and non significant decrease in albumin, globulin and A/G ratio. serum phosphorus levels were significantly increased when compared with control group birds suggesting toxic effect of lead on biochemical parameters in quails at 200, 400, 600, 1000 ppm levels.

Brahmankar (2008) observed non significant decrease in calcium, phosphorus cholesterol, AST and ALT values showed significant increase in lead treated group rats as compared to control group. values of suggesting hepatorenal damage during lead toxicity at 500, 700 and 1000 ppm levels.

Moussa and Bashandy (2008) studied biophysical and biochemical changes in the blood of 32 wistar rats exposed to 2% lead acetate in drinking water observed significant decrease in the plasma proteins and significant elevation of serum aspartate aminotransferase (AST), alanine aminotransferase (ALT), alkaline phosphatase (ALP) and serum cholesterol levels after one, two, three months of lead treatment.

Kale (2008) observed non significant decrease in total proteins ( $8.21 \pm 0.49$ ), albumin ( $4.90 \pm 0.20$ ), globulin ( $3.31 \pm 0.46$ ), A/G ratio ( $1.59 \pm 0.18$ ) and phosphorus ( $4.48 \pm 0.29$ ) and significant decrease in plasma calcium ( $10.18 \pm 1.57$ ) levels in lead treated group rats. significant increase in SGOT ( $145.26 \pm 16.28$ ), SGPT ( $46.26 \pm 4.50$ ) and Creatinine ( $0.98 \pm 0.09$ ) in lead treated group rats at 100, 250 and 5000 ppm level of lead when compared with values of control group i.e. total proteins ( $9.94 \pm 0.21$ ), albumin ( $4.73 \pm 0.08$ ), globulin ( $5.20 \pm 0.17$ ), A/G ratio ( $0.90 \pm 0.02$ ), phosphorus ( $5.95 \pm 0.24$ ), calcium ( $10.65 \pm 1.63$ ), SGOT ( $118.7 \pm 18.09$ ), SGPT ( $40.53 \pm 2.77$ ), and Creatinine ( $0.60 \pm 0.12$ ) respectively.

Gongale (2009) and Meshram (2009) studied pathology of experimental lead toxicity and protective effect of *Plumbago zeylanica* in Japanese quails for a period of four weeks. Birds receiving lead acetate indicated hepatotoxic and nephrotoxic effect, elevated in AST, ALT, creatinine, phosphorus

and alkaline phosphates levels.

Hamadouche *et al.* (2009) observed that exposure of rats to lead showed a significant increase in blood lead concentration, ALP, Cholesterol whereas there was decreased level of calcium, magnesium and ascorbic acid.

Suradkar *et al.* (2009) studied haemato-biochemical alterations induced by lead acetate @ 1 PPM, 100 PPM and 1000 PPM, in drinking deionised water for 28 days in 48 Wistar rats of either sex, divided uniformly into four different groups. Dose dependant significant ( $P < 0.05$ ) increase in AST, ALP, AKP, GGT, BUN and creatinine experiential while TP and albumin levels were decreased in group III and IV.

Autade (2010) and Deshamukh (2010) reported increase in AST, ALT, creatinine, phosphorus and alkaline phosphatase levels in birds suggesting it's hepatotoxic and nephrotoxic effect at 300ppm levels

Chandra *et al.* (2010) studied the effect of chronic lead intake on biochemical parameters in rats administered through orally @ dose rate 600ppm & 100ppm. Reveled Significant decrease in total protein , albumin, and alkaline phosphatase value significant increase in glucose , serum urea, creatinine, and aspartate aminotransferase, bilirubin, alanine amiontransferase and serum cholesterol have been reported.

#### **2.1.4 Gross Pathological Observation**

Various authors have reported gross pathological changes in visceral organs during accidental or experimental lead toxicity studies in animal and birds.

During studies conducted by National Toxicological programme (1996) on four hundred male and four hundred female Sprague-Dawley rats given lead acetate 0, 0.025, 0.05, 0.1, and 0.3% in drinking water, decreased uterine and ovarian weights have been reported.

Shakoor *et al.* (2000) given lead and aluminium chloride simultaneously for 90 days in rats and observed lower body weights and relative organ weights in treatment group as well as increase in heart and kidney weights.

Chen *et al.* (2004) evaluated immunotoxicity in female Fischer 344 rats given lead acetate at 250 ppm through drinking water during pregnancy and until parturition. They observed increased relative spleen weights of dam however lead exposed offspring did not reveal any significant change on relative spleen weight.

Deshmukh (2006) studied gross pathological changes in lead treated group birds that revealed congested mesentery, liver and lung. Liver showed brown discoloration at 300 ppm level of lead acetate. Dose dependent decrease in organ weights was observed in most of the treatment group birds

Rahman (2006) observed decreased average weights of liver, lungs, heart, and kidneys during experimental lead toxicity in broilers at 250,400 ppm.

In quails, Ghule (2007) also reported dose dependant decrease average weights of liver, heart, spleen, testes, intestine, gizzard, pancreas, brain and thymus during experimental studies on lead toxicity at 200, 400, 600, 1000 ppm.

Brahmankar (2008) studied toxicopathology of experimental lead toxicity in male rats at 500, 700 and 1000 ppm revealed decrease carcass size with congestion in visceral organs i.e. liver, lung, heart, spleen, kidney , brain and mesentery with pale discoloration of mucosa and subscapular testicular edema with marked decrease in size of lead treated group rats.

Durgut *et al.* (2008) studied effect of high dose lead toxication on liver, kidneys, heart, brain and blood in rabbits. In lead treated livers were enlarged with swollen and pale pink to grayish. Gall bladder was distended with increased in bile fluid. Kidneys were also pale and swollen with intended outer surface. Macroscopically myocardial muscle appeared pale.

Kale (2008) studied pathology of experimental lead toxicity in female rats at 100, 200 and 500 ppm levels and observed decrease carcass size with congested mesentery, brain and female genital organs. There was dose

dependent decrease in average weights of liver, lung, heart, spleen, kidney and brain in treatment group rats.

Gongle (2009) And Mesharam (2009) studied pathology of experimental lead toxicity and protective effect of *Plumbago zeylanica* in Japanese quails for a period of four weeks. They observed that lead treated animals livers were congested and showing dark discoloration with comparatively decrease size. Also reported dose dependant decreased in size of liver, lungs, heart, kidneys, brain, testicles, and ovaries.

Suradkar *et al.* (2010) described enlarged, pale and friable liver, kidney shows easy peeling of capsule with no adhesion, marked congestion and mild enlargement with bulged edges. There was congestion and erosion of intestinal mucosa. Lung showed haemorrhages, emphysema and mild to moderate congestion. Spleen were enlarged and congested. Heart shows mild congestion and testes were found atrophied with engorged blood vessels.

Chandra *et al.* (2010) investigated toxicity of lead in wistar rats fed lead acetate @ 100 ppm or 600 ppm. They reported grayish white discoloration of capsular surface and necrotic foci irregularly distributed on the surface of liver. Epicardial and endocardial petechial haemorrhages on heart, patchy congestion with diffuse oedema in lung and metallic sheen on serosal surface of gastrointestinal tract.

### **2.1.5 Histopathological Observations**

#### **(A) Visceral Organs**

Sastry (2000) described that lead is a protoplasmic poison. It is poorly excreted and hence cumulative poison in domestic animals. The important lesions are usually found in the gastrointestinal, hemopoietic and nervous system.

Changes in brain of rat which had received high dose of lead acetate was observed by Kang *et al.* (2004). Brain of rats showed diffuse vacuolar degeneration and increased neurovascularization of the cerebral white

matter and hippocampus.

Rahman (2006) when studied histopathological sections of liver of lead treated birds which revealed congestion, granular degenerative changes and intranuclear inclusion in group receiving 400ppm of lead acetate. Kidney sections revealed tubular nephrosis and glomerular nephritis.

Brahmankar (2008) observed dose dependent degenerative changes in liver, kidney, heart and brain. Testicular changes included severe degenerative changes in seminiferous tubule and absence of spermatogenesis indicating toxic effect of lead on reproductive organ during experimental lead toxicity.

In rabbits, Durgut *et al.* (2008) reported that liver showed severe hydropic and vacuolar degeneration in hepatocytes in the lead acetate treated groups. Hepatocytes were swollen and pyknotic. Sinusoids were filled with erythrocytes and a few mononuclear cell infiltrations in the portal areas. Kidneys showed moderate to severe cytoplasmic vacuolation and degeneration of proximal tubular epithelial cells in cortex and brain revealed neuronal degeneration and necrosis. Neuronophagia and glial cell proliferations were detected in cornu ammonis and severe mononuclear cell infiltrations in Virchow-Robin spaces. Myocardial muscle showed moderate degenerations of myofibrilles.

Kale (2008) reported degenerative changes in liver, lung, heart, kidneys and brain in female rats given lead in drinking water. Liver and kidney section revealed intranuclear inclusion bodies along with degeneration and focal areas of necrosis. Satellitosis, edema and degenerative changes were seen in brain. Uterus revealed thinning of wall with extensive endometrial hyperplasia and lack of uterine development.

The histological changes viz. extensive granular and vacuolar changes in hepatocyte with focal areas of haemorrhage, hyperplasia of bile duct around the centralobular vein has been also reported by Gongale (2009). Kidneys revealed vacuolar and degenerative changes while there was edema in brain and mild degenerative changes in neuron.

In rats Chandra *et al.* (2009) reported fatty changes and at places focal area of coagulative necrosis with infiltration of neutrophils and macrophages in liver. In kidney glomeruli revealed moderate to marked vacuolization along with proliferation and degeneration of parietal layer of epithelium lining the Bowman's capsule. In lungs the alveolar and septal blood vessels were congested with accumulation of edematous fluid in the alveolar lumen. Bronchioles showed proliferation, degeneration and desquamation of lining epithelium. Brain shows extravagation of erythrocytes and perineuronal and perivascular oedema in cerebral cortex. Spleen revealed presence of large numbers of golden yellow colored haemosiderin pigments in red pulp. Esophagus shows marked hyalinization on mucosal surface. Glandular and non-glandular epithelium of mucosa of stomach and intestine showed degeneration with infiltration. Congestion and haemorrhages in lamina propria and hyperplasia of goblet cells were also observed. Testes revealed mild depletion of sertoli cells and spermatogonial cells.

Jabeen *et al.* (2010) studied teratogenic effects of lead acetate on kidney in 24 albino mice. Histopathologically fetal kidney revealed thin cortex. Renal corpuscles showed decreased in diameter and thickening of endothelial basement membrane. In deep cortical area PCT & DCT shows tubular atrophy and degenerative changes of the epithelial cells in lead exposed group.

Suradkar *et al.* (2010) studied patho-morphological changes in tissues of wistar rats by given to lead acetate. They observed hepatocytes with the variable degree of nuclear changes like karyolysis, karyorrhexis and pyknosis, distortion of hepatic chords and areas of diffused vacuolar and granular degeneration in liver. Severe congestion, haemorrhages, degeneration and necrosis of tubular epithelium with pink staining proteinous debris in the lumen and foci of mononuclear cells infiltration in the cortex of kidney. Desquamation and denudation of surface epithelium, erosion, ulceration and necrosis of intestinal villi with diffuse mononuclear cells in mucosa and submucosa in intestine. Congestion, haemorrhages, emphysema and infiltration of monocyte in lung, degeneration and necrosis of the lymphoid cells were observed in spleen. Heart revealed focal area of congestion and haemorrhages in interstitium of cardiac muscle. Testes revealed degeneration and necrosis of seminiferous tubules.

Badiei *et al.* (2009) studied that effect of lead on thyroid function in sheep revealed The function of the thyroid was evaluated by measuring the levels of serum thyroid hormones T3, T4, FT3, FT4 and TSH. The hepatic function in both groups was evaluated by measuring hepatic enzyme activities including alanin amino transferase (ALT), aspartate aminotransferase (AST),  $\gamma$  glutamyl transferase (GGT), and total bilirubin (TBIL) when given lead acetate (5 mg/kg/day)

Ashraf *et al.*(2010) studied effects of cadmium and lead on the structure and function of thyroid gland revealed Blood sera was taken from treated rats recorded decrease in the thyroxine (T4) and the 3, 3, 5-triiodothyronine (T3) levels with a concomitant rise in the Thyroid Stimulator Hormone (TSH) levels. Microscopic examination of the cellular structure of the thyroid glands of treated rats recorded changes in the follicular cells of the thyroid tissues in the rats exposed to Pb.

#### **(B) Reproductive Organs :**

Taupeau *et al.* (2001) studied effect of lead toxicity on ovaries of mice. Ovarian changes included follicular atrecia, causing dysfunction of folliculogenesis, with few primordial follicles and increase in atretic antral follicles.

Tchernitchin *et al.* (2003) evaluated the effect of chronic lead exposure on estrogen action in the prepubertal rat uterus. Eosinophilia, edema in the superficial and deep endometria, luminal epithelial hypertrophy and mitotic response in all uterine cells type were inhibited by lead exposure.

Azarnia *et al.* (2004) observed protective role of L-cystiene against the follicular atresia induced during lead toxicity in mouse ovary. Lead acetate was given at the dose of 10 mg/kg intraperitonially. Changes in ovaries included decrease in number of graffian, growing, atretic, primordial follicles and thickness of granulosa of theca layers. These changes were not observed in groups given treatment with a combination of L-cystiene.

Karaca and Nedjet (2006) studied effects of Spirulina on the number of ovary mast cells in lead induced toxicity in rats. Protective effect of Spirulina against the lead induced increase in mast cells of ovary during estrous cycle of rat was confirmed. Experiment suggested protective effect of spirulina

during lead toxicity induced ovarian changes.

Nampoothiri and Gupta (2006) studied the effects of lead and cadmium on granulosa cells of Foster rats. The results demonstrated that both lead and cadmium caused a significant reduction in gonadotropin binding, which altered steroidogenic enzyme activity of granulosa cells. These changes exhibited a positive correlation with membrane changes of the granulosa cells.

Kale (2008) studied the effects of lead on ovary and uterus of Wistar rats. There was hyperplasia of endometrial and glandular epithelium and few sections showed edema with haemorrhages in endometrium and myometrium in uterus, ovary shows the congestion with scanty developing follicles showing degenerative changes and small size corpus luteum.

Quarda *et al.* (2011) studied influence of sudden cystine supplementation and suppression on adrenal and ovary of lead exposed rat revealed that ovary weight was also significantly decreased and has the same manner as that of total body weight. The ovary histological study after 3 weeks lead treatment has showed a graafian follicular atresia. When augmenting the treatment period, full oocyte degeneration accompanied by a disappearance of corona radiata cells and an apoptosis of granulosa cells.

Ingale (2009) studied the effects of lead on ovary with protective effect of *Plumbago zeylanica*. Ovary In lead treated rats showed detached granulosa cells from basement membrane and pyknosis of nuclei in granulosa cells. Damage to small and medium follicles was also observed in lead treated rats which were not recovered in *Plumbago zeylanica* treated rats.iii

Eugenia *et al.* (2008) reported that lead concentration increasing in Fallopian tubes and uterus Comparatively . ovaries weight and uterus and Fallopian tubes weight decreasing when given lead @ 100 ppm.

Meshram (2009) studied effects of *Plumbago zeylanica* against lead induced toxicity in quails given @ 200ppm. Changes in ovaries in lead induced group birds shows that irregularity in shape and size with degenerative changes in various stages of developing follicles .

Nazera *et al.* (2010) reported that lead induced folliculogenesis in swiss mice when lead acetate administered in two doses 160mg, 320mg/kg/body wt. Lead treated females exhibited abnormal follicle development and reduction in follicle size and number.

Dorostghoal *et al.* (2011) studied long term developmental effects of lactational exposure to lead acetate on ovary in offspring wistar rats. He revealed that ovary weights decreased significantly. There was significant decrease in mean number of corpora lutea in the 100 and 300 mg/L/day dose. Neonatal lead treatment has transient effects on follicular development in the ovary of offspring and ovarian parameters.

## **2.2 Medicinal Properties of *Plumbago zeylanica***

Ayurveda, an ancient system of Indian medicine has recommended number of drugs from plants or formulations from plants for medicinal use. A single plant may be associated with a wide spectrum of activity without any concrete pharmacological basis. A herb as used in a traditional system of medicine is a complex potpourri of compounds, some beneficial, some harmful, some vitamins and some even toxic, but these substances have amalgamated in a fusion where one chemical counter balance the undesirable effects of the other, ultimately to give only a beneficial effect.

Smith (1753) on the basis of the classification of plants mentioned that the latin *Plumbago* word indicates a lead like ore alluding to its historical use as cure for lead poisoning.

Bopaich and Pradhan (1999) studied central nervous system stimulatory action from the root extract of *Plumbago zeylanica* in rats and reported that the effects of 50 per cent ethanol extract of the root of *Plumbago zeylanica* on locomotor behaviour and central dopaminergic activity in rats. The effects on the ambulatory behaviour were assessed along with the levels of dopamine.

Kini *et al.* (1997) examined pregnant albino rats given plumagin on the 20<sup>th</sup> day of gestation and reported that the ovaries of the treated group were

clear showing inhibition of growth of graffian follicles, degeneration of the mature follicles and corpus luteum. According to the authors, the antifertility action of plumbagin seemed to be related to its antiovolatory action.

Dai *et al.* (2004) studied the antiallergic properties of 70 per cent ethanol extract from *Plumbago zeylanica* which inhibits mast cell dependant intermediate allergic reaction mediated by reducing release of histamine mediator from mast cell.

Tilak *et al.* (2004) reported that *Plumbago zeylanica* is useful Indian medicinal plant of which roots and its constituents has potential therapeutic properties including anti-atherogenic, cardiogenic, hepatoprotective and neuroprotective properties.

Sivakumar *et al.* (2005) reported that GST activity was significantly inhibited by higher doses of plumbagin (8 mg and 16 mg/kg b.w.) and cyclophosphamide in the study of in vivo micronucleus assay and GST activity in assessing genotoxicity of plumbagin in Swiss albino mice.

Chetty *et al.* (2006) described useful pharmaceutical and therapeutic uses of *Plumbago zeylanica* include diarrhoea, dysentery, abdominal disorders, peptic ulcers, piles, improving appetite, reduce hypercholestermia, improving blood formation during anemia.

Mungwini (2006) reported that the *Plumbago zeylanica* is very popular throughout Africa and Asia as a remedy for skin diseases, infections and intestinal worms especially leprosy, scabies, ulcers of leg, haemorrhoids and hookworms. Root is considered to have highest activity. In Ethiopia powdered bark, root or leaves are used to treat gonorrhoea, syphilis, tuberculosis, rheumatic pain, swellings and wounds.

Sivakumar and Niranjali (2006) reported that pretreatment with alcoholic root extract of *Plumbago zeylanica* (250 and 500 mg/kg b. wt. orally for 5 days) significantly reduced the frequency of micronucleated polychromatic erythrocytes, increase the normochromatic erythrocytes ratio in bone marrow and decrease level of lipid peroxidation products.

Aquil *et al.* (2008) studied the antimutagenic activity of methanolic extracts of four ayurvedic medicinal plants including *Plumbago zeylanica*.

Zambare and Bhole (2008) studied *in vivo* antioxidant activity of *Plumbago zeylanica* and reported antioxidant activity, total phenolic content and water extract of roots of plant *Plumbago zeylanica*.

Maniafu *et al.* (2009) investigate Larvicidal activity of extracts from three *Plumbago* spp against *Anopheles gambiae* .

Jeyachandran *et al.* (2009) reported antibacterial activity of plumbagin and root extracts Of *plumbago zeylanica*. Plumbagin and chloroform extracts of *Plumbago zeylanica*L. root showed antibacterial activity against *Escherichia coli*, *Salmonella typhi* and *Staphylococcus aureus*..

Rajesh Kumar *et al.* (2009) studies hepatoprotective activity of aerial parts of *Plumbago zeylanica* linn.against carbon tetrachloride induced hepatotoxicity in rats.The extract of aerial part of *Plumbago zeylanica* have shown very significant hepatoprotection against CCl<sub>4</sub> induced hepatotoxicity in wistar rats by reducing serum total bilirubin SGPT, SGOT and ALP levels. Histopathological studies also confirmed the hepatoprotective nature of extract. The therapeutic dose for accessing hepatoprotective activity of methanolic extract were 35 and 70 mg /kg/day orally.

Vijay Kumar *et al.* (2009) investigate and antioxidant property of *Plumbago zeylanica* in discreet region of rat brain, antioxidant status was assessed by measuring the lipid peroxidation (LPO), enzymatic antioxidant status (superoxide dismutase (SOD), catalase(CAT), and glutathione peroxidase (GPx) in the discreet region of rat brain (Cerebral cortex, Cerebellum, Midbrain, Ponsmedulla, Hippocampus and Hypothalamus). Thus they reported antioxidant property of *P. zeylanica*.

Zahin *et al.* (2009) studied the *in vitro* antioxidant activity and total phenolic content of root extract of plant *Plumbago zeylanica*.

Adejumo *et al.* ( 2010) studied In vitro antisickling activities and phytochemical evaluation of *Plumbago zeylanica* and *Uvaria chamae*. Phytochemical screening of the investigated plant specimens revealed the presence of flavonoids, saponnins, alkaloids, tannins, cardiac glycosides free and combined anthraquinones.

Kantha *et al.* (2010) observed anti-inflammatory and cytotoxic effects of extract from *plumbago zeylanica*. The root of *P. zeylanica* extracted

with methanol was used for determining the anti inflammatory effects. The use of *Plumbago* species as an effective anti inflammatory agent and its cytotoxic effects have been ascertained and proved.

Vishanukant & Rana (2010) observed anticonvulsant activity of *plumbago zeylanica* Linn leaf extract in albino wistar rats of either sex weighing between 150-200 g.

Zarmouh *et al.* (2010) studied effect of *Plumbago zeylanica* root extract on blood glucose and hepatic enzymes in experimental diabetic rats. The *Plumbago zeylanica* root extract is hypoglycemic, hepatoprotective and is able to ameliorate biochemical damages in Streptozotocin induced diabetic rats.

Ariyanathan *et al.* (2011) studied Capensisonone, isoshinanolone, diomuscinone,  $\alpha$ -amyirin acetate, plumbagin,  $\alpha$ -amyirin,  $\beta$ -sitosterol and  $\beta$ -sitosterol-3 $\beta$ -D- glucoside have been isolated from the methanol extract of the roots of *Plumbago capensis*. Capensisonone, a novel quinone is the first report from the roots of *Plumbago capensis*. The structure of these compounds has been established on the basis of FT- IR, <sup>1</sup>H NMR, and <sup>13</sup>C NMR spectral data.

Dhale *et al.* (2011) studied antimicrobial and phytochemical screening of *Plumbago zeylanica* linn. (plumbaginaceae) leaf. The samples of leaves of *Plumbago zeylanica* were used for the phytochemical studies. Results of the phytochemical analysis indicated the presence of alkaloids, glycoside, reducing sugars, simple phenolics, tannins, Lignin, saponins and flavonoids. The antibacterial activities of the leaves were due to the presence of various secondary metabolites.

Sathis Kumar *et al.* (2011) did medicinal plants survey for treatment of obesity. He observed that Ethanolic extract (50% v/v) of root of *Plumbago zeylanica*, alone and in combination with vitamin E, significantly reduced serum total cholesterol, LDL cholesterol and TG levels.

### 2.3 *Plumbago zeylanica* In Lead Toxicity

Ingle (2008) studied effect of *Plumbago zeylanica* given at the dose rate of 50mg/Kg and 100mg/Kg during experimental lead toxicity @ 750 ppm in rats. He found that lead treated group showed significant decrease in Hb ( $9.46 \pm 0.19$ ), TEC ( $6.67 \pm 0.03$ ) and PCV ( $35 \pm 4.37$ ) which are improves in *P. zeylanica* group rats Hb ( $10.93 \pm 0.25$ ), TEC ( $7.23 \pm 0.35$ ) and PCV ( $45.83 \pm 2.00$ ). In biochemical parameter the values of AST ( $235.61 \pm 15.10$ ), ALT ( $64.45 \pm 6.19$ ), ALP ( $236.40 \pm 5.79$ ), creatinine ( $0.78 \pm 0.03$ ) and calcium ( $7.64 \pm 0.29$ ) increase in lead treated group which are improves in *P. zeylanica* group animals AST ( $209.29 \pm 9.91$ ), ALT ( $53.11 \pm 2.66$ ), ALP ( $193.20 \pm 3.72$ ), creatinine ( $0.06 \pm 0.07$ ) and calcium ( $8.61 \pm 0.45$ ) respectively. Histopathological study revealed degenerative changes in liver, lung and brain in a group which received lead acetate @ 750 ppm which are improved histopathologically in *P. zeylanica* @ 100 mg /kg b.wt. given group, whereas no protective effect was observed in case of kidney, ovary, testis and uterus.

Meshram (2009) studied toxic effect of lead @ 200 ppm and protective effect dry root powder of *Plumbago zeylanica* at 5%, 10% and 15% in quails feed. There was decrease in feed consumption and weekly body weight in lead treated birds and the bird treated with lead and *P. zeylanica* @ 15 % level. Addition of *P. zeylanica* along with lead improved the Hb, PCV, TEC, TLC count and decrease in absolute heterophil count as compare to the group given only lead acetate, indicating beneficial effect of *Plumbago zeylanica* during lead toxicity. The group given *P. zeylanica* @ 15% level showed comparatively normal hepatic parenchyma, lung parenchyma and decreased degenerative changes in heart compared with other treatment group. However *P. zeylanica* failure to protect lead induced degenerative changes of kidney and testis. Similar result were also found by Gongle (2009) who gave lead at 300 ppm and +@ 5%, 10% and 15% level in Japanese quails.



Chapter - III

**Materials and  
Methods**



## CHAPTER – III

### MATERIALS AND METHODS

The present investigations entitled “Pathology of experimental lead toxicity and effect of *Plumbago zeylanica* in female rats (*Rattus norvegicus*) with special reference to reproductive organs” were undertaken in the Department of Pathology, Post Graduate Institute of Veterinary and Animal Sciences, Akola.

The study has been conducted to evaluate the sub chronic lead toxicity in adult nonpregnant female rats with special emphasis on changes in ovaries and uterus. Details regarding the experiment conducted are as follows.

#### **3.1.1. Experimental Animals**

Experimental protocol was approved by the Institutional Animal Ethical Committee (IAEC) & met the national guidelines of Committee for the Purpose of Control and Supervision of Experiments on Animals (CPCSEA), Ministry of Social Justice and Empowerment, Government of India. For the present studies twenty-four nonpregnant female Albino Wistar rats, were procured from Shree Farm Bhandara, a recognized Laboratory Animal Breeding Center.

#### **3.1.2. Housing**

All the experimental animals were kept under standard managerial conditions as per the norms of CPCSEA, in laboratory animal house of Department of Pharmacology and Toxicology, PGIVAS , Akola. Polypropylene cages (47x34x18 cm) with rice husk as a bedding material were used for maintenance of experimental animals. Four animals were kept in single cage with 12hrs light & 12hrs dark periods.

#### **3.1.3. Feeding**

The animals were given standard pellet diet, procured from Swastik Agro Industries Ltd, Maharashtra. Pellet diet consisted of 22.02% crude protein, 4.25% crude oil, 3.02% crude fibre, 7.5% ash and 1.38% sand silica. All the experimental groups were given *ad lib* feed and wholesome drinking water



Plate 1 : *Plumbago zeylanica* plant grown in Nagarjuna Vanaoushadhi Udyan Dr. PDKV, Akola.



Plate 2 : Dry root powder of *Plumbago zeylanica*.



Plate 3 : Cold ethanolic extract of *Plumbago zeylanica* of dry root powder.

throughout the experimental period of 28 days.

#### **3.1.4. Bedding Material**

Dried and autoclaved rice husk was used as a bedding material and was replaced on every alternate day.

#### **3.1.5. Anesthesia / Euthanasia**

On completion of experiment i.e. on 28<sup>th</sup> day all the rats were anesthetized with chloroform inhalation and blood was collected for hematology and biochemical estimations and finally the rats were given euthanasia.

#### **3.1.6 Plant material :**

Alcoholic root extract of *Plumbago zeylanica* was prepared and used as herbal medicine.

#### **3.1.7 Preparation of Alcoholic Extract :**

Root powder of *Plumbago zeylanica* was procured from authenticated Ayurvedic supplier and subjected to cold ethanolic extract as per procedure described below.

The powder was immersed in hydro alcoholic solvent (40% distilled water + 60% ethanol) in a flask stoppered tightly with cotton plug and kept at room temperature for 48 hours at 150 rpm in on orbital shaker. The content of the flask was filtered through the muslin cloth. The residue left in the flask was rinsed using little quantity of solvent which was again filtered through the muslin cloth. The filtrate thus obtained was filtered through Whatman filter paper No. 1 and content was transferred to previously weighed large Petri dish and kept in the hot air oven at 40<sup>o</sup>C for evaporation of solvent. After complete evaporation of solvent, the petri dish was once again weighed to know the amount of extract and percent extractability. The extract thus obtained was stored in air tight screw cap vials in the dessicator until its use for further studies. (Plate-3)

#### **3.1.8 Details of Experiment**

Twenty-four non pregnant adult female rats of 6-7 week age were

procured from the recognized laboratory animal breeding center. Animals were randomly divided in four groups, each group thus comprising six rats.

Group I animals (T<sub>1</sub>) served as control whereas group II, and IV rats (i.e. T<sub>2</sub>, and T<sub>4</sub>) were given 500ppm lead acetate (C<sub>4</sub>H<sub>6</sub>Pb<sub>3</sub>H<sub>2</sub>O ; 397.33) (Hi-Media Laboratories Pvt. Ltd. Mumbai) in drinking water. Group III (T<sub>3</sub>) & IV (T<sub>4</sub>) were given ethanolic extract of dry root powder of *Plumbago zeylanica* @ 100mg/Kg body wt. per day orally to evaluate utility of *Plumbago zeylanica* (Plate 1) during experimental lead toxicity for a period of 28 days as follow.

Details regarding the group and treatment are given in table

#### Experimental schedule.

Sr. No.	Group	No of Rats	Treatments	Period
1	Group I (T <sub>1</sub> )	6	Ad-lib feed + normal drinking water	28 Day
2	Group II (T <sub>2</sub> )	6	Ad-lib feed + 500ppm lead acetate in drinking water.	28 Day
3	Group III (T <sub>3</sub> )	6	Ad-lib feed + <i>Plumbago zeylanica</i> (root extract) @ 100mg/kg orally	28 Day
4	Group IV (T <sub>4</sub> )	6	Ad-lib feed + 500ppm lead acetate in drinking water. + <i>Plumbago zeylanica</i> (root extract) 100mg/kg orally.	28 Day

All animals were acclimatized for a period of one week to the new environment prior to the start of the experiment followed by respective treatments for four weeks.

Observations in respect of following parameters were recorded during experimental period of 28 days.

#### 3.2 – Clinical Observations

#### 3.3 – General performance

#### 3.4 – Hematological Observations

#### 3.5– Biochemical Observations



Plate 4 : Control group rats ( $T_1$ ).



Plate 5 : Group II rats given 500 ppm lead acetate ( $T_2$ ).



Plate 6 : Group III rats given 100 mg/kg body weight ethanolic extract of *Plumbago zeylanica* ( $T_3$ ).




Plate 7: Group IV rats given 500 ppm lead acetate + 100 mg/kg body weight ethanolic extract of *Plumbago zeylanica* ( $T_4$ ).



Plate 8 : Weighing machine used for weekly body weight.




Plate 9 : Variation in growth of different group animals.

### **3.6 – Radiological Investigations**

### **3.7 – Gross Pathological Observations**

### **3.8 – Histopathological Investigations**

#### **3.2 Clinical Observations:**

Rats of each group were kept under observation for any clinical symptoms for said period of experiment i.e. upto 4 weeks period from the start of experiment. Mortality if any was recorded.

#### **3.3 General Performance:**

Effect of lead toxicity on general performance of rats was judged using following parameters.

##### **3.3.1 Feed Consumption:**

Average weekly feed consumption was recorded for each group during the experimental period of four weeks.

##### **3.3.2 Water consumption:**

After the start of experiment water consumption in each group were recorded weekly up to 4<sup>th</sup> week of experiment to evaluate effect of lead acetate on water consumption.

##### **3.3.3 Average Weekly Body Weights:**

A weekly body weight for each group was recorded up to 28<sup>th</sup> day to evaluate effect of lead acetate on weekly body weights.

#### **3.4 Hematological Observations:**

For hematological parameters blood samples were collected from each group at the end of experiment (on 28<sup>th</sup> day of experiment). Blood was collected by retro bulbar method in glass vials containing heparin as anticoagulant for hematological studies. Hematological parameters included Hemoglobin (Hb), Packed cell volume (PCV), Total Erythrocyte count (TEC), Mean Corpuscle Volume (MCV), Mean Corpuscle Hemoglobin (MCH), Mean Corpuscle Hemoglobin Concentration (MCHC), Total Leucocyte Count (TLC) and Differential Leucocyte Count (DLC).

### **3.4.1 Hemoglobin (Hb-gm/dl):**

Hemoglobin (Hb) was estimated by Sahli's hemocytometer as per the standard method described by Benjamin (2001) and values were expressed in gm/dl. Average values for each group were calculated.

### **3.4.2 Packed Cell Volume (PCV %):**

Packed Cell Volume (PCV) was estimated using Wintrob hematocrit tubes as per standard method described by Pierson (2000).

### **3.4.3 Total Erythrocyte Count (TEC × 10<sup>6</sup> cu mm) :**

Total Erythrocyte Count (TEC) was estimated by using standard blood diluting pipette and using RBC diluting fluid as per method described by (Benjamin 2001) and values were expressed in 10<sup>6</sup>/cu mm.

### **3.4.4 Micro Hematocrit Values:**

Mean corpuscular volume (MCV) Mean Corpuscular Hemoglobin (MCH) and Mean Corpuscular Hemoglobin Concentration (MCHC) were derived as per standard method mentioned by Benjamin, (2001) as follows.

#### **3.4.4.1 Mean Corpuscular Volume (Femtoliter) :**

Mean Corpuscular Volume (MCV) was calculated by using following formula.

$$\text{MCV (fl)} = \frac{\text{PCV (\%)} \times 10}{\text{RBC counts in million / cumm}}$$

#### **3.4.4.2 Mean Corpuscular Hemoglobin (Picogram):**

Mean Corpuscular Hemoglobin (MCH) was calculated by using following formula.

$$\text{MCH (pg)} = \frac{\text{Hb ( gm/dl )} \times 10}{\text{RBC counts in million / cumm}}$$

#### **3.4.4.3 Mean Corpuscular Hemoglobin Concentration (gm/dl):**

Mean Corpuscular Hemoglobin concentration (gm/dl) was calculated by using following formula.

$$\text{MCHC (gm/dl)} = \frac{\text{Hb (gm/dl)} \times 100}{\text{PCV in \%}}$$

#### **3.4.5 Total Leucocytes Count (TLC × 10<sup>3</sup>/cumm)**

Total Leucocytes Count was carried out with improved Neubaure's chamber and using WBC diluting fluid and standard WBC diluting pipette as per method described by (Benjamin 2001).

#### **3.4.6. Differential Leucocytes Count (DLC):**

Differential Leucocytes Count (DLC) was carried out as per standard method by using Leishman's stain and examination of smear under oil immersion. A total of 100 leucocytes were counted and the absolute values of leucocytes were calculated to evaluate leucocytosis / leucopenia (Benjamin, 2001).

### **3.5 Biochemical Observations:**

Plasma samples from same six animals of each group were collected at the end of 28th day. Blood samples collected in heparinized tubes were centrifuged at 2500 rpm for 15 min and plasma was separated and stored at - 20<sup>o</sup> C for analysis. Biochemical parameters included estimation of Total Protein, Albumin, Globulin, Calcium, Phosphorous, SGPT, SGOT, Creatinine and Total Cholesterol using Auto Span Diagnostic Kits supplied by Span Diagnostic Ltd. (Surat).

#### **3.5.1 Plasma Calcium (mg/dl):**

Plasma calcium levels in each group were estimated by O.C.P.C. method (Morin, 1974).

### **3.5.2 Plasma Phosphorus(mg/dl):**

Plasma phosphorus levels in each group were estimated by UV molybdate method (Munoz, 1983).

### **3.5.3 Plasma Creatinine (mg/dl):**

Plasma creatinine values were estimated by modified Jaffe's Reaction (Kaplan and Lavernel, 1983).

### **3.5.4 Plasma Aspartate aminotransferase (IU/L):**

Plasma SGOT / AST values were estimated by modified UV (IFCC), Kinetic assay (Schumann, 2002)

### **3.5.5 Plasma Alanine aminotransferase (ALT) (IU/L):**

Plasma SGPT / ALT values were estimated by modified UV (IFCC), Kinetic assay (Schumann, 2002)

### **3.5.6 Plasma Glucose ((mg/dl)-:**

Plasma glucose values were estimated by Enzymatic GOD and POD Method (Titez, 1976).

### **3.5.7 Plasma Total Protein (gm/dl):**

Plasma total protein levels in each group were estimated by modified Buret and Doumas method (Vatzidis, 1977).

## **3.6 Radiological Investigations:**

At the end of 28<sup>th</sup> day of experiment randomly two rats from each group were subjected to radiological examination at Ghadge X-ray Clinic, Akola to evaluate effect of lead toxicity on skeleton. (i.e. bone)

## **3.7 Gross Pathological Examination:**

Six rats from each group were sacrificed on 28<sup>th</sup> day to study gross pathological changes in various visceral organs. During necropsy, lesions observed in various organs i.e. liver, lung, heart, kidney, spleen, brain, uterus and ovary were recorded.

### **3.7.1 Organ Weight:**

After gross pathological examination the visceral organs with ovary and uterus were separated carefully for recording their weights, to evaluate effect of lead acetate on average organ weights.

### **3.8 Histopathological Changes / Observations:**

Tissue of liver, lung, heart, kidney, spleen, brain, ovary and uterus were collected in 10 % neutral buffer formal saline solution for histopathological examination. Tissues were processed by using acetone and benzene method followed by impregnation in paraffin wax (Hi-Media, Mumbai). Sections of 4-6 microns were cut and stained with routine Haematoxyline and Eosin (H & E) stain as per the method described by Luna (1968).



Chapter - IV

***Results and  
Discussion***



## CHAPTER – IV

### RESULT AND DISCUSSION

Present study on “Pathology of experimental lead toxicity and effect of *Plumbago zeylanica* in female rats (*Rattus norvegicus*) with special reference to reproductive organs” was conducted in the Department of Veterinary Pathology Postgraduate Institute of Veterinary and Animal sciences, Akola for a period of 28 days. ( i.e. 4 weeks period)

Twenty Four adult non pregnant female Wistar rats (6-7 weeks age) were procured from the recognized Laboratory Animal Breeding Center Shree Farm, Bhandara. Rats were acclimatized to the new environment for a period of one week before to start the experiment. These female rats were randomly divided in four groups, each group thus comprising of six animals. Group I animals (T1) served as control whereas group II, and IV rats (i.e. T2, and T4) were given 500ppm lead acetate( $C_4H_6Pb_3 H_2O$  ; 397.33) (Hi-Media Laboratories Pvt. Ltd. Mumbai) in drinking water . Group T<sub>3</sub>, T<sub>4</sub>, were given ethanolic extract of dry root powder of *Plumbago zeylanica* at 100mg/Kg body wt. orally for the period of 4 weeks (i.e. 28 days). The findings of present studies were recorded and discussed as follows.

#### 4.1 Clinical Observations:

All the control and treatment group rats were kept under observation for a period of 4 weeks of experiment for clinical symptoms.

During period of acclimatization of one week all animals appeared healthy and did not reveal any discomfort suggesting proper acclimatization to the new environment.

T<sub>1</sub> group animals were given adlib feed and plain drinking water and served as control group. Rats of T<sub>2</sub> & T<sub>4</sub> groups were given lead acetate in drinking water at dose 500ppm levels. Group T<sub>3</sub> and T<sub>4</sub> were given ethanolic extract of dry root powder of *Plumbago zeylanica* at 100mg/Kg body wt. orally.

During the first week of the experiment control and treatment group animals did not reveal any clinical symptoms and appeared normal.

At the end of 3<sup>rd</sup> week, T<sub>2</sub> and T<sub>4</sub> group rats given lead acetate variable symptoms of weakness, lethargy, pale mucous membrane, respiratory distress, palmer grasping and aimlessly biting to cages, climbing on each other in the cages, nervousness and ruffled fur coat with unhealthy look as compared to control group animals. However mortality was not observed in any group.

Similarly T<sub>2</sub> group rats revealed dark brown colour feces along with foul smell indicating digestive disturbance while T<sub>4</sub> group rats given *P. zeylanica* along with lead acetate however showed light in dark brown colour feces . Thus observations of clinical symptoms indicated protective effect of *P. zeylanica* on intestinal wall during lead toxicity.

Similar symptoms of weakness, lethargy, pale mucous membrane, respiratory distress and extreme nervousness have been reported by Suradkar *et al.* (2009) and Chandra *et al.*(2010) in rats.

Present finding of digestive disorder also corroborates with those reported by Bramhankar (2008) in rats . Ghule (2007) reported liquid faeces and soiled vent during lead toxicity due to diarrhea in quails.

Tilak *et al.* (2004) described useful properties of *P. zeylanica* in diseases of digestive system i.e. diarrhea. It is thus observed that *Plumbago zeylanica* may be useful during digestive disturbances. Huxely (1992) and Lledo (1998) reported useful properties of *P. zeylanica* during lead toxicity.

## **4.2 General Performance:**

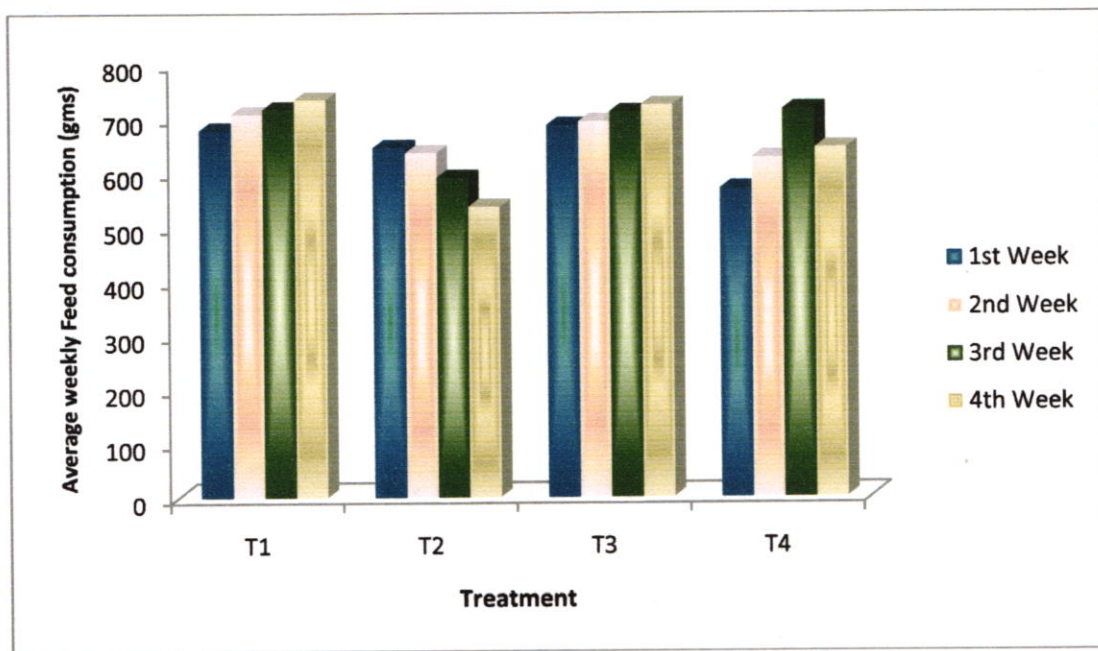
During present study general performance was evaluated on the basis of feed consumption, water consumption, average weekly body weights and average weekly body weight gain in each group up to four week (28 days) of experimental period.

### **4.2.1 Average Weekly Feed Consumption (gms):**

Average weekly feed consumption in rats up to 4 weeks of experimental period was calculated for each group and details are given in Table1 and Fig-1.

**Table 1: Average Weekly Feed Consumption (gms) in different groups.**

<b>Groups</b>	<b>Weeks</b>				<b>Average feed Consumption</b>
	<b>1<sup>st</sup> Week</b>	<b>2<sup>nd</sup> Week</b>	<b>3<sup>rd</sup> Week</b>	<b>4<sup>th</sup> Week</b>	
<b>T1</b>	677.25	707.12	716.0	733.89	708.56
<b>T2</b>	644.84	634.74	588.79	535.19	600.89
<b>T3</b>	685.89	692.82	711.00	724.05	703.44
<b>T4</b>	568.90	625.72	716.12	644.17	638.73



**Fig. 1 : Average Weekly Feed Consumption (gms) in different groups**

Average feed consumption in control and different treatment groups were found to be 708.56 in T<sub>1</sub>, 600.89 in T<sub>2</sub>, 703.44 in T<sub>3</sub> and 638.73 in T<sub>4</sub> respectively. The minimum feed intake was observed in T<sub>2</sub> group receiving lead acetate without *Plumbago zeylanica* while the improved feed consumption was recorded in T<sub>4</sub> group rats given lead acetate with *Plumbago zeylanica*.

Present findings of decrease in feed consumption during lead toxicity corroborates with those reported by Erdogan *et al.* (2005) and Rahman (2009) mentioning decrease in feed intake in lead treated group due to altered set point for feed consumption or decreased appetite.

The lower feed consumption could be possibly due to direct adverse effect of lead on gastrointestinal tract or adverse effect on central nervous system as reported by Kale (2008) in female rats.

Improvement in average feed intake in T<sub>4</sub> group rats indicated beneficial effects of *P. zeylanica* when compared with rats receiving lead without *P. zeylanica*.

*Plumbago zeylanica* improves appetite, helps in digestion and cure various digestive problems also reported by Tilak *et al.* (2004).

#### **4.2.2 Average weekly water consumption (mls):**

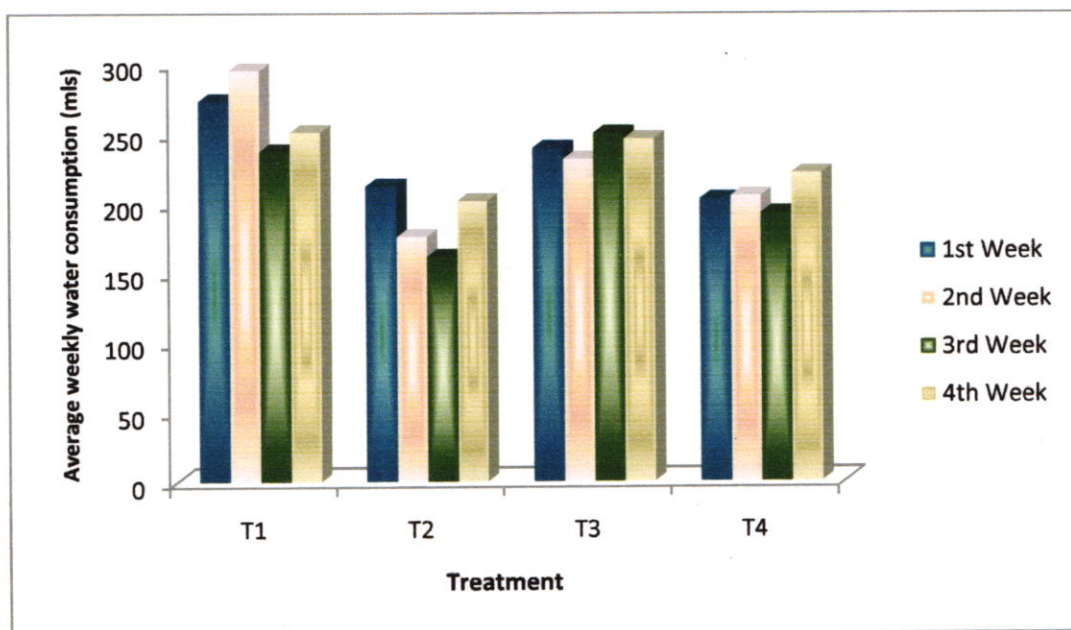
Average water consumption in rats up to 4 weeks period was calculated for each group and is mentioned in (Table 2 and Fig-2)

During present experimental period water consumption was recorded up to the end 4<sup>th</sup> week of experiment. At the end of 4<sup>th</sup> week of experiment average water consumption was found to be in 263.96 T<sub>1</sub>, in 187.67 T<sub>2</sub>, in 241.67 T<sub>3</sub>, and in 205.52 T<sub>4</sub> group. The lowest water intake was observed in group T<sub>2</sub> group rats receiving 500ppm lead acetate in water and highest water intake was recorded in T<sub>1</sub> i.e. control group while the improved water consumption was recorded in T<sub>4</sub> group rats given lead acetate with *Plumbago zeylanica*.

Lower water consumption was observed in T<sub>2</sub> group animals, could be possibly due to less water requirement as result of lower feed

**Table 2: Average Weekly water Consumption (mls) in different groups.**

Groups	Weeks				Average water Consumption
	1 <sup>st</sup>	2 <sup>nd</sup>	3 <sup>rd</sup>	4 <sup>th</sup>	
T1	273.00	295.00	237.00	250.70	263.96
T2	212.14	175.71	161.42	201.40	187.67
T3	239.28	231.42	250.00	246.00	241.675
T4	202.85	205.00	192.85	221.40	205.52



**Fig. 2: Average Weekly Water Consumption (mls) in different groups.**

consumption or may be due to digestive disturbances. Similar significant decrease in water consumption during the lead toxicity is reported by Kale (2008) in female rats & Bramhankar (2008) male in rats.

Improvement in average water intake in T<sub>4</sub> group as compare to T<sub>2</sub> group rats indicated beneficial effects of *P. zeylanica* as reported by Tilak *et al.* (2004) inspite of presence of lead in water in this group.

#### **4.2.3 Average Weekly Body Weight (gms):**

Average weekly body weights indifferent groups were found to be comparable in all treatment and control group before the start of experiment (Table 3 and Fig-3)

In 1<sup>st</sup> week when compared with control group average body weight in T<sub>2</sub> and T<sub>4</sub> group rats were found comparable whereas after 2<sup>nd</sup> week onwards treatment group animals revealed significant decrease in weekly average body weights.

Pooled mean average body weights at the end of experiment were found to be 209.14 ± 7.22 in T<sub>1</sub>, 189.88 ± 1.52 in T<sub>2</sub>, 209.42 ± 7.35 in T<sub>3</sub>, 199.15 ± 3.99 in T<sub>4</sub> group respectively. The lowest average body weight was observed in T<sub>2</sub> group (189.88 ± 1.52) and highst average was observed in T<sub>1</sub> and T<sub>3</sub> group rats given *P. zeylanica* indicating useful properties of *P zeylanica* .

The lowest average mean body weight in T<sub>2</sub> group rats indicated toxic effect of lead on body weight possibly due to lower feed intake or gastrointestinal disturbances. Present findings corroborates with Chandra *et al* (2010) and Dalia *et al.* (2011) in rats.

Ghule (2007) described the cause to be direct effect of lead on central nervous system adversely affecting nutrient absorbtion during experimental studies in quails.

Tilak *et al.* (2004) described the medicinal properties of *P. zeylanica* during various digestive problems and hepatic disorders causing improvement in appetite which is in agreement of present findings as evident from significant increase in body weight of T<sub>4</sub> group rats when compared with T<sub>2</sub> group rats given lead.

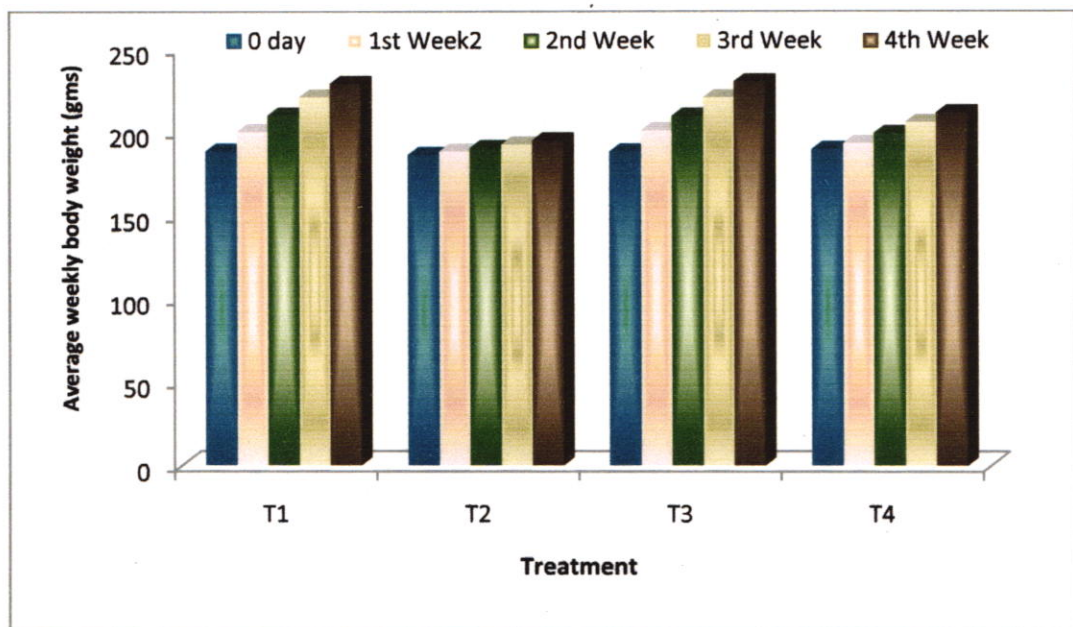
**Table 3: Average Weekly Body Weights (gms) per rat in different groups.**

Group	Age in Weeks					Pooled Mean
	0 <sup>day</sup>	1 <sup>st</sup>	2 <sup>nd</sup>	3 <sup>rd</sup>	4 <sup>th</sup>	
T1	187.88 ± 1.57	199.50 ± 1.43	209.50 ± 1.62	220.33 ± 1.92	228.50 ± 2.43	209.14 <sup>a</sup> ± 7.22
T2	185.63 ± 2.82	187.75 ± 2.86	189.83 ± 2.89	191.87 ± 2.93	194.33 ± 2.91	189.88 <sup>b</sup> ± 1.52
T3	187.62 ± 2.63	200.16 ± 2.35	209.00 ± 3.79	220.00 ± 4.25	229.66 ± 4.14	209.42 <sup>a</sup> ± 7.35
T4	188.94 ± 2.69	192.48 ± 2.93	198.50 ± 3.13	205.00 ± 3.37	210.83 ± 3.11	199.15 <sup>c</sup> ± 3.99
<b>Pooled Mean</b>	187.52 ± 0.68	194.97 <sup>b</sup> ± 2.96	201.87 <sup>c</sup> ± 4.78	209.30 <sup>d</sup> ± 6.82	215.83 <sup>e</sup> ± 8.36	

Mean values with common alphabet as superscript do not differ significantly

CD for treatment = 3.56 (Significant at 1% and 5% level)

CD for week = 3.98 (Significant at 1% and 5% level)



**Fig. 3: Average Weekly Body Weight (gms) per rat in different groups.**

#### **4.2.4 Average weekly body weight gain**

Average weekly body weight gain from 1<sup>st</sup> to 4<sup>th</sup> week age in control and treatment group rats is depicted in Table 4 and Fig. 4.

Differences between average body weight gain per rats in different groups did not reveal significant differences. Pooled mean values of weight gain in T<sub>1</sub>, T<sub>2</sub>, T<sub>3</sub>, and T<sub>4</sub> groups was found to be  $10.15 \pm 0.74$ ,  $02.17 \pm 0.09$ ,  $10.51 \pm 0.70$ , and  $5.47 \pm 0.66$ . Thus indicating toxic effect of lead as evident from lower average values in T<sub>2</sub> group.

However pooled mean of average weekly weight gain was found to be increase in T<sub>4</sub> groups indicating better feed consumption, when compared with the value of T<sub>2</sub> group. Values were comparable in T<sub>1</sub> and T<sub>3</sub> group suggesting non toxic effect of *P. zeylanica* in rats @ 100 mg/ kg body wt.

Similar finding of decrease average weekly body weight gain in broilers during lead toxicity is reported by, Rahman (2006), Deshmukh (2006) and in quails by Ghule (2007), Gongale (2009), and Mesharam (2009).

Body weight gain is usually associated with feed intake. The increase in average weekly weight gain in T<sub>4</sub> groups when compared with T<sub>2</sub> group indicated beneficial effects of *Plumbago zeylanica* during lead toxicity.

Present findings corroborate with those reported by Tilak *et al.* (2004) and Chetty *et al.* (2006) describing beneficial properties of *Plumbago zeylanica* for improving appetite, digestion and cure for various digestive problems.

#### **4.3 Hematological Observations:**

Hematological observations during present study included estimation of Hemoglobin (Hb), Pack cell volume (PCV), Total Erythrocyte Count (TEC), Mean Corpuscular Hemoglobin (MCH), Mean Corpuscular Hemoglobin Concentration (MCHC), Mean Corpuscular Volume (MCV), Total Leucocytes Count (TLC) and Differential Leucocytes Count (DLC) at the end of 4<sup>th</sup> week of experiment to evaluate functional status of hemopoietic system and leucopoietic system during lead toxicity.

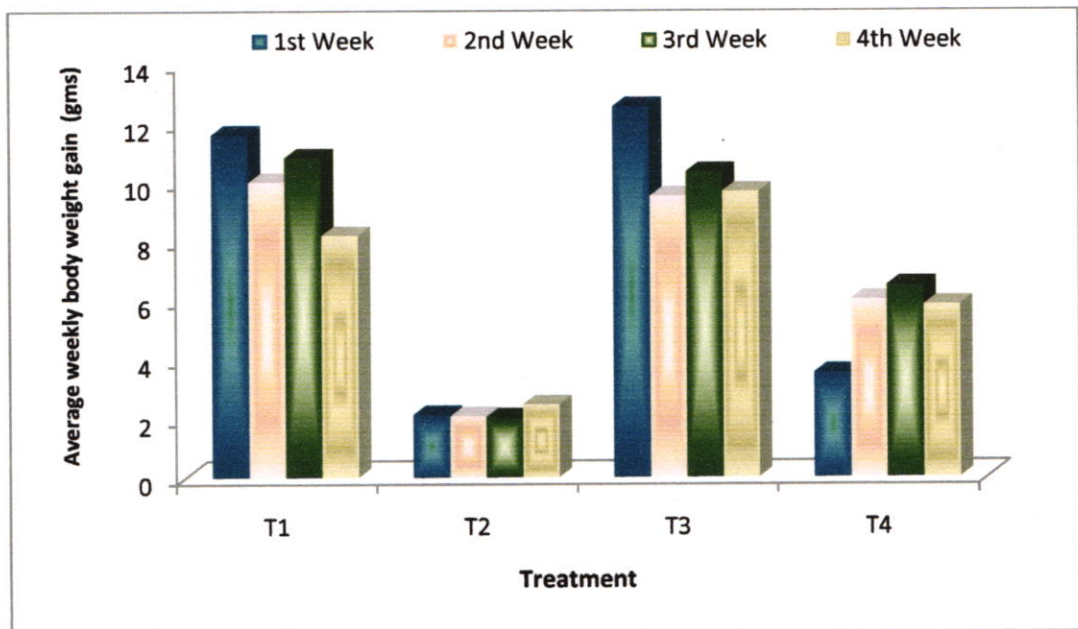
**Table 4. Average weekly body weight gain (gm ) per rat in different groups.**

Group	Period of experiment				
	1 <sup>st</sup>	2 <sup>nd</sup>	3 <sup>rd</sup>	4 <sup>th</sup>	Pooled mean for treatment
T <sub>1</sub>	11.61 ±0.51	10.00 ± 0.51	10.83 ± 0.47	08.19 ±1.07	10.15 ±0.74
T <sub>2</sub>	02.12 ± 0.32	02.07 ± 0.26	02.03 ± 0.47	02.46 ± 0.37	02.17 ± 0.098
T <sub>3</sub>	12.54 ± 0.83	09.50 ± 1.94	10.33 ± 1.54	09.66 ± 0.66	10.51 ± 0.70
T <sub>4</sub>	03.53 ± 0.55	06.01 ± 0.35	06.50 ± 0.34	05.83 ± 0.30	05.47 ± 0.66
Pooled Mean for weeks	7.45 ±2.69	6.89 ±1.83	07.42 ±2.04	06.53 ±1.56	

Mean values with common alphabet as superscript do not differ significantly

CD for weeks = 1.15 (Significant at 1% and 5%)

NS = Non-significant



**Fig. 4. Average Weekly Body Weight Gain (gms) per rat in different groups.**

#### **4.3.1 Hemoglobin (gm/dl):**

Average hemoglobin values in different groups are given in Table 5.

Average hemoglobin values were significantly decrease in T<sub>2</sub> and T<sub>4</sub> group rats when compared with average value of T<sub>1</sub> and T<sub>3</sub> groups. Lowest value of  $08.66 \pm 0.37$  was observed in T<sub>2</sub> group given lead acetate at 500 ppm in water. Average Hb values in different groups were found to be  $13.03 \pm 0.76$  (T<sub>1</sub>),  $08.66 \pm 0.37$  (T<sub>2</sub>),  $12.15 \pm 0.43$  (T<sub>3</sub>) and  $09.65 \pm 0.23$ (T<sub>4</sub>) groups indicating effect of lead toxicity with improvement in hemoglobin values in *Plumbago zeylanica* given group along with lead acetate.

Morgon *et al.* (1975) reported that the mechanism by which lead causes anemia is by increasing hemolysis or interfering with the synthesis at the enzyme level or by reacting with hemoglobin directly causing reduced Hb content of normal cells.

Garg (2000) reported that lead influence the synthesis of haem by inhibiting  $\delta$ -amino levulinic acid ( $\delta$ ALA) dehydratase enzyme, conversion of caproporphyrinogen III to protoporphyrin IX and inhibition of haem synthase which is required to incorporate iron in the haem molecule. It also prevents the entry of iron from cytosol to mitochondria.

Chetty *et al.* (2006) reported that *P. zeylanica* was used is condition of anemia and improves blood formation.

Similar findings of decrease in hemoglobin levels during experimental lead toxicity have been reported by Rahman (2006), Deshmukh (2006), Wagh (2006) in broilers, Ghule (2007) Gongale (2009) Mesharam(2009) in quails and by Brahmankar (2008) and Kale (2008) in rats.

#### **4.3.2 Packed Cell Volume (Percentage):**

Average packed cell volume in different groups is depicted in Table 5.

Mean packed cell volume in different groups were found to be  $42.33 \pm 0.84$ ,  $30.83 \pm 0.79$ ,  $38 \pm 1.40$  and  $34.16 \pm 0.54$  in T<sub>1</sub>, T<sub>2</sub>, T<sub>3</sub>, and T<sub>4</sub> groups,

**Table 5: Hemoglobin (gm/dl), Packed Cell Volume (%), Total Erythrocyte Count ( $10^6$ /cumm), Mean Corpuscular Volume (fL), Mean Corpuscular Haemoglobin (pg) and Mean corpuscular Haemoglobin concentration (%) in different groups.**

Hb		PCV		TEC		MCV		MCH		MCHC	
Group	4 <sup>th</sup> Week	Group	4 <sup>th</sup> Week	Group	4 <sup>th</sup> Week	Group	4 <sup>th</sup> Week	Group	4 <sup>th</sup> Week	Group	4 <sup>th</sup> Week
T1	13.03 <sup>a</sup> ± 0.76	T1	42.33 <sup>a</sup> ± 0.84	T1	6.75 ± 0.41	T1	63.53 ± 3.08	T1	19.75 ± 1.91	T1	30.88 ± 2.03
T2	8.66 <sup>b</sup> ± 0.37	T2	30.83 <sup>d</sup> ± 0.79	T2	5.41 ± 0.18	T2	57.43 ± 3.21	T2	16.18 ± 1.15	T2	28.14 ± 1.23
T3	12.15 <sup>a</sup> ± 0.0.43	T3	38.00 <sup>b</sup> ± 1.4	T3	6.33 ± 0.53	T3	61.19 ± 3.45	T3	19.68 ± 1.39	T3	32.11 ± 1.29
T4	9.65 <sup>b</sup> ± 0.23	T4	34.16 <sup>c</sup> ± 0.54	T4	5.91 ± 0.22	T4	58.09 ± 1.98	T4	16.41 ± 0.65	T4	28.24 ± 0.56
CD for treatment = 1.44 (Significant at 1% and 5% level)		CD for treatment = 1.84 (Significant at 1% and 5% level)		NS		NS		NS		NS	

Mean values with common alphabet as superscript do not differ significantly

respectively. Significant decrease in packed cell volume (PCV) values was observed in all treatment group rats when compared with control group and lowest value observed in T<sub>2</sub> group receiving lead acetate at 500 ppm.

Decreased values of PCV is due to decreased life span of erythrocytes and increased fragility of erythrocytes and inhibitory effect of lead on erythrocyte enzymes (GA3PD and G6PD) as reported by Karamala *et al.* (2011)

Present findings corroborate with those reported by Chandra *et al.* (2010) and Suradkar *et al.* (2009) in rats with decrease in PCV and by Morgon *et al.* (1975) in quails during experimental lead toxicity.

Derease average PCV value during lead toxicity is also reported by Rahman (2006), Deshmukh (2006), Wagh (2006) in case of broilers, by Ghule (2007) in quails and by Kale (2008) in female rats .

Use of *P. zeylanica* during lead toxicity however improved PCV value in T<sub>4</sub> group when compared with T<sub>2</sub> group suggesting useful properties of *P. zeylanica* during lead toxicity. Present finding corroborates with the observation of Chetty *et al.* (2006) reporting its utility in anemia.

#### **4.3.3 Total Erythrocyte Count (10<sup>6</sup>/ cumm):**

The average total erythrocyte count in different groups is given in Table 5.

Average mean values in control and different treatment group rats were found to be 6.75± 0.41, 5.41± 0.18, 6.33 ± 0.53, and 5.91 ± 0.22 in T<sub>1</sub>, T<sub>2</sub>, T<sub>3</sub>, and T<sub>4</sub> groups, respectively . Mean average value of TEC in T<sub>1</sub> and T<sub>3</sub> were found comparable.

However, non-significant decrease in all group of rats was recorded when compared with the values of control group. T<sub>4</sub> group rats showed improvement due to protective effect of *P. zeylanica* as compared to only lead treated T<sub>2</sub> group. Lowest values of TEC values in T<sub>2</sub> group rats could be possibly due to direct toxic effect of lead on hemopoietic system and depressant action of

lead and its deposition in bone marrow as reported by Garg (2004).

Similar findings were reported by Chandra *et al.* (2010) and Suradkar *et al.* (2009) in rats with decrease in TEC during experimental lead toxicity.

Improvement in *P. zeylanica* group could be possibly due to its hematinic properties as described by Chetty *et al.* (2006). Present findings of decrease in TEC in lead treated group corroborate with those reported by Rahman (2006). Deshmukh (2006) in broilers, by Meylorie *et al.* (1977) and Ghule (2007) Gongale and Meshram (2009) in quails and by Kale (2008) and Brahmankar (2008) in rats during experimental lead toxicity.

#### **4.3.4 Erythrocytes Indices :**

The erythrocyte indices values define the size and hemoglobin content of erythrocyte. Values were derived from erythrocyte count, hemoglobin concentration and PCV. Details are given in Table 5.

##### **4.3.4.1 Mean Corpuscular Volume (fL):**

Average Mean Corpuscular Volume (MCV) in different groups did not reveal significant differences. However when compared with control group, values were comparatively decreased in treatment group animals.

The average values in each group were calculated and found to be  $63.53 \pm 3.08$  in T1,  $57.43 \pm 3.21$  in T2,  $61.19 \pm 3.45$  in T3, and  $58.09 \pm 1.98$  in T4 suggesting mild decrease in size of RBC's. Similar observations are reported by Suradkar *et al.* (2009) and Chandra *et al.* (2010) during lead toxicity. This could be possibly due to toxic effect of lead in T2 and T4 groups.

Lower MCV values indicated decrease size of erythrocytes suggesting possibility of iron deficiency anemia indicating toxic effect of lead on hemopoietic system causing microcytic hypochromic anemia in rats Brahmankar (2008) and Kale (2008)

MCV values though showed non-significant differences after

addition of *P. zeylanica* during lead toxicity improved the value of MCV in T<sub>4</sub> group rats suggesting its hematinic effect as reported by Chetty *et al.* (2006).

#### **4.3.4.2 Mean Corpuscular Hemoglobin (pg):**

Average mean corpuscular hemoglobin concentration in different groups is given in Table 5.

Average MCH values in different groups indicated non-significant decrease. Values were found to be  $19.75 \pm 1.91$  (T<sub>1</sub>),  $16.18 \pm 1.15$  (T<sub>2</sub>),  $19.68 \pm 1.39$  (T<sub>3</sub>) and  $16.41 \pm 0.65$  (T<sub>4</sub>) group. Comparatively lower values in T<sub>2</sub> group rats when compared with control group rats could be possibly due to decreased heme synthesis or interference with iron and copper metabolism suggested by Chandra *et al.*(2010)

Suradkar *et al.* (2009) observed decrease MCH values in 48 male and female rats given lead acetate @ 1,100 and 1000ppm during study of subchronic exposure of lead acetate.

Same trend of decrease in MCH value were also reported by Rahman (2006), Deshmukh (2006) and Wagh (2006) in broilers, and Ghule (2007), Deshmukh (2010), Autade (2010) in quails and Kale (2008) Bramhankar (2008) during lead toxicity.

#### **4.3.4.3 Mean Corpuscular Hemoglobin Concentration (gm/dl):**

Average mean corpuscular hemoglobin concentration (MCHC) in different groups revealed significant differences. Table-5

Significant decrease was observed in T<sub>2</sub> and T<sub>4</sub> group rats when compared with control group. Average MCHC values in different groups were found to be  $30.88 \pm 2.03$  in T<sub>1</sub>,  $28.14 \pm 1.23$  in T<sub>2</sub>,  $32.11 \pm 1.29$  in T<sub>3</sub> and  $28.24 \pm 0.56$  in T<sub>4</sub> group respectively.

Average values indicated toxic effect of lead on MCHC values. Present findings corroborate with those reported by Karamala *et al.* (2011), and Chandra *et al.*(2010) suggesting that lower MCHC values in lead treated group animals could be possibly due to lowered hemoglobin synthesis as a result of lead toxicity.

Similar findings of decrease MCHC values during lead toxicity is reported by Brahmkar (2008) and Kale (2008) in rats. The microcytic hypochromic anemia may be possibly due to toxic effect of lead on haem synthesis. Decrease in MCHC values have been also reported by Ghule (2007) in quails, Deshmukh (2006) and Rahman (2006) in broilers which corroborates with present findings. MCHC value were restored in *P. zeylanica* given groups suggesting its hematinic properties though values were not completely restored as that of control group.

Hematinic properties of *P. zeylanica* which corroborates with present findings described by Vijayakumar *et al.* (2006)

#### **4.3.5 Total Leucocyte Count ( $10^3$ /cumm):**

Average total leucocyte count in different groups is depicted in Table 6.

Mean average values revealed significant difference. Lowest values of  $9.79 \pm 0.39$  were observed in T<sub>2</sub> group rats given lead acetate without *P. zeylanica*. However values were found to be comparable in T<sub>4</sub> groups when compared with values of control group, thus indicating beneficial effects of *P. zeylanica* on leucopoiesis during lead toxicity.

Decrease values in T<sub>2</sub> group corroborate with the finding of Suradkar *et al.* (2009) as a result of suppression of immune response and leucopoiesis during lead toxicity.

Suradkar *et al.* (2009) described the possible cause of leucopenia through direct toxic action of lead on leucopoiesis which may be resulting from decreased production from germinal centre of lymphoid organs on their lysis due to presence of lead in bone marrow.

The observations thus suggested beneficial effect of *P. zeylanica* on leucopoiesis during lead toxicity. Decrease TLC values during lead toxicity are also reported by Deshmukh (2006) in broilers and Ghule (2007) in quails.

**Table 6 : Total Leucocyte count ( $10^3/\text{cumm}$ ) and Absolute Leucocyte count in different groups.**

Total Leucocyte Count (TLC)		Neutrophil		Lymphocyte		Eosinophil		Monocyte	
Group	4 <sup>th</sup> Week	Group	4 <sup>th</sup> Week	Group	4 <sup>th</sup> Week	Group	4 <sup>th</sup> Week	Group	4 <sup>th</sup> Week
T1	11.62 <sup>a</sup> ± 0.41	T1	2810 <sup>b</sup> ± 166.30	T1	7807.66 <sup>a</sup> ± 273.65	T1	684.33 ± 23.22	T1	315.66 <sup>b</sup> ± 19.59
T2	9.7 <sup>b</sup> ± 0.39	T2	3838 <sup>a</sup> ± 279.17	T2	4947.00 <sup>c</sup> ± 254.41	T2	596.16 ± 34.26	T2	403.83 <sup>a</sup> ± 7.44
T3	11.38 <sup>a</sup> ± 0.37	T3	2656.66 <sup>b</sup> ± 184.90	T3	7720.33 <sup>a</sup> ± 239.04	T3	680.66 ± 24.86	T3	319.33 <sup>b</sup> ± 20.98
T4	10.83 <sup>ab</sup> ± 0.42	T4	3222.50 <sup>ab</sup> ± 321.10	T4	6610.83 <sup>b</sup> ± 317.54	T4	626.83 ± 15.06	T4	373.16 <sup>a</sup> ± 5.26
CD for treatment = 1.18 (Significant at 5% level)		CD for treatment = 7.26 (Significant at 5% level)		CD for treatment = 8.04 (Significant at 1% and 5% level)		NS		CD for treatment = 4.40 (Significant at 1% and 5% level)	

Mean values with common alphabet as superscript do not differ significantly

Similar findings of decrease in TLC were reported by Kale (2008) and Brahmkar (2008), Gongale (2009), Autade (2010) during experimental lead toxicity.

#### **4.3.6. Absolute Leucocyte Count:**

From the total leucocyte count and differential leucocyte count absolute values of neutrophil, lymphocyte, monocyte and eosinophil were derived and are given in Table – 6

##### **A) Absolute Neutrophil Count ( $10^3/\text{cumm}$ ):**

Mean average absolute values of neutrophil in different groups is given in table-5. Values indicated significant increase in T<sub>2</sub> group animals when compared with the values of control group.

Average values in T<sub>1</sub>, T<sub>2</sub>, T<sub>3</sub>, and T<sub>4</sub> were found to be 2810.16 ± 166.30, 3838.16 ± 79.17, 2656.66 ± 184.90 and 3222.50 ± 321.10 respectively suggesting increase values during lead toxicity in female rats.

Karamal *et al.* (2011) reported similar observations in rats given lead acetate. Contrary to these observations. Meshram (2009) observed neutropenia during lead toxicity in quails. The increased neutrophil count during present studies could be possibly due to decrease in the absolute values of lymphocytes or enteric infection in T<sub>2</sub> group.

Similar relative increase values of neutrophil during experimental lead toxicity in broilers is reported by Deshmukh (2006) and Rahman (2006). Similar observations in quails and rats during lead toxicity is reported by Ghule (2007) and Kale (2008).

Regeneration of neutrophil values in T<sub>4</sub> groups suggested beneficial effect of *P. zeylanica* to overcome the effect of leucocytosis induced during lead toxicity.

##### **B) Absolute Lymphocyte Count ( $10^3/\text{cumm}$ ):**

Absolute lymphocyte count in different groups at the end of 4<sup>th</sup> week revealed significant differences.

All treatment group rats revealed significant decrease when compare with the values of control group animals. Values were found to be  $7807 \pm 273.65$ ,  $4947 \pm 254.41$ ,  $7720 \pm 239.04$ , and  $6610 \pm 317.54$  in T<sub>1</sub>, T<sub>2</sub>, T<sub>3</sub> and T<sub>4</sub> group respectively.

Similar observation of decrease total lymphocyte count in treatment group rats given lead acetate is reported by Rahman (2006) mentioning effects of lead on T and B lymphocytes resulting in decrease in their number in peripheral circulation. Karamal *et al.* (2011) during studies on experimental lead toxicity concluded that lead might be producing toxic action on spleen and lymphoid organs.

However, the improved values in T<sub>4</sub> groups suggested the protective effect of *P. zeylanica* and its useful properties as described by Vijayakumar *et al.* (2006) and Chetty *et al.* (2006)

#### **C) Absolute Eosinophil count (10<sup>3</sup>/cumm):**

Mean average values of absolute eosinophil count revealed non significant differences. Average absolute eosinophil values were found to be  $684.33 \pm 23.22$  in T<sub>1</sub>,  $596 \pm 34.26$  in T<sub>2</sub>,  $680.66 \pm 24.86$  in T<sub>3</sub> and  $626.83 \pm 15.06$  in T<sub>4</sub> group respectively.

Present findings corroborate with those reported by Suradkar *et al.* (2009) indicating toxic effect of lead on leucopoiesis which could be confirmed from low total leucocyte count in treatment group animals.

Similar finding are also reported by Rahman (2006), Deshmukh (2006) in broilers and by Ghule (2007) in quails by Kale (2008) in rats during experimental lead toxicity.

#### **D) Absolute Monocyte count (10<sup>3</sup>/cumm):**

The average total monocyte count in different groups revealed significant differences. Values were found to be significantly increased in T<sub>2</sub> group animals when compared with the values of control group.

Mean total monocyte count in T<sub>1</sub>, T<sub>2</sub>, T<sub>3</sub> and T<sub>4</sub> group were found to be  $315.66 \pm 19.59$ ,  $403.83 \pm 7.44$ ,  $319.33 \pm 0.98$  and  $373.16 \pm 5.26$  respectively.

Monocytosis during subchronic lead toxicity in adult female rats is reported by Kale (2008) in female rats which corroborates with present findings.

T<sub>4</sub> groups showed restoration in absolute monocyte count when compared with T<sub>2</sub> group, which might be due to beneficial effect of *P. zeylanica* as reported by Vijayakumar *et al.* (2006) and Chetty *et al.* (2006).

#### 4.4 Biochemical Parameters:

Biochemical Parameters were studied at the end of 4<sup>th</sup> week of experiment. These included plasma calcium, phosphorus, creatinine, SGOT/AST and SGPT/ALT, Glucose and total proteins. values are depicted in Table 7 and Fig. 5(a) and 5(b).

##### 4.4.1 Plasma Calcium (mg/dl):

Average mean calcium values in different groups revealed significant decrease in treatment groups when compared with the values of control group. Lowest values were observed in T<sub>2</sub> group. Values in different groups were found to be  $11.3 \pm 0.74$ ,  $7.68 \pm 0.35$ ,  $10.13 \pm 0.57$  and  $8.68 \pm 0.48$  in T<sub>1</sub>, T<sub>2</sub>, T<sub>3</sub> and T<sub>4</sub> groups respectively.

Present findings corroborate with those reported by Kale (2009) in rats and Ghule (2007) in quails. Lower calcium levels in treatment group could be possibly due to toxic effect of lead on bone or disturbance in calcium absorption as reported by Saly *et al.* (2004).

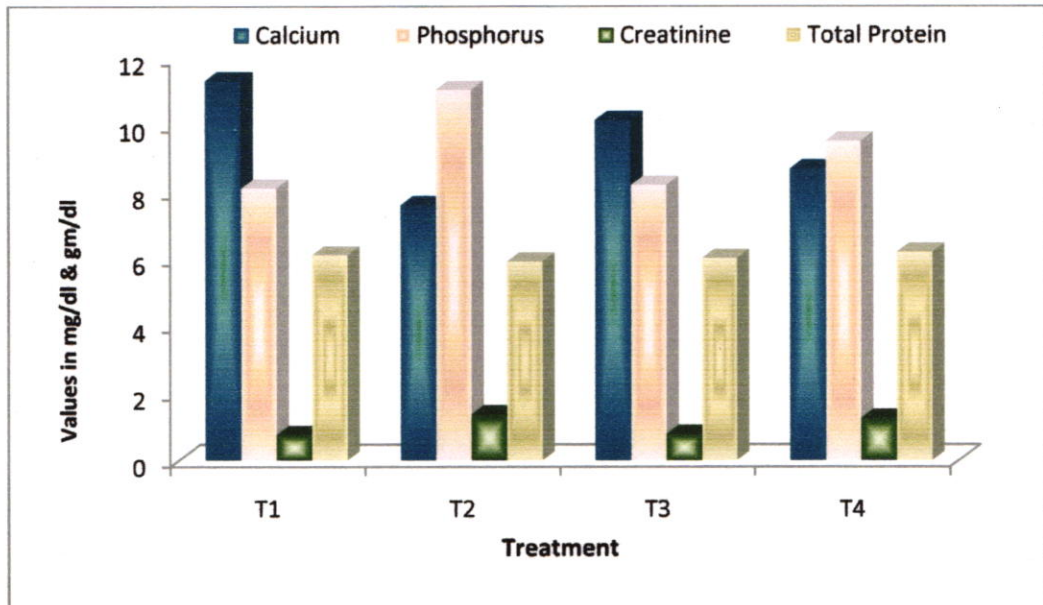
Significant improvement in values observed in T<sub>4</sub> groups when compared with T<sub>2</sub> group. However, values were found to be significantly lower when compared with control group indicating useful properties of *P. zeylanica* for restoration of normal calcium values during lead toxicity.

Tilak *et al.* (2004) and Burkill (1997) reported medicinal properties of *Plumbago zeylanica* as a treatment for bone related conditions and rubefaciency in rheumatism.

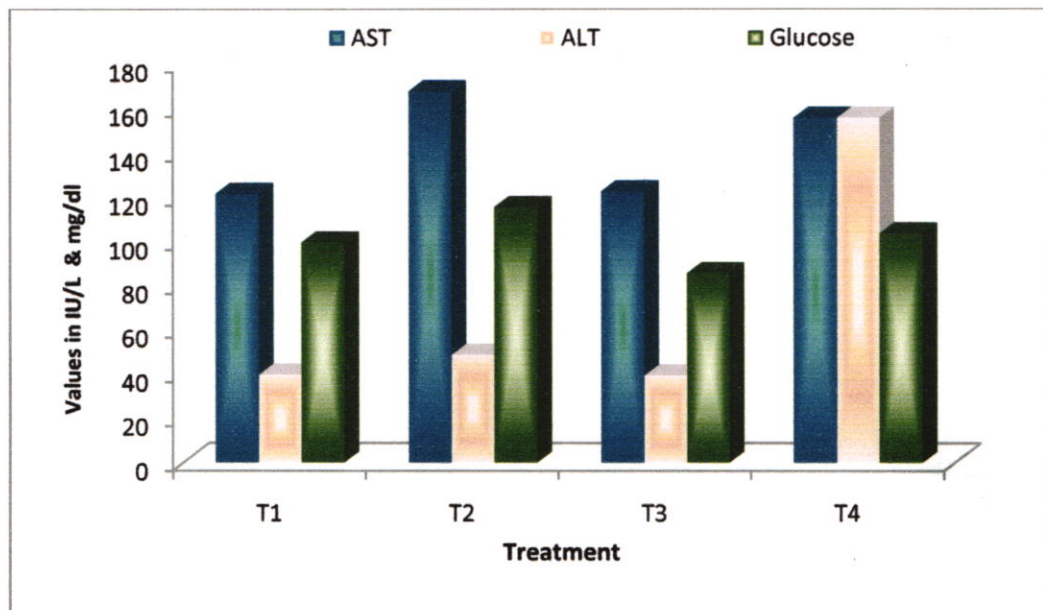
**Table 7: Plasma Calcium (mg/dl), Plasma Phosphorus (mg/dl), Plasma Creatinine, Plasma SGOT (AST) (IU/L), Plasma SGPT (ALT) (IU/L), Plasma Glucose (mg/dl) and Plasma Total Protein (mg/dl) in different groups.**

Calcium		Phosphorus		Creatinine		SGOT (AST)		SGPT (ALT)		Glucose		Total Protein	
Group	4 <sup>th</sup> Week	Group	4 <sup>th</sup> Week	Group	4 <sup>th</sup> Week	Group	4 <sup>th</sup> Week	Group	4 <sup>th</sup> Week	Group	4 <sup>th</sup> Week	Group	4 <sup>th</sup> Week
T1	11.32 <sup>a</sup> ± 0.74	T1	8.11 ± 0.77	T1	0.76 <sup>b</sup> ± 0.26	T1	121.46 <sup>b</sup> ± 2.84	T1	39.51 <sup>b</sup> ± 1.14	T1	99.53 ± 8.60	T1	6.01 ± 0.46
T2	7.6 <sup>c</sup> ± 0.35	T2	11.05 ± 0.71	T2	1.36 <sup>a</sup> ± 0.04	T2	167.50 <sup>a</sup> ± 2.74	T2	48.48 <sup>a</sup> ± 0.95	T2	115.50 ± 6.61	T2	5.91 ± 0.29
T3	10.13 <sup>ab</sup> ± 0.57	T3	8.2 ± 0.83	T3	0.78 <sup>b</sup> ± 0.11	T3	122.50 <sup>b</sup> ± 1.17	T3	39.13 <sup>b</sup> ± 0.75	T3	85.58 ± 9.85	T3	6.016 ± 0.24
T4	8.68 <sup>bc</sup> ± 0.48	T4	9.5 ± 0.057	T4	1.25 <sup>a</sup> ± 0.05	T4	155.45 <sup>a</sup> ± 11.78	T4	45.66 <sup>a</sup> ± 2.07	T4	103.65 ± 3.79	T4	6.2 ± 0.21
CD for treatment = 1.64 (Significant at 1% and 5% level)		NS		CD for treatment = 0.43 (Significant at 5% level)		CD for treatment = 18.41 (Significant at 1% and 5% level)		CD for treatment = 3.09 (Significant at 1% and 5% level)		NS		NS	

Mean values with common alphabet as superscript do not differ significantly



**Fig. 5 (a):- Plasma Calcium (mg/dl), Plasma Phosphorus (mg/dl), Plasma Creatinine (mg/dl), and Plasma Total Protein (gm/dl) in different groups.**



**Fig. 5 (b):- Plasma AST (SGOT) (IU/L), Plasma ALT (SGPT) (IU/L), and Plasma Glucose (mg/dl) in different groups.**

#### **4.4.2 Plasma Phosphorus (mg/dl):**

The details regarding average plasma phosphorus levels in different groups are given in Table 7 and Fig. 5 (b).

Average phosphorus levels in different groups revealed significant differences. Highest average value was observed  $11.05 \pm 0.71$  in T<sub>2</sub> group, given lead without *Plumbago zeylanica* suggesting hyperphosphatemia during lead toxicity.

Saly *et al.* (2004) also observed similar increase in phosphorus level in lead treated group and restoration of values near the levels of control group due to addition of vitamin and mineral mixture during lead toxicity. Increased phosphorus levels could be the cause of lameness as a result of renal insufficiency due to nephrotoxicity is described by Ghule (2007).

Phosphorus levels in T<sub>4</sub> group given lead and *P. zeylanica* were found to be numerically increased as compared to control. However, it was lower as compare to T<sub>2</sub> group suggesting beneficial effect of *Plumbago zeylanica* during lead toxicity.

Protective effect of *P. zeylanica* and its useful properties in bone related conditions is described by Tilak *et al.* (2004) and Burkill (1997).

#### **4.4.3 Plasma Creatinine (mg/dl):**

Creatinine levels in different groups reveal significant differences. Average values were found to be  $0.76 \pm 0.26$  in T<sub>1</sub>,  $1.36 \pm 0.04$  in T<sub>2</sub>,  $0.78 \pm 0.11$  in T<sub>3</sub> and  $1.25 \pm 0.05$  in T<sub>4</sub> group rats respectively. When compared with the values of control group, significant increase was observed in T<sub>2</sub> group. Group T<sub>4</sub> rats showed significant decrease in mean plasma creatinine values as compared to T<sub>2</sub> group which received Lead acetate alone @ 500 ppm.

The present findings of significant increase in creatinine is in close agreement with the findings of Ashour *et al.* (2007) and Deshmukh (2006) in broilers, Kale (2008) and Brahmankar (2008) and Karamala *et al.* (2011) in rats. Gongale (2009) Meshram (2009), Autade (2009) in quails.

Similar findings of increase creatinine values during experimental lead toxicity has been reported by Brar *et al.* (1997)

Benjamin (2001) described that, creatinine is a substance derived from creatin and creatin phosphate in muscles and its concentration in blood is used as index of glomerular filtration rate and renal damage suggesting nephrotoxic effect of lead in rats.

However simultaneous supplementation of *Plumbago zeylanica* extract during lead toxicity showed remarkable restoration on creatinine levels when compared with T<sub>2</sub> group suggesting its beneficial effect.

#### **4.4.4 Plasma AST(IU/L):**

AST levels in different groups reveal significant difference. However, significant increase was observed in T<sub>2</sub> group rats when compared with the values of control group.

Average values were found to be 121.46 ± 20.84 (T<sub>1</sub>), 167.50 ± 2.74 (T<sub>2</sub>), 122.50 ± 1.17 (T<sub>3</sub>), and 155.45 ± 11.78(T<sub>4</sub>)

Deshmukh (2006) reported similar observation suggested possible cause of cellular necrosis, and imparement of cardiac function or hepatic damage during experimental lead toxicity in broilers.

Increase AST values suggested possible hepatorenal damage during lead toxicity as reported by Kale (2008) at 100, 250 and 500 ppm levels and Brahmkar (2008) at 500, 700, 1000 ppm of lead in rats.

However, significant decrease found in T<sub>4</sub> group receiving lead with *Plumbago zeylanica* suggested protective effect of ethanolic root extract of *Plumbago zeylanica* and Bhargava (1984) reported similar hepatoprotective effect of plumbagin in dogs on the basis of normal AST values.

#### **4.4.10 Plasma ALT (IU/L):**

ALT levels in different groups reveal significant differences; however dose dependant significant increase was observed in T<sub>2</sub>, T<sub>3</sub> and T<sub>4</sub> groups rats when compared with values of control group.

Values were found to be 39.51± 1.14 in T1, 48.48 ± 0.95 in T2, 39.13 ± 0.75 in T3 and 45.66 ± 2.07 in T4 group suggesting increased values in treatment group animals. This enzyme appears in lesser amount in kidneys,

heart, and skeleton muscle and is relatively specific indicator of acute liver cell damage. Hepatic damage caused due to lead could be possible cause for elevated levels of ALT during present study.

However, values in T<sub>4</sub> group showed decrease when compared with T<sub>2</sub> group suggesting protective effect of *Plumbago zeylanica* during lead toxicity on ALT values. Santhakumari *et al.* (1978) studied effects of plumbagin on liver and serum enzymes in albino rats and observed significant decrease in ALT levels in serum confirming the present observations.

Present findings also corroborates with those reported by Brar (1994) in Poultry and Kale (2008) and Brahmanekar (2008) in rats during experimental lead toxicity. Bhargava (1984) described cordiotonic effect of plumbagin in dogs.

#### **4.4.1 Plasma Glucose (mg/dl):**

Glucose levels in different groups revealed non-significant difference. However, significant increase was observed in T<sub>2</sub> group rats given lead acetate@500ppm suggesting hyperglycemia when compared with the values of control group.

Average values were found to be  $99.53 \pm 8.60$  (T<sub>1</sub>),  $115.50 \pm 6.61$  (T<sub>2</sub>),  $85.58 \pm 9.85$  (T<sub>3</sub>), and  $103.65 \pm 3.79$ (T<sub>4</sub>) suggesting decreased values in treatment group animals.

Mujumdar (1980) described hyperglycaemia due to insulin decrease and Gilman *et.al.*(1990) suggested cause to be due to decrease activity of  $\beta$  cells. Hyperglycaemia observed in T<sub>2</sub> and T<sub>4</sub> groups could be possible due to adverse effect on endocrine function due to lead. Hyperglycaemia was found to be decrease in T<sub>4</sub> group given *P. zeylanica* with lead suggesting its useful properties due to hyperglycemia.

Similar observations of hypoglycemic effect by stimulating glucose utilization or decrease glucagon, cortisol hormone or reduced absorption of glucose from gut is reported by Zarmouh (2010).

#### **4.4.7 Plasma Total Protein (gm/dl):**

Average plasma total protein levels in different groups revealed non-significant differences. Values were found to be  $6.01 \pm 0.46$  in T<sub>1</sub>,  $5.91 \pm 0.29$  in T<sub>2</sub>,  $6.08 \pm 0.24$  in T<sub>3</sub> and  $6.28 \pm 0.21$  in T<sub>4</sub> groups respectively. Average dose dependant effect of lead on total protein levels.

Present findings corroborate with those reported by Tatjana *et al.* (2003) in rats given lead acetate. They suggested possible cause as hepatotoxic and nephrotoxic effect of lead. Similar significant decrease is also reported by Wagh (2006) and Ghule (2007) in broilers and quails.

Protein levels in T<sub>4</sub> group were found to be comparable with control group. However, it was high compare to T<sub>2</sub> group suggesting beneficial effect of *Plumbago zeylanica* during lead toxicity.

Rajeshkumar *et al.* (2009) and Zarmouh *et al.* (2011) reported hepatoprotective and hypoglycemic properties of *P. zeylanica* root extract.

#### **4.5. Radiological Investigations:**

Two rats from each group were randomly subjected to radiographic examinations at the end of 4<sup>th</sup> week of experiment to evaluate effect of lead on skeleton and joints, if any. (Plate-12 to 15)

Skeleton of control group female rats as well as treatment group rats did not reveal remarkable differences. Radiographic examination thus indicated that 4 weeks experimental lead toxicity at 500 ppm levels in adult females did not show any skeletal deformities in spite of 90% of lead deposited in bone. Similar findings were reported by Kale (2008) in female rats given lead acetate.

#### **4.6. Gross Pathological Observation:**

Detailed necropsy was conducted for recording gross pathological changes in various visceral organs with special emphasis on reproductive organs i.e. ovary and uterus after completion of 4 weeks of experiment.

Most of the visceral organs i.e. liver. Lungs, heart, kidneys, brain, spleen and reproductive organs appeared normal in almost all control group

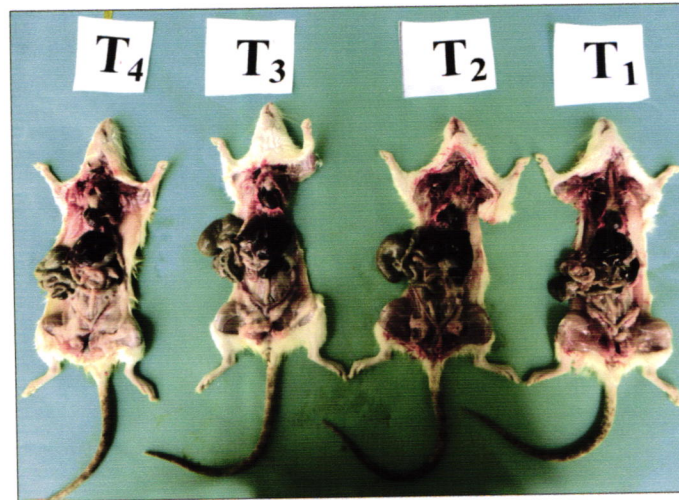


Plate 10 : Variation in carcass size of different group rats.

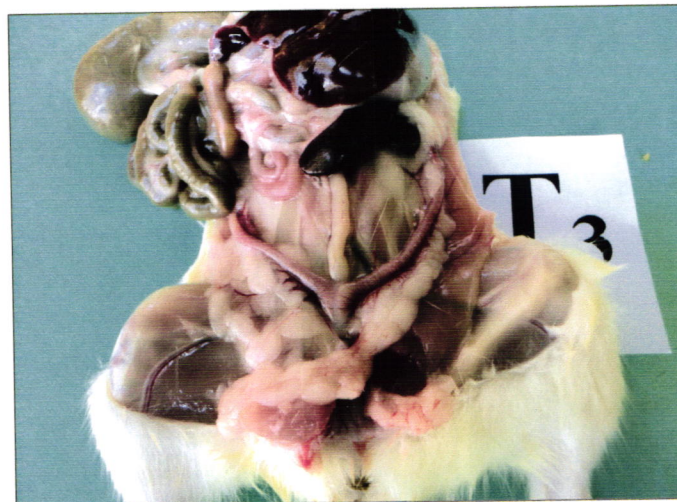

Plate 11 : T<sub>3</sub> group rat showing congestion in uterus.

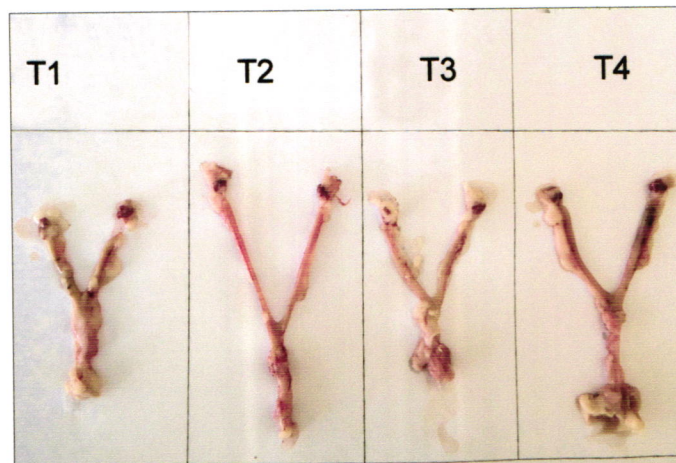


Plate 12 : Variation in size of uterus and ovary in different groups rats.

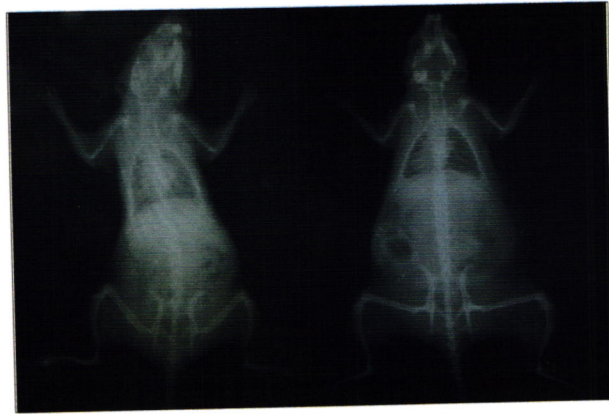

Plate 13 : Radiograph of T<sub>1</sub> group rats.

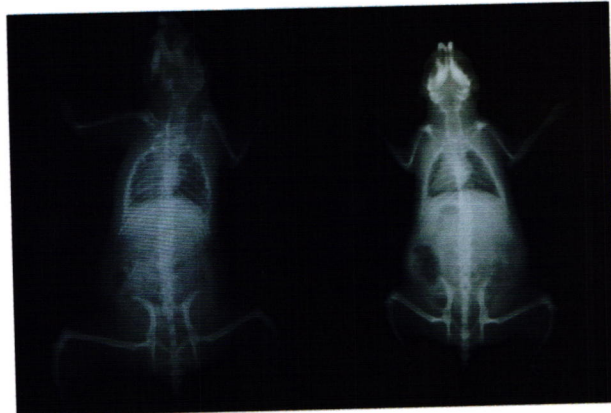

Plate 14 : Radiograph of T<sub>2</sub> group rats.

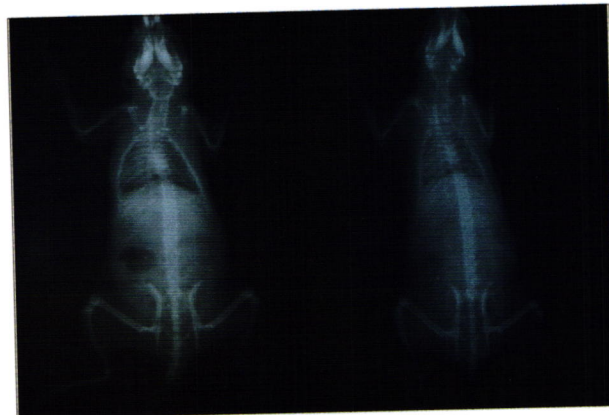


Plate 15 : Radiograph of T<sub>3</sub> group rats.

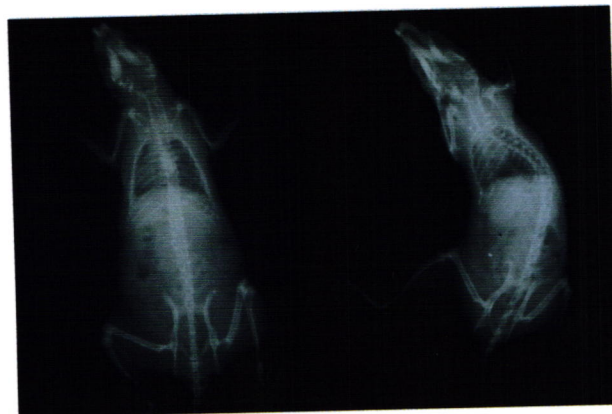


Plate 16 : Radiograph of T<sub>4</sub> group rats.

animals. Necropsy of treatment group animals also did not reveal marked pathological alterations except mild congestion ovaries and uterus of treatment group animals. (Plate-) Similar findings were reported during four weeks period experimental lead toxicity in female rats by Kale (2008).

#### **4.6.1 – Organ Weights:**

After necropsy liver, lung, heart, kidneys, brain, spleen, ovaries, uterus and vulva were separated from carcass of each group. The weights of these organs were recorded to evaluate effect of lead acetate on these organs. (Table 8)

##### **a) Liver (gms):**

Liver weights in different treatment group rats revealed significant differences when compared with control group animals. Significant decrease was observed in T<sub>2</sub> and T<sub>4</sub> group animals when compared with average weights of control group (Plate-13). Average liver weights in T<sub>1</sub>, T<sub>2</sub>, T<sub>3</sub> and T<sub>4</sub> were found to be 6.82 ± 0.23, 5.58 ± 0.31, 6.67 ± 0.25 and 6.27 ± 0.41 respectively. Similar finding of lower average weights of liver during lead toxicity is reported by Kale (2008) in rats and Ghule (2007) in quails. Lower liver weight in treatment group could be possibly due to lower body weights in these groups or hepatotoxic effect of lead.

On the basis of observations of average liver weights, there was improvement in average liver weights in *P. zeylanica* given group along with the lead as compared to T<sub>2</sub> group given lead without *P. zeylanica*, thus indicating improvement in liver weights.

##### **b) Lung (gms):**

The differences in average lung weights in different groups did not reveal significant differences.

Average lung weights in different groups were found to be 1.57 ± 0.09, 1.37 ± 0.05, 1.76 ± 0.17 and 1.67 ± 0.07, in T<sub>1</sub>, T<sub>2</sub>, T<sub>3</sub> and T<sub>4</sub> groups respectively. Present findings are in agreement with those reported by Wagh (2006) and Deshmukh (2006) in broilers, Kale (2008) and Brahmankar (2008) in rats during lead toxicity.

Table 8: Average organ weights (gms) in different groups.

Group	Liver (Weight)	Lung (Weight)	Heart (Weight)	Kidneys (Weight)	Spleen (Weight)	Brain (Weight)	Ovaries (Weight)	Uterus With vulva (Weight)
T1	6.82 <sup>a</sup> ± 0.23	1.57 ± 0.09	0.66 ± 0.05	1.65 ± 0.05	1.46 ± 0.30	1.8 ± 0.13	0.16 ± 0.03	1.18 ± 0.17
T2	5.58 <sup>b</sup> ± 0.31	1.37 ± 0.05	0.62 ± 0.03	1.50 ± 0.06	1.21 ± 0.08	1.67 ± 0.008	0.09 ± 0.007	1.09 ± 0.15
T3	6.67 <sup>a</sup> ± 0.25	1.76 ± 0.17	0.65 ± 0.02	1.63 ± 0.05	1.34 ± 0.17	1.70 ± 0.05	0.16 ± 0.06	1.17 ± 0.10
T4	6.27 <sup>ab</sup> ± 0.41	1.67 ± 0.07	0.64 ± 0.03	1.54 ± 0.06	1.31 ± 0.04	1.69 ± 0.09	0.13 ± 0.01	1.15 ± 0.06
CD	CD for treatment = 0.9 (Significant at 5% level)	NS	NS	NS	NS	NS	NS	NS

Mean values with common alphabet as superscript do not differ significantly.

NS = Non Significant.

### **c) Heart (gms):**

Average weight of heart in different groups did not revealed significant differences. Average weights of heart in different groups were found to be  $0.66 \pm 0.05$ ,  $0.62 \pm 0.03$ ,  $0.65 \pm 0.02$  and  $0.64 \pm 0.03$  in T<sub>1</sub>, T<sub>2</sub>, T<sub>3</sub> and T<sub>4</sub> groups, respectively indicating effect of lead toxicity with improvement in weights in *P. zeylanica* given group along with the lead.

Present findings corroborate with those reported by Wagh (2006) and Deshmukh (2006) in broilers. Kale (2008) lower average heart weights in female rats however, The lower average heart weights in treatment group animals could be possibly due to lower body weights in these groups.

### **d) Kidneys (gm)**

Average weight of kidneys in different groups also did not reveal significant differences. Average weights in different groups were found to be  $1.65 \pm 0.05$  (T<sub>1</sub>),  $1.50 \pm 0.06$  (T<sub>2</sub>),  $1.63 \pm 0.05$  (T<sub>3</sub>), and  $1.54 \pm 0.06$  (T<sub>4</sub>) respectively, indicating limited protective effect of *P. zeylanica* on average weights of kidneys.

Decrease in average kidney weight during lead toxicity through feed in quails is reported by Ghule (2007), in broilers by Deshmukh (2006) and in rats by Kale (2008) and Brahmanekar (2008).

### **e) Spleen (gm):**

Average spleen weights in different treatment groups showed non-significant decrease when compared with control group (Plate-15). Average spleen weights in different groups were found to be  $1.4 \pm 0.30$ ,  $1.2 \pm 0.08$ ,  $1.3 \pm 0.17$  and  $1.31 \pm 0.04$  in T<sub>1</sub>, T<sub>2</sub>, T<sub>3</sub> and T<sub>4</sub> groups respectively. Lowered average spleen weight in treatment group animals could also be possibly due to lower average weights in these groups or depletion of lymphoid population as reported by Wagh (2006) in broilers and Ghule (2007) in quails.

Chen *et al.* (2004) reported increase relative spleen weights and decreased body weight of dams given lead acetate at 250ppm in drinking water. This could be possibly due to longer duration of exposure and low doses of lead acetate employed by them in their experimental studies.

#### **j) Brain (gm):**

Average weight of brain in different groups did not revealed significant differences, however a non-significant decrease was observed in all treatment group animals when compared with the control group. (Plate-17)

Average weights of brain were found to be  $1.82 \pm 0.13$ ,  $1.67 \pm 0.08$ ,  $1.70 \pm 0.05$  and  $1.69 \pm 0.09$  in T<sub>1</sub>, T<sub>2</sub>, T<sub>3</sub> and T<sub>4</sub> group respectively. Similar finding are reported Ghule (2007) in quails Kale and Bramhankar (2008) in rats during lead toxicity. The lower brain weights in treatment group rats cold be possibly due to neurotoxicity or lower body weights in these groups as a result of lead acetate.

#### **h) Ovaries (gms):**

Average weights of ovaries in treatment group revealed non-significant differences when compared with control group animals.

Average weights of ovaries in T<sub>1</sub>, T<sub>2</sub>, T<sub>3</sub> and T<sub>4</sub> groups were found to be  $0.16 \pm 0.03$ ,  $0.09 \pm 0.007$ ,  $0.14 \pm 0.06$  and  $0.13 \pm 0.01$  respectively. Findings indicated numerical decrease in ovary weights during lead toxicity. Lowest average weight of ovaries was found in T<sub>2</sub> group rats given lead acetate at 500ppm level.

Similar findings are reported by Dorostghoal *et al.* (2011) Ouard *et al.* (2008) and Kale (2008) in female rats given lead acetate. The lower average weights of ovary may be possibly due to specific effect of lead acetate on reproductive organs in female rats or lower body weights in this group.

#### **i) Uterus with vulva (gms)**

Average weights of Uterus with vulva in treatment group revealed non-significant differences when compared with control group animals.

Average weights of Uterus with vulva in group T<sub>1</sub>, T<sub>2</sub>, T<sub>3</sub>, and T<sub>4</sub> were found to be  $1.18 \pm 0.17$ ,  $1.09 \pm 0.15$ ,  $1.17 \pm 0.10$ ,  $1.15 \pm 0.06$  respectively. Lowest average weight of Uterus with vulva was found in T<sub>2</sub> group rats given lead acetate at 500ppm level.

Kale (2008) in female rats given lead acetate reported lower

average weights of uterus possibly due to specific effect of lead acetate on reproductive organs in female rats.

#### 4.6 Histopathological Observations:

Sections of liver, lungs, heart, kidneys, spleen, brain, pancreas, thyroid, ovary, uterus and vulva were suggested to histopathological examination and discussed as follows. Special emphasis was given to the changes observed in sections of ovaries, uterus and vulva to evaluate adverse effect of lead on female rats.

##### a) Liver:

Histopathological examination of sections of liver from control group rats revealed normal hepatic parenchyma with mild congestion. (Plate- 17, 18)

Sections from T<sub>2</sub> group rats showed dilated sinusoids and atrophic hepatic parenchyma with bile duct hyperplasia and degenerative changes in hepatic parenchyma similarly sinusoidal lining showed prominent reticular cells(Kuffeer`s cells). (Plate – 19, 20)

Sections from T<sub>3</sub> group rats revealed normal hepatic parenchyma with normal hepatocytes (Plate – 21).

Sections from group T<sub>4</sub> animals revealed restoration of hepatic parenchyma.(Plate- 22)

Present finding corroborates with those reported by Suradkar *et al.* (2010), which could be possible due to toxic effect of lead in T<sub>2</sub> group.

The histopathological examination of liver sections from T<sub>4</sub> group rats given lead with *P. zeylanica* showed comparatively decreasing trend of degenerative changes in hepatic parenchyma suggesting hepatoprotective effect of *P zeylanica*.

Tilak *et al.* (2004) and Bhargava (1984) described hepatoprotective effect of *P. zeylanica* and its medicinal properties. Hepatoprotective activity of *P. zeylanica* is due to higher content of triterpenes, tannins and flavonoids reported by Rajeshkumar *et al.* (2009).

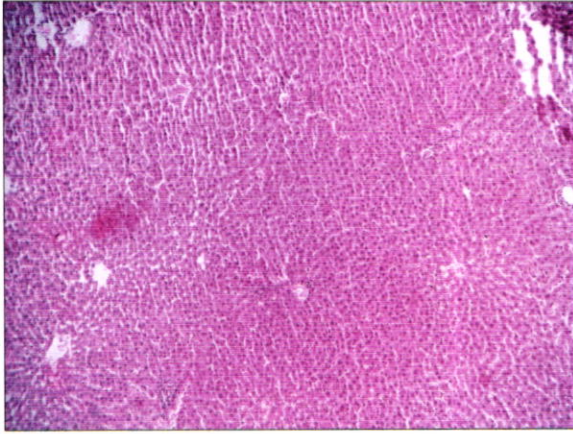


Plate 17 : Section of liver from T<sub>1</sub> group rat showing normal hepatic parenchyma and central lobular vein (100x) H&E.

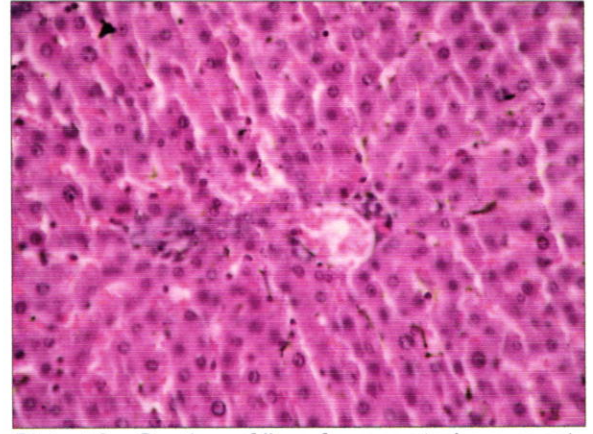


Plate 18: Section of liver from control group rat showing normal hepatic parenchyma (400x) H&E.

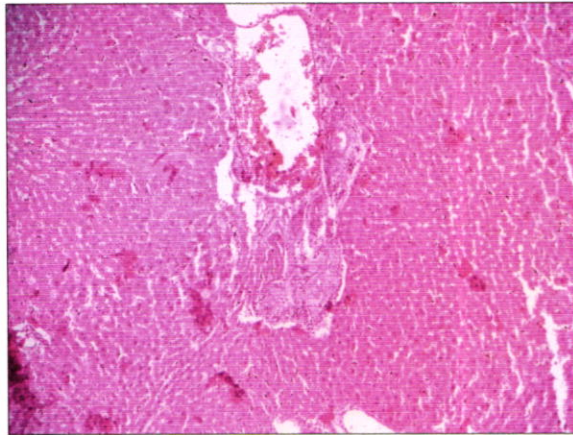


Plate19 : Section of liver from T<sub>2</sub> group rat showing dilated sinusoids and atrophic hepatic parenchyma (200x) H&E.

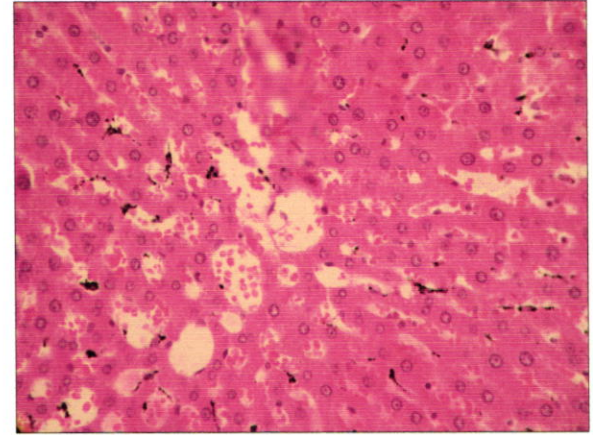


Plate 20 : Section of liver from T<sub>2</sub> group rat showing dilated sinusoids, atrophic parenchyma and hyperplasia of reticular cells (400x) H&E.

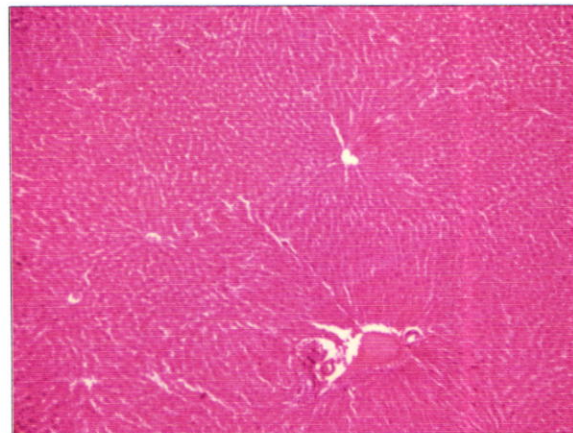


Plate 21 : Section of liver from T<sub>3</sub> group rat normal hepatic parenchyma (100 x) H&E.

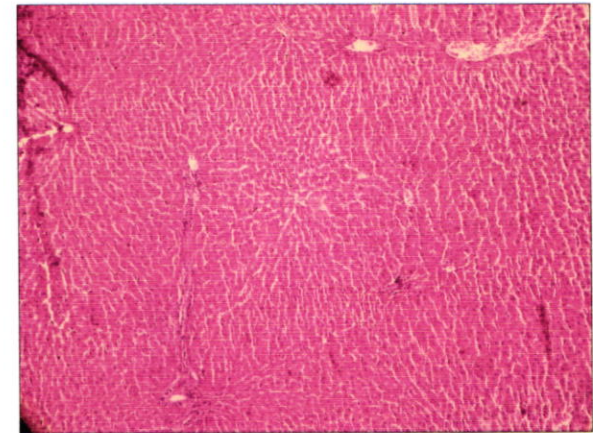


Plate 22 : Section of liver from T<sub>4</sub> group rat showing restoration of hepatic parenchyma (100 x) H&E.

### **b) Lungs:**

Sections of lung from T<sub>1</sub> and T<sub>3</sub> group animals revealed normal alveolar parenchyma (Plate-23) and mild venous congestion with round cell infiltration. (Plate-24) Similar observation of varying degree are also observed in T<sub>4</sub> group animals given lead and *P. zeylanica* alone or in combination. These groups also revealed focal areas of round cell infiltration with normal bronchiolar mucosa.

Present finding corroborates with reported Kale(2008) in female rats and Brahmanekar (2008) in male rats.

Tilak *et al.* (2004) described use of *P. zeylanica* for bronchitis, anemia and hepatic disease.

### **c) Heart:**

Sections of heart from control (T<sub>1</sub>) group rats revealed normal architecture of myocardium.

In T<sub>2</sub> group rats section revealed congestion and severe hemorrhages in epicardium and myocardium. (Plate 25) Section from T<sub>3</sub> group rats revealed normal parenchyma of heart.

In T<sub>4</sub> group rats also section revealed normal parenchyma, myocardium and epicardium. (Plate – 26).

Present finding corroborates with those reported by Rahaman (2006) in broilers which could be possibly due to either direct toxic effect of lead or hypoxic injury to cardiac muscle as result of anemia in lead treated groups. It is also reported by Autade (2010) in quails and Kale (2008) and Chandra *et al.* (2010) in rats during lead toxicity.

Normal parenchymal and myocardial structure in T<sub>4</sub> group rats revealed protective effect of *P. zeylanica* considering the short duration of experiment, Tilak *et al.* (2004) reported cardiogenic, antiatherosclerotic and anticoagulant properties of *P. zeylanica*.

### **e) Kidneys:**

Sections of kidneys from T<sub>1</sub> and T<sub>3</sub> group rats revealed normal tubular and glomerular epithelium (Plate 27). Two sections revealed mild venous

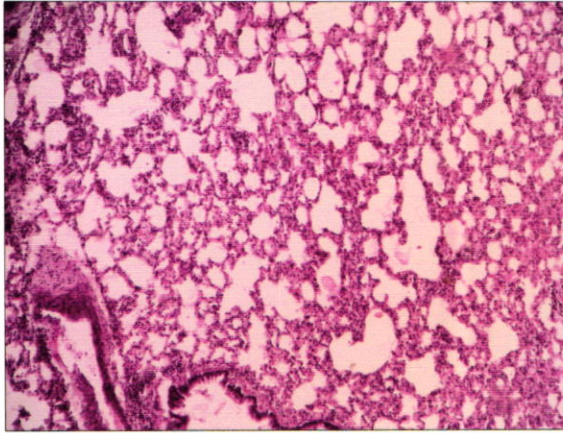


Plate 23 : Section of lung from T<sub>1</sub> (Control) group rat showing normal structure of Alveoli (100x) H&E.

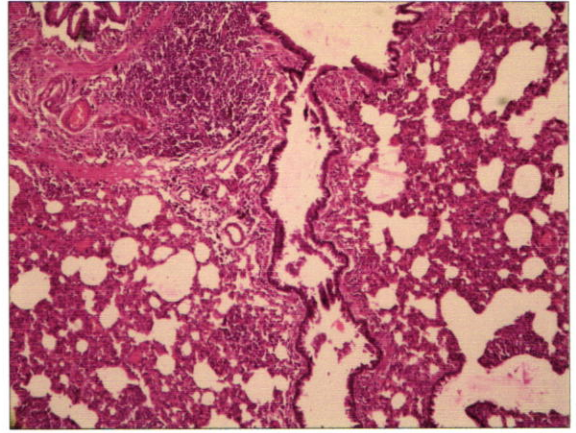


Plate 24 : Section of lung from T<sub>3</sub> group rat showing congestion and round cell infiltration (200x) H&E.

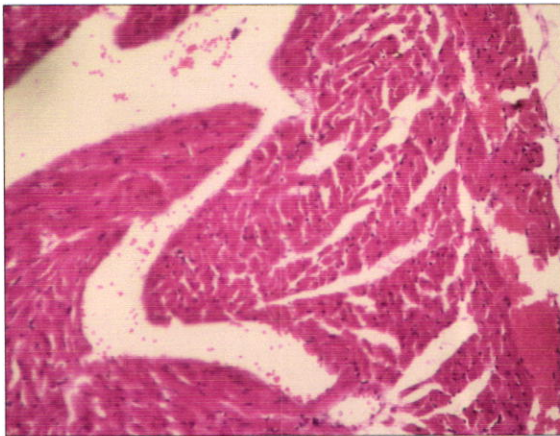


Plate 25 : Section of heart from T<sub>2</sub> group rat showing myocardial congestion and haemorrhages (200x) H&E.

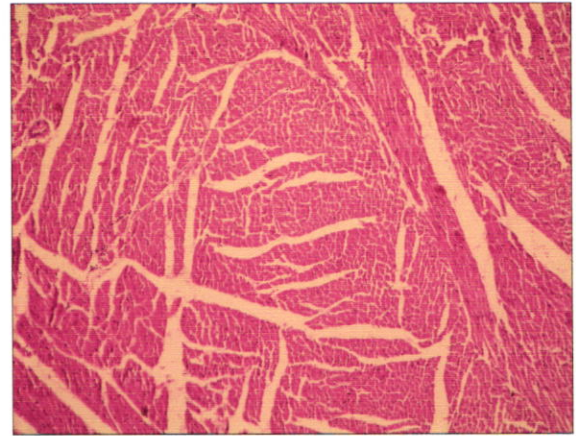


Plate 26 : Section of heart from T<sub>4</sub> group rat showing normal parenchyma & myocardium (100x) H&E.

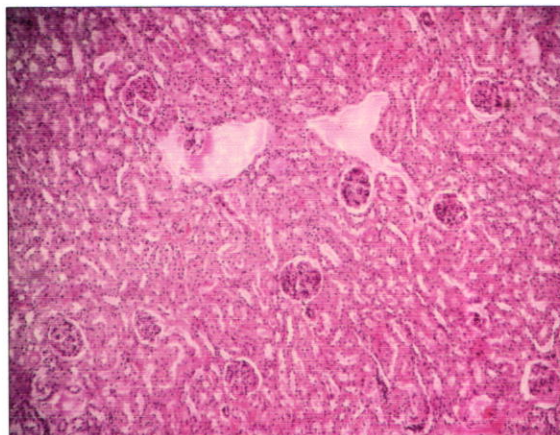


Plate 27 : Section of kidney from T<sub>1</sub> (control) group rat showing normal tubular epithelium & glomeruli (100x) H&E.

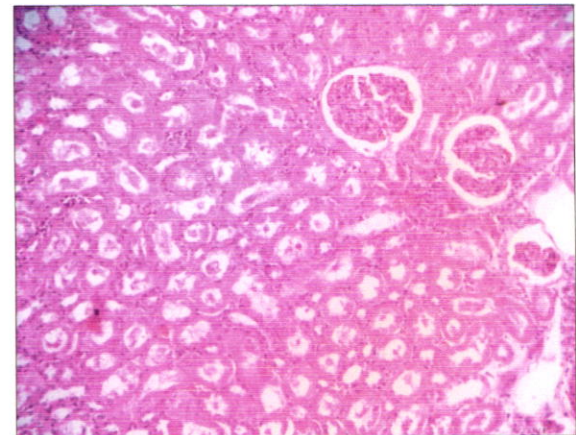


Plate 28 : Section of kidney from T<sub>2</sub> group rat showing desquamated epithelium in lumen & tubular nephrosis (200x) H&E.

congestion.

Sections from most of the T<sub>2</sub> group rats revealed venous congestion and focal areas of hemorrhages. Sections also revealed tubular nephrosis with desquamation of epithelial cells in the lumen of the tubule (Plate-28).

Sections from T<sub>4</sub> group rats revealed degenerative changes in tubular epithelium (Plate - 29). Thus, indicating limited use of *P. zeylanica* for protecting lead induced nephrotoxicity.

Findings of T<sub>2</sub> group rats corroborate with those reported by Garg (2000) describing the cause to be due to higher accumulation of lead concentration in kidney. Similar finding of nephrotoxicity of lead is reported by Deshmukh (2006) and Ghule (2007). There was limited restoration of tubular architecture in rats receiving *P. zeylanica* with lead as compared to the rats receiving only lead acetate. Thus, nephroprotective effect of *P. zeylanica* during lead toxicity needs further confirmation as the duration of the present experiment was only of 4 weeks. However, it is evident that *P. zeylanica* fails to restore renal damage caused due to lead toxicity.

#### **d) Spleen:**

Sections of spleen from control (T<sub>1</sub>) group and (T<sub>3</sub>) group rats revealed normal splenic follicles and connective tissue septa with abundant lymphoid population (Plate – 30).

Sections of spleen in T<sub>2</sub> group rats revealed congestion and depletion of lymphoid population. (Plate – 31).

Sections from T<sub>4</sub> group rats revealed small size lymphoid follicles and germinal centers with moderate lymphoid population.

Present finding corroborates with those reported Ghule (2007) and Wagh (2006) in quails and broilers. This could be possibly due to decreased in average weights of spleen in treatment groups rats as a result of toxic action of lead causing immunosuppression suggested by Rahaman (2006).

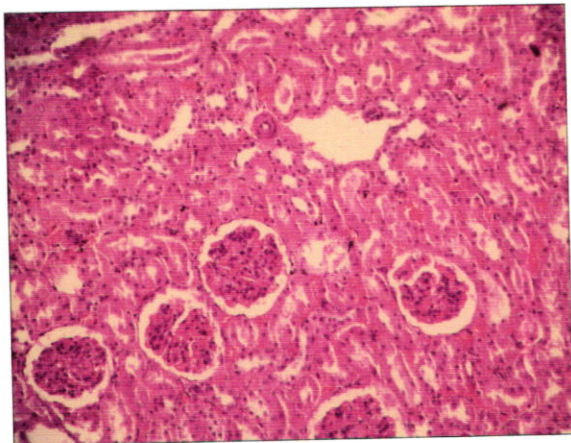


Plate 29 : Section of kidney from T<sub>4</sub> group rat showing changes in tubular epithelium (200x) H&E.

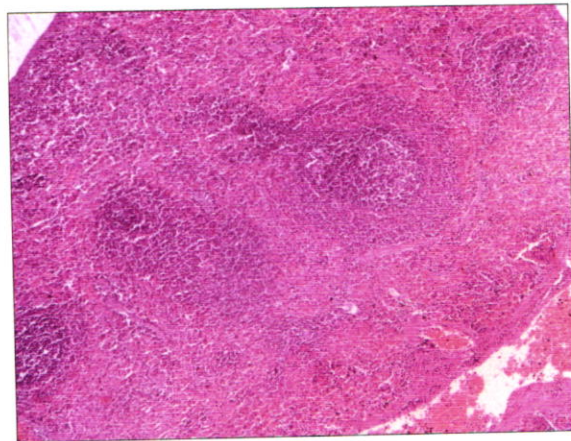


Plate 30: Section of spleen from T<sub>1</sub> group rat showing normal lymphoid population (100x) H&E.

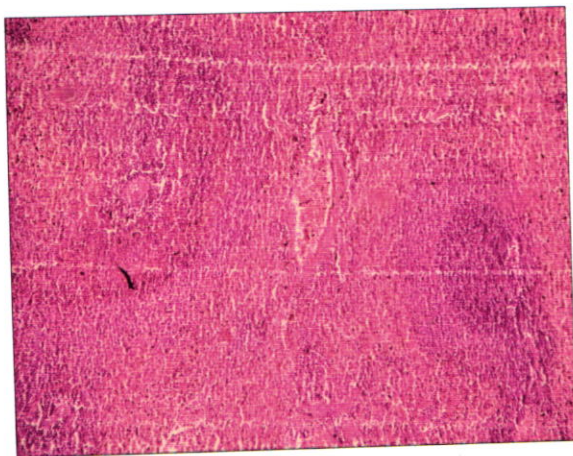


Plate 31 : Section of spleen from T<sub>2</sub> group rat showing congestion and depopulation of lymphocyte (100x) H&E.

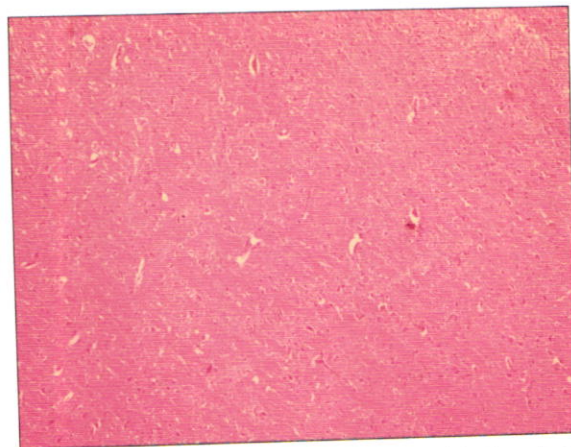


Plate 32 : Section of brain from T<sub>1</sub> (control) group rat showing normal parenchyma (100x) H&E.

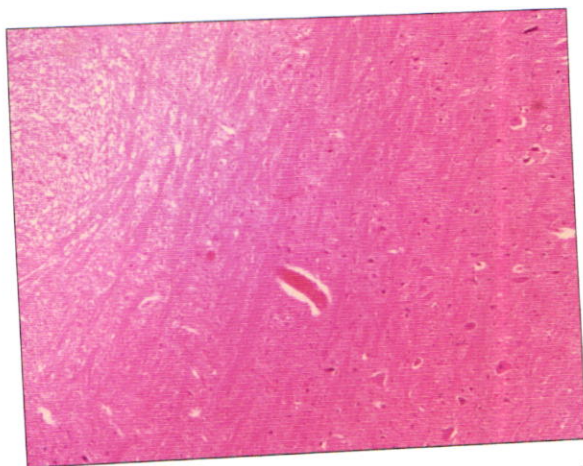


Plate 33 : Section of brain from T<sub>2</sub> group rat showing congestion and edema (200x) H&E.

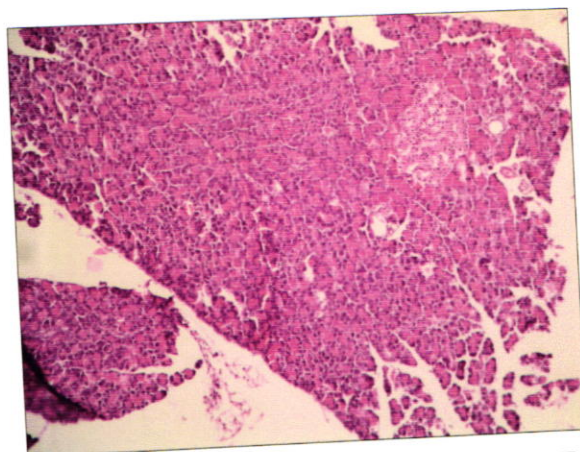


Plate 34 : Section of pancreatic islet from T<sub>2</sub> group rat showing granular and degenerative changes (400x) H&E.

Moderate lymphoid population in T<sub>4</sub> group rats revealed protective effect of *P. zeylanica* as useful medicinal properties describe by Tilak *et al.*(2004).

**f) Brain:**

Sections of brain from T<sub>1</sub> and T<sub>3</sub> group rats revealed normal brain parenchyma (Plate – 32). Mild venous congestion in few sections.

Sections from T<sub>2</sub> group rats revealed sever venous congestion and edema. (Plate – 33).

Sections from T<sub>4</sub> group rats revealed mild venous congestion.

Similar observations are reported by Ghule (2007)in quails and Kale (2008) in rats exposed to lead toxicity.

Deshmukh (2006) described changes in brain parenchyma during lead toxicity possibly due to either direct toxic action or hypoxic injury.

T<sub>4</sub> group rats reveled normal parenchyma suggesting the neuroprotective effect of *P. zeylanica* as described by Tilak *et al.* (2004).

**g) Pancreas**

Histopathological examination of sections of pancreas from T<sub>1</sub> and T<sub>3</sub> group animals reveled normal islet tissue and normal pancreatic acini. (plate-36)

In T<sub>2</sub> group animals sections revealed similar structure with mild granular and vacuolar changes in pancreatic islets showing toxic effect of lead. (Plate- 34 & 35)

Sections from T<sub>4</sub> group animals also revealed normal beta islets and pancreatic acini.

Present observations corroborates with those reported by Ghule (2007) in quails. Deshmukh (2006) in broilers reported increase average pancreatic weights in treatment group birds given lead acetate with significant decrease in serum glucose level suggesting possible toxic effect of lead on endocrine pancreas. This could be possibly due to species difference.

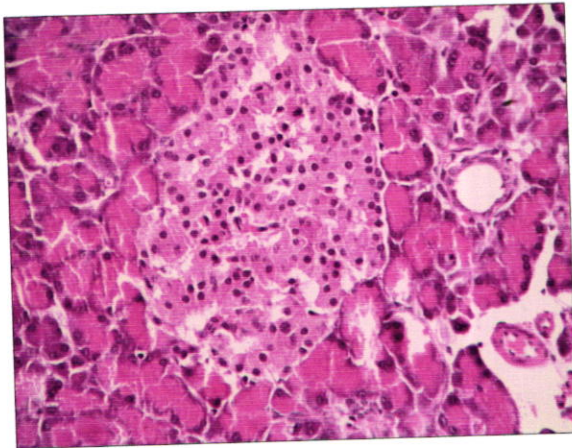


Plate 35 : Under high power Section of pancreatic islet from T<sub>2</sub> group rat showing granular and degenerative changes (400x) H&E.

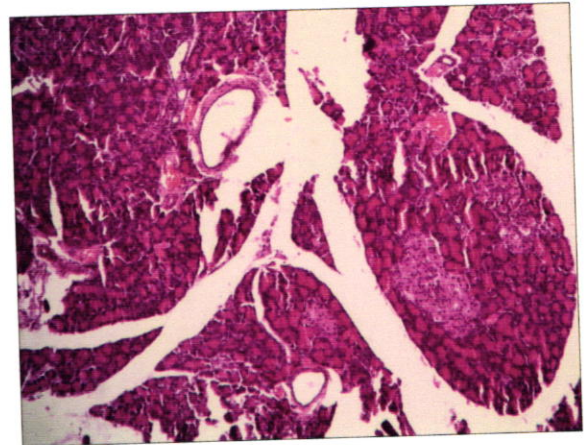


Plate 36 : Section of pancreatic islet from T<sub>3</sub> group rat showing normal pancreatic islet and mild congestion (100x) H&E.

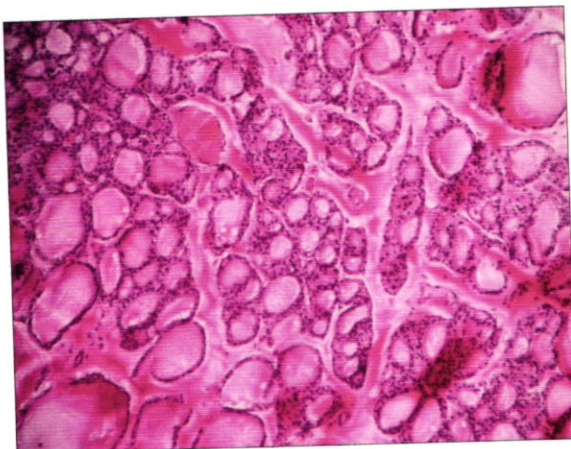


Plate 37 : Section of thyroid from T<sub>1</sub> (Control) group rat showing normal thyroid follicular structure (100x) H&E.

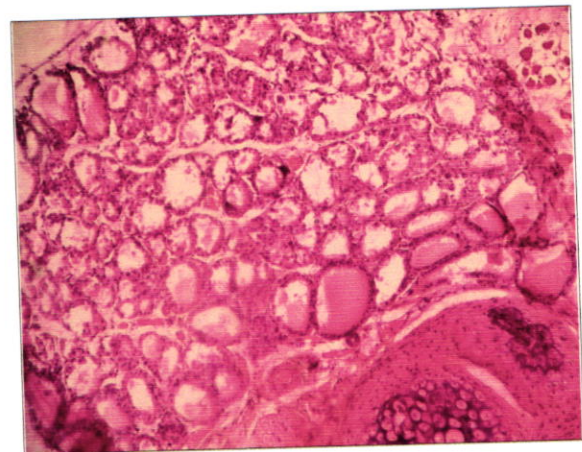


Plate 38 : Section of thyroid from T<sub>2</sub> group rat showing colloid and resorption of colloid (200x) H&E.

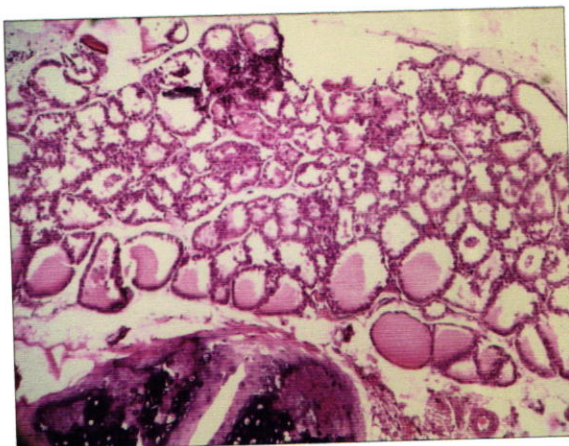


Plate 39 : Section of thyroid from T<sub>3</sub> group rat showing normal colloid resorption and pale colloid (100x) H&E.

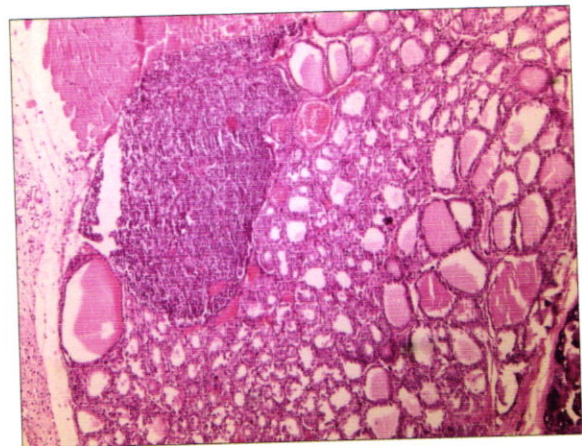


Plate 40 : Section of thyroid from T<sub>4</sub> group rat showing focal round cell infiltration (200x) H&E.

## **h) Thyroid**

Histopathological examination of sections of thyroid from (T<sub>1</sub>) control group rats showing normal accumulation and resorption of colloids. (Plate -37)

Sections from T<sub>2</sub> group rats showed resorption of colloid. (Plate 38)

Sections from T<sub>3</sub> group rats revealed normal secretion of follicle with resorption of colli. (Plate – 39)

Sections from group T<sub>4</sub> animals revealed lymphoid aggregation with variation in size of follicles. (Plate - 40)

Literature did not revealed information regarding effect of lead toxicity on the histomorphological changes in thyroid gland.

## **I) Ovary**

Histopathological examination of sections of ovary from control group rats showing various stages of developing follicles. (Plate-41 & 42)

Sections from T<sub>2</sub> group rats showed severe congestion, haemorrhages and decreased no of follicles. (Plate – 43 )

Sections from T<sub>3</sub> group rats revealed severe congestion and arrest of developing follicles. (Plate – 44)

Sections from group T<sub>4</sub> animals revealed decrease number of developing follicles with severe congestion. (Plate – 45)

Present finding corroborates with those reported by Mohammad *et al.* (1997) in mice and Taupaeu *et al.* (2001) and Azarnia *et al.* (2004) ouarda *et al.* (2008) Dorostghoal *et al.*(2011) in rats.

Kale (2008) indicated adverse effect of lead on development and functional status of ovaries in rats which could be confirmed from lower average weights in treatment groups and histopathological changes.

Sections of T<sub>3</sub> group shows severe congestion and arrest of follicles suggesting negative effect of *P zeylanica* on ovary.

Due to toxic effect of lead and harmful effect of *P. zeylanica* on

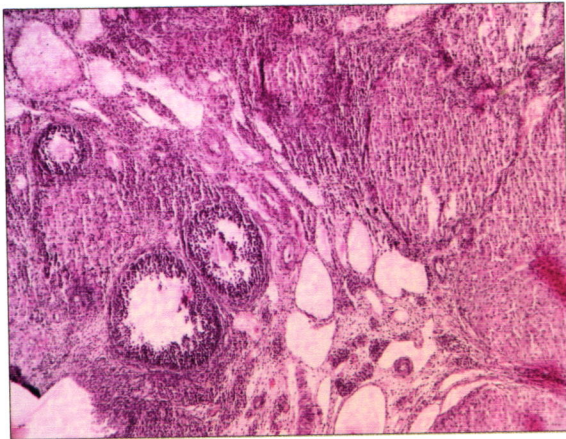


Plate 41 : Section of ovary from T<sub>1</sub> (control) group rat showing developing follicles (100x) H&E.

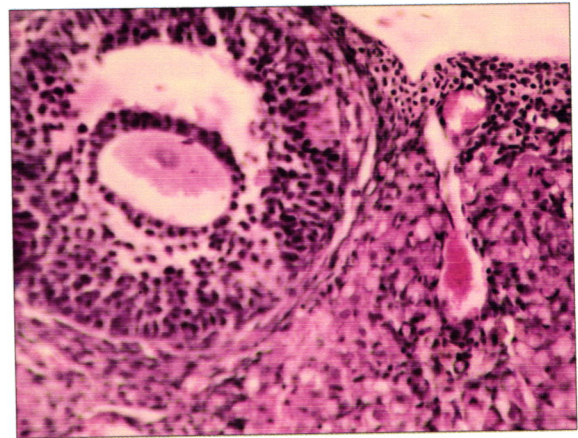


Plate 42 : Section of ovary from T<sub>1</sub> (control) group rat showing developing follicles (antrum) (400x) H&E.

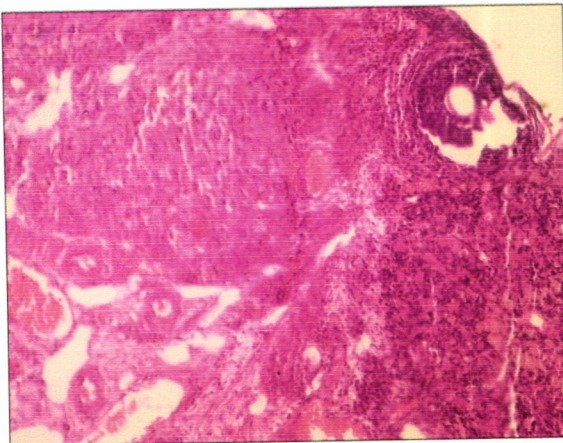


Plate 43 : Section of ovary from T<sub>2</sub> group rat showing sever congestion, haemorrhages and decrease number of follicles (100x) H&E.

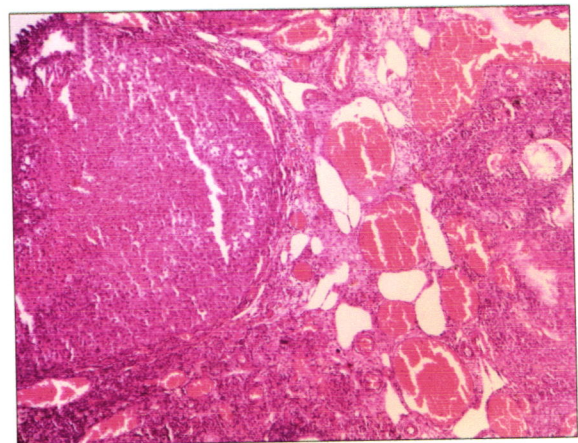


Plate 44 : Section of ovary from T<sub>3</sub> group rat showing sever congestion arrest of developing follicles (200x) H&E.

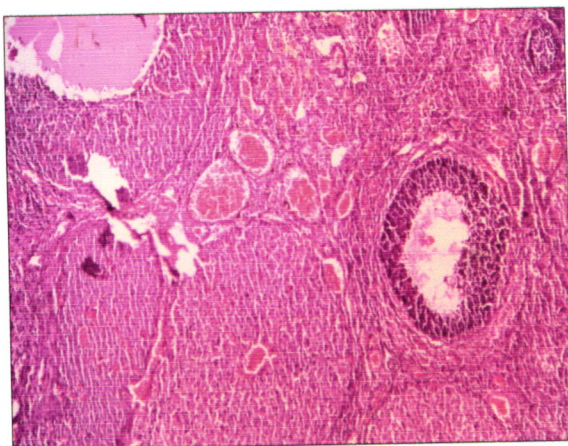


Plate 45 : Section of ovary from T<sub>4</sub> group rat showing decrease number of developing follicle with sever congestion (200x) H&E.

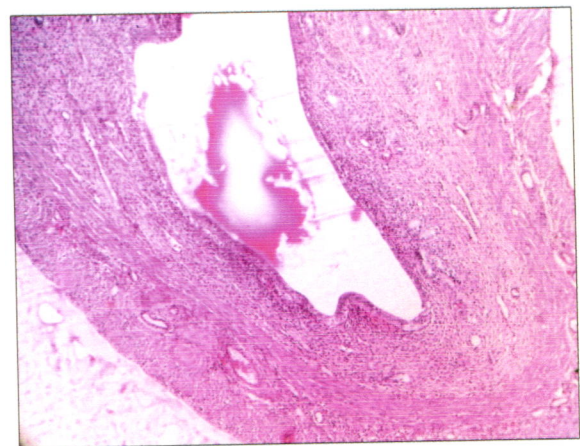


Plate 46 : Section of uterus from T<sub>1</sub> (control) group rat showing myometrium along with glandular epithelium (100x) H&E.

ovary sections of T4 group animal shows decrease no of developing follicles with severe congestion.

Present observation in *P. zeylanica* given groups along with lead are in agreement with those reported by Premakumari *et al.* (1997) describing antifertility activity of plumbagin due to antioovulatory effect.

#### **j) Uterus:**

Histopathological examination of sections of uterus from control group animals revealed normal endometrium and myometrium with glandular epithelium.(Plate – 46 )

In T2 group animals sections revealed thinning of myometrium and congestion with proliferating endometrial gland. (Plate–47 & 48 )

Sections from T3 group rats revealed endometrial glandular hyperplasia and congestion

Sections from T4 group rats revealed myometrium congestion, and glandular hyperplasia.(Plate –49).

These findings corroborate with those described by Tchernitchin *et al.* (2003) who reported edema in the superficial and deep endometria, luminal epithelial hypertrophy and mitotic response in all uterine cells type were inhibited by lead exposure in the prepubertal rats. This could be possibly due to prepubertal rats used during their studies.

Kale (2008) suggested adverse effect of lead on uterus of rats.

Sections from T<sub>4</sub> group rats also revealed myometrial congestion, and glandular hyperplasia thus indicating failure of *P. zeylanica* to protect lead induced damage.

Premakumari *et al.* (1997) described antifertility activity of plumbagin of *P. zeylanica*.

#### **k) Vulva**

Histopathological examination of sections of vulva from control group animals revealed normal stratified and psuedostratified epithelial

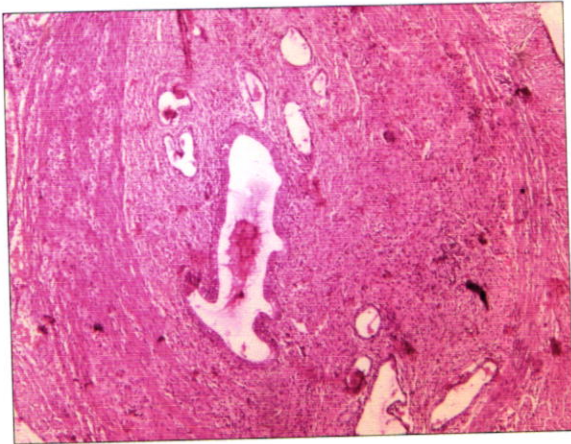


Plate 47 : Section of uterus from T<sub>2</sub> group rat showing thinning of myometrium and congestion with proliferating endometrial glands (200x) H&E.

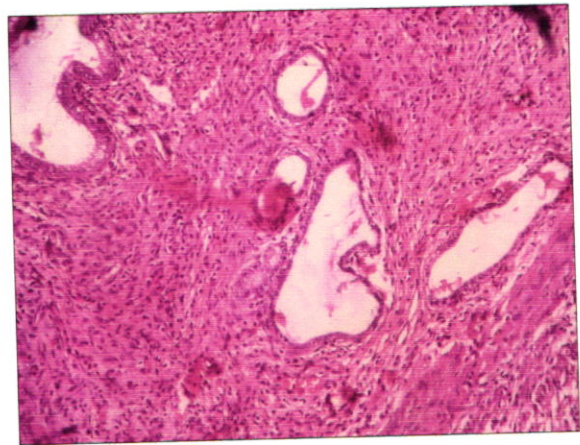


Plate 48 : Section of uterus from T<sub>2</sub> group rat showing hyperplasia of endometrial gland (200x) H&E.

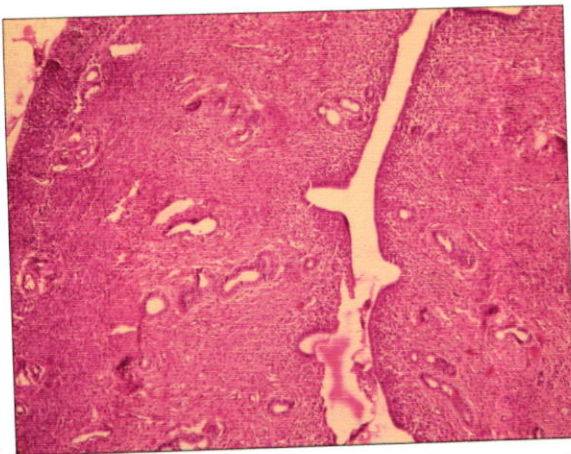


Plate 49 : Section of uterus from T<sub>4</sub> group rat showing glandular hyperplasia (100x) H&E.

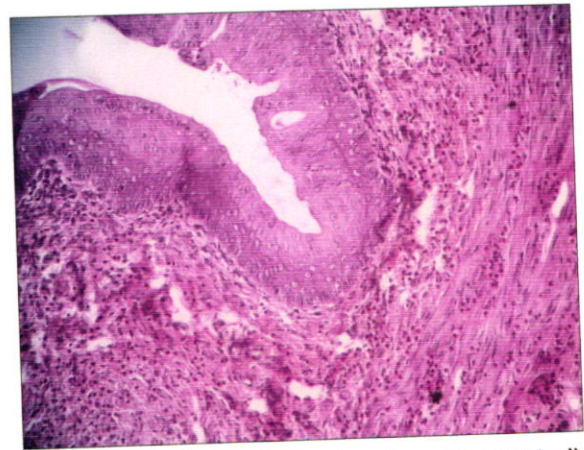


Plate 50 : Section of vulva from T<sub>1</sub> (control) group rat showing normal stratified and pseudostratified epithelium layer (200x) H&E.

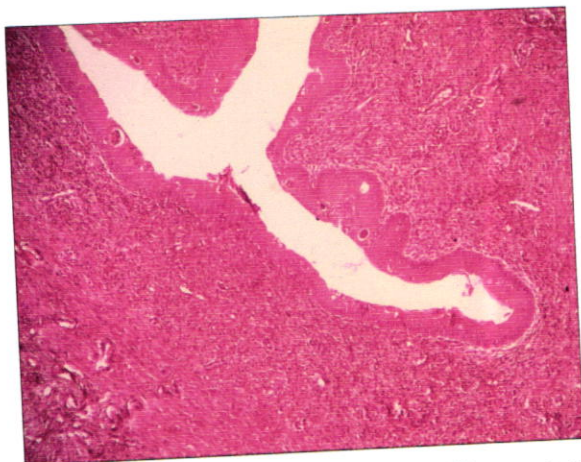


Plate 51 : Section of vulva from T<sub>3</sub> group rat showing stratified squamous epithelium (100x) H&E.

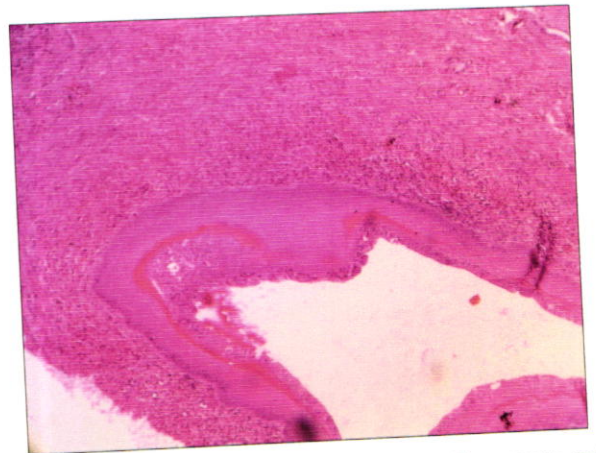

Plate 52 : Section of vulva from T<sub>4</sub> group rat showing desquamation of cornification of mucosa and absence of gland (100x) H&E.

layer.(Plate –50).

In T2 group animals desquamated and thin stratified squamous epithelium. Sections from T3 group rats revealed thin stratified squamous epithelium. (Plate – 51).

Sections from T4 group rats revealed desquamated stratified squamous epithelium, cornification of mucosa and absence of gland.(Plate – 52).

Literature did not revealed information regarding effect of lead toxicity on the histomorphological changes in vulva .

Present findings thus indicated adverse effect of lead on development of vulva in rats and failure of *P. zeylanica* to protect lead induced damage .



Chapter - V

**Summary  
&  
Conclusions**



## CHAPTER – V

### SUMMARY AND CONCLUSION

Present investigations on "Pathology of experimental lead toxicity and effect of *Plumbago zeylanica* in female rats (*Rattus norvegicus*) with special reference to reproductive organs" were undertaken in the Department of Pathology, Post Graduate Institute of Veterinary and Animal Sciences, Akola.

Twenty four non pregnant Wistar adult female rats of 6-7 weeks of age were divided in four groups after completion of one week acclimatization period Group I rats (T<sub>1</sub>) rats were given adlib pelleted diet with normal water however group II, and IV (T<sub>2</sub> and T<sub>4</sub>) rats were given same diet and 500ppm lead acetate in drinking water. Group T<sub>3</sub> and T<sub>4</sub> were given ethanolic extract of dry root powder of *Plumbago zeylanica* at 100mg/kg body wt/day. orally for the period of 4 weeks. Animals were maintained under standard managemental conditions.

Studies included effect of lead acetate on general performance, clinical symptoms, hematological, radiological and biochemical investigations at the end of 4th week. On completion of 28 days rats from each group were sacrificed to study gross pathological changes and effect on different organ weights. Tissues of liver, lung, heart, kidney, spleen, brain, pancrease, thyroid, ovary, uterus and vulva were collected for histopathological examination.

General parameters included clinical observations, feed consumption, water consumption, weekly body weights and weekly body weight gain. T<sub>2</sub> group rats revealed brown coloured foul smelling feces, weakness, lethargy, palmer grasping and aimlessly biting to cages, climbing on each other in the cages and ruffled fur coat as a result of toxic effect of lead on central nervous system. These changes were not evident in remaining groups.

Average feed consumption and water consumption was found to be lowest (600.89gms) and (187.67mls) respectively. Significant decrease was observed in T<sub>2</sub> and T<sub>4</sub> group when compare with control group. However better performance was observed in T<sub>4</sub> group given *P. zeylanica* with lead when compare with T<sub>2</sub> group suggesting beneficial effect of *P. zeylanica* during lead toxicity.

Mean values were found comparable of T<sub>1</sub> and T<sub>2</sub> group however significant decrease was observed in T<sub>2</sub> and T<sub>4</sub> group. T<sub>4</sub> group rats given lead with *P.zeylanica* showed better weight gain when compare with T<sub>2</sub> group showing beneficial effect of *P. zeylanica* during lead toxicity.

Hematological observation indicated significant difference in Hb and PCV however TEC, MCV, MCH and MCHC values showed non-significant differences. Lowest hematological values were observed in T<sub>2</sub> group rats given lead acetate; however rats given lead with *P. zeylanica* showed improvement in hematological parameter suggesting hematinic properties of *P. zeylanica* during lead toxicity. Anemia observed in T<sub>2</sub> group rats was morphologically appeared as microcytic hypochromic.

TLC and absolute neutrophil and lymphocyte count showed significant differences in treatment group rats when compare with control group. T<sub>2</sub> group rats showed leucopenia and relative increase in absolute neutrophil count, absolute lymphocyte count when compare with control and other treatment groups. Values were found to be improved in T<sub>4</sub> group when compared with T<sub>2</sub> group suggesting adverse effect of lead on leucopoiesis and beneficial effect of *P. zeylanica* as evident of T<sub>4</sub> group during lead toxicity.

Biochemical parameter at the end of four weeks indicated significant decrease in calcium and non-significant decrease in total protein in T<sub>2</sub> group when compare with values of T<sub>1</sub>, T<sub>3</sub> and T<sub>4</sub> groups. Similarly T<sub>2</sub> groups also revealed hyperphosphatemia and significant increase in values of creatinine, AST, and ALT values and non-significant increase in glucose values suggestive nephrotoxic and hepatotoxic effect of lead.

Blood glucose levels though revealed numerical decrease in T<sub>3</sub> group when compare with T<sub>1</sub> and T<sub>2</sub> when compare with T<sub>4</sub> showed hypoglycemic action of *P.zeylanica* with or without lead.

Radiographic examination of two rats from each group at the end of 4th week did not revealed marked differences in skeleton of treatment group

and control group rats. Studies thus indicated that 4 weeks of experimental lead toxicity in rats fails to indicate effect on skeleton deformities.

Six rats from each group were sacrificed at the end of 4th week to study gross pathological changes and organ weights of liver, lung, heart, spleen, kidneys, brain, uterus, ovary and vulva. Tissues from these organs were also collected for histopathological examination. During necropsy treatment group rats revealed congested female genital organs with decrease in size of most of the organs.

Organ weights of liver revealed significant and lung, heart, kidneys, brain, spleen, ovary, uterus and vulva in treatment group rats did not reveal significant differences when compared with control group rats. However, rats given lead acetate (T<sub>2</sub>) showed lower average weights of liver, lung, heart, kidneys, brain, spleen, ovary, uterus and vulva indicating toxic effect of lead on average organ weight. Birds given lead acetate with *P. zeylanica* at 100 mg /kg body wt level showed improvement in organ weight of liver, lung and heart.

Histopathological examinations in control group rats revealed normal histomorphology of liver, lung, heart, kidney, brain, spleen, pancreas, thyroid, ovaries uterus and vulva. Sections of liver from T<sub>2</sub> group showing dilated sinusoids atrophic hepatic parenchyma and hyperplasia of bile duct and Kuffer's cells. In T<sub>4</sub> group, liver sections showed comparatively normal hepatic parenchyma and restoration of their changes.

Sections of lung revealed mild congestion however kidney revealed necrosis, congestion and hemorrhages with desquamation of tubular epithelium. Sections of heart revealed congestion, hemorrhages and spleen showed depletion of lymphoid population. Thyroid showed desquamation of follicular epithelium and sections of ovary showed irregular degenerating follicle with sever congestion and increase stroma suggesting adverse effect of lead on these organs.

Sections of uterus showed thinning of myometrium and hyperplasia of endometrial glands however sections of vulva did not revealed

much histomorphological changes except thinning of mucosa. These changes in ovary, uterus was also evident in T<sub>3</sub> and T<sub>4</sub> group indicating adverse effect of both lead and *P. zeylanica* on reproductive organs.

From present investigation following conclusions were drawn.

1. Lead toxicity in rats cannot be confirmed on basis of clinical symptoms as clinical symptoms are not specific
2. Lead toxicity at 500 ppm levels adversely affected performance of rats i.e. feed consumption, water consumption average weekly body weight and average weekly body weight gain. During lead toxicity with *P. zeylanica* dry root extract showed better performance suggesting it's utility.
3. Lead toxicity adversely affect hemopoietic and leucopoietic system and *P. zeylanica* dry root powder extract during lead toxicity showed improved values suggesting it's hematinic properties
4. Biochemical parameter indicated hepatotoxic and nephrotoxic effect of lead acetate @ 500 ppm level and hypoglycemic action of *P. zeylanica*.
5. Gross and histopathological changes indicated adverse effect of lead on visceral and reproductive organs. Extract of *P. zeylanica* was found to be useful as hepatoprotective, however changes in kidney and reproductive organs did not reveal it's beneficial properties during experimental lead toxicity in rats.

On the basis of observation during present investigation it is thus concluded that lead toxicity did not show pathognomic lesion suggestive of diagnosis in rats. Extract of *P. zeylanica* was found useful as heptoprotective during lead toxicity but showed adverse effect on female reproductive organs.



# ***Bibliography***



## BIBLIOGRAPHY

- Adejumo, A. L. Kolapo, O. P. Roleol and L.S. Kasim (2010) *In vitro* antisickling activities and hytochemical evaluation of *Plumbago zeylanica* and *Uvaria chamae*. African Journal of Biotechnology Vol. 9(53), pp. 9032-9036.
- Ajayi, G. O., T. T. Adeniyi and D. O. Babayemi (2009) Hepatoprotective and some hematological effects of *Allium sativum* and vitamin C in lead-exposed Wistar rats. *Intr. J. Med. and medical Sci.* 1 (3) : 64-67.
- Alluri K.V., RVN Tayi, S Dodda and V Mulabagal (2005). Assessment of bioactivity of Indian medicinal plants using brine shrimp (*artemia salina*) lethality assay, 32: 125-134.
- Aquili, F., M. Zahin and I. Ahmad (2008). Antimutagenic activity of methanolic extract of four ayurvedic medicinal plants. *Indian J. Expt. Biol.* 46 ; 668.
- Ariyanathan S., A. Saraswathy and G. Victor Rajamanickkam (2011) Phytochemical Investigation of *Plumbago capensis* Thunb. *International journal of pharmacy & life sciences* 2(4): April
- Ashour, A. E., M. M. Yassin., N. M. AbuAssi and R. M. Ali (2007) Blood, serum glucose and renal parameters in lead loaded albino rats and treatment with some chelating agents and natural oils. *Turk. J.Biol.* 31 : 25-34.
- Ashraf S. yousif and Asma A. Ahmed (2010) Effects of Cadmium and Lead on the structure and function of thyroid gland. *Africa Journal of Animal and Biomedical Sciences* 5 (1),
- ATSDR (2003). Information centre of agency for toxic substances & disease registry Vodela, J.K., J.A. Renden, S.D. Lenz, W.H. McElhenney and B.W. Kempainan (1997) Drinking water contaminants

(arsenic, cadmium, lead, benzenes and trichloroethylene). 1. Interaction of contaminants with nutritional status on general performance and immune function in broiler chickens. *Poultry Science*. 76 (11): 1474-1492.

Autade (2010) Effect of *Allium sativum linn. powder* in experimentally induced lead toxicity in Japanese quails (*Coturnix coturnix Japonica*) M.V.Sc. Thesis submitted to MAFSU, Nagpur.

Azarnia M., A. Shakour, P. Rostami and A. Sanaie-Mehr., (2004): The protective role of L-cystine against follicular atresia induced by lead in mouse ovary. *Journal of Acta Medica Iranica*, 42(2): 83-88

Babalola O. O, R. E. Okonji, J. O. Atoyebi, T. F. Sennuga, M. M. Raimi, E. E. Ejim-Eze (2010) distribution of lead in selected organs and tissues of albino rats exposed to acute lead toxicity. *Scientific research and essay vol. 5(9)*, : 845-848.

Babalola O.O, Ojo LO, Aderemi MO (2005). Lead levels in some biological samples of automechanics in Abeokuta, Nigeria. *Indian J. Biochem. Biophys.* 42: 401-403.

Badiei, K, P. Nikghadam,; K. Mostaghni and M. Zarifi, (2010) effect of lead on thyroid function in sheep *iranian Journal of Veterinary Research, Shiraz University, Vol. 10, No. 3*

Barasa M M., L. Wilber, I. Ndiege and C.C. Wanjala (2009) Larvicidal activity of extracts from three *Plumbago* spp against *Anopheles gambiae* . *Mem Inst Oswaldo Cruz, Rio de Janeiro, Vol. 104(6)*: 813-817

Barbosa F, J. E. Tanus-Santos, R. F. Gerlach and P. J. Parsons (2005) A Critical Review of Biomarkers Used for Monitoring Human Exposure to Lead: Advantages, Limitations, and Future Needs. *Environmental Health Perspectives* 113 (12) : 1669-1674.

Bartels, H. (1972) *Clin. Chem. Acta* 37: 193.

Benjamin, M. M. (2001). *Outline of Veterinary Clinical Pathology*, 3<sup>rd</sup> Edn. Kalyani Publisher, Ludhiana.

Bhargava, S. K. (1984). Effect of Plumbagin on reproductive function of male

dog. *Indian J. Expt. Biology.* 22(3) : 153-156.

Bopaich, C. P. and N. Pradhan (1999). Central nervous system stimulatory action from the root extract of *Plumbago zeylanica* in rats. *J. Phytotherapy Research.* 15(2) : 153-156.

Brahmankar, M. G. (2008). Pathology of experimental lead toxicity in male rats (*Rattus norvegicus*) with special reference to histopathological changes in reproductive organs. M.V.Sc. Thesis submitted to, MAFSU, Nagpur.

Brar, R. S. (1994). Studies on clinicopathological, biochemical and histoenzymological alterations in lead toxicosis in domestic fowl and buffalo calves. *Indian J. Vet. Pathology.* 18(1) : 69-69 (Thesis Abst.).

Cetin N., D. Essiz, G. Eraslan and H. Saltas (2004) Effects of chronic lead intake via drinking water on some hematological parameters in mice. *E.U. J. of Health Sci.*, 13 (3) : 59-63.

Chandra S, A.K. Srivastava and S. Kumar (2010) Pathomorphological and haematological changes in experimentally induced lead toxicity in rats. *Indian J. Vet. Pathology.* 34(2) : 162- 167.

Chen T. E. K. A. Golemboski, R. S. Ha, T. Bunn, F. S. Sanders, and R. R. Dietert (2004) developmental exposure to lead causes persistent immunotoxicity in fischer 344 rats *toxicological sciences* 42, 129-135

Chetty, M., K. G. Sundarsamam and P. Hindusekar (2006). Pharmaceutical studies and therapeutic cases of *Plumbago zeylanica* L. roots (Chitraka, Chitramulamu). *Ethnobotanical Leaflets.* 10 : 294-304.

Dai Y, L.F. Hou, Y. P. Chan, L. Cheng, P.P. H. Bur (2004) Inhibition of immediate allergic reactions by ethanol extract from *Plumbago zeylanica* stems. *Biol Pharm Bull* 27, 429-432.

- Dalia, M. El-Nahal (2010). Effect of using pectin on lead toxicity. *The Journal of American Science* 6(12): 541-554.
- Deshmukh S.V. (2010) Effect of *Emlica officinalis*. powder in experimentally induced lead toxicity in Japanese quails (*Coturnix coturnix Japonica*). M.V.Sc. Thesis submitted to MAFSU, Nagpur.
- Deshmukh, P. S. (2006) Pathology of experimental lead toxicity in broilers. M.V.Sc. Thesis submitted to MAFSU, Nagpur.
- Dev S (1997). Ethnotherapeutic and modern drug development: The potential of Ayurveda. *Cur. Sci.*, 73(11): 909-928.
- Dhale, D.A and S.K. Markandeya (2011) Antimicrobial and Phytochemical Screening of *Plumbago zeylanica* Linn. (Plumbaginaceae) Leaf *Journal of Experimental Sciences* Vol. 2, Issue 3, Pages 04-06
- Dorostghoal M., A. Dezfoolian, F. Sorooshnia (2010) Effects of Maternal Lead Acetate Exposure during Lactation on Postnatal Development of Testis in Offspring Wistar Rats. *Iranian Journal of Basic Medical Sciences*. 14(02) : 122-131.
- Durgut R., A. Koc, R. Gonenci, R. Bal, S. Celik, M. Guzell, M. E. Altug and E. O. Atesoglu (2008) Effects of High dose Lead Toxication on Liver, Kidneys, Heart, Brain and Blood in Rabbits: An Experimental Study. *J. of Applied Biol. Sci.* 2 (2) : 11-18.
- Erdogan, Z., S. Erdogan, T. Aksu and E. Baytok (2005) Effects of Dietary Lead Exposure and Ascorbic acid on Performance, Lipid peroxidation Status and Biochemical parameters of Broilers. *Turk. J. Vet. Anim. Sci.* 29 : 1053-1059.
- Eugenia D, A. Trif , F. Muselin (2008) The consequences of chronic lead acetate intake on exposure and morphological integrity biomarkers (lead level and weight of sexual organs) in female rats. *Lucrări stiințifice medicină veterinară vol. Xli*,
- Fowler, B. A., C. A. Kimmel and J. S. Woods (1980) Chronic low level toxicity in the rat : III An integrated assessment of long term toxicity with special reference to the kidney. *Toxicol. and Applied Pharmacol.* 56 (1) : 59-77.

- Garg, S. K. (2000). Toxicity of Metals : Veterinary Toxicology. 1<sup>st</sup> Edn., CBS Publishers and Distributors, New Delhi: 42-47.
- Ghule, R. P. (2007). Toxicopathology of lead in Japanese Quails (*Coturnix coturnix japonica*), M.V.Sc. Thesis submitted to MAFSU, Nagpur.
- Gongale (2009) Effect of *Plumbago zeylanica* During Experimental Lead Toxicity in Japanese quails M.V.Sc. Thesis submitted to MAFSU, Nagpur.
- Gopinath S., S. Muralidharan, S. Rajan and S. P. Danaphal (2009) Simultaneous Estimation of Plumbagin and Embelin by Reverse Phase-High Performance Liquid Chromatographic method. *Der Pharmacia Lettre*, 1 (1): 135-142
- Hamadouche A. T. N., M. Slimani and A.K. Aous (2009). Biochemical Parameters Alterations Induced by Chronic Oral Administration of Lead Acetate in Albinos Rat. *American J. of Scientific Res.* 4 : 5-16.
- Huxley, A. (1992). *New RHS Dictionary of Gardening*. Macmillan.
- Ingale K.S. (2009) Effect of *Plumbago zeylanica* during experimental Lead toxicity in rats . M.V.Sc. Thesis submitted to MAFSU, Nagpur. In-vivo antioxidant effect of *Plumbago zeylanica* in discrete regions of rat
- Jabeen R, M. Tahir, S. Waqas (2010) Teratogenic effects of lead acetate on kidney *J Ayub Med Coll Abbottabad* : 22 (1)
- Jeyachandran A. M., I. Cndrella, S. sudhakar and K. pazhanichamy (2009) antibacterial activity of plumbagin and root extracts of *plumbago zeylanica* l. *Acta biologica cracoviensia series botanica* 51/1: 17-22,
- Kale, D. B. (2008). Toxicopathology of experimental lead toxicity in female rats (*Rattus norvegicus*) with special reference to changes in reproductive organ. M.V.Sc. Thesis submitted to, MAFSU, Nagpur.

- Kamboj VP (2000). Herbal medicine. *Cur. Sci.*, 78(1): 35-39.
- Kang J.K., S.D.Nam, S. H. Kim and E. Lee (2004). Effects of lead exposure on the expression of phospholipids hydroperoxidase glutathione peroxidase mRNA in the rat brain. *Toxicological sciences*, 82 : 228-236.
- Kantha D. A. , P. Velmurugan and R. Balaji Raja (2010) Anti-inflammatory and cytotoxic effects of extract from *Plumbago zeylanica*. *African Journal of Microbiology Research Vol. 4(12) pp. 1239-1245*
- Kaplan,A. and L.S Lavernel(1983). Lipid Metabolism, In *Clinical Chemistry: Interpretation and Techniques*, 2nd edition Febiger, Philadelphia. pp 333-336.
- Karaca T. and S. Nedjet (2006) : Effects of spirulina on the number of ovary mast cells in lead induced toxicity in rats. *Journal of Phytotherapy Research.*, Vol. 21., issue 1., pages 44-46.
- Karamala S. K., I. Y. Anjaneyulu, T.S Sekhara Rao. S. D. Vasulu and A. P. Pidugu (2011). Hematobiochemical changes of lead poisoning and amelioration with *Ocimum sanctum* in wistar albino rats *Veterinary World* (6): 260-263.
- Kavimani S. R. Ilangi, M. Madheswaran, B. Jayakar, M. Gupta and U. K. Majumdar (1996). Antitumor activity of plumbagin against Datton's ascetic lymphoma. *Indian Journal of Pharmaceutical Science*. 58(5) : 194-196.
- Kini D. P., S. Pandey, B. D. Shenoy, U. V. Singh, N. Udupa, P. Umadevi, R. Kamath and K. Ramanarayan (1997). Antitumor and antifertility activities of *Plumbagin* controlled release formulations. *Indian J. Expt. Biology*. 35(4) : 374-379.
- Kirtikar, K. R. and B. D. Basu (Eds)(1984). *Indian Medicinal Plants*, Vol. I & II, Publishers Blatter, E., Cauis, J. R. and Mhaskar, K. S., Basu, L. M., Allahabad, India.

- Krishnaswamy M. and K. K. Purushothaman (1980). Plumbagin : A study of its anticancer, antibacterial and antifungal properties. *Indian J. Expt. Biology*. 18(8) : 876-877.
- Lledo M. D. (1998). Plumbaginaceae, systematics of Plumbaginaceae based upon cladistic analysis of rbc L. sequence data. *Syst. Bot.*: 21-23
- Luckey T.D, B. Venugopal, D. Hutchson (1975). Heavy metal toxicity,safety and homology. *Qual. Suf. Thieme Stuttgart*, upplement, 1:120
- Luna A. G. (1968) Manual of histological staining methods of the Armed Forced Institute of Pathology, 3<sup>rd</sup> ed. Mc Graw Hill book Co, London: (124-125).
- Majumdar N.N. (1980) Textbook of Histology, Vikas publishing House Privet Ltd. New Delhi : 261-262. .
- Mem Inst Oswaldo Cruz, Rio de Janeiro, Vol. 104(6): 813-817*
- Meshram, S. Y. (2009) Toxicopathology of lead acetate and protective effect of *Plumbago zeylanica* in Japanese quails (*Coturnix coturnix japonica*). M.V.Sc. Thesis submitted to MAFSU, Nagpur.
- Miller T. E., K. A. Golemboski, R. S. Ha, T. Bunn, F. S. Sanders, and R. R. Dietert (1998) Developmental Exposure to Lead Causes Persistent Immunotoxicity in Fischer 344 Rats *Tomcological sciences* 42, 129-1
- Mittal V., S.K. Sharma, P. Jalwal, A. Hood and J. Mor( 2010) *Plumbago zeylanica* Roots: A potential source for improvement of learning and memory. *International J. of Pharma and Bio Science* .1(2):1.
- Morgan, G. W., F. W. Edens, P. Thaxton and C. R. Parkhurst (1975). Toxicity of dietary lead in Japanese quail. *Poultry Sci*. 54 : 1636-1642.
- Morgan, R. V., F. M. Moore, L. K. Pearce and Thomas Rossi (1991). Clinical and laboratory findings in small companion animals with lead poisoning: 347 cases (1977-1986). *J. Am. Vet. Med. Assoc.* 199(1) : 93-97.
- Morin, L. G. (1974). *Am. J. Clin. Pathol.* 61 : 114.

Mounoz, M. A. (1981). *Clin. Chem.* 29(2) : 372.

Moussa, S. A. and S. A. Bashandy (2008). Biophysical and biochemical changes in the blood of rats exposed to lead toxicity. *Romanian J. Biophys.*, 18 (2) : 123–133.

Mugahi, M. N., H. Zahra, H. M. Sagheb, and M. Barbarestani (2003) Effects of chronic lead acetate intoxication on blood indices of male adult rat. *DARU* 11 (4) : 147-151.

Mungwini, L. Y. (2006). *Plumbago zeylanica* L. Prota II : Medicinal Plants / Planets medicinales.

Mussalo-Rauhamaa, H., A. Leppänen S. Salmela, and Pyysalo, H. (1986) In *Archives of Environmental Health*. 41, p. 49-55.

Nampoothiri, L.P., Gupta, S. (2006) : Simultaneous effect of lead and cadmium on granulosa cells : A cellular model for ovarian toxicity. *Reprod. Toxicol.* 179-185.

Nazera Qureshi, R. Sharma, S. Mogra and K. Panwar ( 2010) protective effects of combined treatment of vitamine and c on lead induced folliculogenesis in swiss mice. *J. herbal medicine and toxicology* 4 (2) : 207-213.

Ouarda M. and C. Abdenmour (2011) Evaluation of the therapeutic efficiency of raw garlic on reproduction of domestic rabbits under lead induced toxicity *Annals of Biological Research* 2 (3) :389-393.

Ozcelik, D., M. C. Akyolcu, S. Dursun, S. Toplan, R. Kuhraman and M. Alp (2003). Effect of lead on live performance due to its accumulation in tissue. *J. Phys. IV France*. 107 : 997.

Pierson, F. W. (2000). Laboratory technique for Avian hematology In Schalm's *Veterinary Hematology*, 5<sup>th</sup> Edn. Lippincott Williams and Wilkins, Landon pp 1145-1146.

Poultry International (2003). 42(11).

- Premakumari, P., K. Rathinam and G. Santhakumari (1977). Antifertility activity of Plumbagin. *Indian J. Med. Res.* 65(6) : 829-838.
- Rahman S, Sultana S. (2006) : Chemopreventive activity of glycyrrhizin on lead acetate mediated hepatic oxidative stress and its hyperproliferative activity in Wistar rats. *Chem Biol Interact.* 10; 160(1) : 61-9.
- Rahman, S. A. (2006). Experimental lead toxicity in broilers with special reference to histopathological and immunopathological investigation. M.V.Sc. Thesis submitted to, MAFSU, Nagpur.
- Rajesh Kumar, S. Kumar, A. Patra, S. Jayalakshmi (2009) Hepatoprotective activity of arial parts of *Plumbago zeylanica* against carbon tetrachloride induced hepatotoxicity in Rats (*Rattus norvegicus*) Department of Pharmacognosy & Phytochemistry, College of Pharmacy, IFTM, Moradabad, India.
- Ramachandra R.S. and G.A. Ravishankar (2002). Plant cell cultures: chemical factories of secondary metabolites, *Biotech. Advances*, 20: 101-153.
- Ramachandran A. Ravishankar (2002). Diabetes in Indian National Urban diabetes study. In Proceedings of the diabetes in Asia meeting (Abstract). p. 21.
- Rao N., K., Thammanna, (1987). "Medicinal Plants of Tirumala Hills", Department of Garden, Tirumala Tirupati Devasthanams, Tirupati, India.: 37.
- Saly, J., D. Baranova, L. Pesek, Z. Sevcikova, D. Koscik, V. Sutiak, J. Neuschl and J. Kremen (2004). Effect of lead on health and productivity of layers. *Bull. Vet. Inst. Pulawy.* 48 : 75-80.
- Sanderson, G. C. and F. C. Bellrose (1986). A review of the problem of lead poisoning in waterfowl. III. *Nat. Hist. Surv. Spec. Publ.* 4 : 1-34.
- Santhakumari, G., P. G. Rathinam and C. Sheshadri (1978). Anticoagulant activity of plumbagin. *Indian J. Exp. Biol.* 16(4) : 485-487.

Sastry, G. A. (2001). Textbook of Veterinary Pathology, 7<sup>th</sup> Edition, 133-134.

Sathiskumar D., D. Banji and A. Harani (2010) A medicinal plants survey for treatment of obesity *Journal of Pharmacy Research* 2011,4(3),597-600.

Schumann, G., Bonora, R., Ceriotti, F., Féraud, G., Ferrero, C.A., Franck, P.F.H., Gella, F.J., Hoelzel, W. Jørgensen, P.J., Kanno, T., Kessner, A., Klauke, R., Kristiansen, N., Lessinger, J.-M., Linsinger, T.P.J., Misaki, H., Panteghini, M., Pauwels, J., Schiele, F. and Schimmel, H.G. (2002). 725 IFCC primary reference procedures for the measurement of catalytic activity concentrations of enzymes at 37°C, part 5. *Clin. Chem. Lab. Med.*, 40: 725-733.

Selma Ribeiro de Paiva, Shirley Da Silva, Marques Maria Raquel, Figueiredo, Maria Auxiliadora, Coelho Kaplan (2003). 10(1) : 98-105.

Shah B. N., B. S. Nayak, A. K. Seth, S. S. Jalalpure, K.N. Patel (2004). Search for medicinal plants as a source of anti-inflammatory and antiarthritic agents-A review. *Pharmacognosy magazine*.pp. 344-50.

Shah, Mir Ajab Khan, Dr. Mushtaq Ahmad, Muhammad Zafar and Aftab (2009) Observations on antifertility and abortifacient herbal drugs. *African Journal of Biotechnology* Vol. 8 (9), pp. 1959-1964

Shakoor, A., P. K. Gupta, M. Kataria and S. K. Dwivedi (2000). Effect of simultaneous exposure to aluminum and lead on growth in male albino rats. *Indian J. Toxicol.* 7(2) : 51-56.

Sivakumar, V. and S. Niranjali (2006). Projective effect of *Plumbago zeylanica* against cyclophosphamide induced genotoxicity and oxidative stress in Swiss albino rats. *Drug Chem. Toxicology.* 29(3) : 279-288.

Smith, A. R. (1753). *Plumbago linnaeus*, sp. P 1.1:151. *Gen. Pl.* Ed. 5 (75) : 1754.

- Snedecor, G.W. and W.G. Cochran (1989) *Statistical Methods*, 8<sup>th</sup> Edn. Iowa State Univ. Press, Iowa, USA.
- Sokol, R.Z. (1987). Hormonal effects of lead acetate in the male rat. Mechanism of action. *Biol. Reprod.* 37:1135-1138.
- Stone, C. L., M. R. S. Fox, A. L. Jones and K. R. Mahaffey (1977)  $\delta$ -Aminolevulinic acid dehydratase : A sensitive indicator of lead exposure in Japanese lead toxicity in the Japanese quail. *Poultry Sci.* 55 : 341-349. *quail. Poultry Sci.* 56 : 174-181.
- Stone, C.L. and J.H. Soares Jr. (1976) The effect of dietary selenium level on lead toxicity in Japanese Quail. *Poultry Science*, 55 : 341-349.
- Suradkar S. G., P. D. Vihol, J. H. Patel, D.J.Ghudasara, B.P. Joshi and K.S. Prajapati (2010) Patho-morphological changes in tissues of Wistar rats by exposure of Lead acetate. *Veterinary World Vol.3(2): 82-84.*
- Tatjana, J., K. Gordana, P. Dusica and S. Ivana (2003). Effects of captopril on membrane associated enzymes in lead induced hepatotoxicity in rats. *Acta Fac. Med. Naiss.* 20(3) : 183-188.
- Taupeau C, J. Poupon , F. Nomé and B. Lefèvre (2001) Lead accumulation in the mouse ovary after treatment-induced follicular atresia. *Journal of Reprod Toxicol.* Jul-Aug;15(4):385-91
- Tchernitchin Nina N., Clavero Andrena., Mena., Unda Cristina., Villagra., Cumsille., Tchernitchin Andrei N.(2003). Effect of chronic exposure to lead on estrogen action in the prepubertal rat uterus. *Journal of Environmental Toxicology*, Vol.18, pp 268-277
- Tietz, N. W. (1976): *Clinical Guide to Laboratory Test.* W. B. Saunders Co., Philadelphia. PP. 238 (prescribed methods for serum glucose, Auto span, Span diagnostic Ltd. Gujarat)

- Tilak, J. C., S. Adhikari and P. A. Devasagayam Thomas (2004). Antioxidant properties of *Plumbago zeylanica*, an Indian medicinal plant and its active ingredient. *Plumbagin Redox Report*. 9(4) : 219-227.
- Tiwari, K. C., R. Majumder and Bhattacharjees (1982). Folklore information from Assam for family planning and birth control. *Indian J. Crude Drug Res.* 20(3) : 133-137.
- Tsuji, L.J.S. and Karagatzides (2001). Chronic lead exposure, body condition and testis mass in Wild Mallard ducks. *Bull Environ. Contam. Toxicol.* 67: 489-495.
- Upasani, C. D. and R. Balaraman (2001) Effect of vitamin C and Vitamin E and spirulina on the level of membrane bound enzymes and lipids in some organs of rat exposed to lead. *Ind. J. Pharmacol.* 33 : 185-191.
- Veale L., D.J.H., Havlik, I., and Rama, D.B.K. (1997) Preliminary screening of plants used in South Africa as traditional herbal remedies during pregnancy and labour. *J. Ethnopharmacol*; 55: 185-191.
- Vijayakumar, R. S. Devi, R. Ravindran and S. Latha (2009) In-vivo antioxidant effect of *Plumbago zeylanica* in discrete regions of rat (*Rattus norvegicus*) brain, Dr. ALM.PG.Institute of Basic Medical Sciences, University of Madras, India.
- Vijayakumar, R., M. Senthilvelan, R. Ravindran and R. Sheela Devi (2006). Vascular pharmacology *Plumbago zeylanica* action on blood coagulation profile with and without blood volume reduction. 45 : 46-90.
- Vishnukanta and A. C. Rana (20) Evaluation of anticonvulsant activity of *plumbago zeylanica* Linn leaf extract. Vol.3 Issue 1,

- Vodela, J. K., S. D. Lenz, J. A. Renden, W. H. Mc Elhenney and B. W. Kemppainen (1997) Drinking water contaminants (arsenic, cadmium, lead, benzenes and trichloroethylene) Interaction of contaminants with nutritional status on general performance and immune function in broiler chickens. *Poult. Sci.* 76 : 1493-1500.
- Wagh, S. B. (2006). Studies on lead toxicity in broilers with special reference to immunopathological investigations. M.V.Sc. Thesis submitted to MAFSU, Nagpur.
- Winder, C. (1989). Reproductive and chromosomal effect of occupational exposure to lead on the male. *reprod. Toxicol.* 3: 221-233.
- Zahin, F. Aqil and Iqbal Ahmad (2009) the *in vitro* antioxidant activity and total phenolic content of four indian medicinal plants. *International J. of pharmacy and pharmaceutical* vol. 1
- Zambare, V. and A. Bhole (2008). *In vitro* antioxidant activity of *Plumbago zeylanica*. *Research Journal of Biotechnology*, 3 : 3.
- Zarmouh, M. M., K. Subramaniam, S. Viswanathan and Kumar P. G. (2010) Cause and effect of *Plumbago zeylanica* root extract on blood glucose and hepatic enzymes in experimental diabetic rats. *African Journal of Microbiology Research*. 4(24) : 2674-2677.



# Vita



**VITA**

The author **Miss. Sonal Sham Hingade** , was born on 23<sup>rd</sup> December 1985 at Poghat Dist. Washim in Maharashtra State. She finished her lower education at Yavatmal from Abhyankar Kanya Shala in first division. She has completed Intermediate Education from Amolakchand Mahavidyalaya, Yavatmal in 2003.

.She has joined the Nagpur Veterinary College, Nagpur for degree of B.V.Sc. & A.H. in the year 2004. She has successfully completed the degree in July, 2009 in first division. She joined the Post Graduate Institute of Veterinary and Animal Sciences, Akola, in 2009 for post graduate studies in Veterinary Pathology.

Two fruitful years resulted in the submission of present thesis successfully. As a part of her training in department of Veterinary Pathology she assisted various research works. She actively participated in N.S.S. camp, zonal level interuniversity sports meet and Youth festival .She has good knowledge of computers and internet.



She considered her lucky to have gained the love and respect of her superiors and entire staff of the department.



# ***Thesis Abstract***



## THESIS ABSTRACT

- a) Title of the thesis (in Capital letters) : **PATHOLOGY OF EXPERIMENTAL LEAD TOXICITY AND EFFECT OF *Plumbago zeylanica* IN FEMALE RATS (*Rattus norvegicus*) WITH SPECIAL REFERACE TO REPRODUCTIVE ORGANS .**
- b) Full name of student : **HINGADE SONAL SHAM**
- c) Name and address of Major advisor : **Dr. M. V. JOSHI**  
Professor and Head  
Department of Veterinary Pathology, Post Graduate Institute of Veterinary and Animal Sciences, Akola.
- d) Degree to be awarded : **M.V.Sc.**
- e) Year of award of degree : **2011**
- f) Major subject : **Veterinary Pathology**
- g) Total number of pages in the thesis : **73**
- h) Number of words in the abstract : **557**
- i) Signature of Student : 
- j) Signature, Name and address of forwarding authority :   
**(M. V. Joshi)**  
Head,  
Department of Veterinary Pathology,  
PGIVAS, Akola.

---

## ABSTRACT

Present studies on " Pathology of experimental lead toxicity and effect of *Plumbago zeylanica* in female rats with special reference to reproductive organs." was conducted in the Department of Veterinary Pathology, PGIVAS, Akola.

Twenty four non pregnant Wistar adult female rats of 6-7 weeks of age were divided in four equal groups . Group T1 rats were given adlib pelleted diet with normal water however group T2 and T4 rats were given same diet along with 500ppm lead acetate in drinking water. Group T<sub>3</sub> and T<sub>4</sub> were given ethanolic extract of dry root powder of *Plumbago zeylanica* at 100mg/kg body wt/day. orally for the period of four weeks.

Blood and plasma samples from six animals of each group were collected for hematological and biochemical investigations and were sacrificed at the end of 4<sup>th</sup> week of experiment.

Parameters studied included clinical observations, general performance, hematological, biochemical, radiological, gross and histopathological investigations at the end of four week of experiment.

Hematological parameters included Hb, PCV, TEC, MCV, MCHC, TLC and DLC. Biochemical parameters studied included plasma calcium, phosphorous, creatinine, AST, ALT and glucose .

After detailed gross pathological examination, organs weights of liver, lungs, heart, kidneys, spleen, brain, ovary, uterus and vulva were recorded. Tissues of liver, lung, heart, kidneys, spleen, brain, thyroid pancreas, ovary, uterus and vulva were collected for histopathological examination.

Animals of T<sub>2</sub> group only showed symptoms of excitement i.e. aimless running, climbing on each other in the cages and fighting, pesty dark brown color feces and diarrhea indicating digestive disturbance . When compared with T<sub>2</sub> group animals significant increase of average feed consumption, water consumption, weekly body weight and body weight gain was observed in T<sub>4</sub> group animals given *P. zeylanica* @100mg/kg indicating its useful properties during lead toxicity.

Hematological observation showed significant decrease in Hb, PCV and non significant decreased in TEC , MCV and MCH values in T<sub>2</sub> group rats suggesting microcytic hypochromic anemia. Decrease TLC indicated adverse effect on leucopoiesis with relative increase in absolute neutrophil, lymphocyte and monocyte count. Other group including T<sub>4</sub> showed comparable values suggesting hematinic property of *P. zeylanica*.

Elevated levels of phosphorous, creatinine, AST, ALT and glucose in T<sub>2</sub> group animals indicated toxic effect of lead on liver, pancreas and kidneys.

Decreased values were observed in T<sub>4</sub> group suggesting beneficial effect of *P. zeylanica* during lead toxicity.

Organ weights in T<sub>2</sub> group animals revealed non-significant decrease indicating toxic effect of lead on visceral organs.

Histopathological examination of liver showed bile duct hyperplasia, dilated sinusoids, increased reticular cells, degenerative changes, venous congestion, and atrophy of hepatic parenchyma in T<sub>2</sub> group as a result of toxic effect of lead acetate. T<sub>4</sub> group rats however did not revealed this changes suggesting hepatoprotective effect of *P. zeylanica* during lead toxicity.

Sections of kidneys in T<sub>2</sub> and T<sub>4</sub> group revealed congestion and tubular nephrosis where as control and T<sub>3</sub> group showed normal renal parenchyma. Finding thus indicated that extract of *P. zeylanica* failed to restore nephrotoxic effect of lead.

Other visceral organs however showed normal histomorphology. Sections of ovary showed irregular degenerating follicle with sever congestion and increased stroma. Uterus and vulva showing thinning of myometrium and mucosa in treatment groups respectively.

Findings indicated that both lead and *P. zeylanica* independently or in combination have adverse effect on female reproductive organs. However

*P. zeylanica* have hepatoprotective effect during lead induced hepatic damage.



# प्रबंध सारांश



## प्रबंध सारांश

१. प्रबंधाचे शिर्षक : "मादी मुषकांमध्ये (रेंटस नोर्व्हजिकस) शिशाच्या प्रायोगिक विषबाधेमुळे होणारी पेशी विकृती आणि चित्रक (प्लंबॅगो झेलॅनिका) चा विशेषतः जननेंद्रियावर होणारा परिणाम"
२. विद्यार्थ्यांचे पूर्ण नाव : हिंगाडे सोनल शाम
३. मुख्य मार्गदर्शकाचे नाव व पत्ता : डॉ. एम.व्ही. जोशी  
प्राध्यापक तथा सहयोगी अधिष्ठाता, पशुविकृती शास्त्र विभाग,  
स्नातकोत्तर पशुवैद्यकीय व पशुविज्ञान संस्था, अकोला.
४. प्रदान केली जाणारी पदवी : एम.व्ही.एस्सी. (पशुविकृती शास्त्र)
५. पदवी प्रदान करण्याचे वर्ष : २०११
६. मुख्य विषय : पशुविकृती शास्त्र
७. प्रबंधा मधील एकुण पाने : ७३
८. प्रबंध सारांशामधील एकुण शब्द : ५५७
९. विद्यार्थ्यांची सही : कु. सोनल वा. हिंगाडे
१०. प्रबंधक कार्यवाहीस्तव पाठविणाऱ्या अधिकाऱ्याची सही, नाव व पत्ता:

(डॉ. म. व. जोशी)

विभाग प्रमुख  
पशुविकृती शास्त्र विभाग,  
स्नातकोत्तर पशुवैद्यकीय व पशुविज्ञान संस्था, अकोला.

## सारांश

सदर संशोधन म्हणजेच "मादी मुषकांमध्ये (रेंटस नोर्व्हजिकस) शिशाच्या प्रायोगिक विषबाधेमुळे होणारी पेशी विकृती आणि चित्रक (प्लंबॅगो झेलॅनिका) चा विशेषतः जननेंद्रियावर होणारा परिणाम" हे स्नातकोत्तर पशुविज्ञान व पशुवैद्यकीय संस्था अकोला येथील पशुविकृतीशास्त्र विभागात करण्यात आले.

गाभण नसलेल्या ६ ते ७ आठवडे वयाच्या, व्हिस्टार प्रजातीच्या २४ प्रौढ मुषकमादया ४ समान गटात विभागण्यात आल्या. पैकी गट टी-१ मधील मुषकांना साधारण पाणी व गोळीखाद्य पुरविण्यात आले. तथापि, गट टी-२ आणि टी-४ च्या मुषकांना तेवढेच खाद्य मात्र पिण्याच्या पाण्यात ५०० पीपीएम "लीड अॅसिटेट"

देण्यात आले. त गट टी-३ व टी-४ च्या मुषकांना ४ आठवडयांपर्यंत प्लंबॅगो झेलॅनिका चित्रकाच्या वाळलेल्या मुळांच्या भुकटीचे इथेनॉल अर्क १०० मिग्रॅ प्रति किग्रॅ वजन प्रति दिवस या दराने मुखावाटे देण्यात आले.

प्रत्येक गटातील प्रत्येकी सहा प्राण्यांचे प्रयोगाच्या ४ थ्या आठवडयाला विविध रक्ताच्या व जैवरासायनिक अभ्यासासाठी रक्त व रक्तद्रव्य नमुने घेण्यात आले.

प्रयोगाच्या ४ थ्या आठवडयाअंती विविध वैद्यकीय निरीक्षणे, सर्वसाधारण कार्यप्रवणता, रक्तचाचण्या, जैवरासायनिक चाचण्या, किरणोत्सारी चाचण्या तसेच ठळक व उतिविकृतीय बदलांचा अभ्यास करण्यात आला.

रक्तचाचण्यांमध्ये हिमोग्लोबीन, एकूण पेशी परिमाण, एकूण लाल रक्तपेशी, एमसीव्ही, एमसीएचसी, एकूण पांढऱ्या रक्तपेशी आणि विविध पांढऱ्या पेशी ची तपासणी अशा चाचण्यांचा अंतर्भाव करण्यात आला. जैवरासायनिक चाचण्यांमध्ये रक्तद्रव्यातील कॅल्शियम, फॉस्फरस, क्रिएटीनिन, एएसटी, एएलटी व ग्लुकोज इ. घटकांचे तपासण्यात आले.

विकृतीशास्त्रीय निरीक्षणांती, यकृत, फुफ्फुस, हृदय, मुत्रपिंड, प्लीहा, मेंदू, बिजांड, गर्भाशय आणि योनी इ. अवयवांची वजने घेण्यात आली. यकृत, फुफ्फुस, हृदय, मुत्रपिंड, प्लीहा, मेंदू, थायरॉईड ग्रंथी, स्वादुपिंड, बिजांड, गर्भाशय व योनी इ. अवयवांचे उतिनमुने, उतिविकृतीशास्त्रीय अभ्यासासाठी घेण्यात आले.

सदर प्रयोगादरम्यान टी-२ गटातील प्राण्यांमध्ये उत्तेजन लक्षणे आढळून आली ती याप्रमाणे दिशाहीनपणे धावणे, एकमेकांवर चढाई तथा लढाई, पचन क्रियेतील बिघाडामुळे गडद विटकरी / तपकिरी रंगाची विष्ठा व हगवण इ. टी-२ गटातील प्राण्यांच्या तौलनिक अभ्यासामध्ये सरासरी पाणी व खाद्य ग्रहणता, शारिरीक वजनवाढ व आठवडी वजन इ. टी-४ गटाच्या प्राण्यांत प्ल. झेलॅनिकाच्या १०० मि.ग्रॅ. प्रतिकिग्रॅ दराने लक्षणिय बदल आढळून आलेत जे शिसे विषबाधेत चित्रकाचे महत्व व उपयोगिता स्पष्ट करतात.

रक्तचाचण्यांमध्ये हिमोग्लोबिन, पीसीव्ही मध्ये लक्षणीय घट तसेच एकूण लाल रक्तपेशी, एम.सी.व्ही. व एम.सी.एच. मुल्यांत साधारण घट दिसून आली जे टी-२ गटाच्या मुषकांमध्ये "मायक्रोसायटिक हायपोक्रोमिक" प्रकारच्या रक्तक्षय झाल्याचे दर्शवितात. एकूण पांढऱ्या रक्तपेशी मधील घट पांढऱ्या रक्तपेशी तयार करण्याच्या प्रक्रिये वरील प्रतिकूल परिणाम दर्शवते व न्यूट्रोफिल्स, लिम्फोसाईट व मोनोसाईट या पेशीसंख्येत वाढ दर्शविते. टी-४ सह इतर गटांनी चित्रकाची रक्तक्षय विरोधी गुणधर्माचे दर्शन घडवले.

टी-२ गटातील प्राण्यांत फॉस्फरस, क्रिएटीनीन, एएसटी, एएलटी व ग्लुकोज यांच्या वाढलेल्या पातळ्यांवरून शिशाचा यकृत, स्वादुपिंड, मुत्रपिंडावर होणारा विषारी परिणाम सुस्पष्ट होतो. तद्वतच टी-४ गटातील सदर घटकांच्या घटलेल्या पातळीवरून शिशोविषबाधेमध्ये चित्रकाची उपयोगिता स्पष्ट होते.

टी-२ गटातील प्राण्यांच्या अवयवांत दिसून आलेली अलक्षणीय घट शिशांचा शरिरांतर्गत अवयवांवर होणारा विषारी परिणाम लक्षात येतो. टी-२ गटातील प्राण्यांत लीड ॲस्टिट मूळे यकृताची उत्तिविकृती शास्त्रीय अभ्यासांत पित्त नलिकांच्या संख्येमध्ये वाढ, डायलेटेड सिन्युसाईड, रेटिक्युलर पेशींत वाढ, बदल, व्हेनस कंजेशन, हिपॅटिक पॅरेनकायमाची घट दिसून आली. टी-४ गटातील मुषकांमध्ये असे बदल आढळून आले नाहीत जे चित्रकाची शिशो विषबाधेविरूद्ध यकृतसंरक्षक भूमिका स्पष्ट करतात.

टी-२ व टी-४ गटातील मुत्रपिंडामध्ये "कंजेशन व ट्यूब्यूलर नेफ्रोसिस" वरून शिशाच्या विषबाधेमुळे मुत्रपिंडावर होणाऱ्या वाईट परिणामांना कमी करण्यात चित्रक अपयशी ठरल्याचे दिसून आले.

इतर अंतर्गत अवयवांमध्ये उत्तीरचना अबाधीत आढळून आली, इतर अंतर्गत अवयवांमध्ये साधारणतः दिसून आली. बिजांडांचा अभ्यासात अनियमित नष्ट होणारे फॉलिकल हे कंजेशन व ताणासह आढळून आले. नियंत्रक गटाच्या गर्भाशय व योनी मध्ये मायोमेट्रीयम व म्युकोजाच्या स्तरात घट आढळला.

वरील अभ्यासावरून असे निष्कर्षाप्रत येते की, शिसे व चित्रक हे सोबत व विरोधीपणे मादयांच्या जननेंद्रियावर प्रतिकूल प्रकारे परिणाम करतात. शिशामूळे होणाऱ्या यकृत हानीत चित्रकाचा यकृतसंरक्षक परिणाम दिसून आला.

