

Electrocardiogram changes during xylazine-propofol anaesthesia in dogs: a clinical study

S. Sooryadas¹, T. Sarada Amma^{2†}, K. Rajankutty³, N. Gopakumar⁴ and K.N.M. Nayar⁵

Kerala Agricultural University, Vellanikkara, Thrissur (Kerala)

¹Ph.D. Scholar, Dept. of Veterinary Surgery and Radiology, Madras Veterinary College, Chennai; ²Professor and Head, ³Professor, ⁴Prof. and Head (Retd.), Dept. of Veterinary Surgery and Radiology, College of Veterinary and Animal Sciences, Mannuthy, Thrissur; ⁵Prof. and Head, Dept. of Veterinary Pharmacology and Toxicology, College of Veterinary and Animal Sciences, Pookot, Wyanad.

Received: February 2010

Fifteen dogs of different breeds and of either sex presented for surgery were divided into two groups, group I and group II. Eight apparently healthy dogs undergoing elective surgery formed the first group, while seven dogs undergoing surgery with compromised health status formed the second group. All were premedicated with atropine sulphate and xylazine, followed 10 min later by induction of general anaesthesia with intravenous injection of 1% w/v propofol 'to effect' and was maintained with incremental dose(s) of propofol as intermittent boli as and when required. ECG was recorded using Lead II system at a paper speed of 25 mm/s before and after premedication and every 15 min after anaesthetic induction, till recovery. The changes observed were tachycardia, bradycardia with 2nd degree heart block, wandering pace maker, ventricular pre-excitation, atrial premature contraction, ST coving, biphasic T waves and peaked T waves.

Key words: Dogs, ECG changes, Xylazine-propofol anaesthesia.

Propofol (2, 6-di-isopropyl phenol), an alkylphenol derivative, is an ultra short acting anaesthetic having desirable anaesthetic profile in animals without much side effects (Glen, 1980). It is a sedative-hypnotic anaesthetic having rapid onset, ultra short duration of action, lacks cumulative effects on continuous administration and possesses quick and smooth recovery. The present paper deals with a clinical study evaluating electrocardiogram changes when propofol is used as an induction as well as maintenance agent for surgical anaesthesia in xylazine premedicated dogs.

Fifteen dogs of different breeds of either sex presented for clinical surgery were divided into two groups: group I consisting eight apparently healthy dogs (A1 to A8) presented for elective surgery and group II consisting seven dogs (B1 to B7) presented for emergency surgery. They were premedicated with atropine sulphate (0.04 mg/kg, i.m.) and xylazine (1 mg/kg, i.m.). Ten min later, general anaesthesia was induced with intravenous injection of 1% w/v Propofol (Bharat Serums and

Vaccines Ltd., Thane) and was maintained with incremental dose(s) of propofol as intermittent boli as and when required. ECG was recorded using Lead II system using Cardiart- 108 T (BPL India) at a paper speed of 25 mm/sec before and after premedication and every 15 min after anaesthetic induction till recovery.

ECG after premedication: Tachycardia was noticed in three animals of group I probably due to the effect of atropine. Marked decrease in heart rate with 2nd degree heart block was observed in two dogs of group I (Fig. 1). There was decrease in heart rate in all animals of group II. Sinus bradycardia was observed in one dog of group II. Changes in the height of P wave (wandering pacemaker) was observed in two dogs of groups I and II. P wave sometimes overlapped QRS (ventricular pre-excitation) (Fig. 1), P on T wave (atrial premature contraction) (Fig. 2), and increase in the duration of QRS were observed in one dog each in group I. ST coving was observed in one dog of group I (Fig. 1) and two dogs of group II (Fig. 3). This can be probably due to the hypoxia caused by the decrease in respiration.

ECG after anaesthetic induction: 15 min post-induction, heart rate increased in all animals except one dog in group I (Fig. 4). In group II, heart rate was greater than the value after premedication in four dogs and lesser in two dogs. T wave was biphasic at 45 min. (Fig. 5) and negative and more than ¼ R wave at 60 min and 75 min after induction in one dog of group I. T wave was greater than ¼ R wave (Fig. 6) at 30 min post-induction in one dog of group II. ST coving (Fig. 6) was seen throughout the period of observation in two dogs of group II.

The increase in heart rate during anaesthesia can be attributed to the increased level of carbon

[†]Corresponding author; E-mail: sandeepsharma956@gmail.com

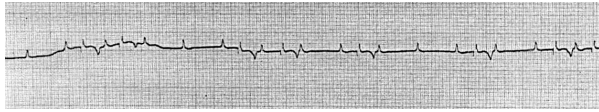


Fig. 1: Ventricular pre-excitation, ST coving and tachycardia in A3

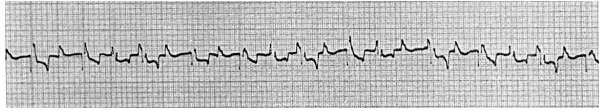


Fig. 2: Second degree heart block and Atrial premature contraction in A4

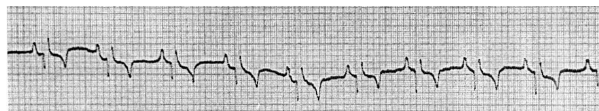

Fig. 3: ST coving in B6

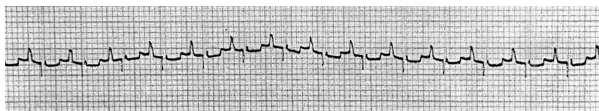


Fig. 4: Tachycardia at 15 min post induction in A3

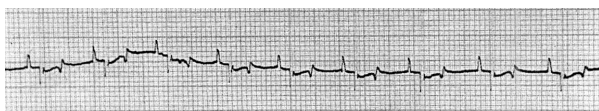

Fig. 5: Biphasic T wave at 45 min post induction in A3

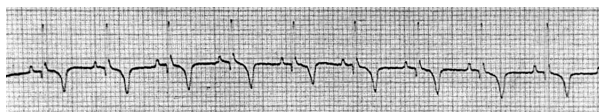


Fig. 6: ST coving, deep T wave at 30 min post induction in B6

dioxide in the blood. The elevation of carbon dioxide in various stages of anaesthesia could be attributed to the reduction in tidal volume, decrease in the ratio of inspiratory time to the total respiratory cycle and decrease in the functional residual capacity (Goodman *et al.*, 1987; Sebel and Lowdon, 1989). Increased carbon dioxide tension stimulates the peripheral chemoreceptor and vasomotor

centres of the medulla, which in turn stimulates the sympathetic activity (Moster *et al.*, 1969). David (1992) in his study observed elevation of heart rate from the pre-induction value followed by decline to normalcy during recovery. The increase in heart rate during recovery in premedicated dogs was attributed to the prolonged effect of atropine. Anoxia during anaesthesia may also increase the heart rate. David (1992) reported that the duration of QT interval was less in premedicated dogs when compared with unpremedicated dogs, which could be attributed to a reduction in vagal inhibition by atropine.

Acknowledgements

The authors are thankful to Mr. N.D. Narayan, Regional Sales Manager and Mr. Sebi, Area Sales Manager (Kerala), Bharat Serums and Vaccines Ltd, Thane, who provided Propofol for the conduction of this work.

References

- David, W.P.A.B. 1992. Studies on propofol as an intravenous central anaesthetic in dogs. Ph.D. thesis submitted to the Tamil Nadu Veterinary and Animal Sciences University, Chennai (TN), India.
- Glen, J.B. 1980. Animal studies of the anaesthetic activity of ICI 35 868. *Br. J. Anaesth.* **52**: 731-741.
- Goodman, N.W., Black, A.M.S. and Carter, J.A. 1987. Some ventilatory effects of propofol (Diprivan) as a sole anaesthetic agent. *Br. J. Anaesth.* **59**: 1487-1503.
- Moster, W.G., Reir, C., Gardier, R.W. and Hamilberg, W. 1969. Cardiac output and post-ganglionic sympathetic activity during acute respiratory alkalosis. *Anaesthesiol.* **31**: 28-34.
- Sebel, P.S. and Lowdon, J.D. 1989. Propofol: A new intravenous anaesthetic. *Anaesthesiol.* **71**: 260-277.