



ISSN: 0976-3376

Available Online at <http://www.journalajst.com>

ASIAN JOURNAL OF
SCIENCE AND TECHNOLOGY

Asian Journal of Science and Technology
Vol. 6, Issue 01, pp. 947-950, January, 2015

RESEARCH ARTICLE

MICROANATOMY OF OVARY IN LAYING AND NON-LAYING EMU BIRDS (*DROMAIUS NOVAEHOLLANDIAE*)

Vijayakumar, K., Balasundaram, K., *Paramasivan, S., Sivaseelan, S., Kumaravel, A. and Madhu, N.

Department of Veterinary Anatomy and Histology, Veterinary College and Research Institute, Namakkal – 637 002, Tamilnadu, India

ARTICLE INFO

Article History:

Received 24th October, 2014
Received in revised form
10th November, 2014
Accepted 01st December, 2014
Published online 30th January, 2015

Key words:

Emu,
Ovary,
Histology.

ABSTRACT

The micronatomical observation was carried out on ovaries of six mature female emu birds at their non-laying stage and six female birds at their laying stage. The female reproductive system of the emu consisted of an unpaired ovary appearing as bunch of grapes and was covered externally by germinal epithelium consisting of a single layer of cuboidal cells. The ovarian follicles of different stages of development, atretic follicles and post ovulatory follicles (corpus luteum) were seen in the cortex. The medulla consisted of collagen and reticular fibres, blood vessels, nerve bundles and smooth muscle fibres. The primary follicles consisted of a single layer of flattened granulosa cells around the oocyte and were smallest among the follicles. The diameter of these follicles varied from $77.47 \pm 7.55 \mu\text{m}$ in non-laying birds to $80.66 \pm 5.49 \mu\text{m}$ in laying birds. The secondary follicles were larger than the primary follicles and consisted of an oocyte with granular cytoplasm surrounded by a single layer of cuboidal granulosa cells. The diameter of secondary follicle was $145.64 \pm 10.98 \mu\text{m}$ in non-laying birds and $174.86 \pm 6.72 \mu\text{m}$ in laying birds. The tertiary and quaternary follicles were located close to the surface of the ovary and quaternary follicles were suspended from the ovary by follicular stalks in laying emu birds. The vacuolated cells identical to the interstitial cells of the stroma formed oval to spherical thecal glands. The diameter of quaternary follicle varied from $927.24 \pm 48.71 \mu\text{m}$ in non-laying birds to $1119.66 \pm 61.93 \mu\text{m}$ in laying birds. These follicle measured upto 3.28 cm in diameter in laying birds as they were filled with enormous amount of yolk. Follicular atresia was observed in various stages of the development of the ovarian follicles. The granulosa and thecal layers were disrupted and degenerated and invaded into the oocytes of atretic follicles. The post-ovulatory follicle (or corpus luteum) was observed in the cortex of the ovary.

Copyright © 2014 Vijayakumar et al. This is an open access article distributed under the Creative Commons Attribution License, which permits unrestricted use, distribution, and reproduction in any medium, provided the original work is properly cited.

INTRODUCTION

The emu is one of the most important wild birds providing oil, leather, feather and meat to the human population. Four distinct types of emus occurred in native Australia before European settlement; only the main land form survives (*Dromaius novaehollandiae*). In birds, normally the left ovary is functional and only the left oviduct is observed as the right one being vestigial except in raptors. Atretic follicles are prominent feature of the avian ovary and numerous follicles undergo preovulatory atresia at different stages of maturity. In all the stages of development the oocytes occupied the follicles leaving no antrum. The typical feature of the tertiary and mature follicles in the avian ovary is the appearance of yolk in the form of spheres.

Emus usually begin to reproduce between 2 and 3 years of age. However, some birds lay as early as 18 months. Average egg production is about 20-50 eggs per year. The exact stimulus for the seasonal beginning and cessation of egg production has to be researched in detail. The avian reproductive system has been studied extensively in some poultry birds, specially the domestic fowl. The general morphology and overall function of the female reproductive system in avian species, especially in *Gallus domesticus*, have been studied for many years. The study on the reproductive system of wild birds is necessary to improve their production and reproduction efficacy and to preserve their species. Review of literature reveals that extensive work had been done on the morphology and the physiology of the reproductive system of the domestic fowl and duck. Though preliminary work had been done on the gross and microscopic anatomical aspects of the reproductive organs in male and female emu, focus detailed histological features of ovary in laying and non-laying birds needs further study. Hence, an attempt has been made to study the

*Corresponding author: Paramasivan, S.,
Department of Veterinary Anatomy and Histology, Veterinary
College and Research Institute, Namakkal – 637 002, Tamilnadu,
India

microanatomy of the ovary during laying and non-laying periods in emu birds.

MATERIALS AND METHODS

The present study on emu bird was conducted at the Department of Veterinary Anatomy and Histology, Veterinary College and Research Institute, Namakkal. The materials for the study were collected from 12 female apparently healthy birds procured from a well organized farm in the neighborhood of Namakkal district of Tamilnadu. The study was carried out on six mature female birds at their non-laying stage and six female birds at their laying stage for recording the structural changes in these birds. The tissues collected from ovary of emu birds were fixed in 10 per cent neutral buffered formalin, Bouin's fluid and Zenker fluid. Fixed tissues were processed through ascending grades of alcohol, cleared in xylene and embedded in paraffin wax at 58-60 °C. Paraffin sections of 3-5 µm thickness were cut and utilized for this study. Freshly collected unfixed frozen tissues and post fixed in formal calcium were cut at 20 µm thickness were utilized for demonstration lipids and enzymes.

Routine and special histological techniques viz. Ehrlich's Haematoxylin - Eosin method, Van Gieson technique for collagen fibres, Verhoeff's method for elastic fibres, Gomori's method for reticular fibres, PTAH method for muscle fibres, Masson's trichrome technique for connective tissues fibres, Periodic acid-Schiff (PAS) technique for carbohydrates, Combined AB-PAS for Neutral mucopolysaccharides (Bancroft and Stevens, 1996) were employed on all the sections of ovary for microanatomical observations. Microanatomical parameters were recorded using the Leica image processing system and software to record the diameter of the ovarian follicles in different stages of development in laying and non laying emu birds.

RESULTS AND DISCUSSION

The female reproductive system of the emu consisted of an unpaired ovary appearing as bunch of grapes and an oviduct in accordance with the findings of Gilbert (1979) in birds and Rao (1994) in domestic duck. The ovary is dark brown to black in colour with numerous ovarian follicles concentrated on the ventral surface as reported earlier by Reed *et al.* (2011). The ovary was covered externally by germinal epithelium consisting of a single layer of cuboidal cells. Bharti *et al.* (2009) observed that the ovary was covered by simple squamous epithelium with patches of simple cuboidal epithelium in chicken of Assam. The ovarian parenchyma was differentiated into cortex and medulla. The ovarian follicles of different stages of development, atretic follicles and post ovulatory follicles (corpus luteum) were seen in the cortex (Plate 1). The stroma of the spongy cortex contained numerous small blood vessels and sinuses. It consisted of collagen fibres, reticular fibres, eosinophils and large masses of yolk. The medulla consisted of collagen and reticular fibres, blood vessels, nerve bundles and smooth muscle fibres. The arteries in different planes of section were observed in the medulla (Plate 5). The interstitial cells occurred throughout the stroma in diffuse form. The cells were oval and possessed round or oval nucleus.


The ovarian follicles were differentiated into primary, secondary, tertiary and quaternary or mature follicles in addition to atretic follicles and post ovulatory follicles were irregularly distributed in the cortex. This is in agreement with the classification of ovarian follicles in fowl and ducks by Rao (1994). The oocytes occupied the entire follicles leaving no antrum in all the stages of follicular development (Plate.2). In contrast, follicles with two or three oocytes and oocytes with two nuclei were reported in fowl (Gilbert, 1979). Hence the chances of producing double yolked eggs are very rare in emu. The primary follicles consisted of a single layer of flattened granulosa cells around the oocyte and were smallest among the follicles. The diameter of these follicles varied from 77.47 ± 7.55 µm in non-laying birds to 80.66 ± 5.49 µm in laying birds. The secondary follicles were larger than the primary follicles and consisted of an oocyte with granular cytoplasm surrounded by a single layer of cuboidal granulosa cells (Plate7) similar to the findings in domestic duck (Rao, 1994). The theca folliculi appeared as a thin layer around the granulosa cells in the secondary follicles.

The cytoplasm of the oocyte in the tertiary follicles was filled by a transparent mass. In mature follicles the cytoplasm of the oocytes had yolk in the form of spheres. The diameter of secondary follicle was 145.64 ± 10.98 µm in non-laying birds and 174.86 ± 6.72 µm in laying birds. The tertiary and quaternary follicles were located close to the surface of the ovary and quaternary follicles were suspended from the ovary by follicular stalks in laying emu birds. The diameter of tertiary follicle was 472.91 ± 33.26 µm in non-laying birds and 512.36 ± 53.19 µm in laying birds. The wall of the mature follicles consisted of stratum granulosa, theca interna, theca externa, a coat of loose connective tissue and a superficial epithelium from within outwards (Plate 3). The stratum granulosa was formed of columnar cells resting on a basement membrane contained round or spherical nucleus located in the centre of the cytoplasm. The cells of stratum granulosa are variously described as simple columnar type in goose (Kovacs *et al.*, 1992) and simple cuboidal cells in Japanese quail (Yoshimura *et al.*, 1993).

The theca folliculi was divisible into internal cellular and external fibrous layers. The thin theca interna consisted of an inner layer of collagen, reticular fibres, and fibroblasts and an outer layer of vacuolated cells. The vacuolated cells identical to the interstitial cells of the stroma formed oval to spherical thecal glands. This is in direct correlation to the reports of Kovacs *et al.* (1992) in goose. The theca externa was the thickest and consisted of dense connective tissue made up of collagen, reticular and elastic fibres. A layer of stromal connective tissue was observed limiting the theca externa from the ovarian epithelium. However, smooth muscle fibres were not identified in the follicular wall in the current study as reported by Rao (1994) in domestic duck. In contrast Nassauw *et al.* (1992) identified the smooth muscle fibres in the theca externa of the pre and post ovulatory follicles in Japanese quail. The diameter of quaternary follicle varied from 927.24 ± 48.71 µm in non-laying birds to 1119.66 ± 61.93 µm in laying birds. These follicle measured upto 3.28 cm in diameter in laying birds as they were filled with enormous amount of yolk. Follicular atresia was observed in various stages of the development of the ovarian follicles. The granulosa and thecal layers were disrupted and degenerated and invaded into the

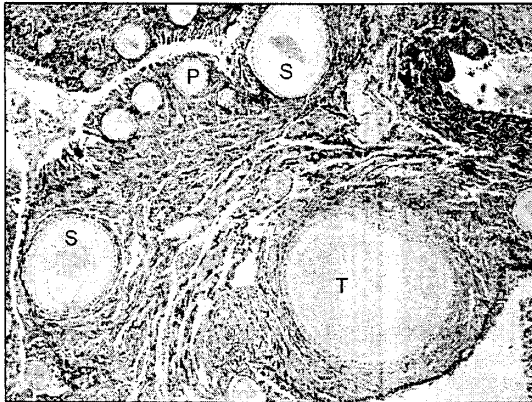
oocytes of atretic follicles. They appeared in many layers and detached from basement membrane (Plate 3). Madekurozwa and Kimaro (2006) noticed the atretic primordial and previtellogenic follicles characterized by the presence of a shrunken oocyte surrounded by a multilayered stratum granulosum in ostrich as observed in the current study. Many lymphocytes and fragments of nuclei were also seen among the granulosa cells within the follicles. The yolk contents were either extruded into the surrounding stroma or resorbed in situ by phagocytic cells. This is in concordance with the findings of Gilbert (1979) who observed the bursting type of atresia, and the invasion atresia leading to the resorption of the yolk in situ in fowl and other birds. The post-ovulatory follicle (or corpus luteum) was observed in the cortex of the ovary (Plate 4). The presence of post-ovulatory follicle was also described by Guraya and Chalana (1976) in house sparrow. The luteal cell mass consists of hypertrophied granulosa luteal cells and thecal luteal cells. During regression, the granulosa luteal cells were degenerated and corpus luteum consisted of few theca luteal cells and more of dense irregular connective tissue.

Plate 3.



Photomicrograph showing Atretic ovarian follicle with degenerating granulosa and thecal layers (arrows) in non-laying emu birds. H & E x 400

Plate 1.




Photomicrograph showing different stages of developing ovarian follicles in laying emu birds. P – Primary follicle, S – Secondary follicle, T – Tertiary follicle. H & E x 100

Plate 4.



Photomicrograph showing post-ovulatory follicle (Po) in the cortex of laying emu birds. H & E x 100

Plate 1.



Photomicrograph showing different layers in the wall of mature ovarian follicle. Bm – Stratum granulosum, Tf – Theca folliculi. AB-PAS x 400

Table 1. Diameter of different ovarian follicles

	Primary follicle (µm)	Secondary follicle (µm)	Tertiary follicle (µm)	Quaternary follicle (µm)
LAYING	80.66 ± 5.49	174.86 ± 6.72	512.36 ± 53.19	1119.66 ± 61.93
NON-LAYING	77.47 ± 7.55	145.64 ± 10.98	472.91 ± 33.26	927.24 ± 48.71

REFERENCES

Bancroft, J.D. and Stevens, A. 1996. Theory and Practice of Histological Techniques. 4th Edn. Churchill Livingstone, Edinburgh, London.

Bharti, S.K., Gautam, A.K., Talukdar, S.R., Sarma M. and Kumari, A. 2009. Histological and histochemical studies on the ovary of adult indigenous chicken of Assam. *Indian J. Vet. Anat.*, 21: 46-48.

Gilbert, A.B. 1979. Female genital organs. Chapter 5 in "Form and function in birds". Eds. A.S. King and J. McLelland. Vol.I, Academic press. London.

- Guraya, S.S. and Chalana, R.K. 1976. Morphology of the post ovulatory follicle of house sparrow. *Acta Biol Acad. Sci. Hung.*, 27: 261-267.
- Kovacs, J., Forgo, V. and Peczely, P. 1992. The fine structure of the follicular cells in growing and atretic follicles of the domestic goose. *Cell Tissue Res.* 267: 565-569.
- Madekurozwa, M.C and Kimaro, W.H. 2006. A morphological and immunohistochemical study of healthy and atretic follicles in the ovary of the sexually immature ostrich (*Struthio camelus*). *Anat. Histol. Embryol.* 35:235-258.
- Nassauw, L.V., Callebart, M., Harrison F. and Schenermann, D.W. 1992. Smooth muscle cells in the walls of ovarian follicles in the Japanese quail. *Cell Tissue Res.* 269: 49-56.
- Rao., T.S.C. 1994. Microanatomical studies on the reproductive system of the domestic duck (*Anas Boschas domesticus*). Ph.D Thesis, Tamil Nadu Veterinary and Animal Sciences University, Madras.
- Reed, R.B.Jr., Cope, L.A. and Blackford, J.T. 2011. Macroscopic anatomy of the reproductive tract of the reproductively quiescent female emu (*Dromaius novaehollandiae*). *Anat Histol Embryol.* 40: 134-41.
- Yoshimura Y., Okamoto, T. and Tamura, T. 1993. Ultrastructural changes of oocytes and follicular wall during oocyte maturation in the Japanese quail. *J. Reprod. Fert.* 97: 189-199
