

## Liposarcoma in a Non-Descript Dog\*

K. Gopal<sup>1</sup>, S. Vairamuthu, C. Balachandran and Ravi Sundar George

Department of Veterinary Pathology, Madras Veterinary College, TANUVAS, Chennai – 600 051.

(Received : 26-09-2016 394/16 Accepted : 24-10-2016)

### Abstract

A nine year old male non-descript dog had the history of swelling on the left thigh for the past one month. Cytological evaluation revealed pleomorphic neoplastic lipocytes amidst foamy background. Histopathological examination revealed neoplastic lipocytes in large lobules surrounded by collagen bundles running in different directions. The neoplastic cells had an indistinct cell outline and faintly eosinophilic cytoplasm with distinct vacuoles of varying sizes. The case was diagnosed as liposarcoma.

**Key words:** non-descript dog, liposarcoma, cytology, pathology

Liposarcomas (LS) are uncommon tumours with an overall incidence of 0.2–0.5% among all the canine neoplasms (Wang *et al.*, 2005). They are locally invasive tumour that rarely metastasizes and wide marginal excision is required to prevent the recurrence (Baez *et al.*, 2004). A case of liposarcoma encountered in a non-descript dog is reported.

### Materials and Methods

A nine year old non-descript male dog was presented at the Madras Veterinary College Teaching Hospital, Chennai with the history of a swelling on the left thigh and difficulty in walking. Clinical examination revealed a firm elongated irregular mass in the lateral aspect of the left thigh extending up to the perineum. The mass was compressing the scrotum on the right side and the animal evinced difficulty in walking (Fig.1). Surgically, the tumour was removed and fixed in 10 percent formalin. Paraffin embedded sections were stained with Hematoxylin and Eosin (H&E).

### Results and Discussion

Cut section of the tumour mass appeared multilobulated with intermingled soft areas of glistening yellow mucoid tissue and fibrous area. The mass was deeply attached to the underlying thigh muscles. Cytological smears revealed pleomorphic neoplastic lipocytes amidst foamy background.

The nuclei were round to oval with coarse chromatin and contained single prominent nucleoli. Mild anisokaryosis was observed (Fig.2). Occasionally multinucleated cells were observed. These findings concurred with earlier work of Krithiga *et al.* (2005).

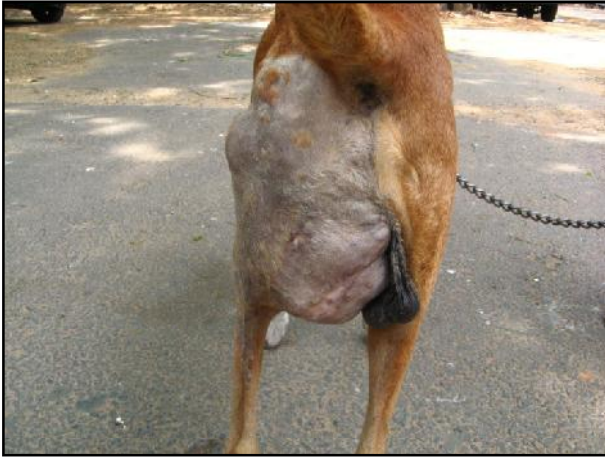Histopathologically, the neoplastic lipocytes occurred in large lobules surrounded by collagen bundles running in different directions. The neoplastic cells had an indistinct cell outline and faintly eosinophilic cytoplasm with distinct vacuoles of varying sizes in a few cells to single large vacuole. Mitotic figures and nuclear moulding were seen. Occasional multinucleated cells and megakaryocyte were also observed.

The etiology of canine liposarcomas is largely unknown and sometimes it is associated with the presence of foreign bodies (Vascellari *et al.*, 2004). The invasion and metastasis of visceral liposarcomas are rarely reported. Most of the liposarcomas are locally invasive and some had evidence of metastasis in the organs like the spleen, liver and lung (Wang *et al.*, *loc. cit.*).

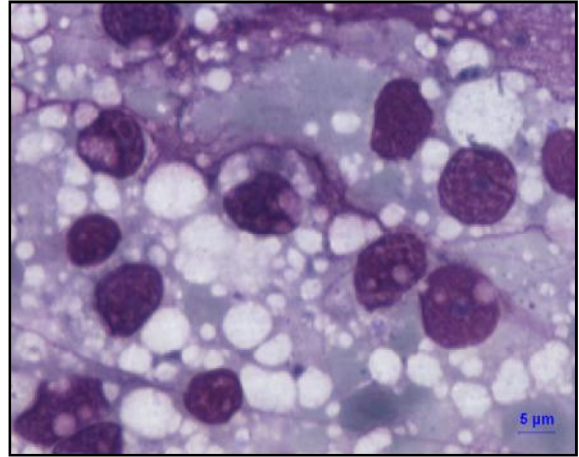
Based on the cellular morphology, liposarcomas are classified into three subtypes in animals: well-differentiated, pleomorphic and myxoid liposarcomas (Murphey, 2007). In the present case, the liposarcoma is confirmed as pleomorphic type because it showed highly

\*Forms part of M.V.Sc thesis work

<sup>1</sup>Corresponding author : Email : drvetpal@gmail.com



**Fig 1.** Dog-Nondescript – Thigh – Liposarcoma



**Fig 2.** Dog-Nondescript – FNAB-Pleomorphic lipocytes with vacuolated cytoplasm. LG Scale bar 5  $\mu$ m

variable morphological features with large multinucleated neoplastic cells.

#### References

- Baez, J.L., Hendrick, M.J., Shofer, F.S., Goldkamp, C. and Sorenmo, K.U. (2004) Liposarcomas in dogs: 56 cases (1989-2000). *J. Am. Vet. Med. Assoc.*, **224**:887-891.
- Krithiga, K., Manohar, B.M. and Balachandran, C. (2005) Cytological and histological diagnosis II. Canine mesenchymal tumours. *Indian J. Vet. Pathol.*, **29**: 121-124.

- Murphey, M.D. (2007) World Health Organization classification of bone and soft tissue tumors: modifications and implications for radiologists. *Semin. Musculoskelet. Radiol.*, **11**: 201-214.

- Vascellari, M., Mutinelli, F., Cossetini, R. and Altinier, E. (2004) Liposarcoma at the site of an implanted microchip in a dog. *Vet. J.*, **168**:188-190.

- Wang, F., Liang, S., Eng, H., Jeng, C. and Pang, V. (2005) Disseminated liposarcoma in a dog. *J. Vet. Diagn. Invest.*, **17**:291-294.

Indian Vet. J., June 2017, 94 (06) : 75 - 77

## Diagnosis of Bovine Hydrothorax with Computed Radiography

**Mahendra Tanwar, T.K. Gahlot, Sakar Palecha and P. Bishnoi**

Department of Veterinary Surgery and Radiology, College of Veterinary and Animal Science, Rajasthan University of Veterinary and Animal Sciences, Bikaner-334001.

(Received : 05-08-2016 **319/16** Accepted : 18-10-2016)

#### Abstract

Hydrothorax condition was diagnosed in 17 bovines (16 cattle, 1 buffalo) in recently parturited, except 7 cattle in advanced pregnancy with clinical signs of tachypnoea, brisket oedema, engorged jugular veins and muffled heart sounds. A right lateral radiograph revealed presence of horizontal fluid line and gas-fluid interaction (15 cases) due to accumulation of varying volume of fluid in the thoracic cavity

and complete obliteration of cardiac shadow. The cases were discussed.

**Key words:** Bovines, computed radiography, hydrothorax

Hydrothorax condition is a result of accumulation of serous, clear and odorless fluid in the thoracic cavity (James *et al.*, 2016). Foetid smell exudate indicated microbial infection or abscess due to penetrating trauma or hardware disease condition (Woolums, 2014). Hydrotho-