

**ULTRASONOGRAPHIC STUDY OF ABDOMINAL
ORGANS IN SLOTH BEARS (*Melursus ursinus*)**

SUMEDH M. SHASTRY

**INSTITUTE OF WILDLIFE VETERINARY RESEARCH,
KODAGU
&
VETERINARY COLLEGE, BENGALURU
KARNATAKA VETERINARY, ANIMAL AND FISHERIES
SCIENCES UNIVERSITY, BIDAR-585 401**

JANUARY, 2018

**ULTRASONOGRAPHIC STUDY OF ABDOMINAL
ORGANS IN SLOTH BEARS (*Melursus ursinus*)**

Thesis submitted to the
Karnataka Veterinary, Animal and Fisheries Sciences University, Bidar
in partial fulfilment of the requirements for the award of the degree of

MASTER OF VETERINARY SCIENCE

in

WILDLIFE

By

SUMEDH M. SHASTRY

**INSTITUTE OF WILDLIFE VETERINARY RESEARCH,
KODAGU
&
VETERINARY COLLEGE, BENGALURU
KARNATAKA VETERINARY, ANIMAL AND FISHERIES
SCIENCES UNIVERSITY, BIDAR-585 401**

JANUARY, 2018

**KARNATAKA VETERINARY, ANIMAL AND FISHERIES
SCIENCES UNIVERSITY, BIDAR
VETERINARY COLLEGE, HEBBAL, BANGALORE
AND
INSTITUTE OF WILDLIFE VETERINARY RESEARCH,
DODDALUVARA, KODAGU**

CERTIFICATE

This is to certify that the thesis entitled *ULTRASONOGRAPHIC STUDY OF ABDOMINAL ORGANS IN SLOTH BEARS (Melursus ursinus)*, submitted by **Mr. SUMEDH M. SHASTRY**, ID. No. **MVHK 1549** in partial fulfilment of the requirements for the award of Master of Veterinary Science in Wildlife of the Karnataka Veterinary, Animal & Fisheries Sciences University, Bidar is a record of bonafide research work carried out by him during the period of his study in this University under my guidance and supervision and the thesis has not previously formed the basis for the award of any degree, diploma, associateship, fellowship or other similar titles.

Bangalore
January 2018

Prof. M. NARAYANA BHAT
Major Advisor

Approved by:

Chairman: _____
(**Prof. M. NARAYANA BHAT**)

Members: 1. _____
(**Prof. L. RANGANATH**)

2. _____
(**Prof. P. T. RAMESH**)

3. _____
(**Dr. M. A. KSHAMA**)

4. _____
(**Dr. ARUN A. SHA**)

Affectionately
Dedicated to
My Beloved Mother,
Father
and Brother

ACKNOWLEDGEMENT

The Almighty God, who has helped me to get an admission in Veterinary College, Hebbal, Bangalore, helped me build a path of own and advised me to select Wildlife, strengthened me at the time of puzzles and difficulties and blessed me with all of His graces to succeed in my studies and life, first of all I thank Him for all His goodness and blessings showered upon me.

I take this opportunity as my privilege and honour to express my deep sense of appreciation, gratitude and wholehearted indebtedness to **Dr. M. Narayana Bhat**, Professor and Head of Department of Teaching Veterinary Clinical Complex and Chairman of my Advisory Committee for his constant supervision, support, motivation, encouragement and who stood by me during my difficult times. Gratitude is offered not only for his excellence as a teacher but also his gentle, persistent, and wise mentoring.

I was fortunate to have advice and constructive suggestions throughout this study from **Dr. L. Ranganath**, Dean, Veterinary College, Hassan and as my Advisory Committee member.

I am really grateful to **Dr. P. T Ramesh**, Professor and Head of Department of Veterinary Medicine, for his continuing encouragement, moral support and valuable suggestions as a member of advisory committee.

I wholeheartedly thank **Dr. Kshama. M.A**, Associate Professor (I/C), Dept. of TVCC, Veterinary College, Hebbal, Bengaluru, for her support, encouragement, innovative suggestions, overwhelming assistance were great inspiration to me throughout the course of my study.

I express my indebtedness and sincere thanks to **Dr. Arun A. Sha**, Director Wildlife SOS, Bannerghatta Bear Rescue Center, Bengaluru, for being a member of my Advisory Committee and his humane attitude, inspiring guidance and technical guidance throughout the course of my research.

I would like to take this opportunity to thank **Dr. Muralidhara. A**, Director, IWVR for his support, encouragement and all his inputs for this work. Also I am grateful to **Dr. H.A. Upendra**, Professor, Department of TVCC, for an enlivening guidance.

It is my pleasure to acknowledge **Dr. K. M. Srinivasa Murthy**, Associate Professor (I/C), Department of Veterinary Surgery and Radiology, for all the suggestions and expert advice.

I feel inadequacy of words to express my heartfelt thanks to **Dr. Sagar. R. S**, for all his help and valuable suggestions to give a proper shape to the current manuscript.

I extend my earnest thanks to **Dr. Nirupama Jaysingh, Dr. Sujay Suresh** and **Dr. Nikita Salian**, Veterinary Officer at Bannerghatta Biological Park, for their constant encouragement and untiring support.

I am gratefully indebted to **Dr. Tista Joseph** and **Dr. Nithin Krishna**, Wildlife SOS, Bear Rescue Centre, Bannerghatta Biological Park for their technical expertise in handling bears. I would also like to thank **Sujith, Krystal, Lenu** and **Shubnoy**, Wildlife SOS, Bear Rescue Centre, Bannerghatta Biological Park for their constant support.

I would like to take this opportunity to be thankful to all the **Sloth Bears** at the Wildlife SOS, Bear Rescue Centre for being cooperative for all the procedures without them this research would not be possible.

I am thankful to the entire **animal keepers** of the Wildlife SOS, Bear Rescue Centre, Bannerghatta Biological Park for their support.

I acknowledge the help of my seniors and friends **Dr. Sanath Krishna** and **Dr. Karthik Manjunath** who have a great passion towards wildlife.

I express gratitude to my best friends **Kruthika** and **Udayshankar** for their emotional support throughout my study.

I am indebted to my friends **Dr. Yamini** and **Dr. Achintha** for all their love, support and informative ideas during the study.

I owe a very special thanks to my friends **Dr. Dilip, Dr. Sujith** and **Dr. Vijay** for standing by me all throughout the course. And to my seniors and friends **Dr. Meghana, Dr. Preeti, Dr. Darshan** and **Dr. Anil** for all their support and encouragement. Also I would like to thank my juniors and friends **Dr. Bhargav** and **Dr. Tvesa** for standing by me during this study.

It is my bound duty to thank my juniors and friends **Namratha** and **Abhay** for their love and affection.

I owe thanks to **Dr. Akanksha** and **Dr. Moiteii Hmar** for their encouragement.

It's my bound duty to thank my friends, colleagues and juniors **Dr. Suprith, Dr. Swagatika, Dr. Prayag, Dr. Dhareppa** and **Dr. Hitaishi** for their help and assistance. The moments spent with you guys in college will be cherished.

It is my duty to thank **Ms. Naima**, Laboratory Assitant, Department of TVCC and **Ms. Rathamma**, attender, Department of TVCC for all their help.

I also would like to thank my friends **Manish, Sumitra** and **Deepak** who stood by me and supported me during this work.

Finally and foremost, without the encouragement, help and support provided by my beloved **Mom (Sunitha), Dad (Muralidhar), Brother (Skanda)**, all **Uncles & Aunts** specially **Dr. Taranath** and **Usha Taranath, Cousins (Padmaja and Aarathi)** and the blessing of both my **grandmothers (Bhagirathamma and Lalithamma)**, I would not have completed this thesis. To all, I am most grateful.

There are many others who in various ways, have contributed to and assisted in this work. I express my sincere thanks to them.

Bangalore

January, 2018

SUMEDH M SHASTRY

CONTENTS

CHAPTER	TITLE	PAGE No.
1.	INTRODUCTION	1-4
2.	REVIEW OF LITERATURE	5-18
3.	MATERIALS AND METHODS	19-25
4.	RESULTS	26-45
5.	DISCUSSION	46-52
6.	SUMMARY	53-54
7.	BIBLIOGRAPHY	55-58
8.	ABSTRACT	59

LIST OF TABLES

Table No.	Title	Page No.
1.	Mean and standard error of measurements of different organs	30
2.	Mean and standard error of physiological parameters	30
3.	Mean and standard error of serum biochemistry	30

LIST OF PLATES

Plate No.	Title	Page No.
1.	Logiq XP ultrasound machine used for ultrasonography in sloth bears with the gel	24
2.	Blowpipe used for administration of the chemical restraint	25
3.	The drugs used for chemical restraints: a) Anased® b) Vetaler® and c) Lori®	25
4.	Sagittal plane of liver	33
5.	Markings showing the liver borders and sharp edges	33
6.	Sagittal acoustic window showing the topographical anatomy of liver, stomach and spleen	34
7.	Markings showing liver, stomach and spleen	34
8.	Sagittal section of gall bladder with liver and hyperechoic diaphragm	35
9.	Longitudinal section of gall bladder with hyperechoic borders and mild echoic sludge	35
10.	Sagittal acoustic window showing liver with diaphragm	36
11.	Markings showing the hyperechoic diaphragm with liver	36
12.	Liver lobes and gall bladder with sludge	37
13.	Markings showing the right lobe and caudate lobe of liver and gall bladder with sludge	37
14.	The capsule surrounding the spleen	38
15.	Marking showing the hyper echogenicity of the capsule	38
16.	Head of the spleen and stomach	39

Plate No.	Title	Page No.
17.	Marking showing the head of the spleen	39
18.	Sagittal section of body and tail of spleen turning at the mid abdomen	40
19.	Marking showing the body and tail of spleen	40
20.	Lobulated left kidney	41
21.	Marking showing the lobulated left kidney with anechoic medulla and hyperechoic cortex in 1:2 ratio	41
22.	Lobulated right kidney	42
23.	Marking showing the lobulated right kidney with anechoic medulla and hyperechoic cortex in 1:2 ratio	42
24.	Hyperechoic urinary bladder wall with anechoic urine	43
25.	Post mortem picture showing the topographical anatomy of abdominal organs in sloth bears in ventro-dorsal view	44
26.	Lobes of liver with gall bladder	44
27.	Gross specimen of sock shaped spleen	45
28.	Gross specimen of lobulated kidney	45

LIST OF ABBREVIATIONS

°F	-	Degree Fahrenheit
ALT	-	Alanine Aminotransferase
AST	-	Aspartate Aminotransferase
BUN	-	Blood Urea Nitrogen
BW	-	Body Weight
cm	-	Centimeter
dl	-	Deciliter
G	-	Gauge
HCl	-	Hydrochloric acid
IU	-	International Units
kg	-	Kilogram
L	-	Liter
mg	-	Milligram
MHz	-	Mega Hertz
ml	-	Milliliter
SONAR	-	Sound Navigation and Ranging

Introduction



1. INTRODUCTION

Bears belong to the order carnivore under the family Ursidae. There are only eight species of bears in the world. They are widespread across the globe appearing in a wide variety of habitats ranging from the Arctic to the tropics. Bears have been found to be in the continents of North America, South America, Europe and Asia.

Common characteristics seen in these bears are large bodies, stocky legs, long hair, snout, sharp nonretractable claws, rounded ears and a short tail. Even though they are heavily built, they still are good runners, climbers and swimmers. Their sense of smell is excellent which helps them in finding feed. Among these eight species of bears, polar bears are true carnivores and giant pandas mostly feed on bamboo. The other six species being omnivore, feed on a variety of diets.

Bears are either diurnal or nocturnal and use caves or logs to make dens. Most of the species occupy the dens during winter for hibernation which ranges up to 100 days.

All bears are solitary in nature except during the mating season, after which the mother and the cubs are together for a short period.

In the recent times, bears have become endangered due to habitat losses and poaching for various bear parts. The trade of these parts is prohibited but still ongoing.

In Indian subcontinent, there are four species of bears which are seen namely; Asiatic Black Bear, Brown Bear, Sun Bear and Sloth Bear. Among these, the Sloth Bear is seen throughout India with populations in the Himalayan foothills and northeast India

becoming isolated, the Western Ghats and central Indian landscapes, now possibly harbor the largest populations (Puri *et al.*, 2015).

The sloth bear is listed as vulnerable by the IUCN and in 'Schedule I' of the Wildlife (Protection) Act, 1972. The Indian Sloth bear can easily be recognized by their shaggy black coat, long muzzle, protruding lip and a white V-shaped patch on the chest. They have a particular proclivity to "vacuum" up termites and ants using their long snout.

Ultrasound is a diagnostic imaging technique which denotes high-frequency sound waves inaudible to the human ear. Audible sound frequency is of the order of 20,000 kilohertz (1 kHz = 1000 cycles per second). Diagnostic ultrasound frequencies range from 2 to 15 megahertz (1 MHz = 1,000,000 cycles per second).

In diagnostic ultrasound a pulse of ultrasound waves is generated by piezo electric crystals present in the probe which is directed into the body. It traverses the tissues until it reaches a reflecting surface from which it is reflected back to the transmitter, which also acts as a receiver. The returning signal is called an echo. The returning echoes reach the probe and a computer processes the signals and displays them on a computer screen as a two-dimensional representation.

Interpretation of ultrasonograms requires an understanding of the principles of ultrasound and its interaction with tissue. In addition, one must be familiar with the ultrasound machine and the transducer and their capabilities, as well as the artifacts that can be generated. Otherwise, problems with misinterpretation or over interpretation will arise.

The ultrasonogram is essentially an image of a thin slice of tissue. The orientation of the transducer and the plane of section within the body cavity or organ of interest are standardized, as is the nomenclature for various organ studies.

Each organ has a specific echo pattern that is dependent on its structure. Ultrasonography can identify changes in the organ size, shape, parenchymal and vascular structures and differentiate homogenous liquids and heterogeneous structures.

Advantages of ultrasound are: 1. It is noninvasive. 2. It enables evaluation of dynamic function (e.g., in vascular structures). 3. It usually does not require general anesthesia or sedation. 4. It permits accurate fine-needle aspiration or biopsy of tissues.

Disadvantages are: 1. The equipment can be expensive. 2. Artifacts may lead to misinterpretation. 3. It allows no real appreciation of skeletal structure except for bony surfaces. 4. It is difficult to attribute changes in echo texture and echogenicity to certain pathophysiologic causes (e.g., focal echo texture changes in the liver may be due to fatty infiltration or neoplasia).

In non-domestic species, most of which lack basic data, ultrasonography is an ideal tool to study reproductive biology, in both captive and wild population. For a long time, the use of ultrasonography for reproduction management in non-domestic species was sporadic. Now, this technique has become an indispensable imaging modality in the diagnosis of diseases.

In amphibians and birds, ultrasonography is an advantage in sex identification. In reptiles, it has also been used in sex identification, pregnancy diagnosis, prediction of

parturition date and identification of prenatal conditions. In case of wild mammals, ultrasound can be used to detect pregnancy and reproductive disorders similar to the domestic animals except with few anatomical changes. It also helps in monitoring fetal development which in turn helps us in feeding the pregnant animal better, especially in elephants where the pregnancy is longest compared to other mammals and it has been difficult to estimate the foetal age.

There is very little known on the normal size, shape and echogenicity of the internal organs in sloth bears due to which it is difficult to differentiate the abnormalities of the organs using ultrasonography.

Due to the paucity of information related to the structure of the abdominal organs, this research is being carried out with the following objectives.

1. To study and record the normal echotexture of different abdominal organs using ultrasonography in sloth bears.
2. To study and record the normal sonographic anatomy of different abdominal organs using ultrasonography in sloth bears.

Review of Literature



2. REVIEW OF LITERATURE

The present work has been undertaken to study the normal echotexture and normal sonographic anatomy of different abdominal organs using ultrasonography in Sloth bears.

In the present chapter, diagnostic imaging techniques, ultrasonography in wild animals, ultrasonography of different abdominal organs, physiological parameters and serum biochemistry in Sloth bears have been reviewed.

Sloth bears are known to suffer from numerous infectious and non-infectious diseases like leptospirosis, neoplasms, tuberculosis, infectious canine hepatitis (Fowler and Miller, 2015) etc.

Sloth bears are endangered species belonging to the Indian sub-continent. The Western Ghats and central Indian landscapes now possibly harbor the largest populations of sloth bears (Puri *et al.*, 2015).

Various imaging techniques can be utilised for the diagnosis of certain diseases. Ultrasonography is one of the diagnostic procedures used frequently in diagnosis in wildlife diseases.

2.1 DIAGNOSTIC IMAGING

Diagnostic radiology has been an integral part of veterinary practice. Imaging modalities such as ultrasound, computed tomography, magnetic resonance imaging and

nuclear medicine have expanded veterinary diagnostic capabilities and understanding of disease.

The science and art of interpreting diagnostic images is the cornerstone of many diagnosis. Imaging tests have the advantage of being quick and noninvasive or minimally invasive. These technologies offer the ability to see inside the body and detect pathologic changes as well as evaluate organ function, which could otherwise be discovered only by surgery or necropsy.

Radiologic interpretation is based on detecting alterations from normal. Changes in size, shape, margin, position, number, symmetry and opacity are evaluated. The same process can be applied to other imaging modalities by substituting opacity for echogenicity in diagnostic ultrasound, attenuation in computed tomography, signal intensity in magnetic resonance imaging and radiopharmaceutical uptake in nuclear medicine (Graham, 2002).

A 22 year old European brown bear was presented to the Onderstepoort Veterinary Academic Hospital, South Africa after an acute onset of hind limb paralysis, radiographs revealed marked degenerative joint disease of the stifles, tarsi and digits and vertebral column revealed multiple lesions consistent with chronic and acute disc herniation (Wagner *et al.*, 2005)

An undescribed endocranial cavity of *Ursus deningeri* was compared using high-resolution x-ray computed tomography with related species such as *Ursus spelaeus* and *Ursus arctos*. The characters studied included the braincase morphology and also

quantitative measurements which are only available with this technique. The surface of the frontal sinuses and the brain cavity, the shape of the ethmoid bone, and the basioccipital pneumatization were analyzed. The resulting analysis supports the relationship of the two ursids included in the cave bear lineage (*U. deningeri* and *U. spelaeus*), as among others, being similar in the endocranial roof or the palatine profile (García *et al.*, 2006).

In bears, diagnostic procedures are generally similar to those used for domestic dogs and could be easily adapted for use in bears. Whole body radiography, including head, thoracic, abdominal and extremity views, is challenging in larger bears because of size, as multiple exposures to cover the entire area are usually necessary and anesthesia time to procedures is increased. It is challenging to ensure that the x-rays penetrate the abdomen of an adult polar bear or brown bear to obtain high-quality diagnostic films. Ultrasonography in larger patients is challenging but is easier and routinely performed in the smaller species. Endocavitary probes are commonly used rectally for imaging the reproductive tract. Joints and teeth are also common sites radiographed in bears (Fowler and Miller, 2015).

2.1.1 ULTRASONOGRAPHY

Ultrasonography is used as a tool in diagnostic imaging. Ultrasonography scans the tissues on the principle similar to the SONAR. For ultrasound, a short pulse of energy of high frequency sound produced by a crystal in the transducer converts electrical energy to ultrasound. Ultrasonographic examination of the abdominal organs must be

systematic and thorough to avoid overlooking lesions. It is performed by scanning each organ in turn for normalcy or evidence of disease (Graham, 2002).

Augusto (2008) stated that each organ has a specific echo pattern that is dependent on its structure. Ultrasonography can identify the changes in size, parenchyma and vascular structures, and differentiate homogenous liquids and heterogeneous structures.

Ultrasound denotes high-frequency sound waves inaudible to the human ear. Audible sound frequency is of the order of 50 to 20,000 kilohertz (1 kHz = 1000 cycles per second). In diagnostic ultrasound, a pulse of ultrasound waves is directed into the body. It traverses the tissues until it reaches a reflecting surface from which it is reflected back to the transmitter, which also acts as a receiver. The returning signal is called an echo. The returning echoes reach a computer that processes the signals and displays them on a screen as a two-dimensional (2-D) representation. Diagnostic ultrasound frequencies range from 2 to 15 megahertz (1 MHz = 1 million cycles per second). Use of this noninvasive, flexible, and relatively safe technique is becoming widespread in practice (Kealy *et al.*, 2011).

Ultrasound waves are generated by the piezoelectric effect in a suitable medium, such as a specially manufactured crystal made of lead zirconate. When an electrical impulse is applied to the crystal, the piezoelectric effect results in the crystal becoming deformed. It then vibrates, and ultrasound waves are generated. The crystal acts both as an emitter (1% of the time), sending ultrasound waves into the body and as a receiver (99% of the time), and receiving returning echoes. When it receives ultrasound echoes, it

produces electrical impulses proportionate to the strength of the returning echoes. These impulses are displayed as various shades of gray on the monitor. Stronger the returning echo, the brighter the point is on the screen image. The time between emission and the return of the reflected echoes depends on the distance traveled. The ultrasound machine calculates the position of the source of reflection of the returning echoes and displays it at a specific site on the monitor. A centimeter scale enables the operator to appreciate the relative depth of structures on the image (Kealy *et al.*, 2011).

2.1.2 ULTRASONOGRAPHY IN WILD ANIMALS

Ultrasound imaging in reproductive medicine offers optimization of the induction of the sexual cycle and ovulation, superovulation regimes, contraception programs, semen collection and testicular sperm extraction techniques, ovum pick up and ovarian transplantation procedures, as well as the application of artificial insemination, embryo collection and transfer. In non-domestic species, most of which lack basic data, ultrasonography is an ideal tool to study reproductive biology, in both captive and wild population. For a long time, the use of ultrasonography for reproduction management in non-domestic species was sporadic. Now, this technique has become an indispensable imaging modality in the diagnosis of diseases (Hildebrandt *et al.*, 2000).

Schildger and Triet (2001) reported that in amphibians, ultrasonography was used in sex identification and other organs have also been studied including the un-compartmented pleuro-peritoneal cavity, fluid within the celom, heart, liver, gall bladder, stomach, kidney and bladder. It was also reported that the liver is hyperechoic when compared to the reptiles.

Ultrasonography is relatively a new addition of imaging modality of soft tissues of the body in zoo and wild animals. It has several advantages over other imaging modalities. Application of ultrasonography in wild animals does have a number of specific problems that includes stress on restraining, anatomical peculiarities and lack of baseline data on sonographic appearances of different organs (Hoque., 2005).

In elephants, the pregnancy is longest compared to other mammals and it has been difficult to estimate the foetal age. With the recent advances in ultrasound scanning it has made it possible to monitor the growth and development of foetus and also know the gestational age (Hildebrandt *et al.*, 2007).

Augusto (2008) opined that in birds, ultrasonography was an advantage in sex identification in monomorphic birds. In reptiles it has been used to study the hepatic disease, urinary bladder calculi, coelomic fluid and cardiac activity. Also it has been used in sex identification, pregnancy diagnosis, prediction of parturition date and identification of prenatal conditions. In chelonians, it is also possible to access the internal organs from the skin between the head and thoracic membrane and the skin cranial to the pelvic membrane. For snakes and lizards, ultrasound is best performed from the ventral aspect and it gives a clear view of the ova development and follicular growth. Only disadvantage being the scales may cause a few artifacts. In case of wild mammals, ultrasound can be used to detect pregnancy and reproductive disorders similar to the domestic animals except with few anatomical changes. It also helps in monitoring fetal development which in turn helps us in feeding the pregnant animal better. This technique is used to identify the normal and abnormal shape and size of the kidney and liver in wild

mammals. It has also helped to identify the distended bowel loops and colon in bush dogs.

Ultrasound scanner has been a practical part of the medical equipment in Cincinnati zoo which has helped them to plan the mixing of male and female Sumatran Rhino based on the size of the female's follicle, which has helped them in conservation of the threatened species (Radcliff *et al.*, 2009).

Ultrasonography was used to characterize giant panda fetal development in 13 giant panda pregnancies, which correlated the fetal development and the physiologic changes in the female during pregnancy, and to confirm delayed implantation (Hemin *et al.*, 2009).

Using ultrasonography, it has been possible to study the normal anatomical structures, their appearance and measurements of the eye in elephants (Bapodra *et al.*, 2010).

Acorda and Mergilla (2010) studied that both the right and left kidney in a Bengal tiger were smooth, bean shaped and elongated in sagittal section. The centrally located renal sinus was observed to be hyperechoic and the renal medulla was seen as hypoechoic to anechoic structure. The renal cortex appeared hypoechoic and the renal capsule was either hyperechoic or less distinct and appeared to blend with the surrounding structures.

Kircher (2011) mentioned that low frequencies (2-3.5 MHz) had good tissue penetration and were used to examine deeper abdominal organs and thoracic structure in

large animals, whereas high frequency (7.5 to 12 MHz) produced good image resolution with limited tissue penetration.

Ultrasonography is a potential armament in the hands of expert sonologists to study wildlife biology, in maximizing their reproductive efficiency and for early and precise diagnosis and effective treatment of diseases in wild animals (Hoque., 2013).

Huaijantug *et al.* (2016) found that ultrasonographic measurements of kidney size were useful in practical diagnosis of kidney disease. Also there was a significant difference in the length of the right and the left kidney. The study demonstrated that kidney length was statistically significantly associated with the body weight.

Hildebrant and Saragusty (2016) observed that the technology has helped in visualizing shape, structure, size and identifies pathologic lesions in many body structures, including skin, muscles, tendons and internal organs. Ultrasonography has a wide range of uses, ranging from assessment of body fat to searching for pathologies in soft tissues and tendons, but the most leading application of this technique has been in reproductive medicine. Various reasons exist for the limited use of the technique in wild animals. The wide range of species differs from each other in many aspects, including their morphology and specialized structures. Effective penetration of ultrasound is limited to certain depths, which makes it often challenging or practically impossible to visualize various internal structures in large-sized animals (e.g. elephants, whales). Due to the recent developments and modifications in ultrasonography, there has been a decrease in machine size that makes it more portable and affordable and the new methods of examination will all facilitate increased use of this tool for health and reproduction

management in wildlife species. In exotic animals, certain specialized structures or features such as the carapace and plastron in tortoises and turtles, feathers and air sacs in birds, scales on many fish and reptilian species, or exoskeleton in many invertebrates may all interfere with the ultrasonographic examination and may require innovative scanning techniques.

For large fish, transducers of 2 to 5 megahertz (MHz) are usually chosen and for small fish, 7.5 to 16 MHz would be more appropriate for better visualization of the small body structures. Ultrasonography has been used in the fish industry at least since the early 1980s. The main application of this technology has been for the determination of the sex and maturity status of juvenile and adult fish. Other areas in which ultrasonography has been found to be a useful tool include evaluation of ovarian activity and ovulation, health assessment, diagnosis of pathologies, anatomic studies and muscle development evaluation. Assessment of reproductive potential, sexual maturity and pregnancy has also been done in elasmobranchs (sharks and rays) (Hildebrand and Saragusty, 2016).

Amphibians are well suited for ultrasonographic examination as they do not have external structures such as fur, feathers or scales that may impede imaging, their coelom usually contains some fluid that helps enhance the quality of the images and this fluid may increase in volume in diseased animals, and to varying degrees, depending on the species, they dwell in water, making it possible to scan them while they are submerged in water as is done in fish. Because of their body sizes, normally transducers ranging from 5 to 16 MHz. The main applications of ultrasonography in amphibians include sex

determination, assessment of the reproductive status, evaluation of cardiac activity and blood flow (including the use of Doppler ultrasonography) and health assessment (e.g., parasitic and neoplastic status) and anatomic studies (Hildebrant and Saragusty, 2016).

Transcutaneous ultrasonography may be problematic in some reptilian species because of the shell or scales that cover their bodies (e.g., Australian bobtail lizard, *Tiliqua rugosa*; or Komodo dragon, *Varanus komodoensis*). . In turtles, because of their shell, ultrasonography may be conducted from two restricted windows between the carapace and the plastron. In snakes and lizards, especially those that are covered with thick hard scales, the best ultrasonographic visualization may be achieved from the ventral aspect of the animals. Smaller animals are best imaged with 7.5 to 16 MHz transducers and large ones may be better examined with 2.0 to 5.0 MHz probes. Coupling gel should be applied to achieve proper coupling. In some cases, when the ventral and lateral aspects of the animal are covered with very thick scales or scutes that partially or completely block ultrasound waves (e.g., *Tiliqua* spp., *Corucia zebrata*), coupling gel may be applied and left for 15 to 30 minutes so that the scales absorb some of the gel for better imaging. The primary use of ultrasonography in reptiles is probably for the assessment of the reproductive tract and reproductive status. This was done in a wide variety of terrestrial, marine, and fresh-water reptilian species. Sex determination in sub-adult or monomorphic reptiles has also been done with the use of ultrasonography. Ultrasonography has also proven useful for medical diagnosis, as well as for ultrasound-guided transcutaneous biopsy. Ultrasonography is very useful for anatomic, morphologic and nutritional studies in reptiles (Hildebrant and Saragusty, 2016).

2.1.3 ULTRASONOGRAPHIC CHARACTERS ABDOMINAL ORGANS

2.1.3.1 Ultrasonography of Liver

Ghosh (1995) observed that the hepatic echotexture was coarser than the splenic parenchyma due to the presence of number of small lobules separated by the connective tissue and small anechoic interruptions were due to the minute venous blood found in the hepatic and portal veins.

Nyland and Mattoon (2002) found that identifying the liver lobes was impossible in dogs under normal situations.

Guimaraes *et al.* (2013) reported that the echotexture and echogenicity of the liver parenchyma of maned wolves were similar to those of the dogs. The hepatic echotexture was somewhat coarse than the splenic parenchyma and the liver parenchymal echogenicity was similar to that of the right renal cortex.

Mauragis and Berry (2016) found the liver in dogs composed of four lobes, four sublobes and two processes namely, right lobe including the lateral and medial sublobes, quadrate lobe, left lobe including medial and lateral sublobe and caudate lobe including the caudate and papillary process.

2.1.3.2 Ultrasonography of Gall Bladder

The unattached portion of the gall bladder is covered with serosa. Deeper to the serosa is a thin muscular coat (Schummer *et al.*, 1979)

Ghosh (1995) reported that the outer covering of the gall bladder consists of connective tissue.

Graham (2002) observed that the size of the gall bladder varied significantly. This might be due to anorexia or fasting the dog.

Evans and de Lahunta (2013) observed that the gallbladder in dogs is a pear-shaped organ that lies between the quadrate lobe of the liver medially and the right medial lobe laterally. When distended, it extends through the thickness of the liver to its diaphragmatic surface and contacts the diaphragm. Its capacity in a Beagle-sized dog is 15 ml. It is approximately 5 cm long and 1.5 cm in its greatest width in such specimens. The blind, rounded, cranial end of the gallbladder is known as the fundus, the large middle portion as the body and its slender, tapering caudodorsally directed extremity, as the neck.

2.1.3.3 Ultrasonography of Spleen

Huynh and Berry (2017) reported that the spleen in cats had a hyperechoic capsule. It is normally homogenous in echotexture.

2.1.3.4 Ultrasonography of Kidneys

The depth of the renal cortex and renal medulla in dogs were in the ratio of 2:1 (Kubodera *et al.*, 1993).

Dyce *et al.* (2010) found that each lobule consisted of a fibrous outer covering and also the presence of arcuate artery which is hyperechoic and curves over the base of the medulla in dogs.

2.1.3.5 Ultrasonography of Urinary Bladder

Graham (2002) reported that the normal bladder has a smooth, well-defined wall and the normal urine was anechoic. A full bladder is ovoid and tapers towards the neck. A nearly empty or partly filled bladder may have an irregular shape.

Huynh and Berry (2016) observed that the bladder was surrounded by a wall which had three layers: Inner- hyperechoic layer which is the submucosa, middle- hypoechoic layer which is the smooth muscles and outer- hyperechoic layer which is the serosal layer.

2.2 PHYSIOLOGICAL PARAMETERS IN SLOTH BEARS

Veeraselvam *et al.* (2014) reported that the temperature, respiration rate and the heart rate were $38.2 \pm 0.92^{\circ}\text{C}$, 16.8 ± 4.53 breaths per minute and 73.4 ± 5.59 beats per minute respectively.

2.3 SERUM BIOCHEMISTRY IN SLOTH BEARS

Bush *et al.* (1980) studied 19 bears representing five species and recorded the serum biochemistry values of sloth bears. The average values for BUN (mg/dl) and AST (IU/l) were 18.3 ± 4.0 and 145.7 ± 1.5 respectively.

Ramsay (1999) reported the normal serum biochemistry values in sloth bears for BUN (mg/dl), Creatinine (mg/dl), AST (IU/l) and ALT (IU/l) to be as 17 ± 6 , 1.8 ± 0.6 , 106 ± 32 and 35 ± 9 respectively.

Veeraselvam *et al.* (2014) reported that the average serum biochemical values in sloth bears for BUN (mg/dl), Creatinine (mg/dl), AST (IU/l) and ALT (IU/l) were 19.08 ± 0.55 , 1.24 ± 0.09 , 137.74 ± 3.11 and 103.56 ± 1.90 respectively.

Fowler and Miller (2015) published a range of the reference values of serum biochemical parameters in sloth bears. The range for BUN (mg/dl), Creatinine (mg/dl), AST (IU/l) and ALT (IU/l) were 8-34, 0.8-3, 43-151 and 11-43 respectively.

Materials and Methods



3. MATERIALS AND METHODS

The present work was carried out to study the normal echotexture and normal sonographic anatomy of different abdominal organs using ultrasonography in sloth bears. The materials used and methods followed in the present study are discussed in this chapter.

3.1 Materials

3.1.1 Animals for the study

This study was carried out utilizing the Sloth bears at Bear Rescue Centre, Bannerghatta Biological Park, Bangalore.

3.1.2 Restraint

3.1.2.1 Chemical Restraint

Xylazine- Anased® 50ml- 100mg/ml

Ketamine HCl- Vetalar® 10ml- 100mg/ml

3.1.2 Blood sample collection

18G needles

10 ml syringe

Sterile vacutainers

3.1.3 Instruments

3.1.3.1 Ultrasonography

Logiq Book XP ultrasound machine, General Electricals (Plate 1).

Linear probe of 4-8 MHz

3.1.3.2 Biochemical Analysis

ERBA Biochemical kits

Analyzer

3.2 Methods

3.2.1 Restraint

3.2.1.1 Physical Restraint

The animal was confined in a den to restrict its movement and food and water was withheld for 12 hours.

3.2.1.2 Chemical Restraint

Chemical restraining was performed to completely immobilise the animal to perform the procedure. A combination of Xylazine at the rate of 2 mg/kg BW and Ketamine at the rate of 5 mg/kg BW was injected using a blowpipe (Plate 2). Further, maintained with Ketamine and Diazepam (Plate 3).

3.2.2 Blood Collection

3.2.2.1 Preparation of blood collection site and collection procedure

Blood samples were collected from the jugular vein. The animal was placed on its dorsal aspect. The area around the jugular was shaved using a blade.

Using an 18 G needle, blood was collected into vacutainers with clot activators.

3.2.2.2 Evaluation

Biochemical parameters viz. aspartate aminotransferase (AST), alanine aminotransferase (ALT), blood urea nitrogen (BUN) and Creatinine were estimated for each sample with the help of ERBA biochemical kits.

3.2.3 Diagnostic Imaging

Animal was placed on dorsal recumbency on the ultrasound table. Scanning area was prepared by clipping the hair from the last intercostal space caudally till the groin region.

Abdominal ultrasound was performed in dorsal recumbency. The animal was positioned in such a way that cranial position of image was oriented towards viewers left on saggital scan and right side of the animal towards viewers left on transverse scan.

Acoustic coupling gel was applied on the desired position. Liberal amount of gel provided sufficient contact for best image possible. Depending on the size of the animal, the frequency of the transducer was set between 4-8 MHz for adequate penetration.

3.2.3.1 Liver

The animal was positioned on dorsal recumbency and the probe was placed just caudal to the xiphoid process.

The examination was performed with the transducer in long-axis plane and it was angled cranially to view the midsection of the liver.

3.2.3.2 Gall bladder

The gall bladder was located to the right of the midline.

The volume of the bile in the gall bladder was observed.

3.2.3.3 Spleen

The probe was placed at the xiphoid cartilage and moved towards the left along the last rib.

The head of the spleen was identified and further when the probe was moved laterally to visualize the body of the spleen.

3.2.3.4 Kidneys

Left kidney: From the level of the spleen, the transducer was moved medially and slightly caudally to identify the left kidney.

Right kidney: With the transducer the caudal vena cava along the right side of the abdomen was traced along the long axis caudal to the liver to the level of the right kidney.

3.2.3.5 Urinary bladder

The transducer was positioned in long axis to the animal and it was moved caudally on the mid line.

The wall of the urinary bladder was evaluated for its thickness

Urinary bladder was evaluated for presence of any particles.

The size, shape and echogenicity of the gall bladder, liver, spleen, urinary bladder and kidneys was examined and the images stored in the form of .jpeg.

3.3 POST MORTEM IN SLOTH BEARS

Topographical anatomy was studied from post mortem specimens from bear rescue centre authorities.

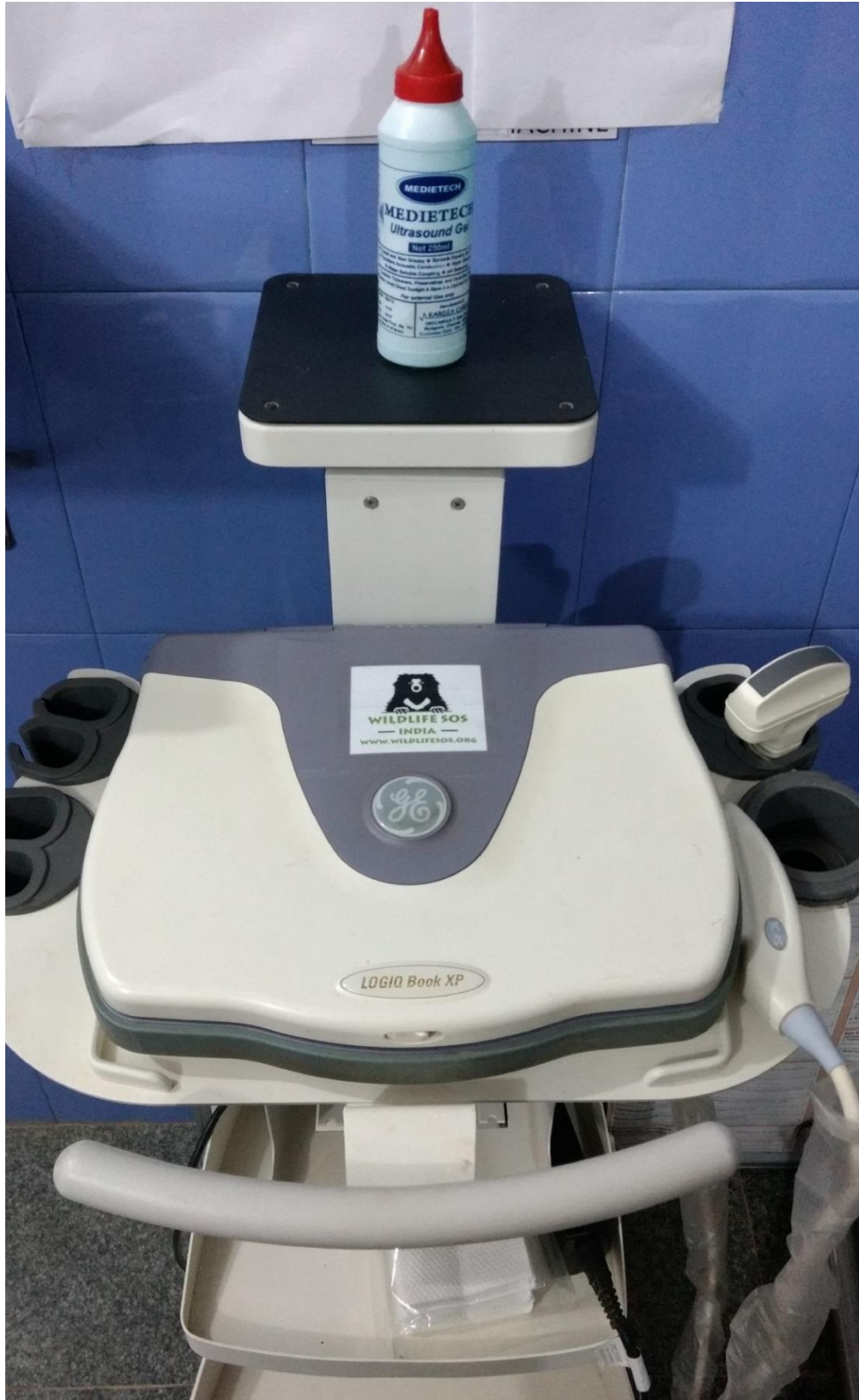

Plate 1: Logiq XP Ultrasound Machine used for ultrasonography in sloth bears with the gel




Plate 2: Blowpipe used for administration of the chemical restraint

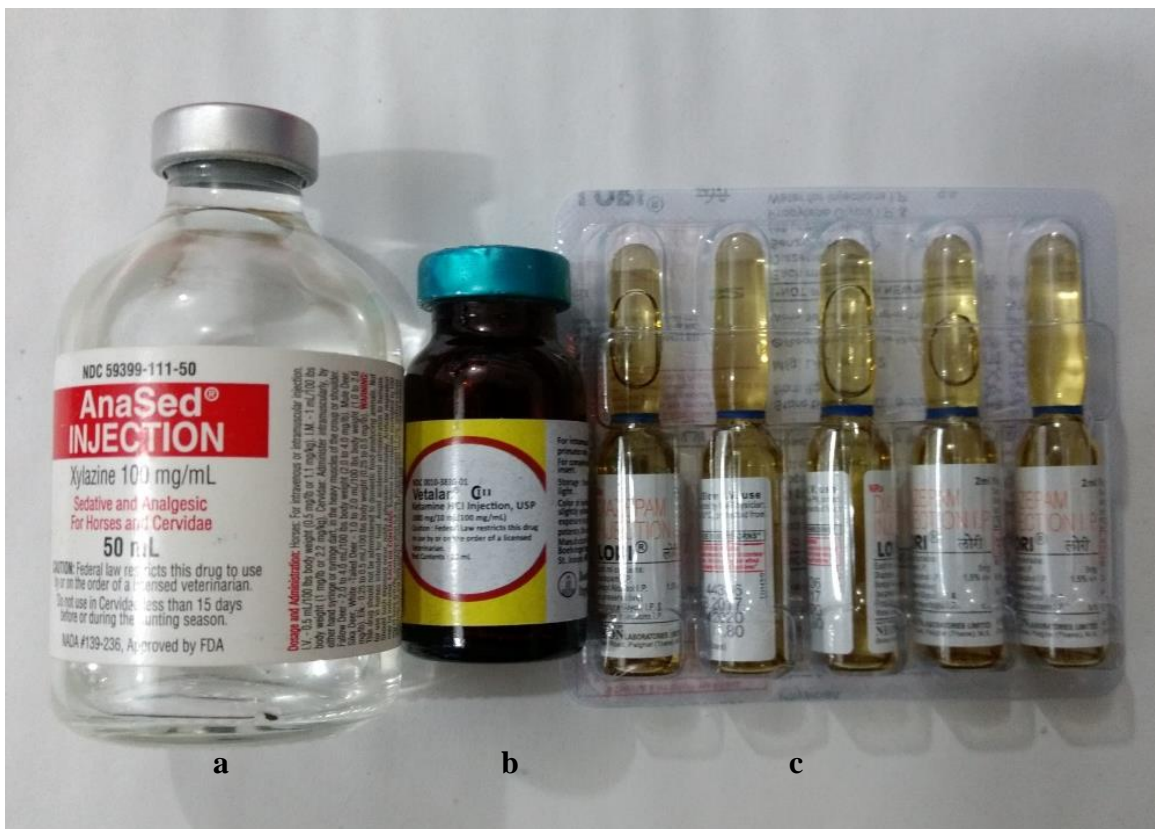

Plate 3: The drugs used for chemical restraints:

a) Anased® b) Vetalar® and c) Lori®

Results



4. RESULTS

The results of the ultrasonographic study of different abdominal organs of sloth bears are presented in this chapter. As the bears need to be restrained for ultrasound examination, chemical restraint using ketamine and xylazine at the dose rate of 5mg/kg BW and 2 mg/kg BW respectively, was found to be optimum for immobilization of sloth bears. Blowpipe helped to easily inject the drugs. The animal was well maintained with ketamine and diazepam.

The dorsal recumbency was found to be better than lateral recumbency for visualization of visceral abdominal organs. Application of acoustic coupling gel helped in getting the best images. The frequency of transducers between 4-8 MHz was found adequate for visualization of various abdominal organs.

4.1 ULTRASOUND SCANNING OF ABDOMINAL ORGANS

The ventro-dorsal recumbency was used for ultrasonography of the liver, gall bladder, spleen, kidneys and the urinary bladder.

4.1.1 Liver

The dorsal recumbency, with placing the transducer caudal towards the right side of the xiphoid process, helped to scan the liver. The ultrasound image of liver was obtained by placing transducer in the long axis plane and angle cranially to view mid-section.

In bears, cranial lobe of the liver was located within the ribcage, cranial to the stomach with cranial margins against the diaphragm (Plate 4 and Plate 5). The diaphragm appeared as a curved hyperechoic line (Plate 10 and Plate 11). Caudally liver was in contact with spleen to the left, centrally stomach and kidney to the right (Plate 6 and Plate 7). Although the liver was divided into five lobes namely, right lobe including lateral and medial sublobes, quadrate lobe, left lobe including lateral and medial sublobes and caudate lobe including the caudate and the papillary processes, the lobes were not well distinguished in ultrasound except for caudate lobe (Plate 12 and Plate 13).

The normal hepatic parenchyma was uniform with fine or coarse granular echogenicity compared to spleen with interruptions seen at the hepatic and portal vein.

4.1.2 Gall bladder

It was round, oval or pear shaped, elongated structure located between the lobes (Plate 9). The size varied significantly based on the size of the animal. The wall was thin, smooth and hyperechoic with variable amount of sludge inside the bladder (Plate 8).

The diameter of the gall bladder was found to be 2.42 ± 0.09 cm (Table 1).

4.1.3 Spleen

Spleen was found to be an elongated sock like structure spreading from cranial abdomen to caudal abdomen towards the left side, aligned in dorso-cranial to ventro-caudal plane. The spleen was divided into head, body and tail. The head of the spleen was placed between the 13th and 14th ribs (Plate 16 and Plate 17). And it continued as the

body and turned at the tail (Plate 18 and Plate 19). The spleen ends close to the urinary bladder.

The spleen was surrounded by a capsule which was found to be hyperechoic on keeping the transducer exactly perpendicular to the capsule (Plate 14 and Plate 15).

The splenic parenchyma was fine, granular and relatively homogenous when compared to the liver. Also the spleen was hyperechoic compared to the liver.

The width of the spleen was found to be 3.03 ± 0.09 cm (Table 1).

4.1.4 Kidney

Kidneys were paired, elongated, lobulated structures. The left kidney was found in the left lateral abdomen, caudal to the tail of the spleen. Mild pressure had to be applied with 4 MHz of frequency. The kidney was found to be lobulated. Each lobule was surrounded by a capsule which was found to be hyperechoic (Plate 20 and Plate 21).

The right kidney was found in the right lateral abdomen and was nested in the caudate lobe of the liver, more caudal in relation to the left kidney. Echogenicity was found to be the same as the left kidney (Plate 22 and Plate 23).

Each lobule consisted of cortex which had very fine and uniform echotexture. Medulla was an anechoic structure. The cortex and medulla were divided by a hyperechoic line. The depth of the renal cortex and renal medulla were in the ratio of 2:1.

The renal pelvis and ureter were found to be on the medial aspect of the kidney.

The length and width of the left kidney was found to be 7.18 ± 0.09 cm and 3.92 ± 0.11 cm respectively. And the length and width of the right kidney was found to be 7.18 ± 0.15 cm and 3.7 ± 0.14 cm respectively (Table 1).

4.1.5 Urinary bladder

The normal bear urinary bladder was pear shaped with round cranial apex and tapering towards the neck of the bladder. The bladder constituted of urine which was anechoic in nature (Plate 24).

When urinary bladder was full, it was found to be in caudo-ventral abdomen and when empty found in the pelvic cavity.

The bladder wall had three layers

1. Inner- hyperechoic layer which is the submucosa
2. Middle- hypoechoic layer which is the smooth muscles
3. Outer- hyperechoic layer which is the serosal layer.

The thickness of the urinary bladder was found to be 0.35 ± 0.015 cm (Table 1).

4.2 ANATOMICAL FEATURES

As there was no previous reports on topographic anatomy and ultrasound study in sloth bears, post mortem findings were recorded and this work was utilized for ultrasound study of various abdominal organs. The gross anatomical features of vital organs of the sloth bears are as follows.

Right side of abdomen	Left side of abdomen
Liver and Gall Bladder	Spleen
Right kidney	Left Kidney
Urinary Bladder	

4.2.1 Liver

Liver was located on the right side of the abdomen and the cranial portion covered by the 13th and 14th ribs. The diaphragmatic surface of the liver was strongly convex in all directions, as it lies mainly in contact with the diaphragm. The visceral surface of the liver was irregularly concave and faces mainly caudoventrally and to the left. It lies in contact with the stomach, duodenum, pancreas and right kidney (Plate 25).

The gastric impression occupied the whole left half of the visceral surface. When the stomach is moderately full it resides in this impression. The renal impression was a deep, nearly hemispheric fossa formed by the cranial pole of the right kidney projecting into the most caudodorsal portion of the liver, the caudate process of the caudate lobe.

4.2.2 Gall bladder

Gall bladder was a pear shaped, elongated, greenish structure located between the lobes of the liver (Plate 26).

4.2.3 Spleen

Spleen was an elongated sock like structure extending from cranial abdomen to caudal abdomen towards the left side (Plate 27).

4.2.4 Kidney

Left kidney was located on the left side of the abdomen just caudal to the spleen. It was lobulated and covered by a layer of the capsule (Plate 28).

Right kidney was located on the right side of the abdomen caudal to the spleen. The right kidney forms an impression on the liver. It was lobulated and covered by a layer of the capsule.

4.2.5 Urinary bladder

The urinary bladder was located cranial to the pelvic region. It was pear shaped and constituted of urine.

4.3 PHYSIOLOGICAL PARAMETERS

The various physiological parameters recorded before starting the ultrasound procedure were, rectal temperature was found to be $97.7 \pm 0.26^{\circ}\text{F}$ and respiration rate was found to be 15.5 ± 1.54 breaths per minute. Further, the heart rate was 52.3 ± 2.12 beats per minute and the pulse was 56.67 ± 2.66 beats per minute (Table 2).

4.4 SERUM BIOCHEMISTRY

The mean with standard error value of aspartate aminotransferase was found to be 90.72 ± 2.56 IU/L. Similarly, the alanine aminotransferase was found to be 25.39 ± 2.33 IU/L. Further, the blood urea nitrogen was found to be 15.17 ± 0.72 mg/dl and the creatinine was found to be 1.47 ± 0.06 mg/dl (Table 3).

Table 1: Mean and standard error of measurements of different organs

Organs	Number of animals (n)	Range	Mean \pm standard error
Gall Bladder (Diameter)	18	1.2- 2.99 cm	2.42 \pm 0.09 cm
Spleen (Width)	18	2.24- 3.61 cm	3.03 \pm 0.09 cm
Urinary Bladder (Thickness)	18	0.23- 0.46 cm	0.35 \pm 0.015 cm
Left Kidney (Width)	11	3.32- 4.57 cm	3.92 \pm 0.11 cm
Left Kidney (Length)	11	6.69- 7.66 cm	7.18 \pm 0.09 cm
Right Kidney (Width)	11	2.68- 4.45 cm	3.7 \pm 0.14 cm
Right Kidney (Length)	11	6.51- 7.83 cm	7.18 \pm 0.15 cm

Table 2: Mean and standard error of physiological parameters

Physiological parameters	Number of animals (n)	Range	Mean \pm standard error
Temperature ($^{\circ}$ F)	18	95-99	97.7 \pm 0.26
Respiration Rate (breaths per minute)	18	6-36	15.5 \pm 1.54
Heart rate (beats per minute)	18	42-81	52.3 \pm 2.12
Pulse (beats per minute)	18	45-89	56.67 \pm 2.66

Table 3: Mean and standard error of serum biochemistry

Biochemical parameters	Number of animals (n)	Range	Mean \pm standard error
AST (IU/L)	18	73-109	90.72 \pm 2.56
ALT (IU/L)	18	12-51	25.39 \pm 2.33
BUN (mg/dl)	18	10-21	15.17 \pm 0.72
Creatinine (mg/dl)	18	1.19-1.94	1.47 \pm 0.06

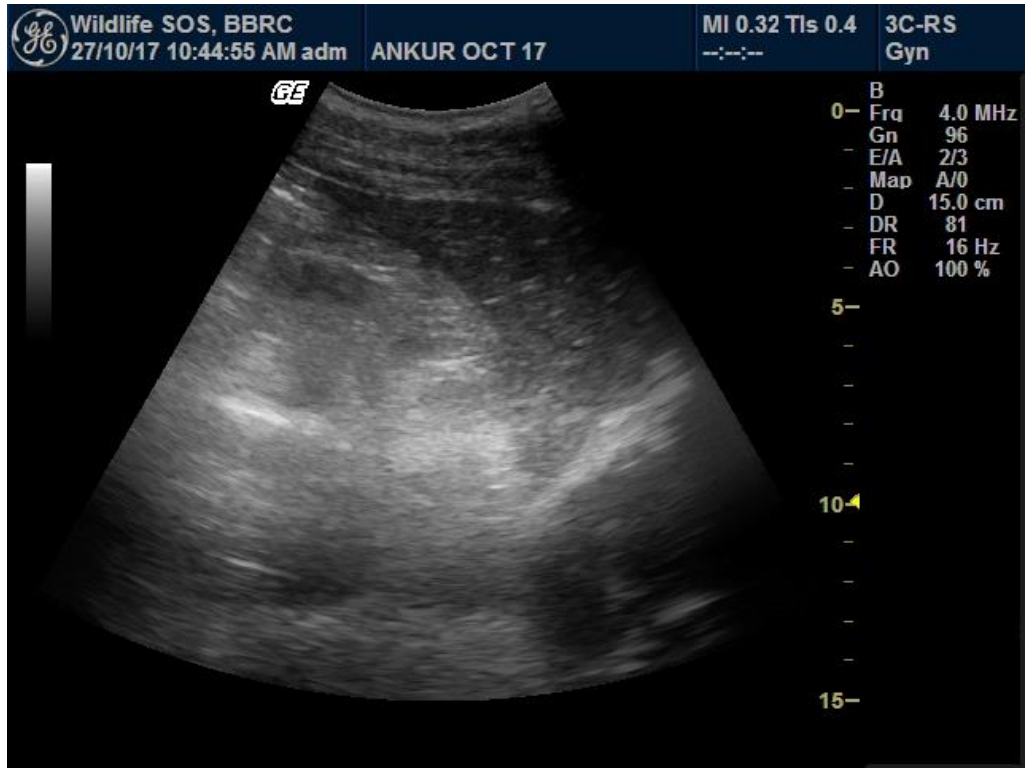


Plate 4: Sagittal plane of liver

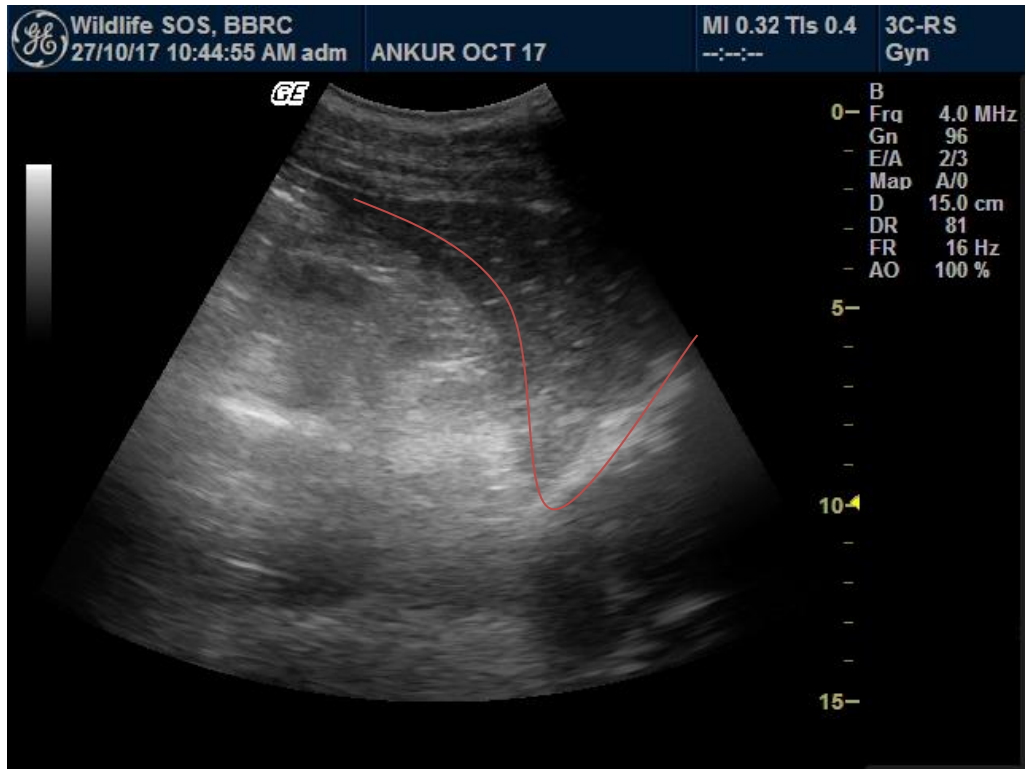


Plate 5: Markings showing the liver borders and sharp edges

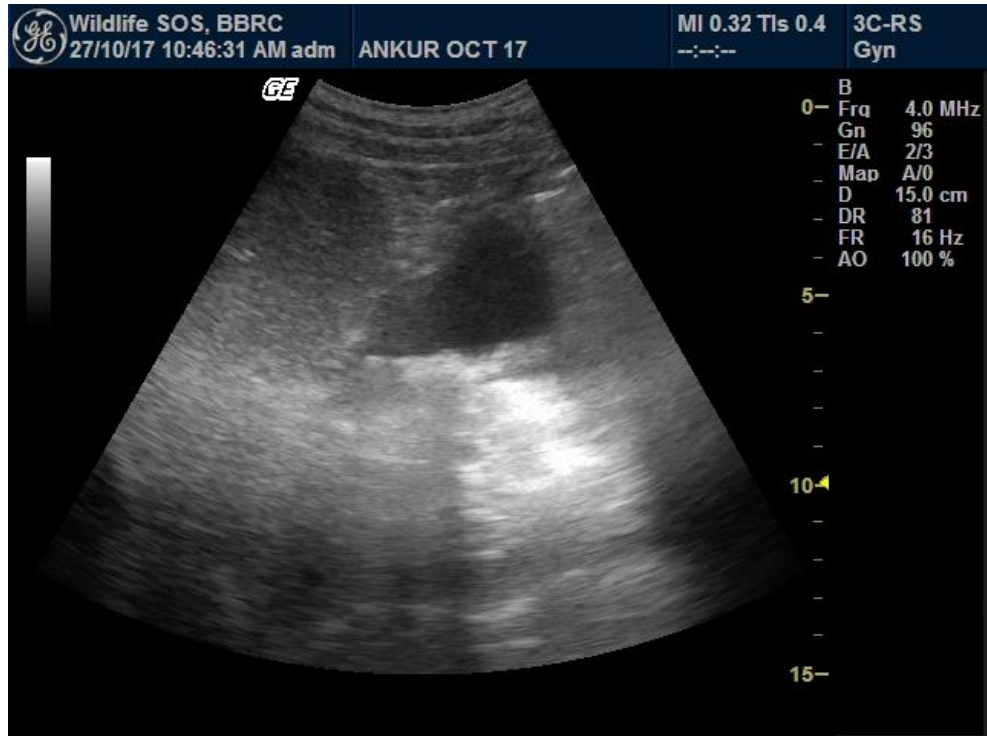


Plate 6: Sagittal acoustic window showing the topographical anatomy of liver, stomach and spleen

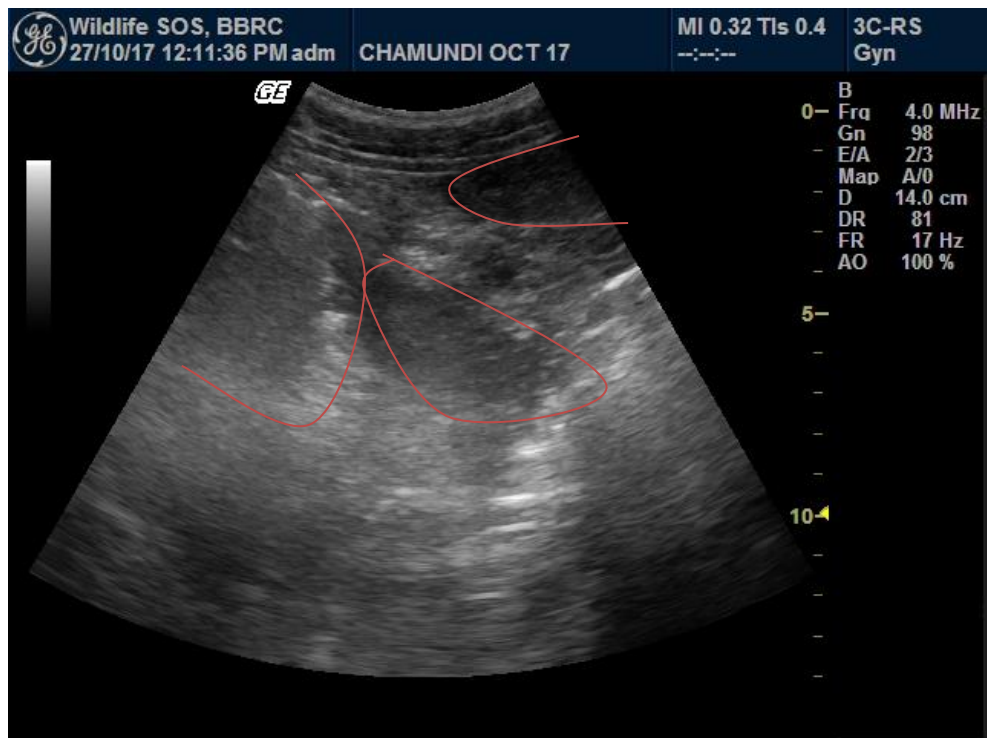


Plate 7: Markings showing liver, stomach and spleen

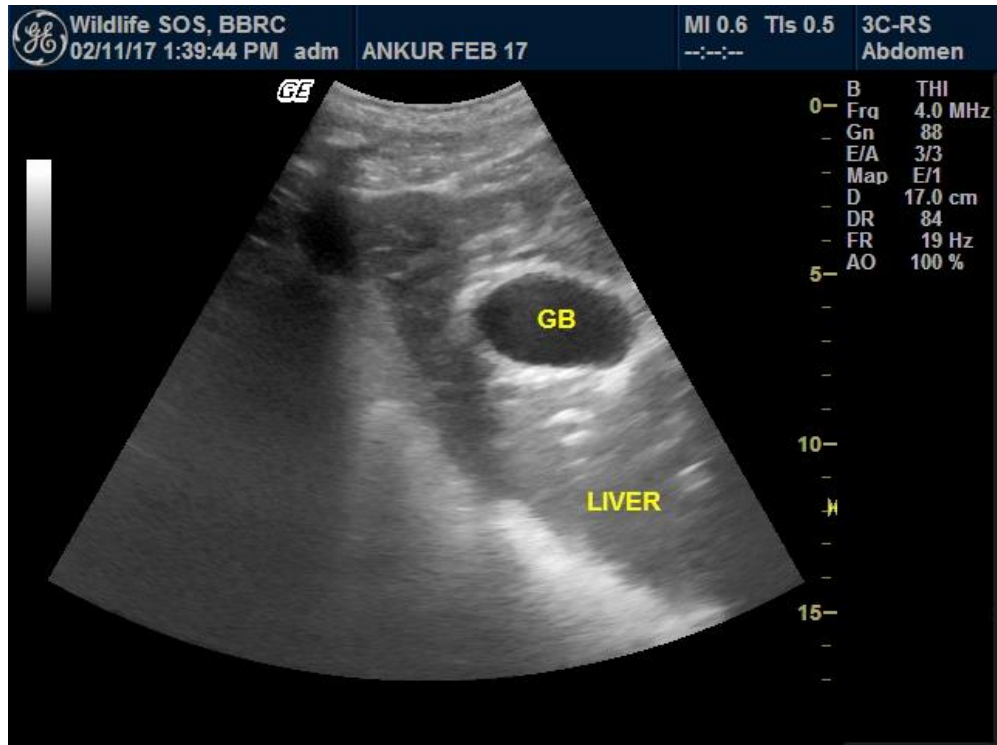


Plate 8: Sagittal section of gall bladder with liver and hyperechoic diaphragm

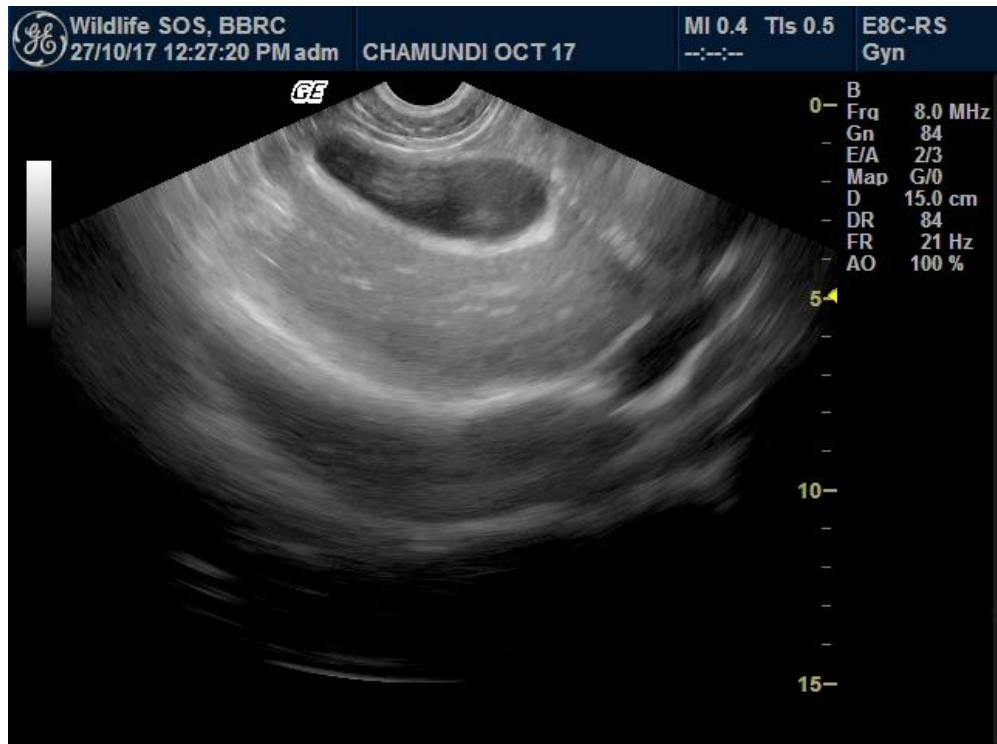

Plate 9: Longitudinal section of gall bladder with hyperechoic borders and mild echoic sludge

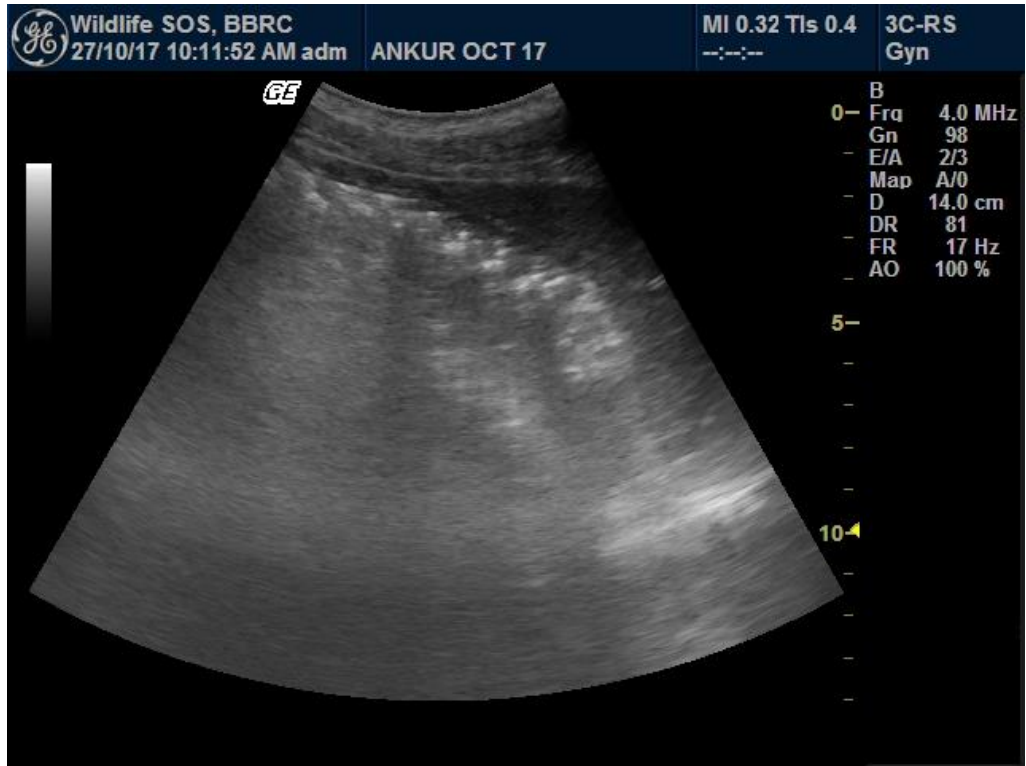


Plate 10: Sagittal acoustic window showing liver with diaphragm

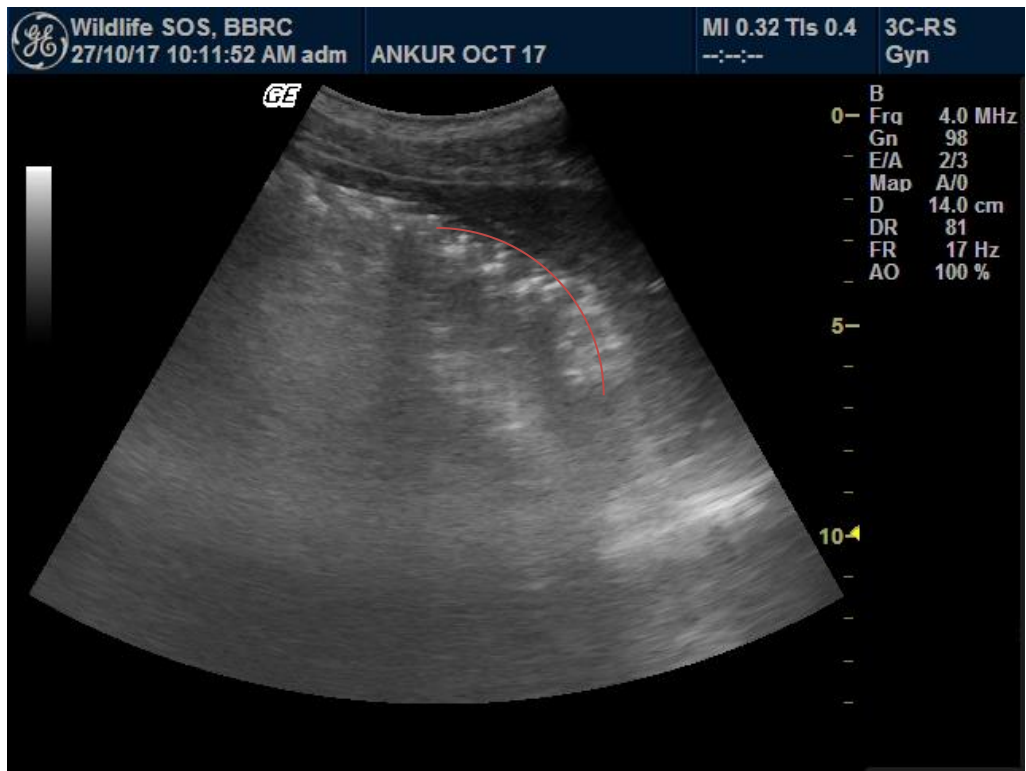


Plate 11: Markings showing the hyperechoic diaphragm with liver

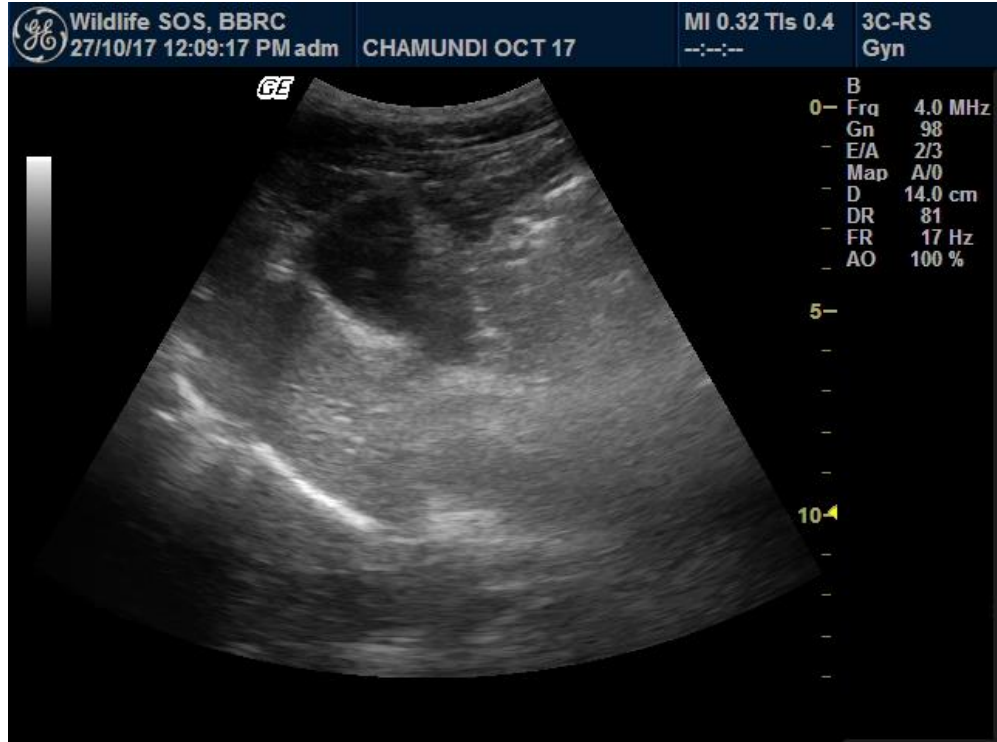


Plate 12: Liver lobes and gall bladder with sludge

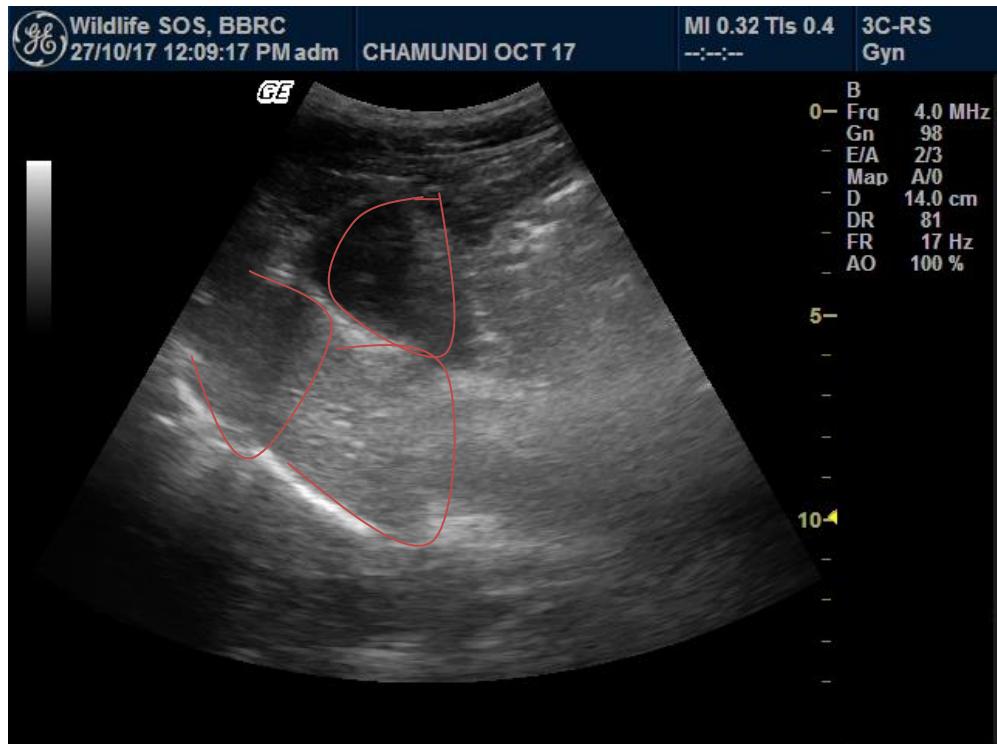


Plate 13: Markings showing the right lobe and caudate lobe of liver and gall bladder with sludge

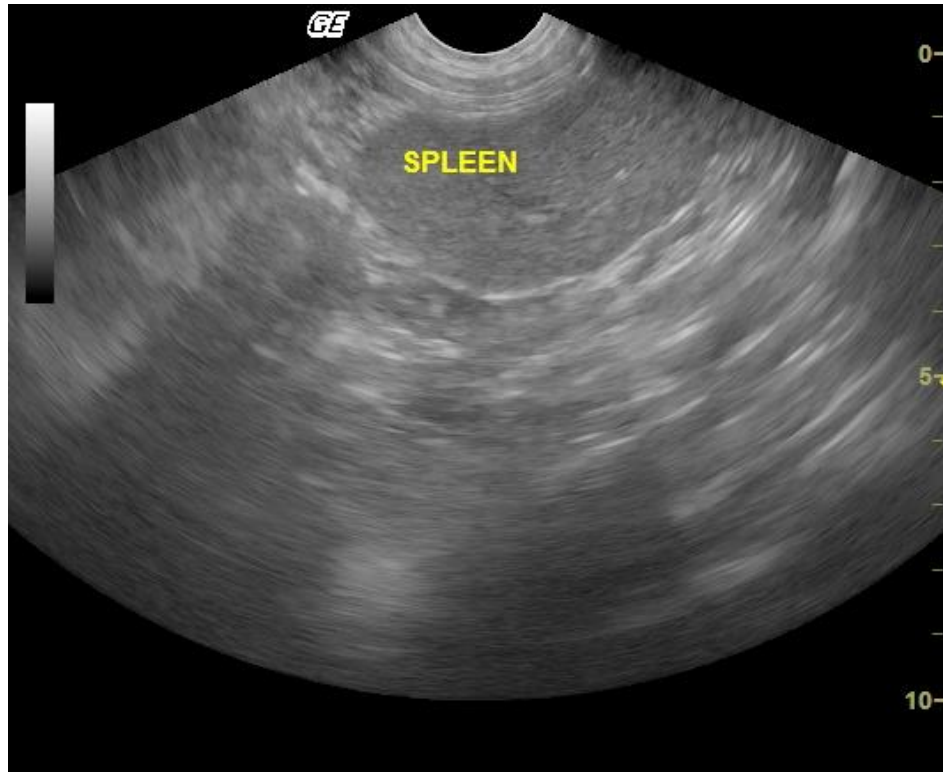

Plate 14: The capsule surrounding the spleen

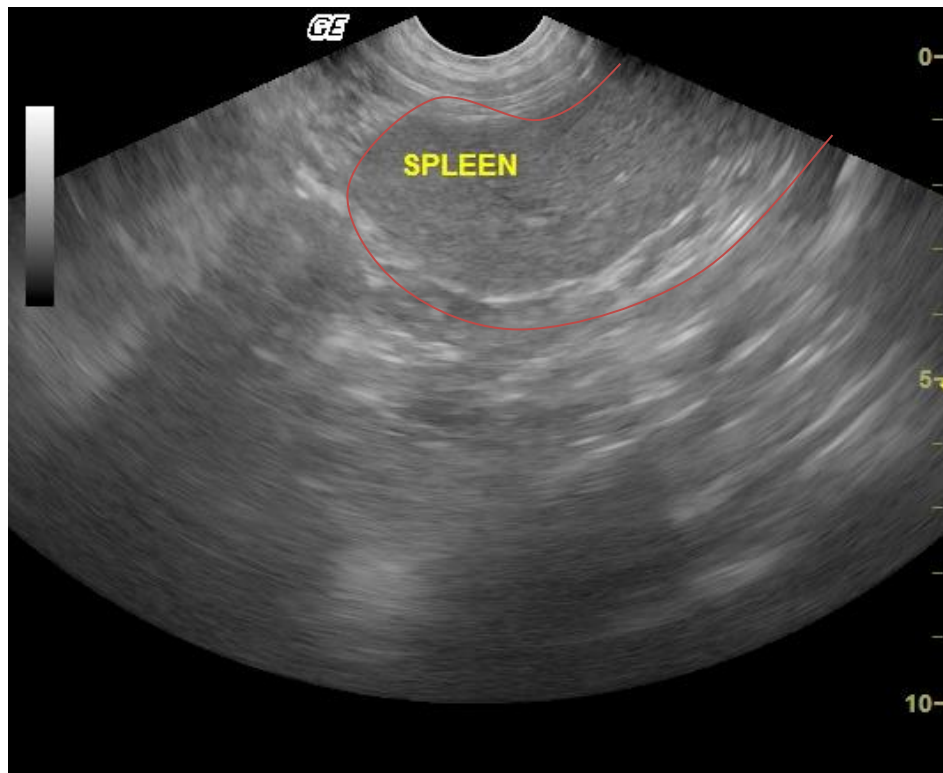


Plate 15: Marking showing the hyper echogenicity of the capsule

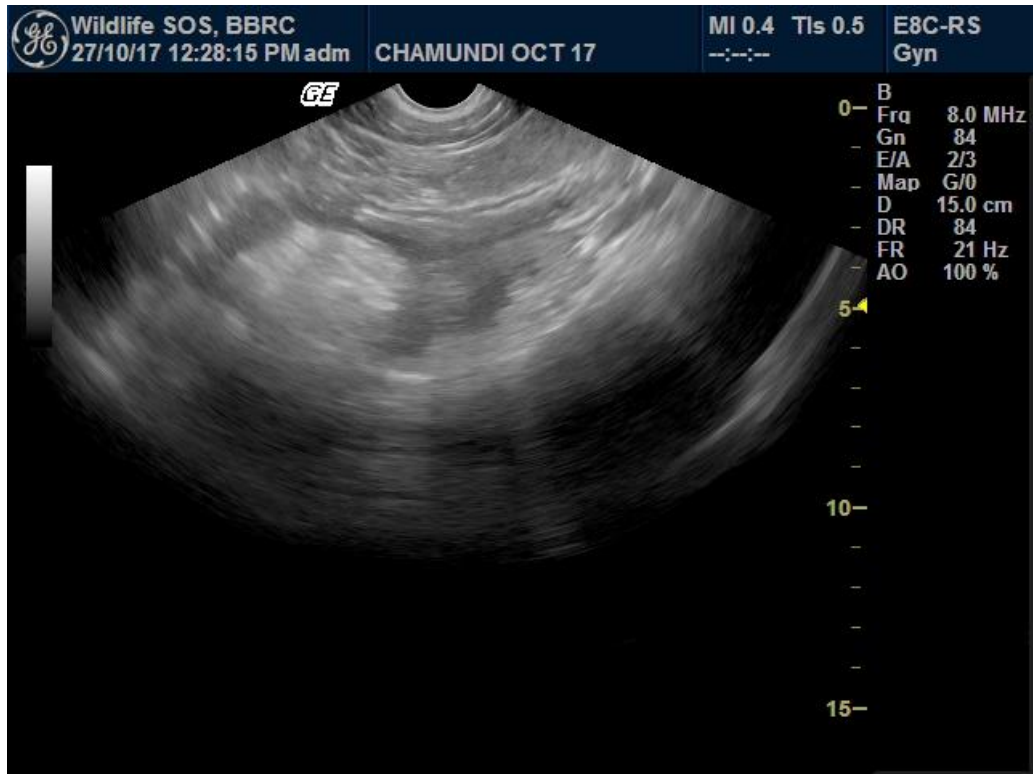


Plate 16: Head of the spleen and stomach

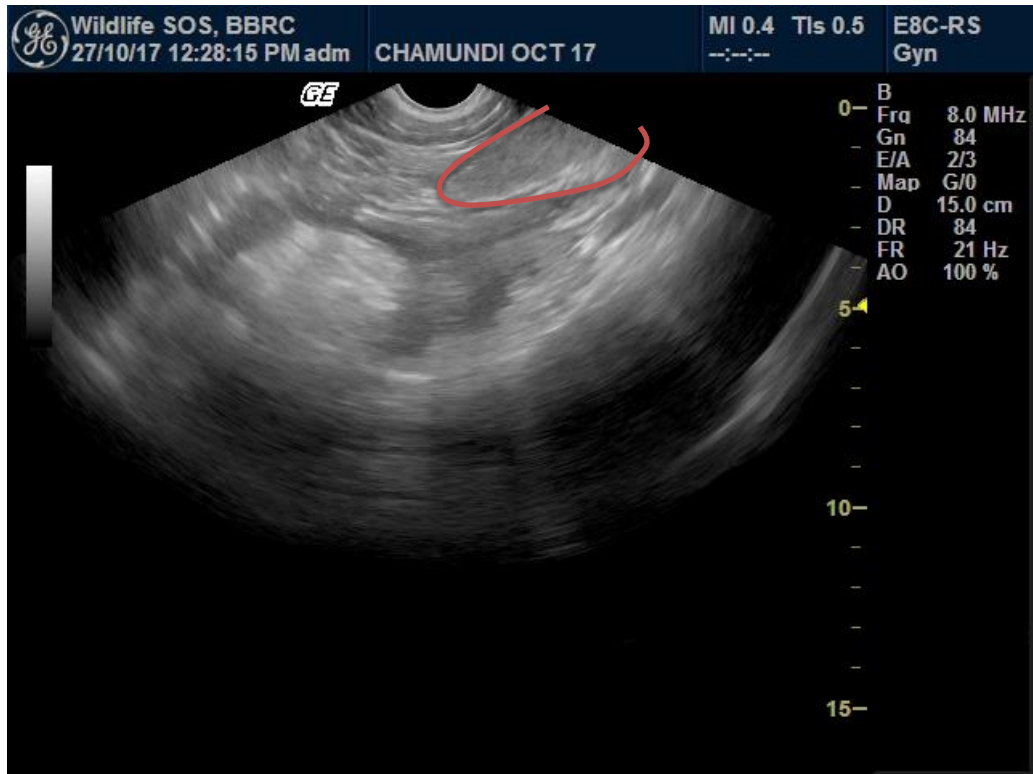


Plate 17: Marking showing the head of the spleen

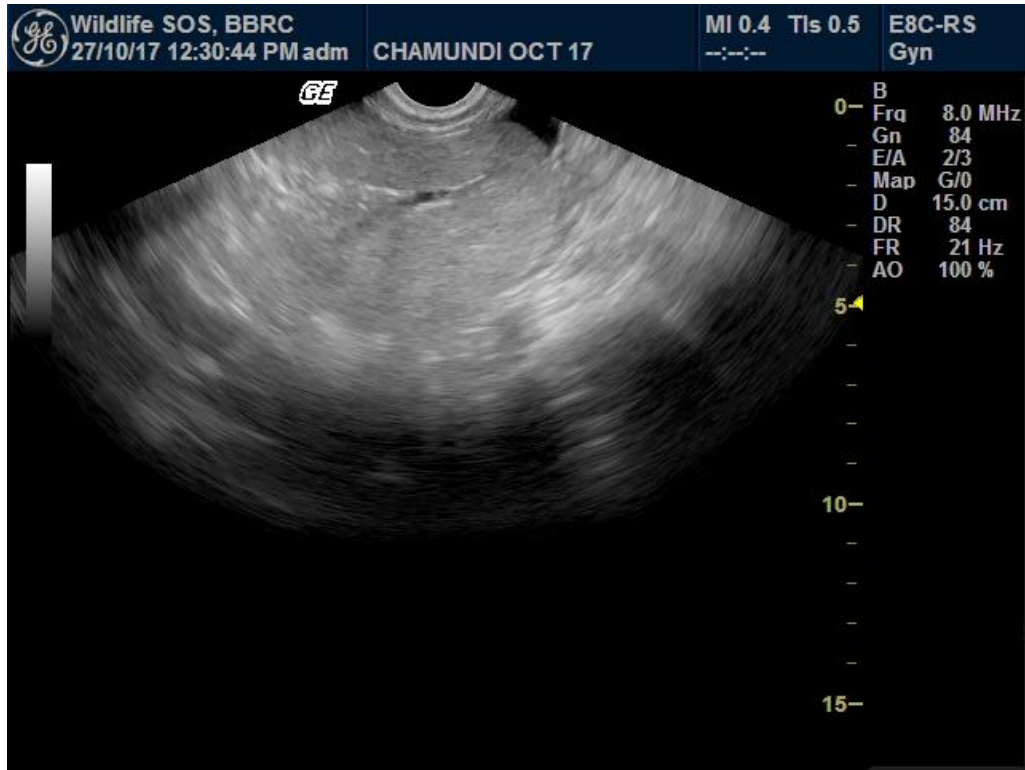


Plate 18: Sagittal section of body and tail of spleen turning at the mid abdomen

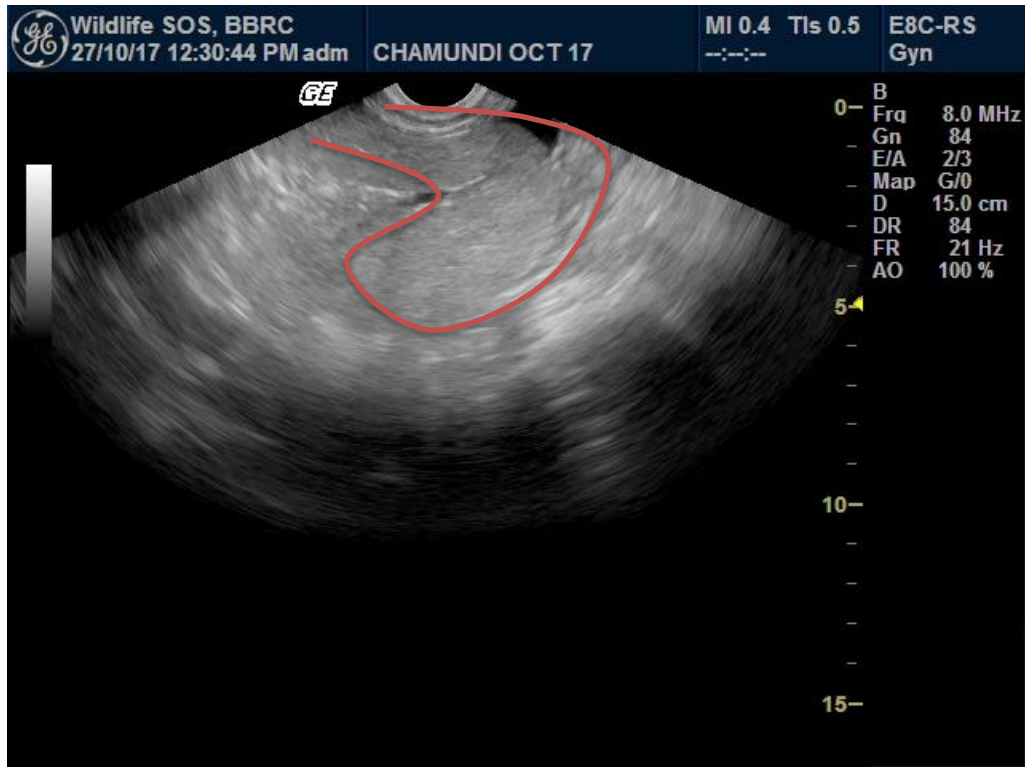


Plate 19: Marking showing the body and tail of spleen

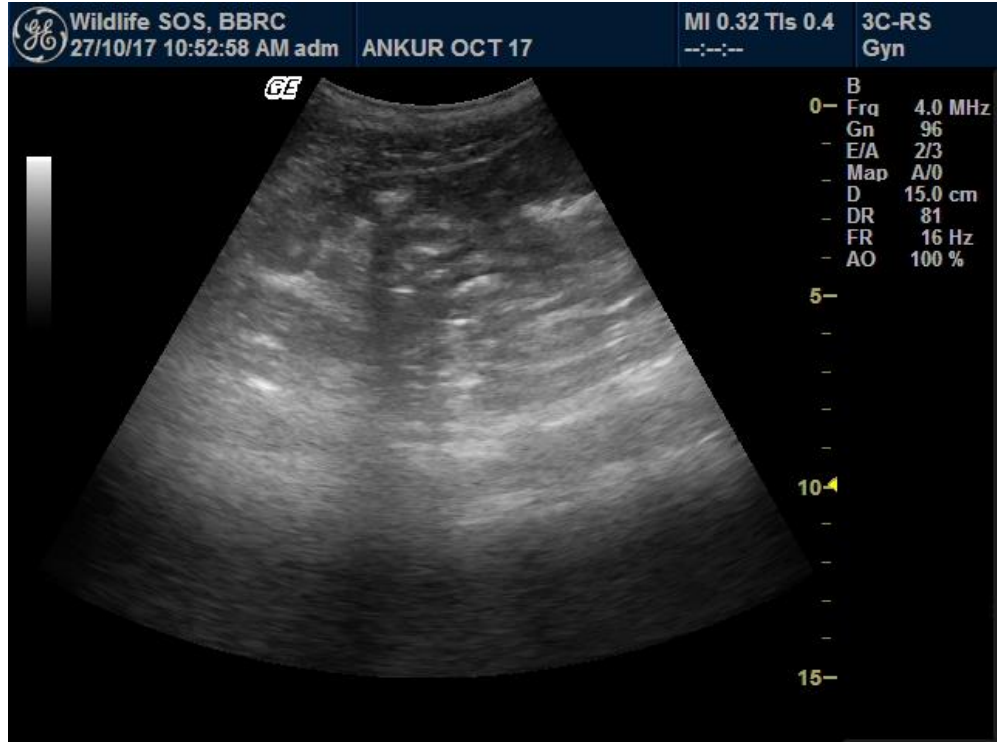


Plate 20: Lobulated left kidney

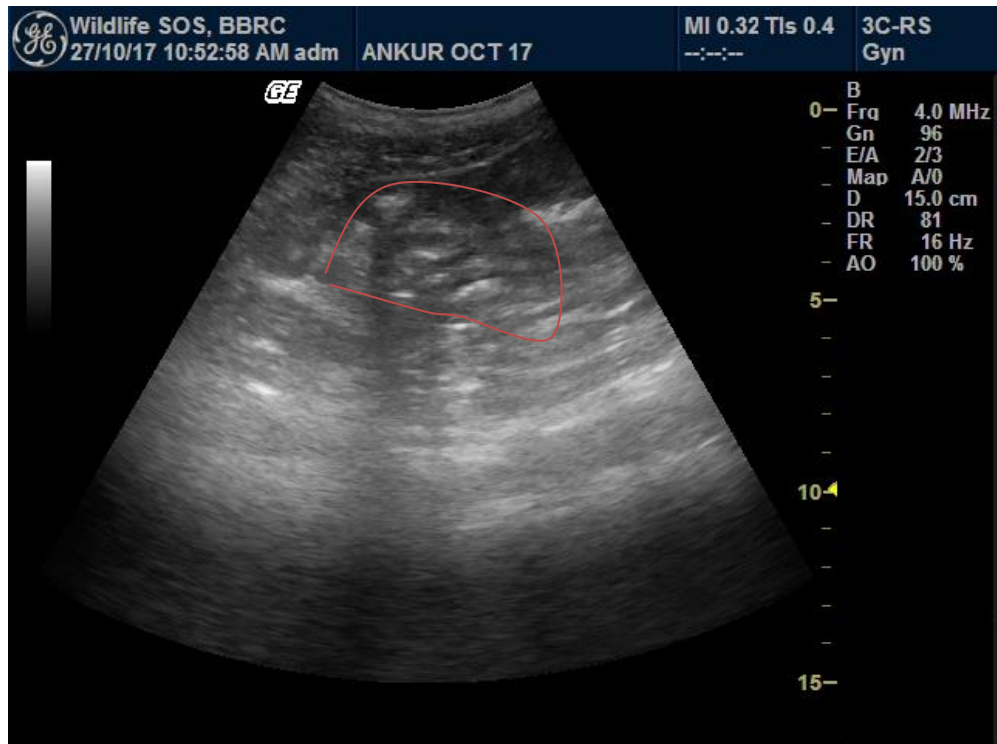


Plate 21: Marking showing the lobulated left kidney with anechoic medulla and hyperechoic cortex in 1:2 ratio

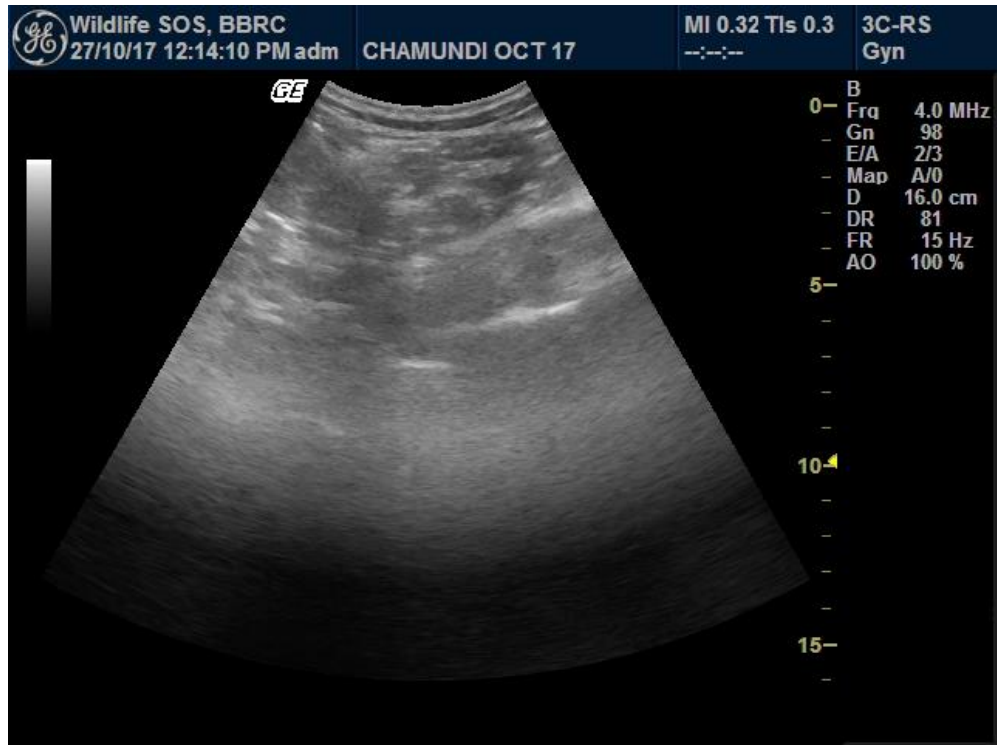


Plate 22: Lobulated right kidney

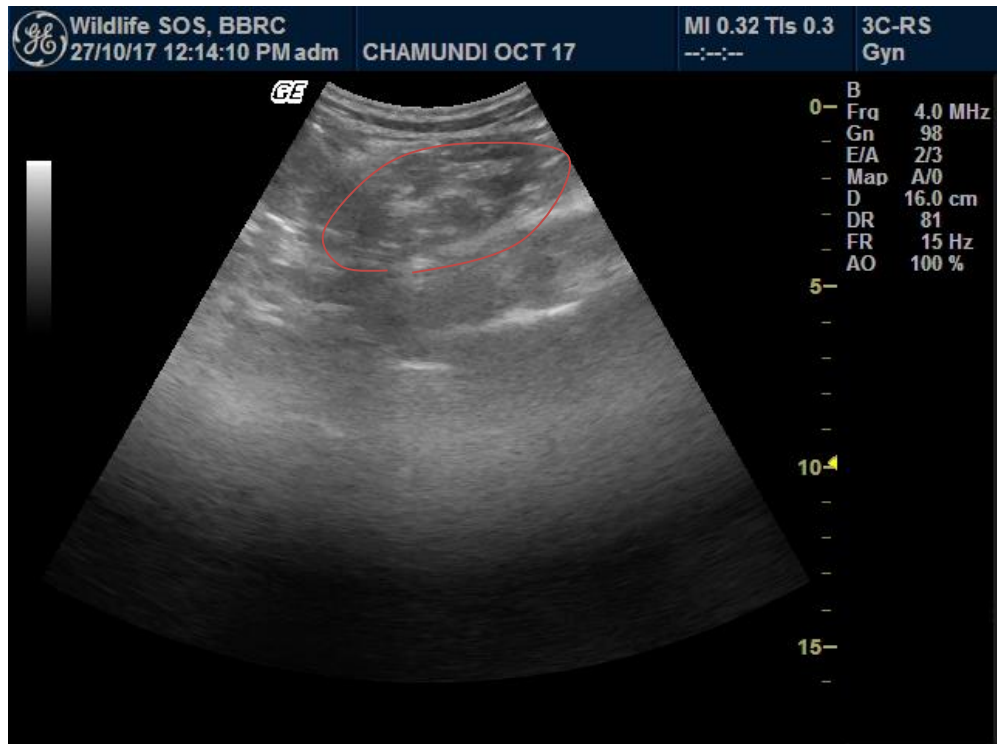


Plate 23: Marking showing the lobulated right kidney with anechoic medulla and hyperechoic cortex in 1:2 ratio

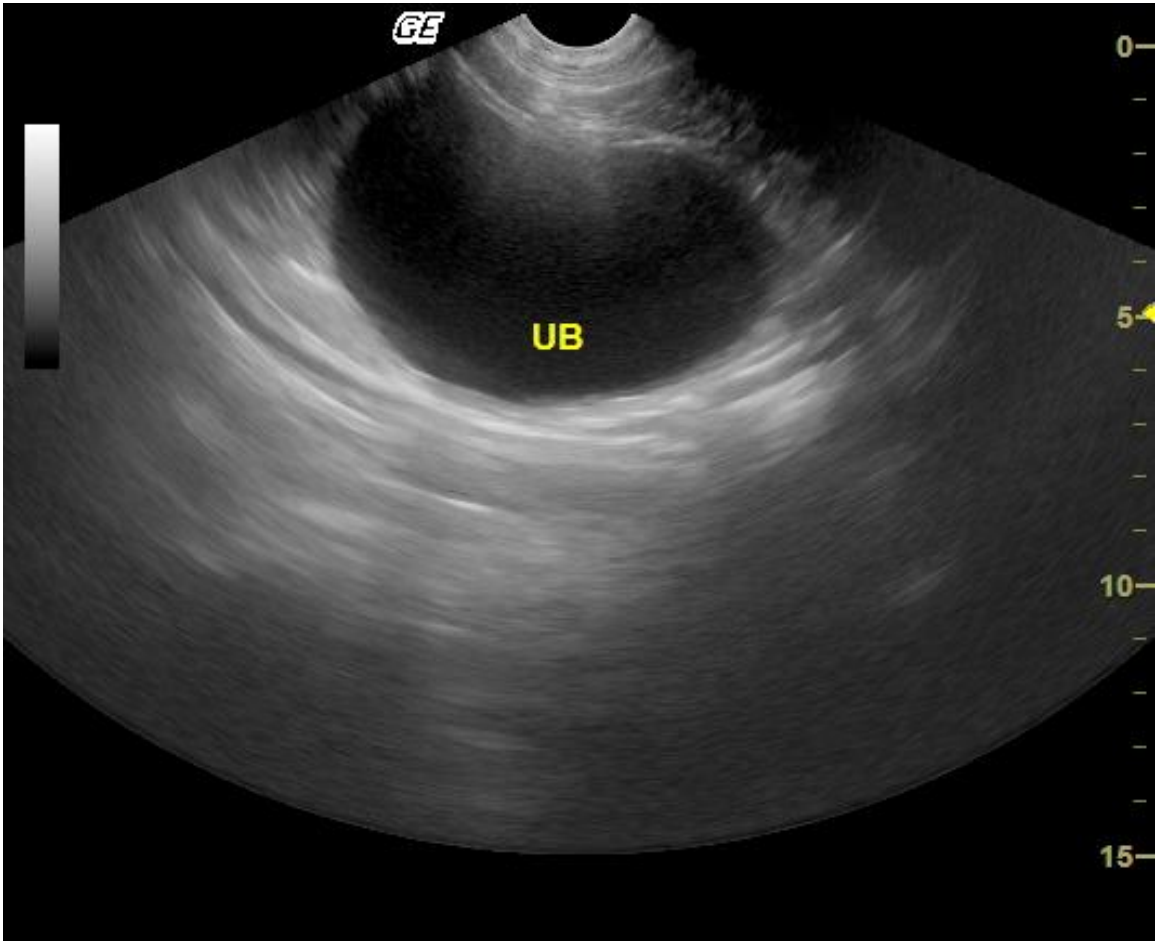


Plate 24: Hyperechoic urinary bladder wall with anechoic urine

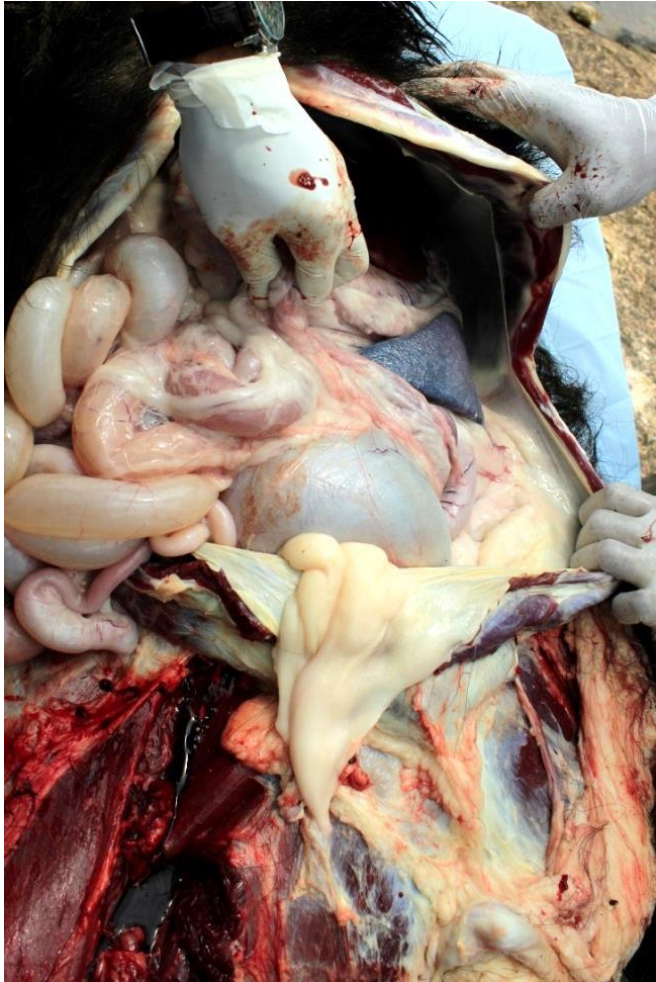


Plate 25: Post mortem picture showing the topographical anatomy of abdominal organs in sloth bears in ventro-dorsal view

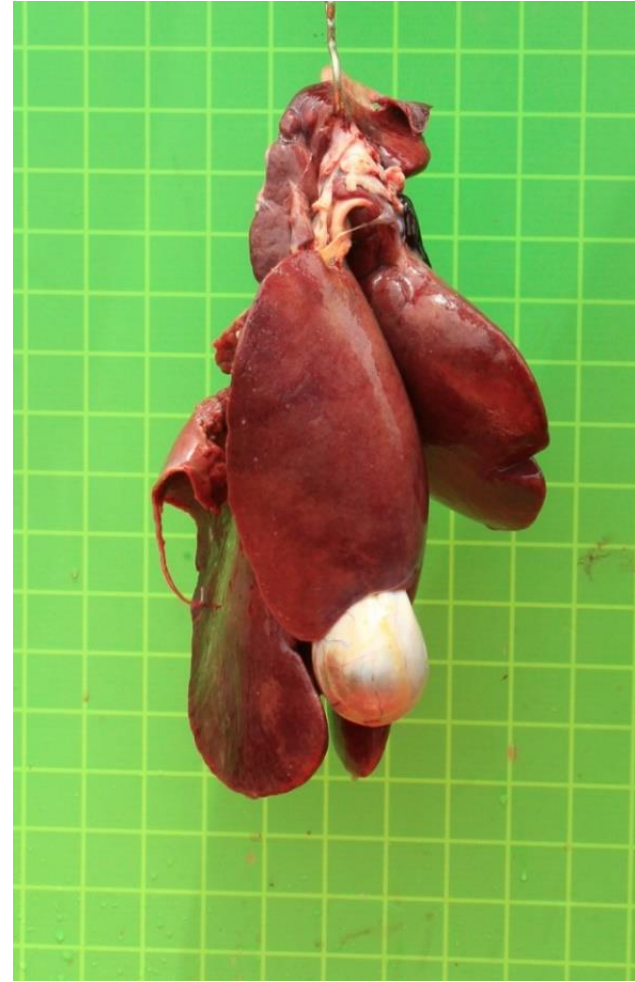


Plate 26: Lobes of liver with gall bladder

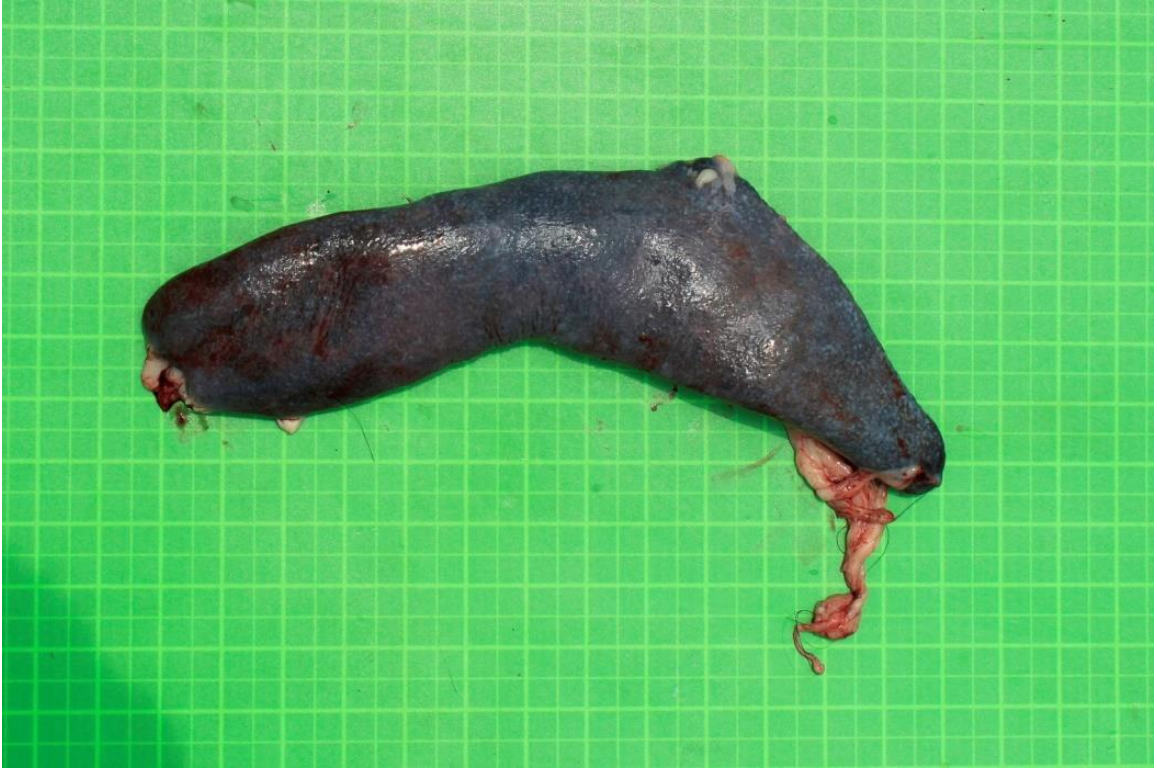

Plate 27: Gross specimen of sock shaped spleen

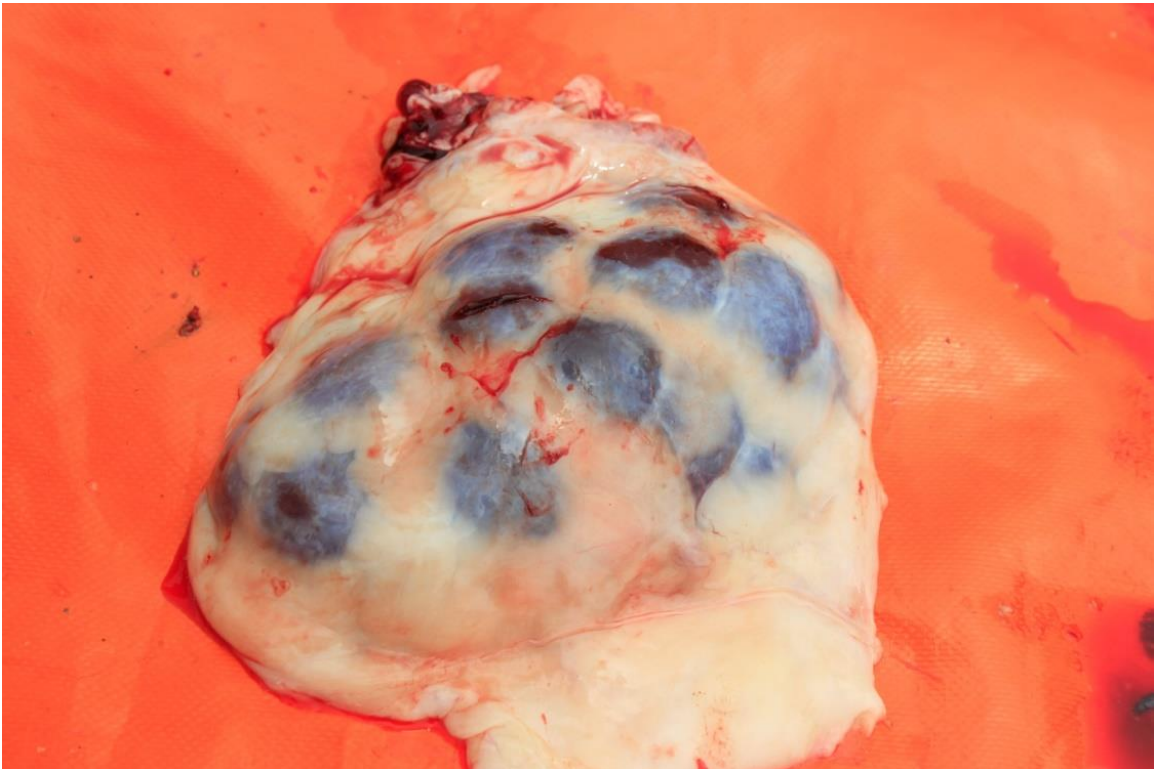


Plate 28: Gross specimen of lobulated kidney

Discussion



5. DISCUSSION

The sloth bears are seen throughout India with western ghat and central Indian landscape harboring a large population (Puri *et al.*, 2015). It is listed as vulnerable by IUCN and under Schedule-1 under the Wildlife (Protection) Act, 1972.

The Sloth bears were used by Kalandars for dancing and other entertainment purposes. In recent times, the government has banned the use of these bears. After this, the bears have been rescued and housed in various rescue centres across India.

Ultrasonography is one of the non-invasive, rapid and safe diagnostic tool which helps to determine the size, shape and echotexture of the internal organs. This is helpful in diagnosis of various disease in wild animals. However, this method has not been utilized in disease diagnosis of sloth bears. Hence, an attempt has been made to standardize the size, shape and echotexture of various abdominal organs using ultrasound in sloth bears.

The ultrasound scanning requires immobilization of the sloth bears as they do not cooperate by physical restraint. The present study utilized a combination of xylazine and ketamine at the dose rate of 2 mg/kg BW and 5 mg/kg BW respectively, for immobilization and maintained with combination of ketamine and diazepam.

The immobilization agents were found to be effective to carry out the ultrasound procedure. This was in agreement with Veeraselvam *et al.* (2014).

5.1 ULTRASONOGRAPHY- TECHNICAL CONSIDERATION

Low-frequency probes are one of the paramount pre requisites of ultrasonography in sloth bears, because of the heavy body conformation and excessive fat deposition in the body. It is important to consider the transducer requirements as most practitioners are equipped with the normal canine and feline ultrasonograph. Low frequencies (2-3.5 MHz) had good tissue penetration and were used to examine deeper abdominal organs and thoracic structure in large animals, whereas high frequency (7.5 to 12 MHz) produced good image resolution with limited tissue penetration. In this study, the frequency used to examine the abdominal organs in sloth bears was 4-6 MHz.

5.2 ULTRASOUND SCANNING OF ABDOMINAL ORGANS

5.2.1 Liver

The liver was located on the right side of the abdomen with the cranial lobe found within the ribcage with the cranial margin of the liver against the diaphragm. Caudally liver was in contact with spleen on the left, centrally stomach and kidney to the right. These findings were in agreement with topographical anatomy of the sloth bear found during post-mortem.

As per the anatomical features, the liver has four lobes i.e. right lobe including lateral and medial sublobes, quadrate lobe, left lobe including lateral and medial sublobes and caudate lobe including the caudate and the papillary processes. It was found that the lobation was similar to that of the dogs. However, in normal bears differentiation of lobes was not prominent except for caudate lobe. This finding was in agreement to the findings of Mauragis and Berry (2016) in dogs.

The hepatic echotexture was coarser than the splenic parenchyma due to the presence of number of small lobules separated by the connective tissue. Small anechoic interruptions were due to the minute venous blood found in the hepatic and portal veins (Ghosh, 1995). The echotexture and echogenicity of the liver parenchyma of the sloth bears was similar to those of the maned wolves (Guimaraes *et al.*, 2013).

5.2.2 Gall bladder

The gall bladder was found to be located between the caudate lobes of the liver. The size of the gall bladder varied significantly. This might be due to anorexia or fasting the animal as observed by Graham (2002). The diameter of the gall bladder was found to be 2.42 ± 0.09 cm. The sludge was concentrated as the bears were withheld of food for 12 hours. The outer wall was hyperechoic due to the presence of connective tissue. This was in agreement with the findings of Ghosh (1995) in dogs.

5.2.3 Spleen

Spleen was found to be an elongated sock like structure located from cranial to caudal abdomen towards the left side, aligned in dorso-cranial to ventro-caudal plane. The spleen was divided into head, body and tail. This was in agreement with the findings of Huynh and Berry (2017) in dogs. The head of the spleen started between the 13th and 14th ribs, and it continued as the body and turned its course at the tail of the spleen. The spleen ends close to the urinary bladder. These were confirmed as per the anatomical features. The width of the spleen was found to be 3.03 ± 0.09 cm.

The spleen was surrounded by a fibrous capsule and was found to be hyperechoic, which was similar to that of dogs (Huynh and Berry, 2017). This might be due the presence of smooth muscle cells as opined by Ghosh (1995).

The splenic parenchyma was fine, granular and relatively homogenous when compared to the liver. The spleen was hyperechoic compared to the liver. This was similar to the findings of Huynh and Berry (2017) in dogs.

5.2.4 Kidney

Kidney of sloth bears were paired, elongated, lobulated structures. The left kidney was found in the left lateral abdomen, caudal to the tail of the spleen. Mild pressure had to be applied with 4 MHz frequency which helped to visualize the kidney. The kidney was found to be lobulated. Each lobule was surrounded by a capsule. This was confirmed with the anatomical features.

The right kidney was found in the right lateral abdomen and was nested in the caudate lobe of the liver, more caudal in relation to the left kidney. This was in agreement with the anatomical features of kidney of the sloth bears. The echogenicity of both the kidneys was found to be almost the same.

Each lobule consisted of an outer covering which was hyperechoic which is due to the fibrous tissue. The cortex had very fine and uniform echotexture. Medulla was an anechoic structure. The cortex and medulla were divided by a hyperechoic line. This hyperechoic line is due to the presence of the arcuate artery that curves over the bases of the medulla as opined by Dyce *et al.* (2010) in case of dogs.

The depth of the renal cortex and renal medulla were in the ratio of 2:1. These findings were similar to the findings of Kubodera *et al.* (1993) in dogs.

As per the anatomical features, the renal pelvis and ureter was found to be on the medial aspect of the kidney.

The length and width of the left kidney was found to be 7.18 ± 0.09 cm and 3.92 ± 0.11 cm respectively. And the length and width of the right kidney was found to be 7.18 ± 0.15 cm and 3.7 ± 0.14 cm respectively.

5.2.5 Urinary bladder

The urinary bladder of sloth bear was a pear shaped organ with a round cranial apex and with tapering end running towards the neck of the bladder. When empty, bladder was irregular in shape. The bladder constituted of urine which was anechoic in nature. This was in accordance with Graham (2002), observed in dogs.

When urinary bladder was full, it was found in the caudo-ventral abdomen and when empty found in the pelvic cavity.

The urinary bladder consisted of three layers: Inner- hyperechoic layer which is the submucosa, middle- hypoechoic layer which is the smooth muscles and outer- hyperechoic layer which is the serosal layer. This was in agreement with the findings of Huynh and Berry (2016) in dogs.

The thickness of the urinary bladder was found to be 0.35 ± 0.015 cm.

5.3 PHYSIOLOGICAL PARAMETERS

The temperature was 97.7 ± 0.26 °F which was in agreement with the findings of Veeraselvam *et al.* (2014).

The respiration rate was 15.5 ± 1.54 breaths per minute which was lower than the findings of Veeraselvam *et al.* (2014).

The heart rate was 52.3 ± 2.12 beats per minute which was lower than the findings of Veeraselvam *et al.* (2014).

These differences may be due to the use of xylazine for anesthetizing the animal which depresses the respiration rate and heart rate.

5.4 SERUM BIOCHEMISTRY

The value of BUN was found to be 15.17 ± 0.72 which was in good agreement with the findings of Bush *et al.* (1980) and Ramsay (1999).

The value of Creatinine was found to be 1.47 ± 0.06 which was similar to the findings of Ramsay (1999) and Veeraselvam *et al.* (2014).

The value of ALT and AST was found to be 25.39 ± 2.33 IU and 90.72 ± 2.56 IU respectively, which is similar to the findings of Ramsay (1999).

All the serum biochemical parameters were within the normal range indicating that the anesthesia had no effect on the biochemical parameters. Further, it indicated that the animals utilized for the study were all healthy.

5.5 CONCLUSION

Ultrasound of various abdominal organs were carried out successfully in the sloth bears after anesthetizing them with ketamine and xylazine.

The topographic dimension, size, shape, thickness and echotexture of various organs were recorded. It may act as a useful indicator to pave way for further ultrasonographic studies on the pathological abnormalities of the abdomen in sloth bears.

The physiological and biochemical parameters were also recorded. The respiration and heart rate were slightly below the normal range. This may have been due to the use of xylazine as anesthesia of the sloth bears. The biochemical parameters were in the normal range.

Summary



6. SUMMARY

The ultrasonographic study of different abdominal organs in sloth bears was carried out at the Wildlife SOS, Bannerghatta Bear Rescue Centre. The sloth bears were anesthetized using ketamine and xylazine for the procedure. The animal was placed on the dorsal recumbency on the examination table to carry out the ultrasonographic study.

The ultrasound study of different abdominal organs like the liver, gall bladder, spleen, kidneys and urinary bladder were carried out. The size, shape, thickness and echotexture of different organs were recorded.

In sloth bears, cranial lobe of the liver was located within the ribcage, cranial to the stomach with cranial margins against the diaphragm. The diaphragm appeared as a curved hyperechoic line. Caudally liver was in contact with spleen to the left, centrally stomach and kidney to the right. Although the liver was divided into four lobes namely, right lobe including lateral and medial sublobes, quadrate lobe, left lobe including lateral and medial sublobes and caudate lobe including the caudate and the papillary processes, the lobes were not well distinguished in ultrasound scanning except for caudate lobe. The normal hepatic parenchyma was uniform with fine or coarse granular echogenicity compared to spleen.

The gall bladder was a round, oval or pear shaped structure located between the lobes. The size varied significantly based on the size of the animal. The wall was thin, smooth and hyperechoic with variable amount of sludge inside the bladder.

Spleen was an elongated sock like structure. The spleen was divided into head, body and tail. The head of the spleen was placed between the 13th and 14th ribs and it continued as the body and turned at the tail. The spleen ended close to the urinary bladder. The spleen was surrounded by a capsule which was found to be hyperechoic. The splenic parenchyma was fine, granular and relatively homogenous when compared to the liver. Also the spleen was hyperechoic compared to the liver.

Kidneys were paired, elongated, lobulated structures. The left kidney was found in the left lateral abdomen, caudal to the tail of the spleen. Each lobule was surrounded by a capsule which was found to be hyperechoic. The right kidney was found in the right lateral abdomen and was nested in the caudate lobe of the liver, more caudal in relation to the left kidney. Echogenicity was found to be the same as the left kidney. Each lobule consisted of cortex which had very fine and uniform echotexture. Medulla was an anechoic structure. The cortex and medulla were divided by a hyperechoic line.

The normal bear urinary bladder was pear shaped with round cranial apex and tapering towards the neck of the bladder. The bladder constituted of urine which was anechoic in nature. The bladder wall composed of three layers, inner- hyperechoic layer which is the submucosa, middle- hypoechoic layer which is the smooth muscles and outer- hyperechoic layer which is the serosal layer.

The physiological and biochemical parameters were also recorded. The respiration and heart rate were slightly below the normal range. This may have been due to the use of xylazine as anesthesia for sloth bears. The biochemical parameters were in the normal range.

Bibliography



7. BIBLIOGRAPHY

- ACORDA, J. A and MERGILLA, M. C. A., 2010. Renal ultrasound features and echo histograms in captive Bengal tigers (*Panthera tigris tigris*). *Philippine J. Vet. Med.*, **47**(2): 6-11
- AUGUSTO, A.Q., 2008. Ultrasonography in south American wild animals. In: Biology, Medicine and Surgery of south American wild animals. *Edt.* Fowler, M.E. and Cubas, Z.S. John Wiley & Sons., pp 464-474
- BAPODRA, P., BOUTS, T., MAHONEY, P., TUMER, S., SILVA-FLETCHER, A. and WATER, M., 2010. Ultrasonographic anatomy of the Asian elephants. *J. Zoo. Wildl. Med.* **41**(3): 409-417
- BUSH, M., CUSTER, R.S. and Smith, E.E., 1980. Use of dissociative anesthetics for the immobilization of captive bears: blood gas, hematology and biochemistry values. *J. Wildlife Dis.* **16**. 481- 489
- DYCE, K. M., SACH, W. O. and WENSING, C. J. G., 2010. Textbook of Veterinary Anatomy. *Edn* 4th. Elsevier and Saunders, St. Louis, Missouri. p 834
- EVANS, H. and DE LAHUNTA, A., 2013. Anatomy of the Dog. Elsevier and Saunders, St. Louis, Missouri. p 331-333
- FOWLER, M. E. and MILLER, R. E., 2015. Zoo and wild animal medicine. *Edn* 8th. Elsevier and Saunders. p 498-508
- GARCÍA, N., SANTOS, E., ARSUAGA, J.L. and CARRETERO, J.M., 2006. High-resolution x-ray computed tomography applied to the study of some endocranial traits in cave and brown bears. *Sci. Annals, Geol. School.* Special Vol. 141-146
- GHOSH, R. K., 1995. Primary Veterinary Anatomy. Current books international. pp 156.166

- GRAHAM, J.P., 2002 . Abdominal ultrasound. In: Diagnostic imaging of dogs and cats. The Gloyd Group. Inc., pp 78-90
- GUIMARAES, L. D., HAGE, M. C. F. N. S., PAULA, T. A. R., BORGES, A. P. B., CARRETTA, M., OLIVEIRA, A. R., CARNEIRO, F. T. and SILVIA, V. H. D., 2013. Abdominal and pelvic ultrasound study of the maned wolf (*Chrysocyon brachyurus*). *Pesq. Vet. Bras.* **33**(2): 265- 272
- HEMIN, Z., LI, D. and WANG, C., 2009. Delayed implantation in giant pandas: the first comprehensive empirical evidence. *Reproduction.* 138: 979- 986
- HILDEBRANDT, T., DREWS, B., GAETH, A.P., GOERITZ, F., HEMES, R., SCHMITT, D., GRAY, C., RICH, P., STRIECH, W.J., SHORT, V.R. and RENFREE, M.B., 2007. Foetal age determination and development in elephants. DOI: 10.1098/rspb.2006.3738
- HILDEBRANDT, T.B. and SARAGUSTY, J., 2016. Uses of ultrasonography in wildlife species. Veteriankey. www.veteriankey.com/use-of-ultrasonography-in-wildlife-species/
- HILDEBRANDT, T.B., HERMES, R., JEWGENOW, K. and GORITZ, F., 2000. Ultrasonography as an important tool for development and application of reproductive technologies in non-domestic species. *Theriogenology.* **53**(1): 73-84
- HOQUE, M., 2005. Ultrasonographic scanning in wild animals. IVth Annual Convention of Association of Indian Zoo and Wildlife Veterinarians. p 76
- HOQUE, M., 2013. Ultrasonography in wildlife health management. National Symposium: Newer Approaches in Welfare and Health Management of Captive and Free Ranging Wild Animals. p 157-160
- HUAIJANTUG, S., MANATPREPREM, K., MANATPREPREM, S. and YATMARK, P., 2016. Ultrasonographic evaluation of the renal dimensions in captive tigers. *J. Vet. Med. Sci.*, **78**(12): 1759–1763

- HUYNH, E. and BERRY, C. R., 2016. *The urinary tract: Urinary bladder and Urethra. Todays Vet. Pract. J.*, **6**(5):61-67
- HUYNH, E. and BERRY, C. R., 2017. Imaging Essentials: Small Animal Abdominal Ultrasonography –The Spleen. *Todays Vet. Pract. J.*, **7**(2) :93-101.
- KEALY, K. J., MCALLISTER, H. and GRAHAM, J. P., 2011. Diagnostic Radiology and Ultrasonography in Dogs and Cats. Edn 5th., Elsevier and Saunders. pp 10-11
- KIRCHER, K. R., 2011. Chapter 2. Equipments. (eds) Barr, F and Gaschen, L. In BSAVA Manual of Canine and Feline Ultrasonography. British Small Animal Veterinary Association, Gloucester, England. Pp 15-20
- KUBODERA, T., ASAKAWA, M. and ITO, H., 1993. Morphometric studies on the cortex and medulla of frontal sectioned kidneys in the Japanese adults. *Kaibogaku Zasshi*. **68**(5): 504-512
- MAURAGIS, D. and BERRY, C. R., 2016. Imaging Essentials: Small Animal Abdominal Ultrasonography –Liver and Gall bladder: Part 1. *Todays Vet. Pract. J.*, **6**(3):73-79
- NYLAND, T. G. and MATTOON, J. S., 2002. Small animal diagnostic ultrasound. Edn 2nd ., W.B. Saunders Company. pp 53-56
- PURI, M., SRIVATHSA, A., KARANTH, K. K., KUMAR, S. N. and KARANTH, U. K., 2015. Multiscale distribution models for conserving widespread species: the case of sloth bear *Melursus ursinus* in India. *Diversity and Distributions.*, **21**(9): 1087-1100
- RADCLIFF, R.W., CANDRA, D. and ANDRIANSYAH, 2009. Ultrasonography the ultimate tool for Sumatran rhinos. *The Horn: 5*
- RAMSAY, E. C., 1999. Ursidae and hyenidae. In: Zoo and wild animal medicine. Edn 5th. Elsevier and Saunders, St. Louis, Missouri. pp 523- 538

- SCHILDGER, B. and TRIET, H., 2001. Ultrasonography in amphibians. *Avian and Exotic Pet Med.* **10**(4): 169-173
- SCHUMER, A., NICKEL, R. and SCIFERLE. E., 1979. The Anatomy of Domestic Animals. Edn 11th. Verlag Paul parey, Berlin. pp: 114-119
- VEERASELVAM, M., SRIDHAR, R., PERUMAL, P. and JAYATHANGARAJ, M. G., 2014. Cemical immobilization of sloth bears (*Melursus ursinus*) with ketamine hydrochloride and xylazine hydrochloride: hematology and serum biochemical values. *Vet. Med. International.* **1**: 1-5
- WAGNER, W. M., HARTLEY, M. P., DUNCAN, N. M. and BARROWS, M. G., 2005. Spinal spondylosis and acute intervertebral disc prolapse in a European brown bear (*Ursus arctos arctos*). *J. S. Afr. Vet. Assoc.*, **76**(2): 120-122

Abstract



8. ABSTRACT

Ultrasonographic study of abdominal organs in 18 sloth bears (*Melursus ursinus*) was conducted in Wildlife SOS, Bannerghatta Bear Rescue Centre. The sloth bears were anesthetized using ketamine and xylazine for the procedure. The animal was placed on the dorsal recumbency. The ultrasound study of different abdominal organs like the liver, gall bladder, spleen, kidneys and urinary bladder were carried out. The size, shape, thickness and echotexture of different organs were recorded. The lobes of liver were not well distinguished in ultrasound scanning except for caudate lobe. The normal hepatic parenchyma was uniform with fine or coarse granular echogenicity compared to spleen. The gall bladder was a round, oval or pear shaped structure. The wall was thin, smooth and hyperechoic with variable amount of sludge inside the bladder. Spleen was an elongated sock like structure. The spleen was divided into head, body and tail. The spleen was surrounded by a capsule which was found to be hyperechoic. The splenic parenchyma was fine, granular and relatively homogenous and was hyperechoic compared to the liver. Kidneys were paired, elongated and lobulated. Each lobule was surrounded by a capsule which was found to be hyperechoic. Echogenicity of both kidneys were the same. Each lobule consisted of cortex which had very fine and uniform echotexture. Medulla was an anechoic structure. The cortex and medulla were divided by a hyperechoic line. The normal bear urinary bladder was pear shaped. The bladder constituted of urine which was anechoic in nature. The physiological and biochemical parameters were also recorded. The respiration and heart rate were slightly below the normal range. This may have been due to the use of xylazine as anesthesia for sloth bears. The biochemical parameters were in the normal range.