



## RESEARCH ARTICLE

### Prevalence of Endoparasites in Captive Psittacine Birds Belonging to Pet Shops and Private Residences In and Around Chennai

A Prathipa<sup>1\*</sup>, Jayathangaraj MG<sup>2</sup>, Gomathinayagam S<sup>3</sup> and Thangavelu A<sup>4</sup>

<sup>1</sup>Department of Wildlife Science, Madras Veterinary College, Chennai -7, India; <sup>2</sup>Department of Wildlife Science, Madras Veterinary College, Chennai -7, India; <sup>3</sup>Centralized University Laboratory, Madhavaram, Chennai -51, India; <sup>4</sup>Department of Veterinary Microbiology, Madras Veterinary College, Chennai -7, India

#### ARTICLE INFO

Received: March 12, 2013  
Revised: March 24, 2013  
Accepted: May 06, 2013

#### Key words:

Captive Psittacines  
Chennai  
Endoparasites

#### \*Corresponding Author

A Prathipa  
prathipa77@gmail.com

#### ABSTRACT

We conducted a study to identify the common endoparasites that affect the captive Psittacine birds reared as pets in and around Chennai, Tamil Nadu (India). A total of 250 samples from dropping of captive Psittacine birds were collected from different companion birds like Budgerigars (150 samples), African Love Birds (50 samples) and Cockatiels (50 samples) that belonged to various pet shops and private residences. The samples were stored in small containers filled with 10% formalin. The samples were examined for the evidence of endoparasitism by both centrifugal sedimentation and floatation techniques as suggested by Soulsby (1982). Our examination revealed the presence of endoparasites such as *Ascaridia* sp. (11.20%), *Capillaria* sp. (20.0%), *Strongyloides* sp. (2.0%), Strongyle (1.60%), oocyst of *Eimeria* sp (10.40%) and mixed infections (11.60%). Based on our study, we identify the major causes for endoparasitism and we suggest important managerial measures to prevent endoparasites and promote the health of birds that are reared as pets.

**Cite This Article as:** Prathipa A, Jayathangaraj MG, Gomathinayagam S and Thangavelu A, 2013. Prevalence of endoparasites in captive psittacine birds belonging to pet shops and private residences in and around Chennai. Inter J Vet Sci, 2(2): 58-60. www.ijvets.com

#### INTRODUCTION

Endoparasitism is one of the major health problems in the companion birds and is on the top of the list of clinical problems considered for differential diagnosis, especially in newly acquired birds and in large aviary collections. Greve (1996) reported that in caged and aviary birds, gastro-intestinal parasitism ranked as the most frequent and important one. Ramisz *et al.* (2007) determined the parasitic species composition, prevalence and intensity of infection in selected parrots. Lee *et al.* (2011) conducted a prevalence study of gastrointestinal parasites in Psittacine birds which while in groups were found to have a significant higher percentage of parasites compared to birds kept individually. Symptoms of endoparasitism include, but not limited to, loss of appetite, changes in vocalization, ruffled plumage, breathing difficulties, weight loss, bloody diarrhea, and inability to survive. Hence, screening for endoparasites is highly essential to assess the health status of the birds. Therefore, we conducted a study by collecting droppings from a variety

of captive psittacine birds that belonged to various pet shops and private residences in and around Chennai. The samples were carefully examined for the presence of endoparasites. Our study revealed a high prevalence of endoparasites in the bird reared as pets. We identified some of the key factors responsible for the prevalence of endoparasites and accordingly we suggest important managerial measures to promote the health of bird reared as pets.

#### MATERIALS AND METHODS

A total of 250 samples from droppings (fecal samples) were collected from a variety of companion birds that belonged to pet shops and private residences in and around Chennai city. Samples were collected from different companion birds such as Budgerigars (150 samples), African Love Birds (50 samples) and Cockatiels (50 samples). Samples were stored in small containers filled with 10% formalin. The samples were thoroughly examined for the presence of various endoparasites using

centrifugal sedimentation and floatation techniques as suggested by Soulsby (1982). The results were analysed scientifically and were documented and statistical analysis was carried out as per the standards given by Snedecor and Cochren (1994).

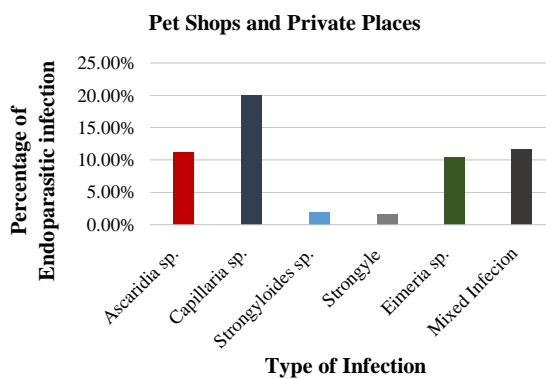
## RESULTS

Samples from droppings of captive psittacine birds were subjected to detailed parasitological examinations. Our examination revealed the presence of endoparasites such as *Ascaridia* sp. (11.20%), *Capillaria* sp. (20.0%), *Strongyloides* sp. (2.0%), *Strongyle* (1.60%) and oocysts of *Eimeria* sp. (10.40%) and mixed infections (11.60%). Details are presented in Table 1 and Figure 1. Our results are strongly indicative of the need for periodical assessment of droppings for endoparasites which will help in the timely treatment of parasitic infections.

**Table 1:** Prevalences of endoparasites in birds belonging to pet shops and private residences (n=250)

Species of the parasites observed		Budgerigars (n=150)	African love birds (n=50)	Cockatiels (n=50)
<i>Ascaridia</i> sp.	+	17	6	5
	%	11.33	12	10
<i>Capillaria</i> sp.	+	30	11	9
	%	20	22	18
<i>Strongyloides</i> sp.	+	4	1	0
	%	2.67	2	0
<i>Strongyle</i> sp.	+	2	1	1
	%	1.33	2	2
<i>Eimeria</i> sp.	+	20	4	2
	%	13.33	8	4
Mixed infection	+	19	6	4
	%	12.67	12	8

+ = Number of positive samples; % = Percentage of infection; n= No. of samples collected



**Fig. 1:** Overall percentage of endoparasites observed in fecal samples from birds that belonged to pet shops and private residences in and around Chennai

## DISCUSSION

The prevalence of Ascarids along with other endoparasites observed in our study was in accordance with the report furnished by Greve (1996), who opined that ascarid infection was common in aviary birds. The mixed infections including the eggs of *Ascaridia* species as noticed in the psittacine birds in our study was further in agreement with the reports of Tully *et al.* (2000) who

opined that round worms were the commonest cause of mortality.

In our study, we observed *Capillaria* species in Budgerigars, Love birds and Cockatiels. This finding was in agreement with the reports of Tully *et al.* (2000), who showed the occurrence of eggs belonging to *Capillaria* sp. (eggs that were small and with bipolar appearance) in domestic birds. The findings of eggs of *Capillaria* sp. in the Psittacine birds in this investigation was in accordance with the study of Kajerova and Barus (2005) who stated that the prevalence of Capillariid eggs in coprological examinations of psittacine birds in captivity was relatively frequent. In psittacine birds of Brazil, the following capillariid species were reported: *Capillaria plagiaticia* and *Eucoleus contortus* (the oesophageal capillariid observed in Budgerigars), s

The mixed infections (*Ascaridia* sp., *Capillaria* sp., *Strongyloides* sp., *Strongyles* and *Eimeria* sp.) that included the eggs of *Ascaridia* sp. was in agreement with the reports of Tully *et al.* (2000), who opined that round worms were the commonest cause of death in parakeets. Khan *et al.* (2010) revealed that during the laboratory investigation of a total of 130 fecal samples collected from various species of parrots, 88 samples were found to be positive for either single or mixed infection of Ascarids.

Viney and Lok (2007) quoted that *Strongyloides* was the genus that consists of about 50 species of gastrointestinal parasites that infect birds, mammals, reptiles and amphibians. Encountering of *Strongyloides* sp. from avifauna as carried out in our investigation was further supported by the studies of Yoshino *et al.* (2012). Lee *et al.* (2005) also demonstrated the occurrence of *Strongyloides* in ~3.8 percent of the 132 fecal samples of psittacines birds collected from pet shops, zoos and individual bird owners.

Burr (1987) showed that numerous species of coccidia infect the small intestines of birds and that these protozoans produced the oocysts that were discharged in the feces. Oocysts of *Eimeria* species were identified in the fecal samples tested according to the protocols provided by Soulsby (1982). The sporulated oocysts containing four sporocysts each with two sporozoites were identified in the positive fecal samples. The encountering of coccidial parasites in this study (in Budgerigars, African Love Birds and Cockatiels) separately as well as in mixed infections was supported by the reports from Price (1992) who stated that coccidiosis was a serious disease of budgerigars and in aviary birds and was shown to cause significant mortality. The clinical signs of coccidiosis include bloody diarrhea and the signs were similar to those associated with the sick bird syndrome.

Papini *et al.* (2012) stated that intestinal coccidia that infect birds included species of the genera *Eimeria*, *Isospora*, *Tyzzeria* and *Wenyonella* and could be distinguished by the characteristic morphology of their sporulated oocysts which differed mainly in the number of sporocysts and sporozoites. Incidence of *Eimeria* infections as encountered in the present study at pet shops and private residences was documented in budgerigars (Put a reference here) and furthermore, it was shown that *Eimeria* infections could occur in passerines in addition to Psittacines (put a reference here). In our study, 4 out of

5 birds infected with coccidia showed clinical signs. However, no appreciable clinical signs were observed in the birds that tested positive for eggs of *Eimeria* species. The degree and stage of parasitism, the physical condition, feed composition, etc. could be attributed as the causal factors for these diverse observations. In this regard, it is important to note that Arora (2003) also quoted about the occurrence of coccidian parasites in avifauna belonging to passerines as well as psittacines.

Overcrowding of birds, lack of knowledge on proper health-related measures, deficiencies in feeding-related practices, poor overall management-related measures, absence of quarantine facilities, etc. can be attributed to the presence of significant levels of mixed infections in the samples collected from pet shops and private residences. Our study clearly indicates the need for periodical examination of droppings and accordingly, treatment with anthelmintic drugs. However, the attending veterinarian needs to take utmost care during the administration of the medicament chosen, considering the risk of physical capture and restraining procedures, safety pertaining to the handler, as well as the invariably high-valued or rare avifauna that is being handled. If oocysts of coccidia are noticed in the fecal samples as encountered in our study, periodical examination needs to be recommended and carried out in such cases. If the oocysts from fecal samples are in high numbers coupled with typical clinical signs like bloody diarrhea in the examined psittacine birds, then the clinical approach should include the usage of specific drugs like amprolium (at the rate of 3 ml of 9.6 per cent solution) or potentiated sulphonamide drugs.

### Conclusions

Fecal samples from captive psittacine birds that belonged to the pet shops and private residences revealed the presence of various species of endoparasites. This finding is alarming and our findings necessitated the need for periodical deworming and proper managerial practices in companion birds.

### REFERENCES

- Arora BM, 2003. Indian Wildlife Diseases and Disorders. Association of Indian Zoo and Wildlife Veterinarians, Bareilly, pp: 212-214.
- Burr EW, 1997. Companion Bird Medicine. Iowa State University Press, Ames, Iowa.
- Greve JH, 1996. Gastrointestinal parasites and Parasites of the skin. In: Diseases of cage and aviary birds. 3<sup>rd</sup> Edn. Ed Roskopf WJ and RW Woerpel. Lea and Febiger. Baltimore, pp: 613-626.
- Khan MA, MS Khan, M Shafee and JA Khan, 2010. Prevalence and chemotherapy of helminthiasis in parrots at Lahore zoo, Pakistan. The Journal of Animal and Plant Sciences. 20: 198-192.
- Lee NYP., A Jalila, and SMA. Babjee, 2005. Prevalence study of gastrointestinal parasites in psittacine birds in the Klang Valley. The 17th Malaysian Veterinary Association Congress, 27-30 July, MIECC, Kuala Lumpur. Pp 77-79.
- Papini R, M Girivetto, M Marangi, F Mancianti and A Giangaspero, 2012. Endoparasite infections in pet and zoo birds in Italy. The Scientific World Journal, 2012: 253127.
- Ramisz AB, AT Marciniak, B Pilarczyk, MW Dabrowska and M Bakowska, 2007. Intestinal parasites of parrots. Wiad Parazytol, 53:129-132.
- Snedecor GW and WG Cochran, 1967. Statistical methods, Oxford and IBH Publishing Company, Calcutta.
- Soulsby EJ, 1982. Helminths, Arthropods and Protozoa of domestic animals. 7<sup>th</sup> edn, ELBS, Bareilly Tindall, London.
- Tully TN, MPC Lawton and GM Dorrestein, 2000. Avian medicine, Butterworth Heinemann, Oxford.
- Viney ME and JB Lok, 2007. Strongyloides spp. WormBook, 23: 1-15.