

**GENITAL STATUS AND REPRODUCTIVE DISORDERS IN
SMALL RUMINANTS-AN ABATTOIR INVESTIGATION**

THESIS

By

**Jitendra Kumar Agrawal
V-2010-30-05**

Submitted to



**CHAUDHARY SARWAN KUMAR
HIMACHAL PRADESH KRISHI VISHVAVIDYALAYA
PALAMPUR-176062 (H.P.) INDIA**

in
partial fulfilment of the requirements for the degree
of

MASTER OF VETERINARY SCIENCE

[ANIMAL REPRODUCTION GYNAECOLOGY AND OBSTETRICS]

(Veterinary Gynaecology and Obstetrics)

2012

Dedicated
Dedicated
to
my parents
and
teachers
teachers



**Department of Veterinary Gynaecology and Obstetrics
DGCN College of Veterinary and Animal Sciences
CSK Himachal Pradesh Krishi Vishvavidyalaya
Palampur-176 062 (H.P) INDIA**

Prof. Navneet Kumar

CERTIFICATE- I

This is to certify that the thesis entitled **“Genital status and reproductive disorders in small ruminants-An abattoir investigation”** submitted in partial fulfilment of the requirements for the award of the degree of **Master of Veterinary Science** in the discipline of **Animal Reproduction, Gynaecology and Obstetrics** of CSK Himachal Pradesh Krishi Vishvavidyalaya, Palampur is a bonafide research work carried out by **Dr. Jitendra Kumar Agrawal (V-2010-30-05)** son of Mr. Girraj Prasad under my supervision and that no part of this thesis has been submitted for any other degree or diploma.

The assistance and help received during the course of this investigation have been duly acknowledged.

Place:

Date:

(Navneet Kumar)
Major Advisor

CERTIFICATE- II

This is to certify that the thesis entitled “**Genital status and reproductive disorders in small ruminants-An abattoir investigation**” submitted by **Dr. Jitendra Kumar Agrawal (V-2010-30-05)** son of Mr. Girraj Prasad to the CSK Himachal Pradesh Krishi Vishvavidyalaya, Palampur in partial fulfillment of the requirements for the award of the degree of **Master of Veterinary Science** in the subject of **Animal Reproduction, Gynaecology and Obstetrics** has been approved by the Advisory committee after an oral examination of the student in collaboration with an External Examiner.

 Prof. Navneet Kumar
 Chair Person, Advisory Committee

 External Examiner

 Dr. Pankaj Sood
 Member

 Dr. Purabi Barman
 Member

 Prof. M.S Kanwar
 Dean’s nominee

 Professor & Head
 Department of Veterinary Gynaecology and Obstetrics
 DGCN College of Veterinary and Animal Sciences
 CSK Himachal Pradesh Krishi Vishvavidyalaya, Palampur, (H.P)

 Dean, Postgraduate studies

ACKNOWLEDGEMENTS

I express my heartiest gratitude to Dr. Navneet Kumar Vasishta, my Major Advisor, for his valuable guidance, constant supervision, constructive criticism, tireless devotion and encouragement throughout the entire course of this investigation.

I am deeply indebted to Dr. Madhumeet Singh for his caring and ever helping attitude and being positively and constructively critical at all times.

I am also grateful to Dr. M.S Kanwar, Dr. Pankaj Sood and Dr. Purabi Barman, members of my advisory committee for their timely help and inspiration during the entire course of my study.

I would like to thank the faculty members of the department, Dr. Amit Sharma and Dr. Pravesh Kumar for their helping attitude, inspiration and kind assistance during the entire course of my study.

I would like to appreciatively acknowledge the support of Dr. R.K. Asrani, Dr. R.D. Patil, Dr. Ajay Masand and Dr. Varun Sankhyan who guided me to carry out my work smoothly. The Dean, Postgraduate Studies and his staff, deserves special thanks, which acted as our guardian and provided us facilities for study as well as accommodations.

I am thankful to all my senior and junior classmates, Drs., Ajit Banthai, Manisha Verma, Mridu Sharma, Yogita Masand, Pradeep Sharma, Shama Khan, Nishant. I want to thank the research fellows of Department of Veterinary Gynaecology & Obstetrics, especially Mr. Naresh, Mrs. Rajni, Mrs. Anuradha and Miss Anjana and staff members, viz. Sh. Anil Kumar, Sh. Kamal Jeet, Sh. Shanti Swaroop, Sh. Nand Kishore and Sh. Ravi Kumar for their unwavering cooperation and help every time I needed.

Heartfelt thanks to Mrs. Meenakshi Sharma and my dear friend, Aasheesh Jain for their moral support and encouragement during my study period. I would like to thank to Dr. Imran Khan, Roohul-Amin, Neeraj Sharma, Ashok, Lakhnupal Singh, Vishnu, Satyavir Dangi and Gaurav Somani also, who helped in my thesis work.

This research work wouldn't have completed without the help of Milapchand, Sappo singh, Ravi and Prakash who helped me for collection of genitalia from different places. I can't forget them.

Words are inadequate to express my gratitude to all my family members, who always encouraged me for this study.

Finally I would like to thank god for always being there.

Palampur
Dated

Jitendra Kumar Agrawal

CONTENTS

CHAPTER	TITLE	PAGE
1	INTRODUCTION	1-2
2	REVIEW OF LITERATURE	3-18
3	MATERIALS AND METHODS	19-22
4	RESULTS AND DISCUSSION	23-44
5	SUMMARY AND CONCLUSIONS	45-48
	LITERATURE CITED	49-61
	APPENDIX	-
	BRIEF BIO DATA OF THE STUDENT	

LIST OF TABLES

Table No.	TITLE	PAGE
1	Genital status and prevalence of reproductive abnormalities in sheep abattoir genitalia (n=267)	23
2	Genital status and prevalence of reproductive abnormalities in goats abattoir genitalia (n=371)	26
3	Distribution of pregnancies and transuterine migration in sheep and goats	36
4	Mean distribution of follicles and CL in sheep ovaries during breeding and non breeding seasons (n=267)	41
5	Mean distribution of follicles and CL in goat ovaries during breeding and non breeding seasons (n=371)	42
6	Mean number of follicles in ovaries with and without CL in sheep (n=534)	43
7	Mean number of follicles in ovaries with and without CL in goats (n=742)	44

LIST OF FIGURES

Figure No.	TITLE	PAGE
1	Distribution (%) of reproductive abnormalities of sheep (n=40)	24
2	Distribution (%) of reproductive abnormalities in goats (n=92)	29
3	Distribution of pregnancies in uterine horns of sheep (n=21) and goats (n=43)	36
4	Incidence (%) of transuterine migration in sheep (n=21) and goats (n=43)	37
5	Distribution of caruncles in gravid and non- gravid uteri of sheep and goats	38
6	Relative activity of right and left ovary in sheep (n=125) and goats (n=202)	39
7	Incidence of single and multiple ovulation in sheep (n=111) and goats (n=177)	40

LIST OF PLATES

Plate No.	TITLE	PAGE
M1	Ovary showing follicular cyst	20
M2	Ovary showing luteinised cyst	20
M3	Ovarobursal adhesions	20
M4	Hydrosalpinx	20
1	Uterus showing pyometra	30
2	Uterus showing bilateral mucometra	30
3	Uterus showing hydrometra	30
4	Uterus showing excessive haemorrhage in uterine horns	30
5	Parovarian cyst	30
6	Parasitic cyst	30
7	Photomicrograph of the uterus showing surface epithelium, endometrial stroma and well distributed endometrial glands	33
8	Photomicrograph of the uterus showing increased size and number of endometrial glands	33
9	Photomicrograph of the uterus showing dilated and hyperplastic endothelial glands filled with pus	33
10	Photomicrograph of the uterus showing large number of lymphocyte and plasma cells in endometrial stroma	33
11	Photomicrograph of the uterus showing clear white areas of serous fluid accumulated in the endometrium	34
12	Photomicrograph of the uterus showing increased glandular epithelial activity and presence of mucinous substance	34
13	Photomicrograph of the uterus showing hypertrophied luminal epithelial cells with vacuolated cytoplasm	34
14	Photomicrograph of the uterus showing excessive golden brown colour pigment in the endometrium	34

**Department of Veterinary Gynaecology and Obstetrics
CSK Himachal Pradesh Krishi Vishvadyalaya
Palampur- 176062**

Title of the thesis : Genital status and reproductive disorders in small ruminants-An abattoir investigation

Name of the student : Jitendra Kumar Agrawal

Admission number : V-2010-30-05

Major discipline : Animal Reproduction, Gynaecology and Obstetrics

Minor discipline : Veterinary Surgery & Radiology

Date of thesis submission : July, 2012

Total pages of the thesis : 71

Major Advisor : Prof. Navneet Kumar Vasishta

ABSTRACT

The present study was undertaken to conduct an abattoir survey on morbid genitalia of sheep (n=267) and goat (n=371) procured from local abattoirs in and around Palampur over a period of one and a half year from September 2010 to March 2012. A detailed gross morphological examination of the genital tracts involving the ovaries, uterus and cervix was carried out to study normal physiological status or detect any abnormality or disease condition and classified as normal, gravid or abnormal. The ovarian activity was assessed on the basis of presence or absence of corpora lutea (CL). To record seasonal variations, the genital tracts were examined for number of small and large follicles and CL.

Out of total sheep genitalia examined, 227 (85.02%) were physiologically normal and 40 (14.98%) had one or more genital abnormalities. Examination of goat genitalia revealed that 279 (75.20%) were normal whereas 92 (24.80%) had genital abnormalities. Ovarian abnormalities were observed in 4.86 per cent of ewes. In goats, 10.24 per cent incidence of ovarian disorders was recorded. Uterine abnormalities were observed in 7.11 per cent of ewes, which included endometritis (0.37%), pyometra (1.87%), mucometra (1.49%), hydrometra (2.99%) and mummification (0.37%). In goats, 8.08 per cent cases of uterine abnormalities were recorded involving endometritis and pyometra (1.34% each), hydrometra (3.5%) and excessive hemorrhage (0.8%). Miscellaneous lesions such as parovarian cysts, parasitic cysts and nodules on outer surface of uterine horns were also evident. The uterine and ovarian abnormalities co-existed only in a few abattoir sheep or goat genitalia. Quite a good number of sheep (7.8%) and goats (11.59%) were pregnant. Right ovary was more active as compared to left in both the species. Significantly (p<0.05) higher mean number of corpora lutea was recorded during breeding season both in sheep (0.64±0.06 vs 0.39±0.06) and goats (0.76±0.05 vs 0.55±0.07).

.....
Signature of student

.....

.....

Major Advisor

Date:

Head of the Department

Chapter 1

Introduction

Livestock sector is an important component of India's economy in terms of income, employment, equity and foreign exchange earnings. Following the sustained economic growth and rising domestic incomes, the demand for livestock products has increased tremendously. This has encouraged the rapid expansion of livestock output during the last few decades.

Among the livestock sector, small ruminants (sheep and goats) are important livestock species of India. It has a large population of these species; third-largest sheep population and second largest goat population of the world. Sheep contribute 13.5 per cent whereas goats contribute 26.5 per cent of total livestock population of India (livestock census 2007).

Sheep and goat have an inseparable identity with the farmers in India from time immemorial. They are principally maintained by poor sections of rural community providing them a source of livelihood. About 5 million households in the country are engaged in rearing of these animals. They contribute immensely to the economy of rural India. They provide milk, meat, wool, pelts, skin and other by products for industrial purpose and also contribute to foreign exchange earnings. Rearing of sheep and goats is more economical and environment friendly as compared to large animals. In addition they form substantially useful fraction of their total farm income, particularly, when crops fail due to drought and other adverse conditions.

The most important factor determining the success of sheep and goat production is its reproductive efficiency which in turn is adversely affected by different reproductive diseases. These diseases usually manifest themselves through infertility, irregular cycling, abortions, fetal mummification and stillborn or weak offspring. If not detected early and an appropriate control strategy put in place, the reproductive abnormalities and/ or diseases in a flock may rapidly attain epidemic proportions. This calls for regular epidemiological studies into the causes of reproductive inefficiency.

Various methods can be used to detect such problems viz. ultrasonography, radiology, laboratory diagnosis and post-mortem or ante mortem examination of abattoir animals. The latter method is very appropriate especially in developing countries because it allows for examination of a large number of animals in a short time at a very low cost (Timurkaan and Karadas 2000). Advances in understanding of seasonality, ovarian

activity, prenatal development, transuterine migration, embryonic losses and pathological conditions of reproductive tracts have frequently entailed examination of abattoir specimens. The abattoir provides a useful source of information on the types and prevalence of genital tract abnormalities and to monitor ovarian cyclic status and reproductive seasonality (Alam 1984).

The livestock are also indiscriminately slaughtered to cater the routine needs of ever increasing population and even gravid animals are slaughtered inadvertently or otherwise. Lack of proper ante mortem examination or inadequate facilities at that time may be the probable reason. This contributes to potential prenatal losses which may subsequently pose uncertainty with regards to country's ever increasing demand for quality meat and its products at an affordable price. There is a little information available on extent of such reproductive wastage. It is therefore important to estimate such losses which are possible through abattoir investigations.

A little is known about seasonality pattern, ovarian activity and reproductive problems in sheep and goats reared by the rural community of Himachal Pradesh. The present investigation was therefore aimed with the following objectives:

- To conduct an abattoir study on the normal genital status and reproductive disorders in sheep and goats.
- To monitor cyclic changes in abattoir ovaries of small ruminants.
- To correlate association between uterine and ovarian abnormalities.

Chapter 2

Review of Literature

Regular and successful reproduction is the key to profitable sheep and goat production. Reproductive efficiency is one of the major factors determining productivity and economic viability of sheep and goat husbandry and it is one of the major contributory factors to the success of livestock development programmes. However, reproductive diseases pose major limitations.

Several factors are known to affect the reproductive performance of farm animals (Mukasa-Mugerwa 1989) and it is a mistake to attempt to diagnose unsatisfactory reproductive performance by focusing on any one particular disorder or symptom because of the interrelationship of the predisposing factors (Erb 1987).

The slaughter house genitalia not only provide an insight into reproductive seasonality, ovarian cyclic status but also help detecting various reproductive abnormalities and many reproductive disorders are diagnosed during post mortem examination (Alam and Rahman 1979; Alam 1984).

2.1 Prevalence of gross reproductive abnormalities

A wide variation has been recorded in incidence of reproductive abnormalities found over different geographical conditions (Raji *et al.* 2010). Among the acquired reproductive abnormalities, cystic ovaries, ovarobursal adhesions and different uterine pathologies have been recorded in ewes (Alosta *et al.* 1998). Smith *et al.* (1999) observed that acquired abnormalities were more significant in terms of individual animal infertility than as a major cause of infertility in sheep flocks. Winter and Dobson (1992) recorded that 23.2 per cent of the tracts had abnormalities and it was considered that 16.8 per cent had abnormalities likely to interfere with the establishment of pregnancy.

Dawood (2010) recorded prevalence of macroscopically diagnosed pathological abnormalities in 25.7 per cent of the ewes. The uterus was most commonly affected, accounting for 70 per cent of the abnormalities, followed by the ovary (24%) and the oviduct (6%). Moghaddam and Gooraninejad (2007) observed 25.8 per cent gross abnormalities of reproductive tracts of ewes but the highest rate of abnormality was in the ovaries (20.1%), followed by oviduct and the uteri.

Sudhakar *et al.* (2010) observed 6.52 per cent abnormal genital tracts out of 3004 tracts of Deccani ewes examined. Long (1980) examined 276 reproductive tracts of ewes and found that incidence of pathological conditions was 8.7 per cent. Alosta *et al.* (1998)

reported that overall 9.4 per cent of the tracts showed evidence of pathological changes and 5.5 per cent of the tracts had abnormalities likely to impair fertility.

Rahman *et al.* (2008) reported 27 (52.9%) genital abnormalities, out of 51 genitalia of goats investigated. Singh and Rajya (1977) observed 21.45 per cent incidence of disorders in the genital system of goats. AI-Baggal *et al.* (1993) recorded 14.69 per cent prevalence of gross abnormalities in Iraqi goats. Chand and Chauhan (1978) observed various pathological conditions in 105 out of 5404 goats examined. Abeyratne and Atureliya (1982) reported an incidence of 11.4 per cent of pathological conditions and malformations in indigenous female goats of Srilanka.

2.1.1 Ovarian abnormalities

2.1.1.1 Ovarian cysts

Abnormalities of gonadal development occur infrequently in domestic and laboratory animals. Such abnormalities may affect one or both gonads (Jones *et al.* 1997). The occurrence of ovarian lesions can be either unilateral or bilateral. They are associated with varying degrees of infertility depending on the nature and extent of the abnormality.

Generally, the ovaries and their surrounding supporting ligaments are reported to be the common sites for development of cysts. While some cysts are incidental findings at post-mortem, others are associated with fertility disturbances. Intra ovarian cysts include anovulatory Graafian follicles and cystic corpora lutea (Maclachlan and Kennedy 2002).

Alosta *et al.* (1998) observed incidence of follicular cysts in 0.8 per cent of cases; of which 0.2 per cent were bilateral and 0.6 per cent were unilateral. Luteal cysts were observed in 0.9 per cent of ewes. Smith *et al.* (1998) identified 9 cases of follicular cyst in culled and 46 cases in nulliparous sheep. The author also recorded luteinised cysts in one culled and three nulliparous ewes. Moghaddam and Gooraninejad (2007) detected 0.3 per cent incidence of follicular cyst and 0.1 per cent luteal cysts in Awassi ewes. Regassa *et al.* (2009) observed 4.3 per cent cases of ovarian cysts in Ethiopian highland ewes.

Chand and Chauhan (1978) reported that cystic abnormalities were more frequent in goats and the follicles larger than 1.2 cm in diameter were considered cystic (Morrow 1986). Sattar and Khan (1988) observed 0.23 per cent incidence of follicular cyst and 0.14 per cent incidence of luteal cyst in goats. Varied incidence of cystic ovaries (0.32%, 1.6%, 0.8% and 12 %) in goats was also recorded by earlier workers (Nair and Raja 1972; Abeyratne and Atureliya 1982; AI-Baggal *et al.* 1993; Moreira *et al.* 1993, respectively).

Ovarian cysts were observed in 2.4 per cent of the slaughtered goats by Lyngset (1968a) which were unilateral or single. Singh (1973) reported that right ovary was more

affected than left in goat and classified them into follicular cyst and luteal cyst. These were larger and persistent anovulatory mature Graafian follicles which only differ in the level of luteinisation (Maclachlan and Kennedy 2002).

Sharma (1980) also diagnosed follicular cysts in ovaries of sheep and goats. These were slightly elevated oval structures varying in size from 1-3.5 cm in diameter filled with clear fluid. Sattar and Khan (1988) classified the ovarian cysts into follicular cysts, luteal cysts and cystic corpora lutea in goats.

Al-Dahash and David (1977) recorded 3.8 per cent incidence of cystic ovaries in cows and found it as most commonly encountered abnormality in his survey.

2.1.1.2 Ovarobursal adhesions

Ovarobursal adhesions vary from thin bands to large sheets of fibrous tissue binding together the walls or crossing the cavity of the ovarian bursa, a peritoneal pouch formed around the ovary by the broad ligament and the mesosalpinx (Acland 2001).

Alosta *et al.* (1998) observed ovarobursal adhesions in 2.3 per cent of the tracts examined, 60 per cent of these were on the right side, 25 per cent were on the left side and 15 per cent bilateral. Moghaddam and Gooraninejad (2007) observed that predominant lesion in ovaries were ovarobursal adhesions (11.5%) in Awassi ewes. Dawood (2010) recorded 2.8 per cent cases of ovaro bursal adhesions of the total number of tracts examined in Iraqi ewes. Sudhakar *et al.* (2010) observed 0.49 per cent cases of ovarobursal adhesions in Deccani ewes.

Nair and Raja (1972) identified seven cases of ovarobursal adhesions out of 1860 goat genitalia examined whereas Sharma (1973) observed 14 such cases out of 1625 genitalia examined. Singh and Rajya (1977) detected variable degree of adhesions in 13 cases, mostly with bilateral involvement in goats. Al-Baggal *et al.* (1993) diagnosed ovarobursal adhesions in 2.47 per cent of specimens in Iraqi goats and observed that most of these were unilateral and mild.

2.1.1.3 Parovarian cysts

The term parovarian cyst is used to describe a variety of cystic structures located adjacent to the ovary. Such cysts could arise from remnants of either mesonephric or paramesonephric tubules (McEntee 1990; Kennedy and Miller 1993). Parovarian cysts have been recorded by various workers in sheep and goats.

Emady (1976) diagnosed parovarian cysts in 10 cases out of 1129 caprine genitalia and 6 cases out of 1006 ovine genitalia. These cysts were attached to the fimbriae of the oviducts and mesosalpinx.

Long (1980) recorded only two cases of parovarian cysts out of 276 reproductive tract of sheep. In both specimen, the cysts were approximately 5 mm in diameter and located adjacent to the fallopian tube near the fimbriae. Whereas Winter and Dobson (1992) recorded only one case out of 133 tracts in culled ewes. Alosta *et al.* (1998) observed parovarian cysts in 1.8 per cent of the tracts in ewes. Most (68.8%) were on the right side.

Nair and Raja (1972) recorded 2 cases of parovarian cysts out of 1860 caprine genitalia. Sharma (1973) observed parovarian cysts in 0.98 per cent of goat genitalia. Slightly higher (1.98%) incidence was recorded earlier in goats (Gopal Yadgirkar *et al.* 1976). Abeyratne and Atureliya (1982) recorded 3.2 per cent of parovarian cysts in female goats of Sri Lanka while Javed *et al.* (1987) recorded 5.14 per cent in Barbari goats. However, Sattar *et al.* (1988) found an incidence of 1.36 per cent only, in goats of Pakistan. AI-Baggal *et al.* (1993) reported 3.95 per cent incidence of parovarian cysts in Iraqi goats.

Singh (1973) observed that parovarian cysts were mostly situated in mesosalpinx in goats. The cysts were thin walled and filled with clear fluid. Sharma (1980) depicted them as spherical tense, greyish-white fluid filled structures situated at different locations such as mesovarium, mesosalpinx and tips of fimbriae of fallopian tube.

2.1.1.4 Oophoritis

Oophoritis is inflammation of the ovary. It may arise as a direct extension from inflammations of adjacent organs or hematogenously as non specific or specific infections. It has been rare in occurrence in domestic animals and reported in sheep and goats. (Singh 1973; Singh and Rajya 1977; Winter and Dobson 1992).

Chronic diffuse cystic oophoritis condition (0.2%) was observed by AI-Baggal *et al.* (1993) in caprines. Rahman *et al.* (2008) also reported one case of oophoritis out of 51 genitalia of goat (*Capra hircus*).

2.1.1.5 Other ovarian abnormalities

Various other congenital or acquired ovarian abnormalities have also been documented earlier in sheep and goats. Moghaddam and Gooraninejad (2007) observed four cases of ovarian hypoplasia and two cases of ovarian fusion in Awassi ewes. Smith *et al.* (1998) diagnosed 12 specimens of fused ovaries out of 23,536 genitalia of nulliparous sheep. Ragassa *et al.* (2009) diagnosed 1.6 per cent incidence of ovarian atrophy in Ethiopian highland ewes. Long (1980) reported first case of ovarian cystadenoma in sheep. Sudhakar *et al.* (2010) identified two cases of bilateral ovarian hypoplasia in Deccani ewes.

Abeyratne and Atureliya (1982) reported 0.4 per cent incidence of ovarian hypoplasia in indigenous female goats of Srilanka. Reddy (1995) observed one case of ovarian hypoplasia and one case of abnormal shape of ovary (cleft ovary) out of 2928 caprine genitalia examined. Nair and Raja (1972) identified one case of ovarian abscess out of 1860 genitalia of goats examined whereas AI-Baggal *et al.* (1993) noticed ovarian abscess and ovarian congestion (two cases each) in Iraqi goats.

Kumi-Diaka *et al.* (1981) recorded 20.4 per cent and 1.9 per cent incidence of atrophic and hypoplastic ovaries, respectively, in cattle.

2.1.2 Oviduct abnormalities

2.1.2.1 Hydrosalpinx

Congenital or acquired hydrosalpinx, distension of the uterine tubes by clear fluid, is caused by mechanical or functional obstruction of the lumen (Acland 2001). Congenital anomalies involving the tubes are very rare, except in freemartins, but secondary hydrosalpinx can be associated with obstructions and segmental aplasia of the uterine horns (Kennedy and Miller 1993).

Moghaddam and Gooraninejad (2007) recorded 4.6 per cent incidence of oviduct abnormalities in ewes and found that most common lesions in oviducts were adhesions (3.3%) and hydrosalpinx (1.1%) whereas Long (1980) observed only one case (0.4%) of hydrosalpinx of total tracts examined of sheep. Dawood (2010) reported 0.9 per cent incidence of hydrosalpinx in ewes. Smith *et al.* (1999) observed hydrosalpinx in 17 culled (out of 9970 tracts) and 10 nulliparous (out of 23,536 tracts) ewes and one case of hydrosalpinx with a heavy pigmentation of melanin throughout the uterine tube was also diagnosed.

Quite low incidence of hydrosalpinx has been documented earlier. In Iraqi goats, AI-Baggal *et al.* (1993) detected one case of hydrosalpinx out of 606 genitalia examined. Sharma (1973) could identify only one case of hydrosalpinx out of 1625 reproductive tracts of goats. Sharma and Sharma (1985) also reported hydrosalpinx in one specimen out of 647 goat genitalia examined. Grossly, the right fallopian tube was uniformly dilated and distended with clear fluid. It had a thin wall and translucent appearance. Some other workers (Nair and Raja 1972; Sattar *et al.* 1988) also detected a lower incidence (0.05%; 0.02%, respectively) in goats.

2.1.2.2 Salpingitis

Inflammation of the oviduct without obstruction and resulting into hydrosalpinx (Morrow 1986) results from spread of infection from uterus to the uterine tubes and is

usually bilateral (Acland 2001). Lesions of salpingitis have been reported by various workers in sheep and goats.

Alosta *et al.* (1998) identified only one case of salpingitis out of 870 ewe genitalia examined. Sharma (1973) recorded only two cases of salpingitis out of 1625 goat genitalia examined. In Iraqi goats, AI-Baggal *et al.* (1993) identified 3 cases of salpingitis out of 606 genitalia examined. Contrarily, A higher incidence of salpingitis was identified by Sattar *et al.* (1988) who recorded 203 cases out of 4186 caprine genitalia examined. Rahman *et al.* (2008) recorded 3.9 per cent incidence of salpingitis in goats. Similarly, Singh (1973) encountered most of the cases of salpingitis to be associated with subacute endometritis in goats.

2.1.2.3 Other oviduct abnormalities

Moghaddam and Gooraninejad (2007) reported 3.3 per cent incidence of oviduct adhesions and 0.1 per cent incidence of aplasia of oviduct in Awassi ewes. Winter and Dobson (1992) observed adhesions of fallopian tubes in one case and apparently blocked fallopian tubes in seven cases out of 133 culled ewes. Nair and Raja (1972) diagnosed cyst in salpinx and parasalpingitis (one case each) condition out of 1860 goat genitalia examined. Sharma and Sharma (1985) identified a case of melanosis of the salpinx out of 647 reproductive tracts of goat. AI-Baggal *et al.* (1993) recorded 2.5 per cent incidence of occlusion of oviduct and also diagnosed one case of pyosalpinx out of 606 genitalia of Iraqi goats. Gopal Yadgirkar *et al.* (1976) detected one case of suppurative parasalpingitis out of 1700 goat genitalia examined.

2.1.3 Uterine abnormalities

Dawood (2010) examined 214 reproductive tracts of sheep and observed that the uterus was most commonly affected. Moghaddam and Gooraninejad (2007) identified 1.2 per cent abnormality in the uteri of ewes and found that hydrometra (0.3%) was a predominant uterine disorder. Rahman *et al.* (2008) observed that uterine abnormalities were in 35.2 per cent of goat genitalia examined.

2.1.3.1 Hydrometra and Mucometra

Hydrometra or pseudo pregnancy is a genital pathological state leading to permanent infertility in sheep (Smith *et al.* 1998) and goats (Hassenlink 1993). It is characterized with accumulation of aseptic fluid in the uterine lumen, presence of persistent corpus luteum in the ovaries, high blood progesterone concentration and is observed in goats with spontaneous ovulation or after oestrus synchronization (Pieterse and Taverne 1986).

Mucometra is a condition where mucus of variable consistency and amount collects in the uterus. The cause is congenital or acquired obstruction of the outflow of mucus initially produced in normal amount. However, it can be due to the production of excessive amounts of mucus in cases of hyperestrogenism (Kennedy and Miller 1993).

Sharma (1980) encountered hydrometra and mucometra in one goat each, on examination of genital tracts of 314 sheep and 647 goats. In case of mucometra, the uterus was enlarged and contained greyish viscid material.

Smith *et al.* (1999) reported hydrometra in 18 culled (out of 9970 tracts) and 62 nulliparous (out of 23,536 tracts) ewes. In a study on genital tracts of 1042 slaughtered Awassi sheep, incidence of hydrometra and mucometra was reported in 0.3 per cent and 0.2 per cent, respectively, of the total genital tracts (Moghaddam and Gooraninejad 2007). Sudhakar *et al.* (2010) detected only single specimen (0.03%) of hydrometra in Deccani ewes. Dawood (2010) reported 1.4 per cent cases of hydrometra in ewes. The author observed that these cases were characterised by the presence of a turbid, thin fluid; in two cases only the right uterine horn was affected and the other case was bilateral. A corpus luteum was seen in all three cases. Histologically, the stroma was severely oedematous, the uterine glands were dilated and the glandular cells notably flattened. Winter and Dobson (1992) diagnosed five cases of mucometra out of 133 culled ewes. Emady *et al.* (1975) also observed mucometra or hydrops uteri condition in three specimens which initially were incorrectly classified as gravid but on incision these specimens revealed the presence of a large quantity of a clear yellow fluid. Hydrometra was not uncommon in the goat but it is rarely associated with uterine abnormalities like segmental aplasia of the uterus in a goat (Webb 1985).

Al-Baggal *et al.* (1993) reported 0.8 per cent incidence of hydrometra in Iraqi goats. Nair and Raja (1972) diagnosed 3 cases of hydrometra out of 1860 goat genitalia whereas Kadu and Kaikini (1988) detected only one case out of 1050 genitalia of goats.

Singh (1973) observed 2 cases of hydrometra in goats. The author observed enlarged and distended uterine horns containing 1-2 litres of thin turbid fluid mixed with flakes and os-cervix was closed. Histopathologically, endometrium and myometrium had changes of pressure atrophy, with mononuclear cell infiltration in lamina propria.

Singh and Rajya (1977) observed 0.06 per cent incidence of hydrometra in goats in which the horns were enlarged, distended and contained 1 to 2 litres of thin turbid watery fluid, mixed with flakes. Morphologically, the endometrium had changes of pressure atrophy in submucosa and myometrium. Mononuclear cells were evident in lamina.

The incidence of hydrometra was investigated in three herds of dairy goats by Hasselink (1993) and its occurrence varied between 3.0 and 20.8 per cent with a mean of 9.0 per cent. The incidence in older goats was significantly higher than in yearlings. Kadu and Kaikini (1988) recorded hydrometra and mucometra in 0.09 per cent and 0.28 per cent of goats, respectively.

2.1.3.2 Pyometra

Pyometra is characterized by progressive collection of a purulent exudate in the uterine cavity, infection, and persistence of a functional corpus luteum. Acyclicity, inflammation and infertility are consequences of pyometra which can be a sequelae to postpartum endometritis (Morrow 1986). Persistency of a functional corpus luteum precipitates occurrence of pyometra by increasing uterine susceptibility to infection, inducing mucus plug formation and inhibition of myometrial contraction. This is mediated by progesterone secreted by the corpus luteum (Kennedy and Miller 1993).

Smith *et al.* (1999) identified pyometra in four cases out of 9970 genitalia of culled ewes whereas Winter and Dobson (1992) observed one case of pyometra out of 133 culled ewes. Moghaddam and Gooraninejad (2007) diagnosed pyometra in 0.2 per cent out of 1042 genital tracts of Awassi ewes. Sudhakar *et al.* (2010) recorded 16 cases of pyometra out of 3004 genital tracts of Deccani ewes. Dawood (2010) recorded 1.9 per cent incidence of pyometra out of 214 tracts of ewes examined. In cases of pyometra, the uterus was enlarged with a greenish-yellow purulent exudate filling the lumen. Microscopically, these cases showed suppurative inflammation and one of these showed cystic glandular hyperplasia. The other two cases showed chronic suppurative inflammation.

Kadu and Kaikini (1988), in their study, recorded only four cases of pyometra out of 1057 abattoir goat genitalia examined. Nair and Raja (1972) found 6 cases of pyometra out of 1860 female genital organs of goats. Al-Beggai (1993) reported 0.3 per cent incidence of pyometra out of 606 genital tracts of Iraqi goats.

2.1.3.3 Endometritis

Endometritis is a pathological condition in which the uterine mucosa becomes discoloured and pus collect on the mucosal surface. There may be malodorous vaginal discharge. This condition may lead to permanent infertility if an ascending infection reaches the oviduct, causing salpingitis and occlusion (Reddy 1995).

Alosta *et al.* (1998) diagnosed 2.3 per cent cases of endometritis and 0.46 per cent cases of metritis in ewes. Smith *et al.* (1999) detected endometritis in four cases out of

9970 culled ewes. Sudhakar *et al.* (2010) recorded 23 cases of endometritis out of 3004 genitalia of Deccani ewes.

Dawood (2010) observed endometritis in 24.8 per cent cases in ewes and classified it under acute, subacute or chronic according to the appearance of the tissue. Acute endometritis was characterised by oedematous swelling, congestion and haemorrhagic spots of variable size on the endometrial surface, along with varying quantities of serous or blood stained exudates in the lumen. Subacute endometritis was characterised by an increase in the number of mononuclear inflammatory cells and fibrosis around the glands. Chronic endometritis which appeared histologically as a diffuse infiltration of mononuclear inflammatory cells in the endometrium; in some cases these cells aggregated to form follicles.

Kadu and Kaikini (1988) identified seven cases of endometritis out of 1057 caprine genitalia examined. Singh and Rajya (1977) reported 1.53 per cent incidence of endometritis in goats and based on the degree and type of inflammatory changes categorised as the acute, subacute and chronic endometritis. Histologically, the epithelium was desquamated along with the presence of focal areas of necrosis and hydropic degeneration. Sharma (1980) classified endometritis as suppurative and non-suppurative endometritis which included the cases of acute, subacute and chronic endometritis in sheep and goats.

2.1.3.4 Cystic endometrial hyperplasia

Cystic endometrial hyperplasia is a progressive and pathological endometrial expansion caused by an increase in the size and number of endometrial glands (Feldman and Nelson 1996). It can lead to permanent infertility in domestic animals by preventing implantation or fertilization (Agnew *et al.* 2003).

In a study on female genital tract of 3431 sheep and 5404 goats, cystic endometrial hyperplasia was observed in nonpregnant uteri of 16 sheep and 8 goats (Chand and Chauhan 1975).

Alosta *et al.* (1998) identified two cases of cystic endometrial hyperplasia out of 870 ewe genitalia examined. This condition has been reported commonly associated with subterranean clover grazing in Australia (Barrett *et al.* 1961). Bennet *et al.* (1946) also reported a severe progressive infertility problem in ewes commonly known as Clover's diseases in ewes grazing on subterranean pasture in Australia. Cystic endometrial hyperplasia may lead to further uterine disorders and other reproductive tract abnormalities (Adams 1975).

Dawood (2010) observed 2.3 per cent cases of endometrial hyperplasia in ewes. In two of five cases, lesions were found in both horns and other three cases showed non-cystic irregular thickening of the endometrium. The author also reported that cystic endometrial hyperplasia was associated with pyometra in two cases suggesting a high probability of exposure to exogenous phyto-estrogens in these cases.

2.1.3.5 Foetal abnormalities

Embryonic or fetal death may result in resorption, mummification, maceration, or abortion. Foetal maceration is the disintegration of the dead foetus into parts by autolysis following bacterial invasion of the dead foetus in the uterus (Jones *et al.* 1997). Fetal maceration results when abortion or parturition fails to occur following fetal death and CL regression. On the other hand foetal mummification is the progressive dehydration of the dead foetus in absence of uterine infections, presence of a functional corpus luteum and a mature foetal skin that is capable of resisting autolysis (Kennedy and Miller 1993).

Fetal mummification in sheep was occasionally observed as affecting single ovine fetus or both twin foetuses. Mummified foetuses with one or more viable fetuses were observed frequently in swine, occasionally in dogs, cats, and horses (Roberts 1971).

Emady *et al.* (1975) recorded 17.9 per cent cases of fetal death or resorption out of 99 gravid ewe genitalia. Emady (1976) detected in one of the ovine specimen in which umbilical cord of fetus was twisted. Absence of the allantochorion in the non gravid horn of the uterus was also noted in two goat and one sheep specimens by Emady (1976). Smith *et al.* (1999) recorded three cases of mummified fetus out of 9970 culled ewes; in two cases the fetus was within the uterus but in third animal the fetus was in the vagina. Dawood (2010) detected mummified and macerated fetus (one case each) out of 214 ewe genitalia examined.

Nair and Raja (1972) detected only one case of fetal mummification in out of 1860 caprine genitalia examined. Markandeya *et al.* (1991) reported a case of fetal mummification in goat where one viable kid was born along with two mummified foetuses. Similar case was also identified by AI-Baggal *et al.* (1993) in which mummified fetus was present in left uterine horn and a normal fetus was located in the right horn. Doijode (1993) diagnosed a case of fetal mummification in which the fetus was like that of a dried chicken without any hair development.

2.1.3.6 Other uterine abnormalities

Moghaddam and Gooraninejad (2007) recorded two cases of uterine adhesions and one case of segmental aplasia of uterus out of 1042 genitalia of Awassi ewes investigated.

Long (1980) detected one case of uterine haematoma in which condition a subserosal, kidney shaped swelling was observed on the right uterine horn. Smith *et al.* (1999) diagnosed 29 cases of parametritis out of 9970 culled ewes and all these cases of parametritis had mesenteric adhesions while in some cases, adhesions to intestine and/or to the abdominal wall developed.

AI-Baggal *et al.* (1993) observed cysts and abscess in uterine wall (one case each) out of 606 genitalia of Iraqi ewes. Nair and Raja (1972) also reported parametritis and perimetritis (one case each) condition and one case of uterine rupture out of 1860 genitalia of goats.

2.1.4 Cervical abnormalities

Congenital malformations of the cervix result from dysgenesis of the paramesonephric ducts during embryonic development (Jones *et al.* 1997).

Cervicitis has generally been reported in association with vaginitis and/or endometritis (Mc Entee 1990) due to specific or non-specific post parturient infections. Cervicitis is not in itself an entity but as a single entity, cervicitis may occur as a sequel of poor artificial insemination or catheterisation techniques. Cervical rings prolapse may also be predisposed by repeated trauma and inflammation resulting from multiple parturitions (Jones *et al.* 1997). Cockcroft and Mc Innes (1998) reported a case of a leiomyoma of the cervix in a goat presented with abdominal straining.

Smith *et al.* (1999) observed bruising and swelling around the external os of the cervix in two culled and excessive tortuous cervical canal in four nulliparous ewes. Winter and Dobson (1992) detected a case of abscess in cervical wall and another case of abnormal cervix out of 133 culled ewes. Sudhkar *et al.* (2010) recorded 30 cases of kinked cervix out of 3004 genitalia of Deccani ewes.

Studies on female genital tract of 3431 sheep and 5404 goats revealed acute cervicitis in 2 sheep and one goat, chronic cervicitis in seven sheep and three goats and acute pericervicitis in one sheep (Chand and Chauhan 1978). Sharma (1980) reported cervicitis in 1.91 per cent cases in sheep and 0.62 per cent cases in goats.

2.1.5 Congenital anomalies

Congenital anomalies in female genital tract of sheep and goat are limited except for those pertaining to hermaphroditism. They result from faulty development of the mullerian ducts during embryogenesis and may also be associated with certain uterine abnormalities, especially when they occur in association with various forms of intersex (Jones *et al.* 1997). Intersexes are relatively common among goats especially dairy breeds

(Morrow 1986). The majority of intersex goats are male pseudohermaphrodite with a female karyotype (Mc Entee 1990).

Smith *et al.* (1998) recorded the incidence of congenital abnormalities of paramesonephric ducts, 2.6 per cent in culled and 7.4 per cent in nulliparous sheep. Uterus didelphus occurred in six sheep and 11 animals were intersex.

Singh and Rajya (1977) diagnosed seven cases of hermaphroditism in adult female goats. Five of these cases had well marked uterus, vagina, bladder and two had well developed testes on either side adhering to fallopian tube in place of ovaries. In remaining two cases ovotestis were found. Dennis (1979) found three cases of male pseudohermaphrodites. Smith *et al.* (1996) found the incidence of ovarian fusion as a developmental abnormality.

Uterus unicornis is a predominant congenital malformation that has been reported in ovine uterus and is characterized by congenital absence of one uterine horn (Smith *et al.* 1998). O'Shea *et al.* (1974) recorded normal estrous cycle in five ewes in which left uterine horn was congenitally absent. Uterus bicorpor bicollis (uterus didelphus) has been reported by Singh and Rajya (1977). In this case two external os instead of one were present with independent cervical canals.

Adenomyosis has been reported in two cases in sheep (Chand and Chauhan 1978). Sharma and Sharma (1986) reported one case of adenomyosis in sheep and four cases in goats out of 314 sheep and 647 goats examined for pathological abnormalities in female genital tract. The authors also reported bent cervix in one sheep and three goats.

2.2 Correlation between ovarian and uterine abnormalities

Regassa *et al.* (2009) recorded a direct strong association between uterine and ovarian abnormalities and observed that the prevalence of uterine abnormalities including hydro/mucometra, endometritis and pyometra was significantly higher in ewes with abnormal ovarian condition than in those with normal ovaries.

Prabhakaran and Raja (1972) observed that the tubo-ovarian adhesions associated with hydrosalpinx and hydrometra were frequent finding in goats, whereas tubo-ovarian adhesions were present in association with ovarian cysts in eleven goat genitalia (Singh and Rajya 1977).

2.3 Pregnancy

Many sheep and goats were slaughtered despite being pregnant. A very high proportion of abattoir sheep (57.5%) and goats (89%) specimens were pregnant (Emady 1976).

Varying incidence of pregnancy has been reported earlier in abattoir genitalia of sheep and goats. Alosta *et al.* (1998) recorded that 10 percent of the ewes examined were pregnant. Out of which, 73.6 per cent had single pregnancy and 26.4 per cent had twin pregnancy. Right horn pregnancy was observed in 60.9 per cent and left horn pregnancy in 39.1 per cent of cases in single pregnancy.

Some investigators have recorded higher number of pregnancies in abattoir sheep genitalia. Moghaddam and Gooraninejad (2007) detected that overall pregnancy was in 21.4 per cent of the tracts of ewes investigated. Dawood (2010), in their study on abattoir sheep genitalia reported that a high proportion of the ewes included in the study (78 of 292; 27 %) were pregnant; the highest proportion of pregnant animals were observed in December and January in Basra, Iraq.

Emady *et al.* (1975) identified 99 (4.7%) gravid genital tracts out of 2081 specimens of goats and recorded maximum pregnancy in January (17.8%). Out of these, 88 had single pregnancies and nine had twin pregnancies, while triplet lambs were observed in two specimens. Comparatively higher proportion (40.43%) of genitalia was detected pregnant (Al-Baggal *et al.* 1993) in Iraqi goats. Amongst the pregnant goat genitalia examined (Lyngset 1968b) 61.96 per cent represented single, 37.03 per cent twin and 1.01 per cent triplet pregnancies. Nair and Raja (1973) observed the evidence of embryonic loss in 18.48 per cent of goat genitalia examined. Basu *et al.* (1961) revealed an incidence of 4.0 per cent of ovum to fetal loss in caprines. Out of 74 pregnant goat genitalia examined, 59 per cent had their fetuses in the right horn and only 41 per cent in the left horn. Chungath and Sharma (1991) examined 103 gravid genitalia of goats, out of which 79.61 per cent carried single fetus and only 20.29 per cent contained doublets or triplets.

Al-Dahash and David (1977) reported 23.36 per cent incidence of gravid genitalia in bovine reproductive tract. Garcia (1988) observed 43.2 per cent pregnant specimens in Zebu cattle. Assey *et al.* (1998) recorded 54 per cent pregnancy in small East African Zebu cattle.

2.4 Trans-uterine migration

Trans-uterine migration is of importance in the reproductive efficiency of domestic ruminants as inequalities of ovarian function occur and all of the multiple ovulations in an individual animal may occur from one ovary. The migration of embryos within the uterus is of importance to the outcome of pregnancy as migration can result in greater efficiency in utilization of intrauterine space and failure to successfully complete trans-uterine migration may be a factor contributing to embryo mortality. When a fetus was located

contralateral to site of ovulation transuterine migration was considered to have occurred (Scanlon 1972).

The distance which the sheep embryo is transported through the genital tract varied widely in different ewes. The usual site of fetal development was in a uterine horn near the external bifurcation of the uterus. The embryo may attach itself in the horn on the side of its origin or it may be carried into the other horn via the body of uterus (Boyd *et al.* 1944). They suggested that trans-uterine migration was of frequent occurrence when double pregnancy resulted from two ovulations in a single ovary, but occurred rarely with single ovulations.

Scanlon (1972) evidenced 8 per cent transuterine migration in single ovulating ewes and 87.5 per cent migration was observed in twin pregnant ewes with two ovulations on one ovary. Similarly Moghaddam and Gooraninejad (2007) identified embryo migration in 9 per cent of gravid uteri of ewes; of which 4.9 per cent was right to left and 4 per cent left to right. Whereas, Alosta *et al.* (1998) observed embryonic transuterine migration in 12 percent of the single ovulating ewes and in all ewes pregnant with twins had double ovulations on one ovary. The direction of migration was observed 66.7 per cent from right to left and 33.3 per cent from left to right.

Earlier, many researchers reported the incidence of migration of embryos between 10 to 20 per cent in the sheep (Curson 1934; Cloete 1939; Casida *et al.* 1966).

Emady (1976) recorded transuterine migration in 74 ovine uteri out of a total of 578 gravid uteri; there were 34 migration from left horn to right horn and 40 from right horn to left horn. The author recorded that incidence of transuterine migration of the early embryo was more frequent in the goat where migration was observed to have occurred in 369 specimens (36.7 %) out of a total of 1005 gravid uteri; there were 168 from left to right horn and 202 from right to left horn. Similarly higher (32.06%) transuterine migration was reported in genitalia of goats, of which migration from right to left was 52.54 per cent and from left to right was 47.46 per cent. It was 67.80 per cent in singles and 32.20 per cent in twins (Kadu and Kaikini 1987).

Chungath and Sharma (1991) also detected a higher percentage (41.98%) of transuterine migration in goats. Nair and Raja (1973) observed the incidence of trans-uterine migration of ova to the extent of 37.35 per cent. The rate of migration was observed much higher (83.87%) in multiple ovulations from single ovary.

2.5 Ovarian activity

Knowledge of the breeding season is an important factor in flock management (Sefidbakht *et al.* 1978). Estrus and breeding activity vary greatly between tropical and subtropical areas (Hafez 1952). Some breeds can be bred throughout the year (El-Fouly *et al.* 1977; Mittal and Ghosh 1980) or they have a long breeding season (Amir and Volcani 1965). While some breeds have seasonal fluctuations in estrous activity (El-Fouly *et al.* 1977).

Unlike thoroughbred temperate breeds, tropical ewes can breed throughout the year (Hambolu *et al.* 1985; Mukasa-Mugerwa and Tekelye 1988). However, there is a body of evidence that, although indigenous sheep can cycle year-round, there is variation in the expression of estrus and duration of sexual cycles depending on a particular season (Mukasa-Mugerwa *et al.* 1993). This is because tropical rainfall patterns and fluctuation in ambient temperature can synchronize biological functions to the most favourable time of the year based on seasonal availability of feeds and water (Bronson 1985).

The major source of variation in ovarian activity in tropical ewes appears to be inadequate nutrition (Mukasa-Mugerwa and Zere 1991) and increased ambient temperature (Yenikoye *et al.* 1981). With the exception of studies in a few breeds (Mukasa-Mugerwa and Lahlou-Kassi 1995), many aspects of native sheep reproductive characteristics are not very well known.

Ovarian activity can be regarded as an indicator of seasonality both in sheep and goats. Various authors have documented that follicles were present throughout the year and even large follicles were seen during the months when ewes were normally anestrus and number of corpora lutea was less than 1 per cent (Long 1980; Scaramuzzi and Downing 1997). They also observed significant difference between right and left ovarian activity.

Hambolu *et al.* (1985) observed that ovarian activity in Yankasa sheep was year-round. Wheeler and Land (1977) recorded variation in estrus and ovarian activity of Finnish, Merino and Blackface ewes during different seasons however, the follicles were observed in each breed throughout the year. Restall (1992) also reported seasonal variation in reproductive activity in Australian goats.

Alosta *et al.* (1998) recorded the incidence of ovarian activity in 59.3 per cent of sheep genital tracts examined and also observed that the right ovary tended to be more active than left. Similarly, Moghaddam and Gooraninejad (2007) recorded ovarian activity in 69.6 per cent of ewes. The right ovary (40.3%) was more active than left (29.3%).

Earlier, Emady *et al.* (1975) also observed that right ovary was slightly more active than the left in ewes.

The presence of CL on an ovary may modify the pattern of growth and atresia of follicles of the same ovary (Rexroad and Casida 1975). In their study on pregnant ewes, they observed that though number of large follicles decreased between early and late pregnancy while the number of small follicles increased but the ovary with corpus luteum contained the greater number of large follicles.

Al-Gubory and Martinet (1987) observed the effect of the corpus luteum on ovarian follicular populations and growth in the ewes and reported that the presence of CL on the ovary increased the preantral follicle populations. Similarly, Dufour *et al.* (1972) also observed that in unilaterally ovulating non-treated ewes, follicular development was greater in the ovary that contained the CL.

Chapter 3

Materials and Methods

3.1 Experimental material

The sheep and goat genitalia were procured from abattoirs around Palampur from September 2010 to March 2012. The animals were purchased for slaughter from local shepherds as well as from different locations. The genitalia were procured irrespective of age, breed or reproductive status at the time of slaughter.

3.2. Collection and transport of genitalia

Whole of the genital tract of sheep and goats was collected in normal saline immediately after slaughter. It was washed with normal saline (0.9%) and transported to the laboratory in separate thermocol containers at 37°C and examined within 2 hours of slaughter.

3.3. Examination of genitalia

3.3.1 Gross abnormalities

Gross morphological examination of genitalia was carried out. Subsequently, they were incised along the longitudinal axis of cervix, uterine body and uterine horns. These genitalia were examined for normal physiological status or abnormality or disease condition and classified as normal, gravid or abnormal.

3.3.1.1 Ovary and oviduct

The detailed examination of ovary and oviduct was done to detect abnormalities or presence or absence of follicle and/or corpus luteum (CL).

Ovaries with follicles ≥ 10 mm diameter were considered cystic (Winter and Dobson 1992). Based on appearance the cysts were classified into follicular and luteinised cyst. Follicular cyst was more tense, thin walled (Plate M1). Follicles were distended with pale yellow fluid while luteinised cysts (Plate M2) were presented as thick walled follicles lined with connective tissue layer containing more amber or dark yellow fluid (Garcia 1988).

Then each tract was carefully examined for the presence of attachment between the ovaries and oviduct. Those adhesions involving about half the area of the ovary were considered as moderate and over three quarters ovary as complete ovaro-bursal adhesion (Plate M3). Those with minor adhesion at small areas were excluded because it was considered that ovulation could normally proceed in these cases (Regassa *et al.* 2009). Oviduct was examined for evidence of salpingitis, hydrosalpinx (Plate M4), pyosalpinx or

Photographs showing ovary and oviduct abnormalities

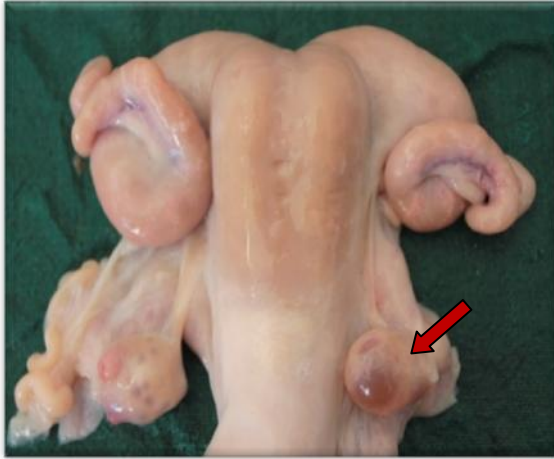

Plate M1. Ovary showing follicular cyst (arrow)

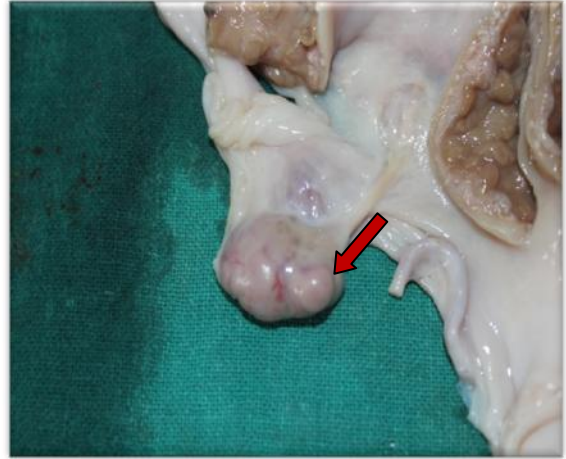


Plate M2. Ovary showing luteinised cyst (arrow)

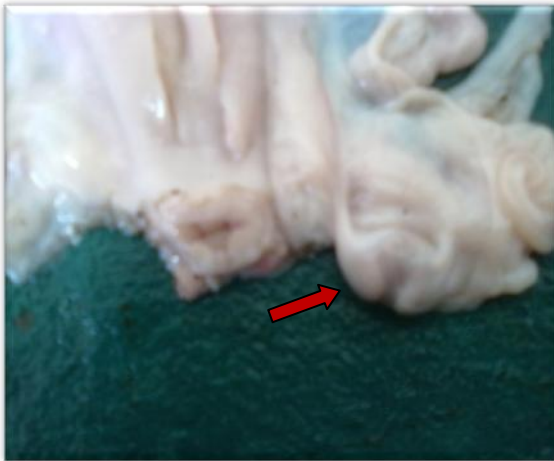

Plate M3. Ovarobursal adhesions (arrow)

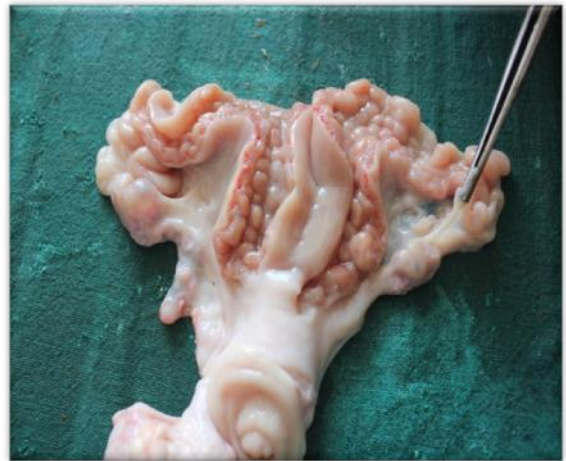

Plate M4. Hydrosalpinx

any other abnormality. The mesovarium and surrounding structures were also examined for miscellaneous abnormalities.

3.3.1.2 Uterus and cervix

The uterine horns were incised to record any pathological abnormality. Number of caruncles was recorded in normal, pathological and pregnant uterine horns.

Uterus was examined for evidence of accumulation of fluid in one or both horns. Depending upon the colour, consistency and viscosity of the uterine contents viz. watery, mucoid or pus mixed, the condition was classified as hydrometra, mucometra or pyometra, respectively. Cervix was also examined for abnormalities.

The detailed examination of pregnant uterus was done to record the number and location of fetus/es. Based on crown-rump (CR) length of the fetus, the age of fetus was estimated using formula:

$X=2.1(Y+17)$, where X is the developmental age in days and Y is crown-rump length in centimetres (Arthur *et al.* 2001).

Transuterine migration was considered to have occurred when a fetus was located in uterine horn contralateral to side of ovulation (Scanlon 1972). Incidence of fetal mummification was also recorded.

3.3.1.3 Histopathological study of uterine lesions

The representative tissue samples of approximately 0.5 cm thickness showing gross pathological lesions in the uterus were immediately collected in neutral buffered formalin (10%) for routine histopathological studies. After proper fixation, the tissues were trimmed, embedded in paraffin, sectioned at 3-5 μm and stained with routine Haematoxylin and Eosin stain (the conventional histological stain) according to Luna (1968). The bright-field images were acquired using a Olympus (BX40F-3, Tokyo, Japan) microscope equipped with Olympus CAMEDIA C-7070 color digital camera (Olympus Optical Co. Ltd., Tokyo, Japan).

3.4 Ovarian activity and seasonal variation

Sheep (534) and goat (742) ovaries were examined during the present investigation. The ovarian activity was assessed on the basis of presence or absence of corpora lutea (CL). The relative activity of right and left ovary was also compared.

The ovaries of 267 sheep and 371 goats were examined to record the seasonal variations in number of small and large follicles and CL. The seasons were classified as breeding or non-breeding. In sheep, the breeding season was considered from October to

March (Emady *et al.* 1975 and Arthur *et al.* 2001) whereas in goats it was considered from August to February (Arthur *et al.* 2001).

The size of the follicles on the ovary was measured by using vernier calliper. Visible follicles ≤ 3 mm in diameter were termed small and >3 mm were termed as large follicles (Alosta *et al.* 1998). The effect of presence or absence of corpus luteum on number of small and large follicles was also evaluated.

3.5 Statistical analysis

The data was statistically analyzed using analysis of variables (Student t-test) with SAS (Statistical Analysis Software), SAS version 9.2.

Chapter 4

Results and Discussion

The present study was designed to conduct abattoir survey on genital status, reproductive disorders and to monitor ovarian cyclic changes in small ruminants.

4.1 Genital status and reproductive abnormalities

Genitalia of sheep (267) and goats (371) were examined during the present investigation. Out of total sheep genitalia examined, 227 (85.02%) were physiologically normal and 40 (14.98%) had one or more genital abnormalities (Table 1). Examination of goat genitalia revealed that 279 (75.20%) were normal whereas 92 (24.80%) had genital abnormalities (Table 2).

Table 1. Genital status and prevalence of reproductive abnormalities in sheep abattoir genitalia (n=267)

Genital Status	Location	Disease Condition	Number (%)
Abnormal (n=40; 14.98%)	Ovary	Ovarian cysts	6 (2.24)
		Ovarobursal adhesions	7 (2.62)
	Total		13(4.86)
	Uterus	Endometritis	1 (0.37)
		Pyometra	5 (1.87)
		Hydrometra	8 (2.99)
		Mucometra	4 (1.49)
		Mummification	1 (0.37)
	Total		19 (7.11)
	Miscellaneous		08 (2.99)
Normal (n=227; 85.02)	Non pregnant		206 (77.15)
	Pregnant		21 (7.86)

Higher incidence of gross genital abnormalities in ewes was recorded earlier in UK (23.2%; Winter and Dobson 1992), Iran (25.8%; Moghaddam and Gooraninejad 2007), Ethiopia (22.2%; Regassa *et al.* 2009) and Iraq (25.7%; Dawood 2010 ;) whereas in goats, 52.9 per cent of abnormal genital tract were identified in Bangladesh (Rahman *et al.* 2008). A lower incidence of 3.3 per cent (Smith *et al.* 1998) and 6.52 per cent (Sudhakar *et al.* 2010) in ewes and 10.86 per cent (Reddy 1995) in goats has been reported earlier. The

differences in the incidence may be due to sample size, breed and the environmental variations in different places.

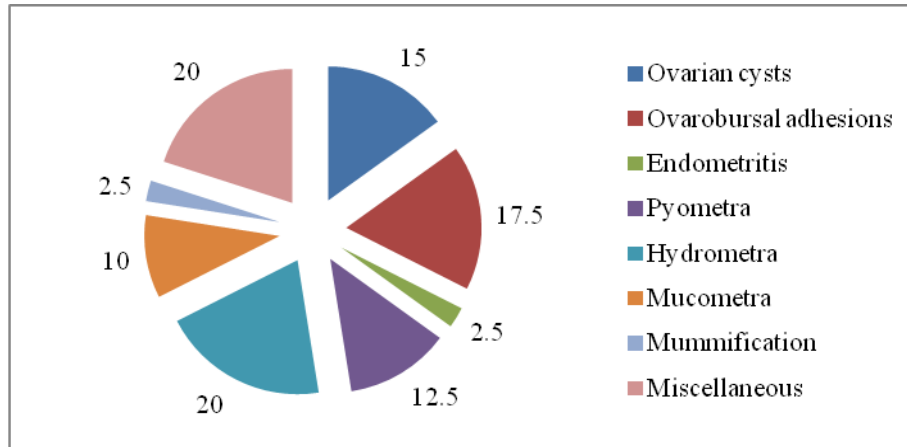
The normal genital status and the prevalence of various types of reproductive tract disorders of sheep and goats are summarised in table 1 and table 2, respectively.

4.1.1 Ovarian Disorders

Ovarian abnormalities were observed in 4.86 per cent of ewes (Table 1). Higher incidence (20.1%) of ovarian abnormalities in ewes has been recorded by Moghaddam and Gooraninejad (2007). Smith *et al.* (1999) observed that ovarian abnormalities were 3.36 per cent of the total acquired abnormalities in the ewes and 10.68 per cent of those in the nulliparous animals.

Follicular cysts were predicted in 2.24 per cent of ewes, of which 83.33 per cent (5/6) were on the right and 16.66 per cent (1/6) were on left ovary. Ovarobursal adhesions were observed in 2.62 per cent of ewes (Table 1); of which 57.14 per cent (4/7) were unilateral (2 each on either ovary) and 42.86 per cent (3/7) were bilateral. Severity of adhesions varied from a few fibrin strands between the ovary and mesosalpinx to complete adhesion involving the entire ovary and a part of surface of urinary bladder.

Figure 1. Distribution (%) of reproductive abnormalities of sheep (n=40)



Ovarian cysts constituted 15 per cent and ovarobursal adhesions 17.5 per cent of the total reproductive disorders detected in sheep abattoir genitalia (Figure 1).

Lower incidence (0.81%, 0.3% and 0.12%) of follicular cysts in ewes has been reported earlier by Alostia and co-workers (1998), Moghaddam and Gooraninejad (2007) and Sudhakar *et al.* (2010), respectively. However, higher incidence (4.3%) of ovarian cysts in Ethiopian highland ewes has also been recorded (Regassa *et al.* 2009). Although the significance of ovarian cysts in the ewe is not very well known it has been a common finding in different breeds of ewes. Rubianes *et al.* (1997) reported that inadequate

concentration of LH receptors in aged follicles could lead to formation of ovarian cysts in the ewes. Ovarian cysts in ewes were associated with high plasma progesterone concentrations (Alosta *et al.* 1998). Emergence of ovarian cysts in cows following long term exogenous progesterone treatment has also been reported (Novel *et al.* 2000). This could be either due to down regulation of uterine immunity and subsequent uterine infection (Lewis 2003a) or endocrine disturbance leading to ovulatory defect (Rubianes *et al.* 1997).

Similar incidence of ovarobursal adhesions, as observed in the present study, has been reported earlier (2.3%; Alosta *et al.* 1998 and 2.8%; Dawood 2010). Moghaddam and Gooraninejad (2007) recorded a higher incidence (11.5% of total tracts) of adhesions in Awassi ewes. Whereas lower incidence of 0.14 per cent, 1.2 per cent and 0.49 per cent of total tracts has also been reported by Emady *et al.* (1975), Long (1980) and Sudhakar *et al.* (2010), respectively. Ovarobursal adhesions may have resulted from ovulatory processes. Ovulation has been regarded as a physiological hazard that involves slight haemorrhage (Arthur *et al.* 1989) and inflammatory process (Epsey 1994). In addition, ovarobursal adhesions may physically prevent ovulation and lead to development of cysts on the ovary (Herenda 1987).

In goats, 10.24 per cent incidence of ovarian disorders was recorded. Ovarian cysts were identified in 7.54 per cent of goat genitalia examined during present investigation (Table 2). Majority (92.86%) of these were follicular cysts; of which 57.69 per cent (15/26) were on the right ovary, 38.46 per cent (10/26) on left ovary and 3.84 per cent (1/26) were present on both the ovaries. The luteal cysts were detected in two specimens (7.14%) only. The proportion of ovarian cysts amongst reproductive disorders was 30.43 per cent (Figure 2).

Higher incidence (20.67%) of cystic ovarian condition in goats has been documented by Moreira *et al.* (1993) whereas lower incidence (0.8% and 0.27 %) of ovarian cysts has been reported earlier (Al-Baggal *et al.* 1993 and Reddy 1995, respectively) in goats. Only one case of ovarian cyst was detected out of 1625 goat genitalia examined by Sharma (1973).

Ovarobursal adhesions were noticed in 2.69 per cent specimens; out of these, 80 per cent (8/10) were unilateral (3 on the right ovary and 5 on the left ovary) and 20 per cent (2/10) were bilateral (Table 2). Among the reproductive disorders, the proportion of ovarobursal adhesions was 10.86 per cent (Figure 2).

Table 2. Genital status and prevalence of reproductive abnormalities in goats abattoir genitalia (n=371)

Genital Status	Location	Disease Condition	Number (%)
Abnormal (n=92; 24.80%)	Ovary	Ovarian cysts	28 (7.54)
		Ovarobursal adhesions	10 (2.69)
	Total		38(10.24)
	Oviduct	Hydrosalpinx	1(0.27)
	Uterus	Endometritis	5 (1.34)
		Pyometra	5 (1.34)
		Hydrometra	13 (3.5)
		Mucometra	4 (1.07)
		Excessive haemorrhage	3 (0.8)
	Total		30 (8.08)
	Miscellaneous		23 (6.19)
Normal (n=279; 75.20)	Non pregnant		236 (63.61)
	Pregnant		43 (11.59)

Similar incidence (2.47%) of adhesions has been documented by Al-Baggal *et al.* (1993) in Iraqi goats. Lower incidence (0.31% of total tracts) of ovarobursal adhesions in goats has also been reported (Reddy 1995).

One (0.27%) case of hydrosalpinx was also recorded in which the oviduct was dilated due to accumulation of clear fluid (Table 2). Similar incidence (0.2% each) of hydrosalpinx was recorded by Reddy (1995) and Al-Baggal *et al.* (1993), respectively. Only two cases of bilateral hydrosalpinx were reported by Singh and Rajya (1977) out of 3971 goat genitalia examined.

Hydrosalpinx can arise in several ways; as a sequel to salpingitis, as a result of external pressure from cysts or possibly as a result of congenital abnormalities. Hydrosalpinx is a common incidental finding in women, in whom its significance is largely confined to impaired fertilization. In domestic animals, it is normally regarded as of pathological significance as an acquired lesion (Kennedy and Miller 1993) but in mice it often occurs in conjunction with hyperplasia of the epithelium of the uterine tube in response to chronically high oestrogen concentrations (King 1978).

4.1.2 Uterine abnormalities

The uterine abnormalities identified in sheep are summarized in table 1 and figure 1. Uterine abnormalities were observed in 7.11 per cent of ewes. Similar incidence of uterine abnormalities in Ethiopian highland ewes (8.9%) was recorded by Regassa *et al.* (2009) whereas lower incidence (1.2%) was recorded by Moghaddam and Gooraninejad (2007) in Awassi ewes.

Endometritis was diagnosed in 0.37 per cent of ewes. Pyometra (Plate 1) was observed in 1.87 per cent of ewes. The uteri were distended with pus to a variable degree. Corpus luteum was invariably associated with pyometra. Mucometra (Plate 2) was recorded in 1.49 per cent of ewes. The uterine lumen of both the horns was filled with clear mucoid fluid. Hydrometra (Plate 3) was diagnosed in 2.99 per cent of ewes. A clear watery fluid was accumulated either unilaterally in three (one in left and two in right uterine horns) or bilaterally in five ewe genitalia. Mummification was evidenced only in 0.37 per cent of ewes (Table 1).

Among the uterine abnormalities in sheep, highest incidence (20%) of hydrometra and lowest (2.5% each) of endometritis and mummification was recorded. Besides these, pyometra (12.5%) and mucometra (10%) were also observed. Thus the uterus was most commonly affected, accounting for 47.5 per cent (19/40) of the abnormalities, followed by the ovary (32.5%; 13/40) in ewes (Figure 1). While Moghaddam and Gooraninejad (2007) observed that the highest rate of abnormalities was in the ovaries, followed by ones in the oviduct and the uteri of abattoir Awassi ewes genitalia examined.

A low incidence of endometritis was recorded in the present investigation. Similar incidence (0.49%) of endometritis in ewes has been documented (Sudhakar *et al.* 2010). However, Smith *et al.* (1999) observed that endometritis occurred only in four (out of 9970 tracts examined) culled ewes. Contrarily higher incidence of endometritis (2.3 per cent; Alostha *et al.* 1998 and 24.8 per cent; Dawood 2010) has also been reported.

Endometritis is a superficial inflammation of the endometrium, extending no deeper than the stratum spongiosum (Bondurant 1999). Infection of genital tract can be specific or non specific with the latter being a more important etiological factor. Microbes associated with endometritis usually arrive by the ascending route, either following natural service or more commonly parturition or abortion (Rebhun 1995). Endometritis occurred during luteal phase or postpartum (Dawood 2010) which may be because the uterine immune function was suppressed during the luteal phase in ewes and cattle (Ramadan and

others 1997; Lewis 2003b). The variation in the prevalence of endometritis may probably be due to differences in the management system under which the animals were maintained.

Similar incidence (1.9%) of pyometra in ewes, as in the present study, was recorded by Dawood (2010). Comparatively lower (0.2%) proportion of ewes had pyometra (Moghaddam and Gooraninejad 2007) whereas only one case of endometritis was detected out of 133 genitalia examined earlier (Winter and Dobson 1992). Pyometra may arise as a sequel to chronic endometritis (Arthur *et al.* 1989) or as a result of infection subsequent to mucometra (Winter and Dobson 1992).

Higher incidence (2.99%) of hydrometra was detected in the present investigation. Comparable incidence (4.13%) of hydrometra in ewes was observed by Winter and Dobson (1992) whereas (Moghaddam and Gooraninejad 2007) reported a lower incidence (0.3%) of hydrometra and it was a predominant uterine disorder in Awassi ewes. Smith *et al.* (1999) reported only 18 cases of hydrometra in 9970 culled and 62 cases (out of 23,536 tracts) in nulliparous sheep.

Many species, including horses (Allen 1988) and mice (Percy and Barthold 1993) have small amount of free fluid in the uterine lumen at various stages of the estrous cycle. In mice, hydrometra can be induced by administration of stilboestrol (Johnson 1987). It is therefore possible that hydrometra in nulliparous sheep may be an over-response to oestrogen stimulation, rather than an overtly pathological phenomenon (Smith *et al.* 1999).

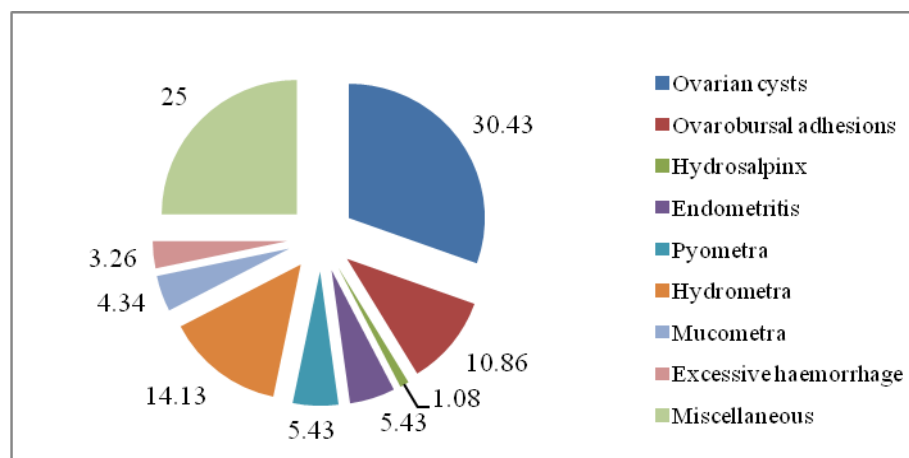
Lower incidence (0.2%) of mucometra in ewes, compared to present findings, was observed by Moghaddam and Gooraninejad (2007). Winter and Dobson (1992) detected five cases (out of 133 tracts) of mucometra in cull ewes. Mucometra was commonly recognised as a consequence of the chronic increase in the concentration of circulating steroid that occurred in cases of cystic ovarian diseases (Roberts 1971).

In present study, among 21 pregnancies only one fetus was mummified. A low incidence of mummified fetus (3 out of 9970 tracts) in cull ewes was reported by Smith *et al.* (1999). Fetal deaths could occur from mechanical injuries, nutritional imbalances, genetic defects and pathogens or any of the haemolytic infectious diseases (Francis 2009). Mummified fetuses may be macerated, expelled spontaneously before or after term or even retained indefinitely (Acland 2001). A sterile uterine environment, presence of viable (functional) corpora lutea in the ovaries and a mature fetal skin capable of resisting autolysis were prerequisites for the occurrence of fetal mummification (Kennedy and Miller 1993). No specific cause of mummification could be established in the present study.

The incidence and distribution of uterine abnormalities in goats is presented in table 2 and figure 2. In goats, 8.08 per cent cases of uterine abnormalities were recorded. Endometritis was recorded in 1.34 per cent of cases. Pyometra was identified in 1.34 per cent specimens of goats. The uterus was enlarged with a yellow purulent exudate filling the lumen. Bilateral mucometra was evidenced in 1.07 per cent specimens. Hydrometra was evident in 13 (3.5%) ewe genitalia involving either both the horns (10/13; 76.92%) or right (2/13; 15.38%) or left (1/13; 7.69%) horn of uterus. Excessive haemorrhage in uterine horns (Plate 4) was evidenced in 0.8 per cent of goats; in one case it was bilateral while in the other two either right or left horn was affected (Table 2).

Among the uterine abnormalities, hydrometra (14.13%) was most frequently detected. Other uterine abnormalities viz. endometritis (5.43%), pyometra (5.43%), mucometra (4.34%) and excessive haemorrhage of uterine horns (3.26%) were almost equally distributed in goat genitalia. In goats, the ovary was most commonly affected, accounting for 41.3 per cent (38/92) of the abnormalities, followed by the uterus (32.6%; 30/92) and oviduct (1.08%; 1/92) in goats (Figure 2).

Figure 2. Distribution (%) of reproductive abnormalities in goats (n=92)



Similar incidence (1.53%) of endometritis was observed by Singh and Rajya (1977) in goats. Higher incidence (3.21%) of endometritis in goats was reported by Reddy (1995). Lower incidence (0.66%) has been documented by Kadu and Kaikini (1988).

Although pyometra was detected only in five specimens, its incidence is slightly higher to that reported earlier (0.31%) in Iraqi (Al-Baggal *et al.* 1993) and (0.3%) non descript Indian (Reddy 1995) goats. Kadu and Kaikini (1988) detected only 4 (out of 1057) whereas Sharma (1973) recorded only one (out of 1625) genitalia affected with pyometra in goats. Al-Baggal *et al.* (1993) reported 0.8 per cent incidence of hydrometra in Iraqi goats. Only two genital specimens out of 2928 caprine genitalia (0.06%) of hydrometra

Photographs showing gross reproductive abnormalities

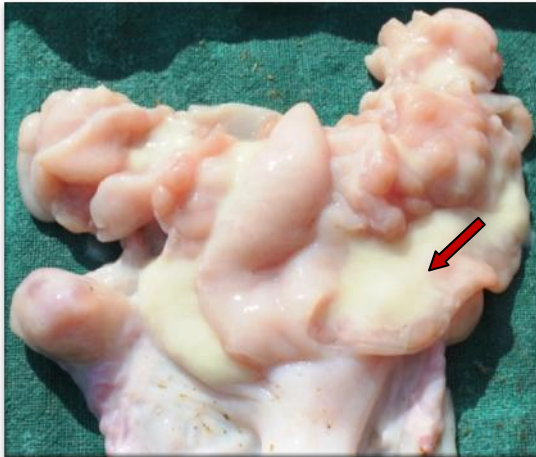


Plate 1. Uterus showing pyometra (arrow)

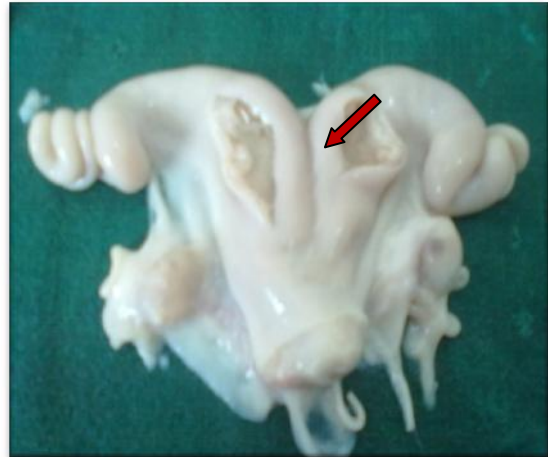

Plate 2. Uterus showing bilateral mucometra (arrow)

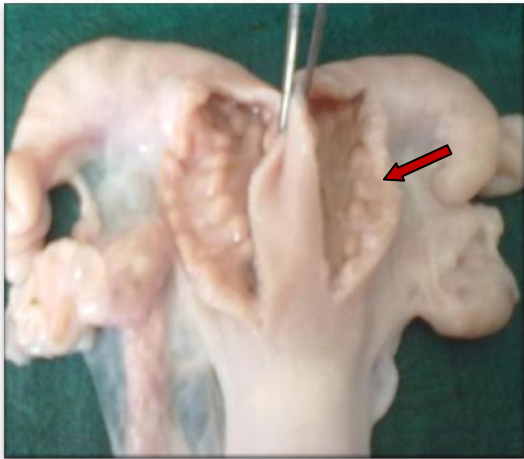


Plate 3. Uterus showing hydrometra (arrow)

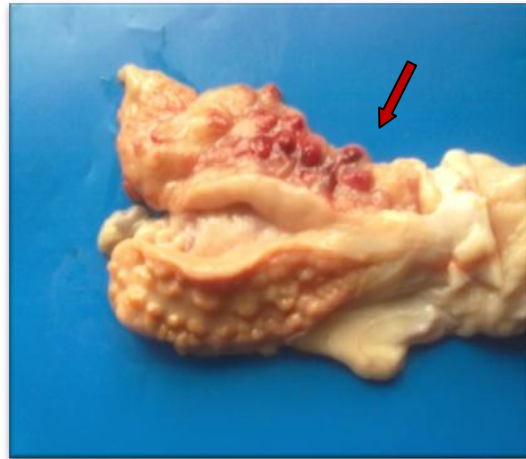


Plate 4. Uterus showing excessive haemorrhage in uterine horns (arrow)

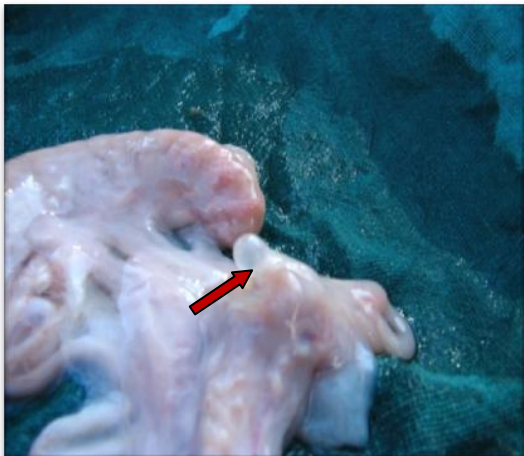

Plate 5. Parovarian cyst (arrow)

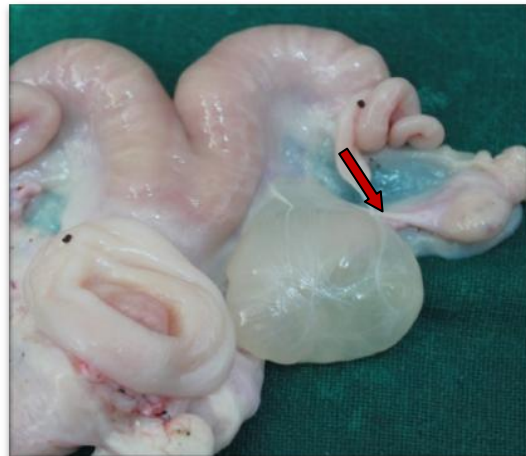

Plate 6. Parasitic cyst (arrow)

were reported by Reddy (1995). Lyngset (1986a) recorded 3 cases of hydrometra out of 1020 reproductive tract examined while Kadu and Kaikini (1988) could identify only one case of hydrometra out of 1050 goat genitalia examined. On the contrary, the incidence of hydrometra varied between 3.0 per cent to 20.8 per cent with a mean incidence of 9.0 per cent in three herds of dairy goats (Hessenlink 1993).

Hessenlink (1993) concluded that hydrometra is an important pathological condition of the uterus in dairy goats, whose aetiology is still unknown. However, it was considered that accumulation of fluid in the uterus was the result of the persistence of the luteal phase rather than its cause (Zarco *et al.* 1984). Taverne *et al.* (1988) investigated the luteotrophic role of prolactin in pseudopregnant goats. These data indicate that a change in prolactin secretion may possibly play a role in the development of a persistent corpus luteum and hydrometra.

4.1.2.1 Histopathological study

Histologically, the non-pregnant animals (sheep and goats) revealed the normal architecture of the uterus comprising uniform layer of surface epithelium, dense endometrial stroma and well distributed endometrial glands in the endometrium (Plate 7). However, gravid or pregnant animals revealed an increase in the size and number of endometrial glands, sparse stromal cell population and the increased cellularity of the surface epithelium (Plate 8).

The common pathological lesions in the uterus such as pyometra, hydrometra, mucometra and haemorrhages/haemosiderosis were in accordance with those reported grossly in the uterus of affected animals showing per cent gross lesions as depicted in table 1 and 2.

Pyometra: The uterus showing gross pathological lesion of pyometra revealed dilated and hyperplastic endothelial glands variably filled with purulent exudation. In acute cases, the predominant cell was neutrophils in the stroma as well as in the lumen of the endometrial glands (Plate 9). However, in case of sub-acute to chronic pyometra cases the surface epithelium of the uterus was variably hyperplastic or hypertropied in nature and a large number of lymphocytes, plasma cells and occasional macrophages were present and the areas of infiltrated inflammatory cell were noted frequently in the endometrial stroma (Plate 10).

Hydrometra: The uterus showing gross pathological lesion of hydrometra revealed variably dilated lumen with thin wall and flat in appearance and the variable sized areas of serous fluid accumulated in the endometrial stroma. The endometrial stroma was

comparatively reduced in size. The endometrium is comparatively thin and flat in appearance with lesser number and size of endometrial glands due to variable pressure atrophy caused by the fluid accumulation in the uterine lumen (Plate 11).

Mucometra: The uterus showing gross pathological lesion of mucometra revealed variably dilated lumen with thin wall and flat in appearance and there was an increase in the number and size of endometrial glands with increased epithelial activity. Excessive mucin or mucinous substances were present within and in-between the stromal cell population of the endometrium (Plate 12). The luminal epithelial cells were comparative taller, columnar, hypertrophied with vacuolated cytoplasm (Plate 13).

Endometrial haemosiderosis/haemorrhages: The uterus showing gross pathological lesion of haemorrhages revealed the focal areas of haemorrhages in the endometrium. The presence of focal areas of variable amount of granular, golden brown colour pigment in the endometrium due to earlier or old haemorrhages was also frequent in these cases. The pigment was present as a cluster either extra-cellularly or intracellularly as evident by the presence of haemosiderin laden macrophages in the endometrial stroma (Plate 14).

4.1.3 Miscellaneous abnormalities

Various other abnormalities were also detected in ewes and goats. Incidence of parovarian cysts (Plate 5) were observed in 1.5 per cent of the ewes. They were generally single but double and triplet cysts were also recorded. Cysts were ranging from 3mm to 8mm in diameter and most of them were located on the outer surface of uterine horns. The cysts were thin walled, tense and contained clear watery fluid. Three cases (1.12%) of parasitic cyst (*Cysticercus* spp.), (Plate 6) and one case (0.37%) of nodules on horns were also detected in ewes.

Similar incidence of parovarian cysts 1.2 per cent and 1.8 per cent was recorded by Long (1980) and Alostha *et al.* (1998) respectively. Higher incidence (7.6%) of parovarian cysts in ewes was observed by Moghaddam and Gooraninejad (2007). The *Cysticercus* cysts have also been detected earlier in sheep. Smith *et al.* (1999) reported presence of *Cysticercus tenuicollis* cyst in ten cull ewes (out of 9970 tracts) and 12 nulliparous ewes (out of 23,536 tracts).

While in goats, parovarian cysts were recorded in 3.77 per cent of specimens. Diameter of these cysts was in range between 2mm to 11mm and most of these were located on the mesovarium. Eight cases (2.16%) of parasitic cyst (*Cysticercus* spp.) and one case (0.27%) of nodules on horns were also detected in goats.

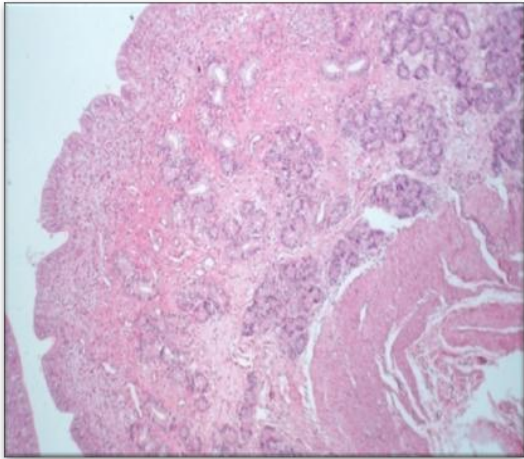


Plate 7. Photomicrograph of the uterus showing surface epithelium, endometrial stroma and well distributed endometrial glands. H&E x 33.

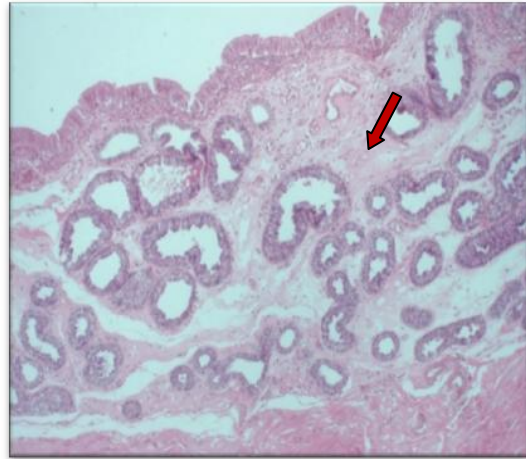


Plate 8. Photomicrograph of the uterus showing increased size and number of endometrial glands (arrow). H&E x 66.

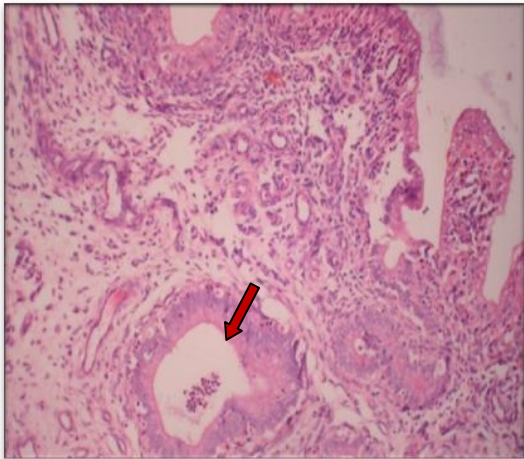


Plate 9. Photomicrograph of the uterus showing dilated and hyperplastic endometrial glands filled with pus (arrow head). H&E x 66

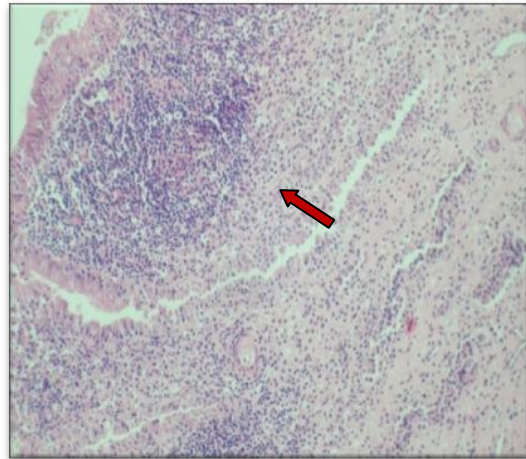


Plate 10. Photomicrograph of the uterus showing large number of lymphocyte and plasma cells in endometrial stroma (arrow head). H&E x 66.

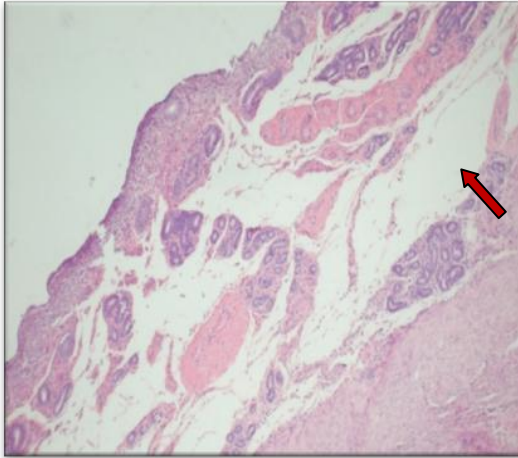


Plate 11. Photomicrograph of the uterus showing clear white areas of serous fluid accumulated in the endometrium (arrow head). H&E x 66

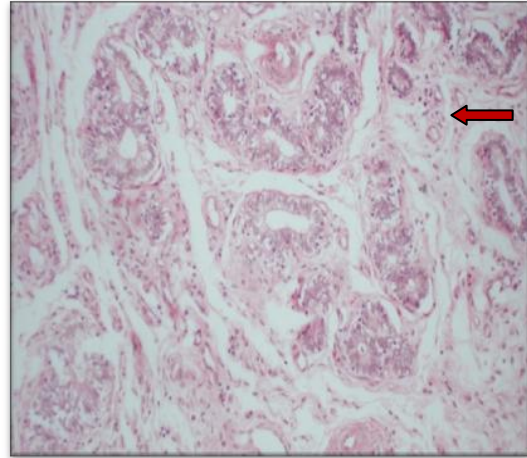


Plate 12. Photomicrograph of the uterus showing increased glandular epithelial activity and presence of mucinous substance (arrow). H&E x 132

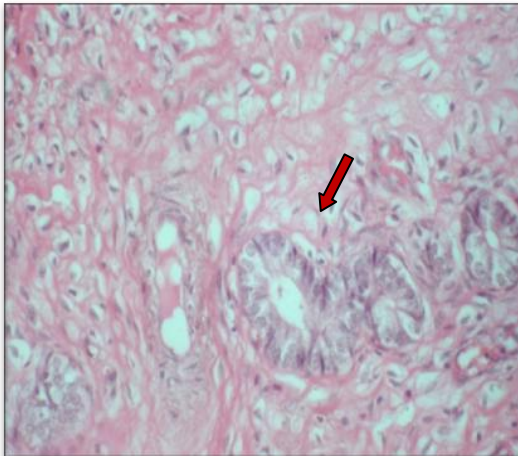


Plate 13. Photomicrograph of the uterus showing hypertrophied luminal epithelial cells with vacuolated cytoplasm (arrow). H&E 132

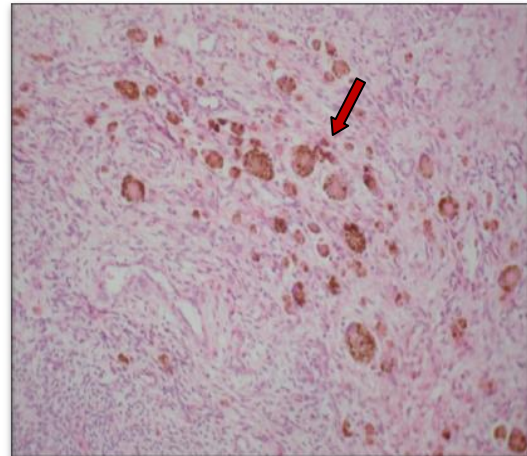


Plate 14. Photomicrograph of the uterus showing excessive golden brown colour pigment in the endometrium (arrow). H&E 66

Similar incidences (2.16%, 3.95% and 2.21%) of parovarian cysts were reported in goats by Singh and Rajya (1977), Al-Baggal *et al.* (1993) and Reddy (1995), respectively. Lower incidence (0.98%) of parovarian cysts in goats was recorded by Sharma (1973). Presence of *Cysticercus tenuicollis* infection (4 cases out of 606 tracts) in genitalia of goats has been noticed earlier also by Al-Baggal *et al.* (1993).

4.2 Correlation between ovarian and uterine abnormalities

The uterine and ovarian abnormalities co-existed only in a few abattoir sheep or goat genitalia. Ovarobursal adhesions were associated with mucometra or pyometra (one specimen each) in ewes while in goats they existed along with endometritis in one specimen only. In two goats, hydrometra was present along with either follicular or luteal cyst. Regassa *et al.* (2009) reported that prevalence of uterine abnormalities including hydro/mucometra, endometritis and pyometra was significantly higher in ewes with abnormal ovarian conditions than in those with normal ovaries.

In cows, disruption of ovarian function as a result of uterine infection has been reported (Sheldon and Dobson 2004). The effect of uterine infection on ovarian function could be due to the role of endotoxins, which are the components of the Gram-negative bacteria cell wall (Mateus *et al.* 2003). In cows (Peter *et al.* 1989) and ewes (Karsch *et al.* 2002) infusion of *Escherichia coli* endotoxin into uterine lumen prevents preovulatory LH surge and ovulation, causing persistent ovarian cysts. The effect of uterine infection and subsequent immune response may directly (Sheldon and Dobson 2004) be exerted on the ovary or indirectly (Karsch *et al.* 2002) by suppression of LH secretion from the pituitary. The uterine infections might be because of ovarobursal adhesions in sheep and goats. The hydrometra in goats might have developed as a result of follicular cysts (Roberts 1971) or persistence of luteal phase (Zarco *et al.* 1984) due to concomitant presence of a luteal cyst.

4.3 Pregnancy status and transuterine migration of embryos

The uteri of sheep and goat genitalia were examined for pregnancy. Distribution of pregnancies in sheep and goats is presented in table 3; figure 3.

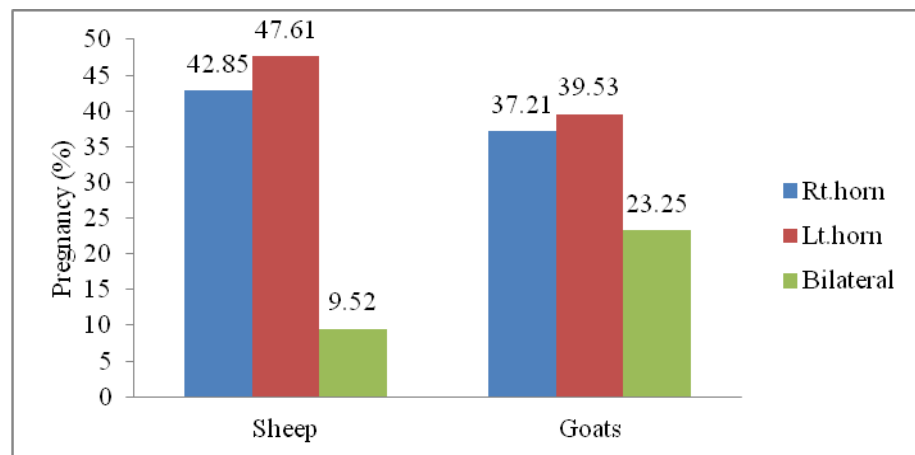
Of the ewe genitalia examined, 7.86 per cent were pregnant. Only one fetus was present in majority (90.48%) of genitalia. Comparative incidence of right and left horn pregnancies was 42.85 per cent and 47.61 per cent, respectively. Bilateral pregnancy was recorded in two (9.52%) ewe genitalia; in one case, both the CL were present on right ovary whereas the other had one CL in each ovary. The incidence of left horn pregnancy was higher than that of right. The CR length of 17 fetuses was measured to estimate the approximate age of fetus.

Table 3. Distribution of pregnancies and transuterine migration in sheep and goats

Gravid genitalia	Pregnant uterine horn			Transuterine migration	
	Right	Left	Bilateral	Right to left	Left to right
Sheep (n=21)	9 (42.85%)	10 (47.61%)	2 (9.52%)	3 (14.28%)	0
Goats (n=43)	16 (37.21%)	17 (39.53%)	10 (23.25%)	9 (20.93%)	7 (16.27%)

Most of the fetuses (16; 94.12%) were estimated to be less than two months old (range 38 to 54 days) and only one (5.88%) had gestational age of 72 days. Out of the 21 gravid uteri, four (19.05%) had early pregnancy.

Approximately similar incidence (10%) of pregnancy in ewes was reported by Alosta *et al.* (1998). The author recorded 73.6 per cent single and 26.4 per cent twin pregnancy in ewes. Comparatively, higher incidence (21.4% and 55.2%) of pregnancy in slaughtered ewes was recorded by Moghaddam and Gooraninejad (2007) and Regassa *et al.* (2007), respectively. Contrarily, lower incidence (3.37%) in cull ewes has also been documented (Smith *et al.* 1999).

Figure 3. Distribution of pregnancies in uterine horns of sheep (n=21) and goats (n=43)

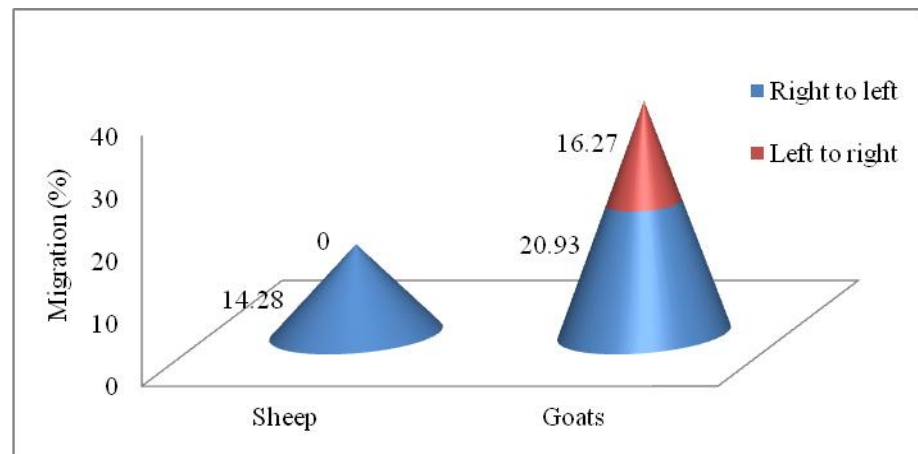
Pregnancy was recorded in 11.59 per cent of the abattoir goat genitalia. Single pregnancy was observed in 76.75 per cent while bilateral pregnancies were observed in 23.25 per cent of the genitalia examined. The incidence of left horn pregnancy (39.53%) was higher than right (37.21%) and bilateral (23.25%) horn pregnancy (Figure 3). A very high (31.7%, 40.43% and 17.88%) incidence of pregnancy in abattoir genitalia of goats was observed earlier (Wilson and Traore 1988; Al-Baggal *et al.* 1993, Bokko 2011 respectively).

Among the 43 pregnant goats, it was possible to estimate CR length of 32 fetuses only as others were of very early gestation. Majority (87.5%) were around 2 months pregnant (range; 36-80 days). Only one fetus had almost completed the gestation period.

In present study, among the sheep and goats slaughtered 7.86 per cent and 11.59 per cent respectively, were pregnant. In majority, the fetal age was approximately 2 months or less. When applied on a nationwide basis, this rate of slaughter of pregnant sheep and goat's population represents a considerable loss in terms of production and income. The routine use of ultrasound scanning as a component of flock health programs could avert such losses, especially since flock owners appear to be unaware of them.

The presence of CL on ovary contralateral to presence of fetus was considered indication of transuterine migration of embryo. Such a discrepancy was identified in 14.28 per cent of the ewes. The direction of migration was from right to left (Figure 4).

Figure 4. Incidence (%) of transuterine migration in sheep (n=21) and goats (n=43)



Approximately similar incidence (12.8% and 11.5%) of transuterine migration in sheep has been documented earlier (Emady 1976; Wilson and Traore 1988, respectively). Contrarily, Emady (1976) reported that out of 74 pregnant ovine uteri; there were 34 migrations from left horn to right and 40 from right horn to left horn. A lower incidence (8.9%) of transuterine migration (4.9% ; right to left and 4%; left to right) in ewes has also been recorded (Moghaddam and Gooraninejad 2007).

Alosta *et al.* (1998) recorded that embryonic migration was observed in 12 per cent of the single ovulating ewes (66.7% right to left and 33.3% left to right) and in all ewes pregnant with twins had double ovulations on one ovary.

Higher incidence (37.2%) of transuterine migration was evidenced in goats. In 20.93 per cent animals the corpus luteum was in the right ovary and the fetus was present

in the left horn whereas in 16.27 per cent cases, it was reverse, in that the corpus luteum was in left ovary and fetus was in the right horn (Figure 4).

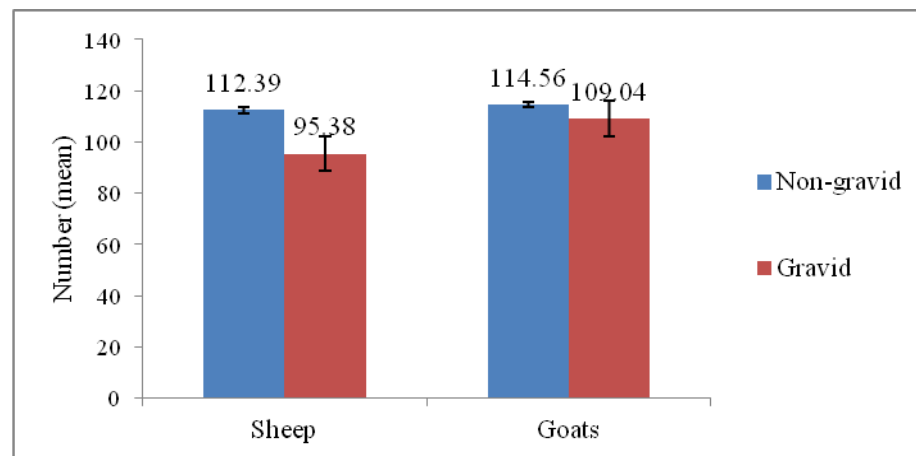
Similar incidence (36.7%) of migration (54.59%; right to left and 45.41%; left to right) in goats has been documented earlier (Emady 1976). Reddy (1995) also recorded a comparable (30.30%) incidence of transuterine migration in goats. A lower incidence (18.9%) has also been recorded in goats with almost equal proportions of left to right and right to left horn migrations (Wilson and Traore 1988).

The transuterine migration is a well established phenomenon in sheep (Alosta *et al.* 1998) and goats (Emady 1976). Presumably, the migration in polytocous animals equalises the distribution of embryos within the uterus despite that the ovaries contribute unequally to total number of embryos (Scanlon 1972; Reimers *et al.* 1973) and hence is of immense significance in minimizing early embryonic losses.

4.4 Number of caruncles in non-gravid and gravid genitalia

The mean number of caruncles recorded in non-gravid and gravid genitalia of sheep and goats are presented in figure 5.

Figure 5. Distribution of caruncles in gravid and non- gravid uteri of sheep and goats



The average number of caruncles in non-gravid genitalia of ewes was 112.39 ± 1.26 as against 95.38 ± 4.09 in gravid genitalia. There was no variation in number of caruncles between right or left horn in either gravid or non-gravid uteri of sheep. Significantly higher ($p < 0.05$) number of caruncles were recorded in non-gravid than gravid sheep genitalia.

The mean number of caruncles in non-gravid genitalia of goats was 114.56 ± 0.94 as against 109.04 ± 2.75 in gravid genitalia. The data also depict that mean number of caruncles are significantly higher ($p < 0.05$) in non-gravid genitalia of goats.

Normally the number of caruncles may vary between 115-120 in non gravid (Morrow 1986) and 80-90 in gravid (Arthur *et al.* 1989) genitalia of sheep and goats.

4.5 Ovarian activity and seasonal variation

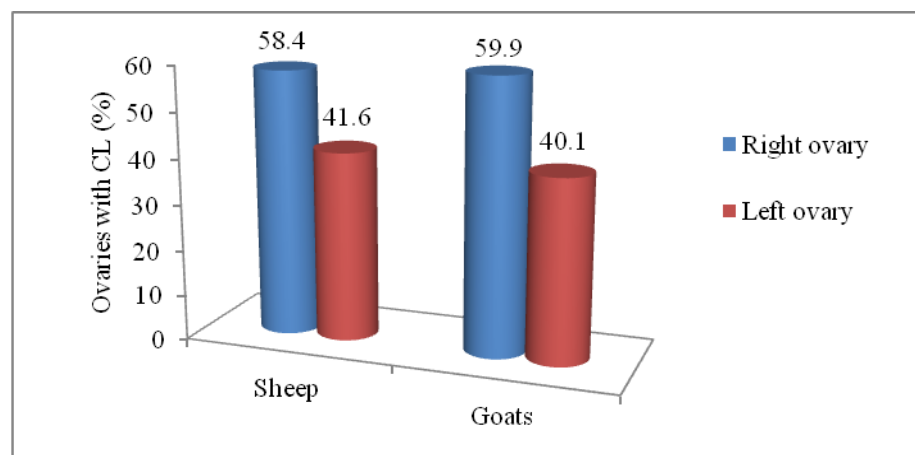
4.5.1 Ovarian activity

Measurements of size of ovaries and observations on their structures can be used to characterise ovarian reproductive status. The activity of the ovaries was assessed by the presence or absence of corpora lutea. The presence of a corpus luteum in the ovary of non-pregnant animals was taken as indication of estrous cyclicity.

A total of 534 ovaries of ewes were examined. Corpora lutea (indicating ovarian activity) were evident in 125 (23.4%) of the ovaries. Out of these ovulations, 58.4 per cent were evident in right whereas 41.6 per cent in left ovary indicating that the right ovary was more active in sheep (Figure 6).

Earlier, higher incidence (59.3% and 69.6%) of ovarian activity was observed by Alostha *et al.* (1998) and Moghaddam and Gooraninejad (2007), respectively, in ewes.

Figure 6. Relative activity of right and left ovary in sheep (n=125) and goats (n=202)



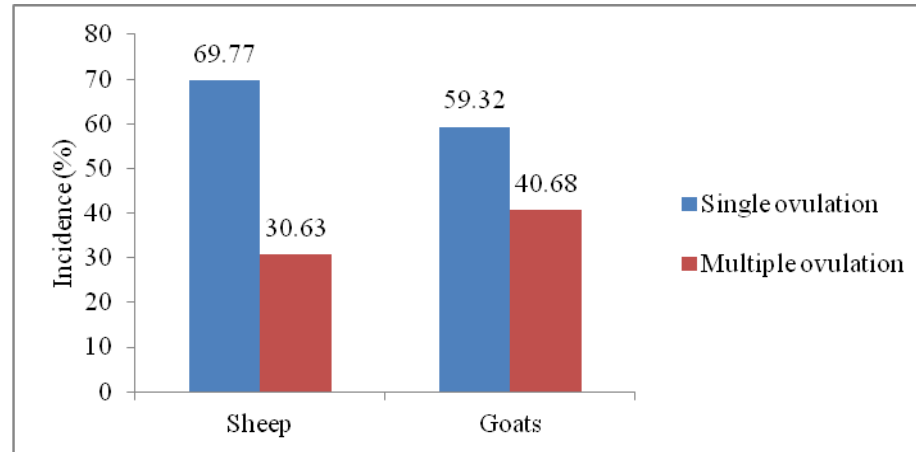
In the present study, the right ovary was more active compared to left. Earlier many researchers (Casida *et al.* 1966; Emady *et al.* 1975; Scaramuzzi and Downing 1997; Regassa *et al.* 2007) also observed more activity on right ovary in ewes. It is possible that local paracrine/autocrine factors and differences in vasculature and lymphatic drainage of the right and left ovaries contributed to the observed variation in activity (Alostha *et al.* 1998).

These ovulations (n=125) had occurred in ovaries of 111 genitalia as single or multiple. Single ovulations (on either of the ovaries) were recorded in 69.77 per cent whereas multiple in 30.63 per cent of genitalia of ewes (Figure 7).

Earlier, Casida *et al.* (1966) has documented 51.92 per cent single ovulation and 48.08 per cent multiple ovulation in ewes. Incidence of single or multiple ovulations may

vary between breeds (Casida *et al.* 1966; Regassa *et al.* 2007) and is also dependent upon nutrition provided before breeding season (Sabra and Hassan 2008).

Figure 7. Incidence of single and multiple ovulation in sheep (n=111) and goats (n=177)



Hill sheep in the UK generally have one lamb, but if they were transferred to lowland pastures where herbage was rich (before onset of breeding season), twins became common. Age was another factor influencing the incidence of twinning. Primiparous ewes were much less likely to have twins than pluriparous ones. Ewes of the Border Leicester and Lleyn breeds were the most prolific of British sheep and commonly bear triplets. The Finnish Landrace and Cambridge breeds normally produced two to four lambs per pregnancy (Arthur *et al.* 1989).

In the present study, most of sheep slaughtered were bought from local shepherds. Usually these shepherds maintain Gaddi and its crossbred ewes. The incidence of multiple ovulations has not been well documented in these breed of sheep.

A total of 742 ovaries of goats were examined. Ovarian activity was observed in 202 (27.22%) goat ovaries; out of which 121 (59.90%) ovulations had occurred in the right ovary and 81 (40.10%) on the left ovary (Figure 6). Thus the right ovary was more active than left in goats as well. These ovulations had occurred on 177 genitalia of goats with some (59.32%) exhibiting single whereas others (40.68%) showing multiple ovulations (Figure 7).

The present findings, that right ovary was more active in goat, was in consonance with the observations of earlier research workers (Singh *et al.* 1974; Rahman *et al.* 1977; Camp *et al.* 1983; Wilson and Traore 1988; Sarkar 1993; Alwan *et al.* 1993) who also recorded more activity on right than the left ovary in goats. The factors as discussed in sheep may be the plausible explanation.

Quite higher incidence of multiple ovulations (40.68%) has been recorded in the present investigation. Earlier, some workers (Otchere and Nimo 1976; Alwan *et al.* 1993) also observed high incidence of twinning in goats. The rate of twinning was associated with breed of dam and breed of sire (Bondoc *et al.* 2004). Roberts (1971) documented that the incidence of twinning was greatly influenced by the nutritional status of the animal at the time of ovulation as well as breed in sheep and goats. The goats slaughtered, in the present study, were either bought from local farmers or were transported from plains. The nutritional status, breed and parity of these goats might have influenced the incidence of twinning.

4.5.2 Seasonal variations

Total number of follicles (small and large) and corpora lutea were counted to compare ovarian activity during the breeding and non breeding season, in all the reproductive tracts of sheep and goats.

The seasonal variation recorded in number of small follicles (≤ 3 mm diameter), large follicles (> 3 mm diameter) and CL on the ewe ovaries has been tabulated (Table 4).

Table 4. Mean distribution of follicles and CL in sheep ovaries during breeding and non breeding seasons (n=267)

Season	Total no. of follicles/genitalia (Mean \pm SE)		Total no. of CL/genitalia (Mean \pm SE)
	Small (≤ 3 mm)	Large(> 3 mm)	
Breeding season(n=173)	17.40 \pm 0.79	1.86 \pm 0.12	0.64 \pm 0.06 ^a
Non breeding season(n=94)	16.58 \pm 1.09	1.71 \pm 0.25	0.39 \pm 0.06 ^b

Values with different superscripts within columns differ significantly (P<0.05)

There was no variation in mean number of small follicles present on ovaries during breeding or non-breeding seasons (17.40 \pm 0.79 Vs 16.58 \pm 1.09, respectively) in ewes. The mean number of large follicles was also comparable between seasons. However, significantly higher (p<0.05) number of corpora lutea were present during breeding (0.64 \pm 0.06) than non-breeding (0.39 \pm 0.06) season. Thus a seasonal variation in ovarian activity was recorded in the present study.

Similar to these observations, Brand and DeJong (1973) revealed that the number of small and medium size follicles was greater in anestrus ewes than in ewes during the luteal phase of estrous cycle. The mean number of large ovarian follicles (> 5 mm diameter) per wave appeared to decrease from mid breeding season to the transition to anestrus (Bartelewski *et al.* 1999). The rise of number of small and medium antral follicles, as

anestrus advanced reflected a change in ovarian follicular responsiveness to gonadotrophins (Bartelewski *et al.* 1998)

However, wide variation exists in seasonality pattern of ewes. Emady (1976) recorded that the onset of major ovarian activity was during October with peak activity during December; a time of the year when under most systems of sheep husbandry the majority of would be pregnant. Later, Wilson and Traore (1988) reported some increment in reproductive activity in April but most animals appeared to conceive during August and September. Sahni and Roy (1967) reported that the Indian native sheep were non seasonal in sexual activity and that in the tropics, ewes showed estrus throughout the year (due to equal light and dark ratio). Earlier, some workers (Emady 1976; Hambolu *et al.* 1985) also observed year-round estrus in tropical sheep.

Many factors influence the seasonality in sheep. The daily photoperiod has long been identified as the determinant factor of seasonal breeding while other factors such as environmental temperature, nutrition, behaviour, lambing date and lactation period exerts a modulator effect (Roja and Bryant 2003).

Likewise , in goat ovaries also breeding and non breeding seasons were compared by presence of follicles and corpus luteum. The average number of small follicles (≤ 3 mm diameter), large follicles (>3 mm diameter) and CL during breeding and non breeding seasons, on the goat ovaries has been tabulated (Table 5).

Table 5. Mean distribution of follicles and CL in goat ovaries during breeding and non breeding seasons (n=371)

Season	Total no. of follicles/genitalia (Mean \pm SE)		Total no. of CL/genitalia (Mean \pm SE)
	Small (≤ 3 mm)	Large(>3 mm)	
Breeding season(n=248)	19.16 \pm 0.68	2.56 \pm 0.10 ^a	0.76 \pm 0.05 ^a
Non breeding season(n=123)	19.80 \pm 0.89	1.72 \pm 0.15 ^b	0.55 \pm 0.07 ^b

Values with different superscripts within columns differ significantly (P<0.05)

The mean number of small follicles recorded on goat ovaries during breeding and non-breeding seasons (19.1+6 \pm 0.68 Vs 19.8 \pm 0.89, respectively) was comparable. The mean number of large follicles available were significantly higher (p<0.05) during breeding (2.56 \pm 0.10) than in non-breeding (1.72 \pm 0.15) season. Simultaneously, the number of CL present during breeding (0.76 \pm 0.05) season were significantly higher (p<0.05) than that of non-breeding (0.55 \pm 0.07) season.

In goats, Wilson and Traore (1988) indicated an increase in ovarian activity in April compared to a period of relative inactivity in January and especially in February and March with a rapid upsurge in conception during May to July.

Goats in tropical and subtropical environments showed seasonal reproductive patterns that relate more to variations in rainfall, available nutrition and temperature than to the day length (Devendra and Burns 1983; Thimonier and Chemineau 1988).

Hambolu and Ojq (1985) also observed that ovarian activity occurred throughout the year in Sokoto red goats in Nigeria but highest activity was observed from June to September (perhaps due to the availability of pasture during this time) and from January to March (temperature increase might be a factor). Hambolu (1982) observed a positive correlation between ovarian parameters and temperature.

The breeding and non-breeding seasons were classified as per Arthur *et al.* (1989). However, further studies are needed to establish seasonal pattern based on ovarian activity exhibiting in goats in Himachal Pradesh.

Table 6. Mean number of follicles in ovaries with and without CL in sheep (n=534)

Group	No. of Follicles/ovary Mean±SE		
	Small (≤ 3mm)	Large(>3mm)	Total
Ovaries with CL(n=125)	8.82±0.52	1.19±0.10 ^a	10.01±0.53 ^a
Ovaries without CL(n=409)	8.47±0.28	0.81±0.06 ^b	9.29±0.28 ^b

Values with different superscripts within columns differ significantly (P<0.05)

In sheep, the mean number of small follicles was comparable between ovaries with or without CL. The mean number of large follicles were significantly higher (p<0.05) (1.19±0.10 Vs 0.81±0.06) in ovaries having corpora lutea (Table 6).

Similar observations were recorded earlier by Dufour *et al.* (1972) who noted that the ovary that contained the corpus luteum had greater follicular development than the ovary that had no corpus luteum. However, Al-Gubory and Martinet (1987) observed that ovary with CL contained more preantral follicles than the ovaries without CL and concluded that presence of CL on the ovary increased the preantral follicle population and further growth to antral stage was restricted. The author hypothesized that this resulted from inadequate pituitary gonadotrophin secretion.

Positive association between number of corpora lutea and the number or size of follicles on an ovary during the luteal phase of the estrus cycle (Clark *et al.* 1971; Dufour *et al.* 1972) might be because there was a common stimulation of both ovulatory and non-

ovulatory follicles at the preceding estrus and corpora lutea may not have a direct effect on the follicles (Rexroad and Cassida 1975).

Table 7. Mean number of follicles in ovaries with and without CL in goats (n=742)

Group	No. of Follicles/ovary Mean±SE		
	Small (≤ 3mm)	Large(>3mm)	Total
Ovaries with CL (n=202)	9.98±0.43	1.15±0.08	11.13±0.43
Ovaries without CL (n=540)	9.57±0.24	1.14±0.04	10.72±0.25

In goats, the mean number of small and large follicles did not differ significantly (1.15±0.08 Vs 1.14±0.04, respectively) between the ovaries with or without CL (Table 7).

Earlier, Schwarz (2003) reported that CL stimulated folliculogenesis within the same ovary during caprine estrous cycle. On the contrary, in the pregnant goats, the mean number of growing and large follicles on CL free ovaries was significantly higher than that of CL bearing ovaries (Schwarz and Wierzchos 2010). The residual local inhibition of follicular development on CL bearing ovaries even during postpartum period has also been demonstrated in goats (Bartelewski *et al.* 1999).

Chapter 5

Summary and Conclusions

The present investigation was carried out with the objectives to conduct an abattoir survey on the normal genital status and reproductive disorders and to monitor ovarian cyclic changes in small ruminants.

Genitalia of sheep (n=267) and goats (n=371) were procured from local abattoirs in and around Palampur, irrespective of age, breed or reproductive status, at the time of slaughter. The genital tract was collected in normal saline (0.9%) and examined within 2 hours of collection. A detailed morphological examination (normal physiological status or any type of abnormality) of genitalia was carried out and classified as normal, gravid or abnormal. The genitalia were incised along the longitudinal axis of cervix, uterine body and uterine horns.

The ovaries were examined for presence of follicles, corpus luteum (CL) or any other abnormal structure. Based upon appearance, cysts on ovaries (≥ 10 mm diameter) were classified into follicular and luteal cyst. Then each tract was carefully examined for presence of ovarobursal adhesions, salpingitis, hydrosalpinx, pyosalpinx or any other abnormality. Uterus was examined to record its normal status, abnormalities, discharge and for presence of fetus. Number and location of fetus was recorded and approximate age of fetus was calculated with known Crown Rump (CR) length. Occurrence of transuterine migration was also recorded. Histopathology of some representative samples showing uterine lesions was done. Ovarian activity was assessed on the basis of presence or absence of CL. The relative activity of right and left ovary was also compared. Variations in number of small (≤ 3 mm diameter) and large follicles (> 3 mm diameter) and CL during breeding and non-breeding seasons were recorded.

Out of total sheep genitalia examined, 227 (85.02%) were physiologically normal and 40 (14.98%) had one or more genital abnormalities. Examination of goat genitalia revealed that 279 (75.20%) were normal whereas 92 (24.80%) had genital abnormalities.

Ovarian abnormalities were observed in 4.86% (13/267) of ewes. Follicular cysts were predicted in 2.24 per cent (6/267) of ewes, of which 83.33 per cent (5/6) were on the right and 0.37 per cent (1/6) were on left ovary. Ovarobursal adhesions were observed in 2.62 per cent of ewes; out of which 57.14 per cent were unilateral (2 on the right and 2 on the left) and 42.85 per cent were bilateral. Severity of adhesions varied from a few fibrin strands between the ovary and mesosalpinx to complete adhesion involving the entire

ovary and part of urinary bladder surface. Ovarian cysts constituted 15 per cent (6/40) whereas ovarobursal adhesions were present on 17.5 per cent (7/40) of total affected tracts.

The incidence of ovarian disorders was recorded in 10.24 per cent (38/371) of goats. Follicular cysts were seen in 7 per cent (26/371) specimens of goat; of which 57.69 per cent (15/26) were on the right ovary, 38.46 per cent (10/26) on left ovary and 3.84 per cent (1/26) were on both ovaries. Ovarobursal adhesions were noticed in 2.69 per cent (10/371) specimens, of which 80 per cent (8/10) were unilateral (3 on the right ovary and 5 on the left ovary) and 20 per cent (2/10) were bilateral.

Of the total affected tracts examined (n=92), ovarian cysts were diagnosed in 28 (30.43%) whereas ovarobursal adhesions were present on 10 (10.86 %) genitalia. Only one case of hydrosalpinx (1.08%) was recorded among the total affected tracts.

Uterine abnormalities were observed in 7.11per cent (19/267) of ewes, which included endometritis (0.37%), pyometra (1.87%), mucometra (1.49%), hydrometra (2.99%) and mummification (0.37%). In pyometra, the uteri were distended with pus to a variable degree. There was always a corpus luteum which appeared to be persistent. In specimens diagnosed with mucometra, the uterine wall was thin and the lumen was filled with clear mucoid fluid. In case of hydrometra, uterus was thin walled due to accumulation of clear and watery fluid in the lumen of uterine horns.

The uterus was most commonly affected, accounting for 47.5 per cent (19 out of 40) of the abnormalities, followed by the ovary (32.5%; 13 out of 40) in ewes. Among the uterine abnormalities in sheep higher incidence of hydrometra (20%; 8/40) whereas lower incidence of endometritis (2.5%; 1/40) and mummification (2.5%; 1/40) was recorded. Besides these, 12.5 per cent (5/40) uteri were affected with pyometra and 10 per cent (4/40) with mucometra.

Of the genitalia (n= 371) investigated in goats, 8.08 per cent cases of uterine abnormalities were recorded involving endometritis and pyometra (1.34% each), hydrometra (3.5%) and excessive hemorrhage (0.8%). Pyometra was characterised by the presence of an enlarged uterus with yellow purulent exudates filling the lumen.

Among the affected goat genitalia (n=92), higher incidence of miscellaneous abnormalities (25%; 23/92) was recorded. Besides these, hydrometra 14.13 per cent (13/92), endometritis 5.43 per cent (5/92), pyometra 5.43 per cent (5/92), mucometra 4.34 per cent (4/92) and excessive haemorrhage of uterine horns 3.26 per cent (3/92) were also diagnosed. The ovary was most commonly affected, accounting for 41.3% (38/92) of the abnormalities, followed by the uterus (32.6%; 30/92) and oviduct (1.08%; 1/92) in goats.

Among the miscellaneous abnormalities, parovarian cysts (1.49%; 4/267), parasitic cysts (1.12%; 3/267) and nodules on horns (0.37%; 1/267) were reported in ewes. Parovarian cysts were recorded in 3.77% (14/371) of the goats. Diameter of cysts ranged from 2mm to 11mm and most of them were located on mesovarium. Eight cases of parasitic cyst and one case of nodules on horns were also reported in goats.

The uterine and ovarian abnormalities co-existed only in a few abattoir sheep or goat genitalia. Ovarobursal adhesions were associated with mucometra or pyometra (one specimen each) in ewes while in goats they existed along with endometritis in one specimen only. In two goats, hydrometra was presented along with either follicular or luteal cyst.

Of the ewes examined, 7.86 per cent were pregnant. Single pregnancy was observed in majority of the cases with fetus present in right (42.85%) or left (47.61%) horn whereas 9.52 per cent were twins. Among goats forty three (11.59%) were pregnant. The proportion of single and twin pregnancy was 76.75 and 23.25 per cent, respectively. Most of the foetuses were estimated to be less than two months old. The incidence of transuterine migration of embryos was 14.28 per cent in ewes and 37.2 per cent in goats.

Significantly higher ($p < 0.05$) number of caruncles were recorded in non-gravid (112.39 ± 1.26) than gravid (95.38 ± 4.09) sheep genitalia. The mean number of caruncles in non-gravid genitalia of goats was 114.56 ± 0.94 as against 109.04 ± 2.75 in gravid genitalia.

The activity of the ovaries was assessed by the presence or absence of corpora lutea. Corpora lutea were evident in 125 (23.4%) of sheep ovaries. Out of these ovulations, 58.4 per cent were evident in right whereas 41.6 per cent in left ovary. A total of 742 ovaries of goats were examined. Ovarian activity was observed in 202 (27.22%) goat ovaries; out of which 121 (59.90%) ovulations had occurred in the right and 81 (40.10%) on the left ovary. Thus the right ovary was more active than left in sheep as well as in goats.

The total number of follicles (small and large) and corpora lutea were counted to compare ovarian activity during the breeding and non breeding seasons, in all the reproductive tracts of sheep and goats. The mean number of small and large follicles was comparable between seasons in ewes. However, significantly higher ($p < 0.05$) number of corpora lutea (0.64 ± 0.06) were present during breeding than non-breeding (0.39 ± 0.06) season.

The mean number of small follicles recorded on goat ovaries during breeding and non-breeding seasons (19.1 ± 0.68 Vs 19.8 ± 0.89 , respectively) was comparable.

However, the mean number of large follicles available were significantly higher ($p < 0.05$) during breeding (2.56 ± 0.10) than in non-breeding (1.72 ± 0.15) season. Simultaneously, the number of CL present during breeding (0.76 ± 0.05) season were significantly higher ($p < 0.05$) than that of non-breeding (0.55 ± 0.07) season. Thus a seasonal variation in ovarian activity was recorded in the both in sheep as well as goats.

The influence of presence or absence of CL on size of follicles was also evaluated. In sheep, significantly higher ($p < 0.05$) number of large follicles (1.19 ± 0.10 Vs 0.81 ± 0.06) were recorded in ovaries having corpora lutea. However, in goats, the mean number of small and large follicles (1.15 ± 0.08 Vs 1.14 ± 0.04 , respectively) did not differ significantly between the ovaries with or without CL.

Conclusions

- In sheep, uterus was most commonly affected, while in goats, the proportion of ovarian abnormalities was higher.
- Among the uterine abnormalities, hydrometra was most frequently detected in both species.
- Uterine and ovarian abnormalities co-existed only in a few abattoir sheep or goat genitalia.
- Majority of gravid sheep and goat genitalia had early pregnancy of less than 2 months.
- Incidence of transuterine migration was higher (37.2%) in goats than sheep (14.28%).
- Ovarian activity occurred throughout the year in both the species but no. of CL was higher during breeding season both in sheep and goats.
- Right ovary was more active than left in both the species.

Literature Cited

- Abeyratne AS and Atureliya OS. 1982. Study on the reproductive organs in the indigenous female goats of Sri Lanka. *Ceylon Veterinary Journal* 27(1): 17-19
- Acland HM. 2001. Reproductive system: Females. In: *Thomson's Special Veterinary Pathology*. Third Edition. (Mac Gavin *et al.* eds.) Mosby Inc. USA. p 601-627
- Adams NA. 1975. A pathological and bacteriological abattoir survey of the reproductive tracts of Merino ewes in Western Australia. *Australian Veterinary Journal* 51(7): 351-354
- Agnew DW, Munson L and Ramsay EC. 2003. Cystic endometrial hyperplasia in elephants. *Veterinary Pathology* 41(2): 179-183
- Alam MGS and Rahman A. 1979. Diseases of genital tract of indigenous cows in Bangladesh. *Tropical Animal Health and Production* 11(3): 179-180
- Alam MGS. 1984. Abattoir studies of genital diseases in cows in Bangladesh. *Veterinary Record* 114(3): 195
- Al-Baggal HAR, Al-Dahash and Alwan AF. 1993. Macroscopic study of the female genital system in Iraqi goats. *Small Ruminant Research* 9(4): 341-346
- Al-Dahash SYA and David. 1977. The incidence of ovarian activity, pregnancy and bovine genital abnormalities shown by an abattoir survey. *Veterinary Record* 101(15): 296-299
- Al-Gubory and Martinet J. 1987. Effect of corpus luteum on ovarian follicular populations and growth in the ewe. *Animal Reproduction Science* 13(4): 269-281
- Allen WE. 1988. Fertility and obstetrics in the Horse., Blackwell Scientific Publications, Oxford, Boston, Chicago. p 9-17
- Alosta RA, Vaugnan L and Collins JD. 1998. An abattoir survey of ovine reproductive tracts in Ireland. *Theriogenology* 50(3): 457-464
- Alwan AF, Al-Dahash SYA and Al-Baggal HAR. 1993. Macroscopic study of the pregnant genitalia of Iraqi goats. *Small Ruminant Research* 11(4): 343-349

- Amir D and Volcani R. 1965. The sexual season of the Awassi fat-tailed ewe. *Journal of Agricultural Science* 64(1): 83-85
- Arthur GH, Noakes DE and Pearson H. 1989. Infertility In: *Veterinary Reproduction and Obstetrics*. Sixth Edition. Bailliere Tindall, London, UK. p 383-577
- Arthur GH, Noakes DE and Pearson H. 2001. Pregnancy and Parturition In: *Veterinary Reproduction and Obstetrics*. Eighth Edition. Bailliere Tindall, London, UK. p 68
- Assey RJ, Kessy BM, Matovelo JA and Minga U. 1998. Incidence of gross reproductive abnormalities in Small East African Zebu cattle. *Tropical Animal Health and Production* 30(6): 361-368
- Barret JF, Moule GR, Braden AW and Harris AN. 1961. Cystic glandular hyperplasia of the endometrium in ewes in New South Wales and Queensland. *Australian Veterinary Journal* 37(1): 14-18
- Bartelewski PM, Beard AP, Cook SJ and Rawling NC. 1998. Ovarian follicular dynamics during anoestrous in ewes. *Journal of Reproduction and Fertility* 113(2): 275-285
- Bartelewski PM, Beard AP, Cook SJ and Rawling NC. 1999. Ovarian function in ewes during the transition from breeding season to anoestrous. *Animal Reproduction Science* 57(1): 51-66
- Basu S, Goswami SK and De SK. 1961. Studied on genitalia of she goats. *Indian Veterinary Journal* 38(5): 302-304
- Bennetts HW, Underwood EJ and Shier FL. 1946. A specific breeding problem of sheep on subterranean clover pastures in Western Australia. *Australian Veterinary Journal* 22(1): 2-12
- Bokko PB. 2011. Pregnancy Wastage in sheep and goats in the Sahel Region of Nigeria. *Nigerian Veterinary Journal* 32(2): 120 – 126
- Bondoc OL, Garcia BR and Beltran ED. 2004. Analysis of Twinning Data on Philippine Native Goats (*Capra hircus* L.). *Philippine Journal of Veterinary and Animal Sciences* 30(1): 47-51

- Bondurant RH. 1999. Information in the bovine reproductive tract. *Journal of Dairy Science* 82(2): 101-110
- Boyd JDW, Hamilton WJ and Hammond J. 1944. Transuterine (“internal”) migration of the ovum in sheep and other mammals. *Journal of Anatomy* 78(1): 5
- Brand A and DeJong WHR. 1973. Qualitative and quantitative micromorphological investigations of the tertiary follicles population during the oestrous cycle in sheep. *Journal of Reproduction and Fertility* 33(3): 431-439
- Bronson IH. 1985. Mammalian Reproduction: An ecological perspective. *Biology of Reproduction* 32(1): 1-26
- Camp JC, Wildt DE, Howard PK, Stuart LD and Chakraborty PK. 1983. Ovarian activity during normal and abnormal length estrous cycles in the goat. *Biology of Reproduction* 28(3): 673-681
- Casida LE, Woody CO and Pope AL. 1966. Inequality in function of the right and left ovaries and uterine horns of the ewe. *Animal Science* 25(4): 1169–1171
- Chand and Chauhan HVS. 1975. Cystic endometrial hyperplasia in sheep and goats. *Indian Journal of Animal Sciences* 45(2): 71
- Chand and Chauhan HVS. 1978. Pathology of female genital organs of sheep and goats in Haryana State. *Indian Journal of Veterinary Pathology* 3(1): 23-25
- Chungath JJ and Sharma RD. 1991. Biometry of the ovary and corpus luteum of pregnant goat. *Indian Journal of Animal Research* 25(1): 15-18
- Clark JRRA, Dailey RA, Staigmiller RB, First NL, Chapman AB and Casida LE. 1971. CL number and follicular fluid weight relationships in swine. *Journal of Animal Science* 33(8): 1156
- Cloete JHL. 1939. Prenatal growth in the Merino sheep. *Onderstepoort Journal of Veterinary Science and Animal Industry* 13(5): 417
- Cockcroft and Mc Innes. 1998. Abdominal straining in a goat with leiomyoma of the cervix. *Veterinary Record* 142(7): 171 (Abstract)

- Curson HH. 1934. Studies on sex physiology. XI. The relationship between a corpus luteum verum and the corresponding pregnant horn. *Onderstepoort. Journal of Veterinary Science* 3(2): 133
- Devendra C and Burns M. 1983. Goat Production in the Tropics. Commonwealth Agricultural Bureau, Farnham House, Slough, UK. p 74-89
- Dawood. 2010. Pathological abnormalities of the reproductive tracts of ewes in Basra, Iraq. *Veterinary Record* 166(7): 205-208
- Dennis SM. 1979. Urogenital defects in sheep. *Veterinary Record* 105(15): 344
- Doijode SV. 1993. A rare case of foetal mummification in goat. *Indian Journal of Animal Reproduction* 14(1): 60-61
- Dufour J, Ginther OJ and Casida LE. 1972. Intraovarian relationship between corpora lutea and ovarian follicles in ewes. *American Journal of Veterinary Research* 33(7): 1445
- El-Fouly MA, Shafie MM, Abdel-Aziz AS and Kandeal SA. 1977. Seasonal variation in oestrous activity in Ossimi and Rahmani ewes. *Egyptian Journal of Animal Production* 17(1): 75-85
- Emady M, Noakes DE and Arthur GH. 1975. Analysis of reproductive function of the ewe based on post mortem examination. *Veterinary Record* 96(12): 261-266
- Emady M. 1976. Reproduction of the ewe and female goat in the province of Fars, Iran. *Veterinary Record* 99(11) : 208-217
- Epsy LL. 1994. Current status of the hypothesis that mammalian ovulation is comparable to inflammatory reaction. *Biology of Reproduction* 38(2): 264-269
- Erb HN. 1987. Interrelationships among production and clinical diseases in dairy cattle: A review. *Canadian Veterinary Journal* 28(6): 326-329
- Feldman EC and Nelson RW. 1996. Cystic endometrial hyperplasia/pyometra complex. In: *Canine and feline endocrinology and reproduction*. Second Edition. (Feldman EC and Nelson RW, eds.). W.B. Saunders, Philadelphia, PA. p 605-618

- Francis M. 2009. Caprine ovarian and uterine lesions: An abattoir survey. *M.Sc. Research Dissertation*. Department of Veterinary Pathology, Makerere University, Uganda.
- Garcia M. 1988. A gross morphological abattoir survey of genital organs from female Zebu cattle. *Acta Veterinaria Scandinavica* 83(2): 34–45
- Gopal Yadgirkar, Sri Raman PK, Suryanarayana Murthy A and Sastry GA. 1976. Studies on the patho-anatomical of female genitalia in goats. *Journal of Research, APAU III* 1(1): 4-6
- Hafez 1952. Studies on the breeding season and reproduction of the ewe. *Journal of Agriculture Science* 64(1): 83-85
- Hambolu JO. 1982. Ovarian biometrics: Seasonal changes in Yankasa sheep and Sokoto Red goats in Zaria. *M.Sc. Thesis*. Ahmadu Bello University, Zaria, Nigeria. p 53
- Hambolu JO and Ojq SA. 1985. Ovarian activity of Sokoto Red goats using abattoir specimens. *Theriogenology* 23(2): 273-282
- Hambolu JO, Ojq SA, Jamdar MN and Molokwu EC. 1985. Ovarian activity of Yankasa sheep using abattoir specimens. *Theriogenology* 23(2): 263-272
- Hassenlink JW. 1993. Incidence of hydrometra in dairy goats. *Veterinary Record* 132(5): 110-112
- Herenda D. 1987. An abattoir survey of reproductive organ abnormalities in beef heifers. *Canadian Veterinary Journal* 28(1): 33–36
- Javed MH, Anwar A, Ahmad KM, Ali CS, Ahmad M and Khan A. 1987. Gross abnormalities of Lohi ewes and female Barbari (Teddy) goats genitalia in different age groups. *Pakistan Veterinary Journal* 7(1): 36-40
- Johnson LD. 1987. Lesions of female genital system caused by diethylstilbestrol in human, subhuman primate and mice. In: *Genital System* (Jones *et al.*, eds.). Springer-Verlag, Berlin. p 84-109
- Jones TC, Hunt DR and King WN. 1997. Genital System. In: *Veterinary Pathology*. Sixth Edition. Lippincott Williams and Wilkins, Baltimore. p 1149 – 1221

- Kadu MS and Kaikini AS. 1987. Functional activities of the ovaries and the uterine horns of goats. *Indian Veterinary Journal* 64(11): 945-949
- Kadu MS and Kaikini AS. 1988. Pathological conditions in the female genital organs of the goat. *Indian Journal of Animal Science* 58(7): 795-798
- Karsch FJ, Battaglia DF, Breen KM, Debus N and Harris TG. 2002. Mechanism for ovarian cycle disruption by immune inflammatory stress. *Stress* 5(2): 101-112
- Kennedy PC and Miller RB. 1993. The Female Genital System. In: *Pathology of Domestic Animals* (Jubb *et al.*, eds.). Third Edition. Academic Press, Inc. San Diego, USA. p 349-454
- King NV. 1978. The reproductive tract. In: *Pathology of Laboratory Animals* (Benirschke *et al.* eds.). Springer-Verlag, New York. p 509-580
- Kumi-Diaka J, Ogwu D and Osori DIK. 1981. Significance of atrophic ovaries in livestock production in Northern Nigeria. *Veterinary Record* 108(13): 277-278
- Lewis GS. 2003a. Role of ovarian progesterone and potential role of prostaglandin F_{2α} prostaglandin E₂ in modulating the uterine response to infectious bacteria in postpartum ewes. *Journal of Animal Science* 81(1): 285-293
- Lewis GS. 2003b. Steroid regulation of uterine resistance to bacterial infection in livestock: a review. *Reproductive Biology and Endocrinology* 1(1): 117
- Livestock Census. 2007. All India Report based on Quick Tabulation Plan, Village Level Totals (Gangadharan R 2010, eds.). Ministry of Agriculture, Government of India
- Long SE. 1980. Some pathological conditions of the reproductive tract of the ewe. *Veterinary Record* 106(8): 175-176
- Luna LG. (1968). Manual of histologic staining methods of the Armed Forces Institute of Pathology. Third Edition. McGraw Hill Book Company, New York.
- Lyngset O. 1968a. Studies on reproduction in the goat iv The functional activity of the uterine horns of the goat V. Pathological conditions and malformations of the genital organs of the goat. *Acta Veterinaria Scandinavica* 9(4): 308-315

- Lyngset O. 1968b. Studies on reproduction in the goat II The genital organs of the pregnant goat. *Acta Veterinaria Scandinavica* 9(3): 242-252
- Maclachlan NJ and Kennedy PC. 2002. Tumours of the Genital System. In: *Tumours in Domestic Animals* (Donald MJ, eds.). Fourth Edition. Iowa State University Press: A Black Well Publishing Company, Ames. p 547-561
- Markandeya NM, Pargaonkar DR, Bakshi SA and Doijode SV. 1991. Foetal mummification in a goat. *Indian Journal of Animal Reproduction* 12(1): 107-108
- Mateus L, Costa LLD, Diniz P and Ziecik A. 2003. Relationship between endotoxin and prostaglandin (PGE2 and PGFM) concentrations and ovarian function in dairy cows with puerperal endometritis. *Animal Reproduction Science* 76(3): 143-154
- Mc Entee K. 1990. The Uterus: Degenerative and Inflammatory Lesions. In: *Reproductive Pathology of Domestic Animals*. Academic Press, Inc. Harcourt Brace Jovanovich Publishers, New York. p 142-186
- Mittal JP and Ghosh PK. 1980. A note on annual reproductive rhythm in Marwari sheep of the Rajasthan desert in India. *Animal Production* 30(1): 153-156
- Moghaddam A and Gooraninijad S. 2007. Abattoir survey of gross abnormalities of the ovine genital tracts in Iran. *Small Ruminant Research* 73(1): 259-261
- Moreira ELT, Nasemento EFD and Chquiloff MAG. 1993. Morphological alterations in the ovaries and uterus of capra hircus L(1) Regressive alterations. *Veterinary Bulletin* 32(1): 4072
- Morrow DA. 1986. Current Therapy in Veterinary Theriogenology: Diagnosis, Treatment and Prevention of Reproductive Diseases in Animals. Second Edition. W. B. Saunders and Company, Philadelphia. p 575- 629
- Mukasa-Mugerwa E. 1989. A review of reproductive performance of female Bos Indicus (Zebu) cattle. *ILCA monograph* 6. Adis Abada, Ethiopia. p 1-34
- Mukasa Mugerwa E and Tekley B. 1988. The reproductive performance of Ethiopia high land ewes. *Animal Reproduction Science* 17(1): 95-102

- Mukasa Mugerwa E, Anindo D, Lahlou-Kassi A, Mutiga ER and Sovani S. 1993. Seasonal variation in ovarian and oestrous activity of tropical Menz sheep as affected by plane of nutrition. *Reproduction Nutrition and Development* 33(6): 585-595
- Mukasa-Mugerwa E and Lahlou-Kassi A. 1995. Reproductive performance and productivity of Menz sheep in the Ethiopian highlands. *Small Ruminant Research* 17(2): 167-177
- Mukasa-Mugerwa E and Zere E. 1991. Resumption of postpartum oestrus behaviour and associated plasma progesterone profile in Menz ewes. *Animal Production* 52(2): 297-300
- Nair KP and Raja CKSV. 1972. Investigation on the pathological conditions in female genital organs of the goat. *Kerala Journal of Veterinary Science* 3(3): 106
- Nair KP and Raja CKSV. 1973. Studies on the gravid genitalia of goats. *Kerala Journal of Veterinary Science* 50(1): 42-50
- Novel Km, Tebble JE, Harvey D and Dobson H. 2000. Ultrasonography and hormonal profile of persistent ovarian follicles (cysts) induced with low doses of progesterone in cattle. *Journal of Reproduction and Fertility* 120(2): 361-366
- O'Shea JD, Lee CS and Cumming IA. 1974. Normal duration of the oestrus cycle in ewes with congenital absence of one uterine horn. *Journal of Reproduction and Fertility* 38(1): 201
- Otchere EO and Nimo MC. 1976. Reproductive performance in the West African Dwarf goat. *Ghana journal of Agricultural Science* 9(1): 57-59
- Percy DH and Barthold SW. 1993. Pathology of laboratory rodents and rabbits. Second Edition. Iowa State University Press, Ames. p 3
- Peter AR, Bosu WTK and DeDecker RJ. 1989. Suppression of preovulatory luteinizing hormone surges in heifers after intrauterine infusion of *Escherichia coli* endotoxins. *American Journal of Veterinary Research* 50(3): 368-373
- Pieterse MC and Taverne MAM. 1986. Incidence of hydrometra in goats. *Theriogenology* 26(5): 813

- Prabhakaran NK and Raja CKSV. 1972. Investigations on the pathological conditions in the female genital organs of the goat. *Kerala Journal of Veterinary Science* 3(1): 106-119
- Rahman A, Hossain A, Ahmed MV and Sen MM. 1977. Studies on some reproductive performances and biometry of the female genital tract of Black Bengal goat. *Journal of Animal Science* 47(4):714-725.
- Rahman MH, Chowdhury EH, Saha SS, Islam A and Alam MGS. 2008. Abattoir study of reproductive diseases in goats. *The Bangladesh Veterinarian* 25(2): 88-91
- Raji MA, Salami SO and Ameh JA. 2010. Pathological conditions and lesions observed in slaughtered cattle in Zaria abattoir. *Journal of Clinical Pathology and Forensic Medicine* 1(2): 9-12
- Ramadan AA, Johnson GL and Lewis GS. 1997. Regulation of uterine immune function during the estrous cycle and in response to infectious bacteria in sheep. *Journal of Animal Science* 75(6): 1621-1632
- Rebhun WC. 1995. Reproductive diseases. In: *Diseases of Dairy Cattle*. Williams and Wilkins, Baltimore. p 309-352
- Reddy KCS. 1995. An abattoir survey on the female reproductive tract of goats. *M.V.Sc. Thesis*. Department of Animal reproduction and Gynaecology, APAU, Hyderabad, India.
- Regassa F, Mengesha D, Dargie M and Tolosa T. 2009. Abattoir evidence on association between uterine and ovarian abnormalities in Ethiopian highland ewes. *Animal Reproduction Science* 111(2): 384-390
- Regassa F, Tamrat H and Bekana M. 2007. Ovarian activity, transuterine embryo migration and prenatal losses in Ethiopian highland ewes. *Tropical Animal Health and Production* 39(2): 131-139
- Reimers TJ, Dziuk PJ, Bahr J, Sprecher DJ, Webel SK and Harmon BG. 1973. Transuterine embryonal migration in sheep, anteroposterior orientation of pig and

- sheep fetuses and presentation of piglets at birth. *Journal of Animal Science* 37(5): 1973
- Restall BJ. 1992. Seasonal variation in reproductive activity in Australian goats. *Animal Reproduction Science* 27(4): 305-318
- Rexroad CE and Casida LE. 1975. Ovarian follicular development in cows, sows and ewes in different stages of pregnancy as affected by number of corpora lutea in the same ovary. *Journal of Animal Science* 41(4): 1090-1097
- Roberts SJ. 1971. Infertility in the cow. In: *Veterinary obstetrics and genital diseases*. Second edition. CBS Publisher and Distributors, India. p 345-579
- Roja HJD and Bryant MJ. 2003. Seasonality of reproduction in sheep. *Small Ruminant Research* 48(3): 155-171
- Rubianes E, De Castro T, Ungerfeld R, Meikle A and Rivero A. 1997. Ovarian response after a GnRH challenge in seasonally anoestrous ewes. *Canadian Journal of Animal Science* 77(4): 727-730
- Sabra HA and Hassan SG. 2008. Effect of new regime of nutritional flushing on reproductive performances of Egyptian Barki ewes. *Global Veterinaria* 2(1): 28-31
- Sahni KL and Roy AA. 1967. Study on the sexual activity of Bikaneri sheep (*ovis aries* L) and conception rate through artificial insemination. *Indian Journal of Veterinary Science and Animal Husbandry* 37(3): 327-334
- Sarkar MK. 1993. Studies on the Incidence of Reproductive Abnormalities in Female Goat (*Capra hircus*). *M.Sc. Thesis*. Department of Anatomy, Bangladesh Agricultural University, Bangladesh.
- Sattar A and Khan MJ. 1988. Incidence and pathology of ovarian diseases of goats. *Pakistan Veterinary Journal* 8(1): 18-21
- Sattar A, Khan MZ and Siddiqui M. 1988. Incidence, pathology and bacteriology of abnormalities of fallopian tubes in goats. *Pakistan Veterinary Journal* 8(1): 14-17

- Scanlon PF. 1972. Frequency of transuterine migration of embryos in ewes and cows. *Journal of Animal Science* 34(5): 791-794
- Scaramuzzi RJ and Downing JA. 1997. The distribution of ovulations from the ovaries of Merino and Border Leicester × Merino ewes and its effect on the survival of their embryos. *Animal Reproduction Science* 47(4): 327-336
- Schwarz T. 2003. Ovarian follicular dynamics in goats. *Ph.D. Thesis*. University of Agricultural in Krakow, Poland.
- Schwarz T and Wierzchos E. 2010. The distribution of corpora lutea and ovarian follicular development in pregnant goats. *Reproductive Biology* 10(1): 53-66
- Sefidbakht N, Mostafavi MS and Farid A. 1978. Annual reproductive rhythm and ovulation rate in four fat-tailed sheep breeds. *Animal Production* 26(2): 177-184
- Sharma AK. 1980. Affections of female genital tract of sheep and goats – occurrence and pathomorphological study. *M.V.Sc. Thesis*. CSA University of Agriculture and Technology, Mathura, U.P., India
- Sharma AK and Sharma DN. 1985. Affections of fallopian tubes in sheep and goat. *Indian Journal of Veterinary Pathology* 9(1): 58-61
- Sharma AK and Sharma DN. 1986. Bent cervix and adenomyosis in sheep and goats. *Indian Journal of Veterinary Pathology* 10(1): 85
- Sharma SK. 1973. Pathological conditions of reproductive system of sheep and goat in Andhra Pradesh. *M.Sc. Thesis*. Andhra Pradesh Agricultural University, Hyderabad.
- Sheldon IM and Dobson H. 2004. Postpartum uterine health in cattle. *Animal Reproduction Science* 82(1): 295–306
- Singh N. 1973. Disorders of female genital system of caprines – patho-anatomical and histochemical studies. *Ph. D. Thesis*. Agra university, U.P., India
- Singh N and Rajya BS. 1977. Pathology of female reproductive system in goats. *Indian Journal of Animal Science* 47(1): 22

- Singh SK, Bhattacharay AR and Luktura SN. 1974. Studies on biometry of genital organs of female goat. *Indian Veterinary Journal* 51(1):81–85
- Smith KC, Long SE and Parkinson TJ. 1998. Abattoir survey of congenital reproductive abnormalities in ewes. *Veterinary Record* 143(25): 679-685
- Smith KC, Parkinson TJ and Long SE. 1999. Abattoir survey of acquired reproductive abnormalities in ewes. *Veterinary Record* 144(18): 491-496
- Smith KC, Parkinson TJ, Pearson GR and Long SE. 1996. Ovarian fusion in sheep. *Journal of Anatomy* 189(1): 199-204
- Sudhakar T, Roy KS, Raju K and Anjaneyulu Y. 2010. Reproductive disorders in Deccani ewes: An abattoir study. *Indian Journal of Animal Reproduction* 31(1): 58-60
- Taverne MAM, Lavoit MC, Bevers MM, Pieters MC and Dieleman SJ. 1988. Peripheral plasma proteins and progesterone levels in pseudopregnant goats during bromocriptine treatment. *Theriogenology* 30(5): 777-860
- Thimonier J and Chemineau P. 1988. Seasonality of reproduction in female farm animals under a tropical environment. In: *Proceeding 11th International Congress Animal Reproduction and Artificial Insemination*: University College, Dublin 5(1): 229-237
- Timurkaan F and Karadas E. 2000. Morphological investigations on pathological changes of the female reproductive organs in goats: ovarium and oviduct. *Journal of Health Science* 14(1): 197-207
- Webb P. 1985. Segmental Aplasia and Hydrometra in a goat. *Veterinary Record* 117(1): 13 (Abstract).
- Wheeler AG and Land RB. 1977. Seasonal variation in oestrous and ovarian activity of Finnish Landrace, Tasmanian Merino and Scottish Blackface ewes. *Animal Production* 24(3): 363-376
- Wilson RT and Traore A. 1988. Livestock production in central mali: reproductive performance and reproductive wastage in ruminants in the agro-pastoral system. *Theriogenology* 29(4): 931-944

- Winter AC and Dobson H. 1992. Observation on the genital tract of cull ewes. *Veterinary Record* 130(4): 68–70.
- Yenikoye A, Andre D, Ravault JP and Mariana JC. 1981. Some reproductive characteristics of the Fulani ewe in Niger. *Reproduction Nutrition and Development* 21(6): 937-951
- Zarco L, Stabenfeldt GH, Kindahl H, Quirke JF and Granstrom E. 1984. Persistence of luteal activity in the non-pregnant ewe. *Animal Reproduction Science* 7(1): 245

Brief Resume of the Student

Name: Jitendra Kumar Agrawal

Mother's Name: Mrs. Vijay Lakshmi

Father's Name: Mr. Girraj Prasad

Date of Birth: 02-10-1984

Permanent Address with Contact No.: B77 Kaptan Colony, Purana Roopbass, Alwar, Rajasthan, India. 09817541204 (jituvet11@mail.com)

Academic Qualifications: (Starting with 10th class)

Qualification	Year	School/Board/University	Marks (%)	Division	Major subject
10 th Class	1999	Board of Sec. Edu. Ajmer (Raj.)	85.5%	1 st	Social sciences
12 th Class	2001	Board of Sec. Edu. Ajmer (Raj.)	71.23%	1 st	Biology & physics
B.V.Sc	2009	COVAS, R.A.U	7.27 %	1 st	Vet. Science
M.V.Sc	2012	COVAS, C.S.K.H.P.K.V	7.24%	1 st	Animal Reproduction, Gynaecology & Obstetrics.

Fellowships/Scholarships/Gold Medals/Awards/Any Other Distinction: Nil

Year: Distinction

Year: Distinction, and so on....

Publications: (Give numbers only)- Nil

Total:

Research papers (in peered journals): Nil

Scientific Popular Articles: Nil

Others: Nil

Visits abroad along with duration and purpose of visit: