

16159

**PROCESSED AORTIC ALLOGRAFTS
FOR OESOPHAGOPLASTY IN DOGS**

**By
T. P. BALAGOPALAN**

THESIS

**Submitted in partial fulfilment of the
requirement for the degree**

Doctor of Philosophy

**Faculty of Veterinary and Animal Sciences
Kerala Agricultural University**

**Department of Surgery
COLLEGE OF VETERINARY AND ANIMAL SCIENCES
MANNUTHY, THRISSUR
KERALA, INDIA**

1998

16159

-Th-598-

6367

6367

B.S. / PR

DECLARATION

I hereby declare that the thesis entitled "**PROCESSED AORTIC ALLOGRAFTS FOR OESOPHAGOPLASTY IN DOGS**" is a bonafide record of research work done by me during the course of research and that the thesis has not previously formed the basis for the award to me of any degree, diploma, associateship, fellowship or other similar title, of any other University or Society.

Mannuthy
30.12.1998




T.P. BALAGOPALAN

CERTIFICATE

Certified that the thesis entitled "**PROCESSED AORTIC ALLOGRAFTS FOR OESOPHAGOPLASTY IN DOGS**" is a record of research work done independently by **Shri. T.P. Balagopalan**, under my guidance and supervision and that it has not previously formed the basis for the award of any degree, diploma, fellowship or associateship to him.


Mannuthy
30.12.1998



Dr. K.N. Muraleedharan Nayar
(Chairman, Advisory Committee)
Professor & Head
Department of Surgery
College of Veterinary &
Animal Sciences, Mannuthy

CERTIFICATE

We, the undersigned members of the Advisory Committee of **Shri. T.P. Balagopalan**, a candidate for the degree of Doctor of Philosophy in Veterinary Surgery, agree that the thesis entitled "**PROCESSED AORTIC ALLOGRAFTS FOR OESOPHAGOPLASTY IN DOGS**" may be submitted by Shri. T.P. Balagopalan, in partial fulfilment of the requirement for the degree.



Dr. K.N. Muraleedharan Nayar

(Chairman, Advisory Committee)

Professor & Head

Department of Surgery

College of Veterinary & Animal Sciences

Mannuthy




Dr. K.T. Punnose

Professor & Head i/c

Department of Microbiology

(Member)



Dr. K.R. Harshan

Associate Professor & Head

Department of Anatomy

(Member)




Dr. N. Gopakumar

Associate Professor

Department of Pharmacology

(Member)




Dr. C.R. Lalithakunjamma

Associate Professor

Centre of Excellence in Pathology

(Member)



External Examiner

17/4/99

ACKNOWLEDGEMENT

In connection with this endeavour, I would like to record my gratitude to many people surrounding me for their encouragement, affirmation and honest feedback.

First and foremost to Dr. K.N. Muraleedharan Nayar, Professor and Head i/c, Department of Surgery, with whom I had the privilege of working with as Chairman of the advisory committee for all his magnanimity and sensitive spirit throughout the study. I owe him much for the valuable guidance, timely suggestions and support for the successful completion of this programme in time.

I am deeply indebted to Dr. K.T. Punnoose, Professor and Head, Department of Microbiology, Dr. K.R. Harshan, Head of the Department of Anatomy, Dr. N. Gopakumar, Associate Professor of Pharmacology and Dr. C.R. Lalitha Kunjamma, Associate Professor of Pathology for their valuable advice, critical comments and suggestions rendered as members of Advisory Committee at various stages of the work.

My sincere thanks are due to Dr. S. Raveendran Nayar, Professor of Surgery for his advice, technical help and careful scrutiny of the thesis.

I express my extreme gratitude to Dr. T. Sarada Amma and Dr. K. Rajankutty, Assistant Professors (Sel. Grade) of Surgery for their timely advice and sincere help during the programme.

Dr. C.B. Devanand, Assistant Professor of Surgery, who has been instrumental in the formulation of the methodology, has been fertile in suggestions and kind in assistance. My special gratitude to him.

I wish to express my sincere thanks to Dr. Syam K. Venugopal and Dr. K.D. John Martin, Assistant Professors of Surgery for their valuable help during my experiment.

I remember with gratitude, the sincere and whole hearted help and assistance extended to me by Dr. P.T. Dinesh, Dr. Neelakanta Praveen Pillai and Dr. A. Kumaresan, Post graduate students, Department of Surgery.

My sincere thanks are due to Dr. T. Sreekumaran, Professor, Dr. N. Divakaran Nayar, Assistant Professor (Sel. Grade) and Dr. Mamman J. Abraham, Assistant Professor, Centre of Excellence in Pathology, Sri. M. Nandakumaran, Associate Professor, Department of Nutrition for their help in conducting biochemical studies.

I express my deep sense of gratitude to Dr. Syam Mohan, Dr. N. Asok, Dr. Joseph Mathew, Dr. G. Girish Varma and Dr. K.P. Sreekumar, Assistant Professor of the faculty for their valuable help and assistance during the period of my study.

I am immensely thankful to Dr. N.V. Kamalam, Associate Professor and Dr. P. Sureshkumar, Assistant Professor, Radiotracer laboratory for their help rendered in sterilization of graft material.

Mr. D. Biju, Ms. P.H. Beena, Ms. Jalaja Menon, Ms. Seema Jayaprakash, Ms. N.M. Sara and Ms. M.K. Beena, Research Associates of the faculty helped me a lot in conducting biochemical analysis. I express my sincere thanks.

My profound thanks are also due to Smt. Indirabai, Assistant Professor (Sel. Grade) and Smt. K.P. Santhabai, Programmer, Department of Statistics in resolving the statistical intricacies of my data.

I am thankful to Smt. K. Indiradevi, Radiographer, Department of Surgery for her help in taking the radiographs.

Mr. A.P. Peter, Technical Assistant, Centre of Excellence in Pathology, provided me with many excellent photographs. My special thanks to him.

I also acknowledge the services rendered by Smt. A. Mary, Sri. Paul Thurumalai and Sri. M. Gandadharan during the period of my experiment.

I am grateful to Dr. A. Rajan, former Dean and Dr. (Mrs.) S. Sulochana, Dean i/c, College of Veterinary and Animal Sciences for providing all the facilities needed for the smooth conduct of the study.

My thanks to the staff of the University and College libraries for their help rendered in scanning the literatures.

My gratitude is also due to the Kerala Agricultural University for granting me part time registration for conducting the research programme.

The assistance rendered by the eminent persons outside the university need to be acknowledged.

Most cordial was the help rendered by Dr. N. Muralidhara Rao, Assistant Director and Head, Dr. T.P. Sastry, Scientist and other members of Bioproducts laboratory, Central Leather Research Institute, Adayar for processing and preservation of graft materials.

Dr. K. Ravindran, Director of Central Institute of Fisheries Technology, Kochi was so generous in providing me the best facilities in conducting the biomechanical studies of the sample materials at the Fishing Technology Division.

Dr. Meenakumari, Senior Scientist and other staff members of Fishing Technology Division were kind enough to conduct the biomechanical studies of the samples and its interpretation, in spite of their busy schedule. I express my sincere thanks.

My obligation to Dr. B. Murali Manohar, Professor, Dr. B. Gangadharan and Dr. T. Leenadevi, Research Scholars of Department of Pathology, Madras Veterinary College cannot be expressed in words. Their sincere efforts in conducting histopathological studies and documentation are greatly acknowledged.

More personally, I would like to thank all my teachers and intimate friends with whom I have had discussions about the project and also for their love, concern and encouragement during my study.

I am thankful to M/s Peagles, Mannuthy, for the prompt and neat typing of the thesis.

I owe much to my family Ms. Vijayalakshmi and Anand, for their endless patience, whole hearted support and constant inspiration during this endeavour. I sincerely thank them for their kind gesture.

and

Finally to me myself and that power which drives me all along.

T.P. BALAGOPALAN

Dedicated To My Family

CONTENTS

Chapter No.	Title	Page No.
I	INTRODUCTION	1
II	REVIEW OF LITERATURE	4
III	MATERIALS AND METHODS	22
IV	RESULTS	37
V	DISCUSSION	100
VI	SUMMARY	127
	REFERENCES	134
	ABSTRACT	

LIST OF TABLES

Table No.	Title	Page No.
1.	Rectal temperature, pulse rate and respiration rate in control group of animals (Mean \pm SE)	42
2.	Haemogram in control group of animals (Mean \pm SE)	43
3.	Serum constituents in control group of animals (Mean \pm SE)	44
4.	Physical and biomechanical characteristics of normal oesophagus, chrome and glutaraldehyde processed aortic tissue of dogs (Mean \pm SE)	45
5.	Rectal temperature, pulse rate and respiration rate in dogs before and after oesophagoplasty using chrome processed aortic allograft (Mean \pm SE)	55
6.	Haemogram in dogs before and after oesophagoplasty using chrome processed aortic allograft (Mean \pm SE)	56
7.	Serum constituents in dogs before and after oesophagoplasty using chrome processed aortic allograft (Mean \pm SE)	57
8.	Biomechanical characteristics of healing site of oesophagoplasty with chrome processed aortic allograft in dogs	58
9.	Rectal temperature, pulse rate and respiration rate in dogs before and after oesophagoplasty using chrome processed aortic allograft and pharyngostomy (Mean \pm SE)	69

Table No.	Title	Page No.
10.	Haemogram in dogs before and after oesophagoplasty using chrome processed aortic allograft and pharyngostomy (Mean±SE)	70
11.	Serum constituents in dogs before and after oesophagoplasty using chrome processed aortic allograft and pharyngostomy (Mean±SE)	71
12.	Biomechanical characteristics of healing site of oesophagoplasty with chrome processed aortic allografts in dogs subjected to oesophageal intubation	72
13.	Rectal temperature, pulse rate and respiration rate in dogs before and after oesophagoplasty using glutaraldehyde processed aortic allograft (Mean±SE)	82
14.	Haemogram in dogs before and after oesophagoplasty using glutaraldehyde processed aortic allograft (Mean±SE)	83
15.	Serum constituents in dogs before and after oesophagoplasty using glutaraldehyde processed aortic allograft (Mean±SE)	84
16.	Biomechanical characteristics of healing site of oesophagoplasty with glutaraldehyde processed aortic allograft in dogs	85
17.	Rectal temperature, pulse rate and respiration rate in dogs before and after oesophagoplasty using glutaraldehyde processed aortic allograft and pharyngostomy (Mean±SE)	96
18.	Haemogram in dogs before and after oesophagoplasty using glutaraldehyde processed aortic allograft and pharyngostomy (Mean±SE)	97

Table No.	Title	Page No.
19.	Serum constituents in dogs before and after oesophagoplasty using glutaraldehyde processed aortic allograft and pharyngostomy (Mean±SE)	98
20.	Biomechanical characteristics of healing site of oesophagoplasty with glutaraldehyde processed aortic allograft in dogs subjected to oesophageal intubation	99

LIST OF FIGURES

Figure No.	Title	Page No.
1.	Polythene sachet containing chrome processed graft material preserved in Isopropanol and a gross specimen of aortic tissue	36-37
2.	Polythene sachet containing glutaraldehyde processed graft material preserved in Isopropanol and a gross specimen of aortic tissue	36-37
3.	Pharyngostomy tube made up of modified polyvinyl chloride	36-37
4.	Cervical oesophagus with experimentally created defect on the ventral aspect	36-37
5.	Oesophagus after reconstruction using the oval shaped graft	36-37
6.	Installation of pharyngostomy tube by modified method	36-37
7.	Pharyngostomy tube entrance site, 14-15 days after removing the tube	45-46
8.	Gross specimen: Normal oesophagus, and graft material	45-46
9.	Photomicrograph: Histomorphology of graft material	45-46
10.	Skiagram of cervical oesophagus on 15th postoperative day	58-59
11.	Cervical oesophagus <i>in situ</i> at autopsy on 15th postoperative day	58-59
12.	Gross specimen: Grafted site on 15th postoperative day	58-59

Figure No.	Title	Page No.
13.	Gross specimen: Grafted site on 30th postoperative day	58-59
14.	Gross specimen: Grafted site on 30th postoperative day	58-59
15.	Gross specimen: Grafted site on 60th postoperative day	58-59
16.	Photomicrograph: Grafted site on 15th postoperative day	58-59
17.	Photomicrograph: Grafted site on 30th postoperative day	58-59
18.	Photomicrograph: Grafted site on 60th postoperative day	58-59
19.	Skiagram of cervical oesophagus on 30th postoperative day	72-73
20.	Cervical oesophagus <i>in situ</i> at autopsy on 30th postoperative day	72-73
21.	Gross specimen: Grafted site on 30th postoperative day	72-73
22.	Gross specimen: Grafted site on 60th postoperative day	72-73
23.	Photomicrograph: Grafted site on 15th postoperative day	72-73
24.	Photomicrograph: Grafted site on 30th postoperative day	72-73
25.	Photomicrograph: Grafted site on 60th postoperative day	72-73
26.	Skiagram of cervical oesophagus on 15th postoperative day	85-86
27.	Gross specimen: Grafted site on 15th postoperative day	85-86

Figure No.	Title	Page No.
28.	Gross specimen: Grafted site on 15th postoperative day	85-86
29.	Gross specimen: Grafted site on 60th postoperative day	85-86
30.	Gross specimen: Grafted site on 60th postoperative day	85-86
31.	Photomicrograph: Grafted site on 15th postoperative day	85-86
32.	Photomicrograph: Grafted site on 15th postoperative day	85-86
33.	Photomicrograph: Grafted site on 30th postoperative day	85-86
34.	Photomicrograph: Grafted site on 60th postoperative day	85-86
35.	Skiagram of cervical oesophagus on 60th postoperative day	99-100
36.	Cervical oesophagus <i>in situ</i> at autopsy on 15th postoperative day	99-100
37.	Gross specimen: Grafted site on 15th postoperative day	99-100
38.	Gross specimen: Grafted site on 30th postoperative day	99-100
39.	Gross specimen: Grafted site on 30th postoperative day	99-100
40.	Gross specimen: Grafted site on 60th postoperative day	99-100
41.	Gross specimen: Grafted site on 60th postoperative day	99-100
42.	Photomicrograph: Grafted site on 15th postoperative day	99-100

Figure No.	Title	Page No.
43.	Photomicrograph: Grafted site on 30th postoperative day	99-100
44.	Photomicrograph: Grafted site on 60th postoperative day	99-100
45.	Photomicrograph: Grafted site on 60th postoperative day	99-100
46.	Photomicrograph: Grafted site on 60th postoperative day	99-100
47.	Comparison of biomechanical characteristics of healing site of oesophagoplasty with chrome and glutaraldehyde processed aortic allografts in dogs	124
48.	Comparison of biomechanical characteristics of normal oesophagus and the healing site of oesophagoplasty with processed aortic allografts in dogs	125
49.	Comparison of biomechanical characteristics of healing site of oesophagoplasty with processed aortic allografts with and without oesophageal intubation in dogs	126
50.	Gross specimen: Grafted site on day of oesophagoplasty, 30th and 60th day postoperatively	126-127

Introduction

CHAPTER-I

INTRODUCTION

Reconstructive surgery of oesophagus is advocated following correction/treatment of conditions like foreign body obstruction, perforations, stenosis, achalasia, dilatations, vascular rings, neoplasms, perioesophageal lesions including complications of diagnostic procedures and for restoring its functional integrity. Cervical oesophageal reconstructive surgery presents a special challenge in dogs. The structural and functional peculiarity of cervical oesophagus necessitates some form of grafting procedures for reconstruction of larger defects (Holmberg et al., 1991). Viable substitutes as homografts or heterografts (Pavletic, 1981), synthetic materials (McGuire et al., 1973 and Howard et al., 1975) and preserved biological materials (Daleck et al., 1987) and various techniques for their implantation had been demonstrated experimentally in dogs. But at times, the problems like availability of suitable tissues, additional stress on the patients on harvesting them, tissue rejection and other long standing complications refrain the surgeons from undertaking such modalities for routine clinical application.

Chemically modified collagen had many of the desirable characteristics important for a biomaterial (Sastry, 1989). Chromicised/glutaraldehyde cross linked collagen of tissues like intestine, bovine artery, calf duramater, urinary bladder, pericardium and human amniotic membrane, were successfully employed as implant materials for experimental reconstruction of hollow organs in bovines and dogs (Gupta et al. (1978); Shetty et al. (1982); Frankland (1986); Sawyer et al. (1987); Sambandam (1992); Rameshkumar (1993); Santillan et al. (1995) and Sreenu et al. (1997)). Perusal of the available literature did not reveal any reports on the use of such collagen based biomaterials for cervical oesophagoplasty in animals. Aorta which contains abundant quantity of elastic and collagen fibres in comparison to many other tissues (Banks, 1981) may provide sufficient strength and elasticity to cope with functional capacity of oesophagus on implantation.

Postoperative management in terms of patient feeding is very important in avoiding complications of oesophageal surgery. Installation of pharyngostomy tube for the administration of nutritional and fluid requirement is a well described and generally accepted technique in veterinary medicine (Lantz et al., 1983).

Pharyngostomy tube placement in dogs and cats was first described by Bohning et al. (1970). Crowe and Downs (1986)

modified this procedure to avoid certain life threatening complications associated with the earlier technique. But a detailed experimental/clinical data on the safety and effectiveness of modified technique is wanting. Moreover, the effects of cesophageal intubation on healing of oesophageal wounds is reported to be controversial (Borgstrom and Lundy, 1959 and Todhunter *et al.*, 1986).

Hence the present study was under taken with the following objectives.

1. To prepare, preserve and evaluate the qualities of chrome/ glutaraldehyde cross linked aortic tissue harvested from dogs.
2. To compare the relative acceptability and efficacy of these graft materials on surgical implantation in experimentally created cervical oesophageal defect in dogs.
3. To evaluate the modified pharyngostomy feeding method in dogs.
4. To compare the healing of cervical oesophagoplasty site at different stages with and without oesophageal intubation in dogs.

Review of Literature

CHAPTER-II

REVIEW OF LITERATURE

Bircher (1894) used skin lined tubes for oesophageal replacement for carcinomatous stricture in a human patient.

Allen (1922) was the first to attempt replacement of resected oesophagus by autogenous fascia lata experimentally in dogs.

Kleinsasser *et al.* (1950) performed simple division and anastomosis of cervical oesophagus in dogs. As an additional measure to prevent leakage, peritoneal grafts harvested from the abdomen were applied to the line of anastomosis by means of interrupted sutures using cotton thread. Bursting pressure studies revealed that the application of peritoneal grafts did not enhance the rate of success.

Klopp *et al.* (1951) after resecting 3-7cm of the cervical oesophagus in dogs, used polythene tubes experimentally for reconstruction. Stricture resulted regardless of the length of segment excised. Histological examination of the reconstructed segment revealed proliferation of stratified squamous epithelium surrounded by fibrous tissue but there was no evidence of muscle regeneration.

Berman (1952) reported the histopathological changes after replacement of a portion of oesophagus by plastic tube. Initially there was haemorrhagic serofibrinous exudation around the tube. Granulation tissue formed was gradually transformed into dense fibrous tissue. Later on it was lined by squamous epithelium. In some specimens small inflammatory nests of lymphocytes and polymorphonuclear leucocytes were seen under epithelium and in the fibrous tissue.

Javid (1953) studied the use of fresh and preserved aortic homografts for reconstruction of oesophageal defects in dogs. By five weeks, thin epithelium had grown in from the adjacent oesophagus, and epithelization was complete in three months.

Borgstrom and Lundy (1959) demonstrated the interference in normal oesophageal healing in presence of intraoesophageal tubing.

Peer (1959) reported the use of homografts of aorta or heterografts of venacava to repair 3-8 cm defects of oesophagus. In four cases goat homografts and in two, canine homografts were implanted. Calf and bull venacava were used in five dogs. Most implants failed because of leakage or stenosis although one calf heterograft was good at nine months. Epithelium from the oesophagus lined the graft in long term survivors.

Seidenberg et al. (1959) performed reconstruction of the cervical oesophagus by a revascularised isolated jejunal segment in dogs. They anastomosed a branch of superior mesenteric artery and vein to the superior thyroid artery and anterior facial veins.

Grimes (1960) used terminal part of ileum with the ileocolic valve with a portion of colon to replace lower oesophagus and upper stomach in dogs.

Petrovsky (1961) employed diaphragmatic grafts for repairing the defects on oesophagus or for strengthening the line of oesophageal anastomosis. It has been concluded that these grafts were useful in operations for benign lesions such as leiomyomas, cysts and diverticulae of oesophagus.

Schultz et al. (1962) evaluated different suture materials viz. 5/0 silk, cotton, Dacron, chromic catgut and 6/0 wire for oesophageal anastomosis in dogs. They found marked tissue reaction with catgut, moderate with silk and slight with Dacron and wire.

Ahmad (1965) tried polythene tubes and teflon tubes for anastomosis of cervical oesophagus following segmental resection in dogs. The plastic and teflon tubes served only for keeping patency temporarily until the ends healed by fibrous tissue proliferation around the tubes. Stricture of

oesophagus was observed in dogs which were treated with teflon tubes.

Bryant and Eiseman (1965) used viable pedicle graft using intercostal muscle for reinforcement in anastomosis and to close small oesophageal defects. The healing was normal with formation of a smooth sheet of fibrous tissue at the site.

Lawson and Pirie (1966) reported that the surgical conditions affecting the oesophagus in dogs were vascular rings, achalasia, tumours and perioesophageal lesions.

La Guerre *et al.* (1968) used a hydrophilic polymer hydron sleeved with Dacron to replace oesophageal segment in dogs and observed that the prosthesis can be modified and developed to an improved oesophageal substitute.

Balkany *et al.* (1970) described more oesophageal erosions and ulcerations when a hard tube material was used in comparison to softer materials for oesophagostomy in dogs.

Bohning *et al.* (1970) performed surgical implantation of a stomach tube through a pharyngostomy at the piriform fossa of the pharynx for parenteral feeding in dogs. The ease of placing the tube, the duration of surgical procedure (7-10 mts), apparent lack of discomfort to the animals while the tube was in place, the ease of feeding, rapid return of strength and the uncomplicated healing within seven days after

removal of pharyagostomy tube were favourable indications for its use in anorectic animals/animals which underwent oesophageal or gastric surgery.

Guffy (1972) conducted radiographic examination of the oesophagus of the dog and cat by plain survey radiography and contrast radiography for diagnosis of abnormalities. Barium sulphate cream was found ideal for the cranial half of oesophagus and Barium sulphate mixed with food for the distal half.

Singh and Tyagi (1972) reported the use of autogenous dermal grafts and fascial grafts for the repair of oesophageal defects. They conducted experimental studies on various techniques of oesophageal reconstruction in bovines and observed that autofascialata was satisfactory for reconstruction of oesophageal wounds. Histopathological examination revealed heavy infiltration of macrophages, lymphocytes and fibroblasts on 7th postoperative day whereas on 15th day, there was predominance of mature fibroblasts. Microscopically, nonabsorbable suture materials incited less tissue reaction than catgut with early maturation of fibroblasts.

Coran (1973) used pericardial graft over the site of oesophageal anastomosis and observed a thick layer of fibrous and granulation tissue at the site of anastomosis but without

actual muscular layer under the mucosa. In the area adjacent to the anastomosis, there was growth of muscular fibres indicative of regeneration.

McGuire *et al.* (1973) reported the use of rubber tube, laminated nylon-polyethylene plastic tube and woven Dacron tube coated with silicone rubber for oesophageal segmental replacement in dogs. They performed oesophagectomy and replacement with woven Dacron tubing in pigs. Eventhough immediate postoperative results were promising, the prostheses were rejected after varying periods from 27-72 days. The Dacron used did not provoke sufficient tissue response to get it incorporated as a permanent structure.

Mukerjee *et al.* (1973) studied the usefulness of omentum in preventing leakage at the anastamotic site on oesophagus by providing a protective covering and also by revascularising the area. It was reported that silk was better than catgut for oesophageal surgery.

Smith (1973) described the indications and the techniques involved in both cervical and thoracic oesophagotomy and oesophageal resection. He opined that the use of an indwelling pharyngeal feeding tube was of considerable assistance in the postoperative care and in promoting healing after oesophageal surgery.

Reed (1974) reported that relatively large portion of posterior oesophagus could be resected and anastomosed without tension by bridging with a segment of small intestine.

Howard et al. (1975) reported clinical and experimental studies of oesophageal reconstruction in dogs using diaphragm, pericardium, intercostal muscle, polypropylene mesh, omentum and gastric tissue. The authors performed oesophageal patch grafting with sternothyroideus muscle. This technique had the advantage of providing a neovascular source, reinforcement to minimize wound leaking, absence of stricture formation and restriction to swallowing.

Lammerding et al. (1976) enumerated the conditions requiring oesophageal surgery as foreign body obstructions, perforations, diagnostic procedures, and for removal of strictures or benign neoplasms. The endogenous tissues used to effect closure of oesophageal defects included intercostal muscle, pericardium, fundic portions of stomach, portions of lung and diaphragm. He compared techniques of simple suturing and grafting using diaphragmatic pedicle grafts for repairing oesophageal defects in dogs. For smaller defects, both the techniques were successful, but in larger defects, simple suturing caused mediastinitis and pleuritis.

Gupta et al. (1978) treated experimentally created wound over the back of guinea pigs with chromicized collagen

prepared from the intestines of cattle. There was complete epithelisation of the wound with good supple scar. Collagen implant was well replaced with fibroblast, new blood vessels and epithelial cells.

Hugh et al. (1979), in an experimental study using pedicled full thickness gastric patches for 'oesophageal reconstruction cranial to diaphragm, demonstrated the occurrence of localized oesophagitis on use of patches containing parietal cell mucosa. Patches containing antral mucosa did not produce oesophagitis.

Gentry et al. (1981) studied the homeostatic effect of various collagen preparation and found that collagen had important role in coagulation by promoting the contact activation of coagulation mechanism and platelet activation and aggregation.

Pavletic (1981) reviewed the use of omental, fascial and dermal grafts, intercostal muscles, pericardium, diaphragm, jejunum, sternocephalicus and sternothyroideus muscles for repairing oesophageal defects in equines and dogs. He suggested a two staged reconstruction of the cervical oesophagus utilizing a cranial pedicled inverse tubed skin graft as a simple, economical and effective method in dogs.

Stick et al. (1981) reported oesophagostomy as a safe, method for extra oral alimentation in equines. Complications

associated with this procedure were usually not life threatening and responded to supportive therapy. Duration of feeding by oesophagostomy tubes beyond 10 days increased the healing time for the closure of the fistula, but did not increase the frequency of complications. The distal end of the feeding tube was to be located in the stomach to avoid serious complications associated with shorter feeding tubes.

Shetty et al. (1982) conducted an experimental study to compare the fate of fresh, formalin preserved, Tyrod's solution preserved and enzyme treated arterial xenograft in carotid artery of dogs on the basis of histopathological examination. The enzyme treated arterial graft was found to be the best vascular substitute. Tanning of the enzyme treated graft with glutaraldehyde increased the holding power of the graft and it incorporated well in the host tissue.

Taylor (1982) opined that an ideal graft should have both biocompatible and biodegradable properties. It should not be grossly rejected and create only minimum adhesions at the site of grafting. He stated that all implanted materials initially gave a foreign body inflammatory reaction associated with exudation and prominent lymphocytic infiltration. The vigor of this response was a measure of biocompatibility. After this initial phase there would be migration of macrophages and fibroblasts into the zone around the implant with vascularisation to form a typical granulation tissue. He also

reported that chronic bovine collagen was slowly absorbed due to slow rate of digestion of collagen by macrophages and giant cells. Glutaraldehyde processing of any allograft or xenograft reduced antigenicity and increased flex resistance.

Lantz et al. (1983) reported evidence of reflex oesophagitis as a sequelae to pharyngostomy tube placement when the tube entered the gastric lumen in dogs. Mechanical irritation from the tube caused erosion and ulceration of the oesophageal epithelium. He recommended the use of a soft tube and placing the distal end of the tube only as far anterior as mid thoracic region.

Clifford (1985) reported that ileum and jejunum could be used to replace resected oesophagus and mentioned that there was risk of peristalsis, leakage, pneumonia, empyaema, oesophagitis, stenosis, shock, pleuritis and peritonitis.

Crowe and Downs (1986) recorded complications with the use of pharyngostomy tubes in 64 out of 125 cases in dogs and cats. Complications were life threatening in sixteen and were associated with airway obstruction or aspiration pneumonia. The tubes were found to interfere with movement of epiglottis and caused partial obstruction of larynx. A modified technique of tube placement was developed in which the tube was placed in the pharynx in a more dorsal and caudal location closer to the origin of the oesophagus. Experimental and

clinical studies using the modified technique was found effective in preventing airway interference and respiratory complications. The aboral end of the tube terminated in the distal thoracic oesophagus to avoid complications like vomiting, oesophagitis, gastric dilatation and volvulus.

Frankland (1986) used porcine dermal collagen cross-linked with glutaraldehyde for repair of perineal hernia in dogs.

Todhunter *et al.* (1986) compared the effects of three feeding techniques viz. *per os*, by nasogastric, and by oesophagostomy, in healing of a cervical oesophageal mucosal resection and anastomosis in equines. Though the mucosal healing was faster in the group fed through oesophagostomy tube, survival rate was more in animals fed through nasogastric tube. Diameter of lumen at the surgical site decreased at 15 and 30 days but increased between 30 and 45 days postoperatively.

Daleck *et al.* (1987) reported an initial acute inflammatory reaction followed by connective tissue proliferation at the site of grafting on cervical oesophagus with fresh autologous peritoneum and peritoneal graft preserved in glycerin in dogs. The epithelium was found to extend to a major portion of the lesion by 15th day.

Kumar et al. (1987) evaluated quantitatively the progress of healing of skin wounds in dogs and buffaloes by estimating breaking strength, tensile strength, wound extensibility and energy absorption using a locally fabricated tensiometer.

Sawyer et al. (1987) studied the suitability of glutaraldehyde fixed bovine artery for peripheral vascular surgery in dogs.

Straw et al. (1987) harvested a section of transverse abdominis muscle fashioned into a tubular graft and vascularised via greater omentum. The tube was advanced into caudal thorax through the section of transverse abdominis muscle and 5 cm section of caudal thoracic oesophagus was replaced with it. They observed presence of granulation tissue at the interface of vascular skeletal muscle graft and oesophagus on 6th day of implantation. Infiltration of neutrophils and macrophages were noted. Marked diffuse fibrosis of the wall of the grafts and skeletal muscle fibres were recognised focally. At the site of anastomosis hyperplasia of the oesophageal epithelium extending on to the granulation tissue were evident. Patchy necrosis had occurred in the skeletal muscle, adipose tissue and peritoneum.

Gregory et al. (1988) replaced a segment of cervical oesophagus from pharynx to thoracic inlet in a dog using a segment of jejunum. They opined that free jejunal transfer

was satisfactory for treatment of otherwise fatal oesophageal lesions that did not respond to conventional methods of medical and surgical therapy. A pharyngostomy tube was maintained for 8 days as a conduit for enteral alimentation.

Kuzma *et al.* (1989) implanted an orthotropic colon graft based on the middle colic artery and vein using microvascular technique and a stapling instrument in five dogs. The grafts were successful in four dogs. A similar colon autograft was used to replace the entire thoracic oesophagus in five dogs. The recipient vessels were the left carotid artery and left external jugular vein. Four of the grafts failed because of kinking and thrombosis of the arterial supply (2 dogs) or the venous out flow (2 dogs). One graft which had a viable vascular supply developed a severe leak at the colon-to-stomach anastomosis, and the dog was killed on third day. The recipient vascular pedicle was modified and used successfully to replace a portion of the cervical oesophagus in three dogs. The grafts survived, the dogs could swallow liquids and semisolid food well, and at post mortem examination after four weeks, the anastamotic sites were well healed. The graft sites contained essentially normal colon mucosa.

Bojrab *et al.* (1990) reported the use of pedicle grafts from pericardium, omentum, diaphragm and gastric wall for patching oesophageal defects or for correction of stricture.

Naveenkumar *et al.* (1990) opined that silk is a better suture material than catgut for oesophageal anastomosis in dogs.

Smeak (1990) reported that "silastic tubing" and "rubber all purpose catheters" were the commonly used tubings for pharyngostomy. He also described a technique for fastening tubes and catheters to the skin for various procedures including pharyngostomy.

Amarpal *et al.* (1991) reported the application of free fascial grafts, autogenous skin grafts, colonic and jejunal segmental transplants and homogenous duramater grafts for repair of oesophageal defects in dogs. They performed successful oesophagoplasty using sternothyroideus muscle in dogs. The graft was sutured on oesophagus using through and through lock stitch pattern and complete healing of the site with regeneration of epithelium was observed by 60th day.

Holmberg *et al.* (1991) performed cervical segmental oesophagoplasty using microvascular colon transfer in dogs. The grafts remained viable and dogs were able to drink normally and swallow gruel from elevated bowls. Chronic regurgitation of solid food due to inadequate graft motility was an unresolved problem.

Amarpal *et al.* (1992) observed a gradual and significant increase in breaking and tensile strengths, extensibility and

energy absorption from 7th to 60th postoperative day following cervical oesophagoplasty with split sternothyroideus pedicle graft in dogs. The graft was infiltrated with large number of inflammatory cells on 7th day. Fibroblast proliferation, epithelization and vascularisation were observed on 15th and 30th day respectively. Thick bundles of collagenous fibres and muscular tissue of the graft were present on 60th day. However deposition of mucopolysaccharide was maximum at 7th day and gradually decreased by 60th day.

Sambandam (1992) revealed that chromicised collagen could be an ideal implant for cystoplasty because of reduced antigenicity, and better regeneration with minimal cellular infiltration. The healing process was characterised by well vascularised collagenous matrix and minimal cellular reaction where collagen was used.

Rameshkumar (1993) performed experimental cystoplasty using graft prepared out of autogenous peritoneum, chromicised allogenic bladder, and glutaraldehyde processed human amniotic membrane. The autogenic peritoneal graft caused better tissue regeneration, chromicised allogenic bladder graft produced moderate healing while the chemically modified xenogenic amniotic membrane graft showed incomplete healing.

Slatter (1993) suggested parenteral feeding for a minimum of seven days postoperatively following patch grafting of

oesophagus. He recommended gastrostomy or jejunostomy instead of pharyngostomy tube feeding for alimentation.

Nimni and Cheung (1994) stated that the collagen network can be crosslinked using a chromium salt, tannin or aldehyde. The animal tissue is preferably from tendon, heart valve, pericardium, ligament, skin, blood vessel, fascia, cartilage or intestine.

Ruijgrok et al. (1994) reported that glutaraldehyde cross linking of collagenous tissue is a widely used method for the preparation of implantable tissues to be used as biomaterials.

Amarpal et al. (1995) conducted experimental oesophago-plasty with free gastric seromuscular graft in 12 dogs. The animals were destroyed 7, 15, 30 or 60 days later. Breaking strength, tensile strength, extensibility and energy absorption of oesophagoplasty sites increased upto day 60. Histopathological and histochemical studies revealed early infiltration of polymorphonuclear leucocytes and lymphocytes followed by gradual increase in collagenous fibres. Epithelialization of grafted site was completed by day 30. On day 60, stratified epithelium was observed at the grafted site but oesophageal glands were not evident in this region. It was concluded that seromuscular free graft induced good healing of cervical oesophageal wall defects.

Mohanty (1995) suggested that the tissue response to implants and their functional acceptance were important modalities of biological evaluation of prosthetic materials. The studies comprised of surgical implantation of materials in soft or hard tissues followed by gross and microscopical evaluation of the response of surrounding tissue at different time intervals.

Ortan and McCracken (1995) reported the use of diaphragmatic pedicle graft for patching the caudal thoracic oesophagus. The diaphragmatic pedicle grafts were used as an onlay graft to reinforce an oesophageal incision and as an inlay graft in oesophagoplasty for relief of oesophageal stricture.

Santillan *et al.* (1995) employed pericardial tissue preserved in 0.5 per cent glutaraldehyde for reconstruction of surgical defects in the thoracoabdominal wall in dogs. The prosthetic material showed a higher tensile strength but a similar per cent elongation in comparison to synthetic mesh samples. The dogs showed good tolerance and the histopathology revealed formation of fibroblast layer with collagen deposits and development of scar tissue.

Jayakrishnan and Jameela (1996) reported glutaraldehyde as a versatile cross linking agent of great value in the preparation of bioprostheses with heart valves, vascular

grafts, elastic cartilages, tendon xenografts, artificial skin, pericardial patches and burn dressings. Glutaraldehyde cross linking of collagenous tissue significantly reduce biodegradation, making them biocompatible, nonthrombogenic and nonantigenic while preserving anatomic integrity, leaf let strength and flexibility.

Devitt and Seim (1997) described an alternative method for placement of oesophagostomy in small animals. The mean duration of tube placement was 23 days. No significant complication related to the tube was noted. The tube was well tolerated by the animals and the time for healing of the esophagostomy site following tube removal was less than two weeks.

Materials and Methods

CHAPTER-III
MATERIALS AND METHODS

Plan of study

The experimental study was conducted in thirty apparently healthy adult mongrel dogs of either sex weighing 9-13 kg. All the animals were housed in separate kennels, under identical conditions of feeding and management. All the dogs were dewormed and kept under observation for a period of 10 days prior to the experiment.

The animals were randomly divided into three groups viz. group I, group II and group III.

The programme of study was as given hereunder:

Group I

This group had six animals and they were subjected to sham operation. Effects of modified method of pharyngostomy were studied in three animals of this group. Pharyngostomy was performed on the left side and the tube was retained for parenteral feeding for 15 days.

Group II

This group consisted of 12 animals and they were divided into two sub groups (IIA and IIB) of 6 animals each and the experiments were as follows.

- IIA. Cervical oesophagoplasty of an experimentally created defect using chrome processed homologous aortic graft.
- IIB. Cervical oesophagoplasty of an experimentally created defect using chrome processed homologous aortic graft. Pharyngostomy was performed on the left side of pharynx.

Group III

This group consisted of 12 animals and were divided into two sub groups (IIIA and IIIB) of 6 animals each and the experiments were as follows.

- IIIA. Cervical oesophagoplasty of an experimentally created defect using glutaraldehyde processed homologous aortic graft.
- IIIB. Cervical oesophagoplasty of an experimentally created defect using glutaraldehyde processed homologous aortic graft. Pharyngostomy was performed on the left side of the pharynx.

Preparation of graft

Thoracic aorta to a length of 12 cm was harvested from euthanised dogs, washed with sterile normal saline and then stored in sterile bottles containing isotonic saline. The tissue samples were processed at Bioproducts Laboratory, Central Leather Research Institute, Adayar, Madras.

Processing

The tissues were made into sheet form and were washed thoroughly in running water to remove the blood. The capillaries and adhering fat tissues, if any, were removed manually, followed by double washing in distilled water.

Cross linking with basic chromium sulfate

The prepared tissues were treated for three hours with occasional stirring in 0.4 per cent (w/v) basic chromium sulfate in aqueous solution containing 0.5 per cent (w/v) sodium chloride. The pH was maintained at 3.2.

Cross linking with glutaraldehyde

The prepared tissues were treated for three hours with 0.5 per cent (v/v) glutaraldehyde solution (25%) in an aqueous medium containing 0.5 per cent sodium chloride and 0.01 per cent (w/v) sodium acetate. The pH of the solution was

adjusted to 6.5 to 7.0 and the material was stirred occasionally.

The sheets thus prepared were aseptically, sealed in polythene covers in 98 per cent isopropanol as preservative (Fig.1 and 2) and sterilised in gamma irradiation chamber at 2 M rads dose (Sastry, 1989) at Radiotracer Laboratory, Kerala Agricultural University, Vellanikkara.

Preparation of Pharyngostomy tube

Siliconised Catheter* made of modified polyvinyl chloride (outer diameter of 7 mm) with an attached X-ray opaque line was used as pharyngostomy tube. The catheter was modified by fixing a cap at the proximal end (Fig.3). The length of the pharyngostomy tube was premeasured for individual animals, spanning the distance from the point of insertion to 8th rib so that the aboral end of the pharyngostomy tube terminated at the distal thoracic oesophagus (Lantz et al., 1983).

Preoperative considerations

All the animals were starved for 24 hours and water was withheld for 12 hours prior to surgery. All the animals were given luke warm soap water enema 3 hours prior to surgery.

* Nelaton Catheter - Sterimed surgical and General Industries, New Delhi

The animals were secured on dorsal recumbency. The skin over the ventral cervical region was shaved, washed with soap and water, mopped, applied 70 per cent alcohol and painted with Tr. Iodine.

Anaesthesia

The animals were premedicated with triflupromazine hydrochloride* at the rate of 1 mg/kg body weight given I.M. Fifteen minutes later, thiopentone sodium** 5 per cent solution was administered intravenous to effect anaesthesia.

Surgical technique

Oesophagoplasty

The animal was secured on dorsal recumbency with the neck supported by sand bags placed underneath it in such a manner that the operative site was slightly convex. The site was suitably draped. A 6 cm long midline incision was made at the mid cervical region. Following the application of the skin drapes, connective tissue was dissected to free the skin from the underlying musculature. The line of cleavage between the two bands of *M. sternothyroideus* was incised and enlarged by

* Siquil - (Vety) - Triflupromazine hydrochloride - 20 mg/ml, Sarabhai Chemical, Baroda, India

** Intraval sodium - Thiopentone sodium injection I.P., Rhone-Poulenc (India) Ltd., Bombay.

blunt dissection to expose the trachea. The oesophagus was located by deeper dissection and the sides were packed with sterile towels. Two pieces of silk threads were passed around the organ, one anterior and one posterior to the proposed site for creating the defect and thus the lumen was occluded (Smith, 1973).

The oesophageal wall measuring 3-4 cm in length and 1/3rd of its circumference was surgically removed to create the defect (Fig.4). The graft material was kept ready by washing with three changes of sterile normal saline solution. A final irrigation and immersion in 150 ml of sterile normal saline was carried out before use. The graft material was trimmed to oval shape, sufficient enough to cover the defect. It was fixed over the wound edges using 5/0 braided silk thread by through and through continuous locking sutures (Fig.5). The threads placed for holding the oesophagus were removed. The cervical muscles and skin incision were approximated in the routine manner using 1/0 braided silk thread and monofilament nylon respectively.

Pharyngostomy

An area posterior to the mandible on left side was prepared for aseptic surgery. After the oesophagoplasty, the animal was kept on right lateral recumbency protecting the cervical skin wound. The mouth of the animal was held open by Grays mouth gag. The gloved index finger was inserted into

the mouth to reach the junction of intrapharyngeal ostium and the laryngopharynx. The index finger was pushed laterally to form an external bulge in that region. Later on, the index finger was substituted by a large curved artery forceps to maintain the bulge. Using a surgical blade a nick incision was made through the skin at the centre of this bulge. The artery forceps was pushed through the nick incision to reach outside. The pharyngostomy tube was grasped with the forceps at its beaded end, drawn into the pharynx via pharyngostomy incision and pushed into the oesophagus eliminating any chance of laryngeal obstruction and interference for movement of epiglottis (Crowe and Downs, 1986) (Fig.6).

Externally the tube was anchored to the skin by passing No.1 braided silk thread subcutaneously and knotting it to the cap of the pharyngostomy tube (Smeak, 1990). The tube was closed with the cap.

Sham operation

Under general anaesthesia, and aseptic precautions as in oesophagoplasty, a 6 cm long skin incision was made at the mid cervical region. The underlying connective tissue and muscles were dissected to expose the oesophagus. The cervical muscles and skin incision were approximated in routine manner.

Post surgical management

Tr. Benzoin seal was applied over the suture line at the cervical region, the neck was well padded with cotton and bandaged including the pharyngostomy tube. The wound was cleaned daily using Povidone Iodine* solution, smeared with Povidone Iodine* ointment and bandaged till the healing was complete.

The pharyngostomytube-skin interface was examined daily for any evidence of bleeding, leakage of food, saliva or both and infection. After the removal of the tube, the tube-skin interface was cleaned with Povidone Iodine* solution daily till the complete healing of the pharyngostomy incision

Gentamicin** at the rate of 8 mg/kg body weight was administered intramuscular daily for seven days postoperatively.

In animals without pharyngostomy, Dextrose in normal saline solution at the rate of 30 ml/kg body weight was

-
- * Betadine lotion/cream - Povidone Iodine - IP-5%
Win-Medicare (Ltd), New Delhi
- ** Gen - Gentamicin 80 mg/2 ml
Blue Shield (Pvt) Ltd. Bombay,
India

administered intravenous, in divided doses, two times a day, for the first seven days postoperatively. The animals were fed on liquid food containing glucose powder, rice porridge, milk and an egg in the second week, bread soaked in milk and boiled atta for third week and regular diet there after.

In animals with pharyngostomy, feeding through pharyngostomy tube was started the next day after surgery. Liquid food comprising of milk, rice porridge, glucose powder and an egg was slowly administered through the tube initially at half strength (diluted) for three times a day. The strength and volume was increased gradually as gastrointestinal tolerance (absence of colic, diarrhoea or vomiting) allowed. Once the animals were tolerant, they were fed fluid diet at full strength, twice daily for 15 days postoperatively. From 15th day onwards, animals were maintained as in other groups.

The cutaneous sutures were removed by 7th to 10th post operative day. The pharyngostomy tube was removed on 15th day, after cutting the anchoring sutures. The wound was allowed to heal by second intention.

Blood samples were collected preoperative and on second, seventh and fifteenth day postoperatively for haematological and biochemical studies. All the animals were kept under observation for a maximum period of 60 days.

Main items of observation

I. Clinical observation

General condition

Active, dull, depressed, dehydrated.

Clinical evaluation of wound

Clinical evaluation of oesophagoplasty was made on the basis of wound inflammation, fistulation, infection, granulation and closure of stoma.

Clinical evaluation of pharyngostomy wound was done daily. The methodology for pharyngostomy was evaluated observing the following parameters.

- a. Ease of management and feeding
- b. Reflux of ingesta around the tube
- c. Obstruction of the tube with ingesta
- d. Tolerance of the tube by the animal
- e. Dislodgement of the feeding tube
- f. Tube related complications
- g. Time for stomal healing following tube removal

Feeding behaviour

Normal, reluctant, painful

II Physiological parameters

Rectal temperature ($^{\circ}\text{C}$), pulse rate, respiration rate, colour of mucous membrane, capillary refill time, skin elasticity test and other observations if any, were recorded preoperative and daily upto seventh postoperative day.

III Haemogram

Blood smears were prepared and venous blood samples were collected in EDTA* on the preoperative day and on 2nd, 7th and 15th day postoperatively for estimation of the total erythrocyte count (TEC), total and differential leucocyte counts (TLC and DC), erythrocyte sedimentation rate (ESR) and packed cell volume (PCV) (Schalm, 1975). Haemoglobin concentration was estimated by cyan-methemoglobin method (Jain, 1986) using Digital haemoglobinometer 185.

IV Serum constituents

- a. Total serum protein and albumin content were estimated by total protein and albumin kit** (biuret method - Inchiosa, 1964) using spectrophotometer model CL-27.

* EDTA - EDTA Disodium Salt (Nice laboratory reagent), New India Chemical Enterprises, Kochi

** Total protein and albumin kit - Sigma Diagnostics (India) Pvt. Ltd., Baroda, India

- b. Serum globulin content and Albumin/globulin ratio were derived from the values of total serum protein and albumin.
- c. Serum sodium and potassium concentrations were estimated using atomic absorption spectrophotometer (Perkin Elmer - Model 2380).
- d. Serum chloride concentration was estimated by chloride kit* based on modified Schoenfeld and Lewellen's Colorimetric method using spectrophotometer model CL-27.

V Radiological studies

Cervical portion of oesophagus of dogs were radiographed on preoperative day and on 15th, 30th and 60th day postoperatively. The study included a lateral survey radiograph and barium meal oesophagogram to assess seepage, mucosal details, extramural and intramural details and adhesion, if any.

VI Terminal findings

Two animals from each subgroup were sacrificed on 15th, 30th and 60th day postoperatively. Cervical oesophagus was exposed and examined

* Serum chloride kit - Dr. Reddy's Laboratories
Hyderabad, India

grossly, for adhesions with the surrounding tissue or muscles and evidence of leakage or fistula. The whole oesophagus, from pharynx to cardia was harvested, cleaned and washed in normal saline. It was incised longitudinally along its dorsal wall. Gross morphological examination of the oral, pharyngeal and entire oesophageal mucosa (cervical, midthoracic, posterior thoracic and intraabdominal) was done, to assess the effect of placement of pharyngostomy tube.

VII Biomechanical studies

Biomechanical studies of chrome and glutaraldehyde processed graft materials (6 samples each), normal oesophagus harvested from control animals and the grafted site on the oesophagus collected from three animals of each subgroup sacrificed on 15th, 30th and 60th day postoperatively were conducted. The following parameters were studied using "disruption from without method" which involves application of a force to a tissue edge while the opposite edge is fixed (Al-Sadi and Gourley, 1977).

- a. Breaking strength (Load - N): The force required to disrupt a tissue regardless of its cross sectional area.
- b. Tensile strength (stress - N/mm^2): The force required to disrupt the tissue per unit cross sectional area.

- c. Extensibility (Extension - %): The degree to which a tissue stretches before it disrupts.
- d. Energy absorption (Toughness - Nm): The work per unit tissue volume required to disrupt a tissue.

Dumb bell shaped specimens of 65 mm length were punched out from the samples. The thickness and width at the centre of the dumb bell shaped specimen were measured using a screw gauge. The mechanical properties were measured using universal testing system (ZWICK-1484) at Fishing Technology Division, Central Institute of Fisheries Technology, Kochi.

- e. Total dilatation capacity (per cent) was assessed by the following procedure. One end of the tubular oesophagus was closed using a long artery forceps and the lumen was filled with water under pressure for getting maximum dilatation. The outer diameter (OD) was measured horizontally across the grafted site and the adjacent normal oesophagus. Total dilatation capacity (per cent) was derived from these values.

VIII Gross morphological examination

Healing at the oesophagoplasty site was evaluated based on

- a. Colour and appearance of the grafted site
- b. Degree of epithelization
- c. Degree of absorption of suture material
- d. Any other complication in healing

IX Histomorphological examination

The healing tissues collected from the junction of oesophagus and graft were subjected to histomorphological examination. The specimen was fixed in 10 per cent neutral buffered formol saline and processed. Sections were cut and stained with Ehrlich's haematoxylin and eosin for routine observation, Verhoeff's method for elastic fibers and Van Gieson's stain for collagenous fibres (Bancroft and Cook, 1984).

Statistical analysis

The data obtained in all the groups were analysed using analysis of covariance test and the means were compared with presurgical values (Snedecor and Cochran, 1967).

Fig.1 Polythene sachet containing chrome processed graft material preserved in Isopropanol and a grossspecimen of aortic tissue

Fig.2 Polythene sachet containing glutaraldehyde processed graft material preserved in Isopropanol and a grossspecimen of aortic tissue

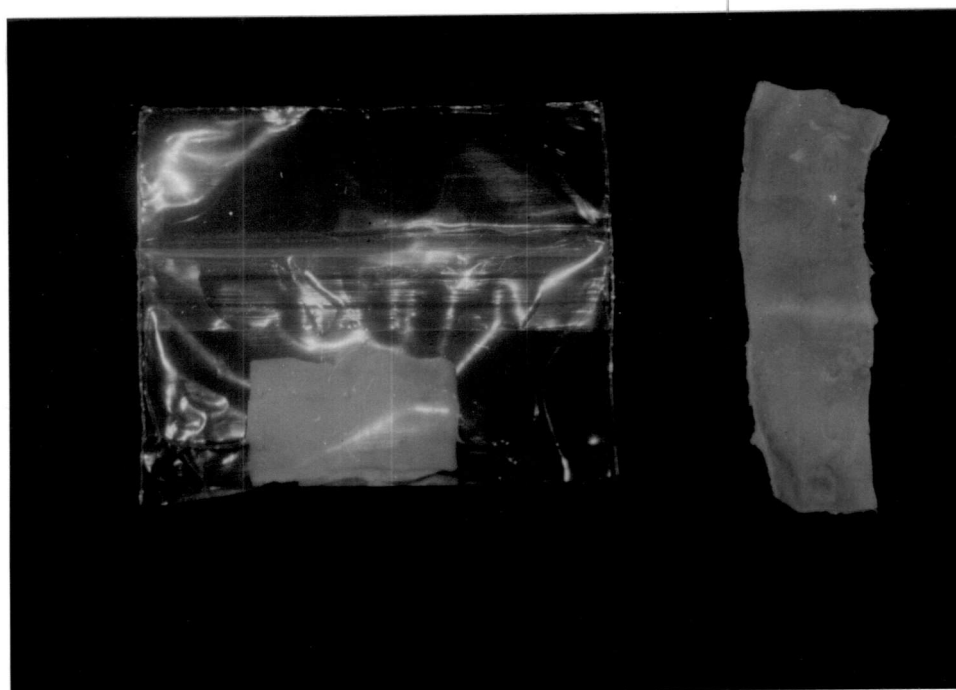
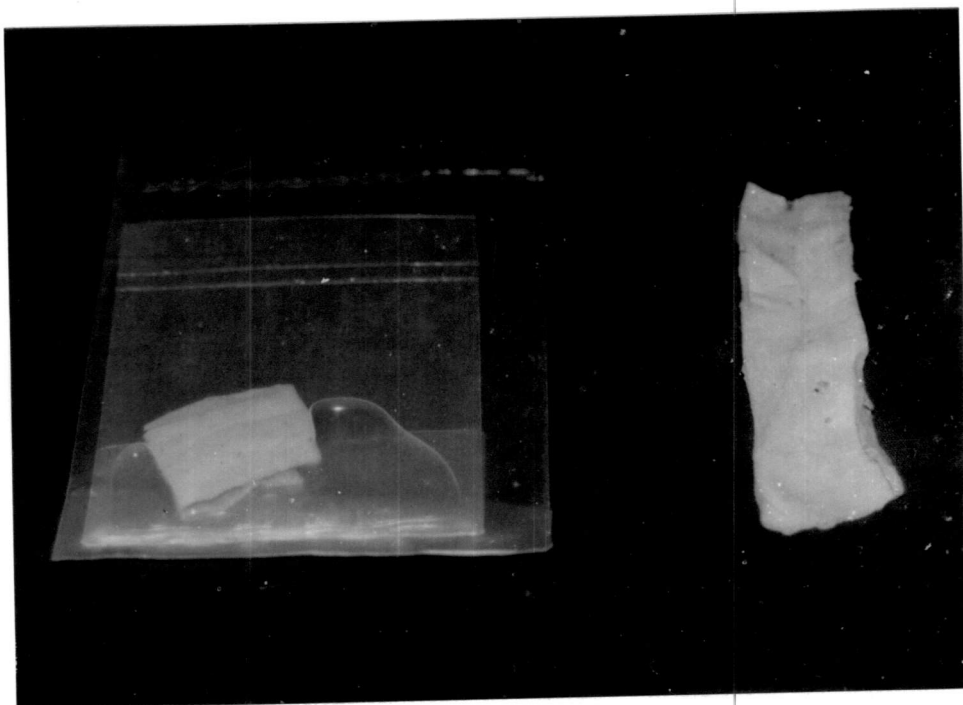

Fig.3 Pharyngostomy tube made up of modified polyvinyl chloride

Fig.4 Cervical oesophagus with experimentally created defect on the ventral aspect

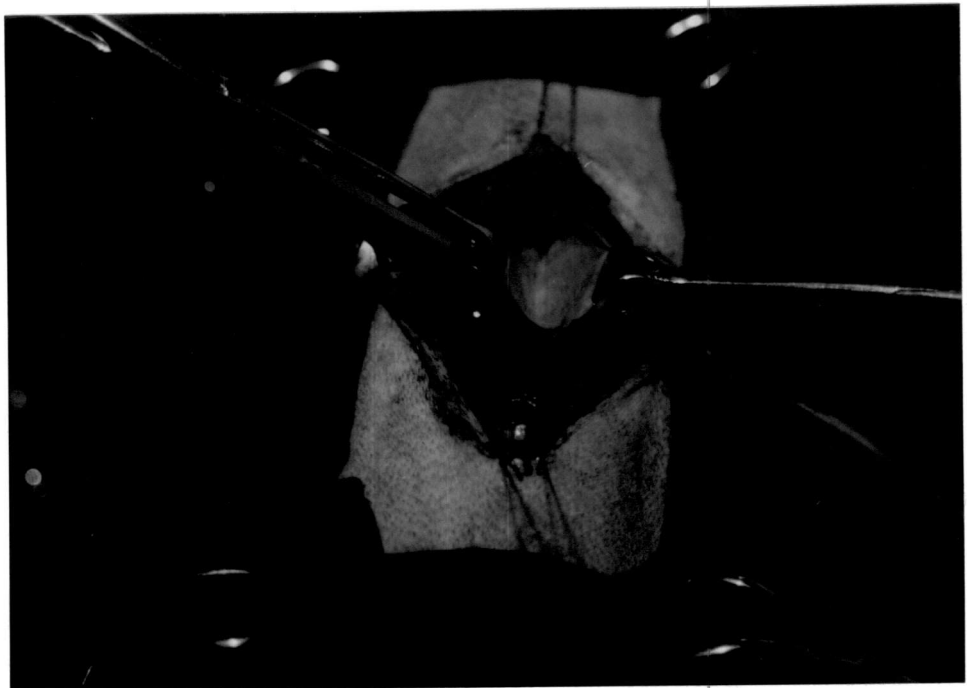
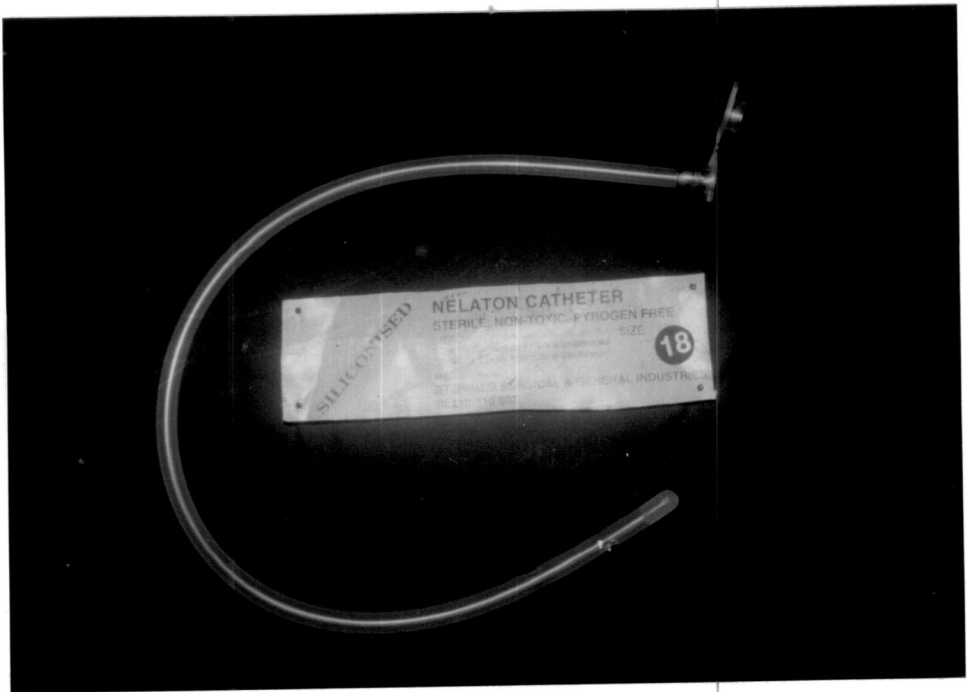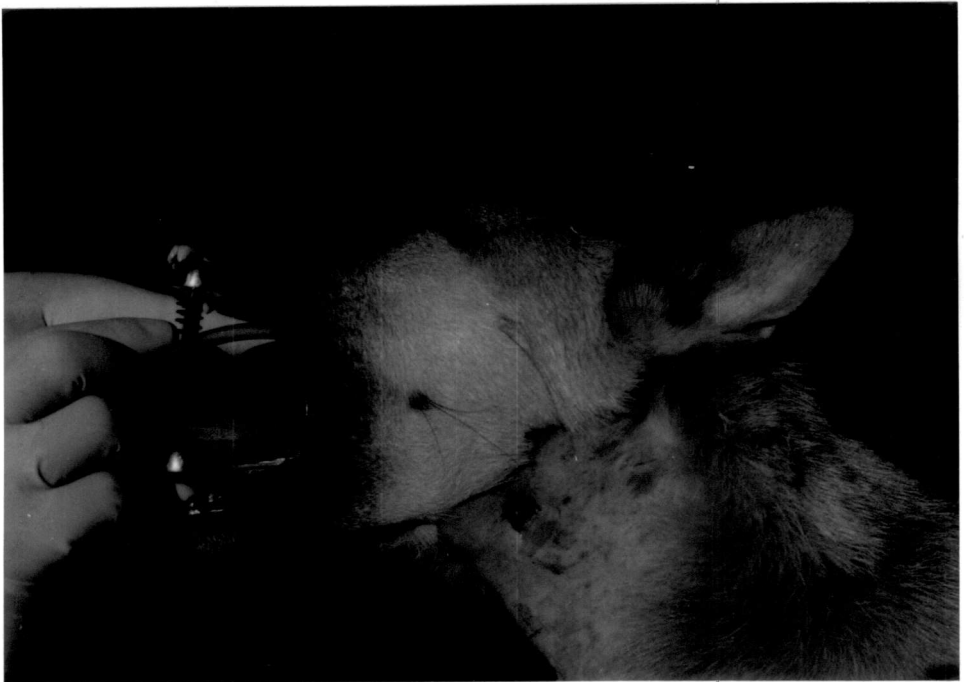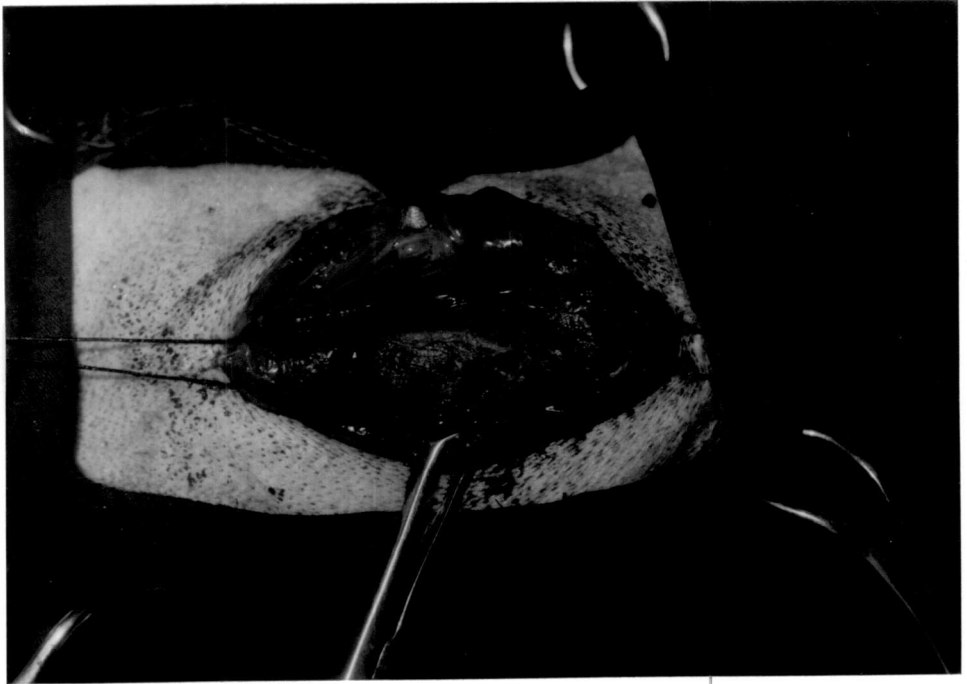


Fig.5 Oesophagus after reconstruction using the oval shaped graft

Fig.6 Installation of pharyngostomy tube by modified method



Results

CHAPTER-IV

RESULTS

GROUP-I

CONTROL ANIMALS

The observations are presented in Tables 1 to 4.

Preoperative considerations

The average body weight (kilogram) of the animals was 9.67 ± 0.94 . The animals were premedicated with triflupromazine hydrochloride (9.67 ± 0.94 mg) and anaesthetised using thiopentone sodium (249.17 ± 36.25 mg) to effect.

Clinical observations

General condition

All the dogs were alert and active within 24 h. postoperatively.

Clinical evaluation of wound

Moderate pain, slight swelling and inflammatory oedema were observed at the operated site in the cervical region in all dogs by the second postoperative day. The inflammatory

reaction gradually subsided and disappeared completely by 15th day. Skin wound showed normal healing and sutures were removed by 7-8th day postoperatively.

Mild swelling observed around the pharyngostomy tube entrance site for 2-3 days postoperatively, subsided spontaneously. No leakage of food or saliva was noticed at the tube entrance site. After the removal of the tube on 15th day, the wound healed by formation of a crust over the opening. The crust got detached by 7-10 days and a healthy pink epithelium was noticed (Fig.7). Wound healed completely by 14-15th day after tube removal. Tolerance of pharyngostomy tube was excellent in all the animals.

Feeding behaviour

The dogs in which sham operation alone was performed, parenteral alimentation through intravenous route was adopted for the first seven days postoperatively and oral feeding thereafter. The dogs which had undergone pharyngostomy were maintained on parenteral alimentation through pharyngostomy tube for the first 15 days postoperatively and oral feeding thereafter.

The dogs which had undergone sham operation were started on liquid food by seventh day and the animals maintained normal appetite and feeding habits throughout the period of observation. Initial tube obstruction during first feeding

through pharyngostomy tube was experienced in two dogs (C 4 and C 6). It was resolved by slow administration of fluid diet initially. On certain occasions, pharyngostomy tube feeding on standing position caused immediate expulsion of fluid through the tube. So animals were made to sit on haunches with their head in upright position while feeding. No cough or gag was observed while feeding. Mild diarrhoea noticed in one dog (C 4) on 3rd-4th day postoperatively, was treated and maintained under restricted feeding. All dogs started feeding on normal diet by 15th day and maintained normal appetite and feeding habits throughout the period of observation.

Other observations

Observations on physiological parameters, haemogram, and serum constituents are presented in Tables 1-3.

Variations observed at different intervals was marginal and non-significant for all parameters except that of total serum protein content, serum globulin content and albumin globulin ratio.

Total serum protein content (g/l) was 61.27 ± 1.87 before anaesthesia. There was a significant increase ($P < 0.05$) on second and seventh day postoperatively followed by a decrease to reach near normal level on 15th day.



Serum globulin content (g/l) was 36.55 ± 1.73 before anaesthesia. There was a significant increase ($P < 0.05$) on second and seventh day postoperatively followed by a decrease to reach near normal level on 15th day.

Albumin globulin ratio was 0.68 ± 0.05 before anaesthesia. There was a significant decrease ($P < 0.05$) on second and seventh day postoperatively followed by an increase to reach near normal level on 15th day.

Qualities of graft materials

Physical and biomechanical characteristics of oesophagus and graft materials are presented in Table 4.

Colour

Chrome processed aortic tissue was grey in colour, whereas glutaraldehyde processed aorta was creamy white in colour.

Texture

Both the graft materials were having relatively low flexibility than normal oesophagus.

Thickness

Chrome processed aortic tissue was slightly thicker than glutaraldehyde processed tissue.

... was 38.55±1.73 ...
... (P<0.05) ...
... by a decrease ...
... to reach ...

... the anaesthesia ...
... on second and ...
... to reach ...
... near normal ...
... of graft ...

... of esophagus ...
... presented in ...
... and graft ...

Color ...
... in colour ...
... processed ...
... white ...

Texture ...
... relatively low ...
... as normal esophagus ...

... processed ...
... processed ...
... processed ...

Width

Width of the graft materials was sufficient enough to cover a defect of a size of 1/3rd of the circumference of cervical oesophagus in dogs (Fig.8).

Shelf life

Graft materials preserved for a period of 15-20 months were used in the present study.

Biomechanical characteristics

Chrome processed aortic tissue had relatively higher breaking strength, extensibility, energy absorption and a low tensile strength than that of glutaraldehyde processed material. Compared to oesophagus, the graft materials were poor in strength but the extensibility was 50-75 per cent of that of normal oesophagus.

Histomorphological characters

The graft materials revealed abundant quantity of elastic fibres reinforced with collagen fibres arranged in a regular fashion (Fig.9).

Table 1. Rectal temperature, pulse rate and respiration rate in control group of animals Mean \pm SE

Parameters with units	Pre-operative	Postoperative intervals (days)						
		1	2	3	4	5	6	7
Rectal temperature (°C)	39.06 \pm 0.16	39.13 \pm 0.21	39.06 \pm 0.16	38.59 \pm 0.16	38.72 \pm 0.13	38.82 \pm 0.06	38.83 \pm 0.22	38.96 \pm 0.06
Pulse rate (per min.)	89.33 \pm 4.06	85.83 \pm 6.36	88.67 \pm 6.10	88.67 \pm 5.44	83.67 \pm 3.96	83.67 \pm 5.81	77.50 \pm 2.54	79.83 \pm 0.17
Respiration rate (per min.)	21.67 \pm 1.52	21.50 \pm 2.22	23.33 \pm 1.02	21.17 \pm 1.22	20.83 \pm 0.83	21.17 \pm 0.17	21.67 \pm 1.49	21.50 \pm 0.92

Director's Office

Page 1

(Date)

Handwritten initials and markings

0100 0.52 3070

0100 0.52 3070

0100 0.52 3070

Handwritten notes at the bottom left

Table 2. Haemogram in control group of animals (Mean±SE)

Parameters with units	Pre-operative	Postoperative intervals (days)		
		2	7	15
Haemoglobin concentration (g/dl)	11.13± 0.89	11.57± 0.64	10.90± 0.91	11.05± 0.97
Erythrocyte sedimentation rate (mm/h)	2.00± 0.26	2.17± 0.31	2.17± 0.48	2.33± 0.42
Packed cell volume (%)	34.50± 2.93	33.50± 2.72	33.50± 2.74	33.00± 2.92
Total erythrocyte count (10 ⁶ /mm ³)	4.99± 0.45	4.10± 0.58	4.65± 0.61	4.86± 0.57
Total leucocyte count (10 ³ /mm ³)	09.18± 1.36	10.67± 1.60	10.80± 1.72	9.89± 1.28
Neutrophil count (%)	66.00± 1.51	66.33± 2.49	72.00± 3.73	66.00± 1.71
Lymphocyte count (%)	30.67± 1.26	31.00± 2.53	26.33± 3.58	31.83± 1.62
Monocyte count (%)	2.17± 0.95	1.33± 0.56	1.67± 0.80	1.67± 0.72
Eosinophil count (%)	1.17± 0.75	1.33± 0.80	0.00	0.50± 0.22
Basophil count (%)	0.00	0.00	0.00	0.00

Table

Year	Area	Value	Unit	Description
1951
1952
1953
1954
1955
1956
1957
1958
1959
1960
1961
1962
1963
1964
1965
1966
1967
1968
1969
1970

Additional notes and data at the bottom of the page, including a large handwritten number '1000'.

Table 3. Serum constituents in control group of animals (Mean±SE)

Parameters with units	Pre-operative	Postoperative intervals (days)		
		n=6		
		2	7	15
Total serum protein (g/l)	61.27± 1.87	* 69.23± 2.04	* 67.81± 0.49	62.15± 2.52
Serum albumin (g/l)	24.73± 1.07	23.11± 0.49	24.58± 0.37	24.57± 0.69
Serum globulin (g/l)	36.55± 1.73	* 46.12± 2.23	* 43.23± 0.58	37.58± 1.94
Albumin-Globulin ratio	0.68± 0.05	* 0.51± 0.03	* 0.57± 0.01	0.66± 0.22
Serum sodium (mmol/l)	102.04± 3.67	100.59± 1.84	101.49± 3.11	98.77± 3.29
Serum potassium (mmol/l)	5.89± 0.22	5.94± 0.25	6.23± 0.26	5.91± 0.28
Serum chloride (mmol/l)	112.22± 1.41	108.14± 2.03	112.39± 2.17	110.96± 0.94

* Significant (P<0.05)

Table 4. Physical and biomechanical characteristics of normal oesophagus, chrome and glutaraldehyde processed aortic tissue of dogs (Mean \pm SE)

n=6			
Parameters with units	Normal oesophagus	Chrome processed aorta	Glutaraldehyde processed aorta
Colour		Grey	Creamy white
Texture		Moderately flexible	Slightly flexible
Thickness (mm)	2.52 \pm 0.63	1.22 \pm 0.03	1.08 \pm 0.04
Width (cm)	4.64 \pm 0.48	2.43 \pm 0.02	2.32 \pm 0.04
Tensile strength (N/mm ²)	12.03 \pm 2.73	0.93 \pm 0.20 (7.74%)	1.17 \pm 0.23 (9.73%)
Breaking strength (N)	128.19 \pm 13.16	8.23 \pm 1.21 (6.42%)	8.09 \pm 0.59 (6.31%)
Extensibility (%)	31.42 \pm 2.58	23.87 \pm 16.23 (75.97%)	14.95 \pm 5.59 (47.58%)
Energy absorption (Nm)	1.35 \pm 0.22	0.09 \pm 0.03 (6.67%)	0.06 \pm 0.02 (4.44%)

Statistics of normal
 processed sorbitol

(18)

Glucose	Normal	Processed
1.06	1.06	1.06
0.04	0.04	0.04
1.17	1.17	1.17
0.22	0.22	0.22
8.92	8.92	8.92
0.59	0.59	0.59
(6.31)	(6.31)	(6.31)
14.88	14.88	14.88
2.88	2.88	2.88
(47.88)	(47.88)	(47.88)
0.04	0.04	0.04
0.02	0.02	0.02
(4.14)	(4.14)	(4.14)

Fig.7 Pharyngostomy tube entrance site, 14-15 days after removing the tube

Fig.8 Gross specimen: Normal oesophagus, and graft material showing the size sufficient enough for covering larger defects on oesophagus

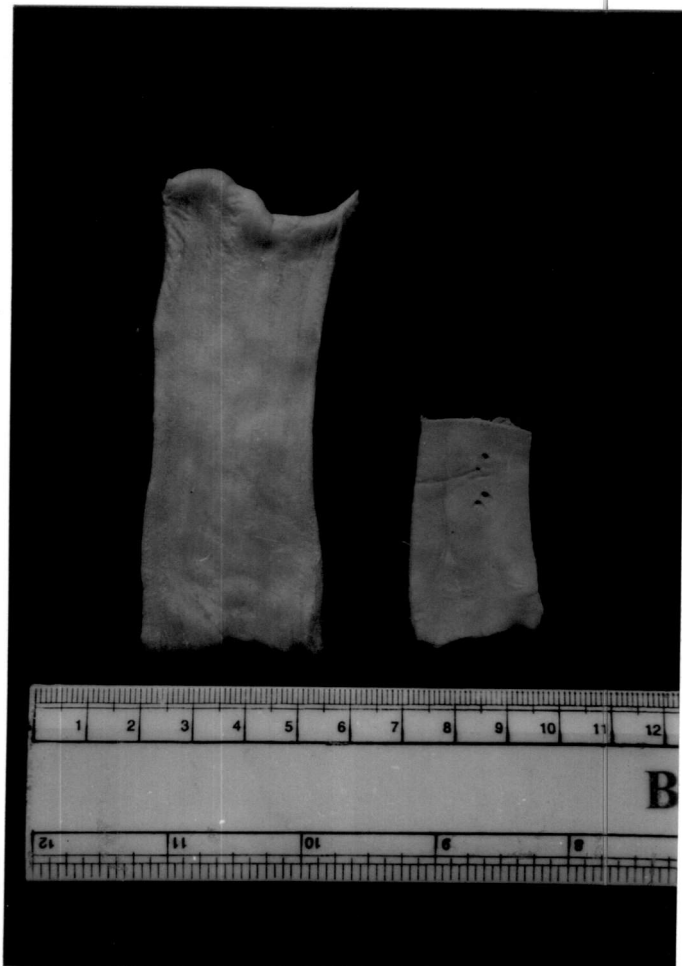
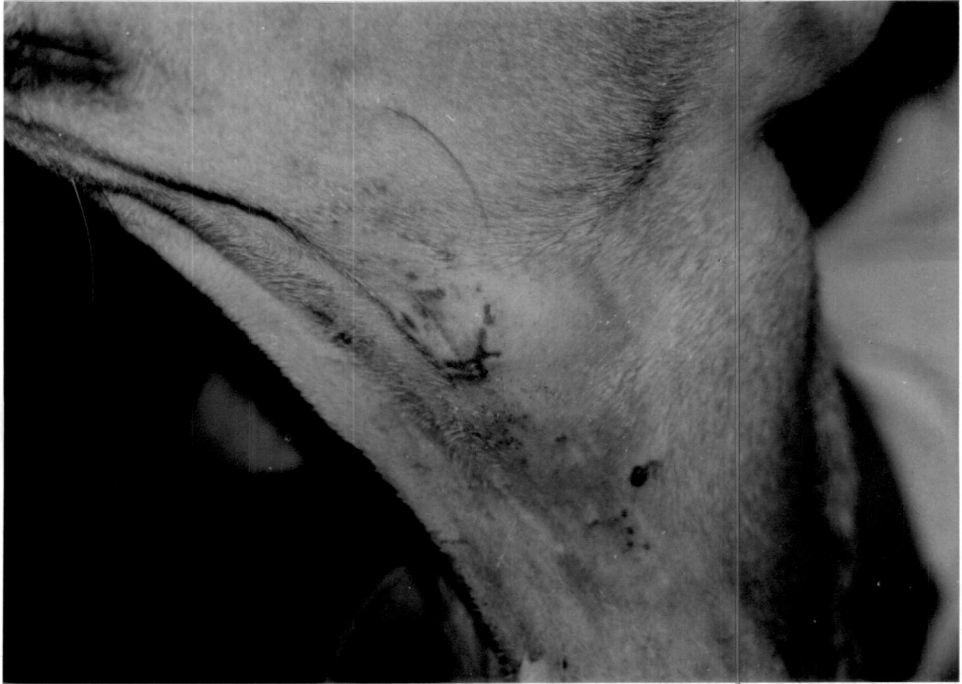


Fig.9 Photomicrograph: Histomorphology of graft material showing abundant quantity of elastic fibres reinforced with collagen fibres arranged in a regular fashion. (H&E) 20x



GROUP-II

SUBGROUP-II A

The observations are presented in Tables 5 to 8.

Preoperative considerations

The average body weight (kilogram) of the animals was 11.58 ± 1.38 . The animals were premedicated with triflupromazine hydrochloride (11.58 ± 1.38 mg) and anaesthetised using thiopentone sodium (340.00 ± 31.62 mg) to effect.

Clinical observations

General condition

All the dogs became alert and active by 2.67 ± 0.42 days postoperatively.

Clinical evaluation of wound

Moderate pain, slight swelling and inflammatory oedema were observed at the operated site in the cervical region by the second postoperative day in all the dogs. The inflammatory reaction gradually subsided and disappeared completely by 3-4 days postoperatively. Skin wound showed normal healing and sutures were removed by 7-8th day in five dogs. One dog (E 4), mutilated the suture line, and the wound

was resutured. The sutures were removed after healing of the wound on ninth day postoperatively.

Feeding behaviour

All the dogs started feeding on liquid food by seventh day and maintained normal appetite and feeding habits throughout the period of observation. Two dogs (E, 1 and E 2) showed mild swelling below the operated site while swallowing, but on restricted feeding it subsided after 4 days. One dog (E 4) vomited once on second day.

Physiological parameters

Rectal temperature ($^{\circ}\text{C}$) was 39.19 ± 0.18 before anaesthesia. After a marginal increase on first day postoperatively, the rectal temperature decreased gradually to a significant level ($P < 0.05$) on sixth day. A marginal increase was noticed on seventh day.

Pulse rate (per min) was 83.33 ± 2.92 before anaesthesia. There was a marginal increase in pulse rate on first day postoperatively and thereafter the value remained at a lower level through out the period of observation.

Respiration rate (per min) was 24.83 ± 1.97 before anaesthesia. After a gradual decrease till third postoperative day, the respiration rate remained at a lower level with marginal variation during the period of observation.

The conjunctival mucosa was slightly pale during 2-3 days postoperatively in all the dogs. By seventh day the mucous membrane in all the animals became normal.

The capillary refill time was less than one (sec) in all the dogs before anaesthesia. Prolongation in time was observed by second day which was followed by a decrease reaching near normal values by seventh day postoperatively.

The time taken for the skin to return to its normal position was less than one second in all the dogs, before anaesthesia. The time increased marginally by fourth day followed by a gradual reduction afterwards during the period of observation.

Haemogram

The haemoglobin concentration (g/dl) was 11.18 ± 0.88 before anaesthesia. Variation during postoperative period was marginal and within normal range.

The erythrocyte sedimentation rate (mm/h) was 2.33 ± 0.21 before anaesthesia. A high rise in ESR on second day was followed by a reduction to reach near normal value by 15th day postoperatively.

The packed cell volume (per cent) was 30.17 ± 2.19 before anaesthesia. There was a marginal decrease in PCV by second day postoperatively followed by an increase afterwards.

The total erythrocyte count ($10^6/\text{mm}^3$) was 4.40 ± 0.29 before anaesthesia. An increase on the second day postoperatively was followed by a marginal variation throughout the period of observation.

The total leucocyte count ($10^3/\text{mm}^3$) was 10.81 ± 0.83 before anaesthesia. There was a significant increase in TLC by second day postoperatively ($P < 0.05$) and became normal by 15th day.

The neutrophil count (per cent) was 70.83 ± 3.79 before anaesthesia. There was an increase in neutrophil count by second day postoperatively followed by a decrease thereafter and it reached near normal value by 15th day.

The lymphocyte count (per cent) was 28.00 ± 3.81 before anaesthesia. A decrease on second day postoperatively followed by a marginal variation during the period of observation was noticed.

The monocyte count (per cent) was 0.83 ± 0.40 before anaesthesia. There was a marginal decrease in the monocyte count by second day postoperatively followed by marginal variation thereafter during the period of observation.

The eosinophil count (per cent) showed a marginal and insignificant variation during the period of observation postoperatively.

Serum constituents

The total serum protein content (g/l) was 63.36 ± 4.93 before anaesthesia. The value increased marginally on 15th day following a decrease by seventh postoperative day.

The serum albumin content (g/l) was 25.88 ± 1.15 before anaesthesia. There was a reduction in the serum albumin content by seventh day postoperatively with a marginal increase on 15th day.

The serum globulin content (g/l) was 37.48 ± 5.09 before anaesthesia. There was a reduction in serum globulin content by seventh postoperative day with a marginal increase on 15th day.

The serum albumin globulin ratio was 0.79 ± 0.16 before anaesthesia. There was an increase in albumin globulin ratio on second postoperative day followed by a decrease to reach near normal value by 15th day.

The serum sodium concentration (mmol/l) was 106.74 ± 4.48 before anaesthesia. There was a marginal increase in serum sodium concentration by second postoperative day followed by a decrease during the period of observation.

The serum potassium concentration (mmol/l) was 6.32 ± 0.17 before anaesthesia. There was an increase in serum potassium

concentration by second postoperative day with marginal variation during the period of observation.

The serum chloride concentration (mmol/l) was 115.38 ± 1.75 before anaesthesia. A marginal increase on second postoperative day followed by a decrease to reach near normal value was observed in serum chloride concentration.

Radiographic observations

Barium meal oesophagogram during the post operative period showed normal oesophageal emptying. Signs of oesophagitis, seepage of contents, adhesion to surrounding structures and clinically significant alterations like stricture and dilation were not observed in any of the animals (Fig.10).

Terminal findings

Vascular and weak fibrinous adhesions were observed between grafted site and perioesophageal cervical muscles in one dog (E 1) which was sacrificed on 15th day postoperatively (Fig.11). Gross pathological changes were not observed on oesophageal mucosa in any of the dogs.

Biomechanical studies

Tensile strength of the specimen collected from the site was 2.67 N/mm^2 on 15th day postoperatively. There was an

increase in tensile strength on 30th day followed by a marginal decrease attaining 20.37 per cent strength to that of normal oesophagus on 60th day.

Breaking strength was 13.22 N on 15th day post-operatively. There was increase in breaking strength during the period of observation and it was 29.04 per cent of the strength of normal oesophagus on 60th day.

Extensibility (per cent) was 9.60 on 15th day postoperatively. There was an increase in extensibility during the period of observation and on 60th day it was 11.20 per cent more than that of normal oesophagus.

Energy absorption was 0.03 Nm on 15th day post-operatively. There was an increase in energy absorption during the period of observation and revealed 31.85 per cent energy absorption to that of normal oesophagus on 60th day.

Total dilatation capacity (per cent) was 84.33 on 15th day postoperatively. There was a reduction in total dilatation capacity on 30th day followed by an increase attaining 85.18 per cent to that of normal oesophagus on 60th day.

Gross morphological studies

15th day

Healing at the grafted site was complete in both the dogs. Mucosal healing was not complete at the centre of the

grafted site as indicated by persisting pink colour of the graft material (Fig.12). In one dog (E 1), an irregular, ragged, hyperaemic thickening of the mucosa was noticed around the graft material.

30th day

Complete healing of the grafted site was noticed in both the dogs (Fig.13). In one dog (E 4), focal area of congestion of the proximal aspect of the graft surrounded by a diphtheretic deposit was noticed on the external aspect at the grafted site (Fig.14).

60th day

Complete healing of the grafted site with normal oesophageal mucosal folds was noticed in both the dogs (Fig.15).

Histomorphological studies

15th day

Mild inflammatory reaction with presence of neutrophils, lymphocytes and a few macrophages was observed at the level of graft. Continuity of the mucosal cells was complete at the site. There was moderate deposition of collagen and elastin in the submucosal area (Fig.16).

30th day

Infiltration of macrophages and a few polymorphs in the lamina propria was noticed. Mucosal cell layer continuity was almost complete and proliferation of lining mucosa was noticed at the grafted site (Fig.17). Muscular layer revealed moderate fibroplasia.

60th day

A few polymorphs and macrophages were noticed at the site of healing. Squamous epithelial lining was complete and was hyperplastic in some regions. Oesophageal glands were scanty. Muscular layer showed proper orientation of the collagen fibres (Fig. 18). Graft tissue was found to be invaded with fibrovascular tissue at the site of implant.

Table 5. Rectal temperature, pulse rate and respiration rate in dogs before and after oesophagoplasty using chrome processed aortic allograft (Mean \pm SE)

Parameters with units	Pre-operative	Postoperative intervals (days)						
		1	2	3	4	5	6	7
Rectal temperature (°C)	39.19 \pm 0.18	39.54 \pm 0.20	39.43 \pm 0.19	39.24 \pm 0.18	39.13 \pm 0.18	38.94 \pm 0.24	38.57 \pm 0.18*	38.72 \pm 0.18
Pulse rate (per min.)	83.33 \pm 2.92	85.83 \pm 7.72	82.17 \pm 9.15	74.17 \pm 2.43	74.50 \pm 4.52	75.67 \pm 2.03	74.50 \pm 2.03	72.50 \pm 1.54
Respiration rate (per min.)	24.83 \pm 1.97	21.17 \pm 2.69	20.33 \pm 2.29	20.00 \pm 0.89	21.00 \pm 1.00	20.83 \pm 0.79	20.67 \pm 1.52	22.00 \pm 1.79

* Significant (P<0.05)

Table 6. Haemogram in dogs before and after oesophagoplasty using chrome processed aortic allograft (Mean \pm SE)

n=6

Parameters with units	Pre-operative	Postoperative intervals (days)		
		2	7	15
Haemoglobin concentration (g/dl)	11.18 \pm 0.88	11.12 \pm 0.83	11.43 \pm 1.01	11.12 \pm 0.59
Erythrocyte sedimentation rate (mm/h)	2.33 \pm 0.21	5.33 \pm 1.59	3.00 \pm 1.18	2.67 \pm 1.12
Packed cell volume (%)	30.17 \pm 2.19	30.00 \pm 2.53	32.83 \pm 3.03	32.50 \pm 1.86
Total erythrocyte count ($10^6/\text{mm}^3$)	4.40 \pm 0.29	5.26 \pm 0.30	4.75 \pm 0.44	5.36 \pm 0.32
Total leucocyte count ($10^3/\text{mm}^3$)	10.81 \pm 0.83	* 12.36 \pm 1.35	8.18 \pm 0.56	10.46 \pm 0.86
Neutrophil count (%)	70.83 \pm 3.79	72.17 \pm 5.33	65.50 \pm 3.99	72.83 \pm 2.14
Lymphocyte count (%)	28.00 \pm 3.81	27.33 \pm 5.26	32.33 \pm 4.25	25.67 \pm 2.43
Monocyte count (%)	0.83 \pm 0.40	0.50 \pm 0.22	1.33 \pm 0.67	0.67 \pm 0.33
Eosinophil count (%)	0.33 \pm 0.21	0.00	1.33 \pm 0.84	0.83 \pm 0.40
Basophil count (%)	0.00	0.00	0.00	0.00

* Significant ($P < 0.05$)

Table 7. Serum constituents in dogs before and after oesophagoplasty using chrome processed aortic allograft (Mean \pm SE)

n=6

Parameters with units	Pre-operative	Postoperative intervals (days)		
		2	7	15
Total serum protein (g/l)	63.36 \pm 4.93	57.13 \pm 4.18	53.12 \pm 3.16	60.11 \pm 2.85
Serum albumin (g/l)	25.88 \pm 1.15	25.33 \pm 2.07	22.27 \pm 1.50	24.35 \pm 0.94
Serum globulin (g/l)	37.48 \pm 5.09	31.80 \pm 4.35	30.85 \pm 2.08	35.76 \pm 3.03
Albumin-Globulin ratio	0.79 \pm 0.16	0.89 \pm 0.14	0.73 \pm 0.05	0.72 \pm 0.84
Serum sodium (mmol/l)	106.74 \pm 4.48	110.37 \pm 4.99	105.66 \pm 10.39	97.14 \pm 4.88
Serum potassium (mmol/l)	6.32 \pm 0.17	6.40 \pm 0.29	5.97 \pm 0.38	6.38 \pm 0.18
Serum chloride (mmol/l)	115.38 \pm 1.75	117.11 \pm 2.84	114.57 \pm 2.99	114.81 \pm 1.23

Table 8. Biomechanical characteristics of healing site of oesophagoplasty with chrome processed aortic allograft in dogs

Parameters with units	Normal oesophagus n=6	Healing oesophageal defect (Interval in days) n=1		
		15	30	60
Tensile strength (N/mm ²)	12.03± 2.73	2.67 (22.19%)	3.32 (27.60%)	2.45 (20.37%)
Breaking strength (N)	128.19± 13.16	13.22 (10.31%)	16.74 (13.06%)	37.22 (29.04%)
Extensibility (%)	31.42± 2.58	9.60 (30.55%)	13.28 (42.27%)	34.94 (111.20%)
Energy absorption (Nm)	1.35± 0.22	0.03 (2.22%)	0.06 (4.44%)	0.43 (31.85%)
Total dilatation capacity	100.00	84.33	77.78	85.18

Fig.10 Skiagram of cervical oesophagus on 15th postoperative day showing normal emptying of the content

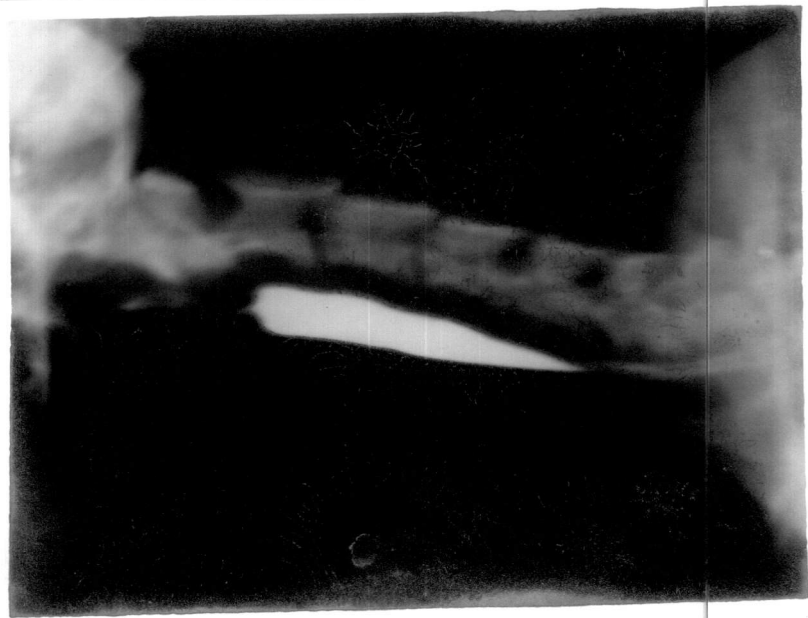


Fig.11 Cervical oesophagus *in situ* at autopsy on 15th postoperative day showing vascular and weak fibrinous adhesion between the grafted site and cervical muscles

Fig.12 Gross specimen: Grafted site on 15th postoperative day showing incomplete mucosal healing at the centre

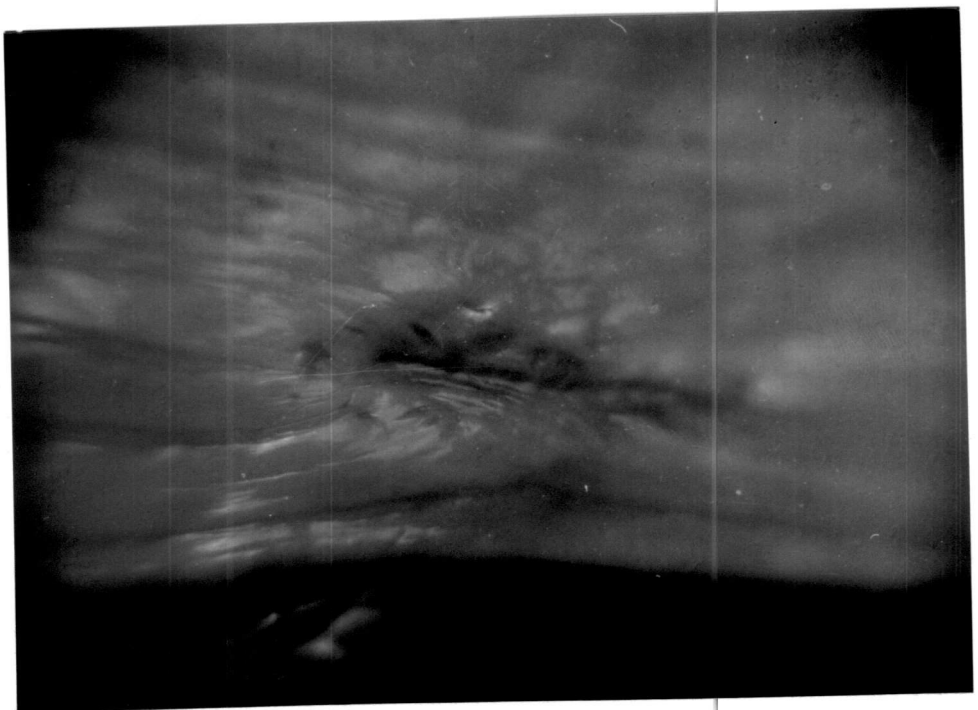
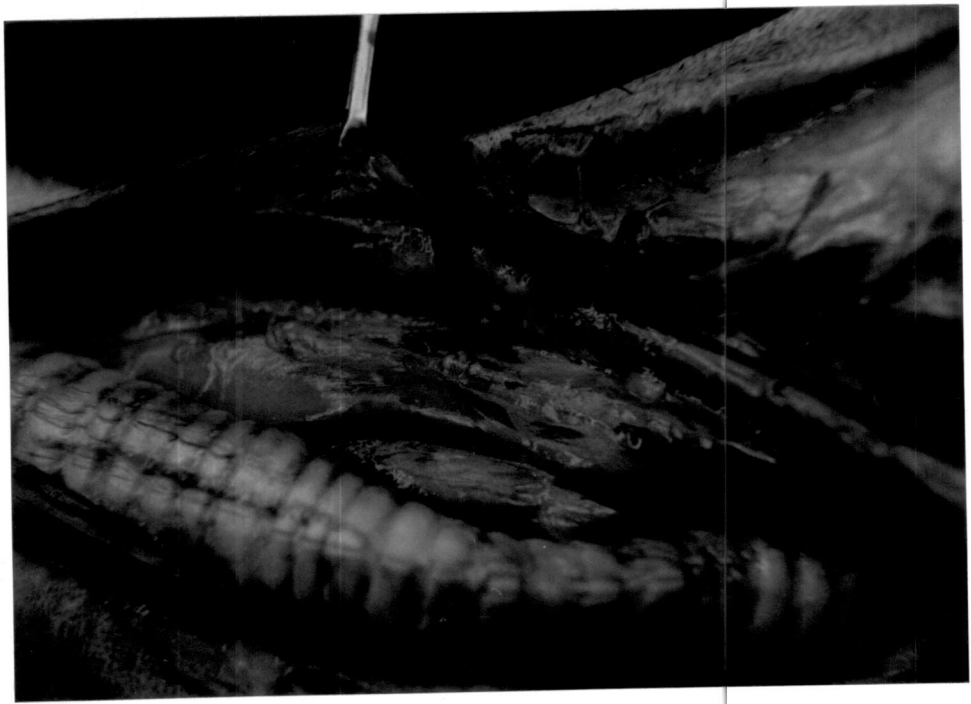

Fig.13 Gross specimen: Grafted site on 30th postoperative day showing incomplete healing with relative increase in thickness of mucosa at the centre

Fig.14 Gross specimen: Grafted site on 30th postoperative day showing diphtheretic deposit externally

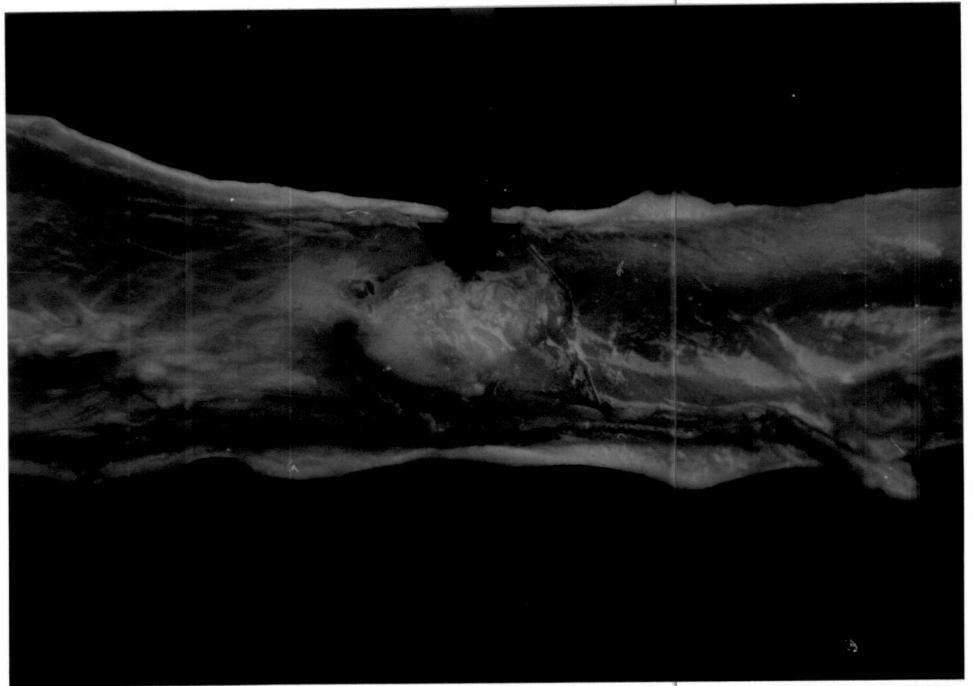
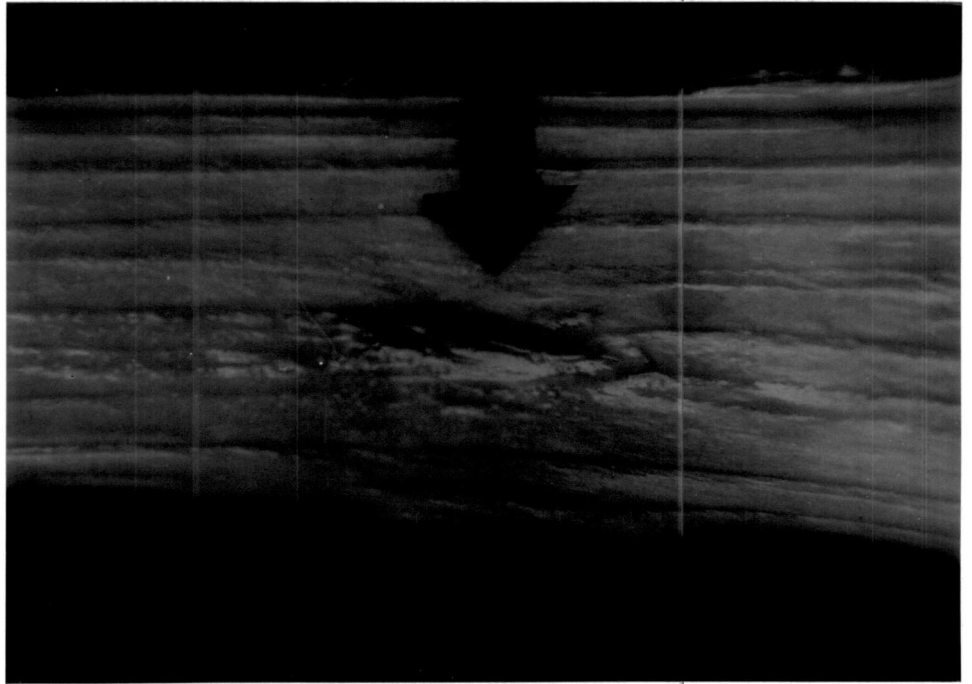
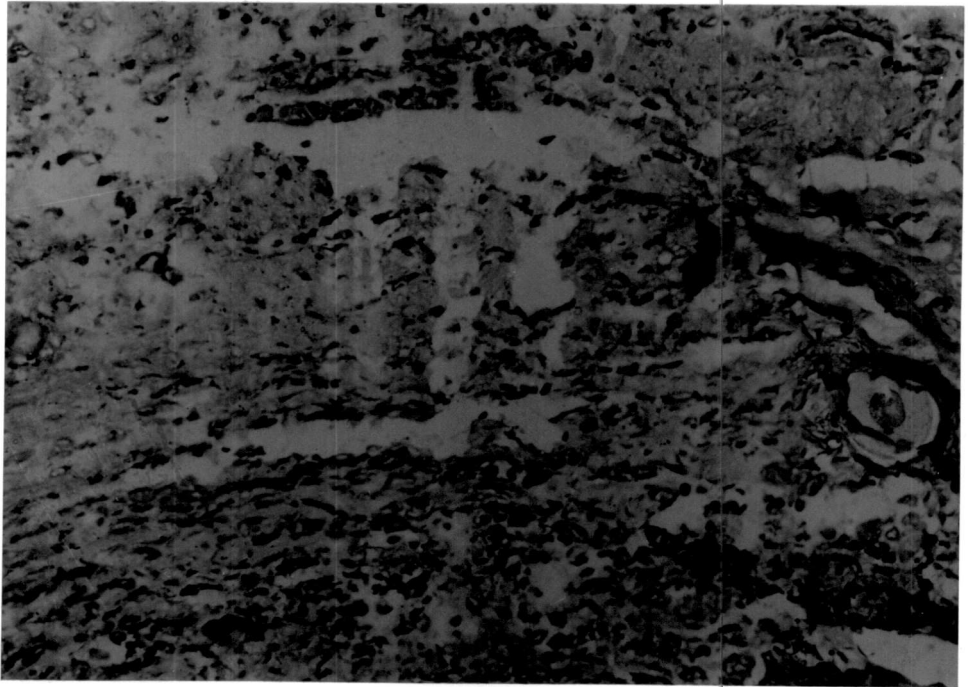
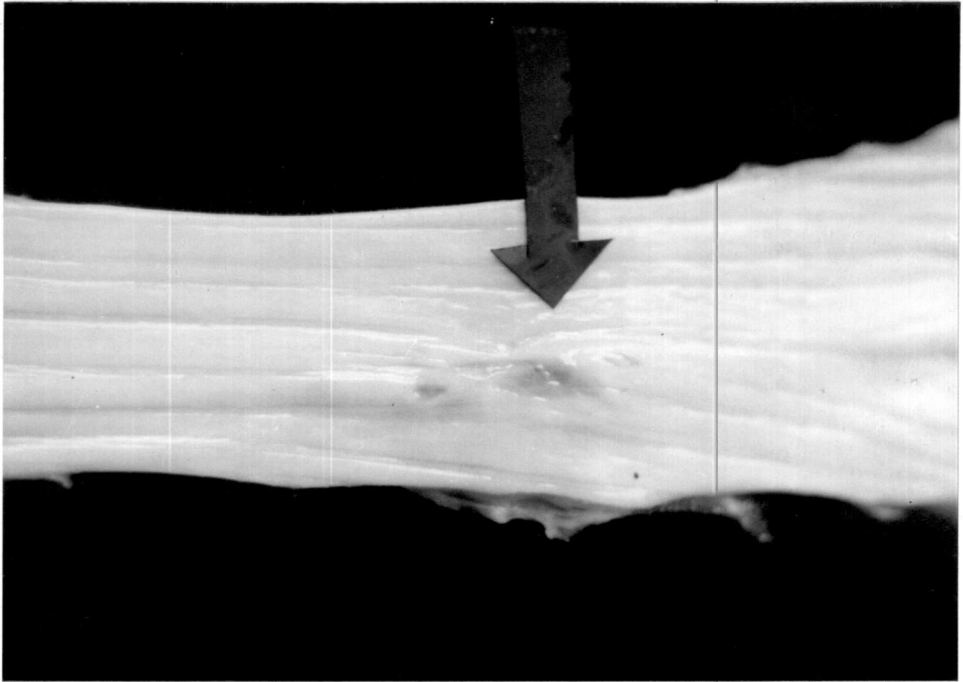


Fig.15 Gross specimen: Grafted site on 60th postoperative day showing complete mucosal healing and continuity with normal oesophageal mucosal folds

Fig.16 Photomicrograph: Grafted site on 15th postoperative day showing mild inflammatory oedema, scattered infiltration of mononuclear cells and mild fibroplasia at lamina propria. (H&E) 320x

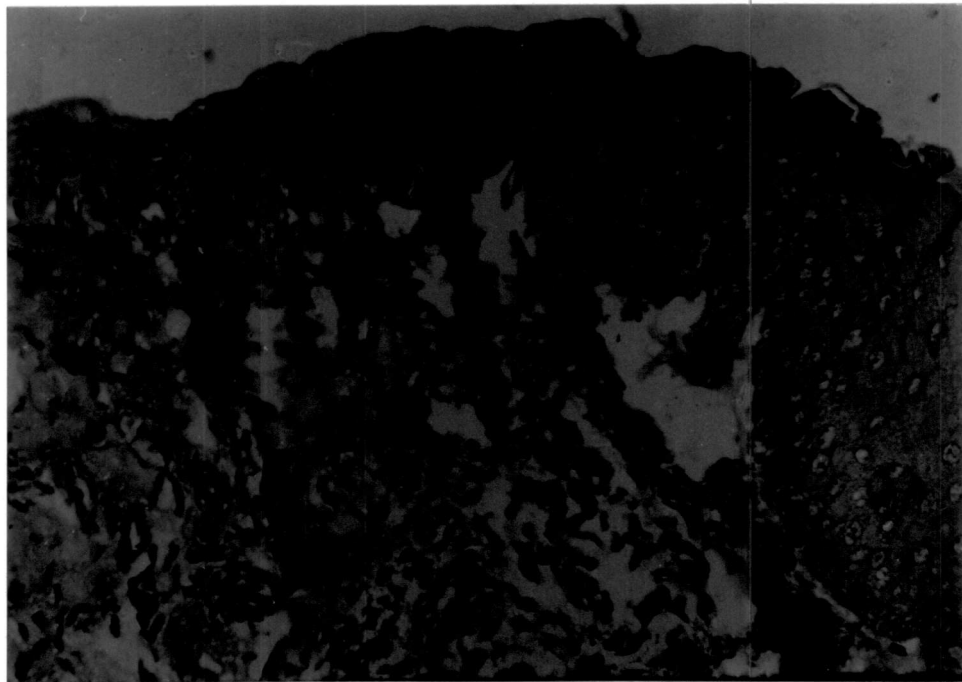



Call on the 1st of the month
of the month of the year
of the year of the month

Call on the 1st of the month
of the month of the year
of the year of the month

Fig.17 Photomicrograph: Grafted site on 30th postoperative day showing infiltration of a few macrophages, polymorphs, proliferation of lining mucosa and moderate fibroplasia at lamina propria (H&E) 80x

Fig.18 Photomicrograph: Grafted site on 60th postoperative day showing an increase in growth of basilar cell layer into the submucosa (H&E) 400x



GROUP-II**SUBGROUP-II B**

The observations are presented in Tables 9-12.

Preoperative considerations

The average body weight (kilogram) of the animals was 11.58 ± 0.63 . The animals were premedicated with triflupromazine hydrochloride (11.58 ± 0.63 mg) and anaesthetised using thiopentone sodium (327.50 ± 9.81 mg) to effect.

Clinical observations**General condition**

All the dogs became alert and active by 2.00 ± 0.37 days postoperatively.

Clinical evaluation of wound

Slight swelling was observed at the operated site in the cervical region by second day postoperatively in all the dogs. The inflammatory reaction gradually subsided and disappeared completely by 3-4 days postoperatively. Skin wound showed normal healing and sutures were removed by 7-8th day in all the animals.

Mild bleeding was observed during the pharyngostomy procedure in one animal (E12). Moderate pain and slight swelling were observed around the pharyngostomy tube entrance site on second postoperative day in three dogs (E 7, E 11 and E 12). Inflammatory reaction subsided by fourth day postoperatively. Tolerance of pharyngostomy tube was excellent in five dogs. One dog (E 10) dislodged the tube by breaking the anchoring sutures on third postoperative day. The tube was cleaned and refixed under sedation on the same day. The pharyngostomy wound healed completely in all the dogs by 15th day after the tube was removed.

Feeding behaviour

Pharyngostomy tube feeding was started from first day postoperatively in all the dogs. Initial tube obstruction during first feeding through pharyngostomy tube was observed in two dogs (E 8 and E 9). One dog (E 9) vomited once on the second day immediately after completion of feeding through the tube. Slow and restricted feeding through pharyngostomy tube resolved the complication. All the dogs started self feeding of liquid diet by 15th day and maintained normal appetite and feeding habits throughout the period of observation.

Physiological parameters

Rectal temperature ($^{\circ}\text{C}$) was 39.20 ± 0.23 before anaesthesia. After a marginal increase on the first day

postoperatively, the rectal temperature was near normal during the period of observation.

Pulse rate (per min) was 81.33 ± 5.09 before anaesthesia. There was a marginal increase in pulse rate on the first day postoperatively, and thereafter the value remained at a lower level during the period of observation.

Respiration rate (per min) was 25.83 ± 1.94 before anaesthesia. After a gradual decrease till the second postoperative day, the respiration rate remained at a lower level with marginal variation during the period of observation.

The conjunctival mucosa was slightly pale for 1-2 days postoperatively in all the dogs and became normal by fourth day.

The capillary refill time was less than one second in all the dogs before anaesthesia. An increase in time was observed on first day postoperatively followed by a gradual decrease reaching near normal by seventh day.

The time taken for the skin to return to its normal position was less than one second in all the dogs before anaesthesia. The time increased marginally by fourth day followed by a gradual reduction afterwards during the period of observation.

Haemogram

The haemoglobin concentration (g/dl) was 11.57 ± 0.45 before anaesthesia. Variation during post operative period was marginal and within normal range.

The erythrocyte sedimentation rate (mm/h) was 1.33 ± 0.21 before anaesthesia. There was an increase in ESR on second day postoperatively, and thereafter remained at a higher level throughout the period of observation.

The packed cell volume (per cent) was 32.50 ± 2.68 before anaesthesia. There was increase in PCV by seventh day followed by a decrease afterwards.

The total erythrocyte count ($10^6/\text{mm}^3$) was 5.06 ± 0.32 before anaesthesia. An increase by seventh day postoperatively was followed by decrease to reach near normal value.

The total leucocyte count ($10^3/\text{mm}^3$) was 9.26 ± 1.25 before anaesthesia. There was an increase in TLC by second day postoperatively and thereafter, decrease was observed during the period of observation.

The neutrophil count (per cent) was 69.00 ± 3.01 before anaesthesia. There was ^{an} increase in neutrophil count by second day postoperatively followed by marginal variation thereafter.

The lymphocyte count (per cent) was 29.50 ± 3.15 before anaesthesia. There was decrease in lymphocyte count by second day postoperatively and the value remained at a lower level throughout the period of observation.

The monocyte count (per cent) was 0.17 ± 0.31 before anaesthesia. Gradual increase was noticed in the monocyte count during the period of observation.

The eosinophil count (per cent) showed marginal and insignificant variation during the period of observation.

Serum constituents

The total serum protein content (g/l) was 68.69 ± 2.03 before anaesthesia. A decrease was noticed on the second day postoperatively with marginal variation thereafter during the period of observation.

The serum albumin content (g/l) was 25.73 ± 1.54 before anaesthesia. There was a reduction in serum albumin content till seventh day postoperatively with a marginal increase on 15th day. The decrease on second and seventh day were statistically significant ($P < 0.05$).

The serum globulin content (g/l) was 42.97 ± 2.61 before anaesthesia. There was increase in serum globulin content on

seventh day postoperatively followed by a decrease to reach near normal value by 15th day.

The albumin globulin ratio was 0.62 ± 0.07 before anaesthesia. There was a decrease in albumin globulin ratio on seventh day postoperatively followed by an increase reaching near normal value by 15th day.

The serum sodium concentration (mmol/l) was 92.43 ± 2.54 before anaesthesia. There was an increase in serum sodium concentration by second day postoperatively followed by a decrease during the period of observation.

The serum potassium concentration (mmol/l) was 6.22 ± 0.16 before anaesthesia. There was an increase in serum potassium concentration on seventh day postoperatively with a decrease by the 15th day.

The serum chloride concentration (mmol/l) was 114.80 ± 1.42 before anaesthesia. A marginal decrease on second day postoperatively was followed by an increase to reach near normal value.

Radiographic observations

Barium meal oesophagogram during the postoperative period showed normal oesophageal emptying. Signs of oesophagitis, seepage of contents, adhesion to surrounding structures and

clinically significant alterations like stricture and dilation were not observed in any of the animals (Fig.19).

Terminal findings

Weak fibrinous adhesion was observed between grafted site and perioesophageal cervical muscles in two dogs (E 8 and E 10) sacrificed on 15th and 30th postoperative day respectively (Fig.20). Gross pathological changes were not observed on oesophageal mucosa in five dogs. In one dog (E 8), mild hyperaemia of the oesophageal mucosa at its posterior third was observed.

Biomechanical studies

Tensile strength of the specimen collected from the site was 2.80 N/mm² on 15th day postoperatively. There was gradual increase in tensile strength during the period of observation and it was 24.61 per cent strength to that of normal oesophagus by 60th day.

Breaking strength was 15.54 N on 15th day postoperatively. There was decrease in breaking strength on 30th day followed by an increase reaching 21.48 per cent to that of normal oesophagus on 60th day.

Extensibility (per cent) was 11.66 on 15th day postoperatively. There was decrease in extensibility on 30th

day followed by an increase attaining 38.89 per cent to that of normal oesophagus on 60th day.

Energy absorption was 0.04 Nm on 15th day post-operatively. There was decrease in energy absorption on 30th day followed by an increase attaining 8.15 per cent to that of normal oesophagus on 60th day.

Total dilatation capacity (per cent) was 84.20 on 15th day postoperatively. There was reduction in total dilatation capacity on 30th day followed by an increase, attaining 79.22 per cent to that of normal oesophagus on 60th day.

Gross morphological studies

15th day

Healing at the grafted site was complete in both the dogs. Mucosal continuity was not complete.

30th day

Healing at the grafted site was complete in both the dogs. Mucosal continuity also was complete. In animal E 9, mild focal ulceration was observed at the grafted site (Fig.21).

60th day

Complete healing at the grafted site with normal oesophageal mucosal folds was observed in both the dogs (Fig.22).

Histomorphological studies**15th day**

Infiltration of neutrophils, lymphocytes, and macrophages and inflammatory oedema were observed at the grafted site. The mucosal continuity was almost complete at the site. Mild fibroplasia, neovascularization and disintegration of elastin fibres were the important features in the lamina propria (Fig.23).

30th day

Minimal inflammatory reaction was noted at the grafted site with the presence of a few macrophages and neutrophils. New epithelial formation with a few layers of cells, fibroplasia of the submucosa and neovascularization were noticed. There was no oesophageal gland in the lamina propria (Fig.24).

60th day

Fibrovascular tissue proliferation with a few polymorphs at the grafted site were the salient features. Epithelization was complete and the new epithelium formed revealed hyperplastic changes. The orientation of collagen and elastic fibres and neovascularization were observed (Fig.25). Oesophageal glands were absent in the lamina propria.

Table 9. Rectal temperature, pulse rate and respiration rate in dogs before and after oesophagoplasty using chrome processed aortic allograft and pharyngostomy (Mean±SE)

Parameters with units	Pre- operative	Postoperative intervals (days)						
		1	2	3	4	5	6	7
Rectal temperature (°C)	39.20± 0.23	39.44± 0.10	39.43± 0.23	39.30± 0.19	38.85± 0.25	38.93± 0.15	39.04± 0.08	38.91± 0.12
Pulse rate (per min.)	81.33± 5.09	83.83± 8.59	77.00± 4.81	78.83± 1.93	78.33± 7.16	74.67± 3.49	80.00± 4.06	78.83± 3.79
Respiration rate (per min.)	25.83± 1.94	20.33± 1.28	18.83± 1.28	21.17± 1.47	20.67± 2.51	20.67± 1.61	24.17± 1.22	23.17± 2.01

Table 10. Haemogram in dogs before and after oesophagoplasty using chrome processed aortic allograft and pharyngostomy (Mean±SE)

n=6

Parameters with units	Pre-operative	Postoperative intervals (days)		
		2	7	15
Haemoglobin concentration (g/dl)	11.57± 0.45	11.10± 0.76	11.28± 0.63	10.75± 0.79
Erythrocyte sedimentation rate (mm/h)	1.33± 0.21	3.00± 0.78	2.83± 0.87	3.17± 1.14
Packed cell volume (%)	32.50± 2.68	32.67± 2.06	34.00± 1.81	32.83± 2.29
Total erythrocyte count (10 ⁶ /mm ³)	5.06± 0.32	5.27± 0.29	5.49± 0.47	4.99± 0.56
Total leucocyte count (10 ³ /mm ³)	9.26± 1.25	13.87± 1.75	12.05± 2.16	9.77± 1.50
Neutrophil count (%)	69.00± 3.01	77.50± 3.81	73.50± 1.82	75.50± 3.93
Lymphocyte count (%)	29.50± 3.15	21.33± 3.51	25.50± 1.73	22.83± 3.89
Monocyte count (%)	0.17± 0.31	0.67± 0.33	1.00± 0.37	1.17± 0.40
Eosinophil count (%)	0.33± 0.21	0.33± 0.21	0.00	0.67± 0.49
Basophil count (%)	0.00	0.00	0.00	0.00

Table 11. Serum constituents in dogs before and after oesophagoplasty using chrome-processed aortic allograft and pharyngostomy (Mean±SE)

n=6

Parameters with units	Pre-operative	Postoperative intervals (days)		
		2	7	15
Total serum protein (g/l)	68.69± 2.03	67.00± 2.22	68.38± 2.74	65.52± 3.07
Serum albumin (g/l)	25.73± 1.54	22.85± 0.94	21.61± 0.48	23.54± 0.46
Serum globulin (g/l)	42.97± 2.61	44.15± 2.27	46.77± 2.91	41.98± 2.76
Albumin-Globulin ratio	0.62± 0.07	0.53± 0.04	0.47± 0.03	0.57± 0.03
Serum sodium (mmol/l)	92.43± 2.54	107.65± 9.33	103.66± 3.71	99.68± 2.29
Serum potassium (mmol/l)	6.22± 0.16	6.39± 0.26	6.67± 0.18	6.43± 0.11
Serum chloride (mmol/l)	114.80± 1.42	111.33± 2.86	112.65± 3.51	113.58± 2.23

* Significant (P<0.05)

Table 12. Biomechanical characteristics of healing site of oesophagoplasty with chrome processed aortic allografts in dogs subjected to oesophageal intubation

Parameters with units	Normal oesophagus n=6	Healing oesophageal defect (Interval in days) n=1		
		15	30	60
Tensile strength (N/mm ²)	12.03± 2.73	2.80 (23.28%)	2.31 (19.20%)	2.96 (24.61%)
Breaking strength (N)	128.19± 13.16	15.54 (12.12%)	11.66 (9.09%)	27.54 (21.48%)
Extensibility (%)	31.42± 2.58	11.66 (37.11%)	9.05 (28.80%)	12.22 (38.89%)
Energy absorption (Nm)	1.35± 0.22	0.04 (2.96%)	0.03 (2.22%)	0.11 (8.15%)
Total dilatation capacity (%)	100.00	84.20	78.57	79.22

Fig.19 Skiagram of cervical oesophagus on 30th postoperative day showing normal emptying of the content

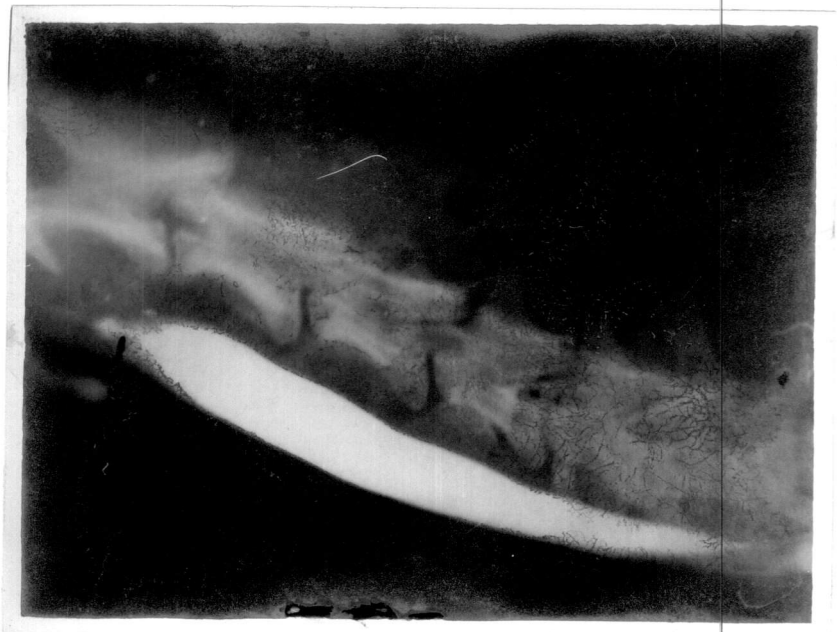

Fig.20 Cervical oesophagus *in situ* at autopsy on 30th postoperative day showing fibrinous adhesion between the grafted site and periesophageal tissues

Fig.21 Gross specimen: Grafted site on 30th postoperative day showing mild focal ulceration

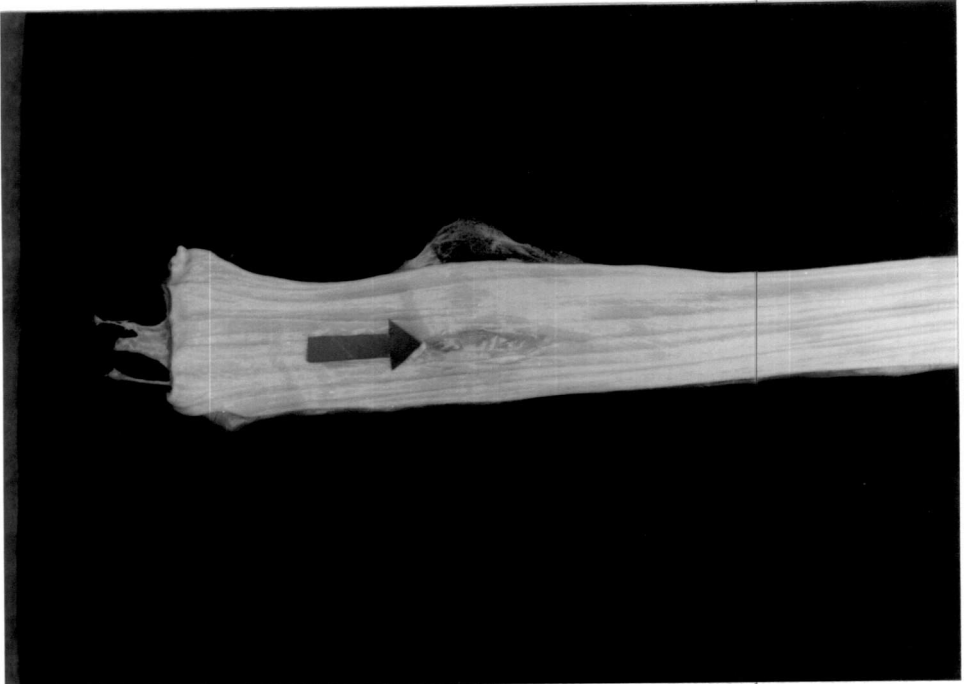
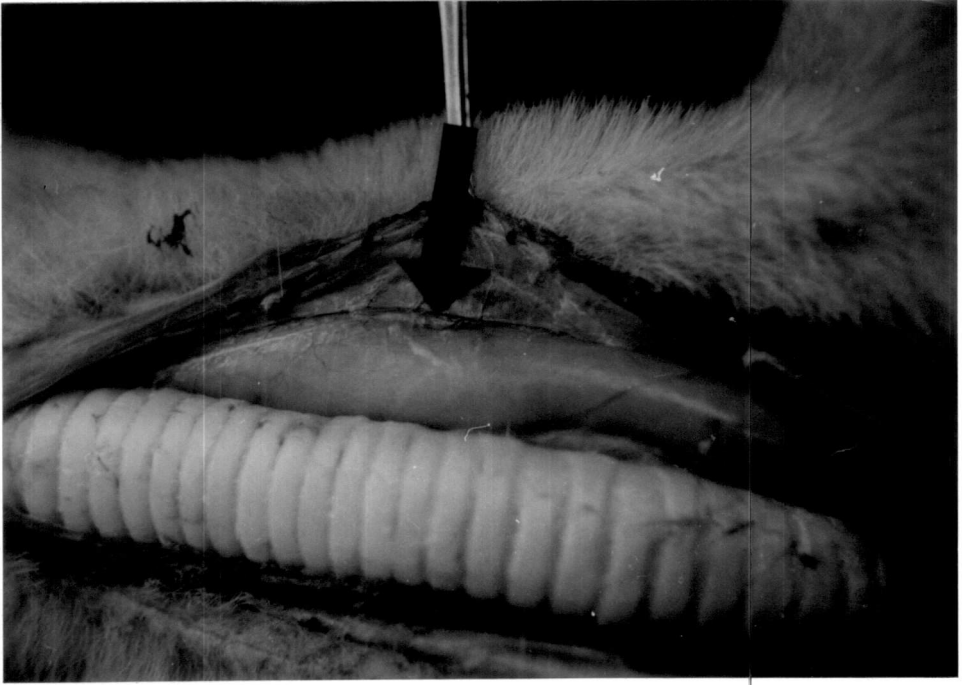

Fig.22 Gross specimen: Grafted site on 60th postoperative day showing complete healing with normal oesophageal mucosal folds

Fig.23 Photomicrograph: Grafted site on 15th postoperative day showing epithelial proliferation, neovascularization and fibroplasia in submucosa and absence of oesophageal glands in lamina propria. (VER) 320x


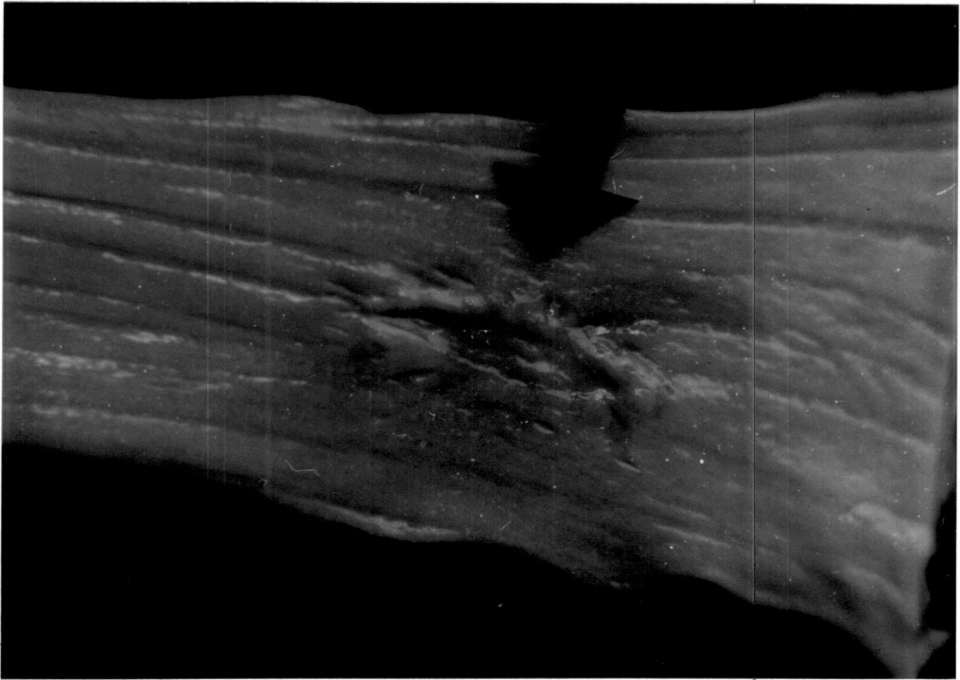
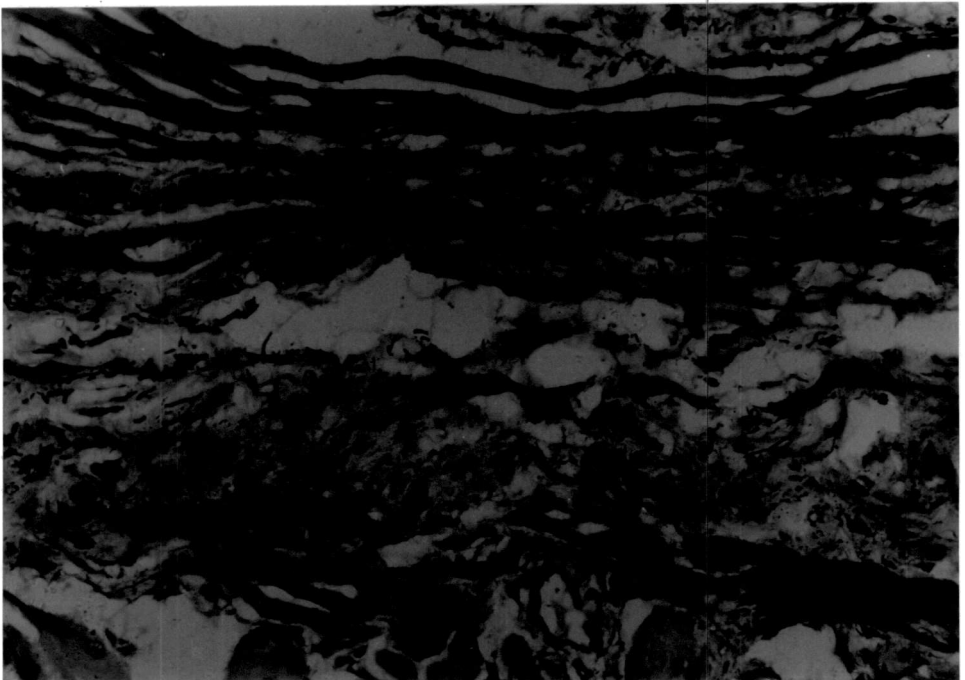



Fig.24 Photomicrograph: Grafted site on 30th postoperative day showing fibroplasia and disintegration of elastin in lamina propria. (VER) 320x

Fig.25 Photomicrograph: Grafted site on 60th postoperative day showing proper orientation of collagen fibres, disintegration and fragmentation of elastin in muscular coat with fibroplasia. (VER) 320x



GROUP-III
SUBGROUP-III A

The observations are presented in Tables 13-16.

Preoperative considerations

The average body weight (kilogram) of the animals was 12.08 ± 1.21 . The animals were premedicated with triflupromazine hydrochloride (12.08 ± 1.21 mg) and anaesthetised using thiopentone sodium (325.00 ± 45.64 mg) to effect.

Clinical observations

General condition

All the dogs became alert and active by 2.50 ± 0.43 days postoperatively.

Clinical evaluation of wound

Mild swelling and moderate pain at the operated site was noticed on the second postoperative day in all the dogs. The inflammatory reaction gradually subsided and disappeared completely by 4-5 days. Skin wound showed normal healing and sutures were removed by 7-8th day in all the animals.

Feeding behaviour

All the dogs started taking liquid food by seventh day and maintained normal appetite and feeding habits throughout the period of observation. One dog (E 13) showed mild swelling at the operated site while swallowing which persisted for four days. There was no leakage at the operated site.

Physiological parameters

Rectal temperature ($^{\circ}\text{C}$) was 39.17 ± 0.10 before anaesthesia. After a marginal increase on the first day postoperatively, the rectal temperature remained near normal during the later period of observation.

Pulse rate (per min) was 87.17 ± 5.33 before anaesthesia. There was a marginal increase in pulse rate on first day postoperatively, and thereafter the value remained at a lower level with marginal variation during the period of observation.

Respiration rate (per min) was 26.83 ± 2.19 before anaesthesia. After a gradual decrease till second day postoperatively, the respiration rate remained at a lower level with marginal variation during the period of observation.

The conjunctival mucosa was slightly pale for 1-6 days postoperatively in all the dogs but became normal by eighth day.

The capillary refill time was less than one second in all the dogs before anaesthesia. Increase in time was observed by second day followed by a gradual decrease reaching near normal value by seventh day postoperatively.

The time taken for the skin to return to its normal position was less than one second in all the dogs before anaesthesia. The time increased marginally by third postoperative day, followed by a gradual reduction during the remaining period of observation.

Haemogram

The haemoglobin concentration (g/dl) was 11.63 ± 0.85 before anaesthesia. There was a decrease in haemoglobin concentration by seventh day postoperatively, but was normal by 15th day.

The erythrocyte sedimentation rate (mm/h) was 1.67 ± 0.33 before anaesthesia. There was ^{an} increase in ESR on second day postoperatively, and thereafter it remained at a higher level throughout the period of observation.

The packed cell volume (per cent) was 29.50 ± 2.14 before anaesthesia. There was decrease in the value by second day postoperatively followed by a gradual increase afterwards.

The total erythrocyte count ($10^6/\text{mm}^3$) was 5.19 ± 0.26 before anaesthesia. An increase in TEC on second day postoperatively was followed by gradual decrease to reach near normal value.

The total leucocyte count ($10^3/\text{mm}^3$) was 9.66 ± 1.53 before anaesthesia. There was an increase in TLC by second day postoperatively but was normal by 15th day.

The neutrophil count (per cent) was 73.83 ± 2.70 before anaesthesia. There was increase in neutrophil count by second day postoperatively followed by a decrease thereafter.

The lymphocyte count (per cent) was 23.17 ± 1.82 before anaesthesia. An increase was noticed in lymphocyte count during the period of observation postoperatively.

The monocyte count (per cent) was 0.83 ± 0.40 before anaesthesia. There was a marginal decrease in monocyte count by second day postoperatively followed by an increase thereafter during the period of observation.

The eosinophil count (per cent) showed a marginal and insignificant variation during the period of observation postoperatively.

Serum constituents

The total serum protein content (g/l) was 65.15 ± 2.38 before anaesthesia. Following an increase on second day postoperatively, it decreased and remained at a lower level during the period of observation.

The serum albumin content (g/l) was 25.34 ± 1.00 before anaesthesia. There was reduction in serum albumin content during the period of observation postoperatively.

The serum globulin content (g/l) was 39.81 ± 3.04 before anaesthesia. There was increase in serum globulin content by second day postoperatively followed by a decrease reaching near normal value by 15th day.

The albumin globulin ratio was 0.66 ± 0.70 before anaesthesia. There was decrease in albumin globulin ratio by second day postoperatively followed by increase on seventh day. The ratio became normal by 15th day.

The serum sodium concentration (mmol/l) was 127.59 ± 10.07 before anaesthesia. There was increase in serum sodium concentration by second day postoperatively followed by marginal variation during the period of observation.

The serum potassium concentration (mmol/l) was 6.79 ± 0.23 before anaesthesia. There was marginal decrease in serum

potassium concentration by seventh day postoperatively followed by increase on 15th day.

The serum chloride concentration (mmol/l) was 113.16 ± 1.05 before anaesthesia. A marginal decrease on seventh day postoperatively was followed by an increase to reach near normal value by 15th day.

Radiographic observations

Barium meal oesophagogram during the post operative period showed normal oesophageal emptying. Signs of oesophagitis, seepage of contents, adhesion to surrounding structures and clinically significant alterations like stricture and dilation were not observed in any of the animals (Fig.26).

Terminal findings

Weak fibrinous adhesion was observed between the grafted site and perioesophageal cervical muscles in two dogs (E 13 and E 14), sacrificed on 15th day postoperatively. Gross pathological changes were not observed on oesophageal mucosa in any of the dogs.

Biomechanical studies

Tensile strength of the specimen collected from the site was $2.80 \text{ (N/mm}^2\text{)}$ on 15th day postoperatively. There was

decrease in tensile strength on 30th day followed by increase, attaining 3.82 per cent more strength than that of normal oesophagus on 60th day.

Breaking strength was 11.12 N on 15th day post-operatively. There was increase in breaking strength during the period of observation and was 64.34 per cent to that of normal oesophagus on 60th day.

Extensibility (per cent) was 7.58 on 15th day post-operatively. There was increase in extensibility during the period of observation and was 58.66 per cent to that of normal oesophagus on 60th day.

Energy absorption was 0.02 Nm on 15th day post-operatively. There was increase in energy absorption during the period of observation and was 34.07 per cent to that of normal oesophagus on 60th day.

Total dilatation capacity (per cent) was 78.51 on 15th day postoperatively. There was reduction in total dilatation capacity on 30th day followed by an increase attaining 81.14 per cent capacity to that of normal oesophagus on 60th day.

Gross morphological studies

15th day

Healing at the grafted site was complete in both the dogs. Mucosal continuity was not complete. In dog E 13, thickening of the mucosal fold was noticed at the junction of the graft and the oesophageal mucosa (Fig.27). Externally thin diphtheretic deposit was evident at the grafted site (Fig.28).

30th day

Healing at the grafted site was complete in both the dogs. Mucosal continuity was not complete. In animal E 15, mild mucosal thickening in the region bordering the graft was noticed.

60th day

Complete healing was observed in both the dogs at the grafted site externally (Fig.29) with normal oesophageal mucosal folds (Fig.30).

Histomorphological studies

15th day

Infiltration of neutrophils, lymphocytes and a few macrophages and inflammatory oedema were observed at the level

of grafting (Fig.31). Mucosal proliferation and continuity was not complete at the site. Mild fibroplasia was noticed in the muscular coat (Fig.32).

30th day

The polymorphs and macrophages were scanty at the site. Mucosal proliferation and continuity was almost complete. There was inflammatory oedema and mild fibroplasia adjacent to the graft. Moderate deposition of collagen fibres along with fragmented and coiled elastin were observed at the muscular coat (Fig.33).

60th day

A few polymorphs and macrophages were noticed at the site of healing. Squamous cell epithelial lining was slightly hyperplastic and the process of epithelization was complete. Muscular layer showed fibroplasia with proper orientation of the collagen fibres (Fig.34).

Table 13. Rectal temperature, pulse rate and respiration rate in dogs before and after oesophagoplasty using glutaraldehyde processed aortic allograft (Mean±SE)

n=6

Parameters with units	Pre-operative	Post operative intervals (days)						
		1	2	3	4	5	6	7
Rectal temperature (°C)	39.17± 0.10	39.26± 0.06	39.02± 0.14	39.11± 0.10	38.87± 0.17	38.89± 0.20	38.91± 0.24	38.85± 0.22
Pulse rate (per min.)	87.17± 5.33	91.83± 8.94	80.50± 5.53	88.67± 8.62	83.17± 5.42	83.17± 5.95	77.17± 6.48	83.67± 5.37
Respiration rate (per min.)	26.83± 2.19	21.67± 1.41	20.83± 1.42	23.33± 1.86	21.83± 2.66	21.17± 2.24	19.83± 2.88	18.67± 0.84

Table 14. Haemogram in dogs before and after oesophagoplasty using glutaraldehyde processed aortic allograft (Mean \pm SE)

Parameters with units	Pre-operative	Postoperative intervals (days)		
		2	7	15
Haemoglobin concentration (g/dl)	11.63 \pm 0.85	11.52 \pm 0.88	10.45 \pm 0.77	11.28 \pm 1.03
Erythrocyte sedimentation rate (mm/h)	1.67 \pm 0.33	3.50 \pm 0.92	3.67 \pm 1.17	4.00 \pm 1.18
Packed cell volume (%)	29.50 \pm 2.14	28.17 \pm 1.82	30.17 \pm 2.34	31.50 \pm 2.77
Total erythrocyte count (10 ⁶ /mm ³)	5.19 \pm 0.26	5.58 \pm 0.44	5.33 \pm 0.52	5.22 \pm 0.26
Total leucocyte count (10 ³ /mm ³)	9.66 \pm 1.53	12.29 \pm 1.85	9.12 \pm 1.08	9.98 \pm 0.96
Neutrophil count (%)	73.83 \pm 2.70	76.17 \pm 4.43	70.67 \pm 6.72	69.33 \pm 2.04
Lymphocyte count (%)	23.17 \pm 1.82	23.33 \pm 4.66	25.67 \pm 7.02	28.33 \pm 2.04
Monocyte count (%)	0.83 \pm 0.40	0.50 \pm 0.34	0.83 \pm 0.40	0.83 \pm 0.40
Eosinophil count (%)	0.50 \pm 0.50	0.00	1.17 \pm 0.83	0.67 \pm 0.49
Basophil count (%)	0.00	0.00	0.00	0.00

Table 15. Serum constituents in dogs before and after oesophagoplasty using glutaraldehyde processed aortic allograft (Mean \pm SE)

Parameters with units	Pre-operative	Postoperative intervals (days)		
		2	7	15
Total serum protein (g/l)	65.15 \pm 2.38	73.80 \pm 2.88	61.56 \pm 5.63	63.37 \pm 3.43
Serum albumin (g/l)	25.34 \pm 1.00	24.74 \pm 1.38	24.62 \pm 0.80	23.15 \pm 0.78
Serum globulin (g/l)	39.81 \pm 3.04	49.06 \pm 2.96	36.94 \pm 5.31	40.22 \pm 4.16
Albumin-Globulin ratio	0.66 \pm 0.70	0.52 \pm 0.05	0.74 \pm 0.11	0.63 \pm 0.10
Serum sodium (mmol/l)	127.59 \pm 10.07	135.56 \pm 10.54	126.86 \pm 4.75	131.57 \pm 9.15
Serum potassium (mmol/l)	6.79 \pm 0.23	6.79 \pm 0.16	6.76 \pm 0.22	7.05 \pm 0.26
Serum chloride (mmol/l)	113.16 \pm 1.05	111.93 \pm 2.42	111.30 \pm 2.33	112.48 \pm 0.94

n=6

Table 16. Biomechanical characteristics of healing site of oesophagoplasty with glutaraldehyde processed aortic allograft in dogs

Parameters with units	Normal oesophagus (n=6)	Healing oesophageal defect (Interval in days) n=1		
		15	30	60
Tensile strength (N/mm ²)	12.03± 2.73	2.80 (23.28%)	1.44 (11.97%)	12.49 (103.82%)
Breaking strength (N)	128.19± 13.16	11.12 (8.67%)	15.76 (12.29%)	82.48 (64.34%)
Extensibility (%)	31.42± 2.58	7.58 (24.12%)	9.29 (29.57%)	18.43 (58.66%)
Energy absorption (Nm)	1.35± 0.22	0.02 (1.48%)	0.03 (2.22%)	0.46 (34.07%)
Total dilatation capacity (%)	100.00	78.51	74.54	81.14

Fig.26 Skiagram of cervical oesophagus on 15th postoperative day showing normal emptying of the content

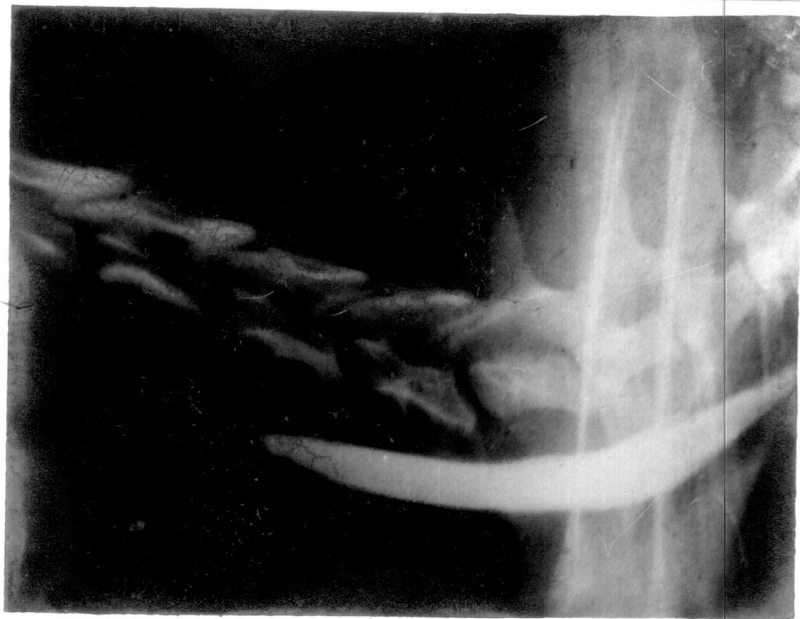
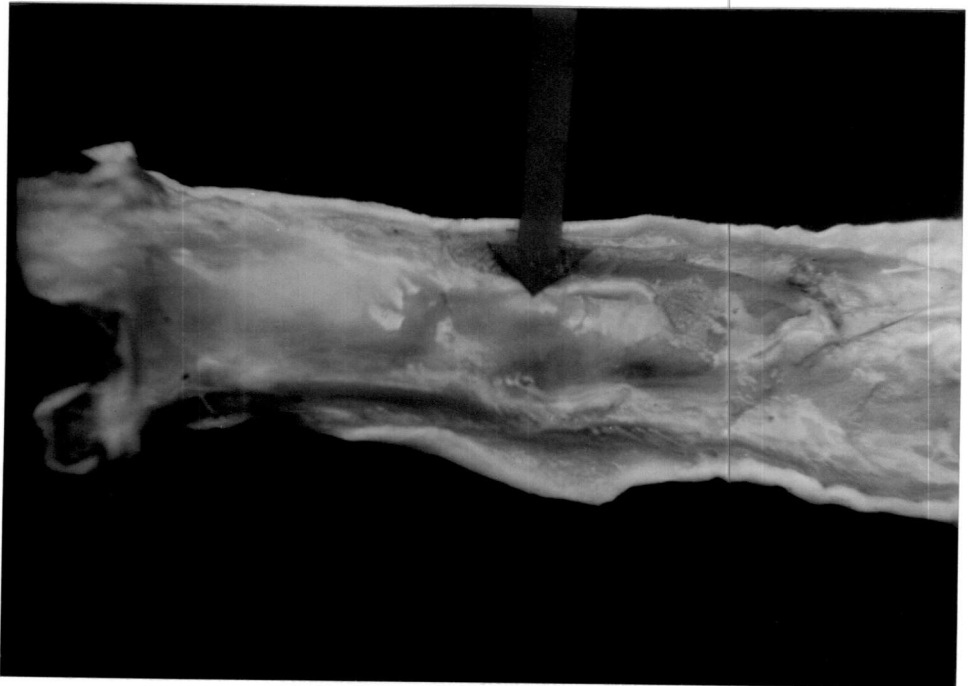
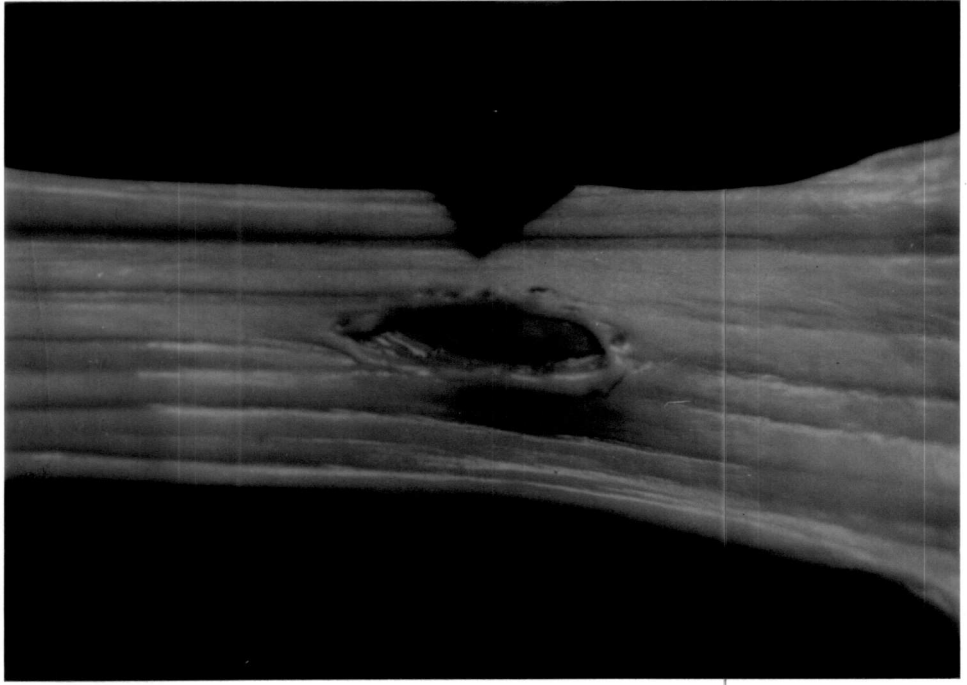


Fig.27 Gross specimen: Grafted site on 15th postoperative day showing corded thickening of the mucosa around the graft

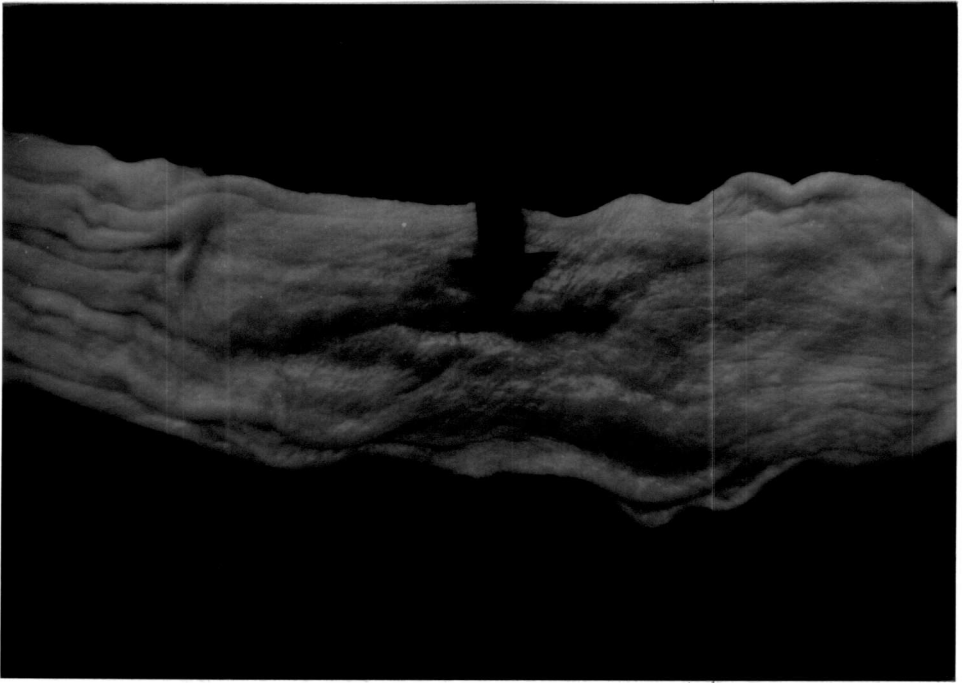
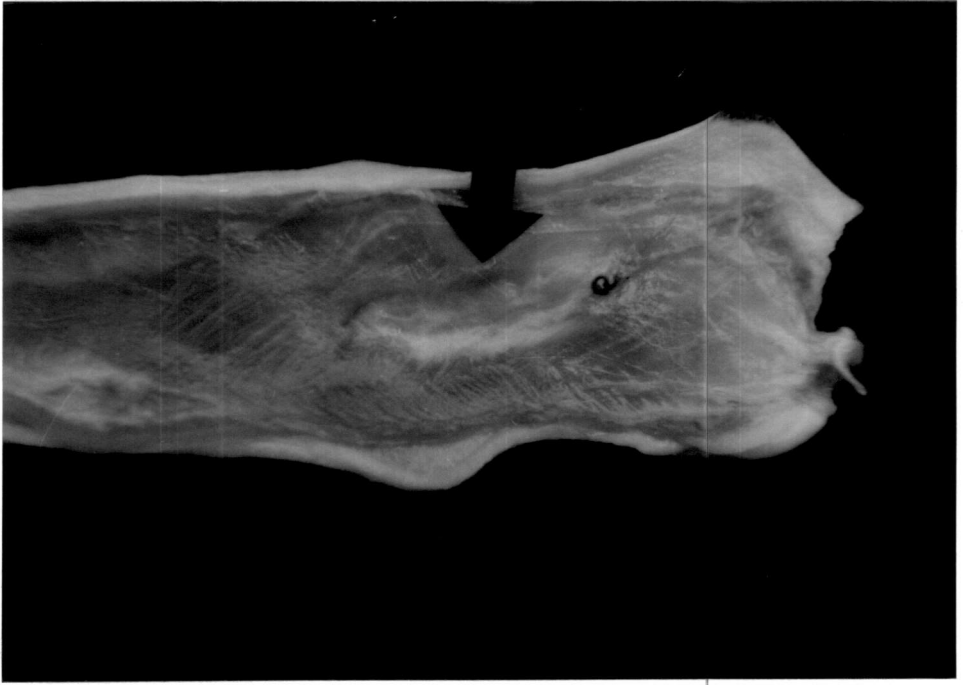
Fig.28 Gross specimen: Grafted site on 15th postoperative day showing thin diphtheretic deposit externally



1723000
1723000
1723000

Fig.29 Gross specimen: Grafted site on 60th postoperative day showing complete healing externally

Fig.30 Gross specimen: Grafted site on 60th postoperative day showing complete healing with normal oesophageal mucosal folds





Faint, illegible text centered on the page, possibly a title or header.

Faint, illegible text at the bottom of the page, possibly a footer or signature.

Fig.31 Photomicrograph: Grafted site on 15th postoperative day showing inflammatory oedema, mononuclear cell infiltration, scattered fibroplasia and cut surface of suture material. (VAN) 320x

Fig.32 Photomicrograph: Grafted site on 15th postoperative day showing mild fibroplasia and collagen deposition with degenerative changes in the muscular coat. (VAN) 40x


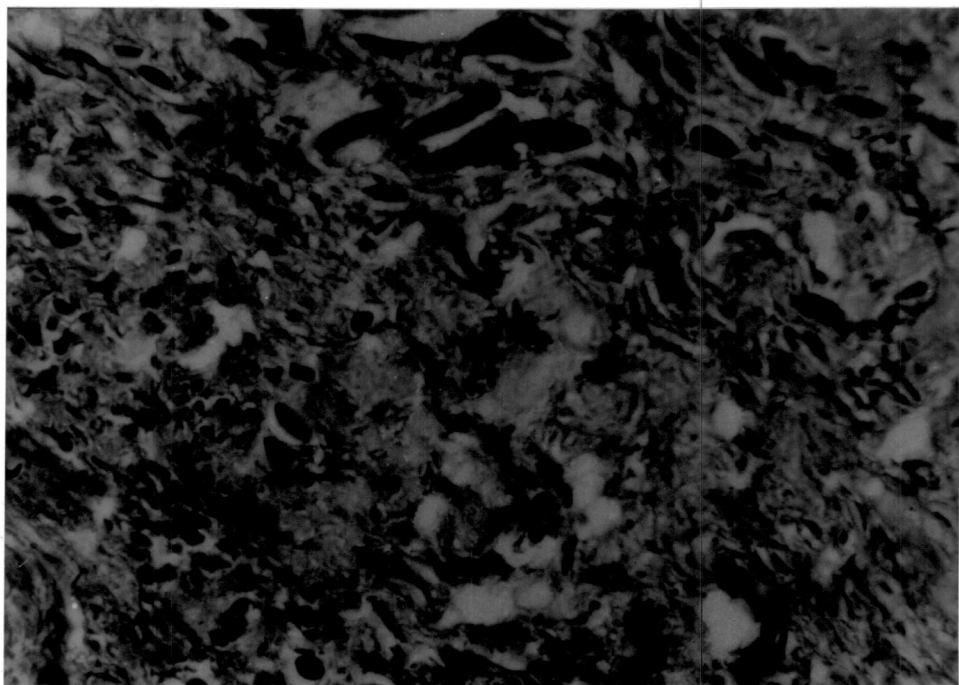


Fig.33 Photomicrograph: Grafted site on 30th postoperative day showing minimal inflammatory reaction. (H&E) 400x

Fig.34 Photomicrograph: Grafted site on 60th postoperative day showing fibrovascular tissue proliferation. (VAN) 320x



GROUP-III
SUBGROUP-III B

The observations are presented in Tables 17-20.

Preoperative considerations

The average body weight (kilogram) of the animals was 10.92 ± 0.78 . The animals were premedicated with triflupromazine hydrochloride (10.92 ± 0.78 mg) and anaesthetised using thiopentone sodium (290.00 ± 23.24 mg) to effect.

Clinical observations

General condition

All the dogs became alert and active by 2.33 ± 0.33 days postoperatively.

Clinical evaluation of wound

Slight swelling and pain were observed at the operated site in the cervical region by second day post operatively in all the dogs. The inflammatory reaction gradually subsided and disappeared completely by 3-4 days postoperatively. Skin wound showed normal healing and sutures were removed by 7-8th day in five animals. One dog (E 23) mutilated the suture line by fifth day, and the wound was freshened and sutured. The

sutures were removed after healing by tenth day postoperatively.

Severe inflammatory oedema around the pharyngostomy tube entrance site was noticed in one dog (E 20). In all the other animals, inflammatory reaction was very mild. Tolerance of pharyngostomy tube was excellent in five dogs. One dog (E 23) dislodged the tube by breaking the anchoring sutures on ninth day postoperatively. The tube was cleaned, reinserted and fixed under general anaesthesia. One dog (E 24) had broken the anchoring sutures of the tube on tenth day. Since the tube was in position, it was reanchored to the wound edges under local anaesthesia. The wound healed completely by 14-15th day after removal of tube in all the dogs.

Feeding behaviour

Pharyngostomy tube feeding was started on the first day postoperatively in all the dogs. One dog (E 21) vomited once, immediately after first time feeding. Initial tube obstruction during first feeding through pharyngostomy tube was experienced in two dogs (E 19 and E 23). All the dogs started self feeding of liquid diet by 15th day and maintained normal appetite and feeding habits throughout the period of observation.

Physiological parameters

Rectal temperature ($^{\circ}\text{C}$) was 39.15 ± 0.24 before anaesthesia. After a marginal increase on second day postoperatively, the rectal temperature remained near normal during the period of observation.

Pulse rate (per min) was 93.00 ± 5.08 before anaesthesia. There was a marginal increase in pulse rate on the first day postoperatively, but the values remained with marginal variations during the period of observation.

Respiration rate (per min) was 25.50 ± 1.86 before anaesthesia. After an initial decrease on the first day postoperatively, the respiration rate remained with marginal variations throughout the period of observation.

The conjunctival mucosa was slightly pale for 1-4 days postoperatively in all the dogs and regained normalcy on fifth day.

The capillary refill time was less than one second in all the dogs before anaesthesia. A marginal increase in time was observed by second day followed by a gradual decrease reaching near normal value on seventh day postoperatively.

The time taken for the skin to return to its normal position was less than one second in all the dogs before

anaesthesia. The time increased marginally by second day and was followed by a gradual reduction during the period of observation.

Haemogram

The haemoglobin concentration (g/dl) was 11.32 ± 0.78 before anaesthesia. Variation during the postoperative period was marginal and within normal range.

The erythrocyte sedimentation rate (mm/h) was 2.33 ± 0.42 before anaesthesia. There was an increase in ESR on second day postoperatively and remained at a higher level throughout the period of observation.

The packed cell volume (per cent) was 35.33 ± 2.73 before anaesthesia. There was a decrease in PCV by seventh day postoperatively followed by an increase afterwards.

The total erythrocyte count ($10^6/\text{mm}^3$) was 4.41 ± 0.27 before anaesthesia. An increase in TEC by seventh day postoperatively was followed by a decrease reaching near normal value by 15th day.

The total leucocyte count ($10^3/\text{mm}^3$) was 12.02 ± 0.79 before anaesthesia. There was an increase in TLC by second day postoperatively and thereafter it decreased during the period of observation.

The neutrophil count (per cent) was 78.83 ± 3.04 before anaesthesia. There was decrease in neutrophil count by second day postoperatively followed by an increase thereafter.

The lymphocyte count (per cent) was 23.83 ± 3.44 before anaesthesia. An increase was noticed in lymphocyte count during the period of observation postoperatively.

The monocyte count (per cent) was 0.67 ± 0.21 before anaesthesia. There was marginal decrease in the monocyte count by second day postoperatively followed by an increase thereafter during the period of observation.

The eosinophil count (per cent) showed a marginal and insignificant variation during the period of observation postoperatively.

Serum constituents

The total serum protein content (g/l) was 72.54 ± 2.76 before anaesthesia. It decreased to a significant level on seventh day postoperatively ($P < 0.05$), and increased marginally on 15th day.

The serum albumin content (g/l) was 25.59 ± 1.06 before anaesthesia. The values remained at a lower level with marginal variation during the period of observation postoperatively.

The serum globulin content (g/l) was 46.95 ± 2.94 before anaesthesia. There was reduction in serum globulin content to a significant level on seventh day postoperatively ($P < 0.05$), with marginal increase on 15th day.

The albumin globulin ratio was 0.56 ± 0.05 before anaesthesia. There was a significant increase on seventh day postoperatively ($P < 0.05$).

The serum sodium concentration (mmol/l) was 127.77 ± 17.79 before anaesthesia. There was a marginal increase in serum sodium concentration by second day postoperatively followed by a decrease thereafter during the period of observation.

The serum potassium concentration (mmol/l) was 6.77 ± 0.27 before anaesthesia. There was a marginal decrease in serum potassium concentration on the seventh day postoperatively with an increase by 15th day.

The serum chloride concentration (mmol/l) was 114.14 ± 1.39 before anaesthesia. A marginal decrease on second day postoperatively was followed by an increase to reach near normal value on 15th day.

Radiographic observations

Barium meal oesophagogram during the postoperative period showed normal oesophageal emptying. Signs of oesophagitis,

seepage of contents, adhesion to surrounding structures and clinically significant alterations like stricture and dilation were not observed in any of the animals (Fig.35).

Terminal findings

Weak fibrinous adhesion was observed between grafted site and perioesophageal cervical muscles in one dog (E 19), sacrificed on 15th day postoperatively (Fig.36). Gross pathological changes were not observed on oesophageal mucosa in both the dogs.

Biomechanical studies

Tensile strength of the specimen collected from the site was 2.65 (N/mm²) on 15th day postoperatively. There was an increase in tensile strength on 30th day followed by a decrease attaining 11.55 per cent strength to that of normal oesophagus on 60th day.

Breaking strength was 16.52 N on 15th day postoperatively. There was an increase in breaking strength on 30th day followed by a decrease attaining 15.03 per cent strength to that of normal oesophagus on 60th day.

Extensibility (per cent) was 8.21 on 15th day postoperatively. There was increase in extensibility during the

period of observation and it was 46.49 per cent more than that of normal oesophagus on 60th day.

Energy absorption was 0.03 Nm on 15th day post-operatively. There was an increase in energy absorption on 30th day followed by a decrease attaining 14.07 per cent energy absorption to that of normal oesophagus on 60th day.

Total dilatation capacity (per cent) was 85.00 on 15th day postoperatively. There was a reduction in total dilatation capacity on 30th day followed by an increase attaining 85.28 per cent to that of normal oesophagus on 60th day.

Gross morphological studies

15th day

Healing at the grafted site was complete in both the dogs. Mucosal continuity was not complete. In dog E 19, mild focal ulceration of the grafted site was observed (Fig.37). In dog E 20, a mucosal thickening was observed at the junction between the graft and the oesophageal tissue.

30th day

Healing at the grafted site was complete in both the dogs. Mucosal continuity was complete. In dog E 22, mild mucosal thickening around the grafted site was observed (Fig.38). Moderate fibrous tissue proliferation at the

anterior commissure of the grafted site was observed externally (Fig.39).

60th day

Complete healing of the grafted site externally (Fig.40) with normal oesophageal mucosal folds was observed in both the dogs (Fig.41).

Histomorphological studies

15th day

Infiltration of mononuclear cells and inflammatory oedema were observed at the level of grafting. Mucosal proliferation was almost complete at the site. Scattered fibroplasia, disintegration of elastin fibres and neovascularization were important features in the lamina propria (Fig.42).

30th day

Minimal inflammatory reaction at the level of graft with the presence of a few macrophages and neutrophil was noticed. Mucosal proliferation was complete at the site. There was mild fibroplasia and collagen deposition with degenerative changes in the muscular coat (Fig.43). Lamina propria was devoid of oesophageal glands.

60th day

A few mononuclear cells were observed at the site of healing. Mucosal lining was continuous and hyperplastic (Fig. 44). The graft tissue was found to be invaded with fibrovascular tissue at the site of implant indicative of late phase of healing. Fibroplasia was evident at the level of lamina propria (Fig.45) and extending into the muscular coat (Fig.46).

Table 17. Rectal temperature, pulse rate and respiration rate in dogs before and after oesophagoplasty using glutaraldehyde processed aortic allograft and pharyngostomy (Mean \pm SE)

Parameters with units	Pre- operative	Postoperative intervals (days)						
		1	2	3	4	5	6	7
Rectal temperature (°C)	39.15 \pm 0.24	38.94 \pm 0.25	39.33 \pm 0.14	38.96 \pm 0.19	38.85 \pm 0.25	38.80 \pm 0.21	39.00 \pm 0.15	39.13 \pm 0.14
Pulse rate (per min.)	93.00 \pm 5.08	84.33 \pm 4.21	94.67 \pm 3.28	94.67 \pm 3.14	86.67 \pm 5.63	79.50 \pm 4.49	85.33 \pm 3.40	85.17 \pm 2.99
Respiration rate (per min.)	25.50 \pm 1.86	22.00 \pm 2.97	26.17 \pm 2.81	23.84 \pm 1.85	24.50 \pm 1.91	22.00 \pm 1.46	21.17 \pm 0.65	23.17 \pm 1.83

n=6

Table 18. Haemogram in dogs before and after oesophagoplasty using glutaraldehyde processed aortic allograft and pharyngostomy (Mean±SE)

Parameters with units	Pre-operative	Postoperative intervals (days)		
		2	7	15
Haemoglobin concentration (g/dl)	11.32± 0.78	10.50± 0.97	11.28± 0.69	10.90± 0.33
Erythrocyte sedimentation rate (mm/h)	2.33± 0.42	3.00± 0.68	4.17± 1.14	3.17± 0.95
Packed cell volume (%)	35.33± 2.73	32.33± 1.86	31.83± 3.07	32.33± 1.69
Total erythrocyte count (10 ⁶ /mm ³)	4.41± 0.27	4.46± 0.35	4.98± 0.51	4.12± 0.16
Total leucocyte count (10 ³ /mm ³)	12.02± 0.79	14.84± 1.94	10.23± 1.86	10.08± 1.43
Neutrophil count (%)	78.83± 3.04	73.83± 2.47	71.67± 2.94	73.17± 2.66
Lymphocyte count (%)	23.83± 3.44	24.83± 2.34	26.33± 3.26	26.33± 3.02
Monocyte count (%)	0.67± 0.21	0.33± 0.21	1.17± 0.54	1.17± 0.40
Eosinophil count (%)	1.67± 0.72	1.00± 0.08	0.83± 0.48	1.00± 0.63
Basophil count (%)	0.00	0.00	0.00	0.00

Table 19. Serum constituents in dogs before and after oesophagoplasty using glutaraldehyde processed aortic allograft and pharyngostomy (Mean \pm SE)

Parameters with units	Pre-operative	Postoperative intervals (days)		
		2	7	15
		n=6		
Total serum protein (g/l)	72.54 \pm 2.76	64.06 \pm 5.23	52.51 \pm 5.22	61.37 \pm 4.64
Serum albumin (g/l)	25.59 \pm 1.06	22.99 \pm 1.57	23.14 \pm 1.36	22.74 \pm 1.12
Serum globulin (g/l)	46.95 \pm 2.94	41.06 \pm 4.37	29.37 \pm 4.34	38.63 \pm 4.06
Albumin-Globulin ratio	0.56 \pm 0.05	0.58 \pm 0.06	0.85 \pm 0.10	0.62 \pm 0.07
Serum sodium (mmol/l)	127.77 \pm 17.79	131.21 \pm 12.31	131.39 \pm 13.66	122.33 \pm 7.76
Serum potassium (mmol/l)	6.77 \pm 0.27	6.49 \pm 0.17	6.64 \pm 0.27	6.99 \pm 0.20
Serum chloride (mmol/l)	114.14 \pm 1.39	108.16 \pm 4.06	109.59 \pm 2.94	114.58 \pm 1.66

* Significant (P<0.05)

Table 20. Biomechanical characteristics of healing site of oesophagoplasty with glutaraldehyde processed aortic allograft in dogs subjected to oesophageal intubation

Parameters with units	Normal oesophagus n=6	Healing oesophageal defect (Interval in days) n=1		
		15	30	60
Tensile strength (N/mm ²)	12.03± 2.73	2.65 (22.03%)	7.47 (62.09%)	1.39 (11.55%)
Breaking strength (N)	128.19± 13.16	16.52 (12.89%)	57.50 (44.86%)	19.27 (15.03%)
Extensibility (%)	31.42± 2.58	8.21 (26.13%)	13.62 (43.35%)	46.03 (146.49%)
Energy absorption (Nm)	1.35± 0.22	0.03 (2.22%)	0.24 (17.77%)	0.19 (14.07%)
Total dilatation capacity (%)	100.00	85.00	76.49	85.28

Fig.35 Skiagram of cervical oesophagus on 60th postoperative day showing normal emptying of the content

Fig.36 Cervical oesophagus *in situ* at autopsy on 15th postoperative day showing weak fibrinous adhesion between the grafted site and cervical muscles

CHAPTER-V
DISCUSSION

Scope of study

I. Reconstructive surgery of cervical oesophagus

Repairing of defects in hollow/tubular organs by reconstructive surgery is an absolute necessity for better re-establishment of functional status and structural integrity. Oesophagus is considered to be an organ having poor healing quality owing to the lack of serosal layer, segmental blood supply, absence of movable surrounding structures like omentum which is capable of forming a rapid seal, lengthwise instretchability, weak musculature with poor suture holding power, tension, motion and distension at the surgical site (Patel *et al.*, 1981; Fingeroth, 1993). Considering these factors, Holmberg *et al.* (1991) opined that some form of grafting procedure is necessary for reconstruction of larger defects on oesophagus specifically at the cervical region.


Advantages of using homologous viable functional substitutes or heterologous tissues as graft materials are many. But disadvantages like additional trauma and stress on healing, difficulty in the availability/harvesting of suitable

and sizeable tissue, problems of tissue rejection and associated functional disturbances and long term complications may co-exist. The possibility of immediate restoration of continuity and functional capacity by a well tolerated prosthesis is hence the next choice.

Synthetic materials like dacron, polyethylene and rubber (McGuire et al., 1973), and Polypropylene (Howard et al., 1975) were employed as oesophageal wall substitute in dogs. Eventhough in some cases these materials have proved to be beneficial, most of them do not possess biological characteristics that are consistently important for a biomaterial.

Collagens are natural macromolecules which offer many of the desirable characteristics important for a biomaterial (Sastry, 1989). Moreover, it can be chemically modified to impart better mechanical properties and shelf life.

In comparison to many other tissues, aorta contains abundant quantity of elastic fibres, fine collagenous fibres and fibroblasts (Banks, 1981) which may provide sufficient tensile strength and elasticity to cope with functional capacity of oesophagus subsequent to grafting. Preserved aortic homografts were recommended as implants for repair of oesophageal defects in dogs (Javid, 1953).



In the present study, tissue samples of thoracic aorta harvested from euthanised dogs were processed, cross linked with chromic sulfate and glutaraldehyde, and preserved for using them as graft materials.

Cross linking of collagenous tissue using chromium salt or glutaraldehyde is a widely used method for preparation of biomaterial (Nimni and Cheung, 1994; Ruijgrok *et al.*, 1994). Jayakrishnan and Jameela (1996) reported that glutaraldehyde is a versatile agent in preparation of vascular graft, making them biocompatible, nonthrombogenic and nonantigenic. It reduces the biodegradation of the graft, preserving its anatomic integrity, leaflet strength and flexibility. Chromicised tissues like intestine (Gupta *et al.*, 1978), calf duramater (Sambandam, 1992), urinary bladder (Rameshkumar, 1993 and Sreenu *et al.*, 1997), glutaraldehyde cross linked bovine artery (Shetty *et al.*, 1982 and Sawyer *et al.*, 1987), dermal collagen (Frankland, 1986), human amniotic membrane (Rameshkumar, 1993), pericardium (Santillan *et al.*, 1995) and urinary bladder (Sreenu *et al.*, 1997) were employed as implant material for experimental reconstruction of hollow organs in bovines and dogs.

Chrome processed graft material showed comparatively more breaking strength, extensibility and energy absorption than glutaraldehyde processed graft material. Tensile strength of chrome processed graft material was relatively lesser than

that of glutaraldehyde processed graft material. Reasonable strength, an extensibility of 50-75 per cent to that of normal oesophagus and the structural qualities of the graft material makes them a functional substitute for oesophageal tissue. These qualities are in accordance with that reported by Sastry (1989) for an acceptable biomaterial. Graft materials used in the present study were having better handling qualities and shelf life as against other viable substitutes or synthetic materials recommended for cervical oesophagoplasty in dogs.

II Pharyngostomy

Bohning *et al.* (1970), Smith (1973), Crowe and Downs (1986) and Gregory *et al.* (1988) recommended the use of pharyngostomy tube feeding in diseased animals that were unable or unwilling to eat following oesophageal surgery to assist in the healing process. Smeak (1990) reported that the pharyngostomy procedure can be employed as a device for decompression of stomach, administration of fluid materials and splint or bypass in oesophageal ailments favouring healing process. However Slatter (1993), differed in his opinion about the use of pharyngostomy tubes for feeding patients who have undergone oesophageal surgery. Todhunter *et al.* (1986) observed a faster healing of wounds on oesophageal mucosa in equines following oesophageal intubation whereas Borgstrom and Lundy (1959) observed interference in normal oesophageal healing in the presence of intraoesophageal tubing.

In the present study, the modified pharyngostomy tube feeding method in dogs as described by Crowe and Downs (1986) and its influence on healing at the site of cervical oesophagoplasty were evaluated. A suitably designed siliconised catheter made of modified polyvinyl chloride with an attached X-ray opaque line was used as pharyngostomy tube. Length of the tube was premeasured for the individual animals.

Modified polyvinyl chloride tubing (Lantz *et al.*, 1983); silastic tubing and rubber all purpose catheter (Smeak, 1990) were advised as pharyngeal tubes in small animals. Lantz *et al.* (1983) recommended the use of soft tubing, placing with its aboral end as far as the anterior or mid thoracic oesophagus to avoid complications due to mechanical irritation of mucosa and gastric reflux. Balkany *et al.* (1970) described severe oesophageal erosions and ulcerations in dogs when a hard tube material was used in comparison to soft tube material.

Thirty apparently healthy, adult, non descript dogs of either sex were used in this study. The animals for the study were randomly divided into three groups viz., Group I, II and III. Group II and III were subdivided into two subgroups each namely IIA, IIB and IIIA, IIIB each consisting of six animals.

The average body weight (kilogram) of the dogs were 9.67 ± 0.94 , 11.58 ± 1.38 , 11.58 ± 0.63 , 12.08 ± 1.21 and

10.92 ± 0.78 in group I, subgroups IIA, IIB, IIIA and IIIB respectively.

Premedication with triflupromazine hydrochloride followed by thiopentone sodium as general anaesthetic was found to be suitable for the surgical procedure in the present study.

Hall (1966) stated that any type of anaesthesia is satisfactory for oesophageal surgery but the use of a relaxant drug is more ideal. Amarpal et al. (1995) employed Meperidine hydrochloride-thiopentone sodium as anaesthetic regimen for performing cervical oesophagoplasty in dogs.

Surgical technique

Oesophagoplasty

A wound on the ventral wall of the cervical oesophagus, oval in shape, measuring 3-4 cm long and 1/3rd of the circumference of oesophagus was created in all the experimental animals. The principles of oesophageal surgery as advocated by Smith (1973) was followed in the present study.

Oesophagoplasty was performed using chrome processed aortic allograft in dogs of subgroup IIA and IIB and glutaraldehyde processed aortic allograft in dogs of subgroup IIIA and IIIB. The graft material was fixed to the wound

edges using 5/0 braided silk thread and through and through continuous locking sutures. Mukerjee et al. (1973) and Naveenkumar et al. (1990) reported silk as a better suture material for oesophageal surgery. Amarpal et al. (1991) observed the effectiveness of through and through lock stitch technique for fixing graft material during cervical oesophagoplasty in dogs. Slatter (1993) recommended a suture pattern incorporating the muscularis and submucosa using, 3/0 or 4/0 silk for oesophageal surgery.

Pharyngostomy

Left side pharyngostomy as described by Crowe and Downs (1986) was performed in three animals of group I and six animals each of subgroups IIB and IIIB. The tube was kept *in situ* for a period of 15 days postoperatively for administration of fluid diet. Lantz et al. (1983) studied the effect of pharyngostomy in dogs by maintaining the tube continuously for 14 days.

Post surgical management

The animals were kept under observation for varying periods of 15, 30 and 60 days postoperatively. Oral feeding was avoided for seven days postoperatively in animals of subgroups IIA and IIIA and for 15 days postoperatively in subgroups IIB and IIIB. Slatter (1993) recommended withholding

of oral feeding for at least seven days postoperatively following patch grafting on oesophagus.

Observations on clinical parameters, physiological parameters, haemogram, serum constituents, oesophagogram and gross morphological changes on autopsy were studied in all animals. Biomechanical and histomorphological studies of the grafted site were conducted in three animals of each subgroup.

Clinical observations

General condition

The dogs became alert and active by first day postoperatively in control group and within 2-3 days in group II and III. The changes noticed might have been due to the prolonged anaesthesia and stress caused by the surgical procedures.

The animals of subgroup IIB and IIIB become alert and active earlier than that of IIA and IIIA which may be due to the effect of hyperelimentation through pharyngostomy tube.

Clinical evaluation of wound

Oesophagoplasty

Moderate pain, slight swelling and inflammatory oedema were observed at the operated site by second postoperative day

in all animals. The local inflammatory reaction gradually subsided and disappeared by 3-5 days. The symptoms observed could be attributed to the effect of surgical trauma. Skin wound showed normal healing and sutures were removed by 7-8th day postoperatively in all the groups, except in two animals, where following mutilation, the sutures were removed on the 10th day.

Pharyngostomy

Moderate pain and slight swelling around the pharyngostomy tube entrance site was observed on second postoperative day in three dogs. Tolerance of pharyngostomy tube was excellent in 13 of the 15 dogs. Two dogs dislodged the tubes once during the period of observation which were refixed on the same day. The pharyngostomy wound healed completely in all dogs by 14-15th day after removal of the tube. Mild bleeding while performing pharyngostomy was noticed only in one animal. Among the 64 complications reported by Crowe and Downs (1986) on a retrospective clinical study of pharyngostomy in dogs and cats, dislodgement of the tube and bleeding while tube insertion were experienced as in the present study.

Feeding behaviour

The experimental animals in which pharyngostomy was not adopted had started feeding liquid food by seventh day

postoperatively and maintained normal appetite and feeding habits throughout the period of observation. Mild swelling at the operated site while swallowing was observed in three dogs and it subsided on restricted feeding later on. Amarpal et al. (1991) observed unsuccessful attempts for regurgitation on fourth and fifth postoperative day following cervical oesophagoplasty in dogs.

Pharyngostomy tube feeding was instituted on first day postoperatively in all the animals subjected to pharyngostomy. Initial tube obstruction during first feeding was observed in six dogs. Slow and restricted feeding through pharyngostomy tube resolved this complication. Two dogs vomited immediately after first feeding through pharyngostomy tube. Mild diarrhoea was noticed in one dog on third and fourth day postoperatively. All the animals started feeding liquid diet by 15th day and maintained normal appetite and feeding habits throughout the period of observation. Crowe and Downs (1986) observed single or periodical vomiting in diseased dogs which received modified technique of pharyngostomy tube placement. In the present study, the feeding through the tube and management of animals were easier than parenteral alimentation adopted in animals of other subgroups. There were no behavioural or structural changes effected by the placement of pharyngostomy tube in the animals.

Physiological parameters

A marginal increase in rectal temperature was observed in animals of all groups on the first to second day post-operatively which gradually decreased and became normal by sixth day in subgroup IIB and IIIB. The value on sixth day was statistically significant in subgroup IIA. The increase in rectal temperature observed initially could be attributed to the presence of inflammation. The lowest temperature noticed in subgroup IIA may probably be due to a fall in basal metabolic rate as the animals were on intravenous parenteral nutrition for seven days. The observations are in agreement with Amarpal *et al.* (1991) on experimental oesophagoplasty in dogs.

There was a marginal increase in pulse rate by 1-3 days postoperatively and thereafter it remained at a lower level during the period of observation in animals of all subgroups. Amarpal *et al.* (1991) observed no significant variation in pulse rate during experimental cervical oesophagoplasty in dogs.

After a gradual decrease by 1-3 days postoperatively, the respiration rate was at a lower level with marginal variation during the period of observation in animals of all subgroups. Amarpal *et al.* (1991) observed no significant

variation in respiration rate following experimental cervical oesophagoplasty in dogs.

The conjunctival mucosa was slightly pale during early postoperative period in all experimental animals (1-4 days). They regained normalcy by 3-6 days. The condition was found to be prolonged in subgroup IIA and IIB.

A prolongation in capillary refilling time was observed by 1-2 days postoperatively in all experimental animals. All of them regained normalcy by seventh day.

The time taken for the skin to return to its normal position indicating mild dehydration was found to be prolonged till 2-4 days in all experimental animals. It was followed by a decrease thereafter during the period of observation.

The observations on physiological parameters during the postoperative period revealed that the graft material and the surgical technique employed for its implantation did not produce any untoward systemic effect. The animals which had undergone hyperalimentation through pharyngostomy tube recovered well at a faster rate during the postoperative period.

Haemogram

In all the experimental animals, haemoglobin concentration showed a marginal decrease by 2-7 days postoperatively followed by an increase on 15th day.

A marginal increase by 2-7 days postoperatively followed by a decrease on 15th day was observed in ESR of animals of subgroups IIA, IIIA and IIIB. In subgroup IIIA, a gradual increase was observed during the period of observation.

A marginal decrease in second day followed by an increase was observed in PCV in animals of all subgroups except IIB.

Animals of all subgroups showed an increase in TEC by 2-7 days postoperatively and reached near normal value on 15th day.

Animals of all subgroups showed an increase in TLC on second day postoperatively followed by marginal variation during the period of observation.

A marginal increase on second day postoperatively followed by a decrease was observed in neutrophil count in animals of subgroup IIA, IIB and IIIA. In subgroup IIIB, the values showed marginal variation during the period of observation.

Animals of subgroup IIA and IIB showed a decrease on second day postoperatively followed by marginal variation in lymphocyte count. In subgroups IIIA and IIIB, a steady increase in value was observed during the period of observation.

The monocyte and eosinophil counts showed marginal and insignificant variation during the period of observation in all the experimental animals.

The marginal variation observed in haemogram may be due to the cellular reactions to surgical trauma during the healing process (Gourley and Vasseur, 1985).

Serum constituents

A decrease in total serum protein content till seventh day postoperatively followed by an increase on 15th day was noticed in animals of subgroups IIA and IIIB. The decrease was statistically significant ($P < 0.05$) in subgroup IIIB. Other subgroups showed marginal variation during the period of observation. The initial decrease observed in total serum protein content may be attributed to the relative protein deficit associated with surgical stress (Carlson, 1997).

The serum albumin content decreased by 2-7 days postoperatively followed by an increase to reach near normal in animals of subgroups IIA, IIB and IIIB. In subgroup IIIA,

it was showing a steady decrease during the period of observation. The decrease in serum albumin content on second and seventh day in subgroup IIB was significant ($P < 0.05$).

The serum globulin content increased by 2-7 days postoperatively followed by a decrease to reach near normal on 15th day in subgroup IIB and IIIA. In subgroups IIA and IIIB, a decrease in serum globulin content till seventh day followed by an increase to reach near normal value was noticed. The decrease in serum globulin value on seventh day was significant ($P < 0.05$) in subgroup IIIB.

An initial increase in albumin-globulin ratio was observed by 2-7 days postoperatively in subgroups IIA and IIIB and a decrease by 2-7 days in other subgroups. The values were near normal by 15th day. The variation on seventh day was statistically significant in subgroup IIIB.

A reduction in serum albumin content and an increase in globulin content was reported following trauma in general (Zaslow, 1984). Variations in serum proteins observed in this study are indicative of the absence of neither heavy surgical stress nor foreign body reaction on graft implantation.

There was a marginal increase in serum sodium concentration on second day postoperatively in animals of all subgroups. The values then decreased to reach near normal by 15th day.

Serum potassium concentration remained marginally at a lower level by 2-7 days postoperatively in all subgroups except IIB. The values were slightly at higher level in all subgroups by 15th day.

Serum chloride concentration was seen maintained marginally at a lower level by 2-7 days postoperatively in all subgroups except IIA. The values were near normal on 15th day in all animals.

The marginal variations observed in serum electrolytes during the postoperative period may be attributed to surgical stress and it can be inferred that the hyperalimentation during the early postoperative period restored the balance of electrolyte in all experimental animals.

Radiographic observations

Barium meal oesophagogram during postoperative period showed normal oesophageal emptying in all experimental animals. Signs of oesophagitis, seepage of contents, adhesion to surrounding structures and clinically significant alterations like stricture and dilation were not observed in any of the animals.

Terminal findings

Gross pathological changes were not observed externally on cervical oesophagus in 18 of the 24 experimental animals.

Section 1

lower level

except in

subgroups

and

marginally

subgroups

in all

cases

is

not

clearly

defined

electronic

radiation

is

not

clearly

defined

to

electronic

any of the

terminal

part

Weak fibrinous adhesions were noticed between grafted site and perioesophageal cervical muscles in five dogs which were sacrificed on 15th day and one dog which was sacrificed on 30th day postoperatively. Such reactions were found to be absent by 60th day. Amarpal *et al.* (1995) reported the occurrence of vascular and fibrinous adhesions between graft and neighbouring muscles as early as 7th postoperative day following cervical oesophagoplasty using gastric seromuscular autogenous graft in dogs. They also observed a progressive reduction in adhesion by 60th day postoperatively.

Gross pathological changes were not observed on entire oesophageal mucosa in 23 of the 24 experimental animals. In one dog of subgroup IIB, mild hyperaemia of the oesophageal mucosa at its posterior third was noticed. The observations are in variance with that of Lantz *et al.* (1983), who observed erosions and ulcerations on oesophageal mucosa on use of modified polyvinyl chloride tubing for pharyngostomy in dogs.

Based on the clinical observations and changes in blood and serum constituents, it was found that the local and systemic response consequent on oesophagoplasty using the two graft material was minimum and well tolerated by the experimental animals. The graft material though autologous and chemically processed and the technique employed for implantation have not initiated systemic antigenic type of

response or functional disturbance in the experimental animals.

Weak adhesions were observed at the site of surgery in five of the eight animals sacrificed on day 15, only one animal out of eight sacrificed on day 30 and none of the animals sacrificed on day 60. The close contact of oesophagus with perioesophageal structures at the cervical region with inflammation caused by the surgical trauma must have initiated the adhesion but the restricted oesophageal movement due to parenteral feeding and the minimal tissue reaction shown by the graft material during the early phase of healing process probably reduced the intensity of local reaction resulting in formation of weak adhesions between the grafted site and perioesophageal tissues in the present study. However, as healing progressed the adhesions appear to have resolved spontaneously indicating that the adhesion in the early phase does not have long standing implications.

Studies on acceptability and functional efficacy of graft materials

Biomechanical studies

Values of tensile strength, breaking strength, extensibility and energy absorption of healing site implanted with chrome processed graft material were marginally higher on 15th day and lower on 30th and 60th day postoperatively than

that of the site implanted with glutaraldehyde processed graft material. Total dilatation capacity of healing site implanted with chrome processed graft material was marginally higher on 15th and 30th day postoperatively and lower on 60th day than that of the site implanted with glutaraldehyde processed graft material (Fig.47).

Healing tissue at the site of oesophagoplasty showed a steady increase in tensile strength, breaking strength, extensibility and energy absorption during the period of observation attaining 40.07, 32.48, 88.83 and 21.48 per cent respectively to that of normal oesophagus (Fig.48). The observations and the trend were in agreement with that of Amarpal *et al.* (1992 and 1995) on cervical oesophagoplasty using sternothyroideus pedicle graft and gastric seromuscular autogenous graft in dogs.

Total dilatation capacity at the grafted site was found to be decreased marginally on 30th day postoperatively followed by an increase attaining 82.70 per cent of that of normal oesophagus on 60th day. Todhunter *et al.* (1986) observed a reduction in lumen diameter of oesophagus on 15th and 30th day postoperatively and an increase between 30th and 40th days during healing process following cervical oesophageal mucosal resection and anastomosis in equines. The reduction in total dilatation capacity noticed on 30th day postoperatively in the present study may be attributed to

cicatrical contraction during the healing process at the site. The natural bougienage for deglutition after 15th day can probably be due to the gradual increase in total dilatation noticed afterwards.

Eventhough, the grafted site had not attained sufficient tensile and breaking strengths as normal oesophagus on 60th day postoperatively, the extensibility and dilation capacity were almost 80-90 per cent. An extesnsibility of 98.64 and 96.23 per cent to that of normal oesophagus was observed at the grafted site on 60th day following cervical oesophagoplasty using viable substitutes like split sternothyroideus pedicle graft (Amarpal et al., 1992) and gastric seromuscular autogenous graft (Amarpal et al., 1995) resepectively in dogs. It can be inferred that the graft materials used in this study are capable for providing sufficient functional capacity almost equal to that provided by live substitutes for oesophagus in dogs.

The animals in which oesophageal intubation was performed, the grafted site exhibited marginally higher breaking strength, extensibility, energy absorption and total dilatation capacity and a low tensile strength on 15th day postoperatively. By 60th day, they maintained a higher extensibility, but all other parameters were at a lower level (Fig.49). Borgstrom and Lundy (1959) reported the occurrence of a reduction in breaking strength in the area of anastamosis

of oesophagus following intubation. The reduction in tensile strength and breaking strength noticed between 30-60th day in the present study cannot be attributed to the oesophageal intubation since the tube was maintained only for 15 days postoperatively.

Gross morphological studies

Healing at the grafted site was complete in all the dogs by the 15th day. The mucosal continuity was not complete at the centre portion as evidenced by the presence of the colour of the respective graft material and relative thinness of the tissue. Mild corded thickening of the mucosa bordering the graft material was observed in three dogs (E 1, E 13 and E 20).

By 30th day, complete healing of the grafted site with a progressive increase in thickness of the tissue at the centre portion was observed in all the dogs. Mild corded thickening of the mucosa bordering the graft material was observed in two dogs (E 15 and E 22). A diphtheretic deposit on external aspect of the grafted site was noticed in one dog (E 4).

Complete healing of the grafted site with normal oesophageal folds were noticed in all the dogs by 60th day. The grafted site could not be differentiated from the normal oesophageal mucosa.

The results proved that the suture material and suturing technique employed in the present study had facilitated early healing, avoiding frequent complications encountered in cervical oesophageal surgery in dogs (Fingeroth, 1993). Morphologically, the healing site was similar to that of simple oesophageal wound (Fig.50).

Histomorphological studies

Mild inflammatory reaction characterised by infiltration of mononuclear cells, a few macrophages and inflammatory oedema were observed at the level of grafting by 15th day. Mucosal continuity was almost complete at the site. Scattered fibroplasia, neovascularization and disintegration of elastic fibres were the important features in the lamina propria.

By 30th day minimal inflammatory reaction at the level of graft with the presence of a few macrophages and polymorphs was noticed. There was proliferation of the lining mucosa and moderate fibroplasia adjacent to the graft. Lamina propria was devoid of oesophageal glands.

A few polymorphs and macrophages were noticed at the site of healing, squamous cell epithelial lining was slightly hyperplastic and the process of epithelization was complete by 60th day. Lamina propria was devoid of oesophageal glands. Muscular layer showed proper orientation of collagen and elastic fibres.

The following table shows the results of the experiments conducted on the effect of temperature on the rate of reaction between hydrogen peroxide and potassium iodide. The reaction is catalyzed by the presence of a small amount of potassium iodide. The rate of reaction was measured by the volume of oxygen gas evolved in a given time.

Temperature (°C)	Volume of oxygen (cm ³)
10	10
20	20
30	30
40	40
50	50

It is seen from the above table that the rate of reaction increases with increase in temperature. This is because the molecules of the reactants possess more energy at higher temperature and hence they are able to overcome the activation energy barrier more easily. The activation energy is the minimum energy required for the reaction to take place.

Amarpal et al. (1992 and 1995) observed almost similar cellular reactions and healing pattern following cervical oesophagoplasty with split sternothyroideus pedicle graft and free gastric seromuscular graft in dogs.

In the present study, it was observed that

The proliferative changes observed in the vicinity of the graft material and in the perioesophageal tissues were minimum.

The pattern of healing observed at the oesophagoplasty site was similar to that of normal first intention healing.

The time taken for acceptance of graft material was short and similar to that of a viable graft.

The healing at the oesophagoplasty site with either of the allografts did not vary considerably when the material was implanted. The presence of foreign material in the form of oesophageal tube has not adversely influenced the healing process.

These observations substantiate the properties of collagen as an excellent substrate for cellular attachment, and cellular ingrowth, and its capacity to stimulate fibroneogenesis. The cross linking of collagen by chrome/

glutaraldehyde processing of canine aortic tissue provided a biomaterial that is ideal for reconstructive surgery of the oesophagus. The experimental evaluation indicate that it satisfy all the qualities as suggested by Taylor (1982).

The biological qualities of the graft material used in the study opens up a new avenue for utilisation of valuable materials which are otherwise wasted. Though the study in the present context was restricted to reconstruction of oesophagus in dogs, the graft material often promises with regard to reconstruction of other tubular organs as well in animals. More extensive studies in other animals and involving various organs and different graft materials will be needed on these lines. Such study would definitely bring out valuable information by which it will become possible to provide biomaterials as cheap, easily available but very effective substitutes for costly synthetic materials.

FIG.47 COMPARISON OF BIOMECHANICAL CHARACTERISTICS OF HEALING SITE OF OESOPHAGOPLASTY WITH CHROME AND GLUTARALDEHYDE PROCESSED AORTIC ALLOGRAFTS IN DOGS

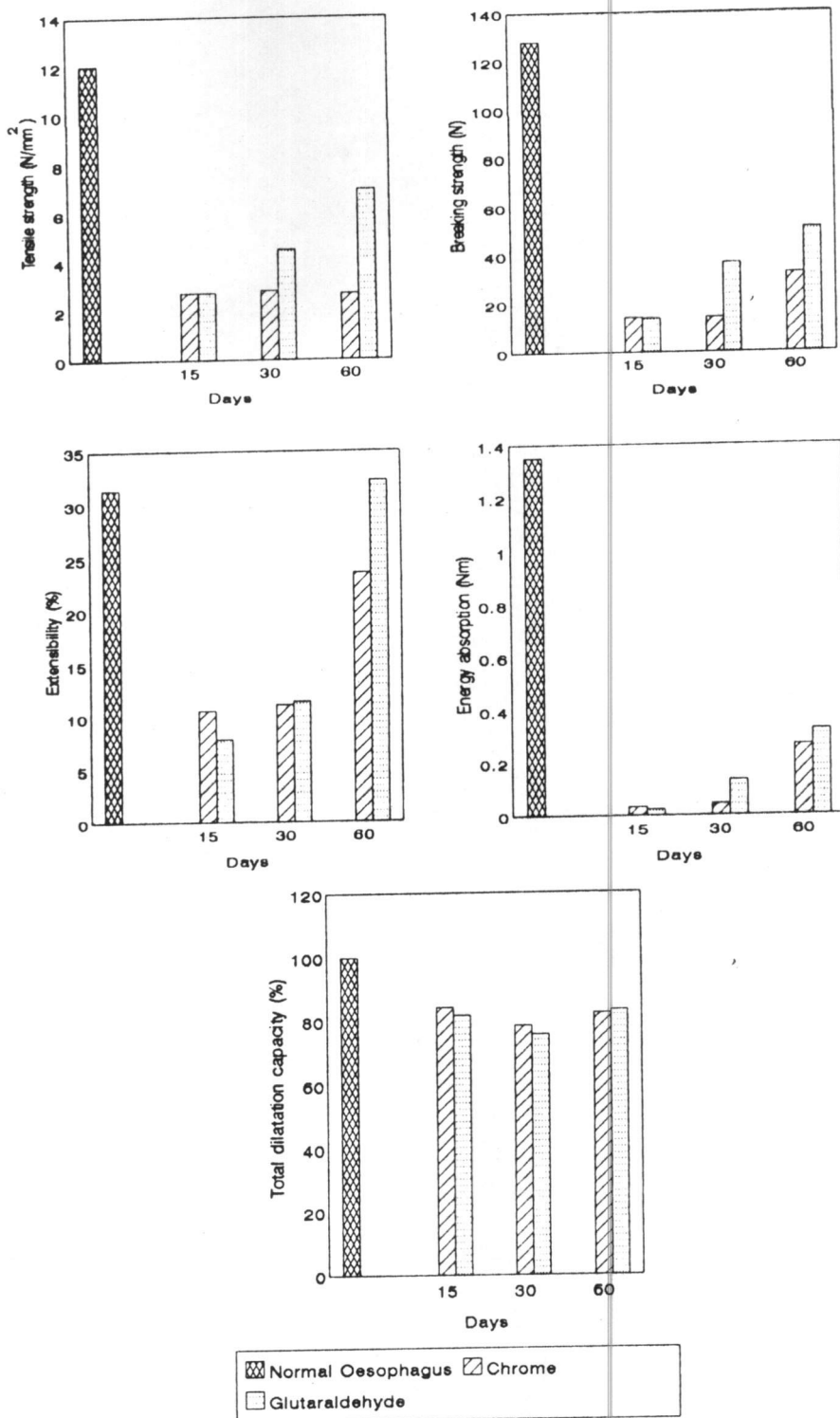


Fig.48 COMPARISON OF BIOMECHANICAL CHARACTERISTICS OF NORMAL OESOPHAGUS AND THE HEALING SITE OF OESOPHAGOPLASTY WITH PROCESSED AORTIC ALLOGRAFTS IN DOGS

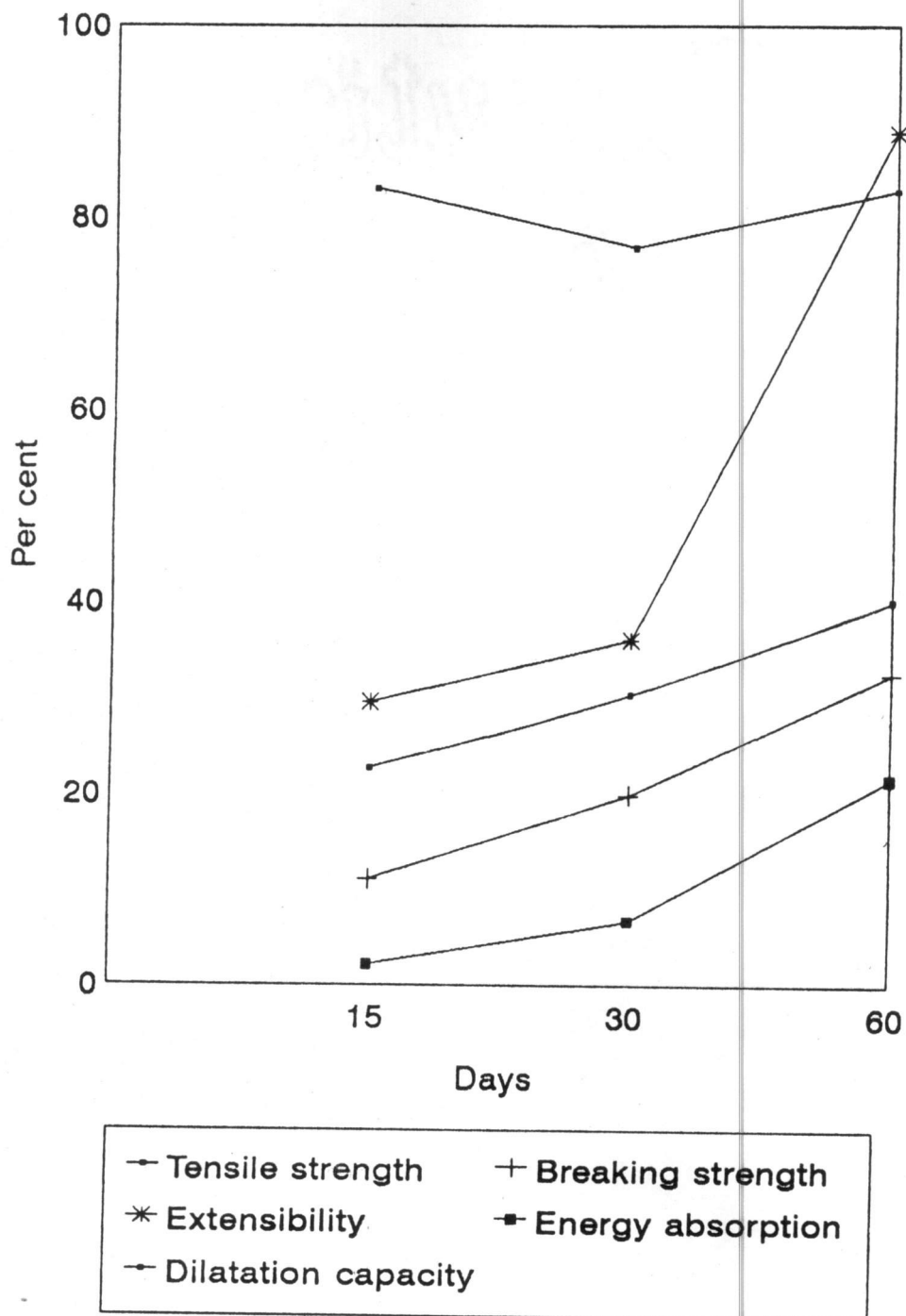
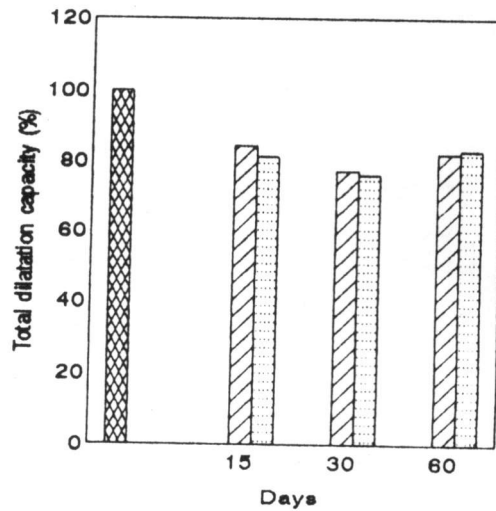
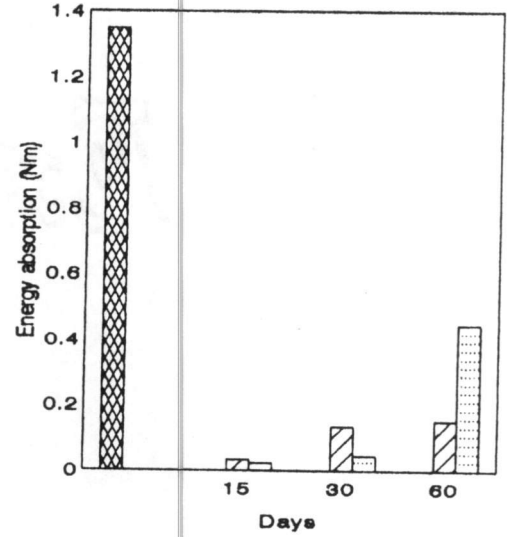
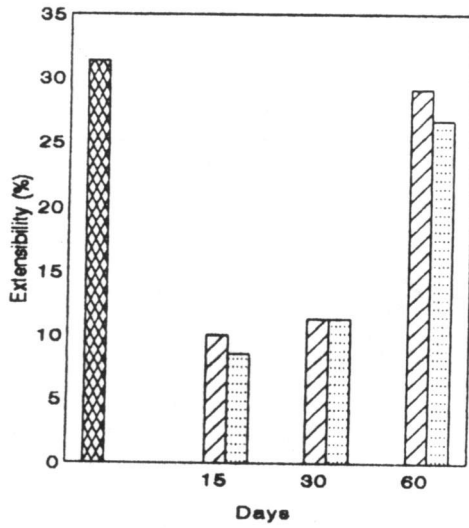
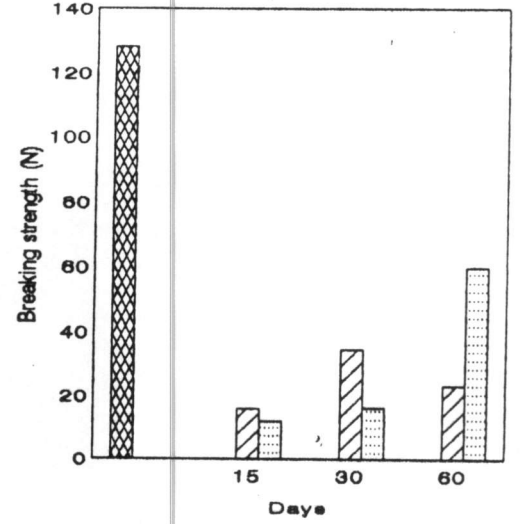
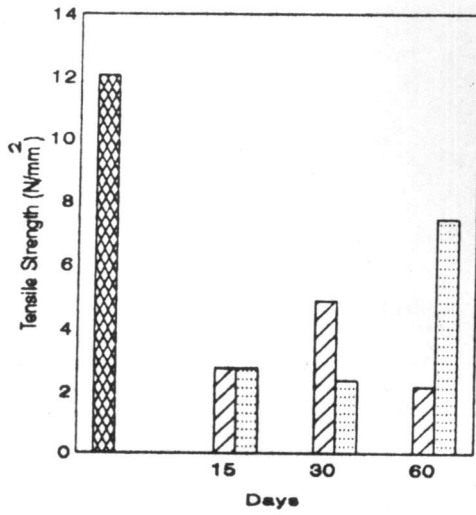
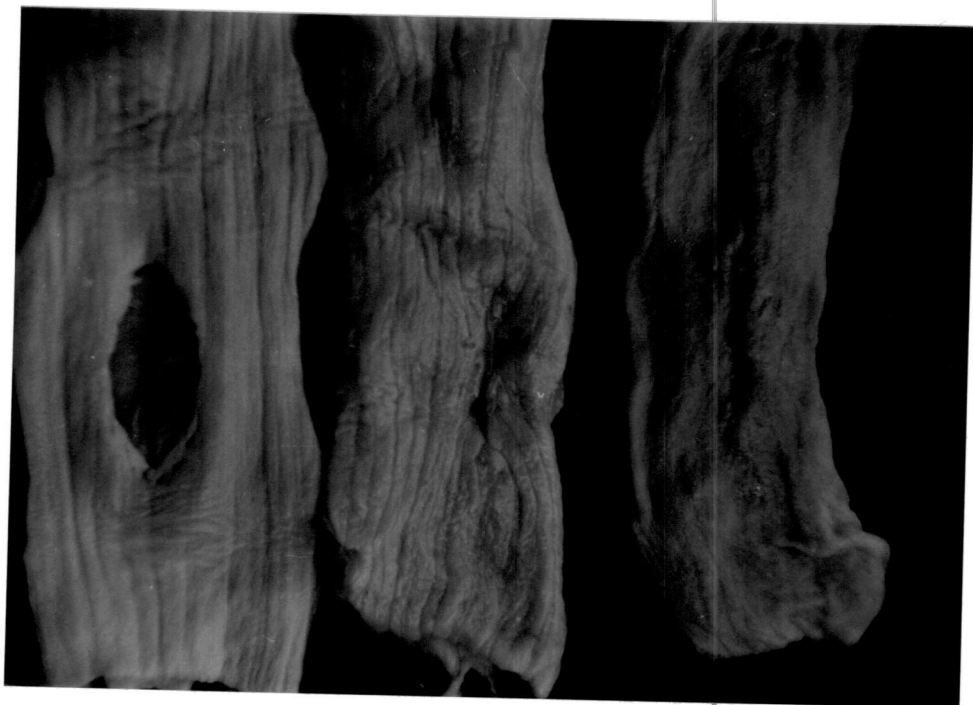


FIG.49 COMPARISON OF BIOMECHANICAL CHARACTERISTICS OF HEALING SITE OF OESOPHAGOPLASTY WITH PROCESSED AORTIC ALLOGRAFTS WITH AND WITHOUT OESOPHAGEAL INTUBATION IN DOGS



Normal Oesophagus
 With intubation
 Without intubation

Fig.50 Gross specimen: Grafted site on day of oesophagoplasty,
30th and 60th day postoperatively



Summary

CHAPTER-VI

SUMMARY

The experiment was conducted in thirty, apparently healthy, adult, nondescript dogs of either sex weighing 9-13 kg. The animals were randomly divided into three groups viz., group I, II and III. Group II and III were subdivided into two subgroups each, namely IIA, IIB and IIIA, IIIB. Group I and the subgroups consisted of six animals each.

Animals of group I were subjected to sham operation. Cervical oesophagoplasty using chrome processed aortic allograft and glutaraldehyde processed aortic allograft were performed in animals of group II and III respectively. Pharyngostomy tube feeding was instituted in three animals of group I and all animals of subgroups IIB and IIIB.

Tissue samples of thoracic aorta harvested from dogs, processed and crosslinked with chromic sulfate and glutaraldehyde were used as graft materials. Chrome processed aorta showed better biomechanical qualities except for tensile strength than glutaraldehyde processed aorta. The grafts had fairly good handling qualities and shelf life.

All the animals were premedicated with triflupromazine hydrochloride and anaesthetized using thiopentone sodium to effect.

Wound, oval in shape measuring 3-4 cm long and 1/3rd of the circumference of the oesophagus, was created in all experimental animals. Oesophagoplasty was performed by fixing the graft material over the defect using 5-0 braided silk thread and continuous lock stitch sutures.

Left side pharyngostomy was performed in 15 dogs. Suitably designed siliconised catheter made up of modified polyvinyl chloride with an attached X-ray opaque line was used as pharyngostomy tube. The tube was kept *in situ* for a period of 15 days postoperatively for administration of fluid diet.

The animals were kept under observation for varying periods of 15, 30 and 60 days postoperatively.

The animals of subgroups IIB and IIIB became alert and active earlier than that of IIA and IIIA.

At the cervical region, the operated site showed mild inflammatory reaction by 1-2 days postoperatively in all animals. The sutures were removed after normal healing by 7-8th day in all animals except one each in subgroup IIA and IIIB, where it was removed on the 10th day.

Mild bleeding while performing pharyngostomy (one dog) and moderate pain and slight swelling around the pharyngostomy tube entrance site (3 dogs) were observed in subgroup IIB. One animal in subgroup IIIB showed severe inflammatory oedema

around the tube entrance site. Tolerance of pharyngostomy tube was excellent in 13 dogs. The pharyngostomy wound healed completely by 14-15th day after removal of the tube in all the dogs.

All the animals started feeding on liquid food by seventh day postoperatively in subgroups IIA and IIIA following hyperalimentation via intravenous route and by 15th day in subgroups IIB and IIIB following hyperalimentation via pharyngostomy tube. They maintained normal appetite and feeding habits thereafter during the period of observation. Mild swelling at the operated site while swallowing (3 dogs) and vomiting (one dog) were noticed among the animals of subgroup IIA and IIIA. Initial tube obstruction during first feeding (6 dogs), vomiting after first feeding (2 dogs) and mild diarrhoea (one dog) were observed among animals of subgroup IIB and IIIB.

A marginal increase in rectal temperature and pulse rate, a gradual decrease in respiration rate, slight palor of conjunctival mucosa, marginal prolongation of capillary refill time, and time taken for skin to return to normal position were observed during early postoperative period in all experimental animals.

A marginal decrease in haemoglobin concentration and packed cell volume, a marginal increase in erythrocyte

sedimentation rate, total erythrocyte and leucocyte count were the salient features of haemogram during early postoperative period in all subgroups.

Differential count showed mild neutrophilia in all subgroups except IIIB. An increase in lymphocyte count in subgroup IIIA and IIIB with marginal variations in other subgroups was observed. Monocyte and eosinophil count showed marginal variation during the period of observation in all subgroups.

During early period of observation, a decrease in total serum protein and albumin content was noticed in all subgroups. Serum globulin content showed an increase in subgroups IIB and IIIA and a decrease in subgroup IIA and IIIB. Albumin-globulin ratio showed an increase in subgroups IIA and IIIB and a decrease in subgroups IIB and IIIA. All animals regained near normalcy by 15th day postoperatively.

Marginal variation in serum sodium, potassium and chloride concentration during the period of observation was noticed in all subgroups.

Oesophagogram during postoperative period showed normal oesophageal emptying and did not reveal signs of any complication.

Gross pathological changes were not observed on cervical oesophagus externally in 18 experimental animals. Weak fibrinous adhesions between grafted site and perioesophageal cervical muscles were noticed in one dog each in subgroup IIA and IIIB and two dogs each in subgroups IIB and IIIA.

Gross pathological changes were not observed on entire oesophageal mucosa in 23 experimental animals. Mild hyperaemia of the oesophageal mucosa at its posterior third was observed in one dog of subgroup IIB.

Healing site of oesophagoplasty showed a steady increase in tensile strength, breaking strength, extensibility and energy absorption during the period of observation.

Total dilatation capacity at the grafted site was showing a reduction on 30th day postoperatively followed by an increase on 60th day. Grafted site with glutaraldehyde processed graft was showing comparatively higher values for all parameters than that of chrome processed graft on 60th day postoperatively.

Healing at the grafted site was complete by 15th day. Regeneration of mucosa from sides of the graft material was grossly visible, which covered the whole graft by 30th day and became thicker and normal oesophageal folds were seen on 60th day. Mild corded thickening of the mucosa bordering the

grafted material was observed in one animal of subgroup IIA, and two animals each of subgroups IIIA and IIIB.

Histomorphological studies by 15th day postoperatively revealed mild inflammatory reaction characterised by the presence of polymorphonuclear cells, lymphocytes and a few macrophages at the site. Scattered fibroplasia, neovascularisation and disintegration of elastic fibres were salient features in lamina propria.

On 30th day, proliferation of lining mucosa, moderate fibroplasia and absence of oesophageal glands in lamina propria were evident.

By 60th day, the squamous cell epithelial lining was slightly hyperplastic, the lamina propria was devoid of oesophageal glands and muscular layer showed proper orientation of collagen and elastic fibres.

The following conclusions could be drawn from this study.

1. Chrome and glutaraldehyde processing of aortic tissue harvested from dogs satisfied the physical requirements for an allograft for oesophagoplasty in dogs.
2. The grafts can be used to reconstruct large oesophageal defects for bridging the gap without variation in size or lumen diameter of oesophagus.

3. The graft materials were well tolerated and the materials were found to cause minimal local or systemic reaction and restored satisfactory functional capacity by 15th day of implantation.
4. Pharyngostomy tube feeding is satisfactory substitute for parenteral administration in dogs subjected to oesophageal reconstruction.
5. Oesophageal intubation did not adversely affect the strength or healing process at the oesophagoplasty site.

References

REFERENCES

- Ahmad, M.A.R. (1965). Studies on experimental resection and anastomosis of the cervical oesophagus in canines. Thesis submitted to Madras University.
- Allen, D.S. (1922). Experimental reconstruction of the oesophagus with autogenous fascialata transplants. *Ann. Surg.* 76: 157.
- Al-Sadi, H.I. and I.M. Gourley. (1977). Simplified method for studying mechanical properties of healing linear skin wounds in the dog. *Am. J. Vet. Res.* 38(6): 903-906.
- Amarpal., B. Singh and Amreshkumar. (1991). Experimental oesophagoplasty in dogs. *Indian Vet. J.* 68: 148-150.
- Amarpal., B. Singh, Amreshkumar and P. Prakash. (1992). Mechanical, histological and histochemical evaluation of split sternothyroideus pedicle graft for cervical oesophagoplasty in dogs. *Indian J. Vet. Surg.* 13(1): 13-15.
- Amarpal, B. Singh and Amreshkumar. (1995). Gastric seromuscular autogenous graft for oesophagoplasty in dogs: Mechanical and histomorphological study. *Indian J. Vet. Surg.* 16(1): 35-38.
- Balkany, T.J., B.W. Jafek and M.L. Wong. (1970). Complications of feeding oesophagostomy. *Arch. Otolaryngol* (106): 122-123.

- Bancroft, J.D. and H.C. Cook. (1984). *Manual of Histological Techniques*. Churchill Livingstone, Edinburgh, London. 1st ed. pp.18-20, 39-41, 56-58.
- Banks, W.J. (1981). *Applied Veterinary Histology*. Williams and Wilkins, Baltimore. pp.306-308.
- Berman, E.F. (1952). The experimental replacement of portions of the oesophagus by a plastic tube. *Ann. Surg.* 135: 337-343.
- Bircher, E. (1894). Eln bietrag Zur plastischem bildung cines neuen oesophagus. *Zeutralbl. F. Chir.* 34: 1479-1907. Cited by Saint, J.H. (1929). Surgery of oesophagus. *Arch. Surg.* 19: 53-128.
- Bohning, R.H., W.D. Dehoff, A. Mc Elhinney. and P.C. Hofstra. (1970). Pharyngostomy for maintenance of anorectic animal. *J. Am. Vet. Med. Ass.* 156(5): 611-615.
- Bojrab, M.J., S.J. Birchard and J.L. Tominson. (1990). *Current Techniques in Small Animal Surgery*. Lea and Febiger, Philadelphia, 3rd ed. pp.204-205.
- Borgstrom, S. and B. Lundy. (1959). Healing of esophageal anastamosis: Animal experiments. *Ann. Surg.* 150: 142-148. Cited by Slatter, D. (1993). *Text Book of Small Animal Surgery*. Vol.I. W.B. Saunders Company, London. 2nd ed. p.558.
- Bryant, L.R. and B. Eiseman. (1965). Experimental evaluation of intercostal pedicle grafts in oesophageal repair. *J. Thorac. Cardiovarsc. Surg.* 50: 626-633.

- Carlson, G.P. (1997). Fluid, electrolyte and acid-base balance. Cited by J.J. Kaneko, J.W. Harvey, and M.L. Bruss. (1997). *Clinical Biochemistry of Domestic Animals*. Academic Press, London. 5th ed. pp.124-132.
- Clifford, D.H. (1985). The Oesophagus. Cited by Gourley, I.M. and P.B. Vasseur. (1985). *General Small Animal Surgery*. J.B. Lippincott Company, Philadelphia. pp.233-299.
- Coran, L.A.G. (1973). Pericardio-oesophagoplasty. *Am. J. Surg.* 125: 294-299.
- Crowe, D.T. (Jr.). and M.O. Downs. (1986). Pharyngostomy complications in dogs and cats and recommended technical modifications: Experimental and clinical investigations. *J. Am. Anim. Hosp. Ass.* 22: 493-503.
- Daleck, C.R., W. Gandolfi, C.L.M. Daleck and A.C. Alessi. (1987). Cervical oesophagoplasty in the dog with autologous or homologous peritoneum preserved in glycerin: Experimental study. *Ars. veterinaria.* 3(2): 195-202.
- Devitt, C.M. and H.B. Seim. (1997). Clinical evaluation of tube oesophagostomy in small animals. *J. Am. Anim. Hosp. Ass.* 33: 55-60.
- Fingerroth, J.M. (1993). Surgical techniques for oesophageal diseases. Cited by Slatter, D. (1993). *Text Book of Small Animal Surgery*. Vol.I, W.B. Saunders Company, London. 2nd ed. p.549-559.

- Frankland, A.L. (1986). Use of porcine dermal collagen in the repair of perineal hernia in dogs - A preliminary report. *Vet. Rec.* 119(1): 13-14.
- Gentry, P.A., M.D. Schneider and J.K. Miller. (1981). Plasma clot - Promoting effect of collagen in gelatin to Collagen - Platelet interaction. *Am. J. Vet. Res.* 42: 708-715.
- Gourley, I.M. and P.B. Vasseur. (1985). *General Small Animal Surgery.* J.B. Lippincott Co., Philadelphia. pp.241-251.
- Gregory, C.R., I.M. Gourley, D.S. Bruyett and L.J. Schults. (1988). Free jejunal segment for treatment of cervical oesophageal stricture in a dog. *J. Am. Vet. Med. Ass.* (193): 230-232.
- Grimes, O.F. (1960). Replacements of oesophagus. *Am. J. Surg.* 100: 278-292. Cited by Archibald, J. (1974). *Canine surgery.* American Veterinary Publication INC, California. 2nd ed. pp.481-503.
- Guffy, M.M. (1972). Radiographic examination of the dog and cat. *J. Am. Vet. Med. Ass.* 161(11): 1429.
- Gupta, R.L., R.K. Jain, M. Kumar, V.K. Pratap, K.J. Scaria and M. Snatappa. (1978). Fate of collagen sheet cover for artificially created raw areas: An experimental study. *Indian J. Surg.* 40: 641-645.
- Hall, L.W. (1966). Conditions of canine oesophagus-III. Anaesthesia for oesophageal surgery. *J. Small Anim. Pract.* 7(2): 129-134.
- Holmberg, D.L., A.B. Kuzma and C.W. Miller. (1991). Free bowel transfer of oesophageal reconstruction in a dog. *Microsurgery.* 12(2): 140-144.

- Howard, D.R., J.J. Lammerding and P.V. Dewevre. (1975). Esophageal reinforcement with sternothyroideus muscle in the dog. *Canine Pract.* 2: 30-35.
- Hugh, T.B., R.J. Lusby and M.J. Coleman. (1979). Antral patch esophagoplasty: A new procedure for Acid-Peptic oesophageal stricture. *Am. J. Surg.* 137: 221-225.
- Inchiosa, M.A. (1964). Direct biuret determination of total protein in tissue homogenates. *J. Lab. Clino. Med.* 63: 319-324.
- Jain, N.C. (1986). Schalm's Veterinary Haematology, Lea and Febiger, Philadelphia, 4th ed. pp.35-44, 53-56.
- Jayakrishnan, A. and S.R. Jameela. (1996). Glutaraldehyde as a fixative in bioprostheses and drug delivery matrices. *Biomaterials.* 17(5): 471-484.
- Javid, H. (1953). Bridging of oesophageal defects with fresh and preserved aorta grafts. *S. forum*, 3: 83. Cited by Peer, L.A. (1959). *Transplantation of Tissues.* Vol.II. The williams and wilkins company, Baltimore. p.378.
- Kleinsasser, L.J., I. Cremer and H. Warshaw. (1950). Anastomosis of cervical oesophagus: Experimental evaluation of peritoneal grafts. *Surgery* 28: 438-442.
- Klopp, C.T., C. Alford and H. Pierpont. (1951). The use of polyethylene film and split thickness skin graft in reconstruction of cervical oesophageal and pharyngeal defects. *Surgery* 29: 231-239.

- Kumar, A., A.K. Sharma and P.N. Kapoor. (1987). Mechanical evaluation of metal and linen sutures for skin closure in dogs and buffaloes. *Indian vet. J.* 64: 123-126.
- Kuzma, A.B., D.L. Holmberg, C.W. Miller, I. Barker and J. Roth. (1989). Esophageal replacement in the dog by microvascular colon transfer. *Vet. Surg.* 18(6): 439-445.
- La Guerre, J.N., H. Schoenfeld, W. Calem, F.E. Gould and B.S. Levowitz. (1968). *J. Thorac. Cardiovasc. Surg.* 56: 674.
- Lammerding, J., D.R. Howard and G.A. Noser. (1976). Diaphragmatic pedicle flaps for repair of distal oesophageal defects in dogs. *J. Am. Anim. Hosp. Ass.* 12: 558-592.
- Lantz, G.C., H.D. Cantwell, J.F. VanVleet, J.C. Blakemore and S. Newman. (1983). Pharyngostomy tube induced oesophagitis in the dog: An experimental study. *J. Am. Anim. Hosp. Ass.* 19: 209-212.
- Lawson, D.D. and H.M. Pirie. (1966). Conditions of the canine oesophagus-II: Vascular rings, achalasia, tumours and perioesophageal lesions. *J. Small Anim. Pract.* 7: 117-127.
- McGuire, N.G., M.N. Hoare and D.C. Davies. (1973). Replacement of hypopharynx and oesophagus by a prosthesis in pigs. *Res. Vet. Sci.* 14(3): 358-363.
- Mohanty, M. (1995). Biological evaluation of materials for medical devices. *Trends in Biomaterials and Artificial organs.* 9(1): 2-8.

- Mukerjee, S., M. Nigam and M.L. Awtarmani. (1973). Evaluation of free omental graft in the healing of oesophageal anastomosis: An experimental study in dogs. *Indian J. Surg.* 35(1): 539-543.
- Naveenkumar, P. Kinjavdeker, R.J. Choudhary, T.K. Gahlot and K.S. Deora. (1990). An experimental study on oesophageal end to end anastomosis by inverting and everting techniques in dogs. *Indian J. Vet. Surg.* 11(1): 11-15.
- Nimni, M.E. and D.T. Cheung. (1994). Pure collagen network preparation from animal tissue. Cited in Derwent Biotechnology Abstracts No.95-02642.
- Orton, E.C. and T.O. McCracken. (1995). Small Animal Thoracic Surgery. Williams and Wilking Co. pp.122-123.
- Patel, G.R., B.M. Jani, R.R. Parsania, K.N. Vyas and M.N. Mannari. (1981). Experimental oesophageal anastomosis by eversion technique in buffalo calves: A histomorphological and histochemical study. *Indian J. Vet. Surg.* 2(2): 57-61.
- Pavletic, M.M. (1981). Reconstructive oesophageal surgery in the dog: A literature review and case report. *J. Am. Anim. Hosp. Ass.* 17: 435-444.
- Peer, L.A. (1959). Transplantation of tissues. Vol.II, The Williams and Wilkins Company, Baltimore. p.378.
- Petrovsky, B.V. (1961). The use of diaphragm grafts for plastic operations in thoracic surgery. *J. Thorac. Cardiovasc. Surg.* 41: 348-355.

- Rameshkumar, B. (1993). Comparative studies on the use of different grafts for experimental cystoplasty in buffalo calves. Ph.D. thesis. Submitted to Tamil Nadu Veterinary and Animal Sciences University.
- Reed, J.H. (1974). Esophagus. Cited by Archibald, J. (1974). Canine Surgery. American Veterinary Publications, INC, California. 2nd ed. pp.481-503.
- Ruijgrok, J.M., J.R. Dewijn and M.E. Boon. (1994). Optimizing glutaraldehyde cross linking of collagen - Effects of time, temperature and concentration as measured by shrinkage temperature. *J. mater. Sci. Mater. Med.* 5: 80-87.
- Sambandam, T. (1992). Studies on cystoplasty using chromicised collagen sheet. M.V.Sc. thesis submitted to Tamil Nadu Veterinary and Animal Sciences University.
- Santillan, D.P., V.R. Jasso, V.A. Sotres, R. Olmes, J.L. Arreola, D. Garcia, B. Vanda and M. Gaxiola (1995). Repair of thoracoabdominal wall defects in dogs using a bovine pericardium bioprosthesis. *Rev. Invest. Clin.* 47(6): 439-446.
- Sastry, T.P. (1989). Development and evaluation of collagen based biomaterials. Ph.D. Thesis submitted to Madras University.
- Sawyer, P.N., J. Fitzgerald and M.J. Kaplitt. (1987). Ten year experience with the negatively charged glutaraldehyde tanned vascular graft in peripheral vascular surgery. Initial multicenter trial. *Am. J. Surg.* 154: 533-537.

- Schalm, C.W. (1975). *Veterinary haematology*. Lea and Febiger, Philadelphia, 3rd ed. pp.39-40, 52-66.
- Schultz, L.R., C. Rodrigues-Pereira and H.W. Clatworthy. (1962). An experimental evaluation of suture materials in the anastomosis of the oesophagus in growing animals. *Am. J. Surg.* 104(6): 843-849.
- Seidenberg, B., S.S. Rosenak, E.S., Hurwitt and M.L. Som. (1959). Immediate reconstruction of the cervical oesophagus by a revascularized isolated jejunal segment. *Ann. Surg.* 149: 162-171.
- Shetty, B.R., GajrajSingh, J.M. Nigam and A.P. Singh. (1982). Histopathological observations following transplantation of fresh and treated bovine arterial xenografts in canine. *Indian J. Anim. Sci.* 52(6): 422-428.
- Singh, J. and R.P.S. Tyagi. (1972). Experimental studies on the oesophageal anastomosis with special reference to transplantation in buffalo calves. *Indian Vet. J.* 49(8): 814-821.
- Slatter, D. (1993). *Text Book of Small Animal Surgery*. Vol.I, W.B. Saunders Company, London. 2nd ed. pp.549-559.
- Smeak, D.D. (1990). The chinese finger trap suture technique for fastening tubes and catheters. *J. Am. Anim. Hosp. Ass.* 26: 215-218.
- Smith, G.S. (1973). Oesophagotomy and oesophageal resection. *J. small. Anim. Pract.* 14: 429-439.

- Snedecor, G.W. and W.G. Cochran. (1967). Statistical methods. Oxford and IBH Publishing Co., Calcutta, 6th ed. p.59.
- Sreenu, M., T.P. Sastry and O. Ramakrishna. (1997). Studies on bladder bursting pressure following cystoplasty using chromic sulfate and glutaraldehyde cross linked bladder grafts in dogs. *Indian J. Vet. Surg.* 18(1): 30.
- Stick, J.A., F.J. Derkson and E.D. Scott. (1981). Equine cervical oesophagostomy: Complications associated with duration and location of feeding tubes. *Am. J. Vet. Res.* 42(5): 727-732.
- Straw, R.C., J.L. Tomlinson, G. Constantinescu, M.A.M. Turk, and P.M. Hogan. (1987). Use of a vascular skeletal muscle graft for canine oesophageal reconstruction. *Vet. Surg.* 16: 155-163.
- Taylor, D.E.M. (1982). Biomaterials for reconstructive surgery. Cited by Bevan, P.G. (1982). *Reconstructive procedures in surgery.* Blackwell Scientific Publications, London. pp.43-63.
- Todhunter, R.J., J.A. Stick and R.F. Slocombe. (1986). Comparison of three feeding techniques after oesophageal mucosal resection and anastomosis in horses. *Cornell Vet.* 76: 16-29.
- Zaslow, I.M. (1984). *Veterinary Trauma and Critical Care.* Lea and Febiger, Philadelphia. 1st ed. pp.33-37.

PROCESSED AORTIC ALLOGRAFTS FOR OESOPHAGOPLASTY IN DOGS


**By
T. P. BALAGOPALAN**

ABSTRACT OF A THESIS
**Submitted in partial fulfilment of the
requirement for the degree**

Doctor of Philosophy
Faculty of Veterinary and Animal Sciences
Kerala Agricultural University

Department of Surgery
COLLEGE OF VETERINARY AND ANIMAL SCIENCES
MANNUTHY, THRISSUR
KERALA, INDIA

1998



ABSTRACT

The study was conducted with the objectives of

- a. Preparation, preservation and evaluation of chrome/glutaraldehyde cross linked aortic tissue of dogs and to compare the relative acceptability and efficacy of them for cervical oesophagoplasty in dogs, and
- b. Evaluation of modified pharyngostomy feeding method and its effect on healing at cervical oesophagoplasty site in dogs.

The experiment was conducted in thirty, apparently healthy, adult, nondescript dogs of either sex weighing 9-13 kg. The animals were randomly divided into three groups viz., group I, II and III. Group II and III were subdivided into two subgroups each, namely IIA, IIB and IIIA, IIIB. Group I and the subgroups consisted of six animals each.

Animals of group I were subjected to sham operation. Cervical oesophagoplasty using chrome processed aortic allograft and glutaraldehyde processed aortic allograft were performed in animals of group II and III respectively. Pharyngostomy tube feeding was instituted in three animals of group I and all animals of subgroups IIB and IIIB.

Tissue samples of thoracic aorta harvested from dogs, processed and crosslinked with chromic sulfate and glutaraldehyde were used as graft materials. Chrome processed aorta showed better biomechanical qualities except for tensile strength than glutaraldehyde processed aorta. The grafts had fairly good handling qualities and shelf life.

All the animals were premedicated with triflupromazine hydrochloride and anaesthetized using thiopentone sodium to effect.

Wound, oval in shape measuring 3-4 cm long and 1/3rd of the circumference of the oesophagus was created in all experimental animals. Oesophagoplasty was performed by fixing the graft material over the defect using 5-0 braided silk thread and continuous lock stitch sutures.

Left side pharyngostomy was performed in 15 dogs. Suitably designed siliconised catheter made up of modified polyvinyl chloride with an attached X-ray opaque line was used as pharyngostomy tube. The tube was kept *in situ* for a period of 15 days postoperatively for administration of fluid diet.

The animals were kept under observation for varying periods of 15, 30 and 60 days postoperatively.

The animals of subgroups IIB and IIIB became alert and active earlier than that of IIA and IIIA.

At the cervical region, the operated site showed mild inflammatory reaction by 1-2 days postoperatively in all animals. The sutures were removed after normal healing by 7-8th day in all animals except one each in subgroup IIA and IIIB, where it was removed on the 10th day.

Mild bleeding while performing pharyngostomy (one dog) and moderate pain and slight swelling around the pharyngostomy tube entrance site (3 dogs) were observed in subgroup IIB. One animal in subgroup IIIB showed severe inflammatory oedema around the tube entrance site. Tolerance of pharyngostomy tube was excellent in 13 dogs. The pharyngostomy wound healed completely by 14-15th day after removal of the tube in all the dogs.

All the animals started feeding on liquid food by seventh day postoperatively in subgroups IIA and IIIA following hyperalimentation via intravenous route and by 15th day in subgroups IIB and IIIB following hyperalimentation via pharyngostomy tube. They maintained normal appetite and feeding habits thereafter during the period of observation. Mild swelling at the operated site while swallowing (3 dogs) and vomiting (one dog) were noticed among the animals of subgroup IIA and IIIA. Initial tube obstruction during first feeding (6 dogs), vomiting after first feeding (2 dogs) and mild diarrhoea (one dog) were observed among animals of subgroup IIB and IIIB.

A marginal increase in rectal temperature and pulse rate, a gradual decrease in respiration rate, slight palor of conjunctival mucosa, marginal prolongation of capillary refill time, and time taken for skin to return to normal position were observed during early postoperative period in all experimental animals.

A marginal decrease in haemoglobin concentration and packed cell volume, a marginal increase in erythrocyte sedimentation rate, total erythrocyte and leucocyte count were the salient features of haemogram during early postoperative period in all subgroups.

Differential count showed mild neutrophilia in all subgroups except IIIB. An increase in lymphocyte count in subgroup IIIA and IIIB with marginal variations in other subgroups was observed. Monocyte and eosinophil count showed marginal variation during the period of observation in all subgroups.

During early period of observation, a decrease in total serum protein and albumin content was noticed in all subgroups. Serum globulin content showed an increase in subgroups IIB and IIIA and a decrease in subgroup IIA and IIIB. Albumin-globulin ratio showed an increase in subgroups IIA and IIIB and a decrease in subgroups IIB and IIIA. All animals regained near normalcy by 15th day postoperatively.

Marginal variation in serum sodium, potassium and chloride concentration during the period of observation was noticed in all subgroups.

Oesophagogram during postoperative period showed normal oesophageal emptying and did not reveal signs of any complication.

Gross pathological changes were not observed on cervical oesophagus externally in 18 experimental animals. Weak fibrinous adhesions between grafted site and perioesophageal cervical muscles were noticed in one dog each in subgroup IIA and IIIB and two dogs each in subgroups IIB and IIIA.

Gross pathological changes were not observed on entire oesophageal mucosa in 23 experimental animals. Mild hyperaemia of the oesophageal mucosa at its posterior third was observed in one dog of subgroup IIB.

Healing site of oesophagoplasty showed a steady increase in tensile strength, breaking strength, extensibility and energy absorption during the period of observation.

Total dilatation capacity at the grafted site was showing a reduction on 30th day postoperatively followed by an increase on 60th day. Grafted site with glutaraldehyde processed graft was showing comparatively higher values for

all parameters than that of chrome processed graft on 60th day postoperatively.

Healing at the grafted site was complete by 15th day. Regeneration of mucosa from sides of the graft material was grossly visible, which covered the whole graft by 30th day and became thicker and normal oesophageal folds were seen on 60th day. Mild corded thickening of the mucosa bordering the grafted material was observed in one animal of subgroup IIA, and two animals each of subgroups IIIA and IIIB.

Histomorphological studies by 15th day postoperatively revealed mild inflammatory reaction characterised by the presence of polymorphonuclear cells, lymphocytes and a few macrophages at the site. Scattered fibroplasia, neovascularisation and disintegration of elastic fibres were salient features in lamina propria.

On 30th day, proliferation of lining mucosa, moderate fibroplasia and absence of oesophageal glands in lamina propria were evident.

By 60th day, the squamous cell epithelial lining was slightly hyperplastic, the lamina propria was devoid of oesophageal glands and muscular layer showed proper orientation of collagen and elastic fibres.

