


02
25221

PREVALENCE AND PATHOLOGY OF DERMATOLOGICAL DISORDERS IN CATTLE

By
R. ANILKUMAR



THESIS

Submitted in partial fulfilment of the
requirement for the degree

Master of Veterinary Science

Faculty of Veterinary and Animal Sciences
KERALA AGRICULTURAL UNIVERSITY

Centre of Excellence in Pathology
COLLEGE OF VETERINARY AND ANIMAL SCIENCES
MANNUTHY - THRISSUR


1996

DECLARATION

I hereby declare that the thesis entitled "PREVALENCE AND PATHOLOGY OF DERMATOLOGICAL DISORDERS IN CATTLE" is a bonafide record of research work done by me during the course of research and that the thesis has not previously formed the basis for the award to me of any degree, diploma, associateship, fellowship or other similar title, of any other University or Society.

Mannuthy,

25-7-96



R. ANIL KUMAR

CERTIFICATE

Certified that this thesis, entitled "PREVALENCE AND PATHOLOGY OF DERMATOLOGICAL DISORDERS IN CATTLE" is a record of research work done independently by Sri. R. Anil Kumar, under my guidance and supervision and that it has not previously formed the basis for the award of any degree, fellowship or associateship to him.



2021

Dr. A. Rajan

(Chairman, Advisory Committee)

Dean

College of Veterinary and


Animal Sciences

Mannuthy

Mannuthy

CERTIFICATE

We, the undersigned members of the Advisory Committee of Sri. R. Anil Kumar, a candidate for the degree of Master of Veterinary Science in Veterinary Pathology, agree that the thesis entitled "PREVALENCE AND PATHOLOGY OF DERMATOLOGICAL DISORDERS IN CATTLE" may be submitted by Sri. R. Anil Kumar, in partial fulfilment of the requirement for the degree.



Dr. A. Rajan


(Chairman, Advisory Committee)

Dean


College of Veterinary and Animal Sciences
Mannuthy



Dr. K.M. Ramachandran
Professor and Head
Department of Pathology
(Member)



Dr. K.V. Valsala
Associate Professor
Department of Pathology
(Member)



Dr. V.S. Balakrishnan
Professor
Department of Clinical Medicine
(Member)



External Examiner

ACKNOWLEDGEMENT

I wish to express my deep sense of gratitude and indebtedness to Dr. A. Rajan, Dean, College of Veterinary and Animal Sciences, Mannuthy and Chairman of the Advisory Committee for the constant encouragement, valuable guidance and untiring support rendered throughout the period of study.

I am deeply indebted to Dr. K.M. Ramachandran, Professor and Head, Department of Pathology and member of the advisory committee for his meticulous guidance, constant encouragement and paternal affection shown to me during the course of my research.

I express my profound gratitude to Dr. K.V. Valsala, Associate Professor, Department of Pathology for her timely help and encouragement as a member of the advisory committee.

I am very much grateful Dr. V.S. Balakrishnan, Professor, Department of Clinical Medicine for his advice and support as a member of the advisory committee.

I express my sincere gratitude to all the staff members of the Centre of Excellence in Pathology for their constant help and valuable suggestions.

Credit is also extended to the staff of the University Veterinary Hospitals, Kokkalai, Mannuthy and to Veterinary Surgeons Dr. Naveen, Dr. Harshakumar, Dr. Varghese, Dr. Pradeep and Dr. S. Manu Mohan of Animal Husbandry Department Institutions in and around Thrissur for the help rendered in collecting skin biopsies.

I express my sincere thanks to Dr. K.C. George and other staff members of the Department of Statistics for the help rendered by them.

I am also thankful to Mr. A.P. Peter of the Centre of Excellence in Pathology for his generous help and cooperation.

I appreciate the whole hearted co-operation help and motivation offered to me by my colleagues. Dr. Ajith Jacob George, Dr. Jacob Alexander, Dr. Prasanna, K.S., Dr. S.K. Chaudhari, Dr. K.C. George, Dr. Vyas, M.S., Dr. S. Manu Mohan and many others.

I am thankful to the Kerala Agricultural University for awarding me the fellowship for the period of study.

I am short of words to express my gratitude to my parents and family members who had been the main support during the study.

R. ANIL KUMAR

***In memory of
my beloved father***

CONTENTS

Chapter No.	Title	Page No.
1.	INTRODUCTION	1
2.	REVIEW OF LITERATURE	4
3.	MATERIALS AND METHODS	41
4.	RESULTS	46
5.	DISCUSSION	76
6.	SUMMARY	88
	REFERENCES	92
	ABSTRACT	

LIST OF TABLES

Table No.	Title	Page No.
1.	Cattle population in Kerala	64
2.	Prevalence of Tail Necrosis in cattle in Kerala state during the period 1989 to 1993	65
3.	Prevalence of Cutaneous mycosis in cattle in Kerala state during the period 1989 to 1993	66
4.	Prevalence of Eczema in cattle in Kerala state during the period 1989 to 1993	67
5.	Prevalence of pox in cattle in Kerala state during the period 1989 to 1993	68
6.	Prevalence of tick infestation in cattle in Kerala state during the period 1989 to 1993	69
7.	Prevalence of lice infestation in cattle in Kerala state during the period 1989 to 1993	70
8.	Prevalence of Mangy dermatitis in cattle in Kerala state during the period 1989 to 1993	71
9.	Different types of skin lesions encountered in cattle during the period of study (September 1992 to August 1994)	72
10.	Measurement of the thickness of the skin in calves before and after administration of PHA-M	73
11.	Measurement of thickness of the skin in mm calves before and after application of DNCB	74
12.	Measurement of thickness of skin in mm calves before and after administration of BCG	75

LIST OF ILLUSTRATIONS*

Figure No.	Title
1.	Prevalence of dermatological disorders in cattle of Kerala (Disease Surveillance report 1989-1993)
2.	Dermatological disorders encountered in cattle during the period of study (1992-1994)
3.	Cow-Hyperkeratosis - Lumbar region with irregular thick greyish white patch
4.	Hyperkeratosis of stratified squamous epithelium acanthosis and thickening of the stratum corneum. H&Ex100
5.	Hyperkeratosis - degenerated hair follicles, cystic follicular structures surrounded by flattened epidermal cells and concentrically arranged keratin. H&Ex250
6.	Hyperkeratosis - cystic hair follicles with concentrically arranged keratin and thick layer of stratum corneum. H&Ex160
7.	Hyperkeratosis - follicles filled with keratin plugs. H&Ex250
8.	Cow-Hypertrichosis - Lumbar region - bilateral multiple black irregular patches with excessive hair growth
9.	Hypertrichosis - hyperplasia of the outer root sheath cells - Hair follicles show keratin plugs. H&Ex250
10.	Hypertrichosis high proportion of medullated hair follicles - hyperkeratosis of stratum corneum - more number of follicles in a given area. H&Ex160
11.	Cow - Fly bite dermatitis base of the neck and shoulder region - raised greyish white necrotic papules and wheals

Figure No.	Title
12.	Cow - Ear - Fly bite dermatitis - necrotic papules and wheals with haemorrhagic crusts
13.	Fly bite dermatitis - perivascular dermatitis - with infiltration of inflammatory cells in the dermo-epidermal junction. H&Ex160
14.	Cow - Fly bite dermatitis superficial haemorrhage - epidermal oedema - mild hyperkeratosis. H&Ex250
15.	Cow - Cutaneous ulceration - neck region - exposure of raw surface - scar tissue formation and loss of hair
16.	Cow - Cutaneous ulceration - shoulder region - A well defined ulcer with granulating base
17.	Cutaneous ulceration - epidermal lysis - mild perivascular reaction - folliculitis. H&Ex160
18.	Cutaneous ulcerations - loss of architecture of the epidermis and part of the dermis. Areas of hyalinisation
19.	Cutaneous ulceration - Epidermolysis - free hyalinised hair shafts in the follicle - Hydropic degeneration of basal cells below the necrosed layer. H&Ex160
20.	Cow - Decubitus ulcers - shoulder region
21.	Decubitus ulcers Thinning of the epidermis with exudation - Atrophic changes of hair follicles. Dilatation of the sweat glands H&Ex160
22.	Decubitus ulcers - atrophic changes of the hair follicular epithelium
23.	Decubitus ulcers - atrophy of the hair follicles and sebaceous gland atrophy. H&Ex250
24.	Cow - Dermatophilosus - rump region with focal circumscribed areas of hyperkeratosis - some areas show multiple crusts

Figure No.	Title
25.	Dermatophilosis - hyperkeratosis - acanthosis - hydropic changes in the prickle cell layer. H&Ex250
26.	Dermatophilosis - parakeratosis and coccoid organisms are seen - diffuse dermatitis. H&Ex250
27.	Teat lesions - epidermal necrosis - fibrous tissue proliferation - diffuse granulomatous reaction and exudation above the necrosed epidermal layer. H&Ex160
28.	Exudative dermatitis - hydropic degeneration of the epidermal cells - perivascular inflammatory reaction. Exudative reaction on the epidermis - dermal odema. H&Ex160
29.	Ectoparasitic injury - focal epidermal necrosis - slight infiltration of inflammatory cells - epidermal cells shows hydropic change
30.	Cow - papillomatosis - udder and base of the teat - flat firm and broad based warts
31.	Papillomatosis - epithelial and fibrous tissue proliferation, ballooning degeneration and clumping of keratohyalin granules. Spongiosis - dyskeratosis. H&Ex400
32.	Papillomatosis - irregular and undulating epidermal configuration - Dyskeratosis and pronounced acanthosis. H&Ex160
33.	Papillomatosis irregular and undulating epidermal configuration - lower layer reveals spongiosis - and engorged blood vessels. H&Ex250
34.	Squamous cell carcinoma - epidermal hyperplasia - islands of epidermal cells in dermis - cell nests with keratohyalin granules. H&Ex250
35.	Cow - Fibroma - interlacing wavy bundles of proliferating fibroblasts. H&Ex160

Figure No.	Title
36.	Fibroma - lymphocytic infiltration - Epidermal hyperplasia bundles of collagen seen separating the bundles of proliferating cells. H&Ex250
37.	Cow - Teat - Fibrosarcoma - interwoven bundles of immature fibroblasts seen irregularly scattered - Varying stages of mitosis seen - Scanty collagen bundles seen separating group of fibroblasts. H&Ex160
38.	Cutaneous hypersensitivity reaction to PHA-M 48 h biopsy - perivascular cuffing of lymphocytes. H&Ex250
39.	Cutaneous hypersensitivity reaction to DNCB 48 h biopsy - Capillary congestion and oedema - perivascular cuffing with macrophages and lymphocytes. H&Ex250
40.	Cutaneous hypersensitivity reaction to BCG 48 h biopsy - oedema cellular infiltration in the deeper part of dermis with mononuclear cells. H&E x 250
41.	Changes in the skin to BHC application 5th day biopsy - slight hyperkeratosis and dermolysis. H&Ex160
42.	Changes in the skin to Furadan application - 5th day biopsy - mild degree of hyperkeratosis and acanthosis and cystic dilatation of sweat glands

* In between page Nos. 75&76

Introduction

INTRODUCTION

Skin is the largest organ in the body which serves as the anatomical and physiological barrier between the animal and the environment. It provides protection to the animal from the physical, chemical and microbiologic injury and the sensory components of the skin perceive heat, cold, pain, pruritis, touch and pressure. In addition, the skin is synergistic with internal organ systems and thus reflects pathologic processes that either are primary elsewhere or are shared with other tissues.

Not only is the skin an organ with its own reaction patterns but also it is a mirror reflecting the "milieu interior" and at the same time manifesting the reaction to the capricious world to which it is exposed. The function of the skin are varied and significant, and the body cannot exist without it. In spite of the significance of this organ, the diseases affecting the skin has not been given due importance in veterinary medicine.

As it has a very significant role to play as an organ of the body it also play a major role in the Indian economy. According to the report of the National Commission on Agriculture (1976) the annual production of hide and skin in the world is 6 million and 1.3 million tonnes respectively.

The share of India is 12 per cent in hide production and 7.4 in skin production and ranks 2nd and 5th in the world respectively. The average annual export ranged from Rs.63 crores during the triennium ending 1968-69 to Rs.146 crores during the triennium ending 1973-74. Damage to the skin causes severe economic loss as it earns a good amount of foreign currency which is dearly needed for the country. Any damage to the skin of the animal will result in its condemnation or reduction in price leading to a big loss.

Although, reports have been made on the diseases of the skin of cattle from this country, disorders affecting the skin of cattle has not been the subject of detailed investigation. It would appear that when compared to other organs this organ of vital importance has not been given due importance in research investigations.

The skin is the reacting zone to the change in the environment as far as the animal is concerned. In accordance to the change in the environment, there is likely to be dermatologic changes based on the environmental changes prevalent in different regions. Therefore, dermatological studies also have regional importance.

Studies on the skin diseases of cattle have been very much limited in the country and also in the state of Kerala. Mostly the studies made are confined to isolated individual

cases and so far, no systematic studies have been undertaken on the skin disorders of cattle in Kerala.

Therefore, with the objective of studying the prevalence and nature of skin disorders in cattle an in-depth study was undertaken. In addition, in order to elicit and evaluate the nature of cutaneous response in cattle to certain agro-chemicals, an experimental study was also undertaken.

Review of Literature

REVIEW OF LITERATURE

Published literature on different dermatological disorders encountered in cattle are relatively meagre. The published reports have been documented under different well recognised dermatologic lesions.

2.1 Dermatitis

It was described to be caused by a variety of bacterial agents, viral agents, parasites, plant poisons and chemical agents (Scott, 1988).

2.1.1 Bacterial dermatitis

Staphylococcal dermatitis

Baklen (1980) isolated *Staphylococcus aureus* from summer sores at the base of the teats in dry cows.

Nicholls and Rubiro (1981) described an outbreak of staphylococcal dermatitis in cattle associated with mastitis. Many cows had skin lesions which could be grouped as small pustules, large healing erosive lesions or generalised exudative dermatitis extending from the perineum to teats and laterally down each side of the udder and thighs. Skin biopsy

revealed subcorneal pustular dermatitis and cocci were visible within the pustules.

Mbassa (1985) reported a case of diffuse gangrene of the hind limb associated with umbilicus infection in a calf. *S. aureus* was isolated from this gangrene.

Staphylococcal folliculitis and furunculosis were commonly seen in young bulls and lesions were mainly found in the tail and perineum. In some cases it was seen as papules and crusts over the rump. Skin biopsy revealed varying degree of perifolliculitis, folliculitis and furunculosis with extensive tissue eosinophilia (Scott, 1988).

Hararika et al. (1990) isolated *S. hycus* from cutaneous lesions of cattle and intracutaneous administration of *S. hycus* in a calf resulted in exfoliative dermatitis.

Corynebacterial dermatitis

Outbreak of ulcerative lymphangitis in cattle caused by *Cornyebacterium ovis* was reported (Purchase, 1944). Lesions were found on the shoulders, forelegs and flanks. Skin biopsy revealed superficial and deep perivascular dermatitis to diffuse dermatitis.

C. paratuberculosis was also described to cause ulcerative lymphangitis in cattle. Lesions were seen on the

fetlock region which consisted of hard to fluctuant nodules with abscesses. The dermatitis was suppurative with oedema and fibrosis (Blood and Radostits, 1983). Addo (1983) studied the role of *Musca domestica* in the spread of ulcerative lymphangitis.

Dermatophilosis

Abusamra *et al.* (1976) described the palisading crust formation histopathologically in dermatophilosis in cattle.

Pianta (1987) isolated *D. congolensis* from the epithelial crust and skin scrapings from cattle in Brazil. Scott (1988) stated that Dermatophilosis could be diagnosed by the typical "rail road tracks" appearance of coccoid cells from the impression smears of exudate and crusts.

Pal (1989) stated that out of 140 animals examined 25.7 per cent were clinically affected. 72.2 per cent of these had encrusted lesions.

Hannes and Dom (1990) isolated *D. congolensis* from a cow with exudative epidermitis in a herd of 65 cows in Antwerp province of Belgium.

Histopathologically skin revealed varying degree of folliculitis, perivascular dermatitis and intercellular oedema of keratinocytes. Surface crust was characterized by

alternating layers of keratin and leukocytic debris in the palisading crust.

Morrow and Compton (1991) reported that studies conducted in 927 cattle in the wet season of St. Lucia, 39 cattle were positive for *D. congolensis*. The prevalence of this disease was severe in certain areas where *Amblyomma variegatum* ticks were present. Sharma et al. (1992) reported an outbreak of Dermatophilosis in Punjab. Asegedech Sirak and Iofante (1994) demonstrated characteristic branching hyphae of *D. congolensis* in smears of the scabs in 51 dairy cattle in Ethiopia.

Actinobacillosis

Campbell et al. (1975) reported an unusual epizootic of actinobacillosis in dairy heifers characterized by thick walled abscesses of soft tissue of the head. They observed 73 per cent morbidity and were mainly seen in animals aged 4-21 months. Parihar et al. (1977) reported a case of cutaneous Actinobacillosis in a bull which showed multiple alopecia and crusted nodules over the back. There was a rough oval growth on the anterior-lower margin of the dewlap attached to the skin by a thick peduncle. Histopathology revealed proliferated connective tissue which contained various sized purulent foci containing bacterial aggregation having dense centre and clubbed periphery.

Mycobacterial dermatitis

Mitchell (1928) stated that atypical Mycobacteriosis was a world wide cause of skin disease in cattle. Jarnagin (1983) isolated *M. kansasii* from the lymph node of cattle affected with skin tuberculosis in USA. Dermatohistopathological findings included tuberculoid granulomas with or without caseation and mineralization.

Cutaneous Anthrax

Mohiyudeen and Rao (1958) reported an epidemic of cutaneous Anthrax among bovines in north Kanara District. Massive oedematous swelling was seen on the neck, brisket, flanks, abdomen and perineum. Necrosis and sloughing were also observed. Histopathology revealed diffuse subcutaneous and dermal odema with numerous extravasated erythrocytes and few inflammatory cells.

Salmonellosis

O'Conner et al. (1972) reported *S. dublin* infection associated with gangrene of the distal extremities of the tail and pinnae in cattle. Histopathological studies revealed intimal thickening, thrombosis of arteries and veins and perivascular inflammation. Richardson (1972) reported *S. dublin* infection in calves associated with necrosis and

sloughing of the entire patch of the skin of the feet due to capillary engorgement and thrombosis.

2.1.2 Viral dermatitis

Pox virus infections

Cherille and Shey (1967) and Nagington *et al.* (1967) reported cases of pseudo cow pox affecting the teats udder and perineum. Ulcerations were seen characterised by horse-shoe shaped crust.

Magsood (1958) reported a case of generalised buffalo pox. The lesions predominantly affected teats, udder, medial aspect of thighs lips and muzzle.

Lauder *et al.* (1971) experimentally induced vaccinia infection in cattle which resulted in papular lesions.

Gibbs *et al.* (1973) reported a case of cow pox in a dairy herd in the United Kingdom. There was pyrexia and tenderness of teats followed by typical cutaneous sequence of events leading to pocks which were thick red crust of 1-2 cm in diameter and lesions were confined to teats and udder. Scabs were thick tenaceous and yellow-brown to red in colour.

Lumpy skin disease

Ali and Obeid (1977) reported an outbreak of lumpy skin disease in Sudan. The 0.5 to 5 cm in diameter lesions were firm, well circumscribed and flattened. Histopathologically eosinophilic, intracytoplasmic inclusion bodies were found in the keratinocytes, macrophages, endothelial cells, pericytes and fibroblasts. Rajan et al. (1990) reported a case resembling lumpy skin disease in Kerala. El-Allawy et al. (1992) isolated 20 isolates from skin nodules and skin scrapings and identified them as pox virus by their cytopathogenic effect on CAM, MDBK, cell lines and serologically by solid phase ELISA.

Foot and mouth disease

Udayasankar (1986), Balakrishnan (1988) reported abnormal hair coat of varying degree in 93.48 per cent of the panthers in some villages of Chittoor and Thirupathi in Andhra Pradesh.

Skin lesions encountered in foot and mouth disease were described by Dibakarsen (1990). Lesions were seen on the neck, shoulder, ventral surface of the abdomen, udder and buttocks. Rupture of vesicles and bullae lead to painful erosions on the muzzle, nostrils, coronet, interdigital spaces udder and teats. Biopsy revealed hyperplastic superficial and deep perivascular dermatitis with marked intra and inter

cellular oedema within the stratum spinosum (Yilma, 1980). Generalized hypertrichosis was observed in cattle suffering from chronic foot and mouth disease (Jubb et al. 1992).

Rinderpest

Joshi et al. (1977) described cutaneous eruptions in Rinderpest out break among bovines. Cutaneous changes were characterized by erythema, papules, oozing, crust and alopecia over the perineum, flanks, medial thigh, neck, scrotum and teats. Skin lesions were described, in a buffalo with a moist eczematous lesion of the udder, inner aspect of thighs, neck and flank. Biopsy revealed hydropic interface dermatitis with single cell necrosis and multinucleate syncytial formation within the epithelium (Jubb et al. 1992).

2.1.3 Mycotic dermatitis

Dermatophytosis (Ringworm)

In cattle *T. verrucosum* was the most common cause of dermatophytosis. Lesions were most commonly seen on the head, neck and pelvis and varied from discrete circular areas of alopecia to severe scaling, crusting, suppuration and ulceration (Sellers, 1956).

Gupta and Singh (1969) observed characteristic locations of lesions such as periocular region of calves, the thorax and

limbs of cows and heifers and the dewlap and intermaxillary space of bulls.

An outbreak of ring worm infection in a group of cattle in USA was reported by Edwardson and Andrews (1979). Chatterjee and Sengupta (1979) reported 9.8 per cent incidence of ring worm infestation in cattle of West Bengal which were mainly caused by *T. verrucosum* and *T. mentagrophytone*. Lesions were seen mainly on the head, face and neck. Grunder (1984) recorded 1 per cent incidence of ring worm infection out of 725 cattle in an abattoir study in Germany. A similar outbreak in a group of buffalo calves was reported in India by Sharma et al. (1991). Lesions were seen on the head, neck and inter maxillary space. They were circumscribed, and 2-6 cm in diameter covered with very thick layer of grey white scale crust. Histopathologically acanthosis, hyperkeratosis parafolliculitis, folliculitis and furunculosis were seen. The fungus was demonstrated at the dermis and subcutis.

Visual examination of 12520 veal calves of Zurich abattoir gave a mean prevalence of ring worm of 7.7 per cent. Ringworm infection was more prevalent in farms with large groups of calves (Haab et al. 1994).

2.1.4 Protozoal dermatitis

Trypanosomiasis

T. brucei was reported to cause urticarial plaques over the neck, chest and flanks of cattle in Africa. Direct smear revealed numerous trypanosomes and skin biopsy revealed perivascular to diffuse dermatitis with numerous lymphocytes histiocytes and extravascular trypanosomes (Ikede and Losos, 1972).

Besnoitiosis

Hussein and Haroun (1975) reported on outbreak of besnoitiosis in Sudan. Affected cattle developed anorexia, pyrexia, photophobia and painful swellings on the distal extremities and ventrum.

The skin was thickened, lichenified, and fissured. Biopsy revealed parasitic cysts which were surrounded by degeneration, fibrosis, necrosis and a mixed inflammatory cell infiltration (Soulsby, 1982). Liu and Wang (1982) demonstrated trophozoites of *Besnoitia besnoiti* in skin nodules causing 'thick skin disease' of cattle in Mangolia.

2.1.5 Parasitic dermatitis

Psoroptic mange

Linklater and Gillespie (1984) reported an outbreak of psoroptic mange in cattle in USA. Affected area of the skin was thickened and alopecic. There was intense pruritis on the shoulders and rump. Non follicular papules and pustules, crusts, excoriations and lichenification were also observed. Stromberg et al. (1986) studied the systemic pathologic responses in experimentally induced *Psoroptes ovis* infestation in Hereford calves. Eosinophilia was observed.

Gradle(1987) stated that hide damage in cattle brought for slaughter was mainly due to mange when compared with other disease damages to hide.

Gabaj et al. (1992) conducted a survey of mites in farm animals in Libya and noted that the commonest parasites in cattle were psoroptes and chorioptes.

Chorioptic mange

Amstutz (1979) stated that *C. bovis* was common in stabled dairy cattle during winter in USA. Lesions were nonfollicular papules, crusts, alopecia, erythema, oozing and ulceration.

A syndrome characterized by coronitis, foot rot like lesion, muzzle lesions, weight loss and drop in production was described by Scott (1988).

Reddy et al. (1992) reported a generalized form of chorioptic mange in a Holstein Friesian cow. Biopsy revealed variable degree of superficial perivascular dermatitis with numerous eosinophils.

Demodectic mange

Baker (1973) reported Demodex species in the meibomian gland of Irish cattle. Murray et al. (1976) stated that Demodectic mange caused severe economic loss due to hide damage in Australia. Slingenbergh et al. (1980) related the extent of visible skin lesion in bovine demodicosis to the level of nutrition and exposure to sunshine. Gearhart et al. (1981) reported a case of bilateral lower palpebral demodicosis in a dairy cow. There was sudden appearance of diffuse firm swelling beneath both eyes and biopsy revealed a chronic eosinophilic granulomatous cellulitis and degenerated mites. Valentine et al. (1991) explained the pathology of hair follicle lesions in the nodular form of demodectic mange in cattle. The nodule arose when granulomatous inflammation was complicated by secondary bacterial infection.

Tick infestation

Rajmohan (1980) reported the prevalence of *Boophilus annulatus* in Kerala. They were seen during all seasons of the year in all the districts. The infestation was more in hilly tracts compared to costal areas. The area of attack on the skin was the ear, face, neck, axillae, groin, distal limbs and tail. Initially skin lesions consisted of papules, pustules, wheals and nodules centered around ticks. These primary lesions developed crust, erosion, ulcers and alopecia. Biopsy revealed epidermal necrosis, oedema and infiltration with neutrophils, eosinophils and mononuclear cells. Reactions of the previously infested hosts were characterized by intraepidermal vesicopustular dermatitis (Scott, 1988). Studies in the stuttgart abattoir by Platzen (1988) revealed that hide damage due to ectoparasites especially ticks was considerably high (19%). Host reaction in heavy *B. microplus* infestation included irritation, itching haemorrhagic spots, papule formation, oedema, hyperemia and inflammation accompanied by alopecia at the site of attachment. Serum revealed significant reduction in albumin content and slight increase in globulin content. Microscopically changes consisted of superficial invasion of mononuclear cells like lymphocytes and neutrophils at the site of tick bites. There was dilatation of blood vessels with

lymphatic accumulation around blood vessels along with increased sweat and sebaceous secretions (Hazari et al. 1991).

Lice infestation

Menon (1953) recorded the incidence of *Haematopinus tuberculatus* in India throughout the year but more prevalent during the winter season.

Herford cattle maintained on range had heavy infestation with *Haematopinus eurysternus*. In these animals anaemia and loss of weight were observed (Collins et al. 1965). Galloway (1972) observed anaemia, loss of weight, unthriftiness and predisposition to other diseases due to heavy lice infestation. Chaudhuri (1976) reported the occurrence of *Haematopinus tuberculatus*, *H. eurysternus* and *Linognathus vituli* in India. He observed that the cattle became lousy when they remained inside sheds during winter. Mohan (1979) reported an occurrence of *Haematopinus quadripertusus* and *Linognathus vituli* in cattle of Kerala with an incidence of 44.34 per cent and 3.47 per cent respectively.

Chalmer and Charleston (1980) reported the prevalence of *Damalina bovis* and *Linognathus vituli* in New Zealand. *D. bovis* was observed on beef breeds and *L. vituli* on dairy herd. Louse infestation caused pruritis, and restlessness. Sucking lice like *Haematopinus eurysternus*, *Linognathus vituli* and

Solenopotes capillatus were found commonly around the poll nose, eyes, neck and groin. *Damalina bovis* a biting louse preferred the neck, withers and tailhead. Patchy alopecia, excoriation and scaling of skin were noticed. Skin biopsy revealed varying degree of superficial perivascular dermatitis with numerous eosinophils, focal area of epidermal necrosis, odema and leukocytic exocytosis as well as eosinophilic intraepidermal microabscesses (Scott, 1988).

Biting flies

Mosquitoes

Mosquitoes caused substantial economic loss via decreased milk production, hide damage and disease transmission. Mosquito bite produced wheals and papules that were invariably pruritic and painful (Blood and Radostits, 1983).

Culicoides

Culicoides caused immediate pain, pruritis, followed by papules and wheals (Soulsby, 1982). Yeruham et al. (1993) described hypersensitivity lesions in the skin of cattle from various regions of Israel due to *Culicoides*. Lesions on the legs and abdomen were due to *C. obsoletus* and lesions on the back, flanks, head and neck were due to *C. imicola*.

Simulium

Scott (1988) described lesions in simulium bite. Simulid bite caused painful papular wheals and often caused vesicular haemorrhagic and necrotic sites on the head, neck, ventrum and ears. Biopsy revealed varying degree of superficial perivascular dermatitis with numerous eosinophils, focal areas of epidermal necrosis, purpura and subepidermal haemorrhagic bullae.

Hypodermiasis

Khan (1968) stated that the larval stages of *Hypoderma bovis* and *H. lineatum* were common parasites of cattle in many parts of the northern hemisphere. Gingrich (1982) stated that calves and younger cattle were more frequently and severely affected than older cattle and suggested the development of acquired immunity.

Scott (1988) described the lesion produced by *Hypoderma*. Lesions appeared as numerous subcutaneous nodules and cysts over the back. Histopathological findings revealed the presence of larvae in the subcutaneous and dermal cysts. There was suppurative pyogranulomatous reaction containing numerous eosinophils and larval segments.

Onchocerciasis

Onchocerciasis has been reported throughout the world. In India (Srivastava, 1939) and Ruanda in Africa (Herin and Fain, 1955) recorded onchocerciasis.

Isshiki (1963) described the loss due to hide damage by *Onchoceria gibsoni*. The nodules consisted of fibrous tissue canalized by the long body of the worms. Nodules of 3 cm diameter were noticed on the subcutaneous tissue. Ottley and Moorehouse (1978) stated that adult worms were the nidus for necrosis, abscess formation, mineralization and granulomatous inflammation. Kivako (1979) stated that the base of teats and skin of udder anterior to the teats were the sites of prediliction for onchocerca infection in cows. Biopsy from the base of the teat could be used as an indicator for the severity of the infestation. Otteley (1980) reported onchocerciasis in *Bos indicus* cattle in Australia.

Stephanofilariasis

Patnaik (1968) described lesions of hump sore in cattle. Humpsore lesions occurred most commonly on the humps of cattle, eye, neck, poll, base of horns, ears, muzzle, back, base of tail, legs, and abdominal wall. Odaye (1971) observed circumscribed raised, dry, alopecic, hyperkeratotic lesions. Histological changes were hyperkeratosis, parakeratosis,

acanthosis and fibrosis. Mononuclear infiltration, perivascular cuffing of lymphocytes, monocytes and plasma cells were also noticed. Bakken (1980) isolated stephanofilaria from summer sores on cow's teat in Norway. Adult worms were seen in the cysts in the base of the hair follicle (Johnson, 1981).

Parafilariasis

Khajuria (1966) reported the incidence of parafilariasis in bovines in Jammu Province. Bech-Nielsen *et al.* (1982) stated that bovine parafilariasis caused severe economic loss through downgrading of meat quality and slaughter condemnation. Skin biopsy revealed nodular to diffuse dermatitis. Adult nematodes were seen at the centre of the lesion surrounded by necrotic debris and an inflammatory infiltrate containing numerous eosinophils (Ishtharai *et al.* 1982).

2.1.6 Non infectious dermatitis

2.1.6.1 Chemical toxicosis

Molybdenosis

Gardner (1968) reported molybdenosis in cattle grazing downwind from an oil refinery unit. It caused secondary copper deficiency in ruminants characterized by depigmentation

of hair. The molybdenum level was higher than 10 ppm in the forage.

Arsenic toxicosis

Clarke and Clarke (1981) described arsenic toxicosis in all large animals. They observed a dry, dull, rough, easily epululated hair coat progressing to alopecia and seborrheic skin disease.

Mercury toxicosis

A case of ammoniated mercury toxicity in cattle was reported by Irving and Butler (1975). Skin showed ulcers, hyperkeratosis and depilation of hair at the tail head.

Cutaneous iodism

In experimental toxicosis of calves the cutaneous lesions were limited to scaly patches without alopecia (Mangkoewidjojo, 1980).

2.1.6.2 Mycotoxicosis

Ergotism

Edward (1953) observed typical lameness of the hind limbs in cattle with ergotism. Swelling at the coronary band,

fetlocks and metatarsi were observed on the affected feet. Biopsy revealed degeneration and necrosis of the vascular endothelium, thrombosis and necrosis of the surrounding tissue (Burfening, 1973).

Fescue toxicosis

Williams *et al.* (1975) induced fescue foot syndrome in cattle by fractional extracts of toxic fescue hay. Erythema, swelling, necrosis and sloughing of the limbs distal to the fetlocks were observed. Skin biopsy revealed degeneration and thickening of the blood vessel walls, narrowing of vascular lumina, and necrosis of the surrounding tissue.

Stachybotryotoxicosis

Wyllie and Morehouse (1978) described cutaneous lesions in Stachybotryotoxicosis. They consisted of focal area of necrosis and ulceration of mucocutaneous areas. Petechiae and ulceronecrotic lesions were present on the visible mucous membranes.

Miscellaneous mycotoxicosis

Aflatoxin from *Aspergillus flavus* and Pithomycotoxicosis, and lupinosis caused hepatogenous photosensitization in cattle. T₂ toxins from *Fusarium tricinctum* caused Degnala

disease and hepatogenous photosensitization in cattle (Wyllie and Morehouse (1978)).

Ingestion of the mushroom, *Amanita verna* was reported to cause dermatitis characterized by vesicles, papular and necrotic foci (Wyllie and Morchouse, 1978). Rajan et al. (1977) observed tail necrosis in cattle and suggested mycotoxins as an aetiological factor. Wolter (1980) reported an outbreak of prurigenous dermatitis, a new syndrome in dairy cattle of France fed silage. The aetiology was attributed to a mycotoxin. Deng et al. (1984) attributed consumption of mouldy rice straw as the cause of Degnala disease. They isolated *F. equiseti*, *F. semitectum* and *F. anguioides* from mouldy rice straw. Xavier (1989) suggested a mycotoxic aetiology for Degnala disease based on the clinicopathological findings. But he could not isolate and identify *Fusarium* species of fungi and *Trichothecenes* from the paddy straw.

2.1.6.3 Dermatotoxic plants

Galitzer and Oehme (1978) reviewed the primary photosensitization in cattle which was mainly due to *Lantana camara*, *Panicum* spp., *Heliotropium europaeum*, *Brassica* spp. and *Tetradymia* spp. Cutaneous lesions were often restricted to the light skinned, sparsely haired areas but in severe cases it extended into the surrounding dark skinned areas.

The eye lids, lips, face, ears, perineum and the coronary band region were commonly involved.

2.1.6.4 Miscellaneous plant toxicosis

Leucaeniosis

Mullenax (1957) reported hair loss in Bahamian Livestock due to dietary intake of *Leucaena leucocephala*. He observed gradual loss of long hairs of the mane tail and fetlock region. Jones (1984) reported leucaeniosis in cattle of Australia.

Hairy vetch toxicosis

Kerr and Edwards (1982) reported hairy vetch toxicosis in cattle. Lesions were papules and plaques from which oozed a yellow pus like material which became encrusted.

Histologically there was diffuse dermatitis containing histiocytes, lymphocytes, plasmacells multinucleated giant cells and eosinophils. Green and Kleynhans (1989) reported a case of vetch poisoning in Friesland cow in Republic of South Africa showing pruritis and raised nodules evenly over the whole body.

2.1.6.5 Nutritional disease

Vitamin A

Booth *et al.* (1987) reported a case of hypovitaminosis A in feedlot cattle which was associated with chlorinated naphthalene poisoning in cattle. A rough dry often faded hair coat and seborrheic skin disease were observed.

Vitamin C

Scott (1988) described Vitamin C responsive dermatosis in calves. There was scaling, alopecia, easy epilation of hairs and erythematous and purpuric extremities. Dermatohistopathological findings were orthokeratosis, parakeratosis, follicular keratosis, curlicue hairs, vascular dilatation and congestion and perifollicular purpura.

Copper

The biochemical and pathological changes in the tissue of Friesian cattle during experimental induction of copper deficiency were studied by Mills (1976). He observed a rough brittle faded hair coat and varying degree of itching and hair licking. There was exfoliative pododermatitis and heel cracks.

Selenium

Selenium deficiency was reported in a dairy herd with foot and leg problems, and dermatitis around the base of the tail (Jones, 1984).

2.2 Tumours of the skin

Papillomatosis

Barthold et al. (1978) reported so called atypical warts in cattle of all ages caused by BPV3 and were non pedunculated with frond like projection on their surface.

Lancaster et al. (1979) stated that typical fibropapillomas on the teats and penis were caused by bovine papovavirus Type I (BPV1). BPV2 produced typical fibropapillomas on the head, neck, dewlap and occasionally the legs and teats of animals less than two years of age.

Meischke (1979) observed that of the 721 cattle brought for slaughter in Glasgow abattoir 260 (35%) were affected with teat papillomatosis. Macroscopically they were classified into frond type, flat and round type and rice grain type. Ultrastructurally BPV was demonstrated. Rebhun et al. (1980) reported a case of interdigital papillomatosis in dairy cattle with typical fibropapillomas on the dorsal and ventral aspect

of the interdigital space of the hind legs. An abattoir survey revealed papillomatosis in 0.8 per cent of the cattle in Germany (Grunder, 1984). El-Mahdi (1989) gave histomorphological description of papilloma in calves in the UAE. Small acidophilic inclusion bodies were present in the nucleus of the stratum spinosum cells. Yeruham et al. (1993) reported papillomas in cattle following tattooing by liquid nitrogen. They stated that the decrease in the number of Langerhan's cells at these sites and secondary infection with papilloma virus resulted in papillomas.

Squamous cell carcinoma

Ulgire (1947) reported a case of squamous cell carcinoma of the vulva of cattle. Kulkarni (1953) recorded 31 cases of horn cancer. They were mainly found in Kankrej cattle, Gir and Nondescript cattle of Gujarat. Analysis of over two thousand neoplasms from bovines in Madras Veterinary College during the period 1940-1951 by Nair and Sastry (1954) revealed 836 cases of Squamous cell carcinoma of eye, 464 cases of Squamous cell carcinoma of horns and 96 cases of Squamous cell carcinoma in other locations which include 12 cases of vulval squamous cell carcinoma. Murray (1968) stated that squamous cell carcinoma usually occurred at the mucocutaneous junction especially periocularly and on the vulva. Naik (1969) reported a case of horn cancer in Zebu cattle which was a

squamous cell carcinoma that arose from the frontal sinus mucosa and invaded the horn core. Vijayasarithi et al. (1976) reported a case of squamous cell carcinoma on the vulva of a cow which measured 5 x 3 x 3 cm. An abattoir survey of 488007 cattle by Naik and Randelia (1978) revealed 459 cases of horn cancer. Squamous cell carcinomas were seen at the mucocutaneous junction especially in adult and aged animals Moulten (1978).

Damodaran et al. (1979) reported two cases of Horn cancer, one in a Murrah buffalo bull and another in Sindhi bull. Histopathology revealed infiltrating columns of prickly cells, and 'cell nests'.

Gupta (1980) reported a case of horn cancer in a bull. Chauham (1981) reported a prevalence rate of 5.40 to 27.08 in different breeds and overall prevalence rate was 9.9/1000 cattle examined. He also stated that Horn cancer affected bullocks between 5 and 8 years of age. Analysis of over 606 neoplasms from bovines in South Africa during the period 1935-1974 by Bastianello (1982) revealed a higher incidence of ocular and vulval squamous cell carcinoma. Yeruham et al. (1993) stated that squamous cell carcinoma can occur at the site of tattooing using liquid nitrogen due to the decreased number of Langerhan's cells in these site and secondary

infection with papilloma virus leading to the appearance of tumours.

Fibrosarcoma

Dozsa and Weiss (1971) reported a case of multiple subcutaneous fibrosarcoma with internal metastasis in a 2 month old calf. A case of subcutaneous fibrosarcoma was reported by Scott (1988). Biopsy revealed interwoven bundles of immature fibroblasts and collagen fibers. Mitotic figures were also seen.

Myxoma

Ramkumar (1978) reported a case of myxoma of the anterior nares in a bullock. Misra (1981) reported a case of interdigital myxoma in a Haryana cow.

Histopathologically these tumours were characterized by stellate to fusiform tumour cells distributed in a vacuolated basophilic mucinous stroma.

Neurofibroma (Schwannoma)

Simon and Brewer (1963) reported multiple neurofibromas in a cow and a calf. Lesions were multiple, firm, round, subcutaneous and 8 cm in diameter on the head and trunk. Doughty (1972) reported virus like particles in the tumour

cells. Histologically spindle shaped cells exhibiting nuclear palisading and faintly eosinophilic thin wavy fibres alternating with areas of oedematous stroma containing relatively few haphazardly arranged cells were seen (Moulton, 1978). Sartin et al. (1994) reported cutaneous neurofibromatosis in a small group of cows in a Holstein dairy herd. All cutaneous lesions were consistent with neurofibromas in non-cutaneous sites in cattle.

Melanoma

Sivadas et al. (1971) reported a case of congenital melanoma in a Red Sindhi calf. Valsala and Bhaskaran (1973), Vijayasarathi et al. (1976), Wiseman et al. (1977) and Maradwar et al. (1978) reported melanomas in cattle. Lesions were multilobulated, extensive black growth encircling the metacarpal region and cauliflower like black growth on the chin. Biopsy revealed densely packed pigmented irregular round and spindle shaped cells with scanty cytoplasm extending deep into the dermis. Moulton (1978) observed subcutaneous melanomas to be more frequent in dark haired cattle especially in *Aberdeen angus*. Ganesh et al. (1990) reported a case of melanoma in a crossbred cow and a case of malignant melanoma, in a buffalo.

Lymphosarcoma

In India lymphosarcoma in indigenous cattle was reported by Vaidyanath (1952), Prasad and Nair (1972) and in crossbred cattle by Koshy Varhese (1980).

Miller (1980) described cutaneous lymphosarcoma in cattle. The lesions were multiple and dermoepidermal to subcutaneous. Histologically infiltration of malignant lymphocytes in the dermis and subcutis was noticed. Zwahlen *et al.* (1989) reported a case of cutaneous lymphosarcoma of helper T cell origin in a calf. It was a lymphoproliferative disease resembling human mycosis fungoides. Tumour cells were 10-15 μm in diameter and had round to oval nucleus without indentation.

Haemangioma

Krickbridge (1973) reported a case of hemangioma in a bovine foetus with chorioangioma of the placenta. Baker *et al.* (1982) reported a case of cavernous haemangioma in a calf. Haemangiomas were pink, soft, sessile masses 0.5 to 2.5 cm in diameter. Biopsy revealed proliferation of blood filled vascular spaces lined by single layer of well differentiated endothelial cells.

Mast cell tumour

Groth et al. (1960) reported a case of mastocytoma in a cow. Bliss and Iverson (1981) reported 2 cases of mastocytoma in dairy cattle. Lesions were multiple, 1 to 40 cm in diameter firm to fluctuant and dermal to subcutaneous. Histologically mast cell tumours were characterized by a diffuse to multinodular proliferation of mast cells which were well differentiated. Tissue eosinophilia and focal areas of collagen degeneration were present (Madewell et al. 1984).

2.3 Dermatological diagnosis by histopathologic patterns

Scott (1988) described a dermatological diagnostic scheme based on histopathological pattern modifying the criteria described by Ackerman (1978) as detailed below.

2.3.1 Perivascular dermatitis

Perivascular dermatitis the predominant inflammatory reaction centered around either or both the superficial and the deep dermal blood vessels. Perivascular dermatitis was subdivided on the basis of epidermal changes into four types.

1. Pure perivascular dermatitis

Ectoparasitism and contact dermatitis were associated with this type of lesion. Focal areas of epidermal edema eosinophilic exocytosis and necrosis were suggestive of ectoparasitism. Other perivascular dermatitis that contained numerous eosinophils included dermatophilosis and dermatophytosis.

2. Interface dermatitis

In interface dermatitis the dermoepidermal junction showed hydropic degeneration, lichenoid cellular infiltrate or both. The hydropic type of interface dermatitis was seen with drug eruptions, Rinderpest, bovine viral diarrhoea and graft versus host reactions.

3. Spongiotic perivascular dermatitis

It was characterized by varying degree of spongiosis and spongiotic vesicle formation. Severe spongiotic vesiculation sometimes blew out the basement membrane zone, resulting in sub-epidermal vesicles. The epidermis frequently showed varying degree of hyperplasia and hyperkeratosis. Spongiotic dermatitis may be monomorphous or polymorphous.

4. Hyperplastic perivascular dermatitis

It was characterized by varying degree of epidermal hyperplasia and hyperkeratosis with little or no spongiosis. This was a common non diagnostic chronic dermatitis reaction and was commonly seen with hypersensitivity reaction, ectoparasitism, contact dermatosis, seborrheic dermatosis and post inflammatory dermatosis.

2.3.2 Vasculitis

Vasculitis was an inflammatory process in which inflammatory cells were present within and around blood vessel walls and these were concomitant signs of damage to the blood vessels. Vasculitis was classified on the basis of dominant inflammatory cells within, vessel walls. They were neutrophilic, eosinophilic and lymphocytic type. Neutrophilic vasculitis was either leukocytoelastic or non leukocytoelastic and was seen in connective tissue disorders. Septicemia thrombophlebitis and lymphocytic vasculitis were seen in malignant catarhal fever, drug eruptions and ectoparasitism.

2.3.3 Nodular and diffuse dermatitis and granulomatous inflammation

Nodular dermatitis revealed clusters of cells. Such dermal nodules were usually multiple, occasionally large and

solitary. Diffuse dermatitis denoted a cellular infiltrate so dense that discrete cellular aggregates were no longer easily recognized.

Granulomatous inflammation represented a heterogenous pattern of tissue reaction in response to various stimuli. Granulomatous inflammation was characterized by circumscribed tissue reaction, subacute to chronic located around one or more foci.

2.3.4 Intraepidermal vesicular and pustular dermatitis

Intraepidermal vesicles and pustules were produced by intercellular or intracellular oedema which was observed in acute to sub acute dermatitis and ballooning degeneration in viral infection. Acantholysis was due to the proteolytic enzymes from neutrophils in microbial infections and hydropic degeneration of basal cells in drug eruptions.

Subepidermal vesicular and pustular dermatitis

Subepidermal vesicles and pustules were formed through hydropic degeneration of basal cells and dermoepidermal separation, severe subepidermal oedema or cellular infiltration especially in cases of urticaria, cellulitis, vasculitis and ectoparasitism.

2.3.5 Perifolliculitis, folliculitis and furunculosis

It was stated to be a common secondary complication in pruritic dermatosis. eg. hypersensitivities and ectoparasitism, seborrheic dermatosis and hormonal dermatosis. Follicular inflammation was observed to be caused by bacteria, fungi, parasites and is seen in eosinophilic folliculitis and unilateral papular dermatosis. Any chronic folliculitis particularly when there was furunculosis became pyogranulomatosis or granulomatosis.

2.4 Cutaneous response to mitogens in cattle

2.4.1 Response to phytohaemagglutinin (PHA)

Blease et al. (1973) administered PHA intradermally (I/D) in human patients and studied the response. Cutaneous reactions were characterized histologically by perivascular mononuclear cell infiltration. Jedrzejezak (1976) used the PHA skin test in predicting the prognosis in cancer patients.

Haggard et al. (1980) studied the cell-mediated immune response in experimentally produced iodine toxicosis in calves. They injected 100 ug of PHA I/D into six calves and studied the indurative response at 24, 48, 72, 96 and 120 hours. The mean diameter of the induration sites of all


iodine fed calves was significantly less than that of the control calves at 96 hours post inoculation.

Reddy and Rajan (1984) assessed the cell-mediated immunity in cattle bearing carcinoma of the mucosa of the ethmoid employing phytohaemagglutinin. Slight induration of the skin was observed at the site by 24 h in both healthy and tumour bearing animals. The induration was perceptible even after 48 h but by 72 h the skin at the site of injection showed normal thickness in most of the animals.

Histopathologically 24 h post inoculation revealed slight to moderate focal infiltration of lymphocytes and a few macrophages were seen in the epidermis and upper layers of the dermis.

Forty-eight hours post inoculation revealed macrophages and lymphocytes which were almost equal in proportion. The infiltrate extended into the deeper layers of the dermis. Perivascular cuffing of the lymphocytes was seen around the hair follicles. Seventy-two hours post inoculation revealed very few scattered macrophages and lymphocytes in all the layers of the dermis and epidermis.

The cutaneous responses to PHA in sheep with special reference to eosinophil leucocytes were studied by Rothwell *et al.* (1991). Mast cells in mitogen injected skin were less



densely granulated than cells in normal skin. It was concluded that local lymphokine release was responsible for the imigration and degranulation of eosinophils and basophils as well as the other inflammatory changes that followed mitogen injection.

2.4.2 Response of 2-4 Dinitrochlorobenzene (DNCB)

Brown *et al.* (1967) studied the efficacy of various skin tests including the DNCB skin test in fifty Hodgkin's disease patients and found DNCB to be one of the most reliable skin tests in evaluating the cell mediated immune status of the patients.

Eilber and Morton (1970) reported a correlation between the prognosis of cancer and DNCB sensitivity.

Chakravorthy *et al.* (1973) and Joshi *et al.* (1975) reported DNCB positive reaction among 82 to 100 per cent normal control subjects who were immunologically competent.

In animals for the evaluation of CMI response the application of DNCB was first tried in calves by Brummerstedt and Basse (1973). They tried different concentrations of DNCB and sensitized calves for seven consecutive days. On challenging after 48 h they found the skin to be thickened and

the swelling was movable in relation to the underlying subcutis.

Histologically perivascular cuffing of lymphocytes, macrophages and eosinophils were found in the dermis.

Jennings (1979) studied leucocyte adherence inhibition (LAI) in calves sensitized by DNCB.

Reddi *et al.* (1981) evolved a technique and standardized it for evaluating the cell-mediated immune response in cattle induced by 2-4 dinitrochlorobenzene.

2.4.3 Response to BCG

Rosenthal (1957) and Khalil *et al.* (1975) stated that the BCG when given intradermally or subcutaneously or intravenously caused lymphoproliferative reactions.

Direct activation of lymphoid cells by BCG was described by Baldwin and Pimm (1978).

Sreekumaran (1980) evaluated the CMI response in cattle bearing tumour of the ethmoid mucosa by using BCG which was administered intradermally.

Rajan *et al.* (1982) using BCG as a test antigen evolved a technique and standardized it for evaluating the CMI response in goats.

Materials and Methods

MATERIALS AND METHODS

3.1 Prevalence

To study the prevalence of skin disorders in cattle the data maintained at the Directorate of Animal Husbandry Department, Trivandrum for a period of five years from 1989-1993 were scanned.

3.1.1 Gross pathology

The detailed gross pathology of the skin lesions encountered in 97 animals at the Veterinary College Hospitals, Livestock Farms and Veterinary Dispensaries of the Animal Husbandry Department during the period September 1992 to August 1994 were studied.

3.1.2 Histopathology

Representative skin biopsies (1 cm x 0.5 cm size) as and when required were taken from the animals suffering from dermatological disorders by giving 0.5 per cent Lignocain infiltration around the lesion and excision biopsy was taken and preserved in 10 per cent neutral formalin and wound was sutured by horizontal mattress suture using cotton thread as suture material. The tissue collected were processed using Cedar wood oil (natural) as clearing agent for 15 days after

proper fixation. Then by routine paraffin embedding technique described in Armed Forces Institute of Pathology Manual (1968) paraffin sections were cut at four to five microns thickness and were stained with Harri's Haematoxylin and Eosin. In addition, wherever necessary sections were also stained with special stains such as VanGiesons, Periodic acid Schiff (PAS) and Trichrome (Armed Forces Institute of Pathology Manual 1968).

3.2 Experimental: Part I

An investigation was undertaken to evaluate the mast cell response in cutaneous hypersensitivity reaction to:

3.2.1 Phytohaemagglutinin-M

Six healthy male calves in the age group of 6-8 months were used for the study. Phytohaemagglutinin (PHA) was given I/D to six calves employing the method described by Reddy *et al.* (1984). The site was the middle of the neck region on the left side. Four sites were marked on each calf and the areas were shaved and disinfected. At each site 0.1 ml of saline containing 10 micrograms PHA-M (Sigma) was administered I/D at three sites. The fourth site was used as control and 0.1 ml saline was administered I/D as control. The thickness of the skin was measured with calipers before and 24, 48 and 72 hours post inoculation. Specimen biopsies of the skin at

the site of inoculation having a size of 1 cm x 0.5 cm was also taken at the same time intervals and fixed in 10 per cent formol alcohol. The biopsy tissues were processed with cedar wood oil as clearing agent for histopathological studies and paraffin sections cut at 4-5 μ thickness were stained with Harri's Haematoxylin and Eosin and mast cells were demonstrated by the method described by Padawer (1959).

3.2.2 2,4 Dinitrochlorobenzene

Six healthy male calves in the age group of 6-8 months were used in the study. Method described by Reddy *et al.* (1981) was followed. 2,4 Dinitrochlorobenzene (Difco) (DNCB) as a 2 per cent solution in acetone was used for application. DNCB was applied at the neck region 15 cm anterior to the shoulder blade. In this region 4 areas of 3 cm diameter were marked with the help of a metallic ring and these areas were clipped close to the skin with scissors on the right side. Metallic ring was placed over the prepared area and 2 per cent solution of DNCB in acetone was dropped slowly 2 to 3 drops at a time using a 1 ml tuberculin syringe with hypodermic needle, on three areas and on the fourth area 2 per cent solution of acetone was applied as control. The solution was allowed to dry immediately by blowing so as to prevent it from running down the neck region. The skin thickness was measured before and 24, 48 and 72 hours following application. Skin biopsies

of the size 1 cm x 0.5 cm were taken at these intervals and fixed in 10 per cent formol alcohol and processed as mentioned in the previous experiment.

3.2.3 BCG

Six healthy male calves were used for this experiment. Method described by Rajan et al. (1982) in goats was followed. The BCG (0.5 mg - Glutamate BCG vaccine Japan BCG Laboratory) was dissolved in 0.2 ml of distilled water and 0.2 ml of this solution containing 0.5 mg of BCG was given at 3 sites for each calf on the right side of the neck. On the fourth site 2 ml of distilled water was given I/D as control. Before giving injections the area was shaved and the skin thickness was measured using a vernier caliper. Subsequent measurements were taken at 24, 48 and 72 hours post inoculation. The biopsy specimens were taken at 24, 48 and 72 hours and fixed in 10 per cent formol alcohol and processed as mentioned in the previous experiment.

3.3 Experiment : Part II

Studies were conducted to delineate the gross and histopathological changes in the skin caused by two common pesticides, since they are likely to come into contact with the skin of cattle at the farmers place.

The pesticides used were Carbofuran compound and BHC. Carbofuran compound 1 per cent (Furadan Rallies India, Ltd.) and BHC 1 per cent were made up in acetone and applied at the neck, wither and back region of six healthy male calves. Before application the sites were shaved and cleaned with soap and water. Skin biopsies were taken on the 3rd, 5th and 7th day. Biopsies were fixed in 10% formol saline and processed as described earlier. Detailed histopathological examination was made and tissue response was studied.

Results

RESULTS

Prevalence

To study the prevalence of dermatological disorders in cattle of Kerala data were collected from the Disease Surveillance report published by the Directorate of Animal Husbandry during the period 1989 to 1993.

The various skin disorders encountered in animals according to this data were tail necrosis (1.44 per cent), cutaneous mycosis (10.58 per cent), eczematosis (6.09 per cent), pox (4.75 per cent), tick infestation (37.22 per cent), lice infestation (25.71 per cent), mangy dermatitis (13.82 per cent) and wart (0.36 per cent) Fig.1.

Over all prevalence of skin disorders during the period 1989 to 1993 was 2.5 per cent.

The year-wise prevalence of each skin condition is represented in Tables 1 to 8.

During the period 1989-93 the prevalence of tail necrosis was found to be 0.0166 per cent. The highest incidence was recorded in the year 1984 (0.023 per cent) (Table 2).

The overall prevalence of cutaneous mycosis was 0.125 per cent with the highest incidence of 0.174 per cent during the year 1990 (Table 3).

The overall prevalence of eczematosis was found to be 0.359 per cent with the highest incidence during the year 1989 (Table 4).

The prevalence of pox was found to be 0.558 per cent with a highest incidence of 0.079 per cent during 1990 (Table 5).

Overall prevalence of tick infestation was found to be 0.4418 per cent with a higher incidence of 0.547 per cent in 1989 (Table 6).

Highest incidence of lice infestation was recorded in 1990 (0.4 per cent) with an overall Prevalence of 0.305 per cent (Table 7).

Incidence of mangy dermatitis was found to be highest in 1989 (0.248 per cent) with an overall prevalence of 0.1636 per cent (Table 8).

The observations made during the course of this investigation are presented in the ensuing pages. Out of 97 animals examined 17 animals had dermatosis, 67 animals had dermatitis and 13 animals had skin tumours.

Detailed histopathological studies on 97 cattle revealed the following skin lesions. Hyperkeratosis (9.3 per cent), hypertrichosis (8.25 per cent), Fly bite dermatitis (14.46 per cent), Cutaneous ulceration (22.68 per cent), Decubitus ulcers

(12.47 per cent), Dermatophilosis (1.03 per cent), Teat lesions (6.19 per cent), Exudative dermatitis (5.20 per cent), Ectoparasitic injury (6.19 per cent), Papillomatosis (9.27 per cent), Squamous cell carcinoma (1.03 per cent), Fibroma (2.07 per cent) and Fibrosarcoma (1.03 per cent) (Table 8) Fig.2.

4.1 Dermatosi s

4.1.1 Hyperkeratosis

Out of 17 cases of dermatosis, 10 cases were classified under hyperkeratosis.

On the dorsal aspect of the lumbar region in two cows there was an irregular thick greyish white patch. The affected region was rough, scaly, dry and wrinkled. There was partial loss of hair and the few hairs which were remaining were coarse, brittle and erect (Fig.3). In three cases lesions were confined to the withers and dorsum of the neck. Pruritis was absent. In four cases lesions had diffusely spread on the lateral sides of the neck.

Histopathology

Biopsy revealed hyperkeratosis of the stratified squamous epithelium. There was acanthosis and thickening of the stratum corneum (Fig.4). Hyperkeratosis of the internal root sheath was observed (Fig.7). Some of the sections revealed

degenerated hair follicles in the form of vacuole, and circular cystic structures surrounded by flattened epidermal cells containing concentrically arranged lamellar keratin (Fig.5,6).

4.1.2 Hypertrichosis

Out of 17 cases of dermatosis 8 cases were classified under hyperkeratosis, seven animals were having generalized form of hypertrichosis which was found in crossbred cattle with chronic debility recovered from foot and mouth disease. The hair coat was shaggy and wavy. In one animal there was bilateral multiple black irregular round areas varying in size from 1-3 cm diameter on the lumbar region of a cow. These areas showed excessive hair growth (Fig.8).

Histopathology

Histologically there was hyperplasia of the outer root sheath of the hair follicle. There was more number of hair follicles in a given area. There was relatively high proportion of medullated hair follicles. Hair follicles contained keratin plugs and in some they were seen encircling the hair shaft (Fig.9). Some sections revealed hyperkeratosis of stratum corneum (Fig.10).

4.2 Dermatitis

4.2.1 Fly bite dermatitis

Out of 67 cases of dermatitis 15 animals were found to have fly bite dermatitis. In focal areas, groups of raised greyish white necrotic papules and wheals were seen on the neck, shoulder and ears. In some cases necrotic papules and wheals were seen around the eyes with haemorrhagic crusts (Fig.11,12).

Histopathology

In the upper dermal layer and in the dermo-epidermal junction there was perivascular dermatitis with diffuse infiltration of neutrophils, lymphocytes and eosinophils around the blood vessels (Fig.13,14). Focal areas revealed superficial haemorrhage (Fig.14), epidermal oedema and mild hyperkeratosis. The hair follicles were found intact except for mild lymphocytic infiltration in and around them.

4.2.2 Cutaneous ulceration

Out of 67 cases of dermatitis 22 animals had chronic dermatitis and cutaneous ulceration. This was observed on the neck region (Fig.15) and shoulder region (Fig.16). There was erosion of the epidermal layer and exposure of raw scar tissue

and loss of hair. Some cases revealed scaling, crust and lichenification.

Histopathology

Biopsy revealed perivascular infiltration of neutrophils and macrophages. Epidermal lysis (Fig.17) was seen and loss of architecture of the epidermal layer and part of the dermis. There was some degree of folliculitis. Atrophic hair follicles were seen with inflammatory cells around the follicles (Fig.18). Hyalinised hair shafts were seen free in the follicles. Some sections revealed sebaceous gland atrophy. The lymphatics were seen obliterated. Hydropic degeneration of the basal cells was seen below the necrosed layer (Fig.19).

4.2.3 Decubitus ulcers

Out of 67 cases of dermatitis examined 12 cases of bed sores were encountered.

Lesions were erythematous to reddish purple discolouration. There was slight exudation and necrosis. This was mainly seen near the stifle joint, on the thoracic region and shoulder (Fig.20). Lesions were moist, occupying a larger area with size ranging from 2 cm to 10 cm in diameter.

Histopathology

Thinning of the epidermis and exudation were noticed above the epidermis. Atrophic changes were seen in the hair follicular epithelium (Fig.21,22). Some sections revealed diffuse infiltration of neutrophils and lymphocytes. Sebaceous gland atrophy was observed in some sections (Fig.23).

4.2.4 Dermatophilosis

Out of 67 cases of dermatitis one case of dermatophilosis was seen. The lesions were seen on the rump and top line mainly. It consisted of focal circumscribed areas of hyperkeratosis. On removing the circumscribed lesions a moist exudating raw surface was seen. Lesions were 0.5-1 cm in diameter. There was alopecia and multiple crust in some areas (Fig.24). The under surface of the crust was concave with the roots of the hair protruding. Direct smears of the exudate and impression smears of the crusts revealed cuboidal packets of coccoid cells arranged in parallel rows with typical "rail road tracks" appearance of *Dermatophilus*.

Histopathology

Epidermis revealed hyperkeratosis and acanthosis. Some of the epidermal cells in the prickle cell layer showed hydropic

degeneration. There was diffuse dermatitis with extensive infiltration of inflammatory cells, odema and fibrin (Fig.25).

In some areas parakeratosis was observed. Some cocoid cells could be seen in the keratin debris on the surface of the skin (Fig.26).

4.2.5 Teat lesions

Six cases of teat lesions were seen in cattle mostly of inflammatory type out of 67 cases of dermatitis examined. As a result of mechanical injury painful inflammatory swelling and severe enlargement of the teat were seen. The size of the swelling varied from a goose berry to a lemon. There was slight exudation on the surface of the lesion.

Histopathology

There was moderate to severe epidermal necrosis. The subcutaneous tissue revealed necrosis, fibrous tissue proliferation and inflammatory cells. There was diffuse granulomatous reaction. The exudation was seen just above the necrosed epidermal layer (Fig.27).

4.2.6 Exudative dermatitis

Out of 67 cases of dermatitis 5 animals had exudative dermatitis mostly affecting the thoracic region with matting of hair.

A case of superficial inflammatory reaction characterized by erythema and oozing was observed on the medial thigh region. There was also foul odour. This was seen on both sides of the thigh rubbing the udder.

Histopathology

There was hydropic degeneration of the epidermal cells with some exudative reaction on the epidermis characterized by perivascular inflammatory cells. Mild degree of dermal oedema was also seen (Fig.28).

4.2.7 Ectoparasitic injury

Out of 67 animals examined 6 animals were found to have heavy *Boophilus* tick infestation especially on the neck and back region. Wheals and slight erosions were found at the neck region at the site of the tick bite.

Histopathology

There was focal epidermal necrosis, oedema and slight infiltration of inflammatory cells consisting of lymphocytes, eosinophils and neutrophils. The epidermal cells revealed hydropic change (Fig.29).

4.3 Skin tumours

Thirteen cases of skin tumors were encountered in this study.

4.3.1 Papillomatosis

Out of 9 cases of papillomatosis, two cases of papilloma were seen as solitary warts on the neck and forehead. They were round to oval in shape, firm in consistency and had a narrow base. Six cases of teat and udder papillomas (Fig.30) of the flat and round type varying in size from 1 to 1.50 cm in diameter were seen diffusily scattered on the teat and udder. They were grey in colour and firm in consistency. In an animal a generalized form of papillomatosis in which lesions were low, flat, circular and non pedunculated with frond like projections on the surface were seen on the back, neck and hind limbs.

Histopathology

There was epithelial and fibrous tissue proliferation. The fibrous tissue formed the core. Some of the sections the epithelial cells revealed ballooning degeneration and clumping of keratohyalin granules. There was also marked orthokeratotic hyperkeratosis (Fig.31). Epidermal configuration was irregular and undulating (Fig.31). The lower layer of the epidermis

revealed spongiosis. Dyskeratosis was also seen characterised by eosinophilic swollen cytoplasm and dark staining nucleus. In some of the sections engorged capillaries were seen (Fig.33).

4.3.2 Squamous cell carcinoma

A growth was seen in the vulval region at the mucocutaneous junction. It was soft and greyish pink and measured 10x6 cm. The surface was irregular and ulcerated. There was focal areas of haemorrhage and purulent foci.

Histopathology

There was marked epidermal hyperplasia. Irregular proliferating masses of epidermal cells were seen as islands in the dermis with prickle cell layer externally and other layers internally forming "cell nests" with keratohyalin in the centre. Elongated retepegs were seen invading the dermis. Slight inflammatory changes were also noticed in the stroma (Fig.34).

4.3.3 Fibroma

Two cases of fibroma were studied. One was seen as a firm growth of 1 cm diameter on the base of the right fore teat in a cow. The other was seen on the medial aspect of the

right thigh region measuring about 6x10 cm. The growth was firm and the surface was irregular and ulcerated.

Histopathology

Biopsy revealed interlacing wavy bundles of proliferating fibroblasts (Fig.35). Nucleus of the fibroblasts was elongated spindle shaped. There was infiltration of lymphocytes in the perivascular location and hyperplasia of the epidermis with irregular configuration extending into the dermis. Bundles of collagen were seen separating the bundles of proliferating cells (Fig.36).

4.3.4 Fibrosarcoma

A case of fibrosarcoma was recored. It was a solitary firm growth 2 cm diameter on the body of the teat surface. The cut surface was greyish white in colour.

Histopathology

Interwoven bundles of immature fibroblasts were seen irregularly scattered and in groups. The cells were fusiform in shape with prominent nucleus. There were many cells in varying stages of mitosis. Scant amount of collagen bundles was seen separating the groups of fibroblasts (Fig.37).

4.4 Mast cell response in cutaneous hypersensitivity reaction to phytohaemagglutinin-M

4.4.1 Skin measurement

Table 10 shows the measurement of the skin after 24 h of inoculation of PHA-M. Slight induration of the skin was observed and the average thickness of the skin was $5.54 \text{ mm} \pm 0.47$. The induration was perceptible even after 48 h and the average thickness was $4.37 \text{ mm} \pm 0.32$. By 72 h there was no visible induration and the average thickness was reduced to $3.49 \text{ mm} \pm 0.31$. The 0 h average thickness was 3.27 ± 0.36 .

4.4.2 Histopathology

At 24 h

Slight to moderate infiltration of lymphocytes and few macrophages were seen in the epidermis and upper layer of the dermis. A few eosinophils were also observed. The upper layer of the dermis revealed varying degree of oedema. The lymphatics were dilated. Macrophages and few neutrophils were seen around the hair follicles. Few degranulated mast cells were seen near the blood vessels at the upper layer of the dermis.

At 48 h

Few lymphocytes and relatively more number of macrophages were found infiltrating the upper and deeper layers of the dermis. Perivascular cuffing of lymphocytes were seen. Cuffing of lymphocytes were also seen adjacent to the hair follicles (Fig.38). Mast cells which were degranulated and normal mast cells without degranulation could be seen near the blood vessels on the upper layer of the dermis (Fig.38).

At 72 h

Lymphocytes and macrophages were seen in all the layers of the epidermis and dermis. The cellular and vascular changes were much less compared to 24 and 48 h. Some of the mast cells which were non degranulated were seen near the blood vessels at the dermo-epidermal junction.

4.5 Mast cell response in cutaneous hypersensitivity reaction to 2-4 Dinitrochlorobenzine

4.5.1 Skin measurement

By 24 h there was slight induration and borders were clear at the site of application and the average increase in thickness was $5.35 \text{ mm} \pm 0.42$. At 48 h after application of DNCB there was minimum visible reaction which could be correctly gauged and thickness was $4.44 \text{ mm} \pm 0.27$. By 72 h

there was not much visible reaction and average thickness was $4.04 \text{ mm} \pm 0.31$ (Table 11). The normal average thickness being 3.35 ± 0.32 .

4.5.2 Histopathology

At 24 h

Lymphocytes and moderate number of macrophages were seen scattered in the upper layer of the dermis. Infiltrating cells appeared mostly in the perivascular location. Some degranulated mast cells were seen at the dermoepidermal junction.

At 48 h

Capillary congestion and odema were observed. Cellular infiltrate was more diffuse and it consisted of macrophages and lymphocytes (Fig.39).

Some degranulated mast cells were seen at the dermo epidermal junction and normal mast cells without degranulation in the dermis.

At 72 h

Lymphocytes and macrophages were seen in the dermis. However, they were less compared to 48 h. The cellular and

vascular changes were also less. Very few normal mast cells were seen.

4.6 Mast cell response in cutaneous hypersensitivity reaction to BCG

4.6.1 Skin measurement

By 24 h slight induration and warmth were noticed at the site of inoculation with an average thickness of $5.13 \text{ mm} \pm 0.41$. Forty eight hours observation revealed relatively less induration and warmth at the site with an average thickness of $4.76 \text{ mm} \pm 0.53$. By 72 h there was no appreciable reaction and average thickness was $4.17 \text{ mm} \pm 0.43$. the normal 0 h thickness was $3.65 \text{ mm} \pm 0.52$ (Table 12).

4.6.2 Histopathology

At 24 h

Milddoedema and moderate infiltration of mononuclear cells consisting of lymphocytes and few macrophages were seen. Perivascular cuffing of lymphocytes was evident. Dilated lymphatics and congested capillaries were quite prominent. Few degranulated mast cells were seen at the dermo-epidermal junction.

At 48 h

Cellular infiltrate consisted mainly of lymphocytes. Cellular changes and oedema were intense. Congestion of capillaries and lymphatic dilatation were prominent. Few neutrophils were found amidst the lymphocytic-macrophage infiltrate. In some sections infiltration was seen extending into the deeper part of dermis and revealed diffuse infiltration of mononuclear cells. Mast cells were not seen (Fig.40).

At 72 h

Cellular infiltration and capillary congestion were less compared to 48 h. Focal collection of cells around the capillaries was noticed. Macrophages and lymphocytes were almost equally found infiltrating the upper layer of the dermis. Mast cells were not seen.

4.7 Gross and histopathological changes in the skin to pesticides

4.7.1 Benzene hexachloride

On application for 7 days there was no external visible gross lesions.

Histopathology

The third day biopsy revealed slight hyperkeratosis and dilatation of lymphatics. The 5th day biopsy, revealed slight hyperkeratosis and dermolysis (Fig.41). Seventh day biopsy revealed no significant changes.

4.7.2 Furadan

On application for 7 days there was no visible gross lesions.

Histopathology

The third day biopsy revealed not much changes except dilatation of lymphatics. On the 5th day biopsy, some sections revealed mild degree of hyperkeratosis and acanthosis (Fig.42). The 7th day biopsy revealed no changes.

Table 1. Cattle population in Kerala*

District	Cattle population
Thiruvananthapuram	264250
Kollam	309388
Pathanamthitta	219985
Alappuzha	199824
Idukki	192311
Kottayam	276044
Ernakulam	323854
Thrissur	263691
Palakkad	303935
Malappuram	229765
Kozhikode	262497
Wayanad	122303
Kannur	272011
Kasargod	184127
State	3423985

* 1987 Livestock Census

Table 2. Prevalence of Tail Necrosis in cattle in Kerala state during the period 1989 to 1993

	1989	1990	1991	1992	1993
January	76	51	33	95	31
February	84	62	41	84	30
March	96	49	50	68	52
April	42	47	52	84	41
May	89	42	44	52	10
June	92	48	42	46	20
July	120	46	129	33	21
August	46	60	47	18	41
September	50	55	48	21	10
October	42	48	52	21	33
November	32	49	41	19	24
December	42	46	59	9	20
Total	811	603	638	550	333
Prevalence %	0.023	0.017	0.018	0.016	0.009

Table 3. Prevalence of Cutaneous mycosis in cattle in Kerala state during the period 1989 to 1993

	1989	1990	1991	1992	1993
January	410	506	378	514	231
February	398	563	353	319	210
March	510	557	254	416	421
April	476	416	331	280	290
May	420	410	390	216	260
June	510	567	396	229	239
July	507	388	353	298	216
August	467	484	525	96	92
September	548	562	341	212	221
October	536	524	362	84	68
November	548	514	351	131	121
December	487	496	370	31	128
Total	5817	5987	4405	2826	2497
Prevalence %	0.169	0.174	0.128	0.082	0.072

Table 4. Prevalence of Eczema in cattle in Kerala state during the period 1989 to 1993

	1989	1990	1991	1992	1993
January	216	218	144	123	137
February	279	192	196	109	217
March	364	199	118	122	164
April	341	237	109	63	216
May	350	240	102	119	310
June	274	284	166	123	291
July	280	180	265	124	310
August	215	319	137	110	215
September	233	231	161	114	176
October	273	246	149	82	210
November	416	210	420	146	288
December	235	169	210	20	212
Total	3434	2725	2177	1255	2794
Prevalence %	0.100	0.079	0.063	0.036	0.081

Table 5. Prevalence of pox in cattle in Kerala state during the period 1989 to 1993

	1989	1990	1991	1992	1993
January	140	187	197	227	54
February	126	203	111	46	90
March	140	209	128	69	69
April	124	204	74	212	102
May	144	170	18	112	116
June	140	399	170	145	399
July	143	408	167	154	170
August	169	164	256	113	182
September	198	160	210	124	208
October	192	182	19	24	282
November	198	208	196	42	213
December	169	214	98	90	180
Total	1883	2708	1640	1358	2065
Prevalence %	0.054	0.079	0.047	0.039	0.060

Table 6. Prevalence of tick infestation in cattle in Kerala state during the period 1989 to 1993

	1989	1990	1991	1992	1993
January	1792	1646	1235	1407	1381
February	1526	1608	991	1308	1380
March	1909	1458	1103	1687	1211
April	1809	1454	1103	1157	1240
May	1885	1289	1050	812	1298
June	1406	1339	1075	716	1429
July	1330	1280	986	637	1426
August	1356	1450	1151	694	1629
September	1482	663	1291	541	1450
October	1494	1428	1128	381	1308
November	1436	1296	1201	418	1202
December	1624	1308	1029	138	1454
Total	18749	17212	13428	9896	16408
Prevalence %	0.547	0.502	0.392	0.289	0.479

Table 7. Prevalence of lice infestation in cattle in Kerala state during the period 1989 to 1993

	1989	1990	1991	1992	1993
January	1421	1118	956	1250	188
February	1441	1291	815	1186	175
March	1291	1321	780	1152	103
April	954	989	771	811	207
May	956	933	725	416	310
June	998	1100	806	559	316
July	1161	1214	820	513	1100
August	1001	1283	981	316	936
September	987	1208	729	472	1216
October	1028	1104	714	354	1204
November	1121	1162	824	319	1108
December	947	1208	851	85	986
Total	13105	13931	9972	7433	7849
Prevalence %	0.382	0.406	0.291	0.217	0.229

Table 8. Prevalence of Mangy dermatitis in cattle in Kerala state during the period 1989 to 1993

	1989	1990	1991	1992	1993
January	742	730	339	568	92
February	641	548	460	329	181
March	898	578	418	439	83
April	648	446	471	288	210
May	658	515	395	219	506
June	624	511	249	325	408
July	849	617	435	309	310
August	669	676	414	212	584
September	655	684	421	192	681
October	681	624	419	143	426
November	777	618	385	413	408
December	679	422	364	70	446
Total	8519	6969	4770	3507	4335
Prevalence %	0.248	0.203	0.139	0.102	0.126

Table 9. Different types of skin lesions encountered in cattle during the period of study (September 1992 to August 1994)

Sl. No.	Type of lesion	Total number of animals affected	Per cent
I.	Dermatosis	17	
	a. Hyperkeratosis	9	9.30
	b. Hypertrichosis	8	8.25
II.	Dermatitis	67	
	a. Fly bite dermatitis	15	15.46
	b. Cutaneous ulceration	22	22.68
	c. Decubitus ulcers	12	12.47
	d. Dermatophilosis	1	1.03
	e. Teat lesions	6	6.19
	f. Exudative dermatitis	5	5.20
	g. Ectoparasitic injury	6	6.19
III.	Skin tumors	13	
	a. Papillomatosis	9	9.27
	b. Squamous cell carcinoma	1	1.03
	c. Fibroma	2	2.07
	d. Fibrosarcoma	1	1.03

Table 10. Measurement of the thickness of the skin in calves before and after administration of PHA-M

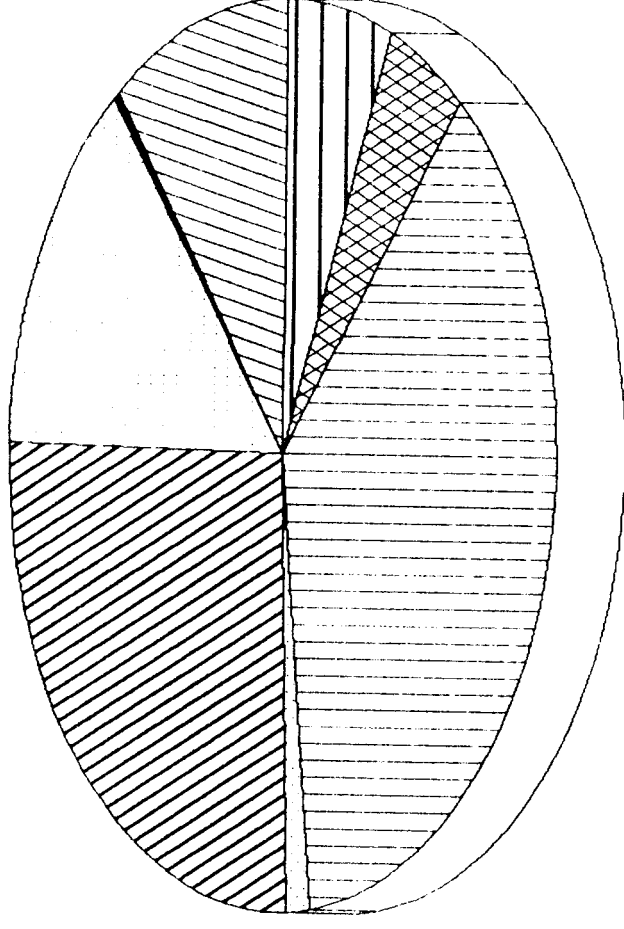
Sl. No.	0 h thickness (mm)			24 h thickness (mm)			48 h thickness (mm)			72 h thickness (mm)				
	1st site	2nd site	3rd site	Ave	1st site	2nd site	3rd site	Ave	1st site	2nd site	3rd site	Ave		
1.	3.5	3.7	2.8	3.33	8.6	7.5	6.5	7.53	4.8	4.0	4.4	4.4	3.2	3.2
2.	4.7	4.5	3.0	4.1	6.0	5.9	4.7	5.53	6.0	4.0	5.0	5.0	4.0	4.0
3.	2.0	1.9	2.0	1.9	6.5	5.8	5.0	5.76	3.0	2.8	2.9	2.9	2.6	2.2
4.	2.8	2.9	2.9	2.86	4.9	3.9	3.0	3.93	4.8	5.0	4.9	4.9	3.2	3.2
5.	3.5	3.0	2.7	3.06	6.0	5.8	3.9	5.23	5.5	5.7	4.0	5.06	3.5	3.5
6.	4.2	4.5	4.5	4.4	5.2	5.4	5.3	5.3	5.0	4.9	4.95	4.95	4.5	4.7
Mean				3.27 [±]				5.54 [±]				4.37 [±]		3.49 [±]
+ SE				0.36 ⁻				0.47 ⁻				0.32 ⁻		0.31 ⁻

Table 11. Measurement of thickness of the skin in calves before and after application of DNCB in mm

Sl. No.	0 h thickness (mm)			24 h thickness (mm)			48 h thickness (mm)			72 h thickness (mm)					
	1st site	2nd site	3rd site	1st site	2nd site	3rd site	1st site	2nd site	3rd site	1st site	2nd site	3rd site			
1.	3.9	3.7	2.8	3.46	4.8	4.0	3.9	4.23	4.0	3.9	3.95	3.8	3.7	3.75	
2.	4.6	3.0	3.7	3.76	5.5	5.5	6.4	5.80	4.6	4.8	4.70	4.0	4.7	4.35	
3.	2.8	2.0	1.9	1.23	4.8	4.5	3.8	4.36	3.9	3.2	3.55		3.0	3.00	
4.	4.5	3.0	3.5	3.66	6.8	6.7	4.8	6.1	5.0	4.5	5.0	4.83	5.0	4.5	4.75
5.	3.5	2.4	2.0	2.63	4.7	5.2	4.7	4.86	4.9	4.0	3.8	4.20	4.0	2.9	3.45
6.	5.6	3.8	3.8	4.40	7.5	7.9	5.0	6.80	6.5	5.2	4.7	5.46	5.9	5.0	4.96
Mean				3.35±				5.35±				4.44±			4.04±
+ SE				0.32				0.42				0.27			0.31

Table 12. Measurement of thickness of skin in calves before and after administration of BCG in mm

Sl. No.	0 h thickness (mm)			24 h thickness (mm)			48 h thickness (mm)			72 h thickness (mm)						
	1st site	2nd site	3rd site	1st site	2nd site	3rd site	Ave	1st site	2nd site	3rd site	Ave	1st site	2nd site	3rd site	Ave	
1.	3.5	3.7	2.8	3.33	5.9	5.0	4.8	5.23	4.5	4.5	4.5	4.5	4.5	4.0	4.0	4.0
2.	5.8	5.8	6.0	5.86	6.8	6.8	5.0	5.20	7.5	6.5	7.0			6.0	6.0	6.0
3.	2.1	1.9	2.0	2.00	4.0	3.0	3.0	3.33	3.0	3.0	3.0	3.0		2.8	2.8	2.8
4.	3.0	3.2	3.2	3.13	6.0	5.0	5.0	5.33	5.0	4.0	4.0	4.3	4	4	3.9	3.96
5.	3.7	3.3	3.4	3.46	4.9	4.7	4.7	4.76	4.9	4.2	4.7	4.6	3.9	3.8	3.6	3.76
6.	4.1	4.2	4.2	4.16	5.9	5.8	6.2	5.96	5.1	4.6	5.9	5.2	4.3	4.4	4.9	4.53
Mean				3.65±				5.14±				4.76±				4.18±
+ SE				0.52				0.41				0.53				0.43



- ▨ Cutaneous mycosis
- Warts
- ▨ Mangy dermatitis
- ▨ Lice infestation
- ▨ Tail necrosis
- ▨ Tick infestation
- ▨ Pox
- ▨ Ecematosis

Fig.1 Prevalence of dermatological disorders in cattle of Kerala (Disease surveillance report 1989-1993).

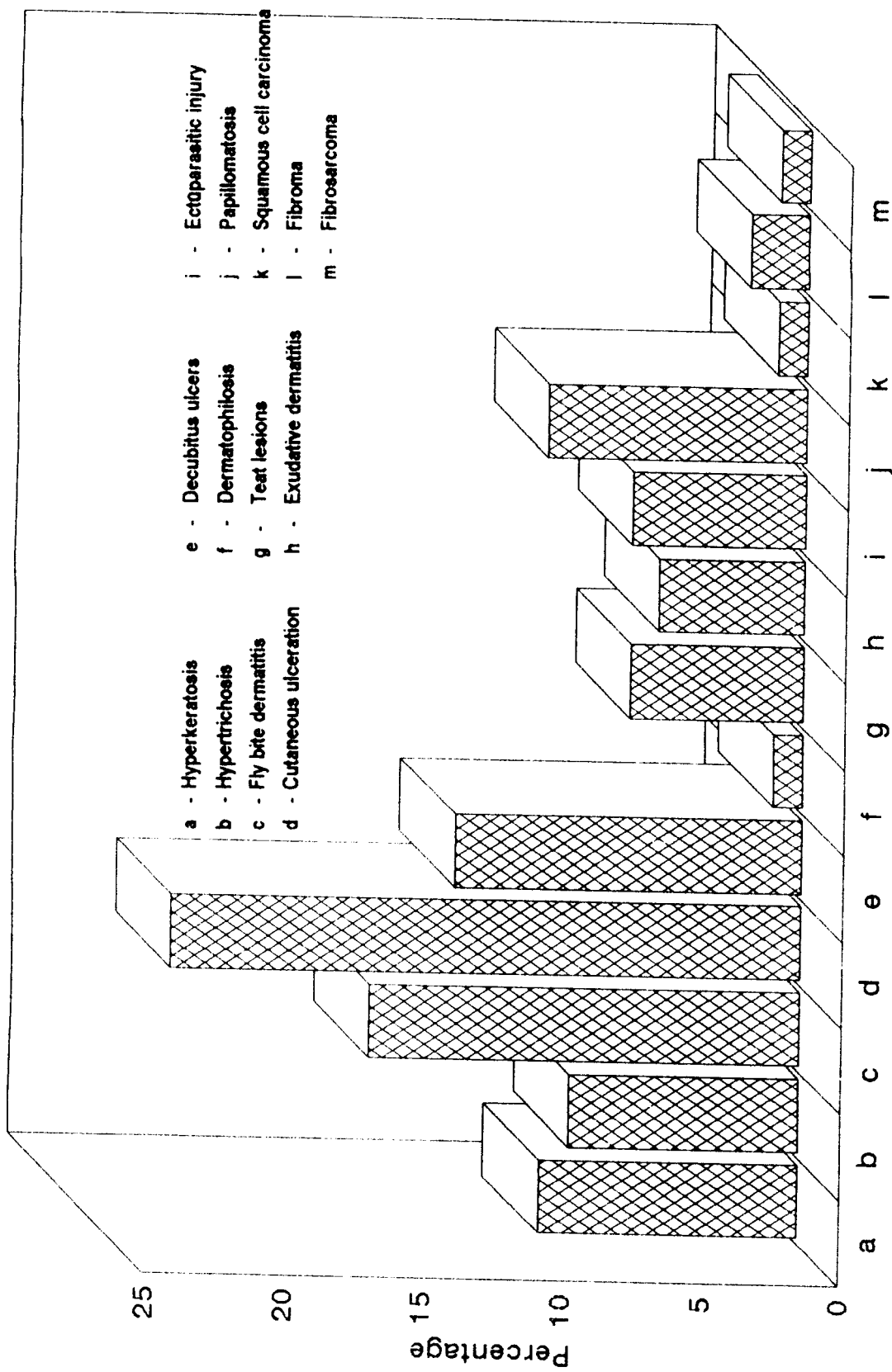


Fig.2 Dermatological disorders encountered in cattle during the period of study (1992 - 1994).

Fig.3. Cow-Hyperkeratosis - Lumbar region with irregular thick greyish white patch

Fig.4. Hyperkeratosis of stratified squamous epithelium acanthosis and thickening of the stratum corneum. H&Ex100


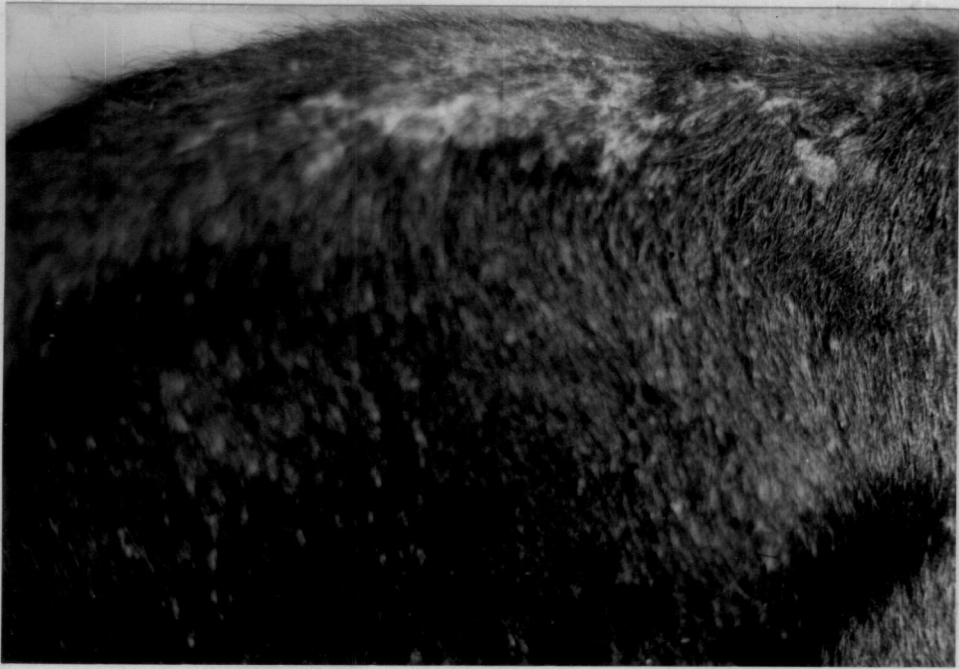


Fig.5. Hyperkeratosis - degenerated hair follicles, cystic follicular structures surrounded by flattened epidermal cells and concentrically arranged keratin. H&Ex250

Fig.6. Hyperkeratosis - cystic hair follicles with concentrically arranged keratin and thick layer of stratum corneum. H&Ex160

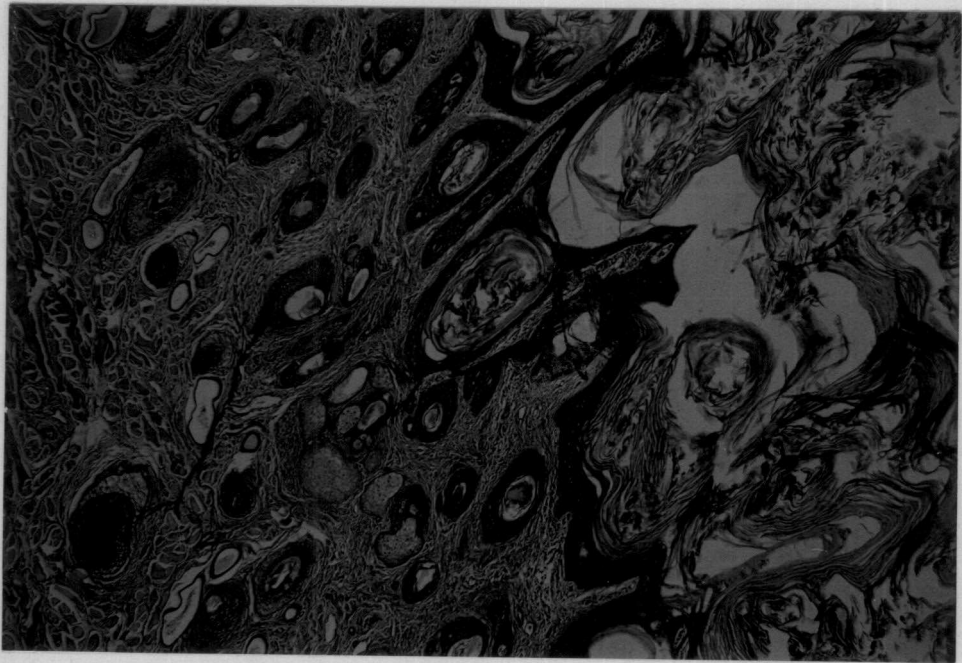
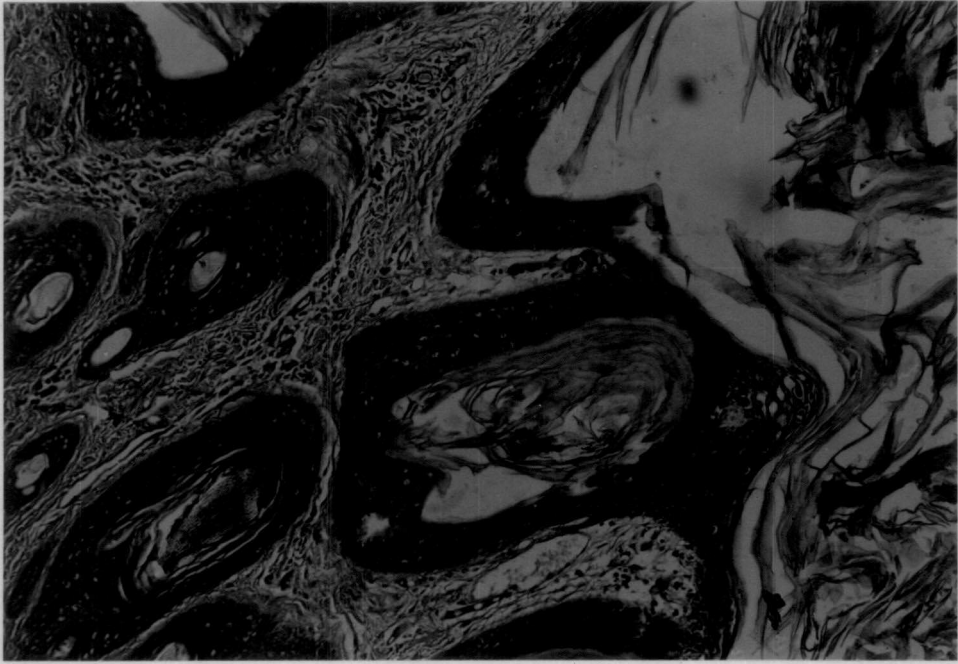


Fig.7. Hyperkeratosis - follicles filled with keratin plugs. H&Ex250

Fig.8. Cow-Hypertrichosis - Lumbar region - bilateral multiple black irregular patches with excessive hair growth

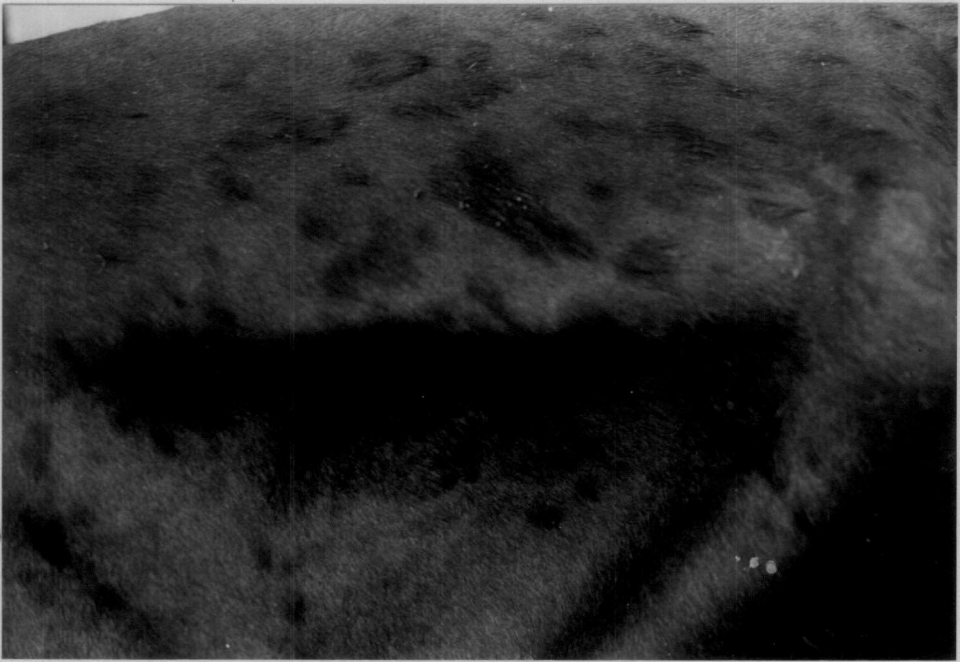
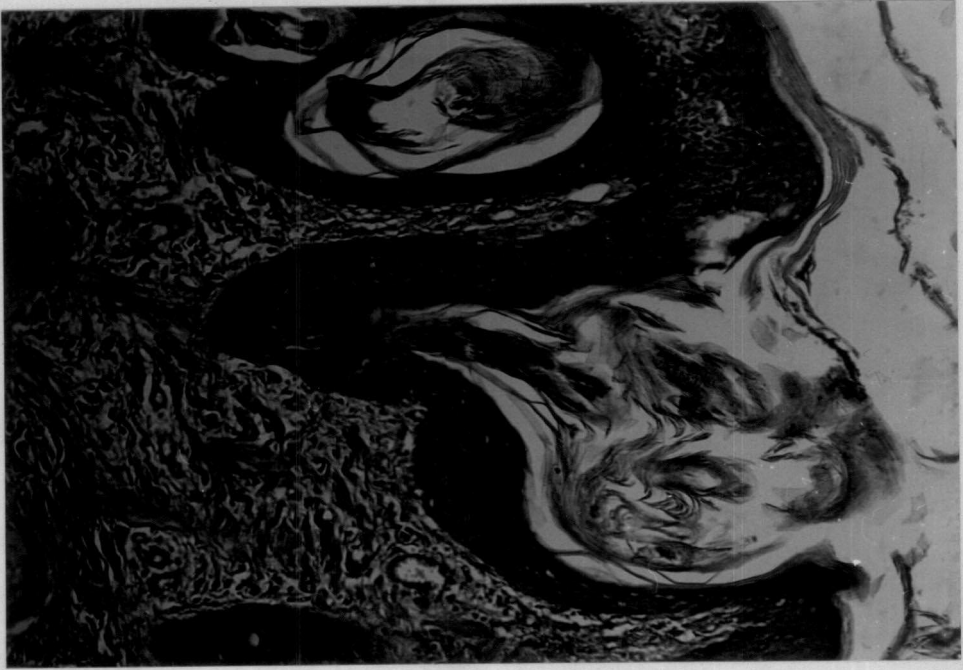


Fig.9. Hypertrichosis - hyperplasia of the outer root sheath cells - Hair follicles show keratin plugs. H&Ex250

Fig.10. Hypertrichosis high proportion of medullated hair follicles - hyperkeratosis of stratum corneum - more number of follicles in a given area. H&Ex160

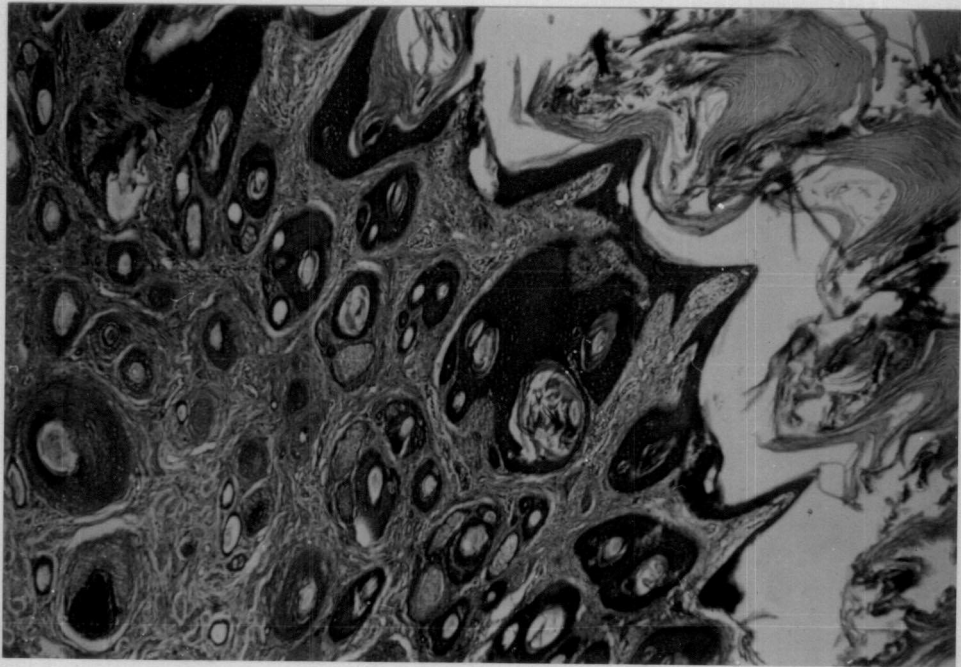
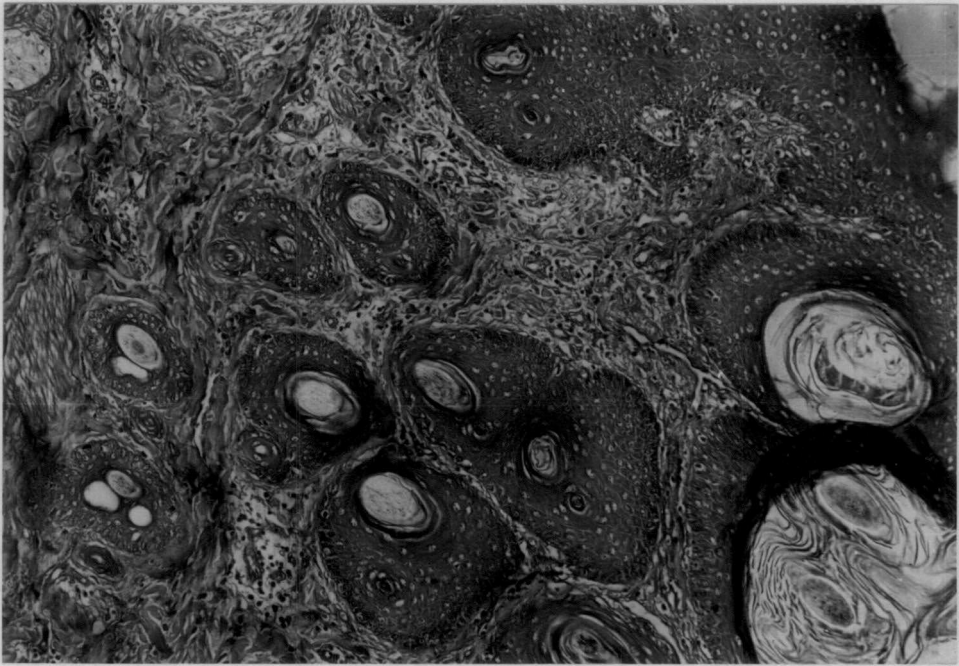


Fig.11. Cow - Fly bite dermatitis base of the neck and shoulder region - raised greyish white necrotic papules and wheals

Fig.12. Cow - Ear - Fly bite dermatitis - necrotic papules and wheals with haemorrhagic crusts

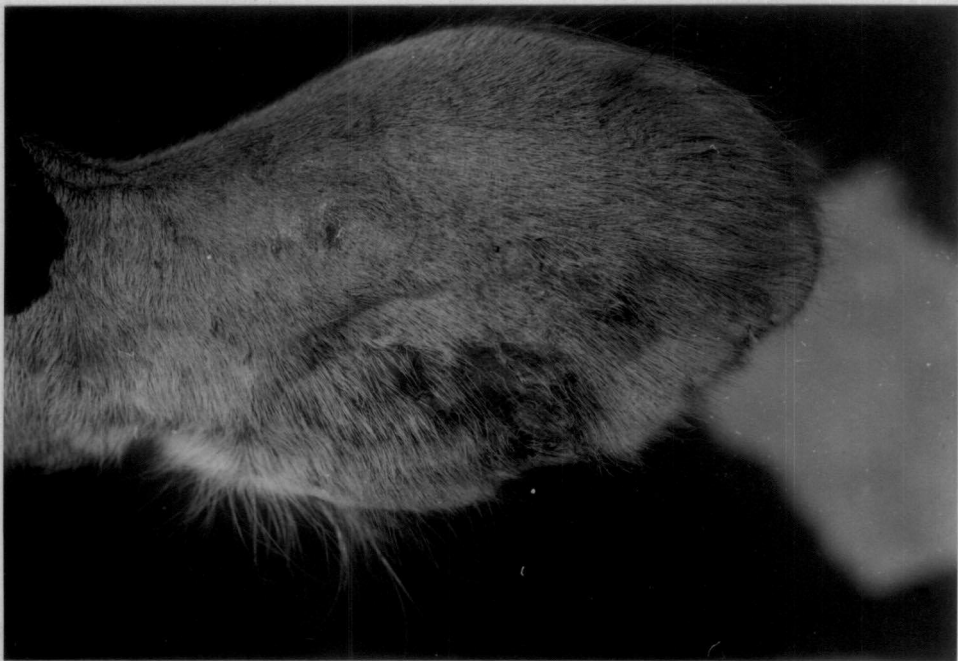
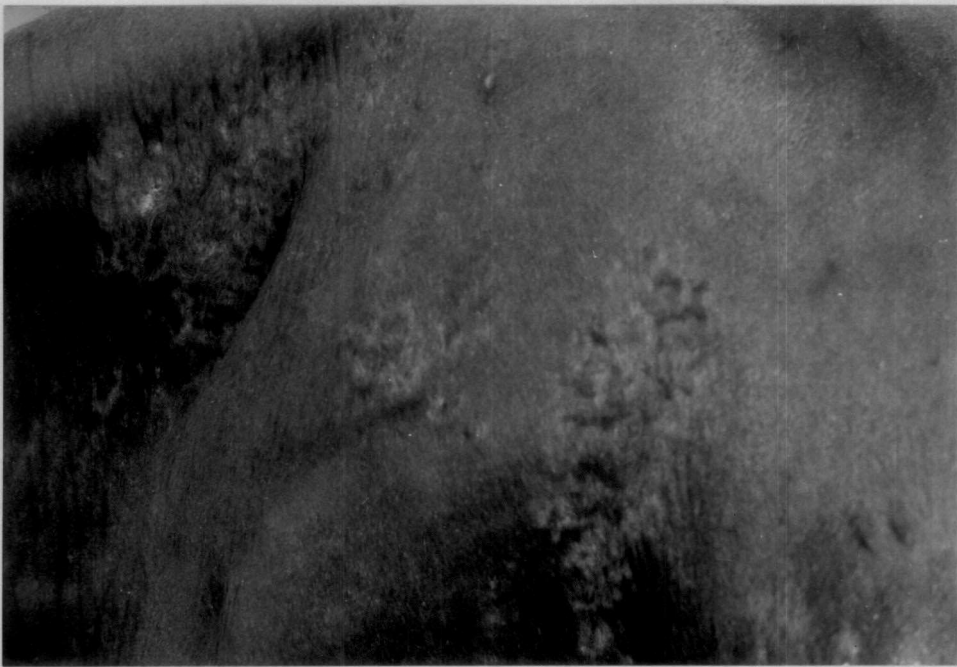

Fig.13. Fly bite dermatitis - perivascular dermatitis - with infiltration of inflammatory cells in the dermo- epidermal junction. H&Ex160

Fig.14. Cow - Fly bite dermatitis superficial haemorrhage - epidermal edema - mild hyperkeratosis. H&Ex250


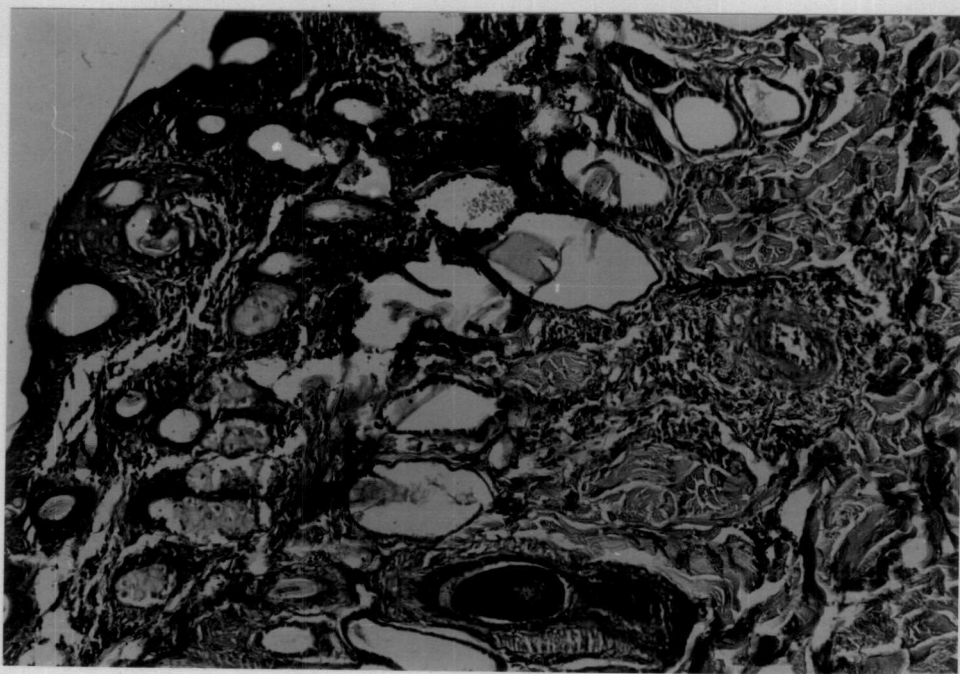


Fig.15. Cow - Cutaneous ulceration - neck region - exposure of raw surface - scar tissue formation and loss of hair

Fig.16. Cow - Cutaneous ulceration - shoulder region - A well defined ulcer with granulating base

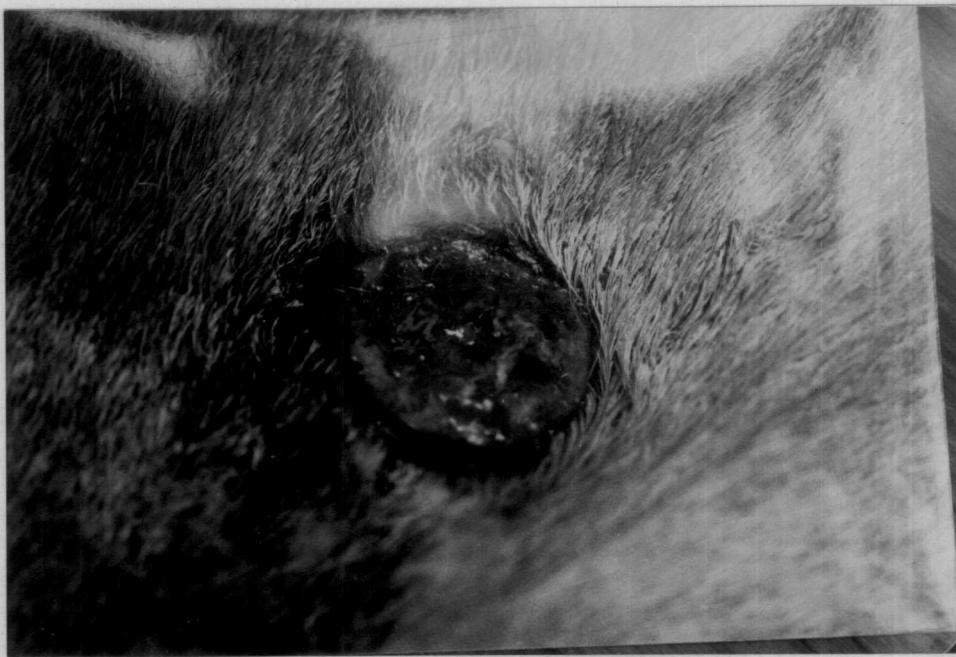
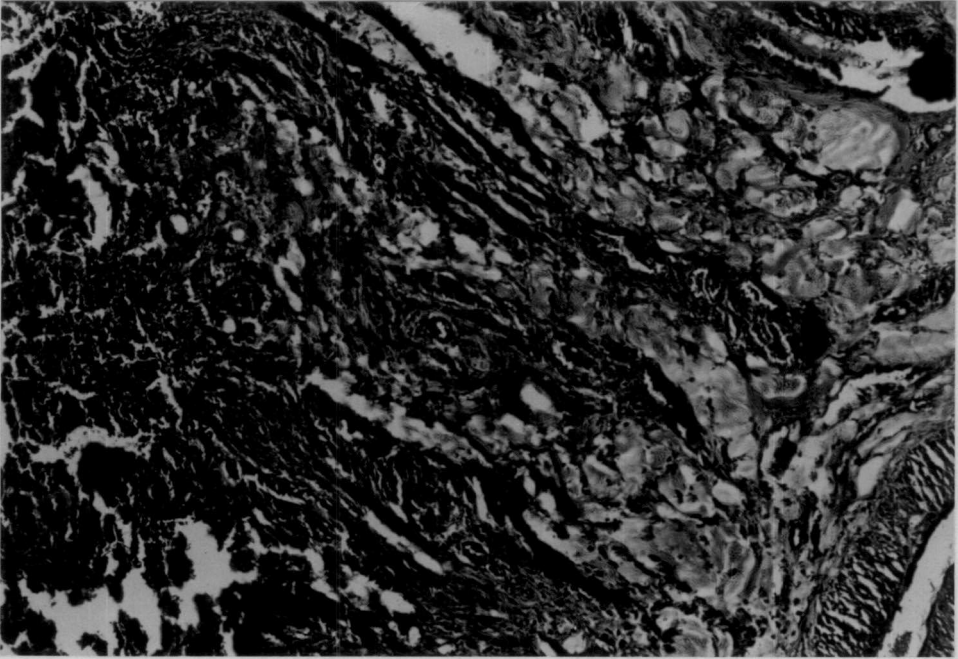
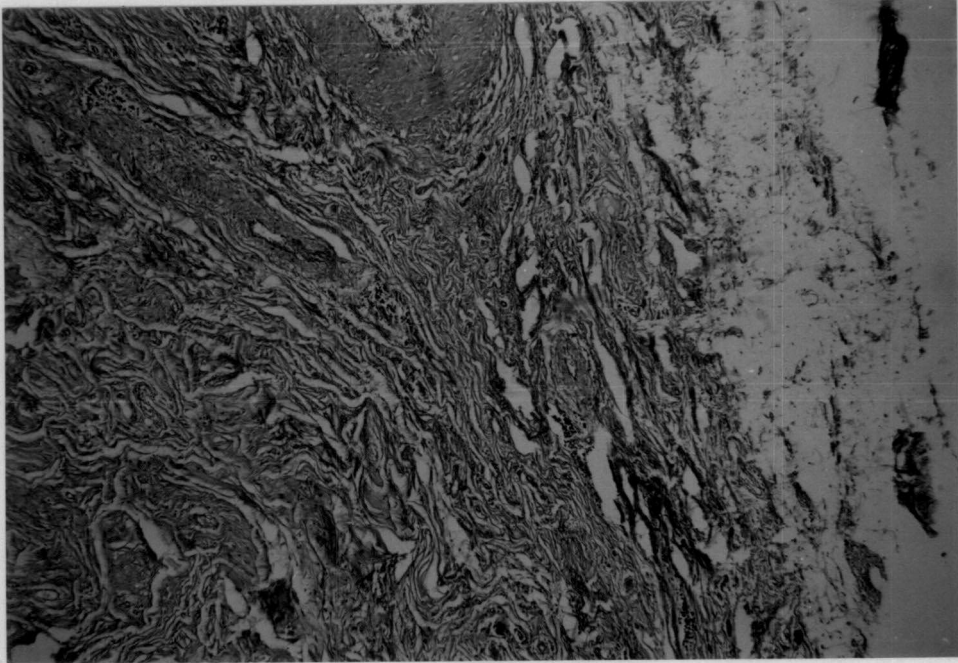


Fig.17. Cutaneous ulceration - epidermal lysis - mild perivascular reaction - folliculitis. H&Ex160

Fig.18. Cutaneous ulcerations - loss of architecture of the epidermis and part of the dermis. Areas of hyalination



**Fig.19. Cutaneous ulceration - Epidermolysis - free hyalinised hair shafts in the follicle - Hydropic degeneration of basal cells below the necrosed layer.
H&Ex160**

Fig.20. Cow - Decubitus ulcers - shoulder region

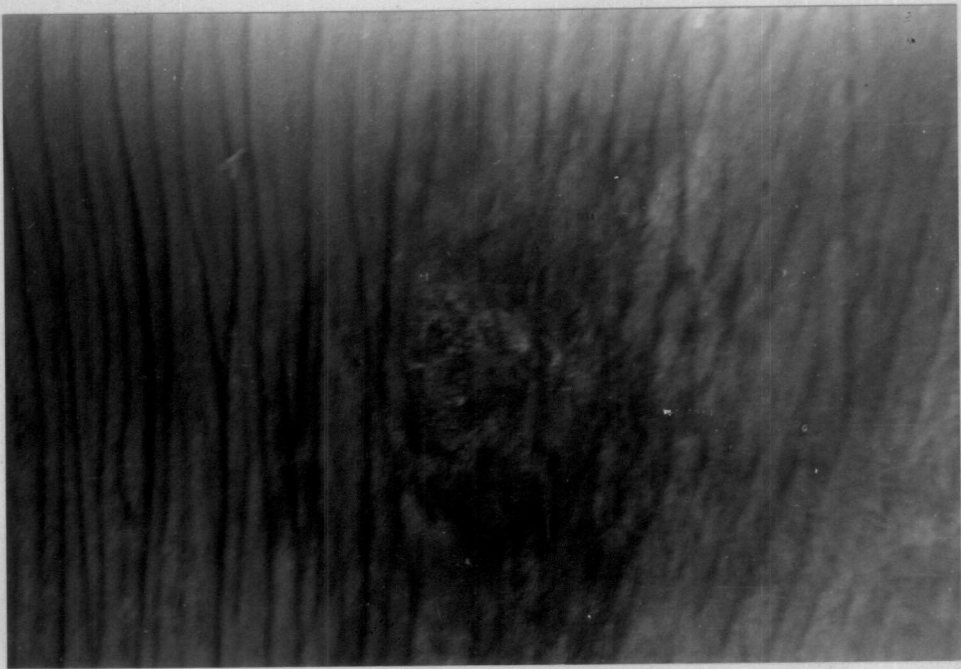
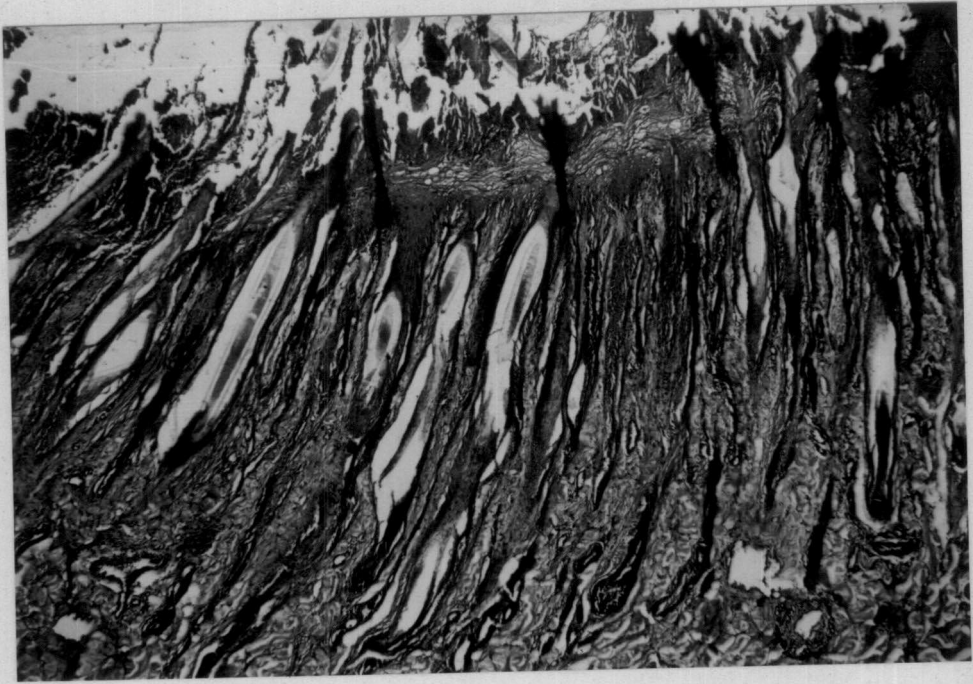

Fig.21. Decubitus ulcers Thinning of the epidermis with exudation - Atrophic changes of hair follicles. Dilatation of the sweat glands H&Ex160

Fig.22. Decubitus ulcers - atrophic changes of the hair follicular epithelium

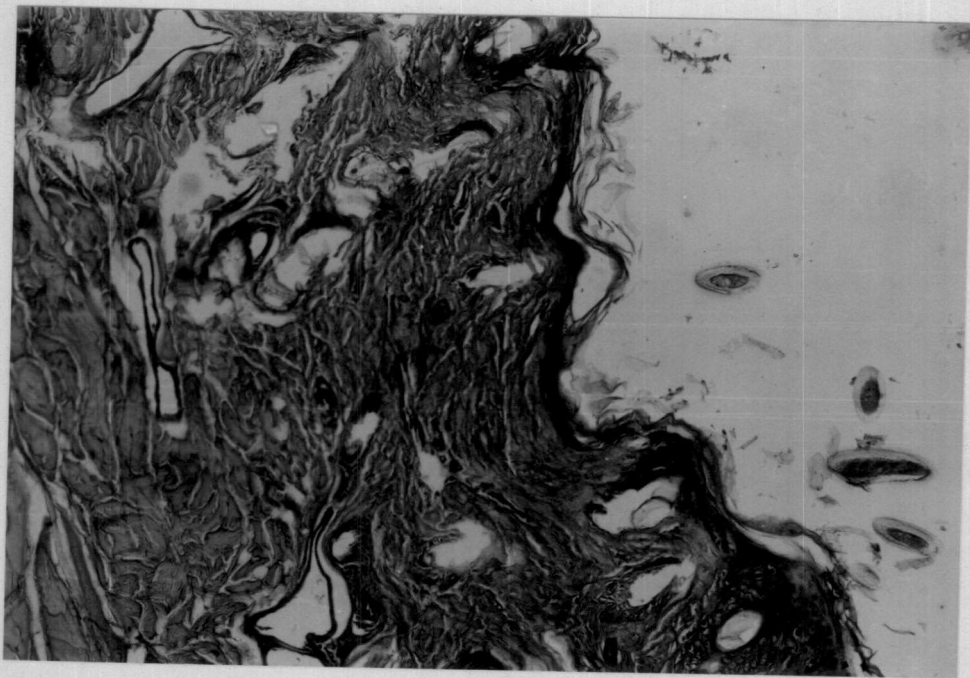
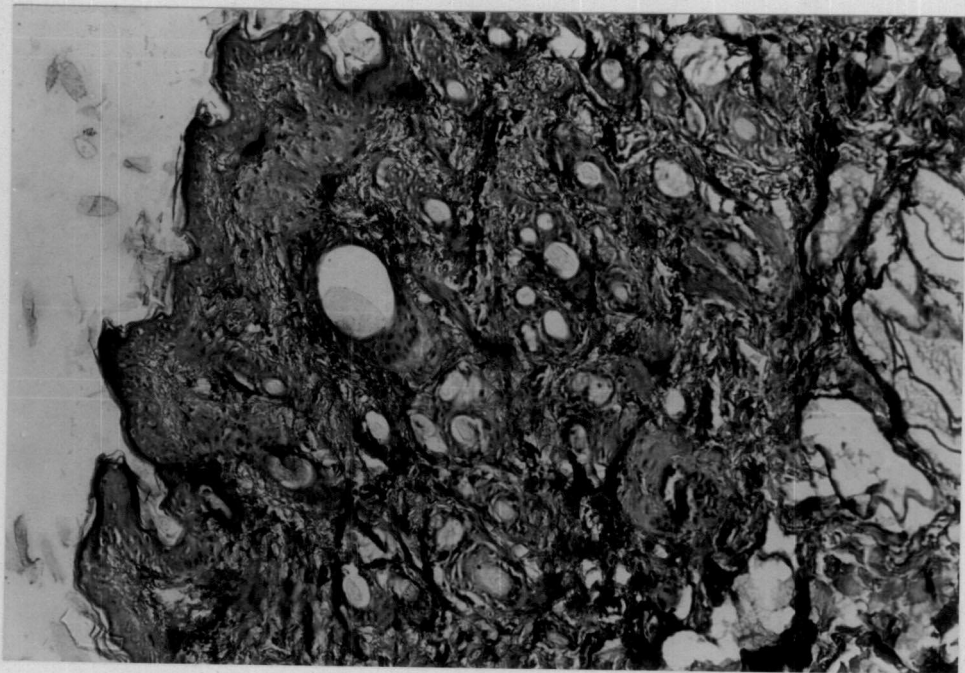


Fig.23. Decubitus ulcers - atrophy of the hair follicles and sebaceous gland atrophy. H&Ex250

Fig.24. Cow - Dermatophilus - rump region with focal circumscribed areas of hyperkeratosis - some areas show multiple crusts

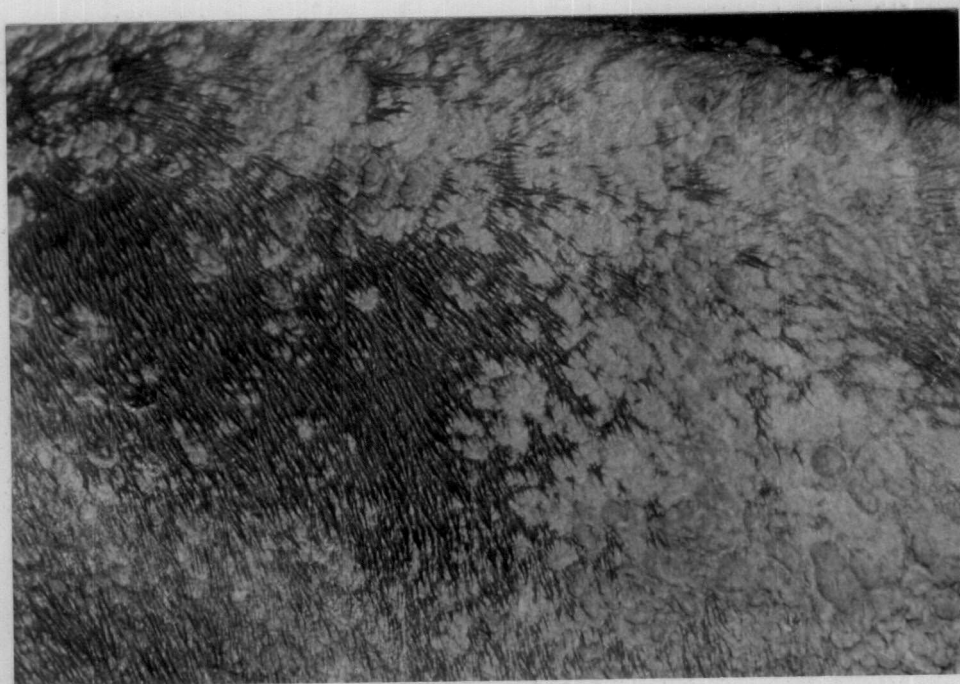
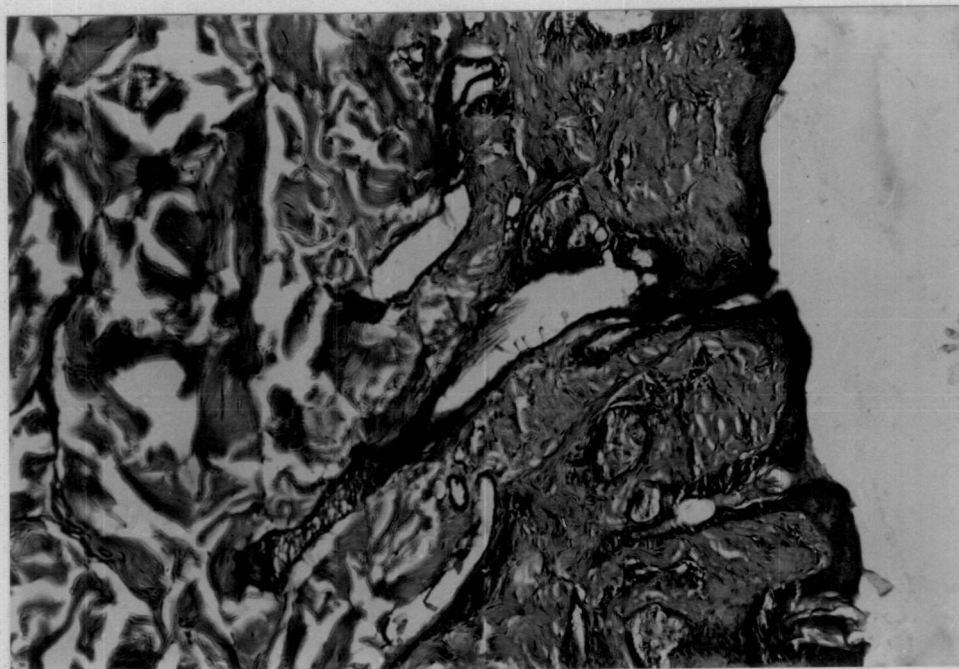


Fig.25. Dermatophilosis - hyperkeratosis - acanthosis - hydropic changes in the prickle cell layer. H&Ex250

Fig.26. Dermatophilosis - parakeratosis and coccoid organisms are seen - diffuse dermatitis. H&Ex250



Fig.27. Teat lesions - epidermal necrosis - fibrous tissue proliferation - diffuse granulomatous reaction and exudation above the necrosed epidermal layer. H&Ex160

Fig.28. Exudative dermatitis - hydropic degeneration of the epidermal cells - perivascular inflammatory reaction. Exudative reaction on the epidermis - dermal oedema. H&Ex160

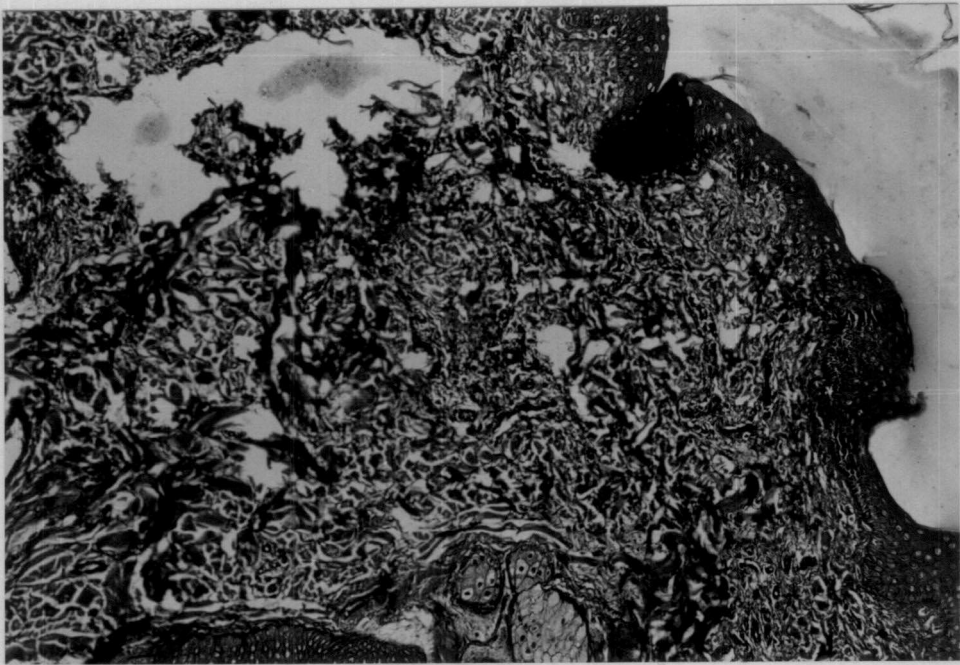
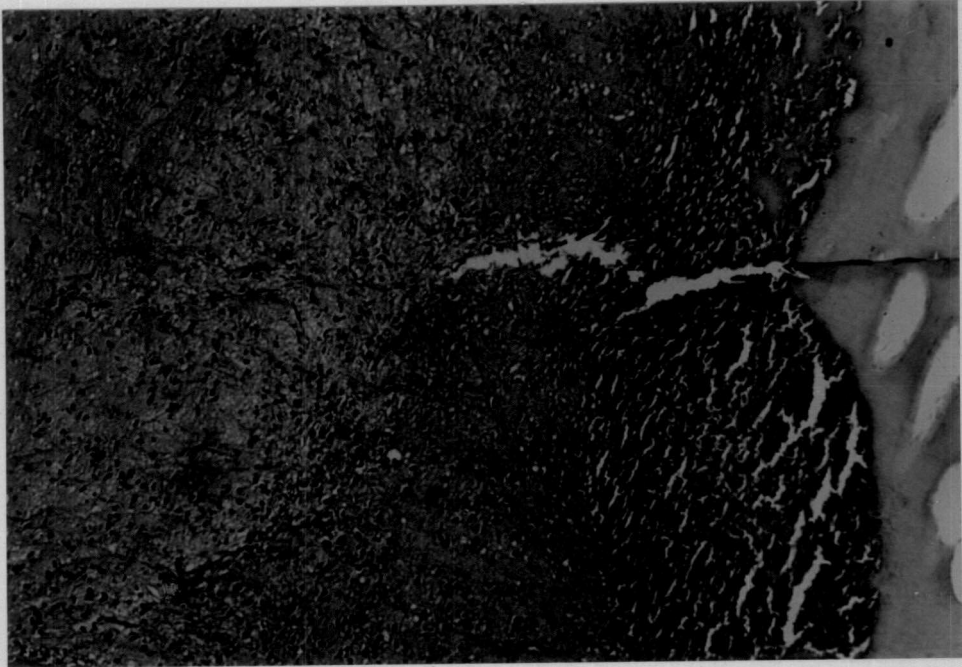


Fig.29. Ectoparasitic injury - focal epidermal necrosis - slight infiltration of inflammatory cells - epidermal cells shows hydropic change

Fig.30. Cow - papillomatosis - udder and base of the teat - flat firm and broad based warts

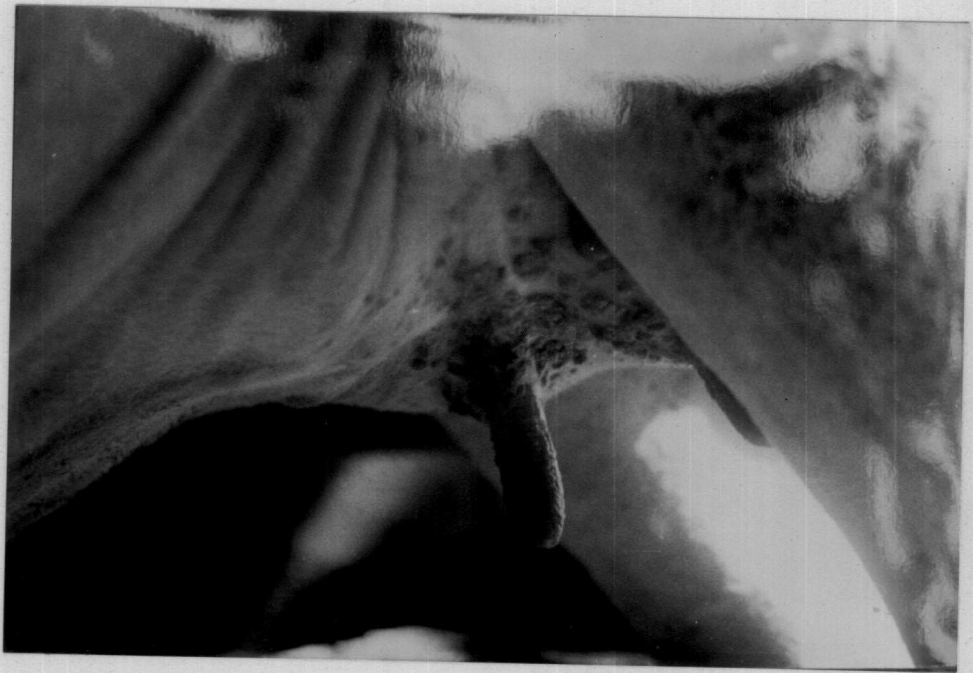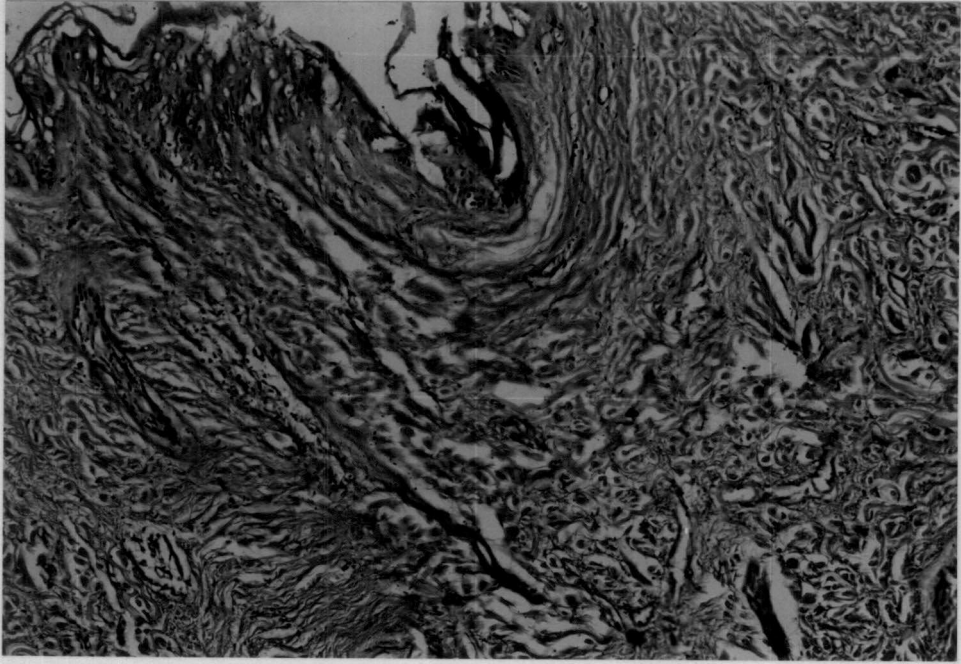


Fig.31. Papillomatosis - epithelial and fibrous tissue proliferation, ballooning degeneration and clumping of keratohyalin granules. Spongiosis - dyskeratosis. H&Ex400

Fig.32. Papillomatosis - irregular and undulating epidermal configuration - Dyskeratosis and pronounced acanthosis. H&Ex160

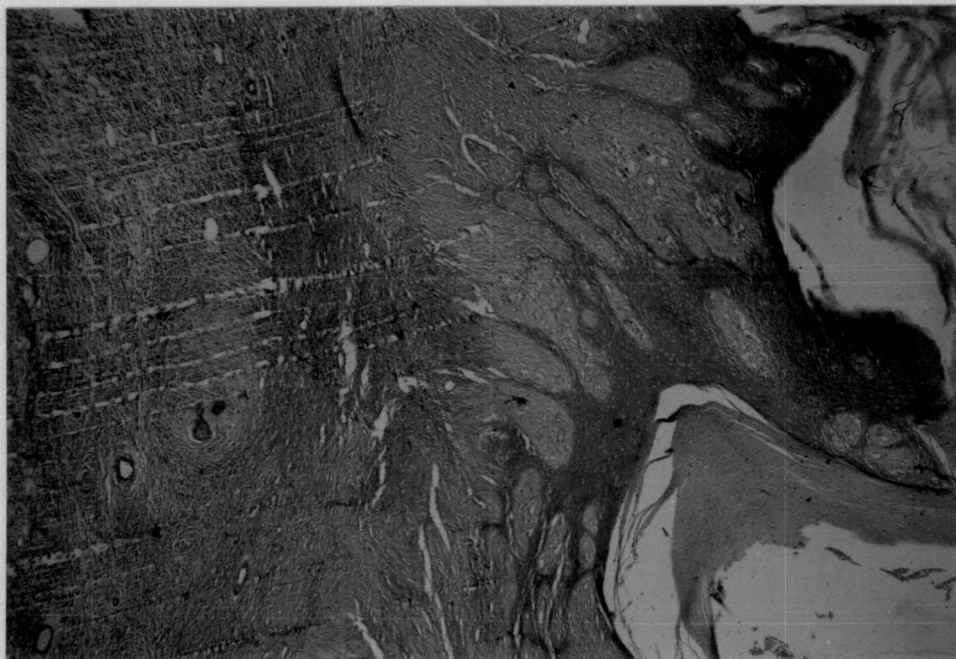
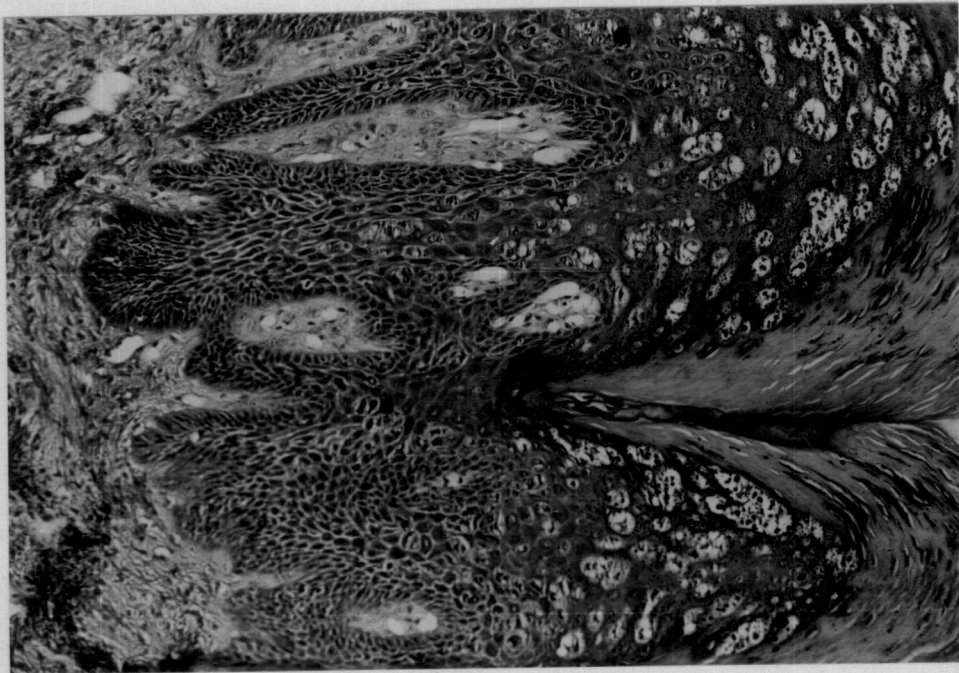


Fig.33. Papillomatosis irregular and undulating epidermal configuration - lower layer reveals spongiosis - and engorged blood vessels. H&Ex250

Fig.34. Squamous cell carcinoma - epidermal hyperplasia - islands of epidermal cells in dermis - cell nests with keratohyalin granules. H&Ex250

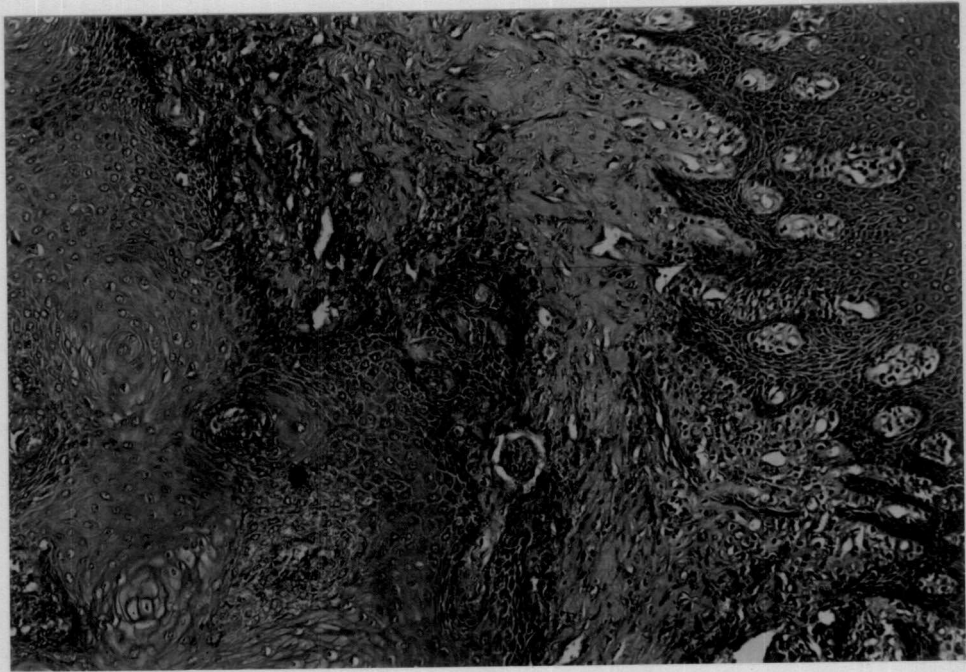



Fig.35. Cow - Fibroma - interlacing wavy bundles of proliferating fibroblasts.
H&Ex160

Fig.36. Fibroma - lymphocytic infiltration - Epidermal hyperplasia bundles of collagen seen separating the bundles of proliferating cells. H&Ex250

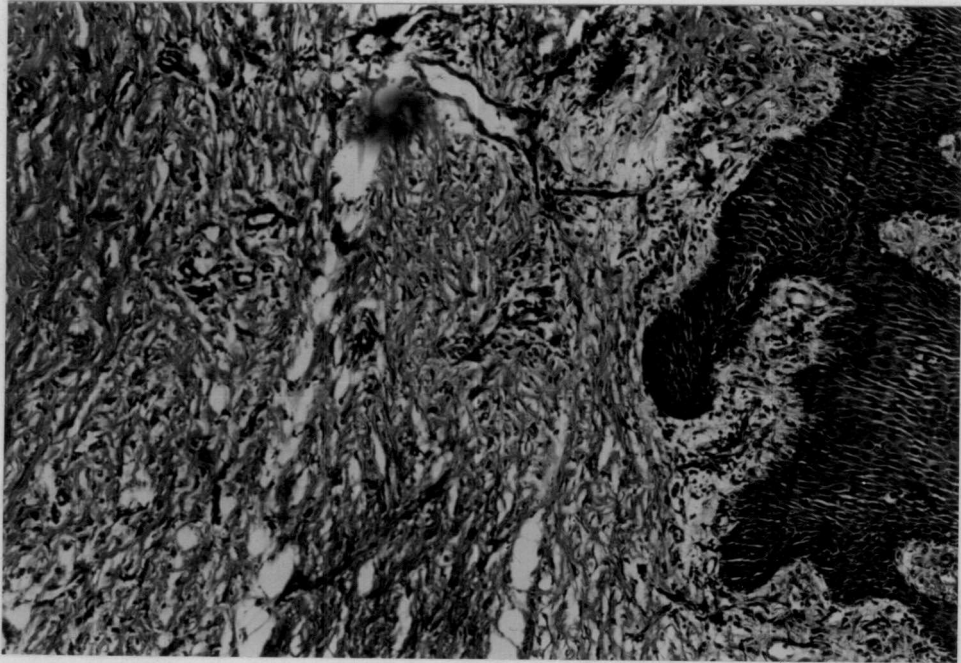



Fig.37. Cow - Teat -Fibrosarcoma - interwoven bundles of immature fibroblasts seen irregularly scattered - Varying stages of mitosis seen - Scanty collagen bundles seen separating group of fibroblasts. H&Ex160

Fig.38. Cutaneous hypersensitivity reaction to PHA-M 48 h biopsy - perivascular cuffing of lymphocytes. H&Ex250

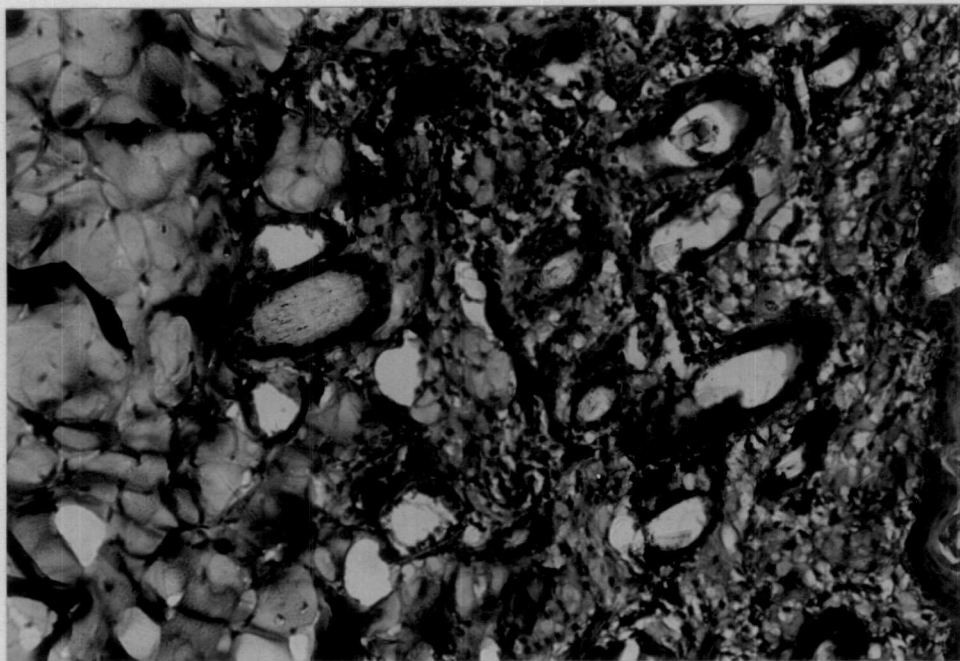
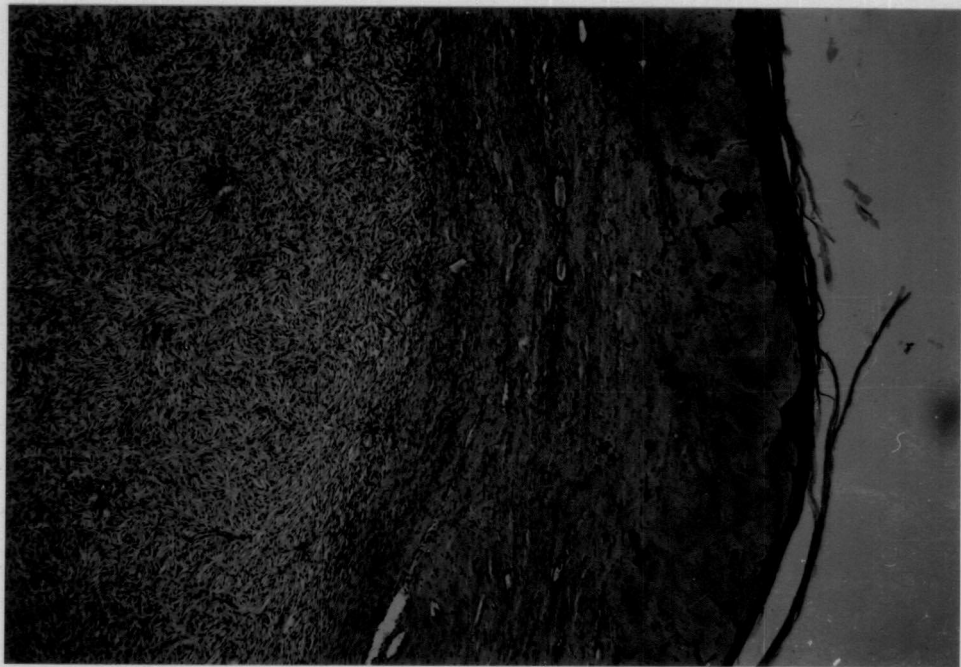


Fig.39. Cutaneous hypersensitivity reaction to DNCB 48 h biopsy - Capillary congestion and œdema - perivascular cuffing with macrophages and lymphocytes. H&Ex250

Fig.40. Cutaneous hypersensitivity reaction to BCG 48 h biopsy-œdema cellular infiltration in the deeper part of dermis with mononuclear cells. H&E x 250

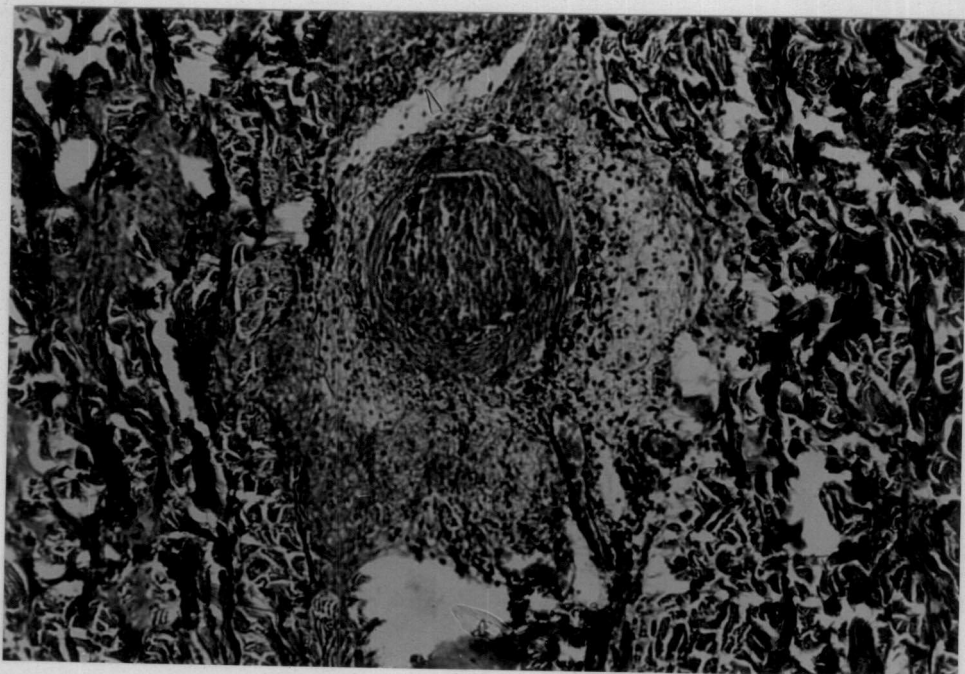
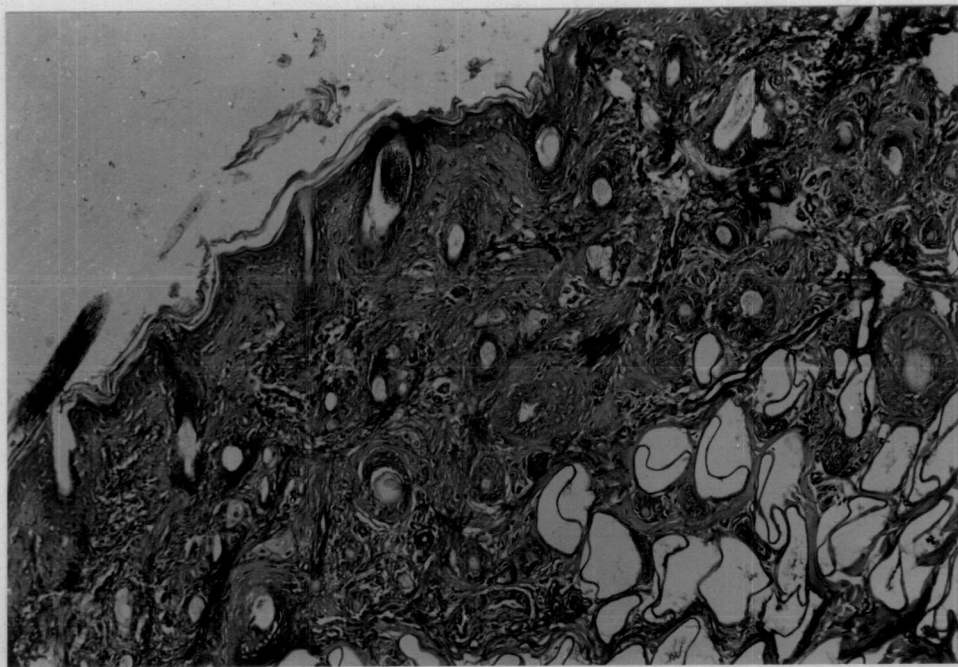
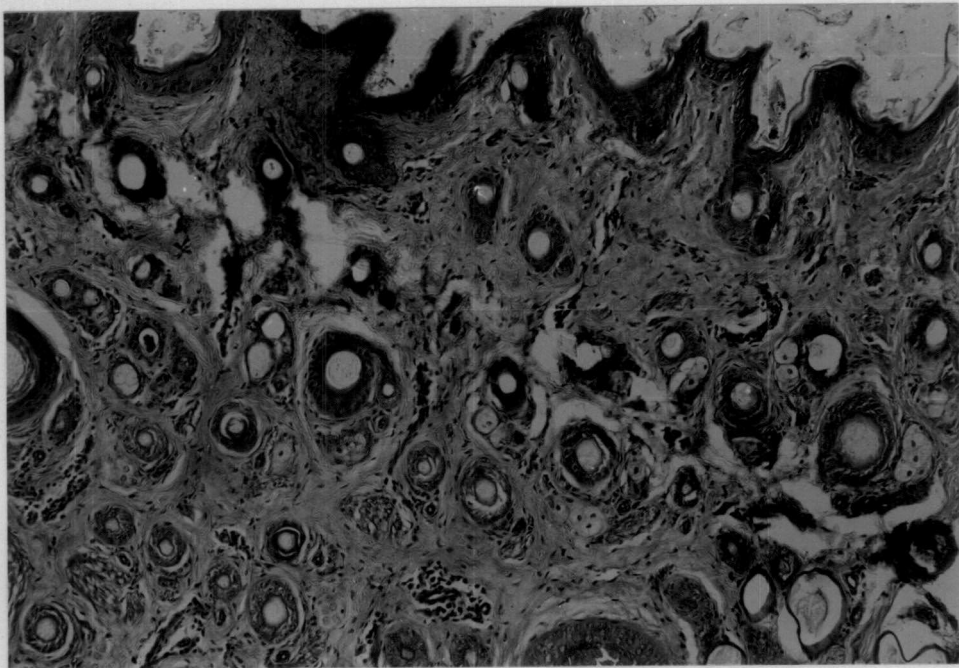


Fig.41. Changes in the skin to BHC application 5th day biopsy - slight hyperkeratosis and dermolysis. H&Ex160

Fig.42. Changes in the skin to Furadan application - 5th day biopsy - mild degree of hyperkeratosis and acanthosis and cystic dilatation of sweat glands



Discussion

DISCUSSION

Analysis of the data collected from the disease surveillance report published by the Directorate of Animal Husbandry Kerala state during the period 1989-1993 revealed 2.5 per cent prevalence of skin disorders in cattle. The diseases encountered on the skin are a reflection of the health of the animals. The prevalence recorded was relatively low. The skin disorders until and unless they cause severe damage to the skin, the farmer generally will overlook them and do not bring the animals for treatment. The hospital record is, therefore, not a true record of the incidence of the skin disorders. Tick infestation was found to be very high (37.22%) compared to other skin conditions which causes considerable amount of hide damage. Kerala has a relatively more proportion of high ranges and animals in high ranges are let off for grazing and they contract infections. Theileriasis, a tick borne infection is also common in high ranges. Tick infestation is indirectly a reflection on the immune status of the cattle. There is high percentage of crossbred cattle in Kerala and they have lower level of immunity compared to the non-descript animals. This may be one of the reasons for higher prevalence of tick infestation in Kerala state. Rajmohan (1980) reported the prevalence of *Boophilus annulatus* in Kerala. They were seen during all seasons of the year in all the districts of Kerala. The

prevalence of infection was more in hilly tracts compared to costal areas. This may be due to the higher density of vegetation ideal for the survival of intermediate stage for moulting and reinfestation in cattle of hilly tracts.

Another main dermatological problem reported was lice infestation with 25.71 per cent prevalence. Heavy infestation can cause anaemia and loss of weight. Menon (1953) recorded the incidence of *Haematopinus tuberculatus* in India throughout the year but more prevalent during the winter season. Collins *et al.* (1965), Galloway (1972) observed anaemia, loss of weight unthriftiness and predisposition to other diseases due to heavy lice infestation. Chaudhuri (1976) reported the occurrence of *Haematopinus tuberculatus*, *H. curysternus* and *Linognathus vituli* in India. He observed that the cattle became lousy when they remained inside sheds during winter. Mohan (1979) reported on the occurrence of *Haematopinus quadripertusus* and *Linognathus vituli* in cattle of Kerala with an incidence of 44.34 per cent and 3.47 per cent respectively.

Chalmers and Charleston (1980) observed 30.8 per cent prevalence of lice infestation in New Zealand. Their results are in general agreement with the present observation.

Mangy dermatitis with an incidence of 13.81 per cent was also found to be an important problem.

Gradle (1987) encountered 16.73 per cent mange infestation in cattle in a slaughter house which caused hide damage.

Gabaj et al. (1992) recorded 56.9 per cent of mangy dermatitis in farm animals of Libia. The commonest parasites on cattle were *psoroptes* and *chorioptes*. Mbutia et al. (1993) recorded an incidence of 14.80 per cent in cattle of Kenya. Both the records are in almost agreement with the present survey.

According to Buchner et al. (1994) *Demodex bovis* caused maximum damage to the hide followed by *Scarcoptes* and *Chorioptes*.

The prevalence of cutaneous mycosis was found to be 10.58 per cent and this is in general agreement with the observation of Chatterjee and Sengupta (1979).

According to Blood and Radostits (1983) dermatomycosis occurred when animals were housed in close proximity to each other for long periods. A high incidence of clinical cases in the winter and spontaneous recovery in summer were also observed by them. Management practice followed by farmers of Kerala and the ideal humid climatic condition prevalent in Kerala supports the observations made by them.

The prevalence of Eczematosis was 6.09 per cent. This may be a form of epidermitis associated with *Staphylococcus aureus* and *Staphylococcus hycus* in India as observed by Nicholls and Rubiro (1981) and Hazarika et al. (1990). They observed small pustules, large healing erosive lesions, generalised exudative dermatitis and exfoliative dermatitis affecting the perineum, udder, thighs and teats.

Eczematosis was also observed when the epidermal cells were brought into contact with allergens like external parasites, antiseptics, disinfectant washes, long term soiling and accumulation of skin debris (Blood and Radostits, 1983).

Prevalence of pox lesions was 4.75 per cent which may be pseudocowpox mostly affecting the teat and udder. It can cause difficulty in milking and increases the incidence of mastitis. This disease is transmitted to milkers causing milkers nodules which is then transmitted to other animals.

The prevalence of tail necrosis was 1.44 per cent. George et al. (1970) recorded an incidence of 11.26 per cent in various part of Kerala during the year 1968-69. Kwatra and Singh (1972), Dhillon (1973) related the incidence of the disease to paddy straw feeding during winter months. Rajan et al. (1977) reported on the prevalence and pathology of tail necrosis of bovines in Kerala. They also stated that cows were mainly fed paddy straw due to scarcity of fodder. The

straw which was purchased in bulk and stacked with the presence of moisture due to rain favours fungal attack releasing mycotoxins and this was suggested as the cause of tail necrosis. This observation was also supported by Deng et al. (1984) and Xavier (1989).

The prevalence of warts recorded was 0.36 per cent. Warts can occur on the face, ear, nose, forehead, cheek, neck, dewlap, udder, teats and limbs as observed by Nair and Sastry (1954). In cattle these may interfere with the sale because of their unsightly appearance. Warts on the teats can also interfere with milking. The marketability of hide can be considerably affected.

In the present investigation detailed gross and histopathological studies on 97 cattle were studied and classified.

Among the dermatological disorders encountered, cutaneous ulceration was the most common finding (22.68%). They were noticed mainly at the neck and shoulder region where the tail cannot reach. These were observed in stall fed cattle due to the excessive rubbing of the neck and shoulder region. These regions were untouched by the switch of the tail to alleviate the irritation. Some of the animals resisted irritation with their prominent horns or rubbing on

rough surfaces. This led to ulceration and later secondary infection.

Another main dermatological problem affecting cattle was fly bite dermatitis (15.46%). Groups of white necrotic papules and wheals were seen on the neck shoulder, ears and around eyes. Flies encountered were mainly mosquitoes, *Culicoides* and *Simulium*. Large swarms of mosquitoes from waterlogged areas in the coastal region attack animals in the night and can cause severe irritation and damage the skin due to hypersensitivity reaction. This annoyance can affect milk production. This observation points out the need for planned control programme against these biting flies.

Decubitus ulcers were also another problem in cattle recumbent for long periods especially in downers. Some of the skin samples were obtained from the postmortem room from dead animals. 12.47 per cent of the animals studied were having decubitus ulcers. These bed sores and ulcers can cause considerable hide damage. This was supported by the observations of Platzzen (1988) who recorded 19 per cent of hide damage during transport, which were mainly due to ulcerations and pressure sores.

Nine cases of localized hyperkeratosis were recorded especially on the dorsum of the neck and lumbar regions. The affected regions were rough, scaly, dry and wrinkled. Blood

and Radostits (1983) observed high incidence of hyperkeratosis in hypovitaminosis A in feed lot cattle. Hypo-vitaminosis A is a common occurrence in Kerala particularly during summer due to lack of green fodder.

Another dermatological problem encountered in cattle was cutaneous papillomas (9.27%) especially on the back, neck, forehead, limbs, udder and teat. Nair and Sastry (1954) recorded an incidence of 6.60 per cent of papillomatosis in Madras state and lesions encountered were mainly on the eyelids, cheek, neck, dewlap, udder, vulva and limbs. A case of generalized form of cutaneous papillomatosis was observed in this study in a cow. This was characterized by low flat circular and nonpedunculated warts.

William et al. (1992) reported 25.18 per cent of papillomatosis and sites were udder, followed by head and neck, limbs and trunk. The occurrence of papillomatosis was in agreement with the observation made by Nair and Sastry (1954) whereas William et al. recorded a higher occurrence (25.18%). Papillomas renders the animal unsightly and teat involvement causes difficulty in milking. The acceptance rate of hide can be affected. Secondary bacterial infection can lead to loss of condition and those with teat involvement lead to mastitis.

In this study, the incidence of hypertrichosis was 8.5 per cent. These were mainly seen in animals recovered from foot and mouth disease. Kablov (1958) stated that degenerative changes in nerve supplying cutaneous blood vessels could result in hypertrichosis. Kelly (1974) was of the opinion that the persistent nutritional disturbances affected the coat and which became lusterless, dry and staring. Jubb et al. (1992) stated that higher incidence of hypertrichosis in such animals were mainly due to impairment in the function of the thermoregulatory system.

Six cases of ectoparasitic infestation were studied in this investigation. Tick infested mainly were *Boophilus annulatus* which were seen during all seasons of the year similar to the observations made by Rajmohan (1980). Morrow et al. (1991) reported an incidence of 4.2 per cent in cattle at St. Lucia with *Amblyomma* species. Wheals and slight erosions were found at the site of bite. Tick infestation can cause hide damage as the histopathology revealed epidermal necrosis. This observation is in accordance with the findings of Gradle (1987) where he recorded higher incidence of hide damage due to tick infestation in cattle.

Scott (1988) observed that the ability of animals to resist tick infestation was related to the immune status.

Teat lesions encountered in this study (6.19%) were mainly due to traumatic injury due to stepping on teats, chapping and accidental bite by other cows. These lesions were mainly inflammatory type with secondary bacterial infection. Chapping was a common problem encountered due to the cold dry wind during the month of December and January. Milking process was difficult in such animals because of the pain.

Two cases of fibromas were recorded in this investigation. Nair and Sastry (1954) reported an occurrence of 3.60 per cent. Moulton (1978) stated that fibromas were uncommon neoplasm in large animals. The observation made in the investigation is in agreement with his statement. But Joshi *et al.* (1985) reported a higher occurrence of 10.63 per cent in Gujarat State. Histopathology of these fibromas were similar to the fibromas described by Jubb *et al.* (1991).

One case of fibrosarcoma was also documented in this investigation which was on the teat of a cow. The reports of fibrosarcomas on the teat are scanty. A case of subcutaneous fibrosarcoma was reported by Scott (1988) in a calf. Histopathology revealed interwoven bundles of immature fibroblasts in varying stages of mitosis.

In this study only one case of squamous cell carcinoma was encountered. This was located at the vulval region, and the surface was irregular and ulcerated. There was focal areas of haemorrhage and purulent foci. Vijaya Sarathi *et al.* (1976) reported a similar case of vulval squamous cell carcinoma in Karnataka state, which measured 5x3x3 cm. According to Moulton (1978) squamous cell carcinomas occurred mainly at the mucocutaneous junction especially in the adult and aged animals. Squamous cell carcinomas were mostly encountered on the eye and vulva according to a survey conducted by Bastianello (1982) in South Africa.

A case of dermatophilosis was observed in this investigation. Lesions were seen as focal circumscribed areas of hyperkeratosis and multiple crusts. It was diagnosed by the typical "railroad tracks" appearance and by the presence of coccoid cells in the impression smears as stated by Scott (1988). He also pointed out the importance of moisture for the relatively high incidence of Dermatophilosis. Pal (1989) also recorded similar encrusted lesions.

Experimental trials were conducted to study the response of mitogens like PHA, 2,4-DNCB and BCG on the skin of bovines.

Response to PHA was studied by administering PHA intradermally. Gross and histological results were similar to

that observed by Blease *et al.* (1973), Jedrzejczak (1976), Rajan *et al.* (1984).

Response of 2,4 DNCB was studied on six calves and the cutaneous reactions were comparable with the results obtained by Brown *et al.* (1967), Chakravarthy *et al.* (1973), Brummerstedt and Basse (1973), Jennings (1979), Reddi *et al.* (1981).

Response of BCG was studied on six calves. The cutaneous reactions and histomorphological picture were identical with the observations made by Rosental (1957), Sreekumaran (1980), Rajan *et al.* (1982).

Mast cell response were also studied using PHA, 2,4-DNCB and BCG. There is not much literature regarding the influence of these mitogens on the mast cell response. Rothwell *et al.* (1991) stated that mast cells in mitogen injected skin were less densely granulated than cells in normal and PBS injected skin as observed in this study. The response of the mast cells was almost similar to PHA and DNCB. However, the response to BCG was much less. Perhaps the reaction to BCG was more of a sub-acute to chronic type compared to PHA and DNCB. Clinically the response of the mast cells is seen particularly in acute inflammatory reaction.

Application of selected agro pesticide like BHC and Furadan revealed mild degree of hyperkeratosis and dilated lymphatics and dermolysis. There is not much literature regarding the effect of these drugs in the skin of domestic animals on external application. A longer duration of exposure might cause considerable histomorphological changes. The animals are likely to come into contact with pesticides. The response observed in this study was dermatosis rather than dermatitis. This observation would point out the need for avoiding pesticide contamination on the skin of animals during farm operations. Initial dermatosis may lead to secondary dermatitis by bacterial and fungal invasion. Therefore adequate care has to be taken to prevent the animal skin coming into contact with pesticides. The reaction of the pesticides was relatively less and transient. Perhaps continuous exposure might cause a hypersensitivity and a more severe reaction. This has to be studied in detail.

Summary

SUMMARY

An investigation was undertaken to study the prevalence and nature of dermatological disorders of cattle in Kerala. For this study data on the prevalence of different dermatological disorders encountered in cattle were collected from the Disease Surveillance report published by the Directorate of Animal Husbandry during the period 1989-1993. This study revealed an overall prevalence of 2.5 per cent skin disorders in cattle. The various skin disorders encountered in animals according to this data were tail necrosis (1.44 per cent); Cutaneous mycosis (10.58 per cent); Eczematosis (6.09 per cent); Pox (4.75 per cent); tick infestation (37.22 per cent) lice infestation (25.71 per cent) mangy dermatitis (13.82 per cent); Wart (0.36 per cent). Tick infestation was found to be more prevalent.

In the present investigation detailed gross and histopathological studies on 97 cattle were studied and classified. The percentage incidence of various type of dermatological disorders in the decreasing order of frequency were Cutaneous ulceration (22.68 per cent); Fly bite dermatitis (15.46 per cent); Decubitus ulcers (12.47 per cent); Hyperkeratosis (9.3 per cent); Papillomatosis (9.27 per cent); Hypertrichosis (8.25); Ectoparasitic injury (6.19 per cent); Teat lesions (6.19 per cent); Fibroma (2.07 per cent); Dermatophilosis (1.03 per cent), Squamous cell carcinoma (1.03 per cent); and Fibrosarcoma (1.03 per cent).

Cutaneous ulceration was the most common disorder encountered. Erosion of the epidermal layer with scaling and crust formation was noticed. Histopathologically there was epidermal lysis and hydropic degeneration of basal cells.

Fifteen cases of fly bite dermatitis were encountered in this study. Grossly lesions were characterised by greyish white necrotic papules and wheals on the neck shoulder ears and around eyes. Biopsy studies revealed perivascular dermatitis with infiltration of inflammatory cells.

Decubitus ulcers were a problem mostly associated with prolonged recumbancy especially near the stifle, thoracic region and shoulder region. Biopsy studies revealed exudation and thinning of the epidermis with diffuse inflammatory changes.

Nine cases of hyperkeratosis were studied which may be associated with hypovitaminosis A. Lesions were confined to the withers, dorsum of the neck and lumbar region. Histologically there was thickening of the stratum corneum.

Papillomatosis was recorded in 9.27 per cent of the cases. They were mainly seen on the udder and teat with ballooning degeneration and clumping of keratohyalin granules microscopically.

Hypertrichosis was observed in crossbred cattle (8.25%) recovered from foot and mouth disease. The hair coat was shaggy and wavy.

Six animals were found to have Ectoparasitic injury due to *Boophilus* infestation on the neck and back region with wheals and erosions at the site of bite. Microscopically focal epidermal necrosis and odema were seen.

Teat lesions were encountered in six animals which were mainly due to traumatic injury and chapping. Milking process was painful. Subcutaneous tissue revealed necrosis and fibrous tissue proliferation. Two cases of fibromas were studied. The growth was firm and surface was encapsulated and ulcerated. Biopsy studies revealed interlacing bundles of proliferating fibroblasts.

A case of Dermatophilosis was encountered with focal circumscribed areas of hyperkeratosis and multiple crusts. Impression smears from the crusts revealed coccoid cells of *Dermatophilus*. Microscopically some areas of parakeratosis and diffuse dermatitis were observed.

A growth on the vulval region measuring 10x6 cm was diagnosed as squamous cell carcinoma. Microscopically islands of epidermal cells were seen in the dermis forming "cell nests".

A rare case of fibrosarcoma was encountered as a solitary firm growth on the body of the teat. Interwoven bundles of immature fibroblasts were seen microscopically.

An experimental study on the cutaneous hypersensitivity reaction in cattle to PHA, 2,4-DNCB and BCG was carried out. Cellular and vascular changes declined from 24 h to 72 h with these mitogens. Mast cell response to these mitogens were also evaluated. The response was almost similar to PHA and DNCB. But response to BCG was much less.

Effect of Agro pesticides Furadan and BHC on the skin of calves was studied. There was no visible gross lesions. On BHC application, histologically mild hyperkeratosis and dermolysis were observed.

Furadan application also revealed similar changes with mild degree of acanthosis.

References

REFERENCES

- Abu Samra, M.T. Imbabi, S.E. and Mahgoub, S.E. (1976). *Dermatophilus angolensis*. A bacteriological in vitro antibiotic sensitivity and histopathological study of natural infection in Sudanese cattle. *Br. Vet. J.* 132(6): 627-633.
- Ackerman (1978). *Histological diagnosis of inflammatory skin diseases*. Philadelphia, Lea & Febiger.
- Addo, P.B. (1983). Role of the common housefly *Musca domestica* in the spread of ulcerative lymphangitis. *Vet. Rec.* 113: 496-499.
- Ali, B.H. and Obeid, H.M. (1977). Investigation of the first outbreaks of Lumpy skin disease in the Sudan. *Br. Vet. J.* 133: 184-187.
- Amstutz, H.E. (1979). Bovine skin conditions. A brief review. *Mod. Vet. Pract.* 60: 821-829.
- Asegedech Sirak, Infante, S.I. (1994). Histopathological analysis of bovine skin lesion caused by *Dermatophilus congolensis*. *Indian Vet. J.* 71 (1): 16-18.
- Baker, K.P. (1973). *Demodex* spp. in the meibomian gland of Irish cattle. *Vet. Rec.* 92: 699.

- Baker, J.C., Hultgren, B.D. and Larson, L.V. (1982). Disseminated cavernous hemangioma in a calf. *J. Am. Vet. Med. Assoc.* 181: 171-173.
- Bakken, G. (1980). Nemetodes found in summer sores on cows teat. *Norsk Vet Tidsskr.* 92 (2): 99. Cited in *Vet. Bull.* (1980) 50. Abstr. 7181.
- Balakrishnan, V.S. (1988). Clinico-therapeutic studies on panthers. Ph.D. thesis, Andra Pradesh Agricultural University, Hyderabad.
- Baldwin, R.W. and Pimm, M.V. (1978). BCG in tumour immunotherapy - *Advances in cancer research.* 28: 91-147. Ed. by Klein, G. and Weinhouse, S. Academic Press, New York.
- Barthold, S.W., Koller, L.D., Olson, C. and Studer, E. (1978). Atypical warts in cattle. *J. Am. Vet. Med. Assoc.* 165(3): 276-280.
- Bastianello, S.S. (1982). A survey on neoplasm in domestic spieum over a 40 year period from 1935-1974 in republic of south Africa I Tumor occurring in cattle. *Onderstepoort. J. Vet. Res.* 49 (4): 195-204. Cited in *Vet. Bull.* (1983) 53 (10). Abstr. 6599.
- Bech-Nielsen, S., Sjogren, U. and Lundquist, H. (1982). Parafilaria bovicola (Tubangui, 1934) in cattle Epizootiology disease occurrence. *Am. J. Vet. Res.* 43: 945.

- Blease, R.M., Weiden, P., Oppenheim, J.T. and Waldman, T.A. (1973). Phytohaemagglutinin as a skin test for the evaluation of cellular immune competence in man. *J. Lab. Clin. Med.* 81: 538-548.
- Bliss, E.L. and Iverson, W.D. (1981). Mastocytoma in a dairy cow: Two case reports. *Vet. Med. Small Anim. Clin.* 76(1): 79.
- Blood, D.C. and Radostits, O.M. (1983). *Veterinary Medicine VI*. Philadelphia, Lea & Febiger. pp. 475-496.
- Booth, A., Reid, M. Clark, T. (1987). Hypovitaminosis A in feedlet cattle. *J. Am. Vet. Med. Assoc.* 190: 1305-1307.
- Brown, R.S., Haynes, H.A., Poley, H.T., Godwin, H.A., Berard, C.W. and Carbone, P.P. (1967). Hodgkin's Disease. Immunologic, clinical, and histologic features of 50 untreated patients. *Ann. Int. Med.* 67: 291-302.
- Brummerstedt, E. and Basse, A. (1973). Cutaneous hypersensitivity to 2-4 Dinitro-chlorobenzene in calves. *Nord. Vet. Med.* 25: 392-398.
- Buchner, A., Baumgartner, W. and Carda, C.H. (1994). Aetiology of mechanical and infectious damages to cattle hide. *Proceedings of 18th world Buietrics congress 26th congress of Intalian Association of Buiiatrics Bologna Haly Aug. 29. Cited in Vet. Bull. (1996) 66 (3) Abstr. 1614.*
- Burfening, P.J. (1973). Ergotism. *J. Am. Vet. Med. Assoc.* 163: 1288-1290.

- Campbell, S.G., Whitlock, R.M., Timoney, J.F. and Underwood, A.M. (1975). An unusual epizootic of actinobacillosis in dairy heifers. *J. Am. Vet. Med. Assoc.* 166(6): 604.
- Chakravorthy, R.C., Curutche, H.P., Coppolla, F.S., Park, C.M., Blaylock, W.K. and Lawrence, W. (1973). The delayed hypersensitivity reaction in cancer patients observation made on sensitization by DNCB. *Surgery* 73: 730-735.
- Chalmer, K. and Charleston, W.A.G. (1980). Cattle lice in New Zealand observation on the prevalence distribution and seasonal pattern of infestation: observation on biology and ecology of *Damalina bovis* and *Linognathus vituli*. *N.Z. Vet. J.* 28: 198-237. Cited in *Vet. Bull.* (1981) 15 (6). Abstr. 3291.
- Chatterjee, A., Sengupta, D.N. (1979). Ringworm in domestic animals. *Indian J. Anim. Heath.* 18 (2): 37-46.
- Chaudhuri, R.P. (1976). *Insects pests of farm animals in India*. I.C.A.R., New Delhi. pp.55.
- Chauham, H.V.S. (1981). Studies on horn cancer etiopathology. *Indian Vet. J.* 58: 851-855.
- Cherille, N.F. and Shey, D.J. (1967). Pseudocowpox in dairy cattle. *J. Am. Vet. Med. Assoc.* 150: 855-861.
- Clarke, E.G.C. and Clarke, M.L. (1981). *Veterinary Toxicology* II, London, Baillicre Tindall, 2 edn.

- Collins, R.C. and Dewrist, L.W. (1965). Some effects of the suckling louse *Haematopinus eurysternus* on cattle on unsupplemented range. *J. Am. Vet. med. Assoc.* 146(2): 129-132.
- Damodaran, S., Sundararaj, A. and Ramakrishnan, R. (1979). Horn cancer in bulls. *Indian Vet. J.* 56: 248.
- Deng, W.L., Tang, X.M., Chen, L. and Li, M.H. (1984). A foot disease in cattle caused by mycotoxins *Chin. J. Vet. Sci. Technol.* Cited in *Rec. Med. Vet. Mycol.* (1986). (21). Abstr. 598.
- Dhillon, K.S. (1973). Preliminary observation on the treatment of Degnala disease in buffaloe. *Indian Vet. J.* 50: 482-484.
- Dibakarsen. (1990). Skin lesions of FMD. *Indian J. Ani. Health* 29(1): 99-100.
- Doughty, F.R. (1972). Virus particles in a bovine neurofibroma. *Aust. Vet. J.* 48: 365-369.
- Dozsa, L. and Weiss, R. (1971). Multiple fibroblastic tumour in a two month old-calf. *Cornell. Vet.* 61: 705-706.
- Edwards, C.M. (1953). Ergot poisoning in young cattle. *Vet. Rec.* 65: 158.
- Edwardson, J. and Andrews, A.H. (1979). An outbreak of ring worm in a group of young cattle. *Vet. Rec.* 104: 474-478.


- Eilber, F.R. and Morton, D.L. (1970). Impaired immunologic reactivity and recurrence following cancer surgery. *Cancer* 25: 362-367.
- El-Allawy, T.A., El-Trabildi, M.M.A., Mourad, M.I. and Sedek, S.R. (1992). Isolation and identification of Lumpy skin disease virus from upper Egypt. *Assiut Veterinary Medical Journal* 28(55): 279-289. Cited in *Vet. Bull.* (1993) 63 (7). Abstr. 4437.
- El-Mahdi, M.M. (1989). Histomorphological description of papilloma in calves in the UAE. *Arch. Exp. VetMed.* 43(1): 61-65. Cited in *Vet. Bull.* (1990) 60 (8). Abstr. 4117.
- Gabaj, M.M., Beesley, W.N. and Awan, M.A.Q. (1992). A survey of mites on farm animals in Libya. *Ann. trop. Med. Parasit.* 86(5): 537-542.
- Galloway, J.H. (1972). *Farm animal health and disease control.* Lea and Febiger, Philadelphia. 45: 452.
- Galitzer, S.J. and Oehme, F.W. (1978). Photosensitization - A literature review. *Vet. Sci. Coomon.* 2: 217-230. Cited by Scott, D.W. (1988).
- Gardner, A.W. and Hall-Patch, P.K. (1968). Molybdenosis in cattle grazing downwind from an oil refinery unit. *Vet. Rec.* 82: 86.
- Gearhart, M.S., Crissman, J.W. and Georgi, M.E. (1981). Bilateral lower palpebral demodicosis in a dairy cow. *Cornell Vet.* 71: 305-310.

- George, P.O., Cheeran, J.V. and Aleyas, N.M. (1970). Necrosis of tail in bovine animals. *Vet. Rec.* 87: 231-233.
- Gibbs, E.P.J. (1973). Cow pox in dairy herd in the United Kingdom. *Vet. Rec.* 87: 602.
- Gingrich, R.E. (1982). Acquired resistance to *Hypoderma lineatum* comparative immune response of resistant and susceptible cattle. *Vet. Parasitol.* 9: 233-239.
- Ganesh, T.N., Manikarajan, M., Ameerjan, K. and Sundararaj, A. (1990). Melenoma and malignant melenoma in bovines 2 case reports. *Indian Vet. J.* 67(2): 558-560.
- Gradle, K. (1987). Occurrence frequency and courses of skin diseases of slaughter cattle resulting skin and leather damage as seen at the Bomberg abattoir. Inagural *Dissertaion, Justus-Liebig-Univerbitat Giessen, German Federal Republic.* pp. 195. Cited in *Vet. Bull.* (1988) 58. Abstr. 2045.
- Green, J.R. and Kleynhans, J.E. (1989). Suspected vetch (*Vica benghalensis* L.) poisoning in a Friesland cow in the Republic of South Africa. *J. Af. Vet. Assoc.* 60(2): 109-110. Cited in *Vet. Bull.* (1990) 60, Abstr. 726.
- Groth, A.M., Bailey, W.S. and Walker, D.F. (1960). Bovine mastocytoma - a case report. *J. Am. Vet. Med Assoc.* 137: 241-243.

- Grunder, H.D. (1984). Skin diseases in calves and cattle particularly new ways of controlling mange and ring worm. *Hautkrankheiten bei Kalbern und Rindern Insbesondere neuere Verfahren Zur bekämpfung von Raude and Trichophyte Paraktische Tierarzt.* 65: 74-82. Cited in *Vet. Bull.* (1984) 54. Abstr. 6530.
- Gupta, R.K.P. (1980). Horn cancer in an intact bull. *Vet Rec.* 107: 312.
- Gupta, P.K. and Singh, R.P. (1996). A note on the effect of age on the incidence of ringworm in cattle buffalo and horses. *Indian J. Anim. Sci.* 37: 69-72.
- Haab, C., Bertschinger, H.V. and Rotz, A. Von. (1994). Epidemiology of ring worm in veal calves with regard to prevention of leather defects. *Schweizer Arch. Tierheilk.* 136 (6): 217-226. Cited in *Vet. Bull.* (1995) 65. Abstr. 3050.
- Haggard, D.L., Stowe, H.D., Conner, G.H. and Johnson, D.W. (1980). Immunologic effects of experimental iodine toxicosis in young cattle. *Am. J. Vet. Res.* 41: 539-543.
- Hannes, C. and Dom, P., Haesebrouk, F. and Devriese, L. (1990). First isolation in Belgium of *Dermatophilus congolensis* from a cow. *Vlaams. diergeneesk. Tijdschr.* 60(50): 1983-1984. Cited in *Vet. Bull.* (1992) 62. Abstr. 1135.
- Hazari, M.M., Misra, S.C., Panda, M.R., Bisoi, P. and Rao, A.T. (1991). Host response to heavy *Boophilus microplus* infection. *Indian Vet. J.* 68(5): 409-412.

- Hazarika, R.A., Mahanta, P.N., Dutt, G.N. and Devriese, L.A. (1990). Cutaneous infection associated with *Staphylococcus hyicus* in cattle. *Res. Vet. Sci.* **61**(3): 620-626.
- Herin, V. and Fain, A. (1955). Filarioses des bovidés au Ruanda-Urundi I' Etude Clinique. *Annls Soc. belge Med. trop.* **35**: 503-521.
- Hussein, M.F. and Haroun, E.M. (1975). Bovine besnoitiosis in the Sudan: A case report. *Br. Vet. J.* **131**: 85-89.
- Igmire, C.U. (1947). Carcinoma in the vulva of a cow. *Vet. Med.* **42**: 427-430.
- Ikede, B.O. and Losos, G.T. (1972). Pathological changes in cattle infected with *Trypanosoma brucei*. *Vet. path.* **9**: 272-274.
- Irving, F. and Butler, D.G. (1975). Ammoniated mercury toxicity in cattle. *Can. Vet. J.* **16**: 260-264.
- Ishtharai, K., Sasaki, Y. and Kitagawa, H. (1982). Occurrence of cutaneous hemorrhagic parafilaria in cattle. *Jpn. J. Vet. Sci.* **44**: 669-673.
- Isshiki, O. (1963). Studies on bovine enchocerciasis in Korea. *Jpn. J. Vet. Sci.* **25**: 375.
- Jarnagin, J.L. (1983). Isolation of *Mycobacterium kansasii* from lymph nodes of cattle in the United States. *Am. J. Vet. Res.* **44**: 1825-1828.

- Jedrzejczak, W.W. (1976). Phytohaemagglutinin (PHA). Skin test in predicting prognosis in cancer patients. *Int. Arch. Allergy Appl. Immunol.* 51: 574-582.
- Jennings, P.A. (1979). Leucocytes adherence inhibition: A micro assay demonstrating antigen recognition in cattle. *Res. Vet. Sci.* 26: 111-113.
- Johnson, S.J. (1981). Stephanofilariasis in cattle. *Aust. Vet. J.* 57: 411-414. Jones, R.J. (1978). Toxicity of *Leucaena leucocephala*. *Aust. Vet. J.* 54: 387-389.
- Jones, G. (1984). Selenium deficiency in a dairy herd. *Med. Vet. Pract.* 65: 868-872.
- Joshi, R.C., Chaudhary, P.G. and Bansal, R.P. (1977). Occurrence of cutaneous eruptions in rinderpest outbreak among bovine. *Indian Vet. J.* 54: 871-873.
- Joshi, C.S., Gollerkerim, P. and Gongal, S.G. (1975). Evaluation of immunoresponsiveness in cancer patients. *Indian J. Med. Res.* 63: 315-325.
- Joshi, B.P., Parajapathi, K.S. and Heranjali, D.D. (1985). A survey of Bovine neoplasms in Gujarat state. *Indian J. Anim. Res.* 19 (1): 33-36.
- Jubb, K.V.F., Kennedy, P.C. and Palmer, N. (1992). *Pathology of domestic animals*. 4 edn. Vol.I. Academic Press Ltd., London. pp. 513-737.



- Kablov, G.A. (1958). Changes in nervous elements of skin and mucous membrane of oral cavity in Foot and Mouth disease in cattle. *Arch. Path.* 20: 43-48. Cited in *Vet. Bull.* 29, Abstr. 376.
- Kelly, W.R. (1974). *Veterinary clinical diagnosis*. 2nd Ed. Bailliere, Tindall, London.
- Kerr, A. and Edwards, W.C. (1982). Hairy vetch poisoning of cattle. *Vet. Med. Small Anim. Clin.* 77(2): 257-259.
- Khajuria, R.R. (1966). Incidence and control of parafilariasis in bovines in Jammue province. *Indian Vet. J.* 43: 749-751.
- Khan, M.A. (1968). Examination of cattle grubs hypoderma spp. on a regional basis. *Vet. Rec.* 83: 97-98.
- Kirickbridge, C.A. (1973). Hemangioma of a bovine fetus with a chorioangioma of the placenta. *Vet. Pathol.* 10: 238-240.
- Koshy Varghese (1980). Bovine lymphosarcoma in crossbred cattle histopathology, Hematological and Serological studies. M.V.Sc. thesis Gujarat Agricultural University Sardarkrishinaryn Gujarat.
- Khalil, A., Bourut, C., Halle-Pannenko, O., Mathe, G. and Rappaport, W. (1975). *Biomedicine* 22: 142-121. Cited by Baldwin, R.W. and Pimm, M.V. 1973.

- Kivako, N.P. (1979). Diagnosis of micro onchocercarial infestation of the udder skin of cows. *Byull. vses. Inst. Gelmintol.* 24: 31-34. Cited in *Vet. Bull.* (1981) 51. Abstr. 711.
- Kulkarni, H.V. (1953). Carcinoma of horn in bovines of old Boroda State. *Indian Vet. J.* 29: 415.
- Kwatra, M.S. and Singh, A. (1972). Cited by Dhillon. *Indian Vet. J.* 50: 482-489.
- Lancaster, W.D., Theilen, G.H. and Olson, C. (1979). Hybridisation of bovine papilloma virus type 1 and type 2 DNA from virus-induced hamster tumours and naturally occurring equine tumours. *Intervirolgy* 11: 227-229. Cited in *Vet. Bull.* (1980) 50 (5). Abstr. 2960.
- Lauder, I.M. (1971). Experimental vaccinia infection of cattle: A comparison with other virus infections of cows' teats. *Vet. Rec.* 89: 671-573.
- Linklater, K.A. and Gillespie, I.D. (1984). Outbreak of psoroptic mange in cattle. *Vet. Rec.* 115: 211-215.
- Liu, W.A. and Wang, X.S. (1982). A survey of bovine besnoitiosis in the Jerem leagul in Inner mongolia. *Chin. J. Vet. Med.* 9 (8): 10-12.
- Madewell, B.R., Munn, R.J., Phillips, L.K. (1984). Ultrastructure of canine, feline and bovine mast cell neoplasms. *Am. J. Vet. Res.* 45: 2066-2070.

- Mangkoewidjojo, S., Sleight, S.D., Convey, E.M. (1980). Pathologic features of iodide toxicosis in calves. *Am. J. Vet. Res.* 41(7): 1057-1060.
- Maradwar, S.S., Bhagwat, S.S., Narkhede, M.D. (1978). Melanomas in bullocks. *Indian Vet. J.* 55: 667-668.
- Magsood, M. (1958). Generalized Buffaloe Pox. *Vet. Rec.* 70: 321-322.
- Mbassa, G. (1985). Diffuse gangrene of the hind limb associated with umbelicus infection in a calf. *Vet. Rec.* 116: 662.
- Mbuthia, P.G. Ngatia, T.a. and Wamukoya, J.P. (1993). Occurrence of bovine skin diseases in Kenya. *Bull. Anim. Hlth. Prod. Africa.* 41 (4): 311-316. Cited in *Vet. Bull.* (1994) 64. Abstr. 6392.
- Meischke, H.R.C. (1979). A study of bovine teat papillomatosis. *Vet. Rec.* 104: 28-32.
- Menon, P.B. (1953). Seasonal incidence of arthropodes of veterinary importance at Izathnagar - Bareilly, UP. M.Sc. thesis submitted to the University of Madras.
- Miller, J.M. (1980). Bovine lymphosarcoma. *Mod. Vet. Pract.* 61: 588-592.
- Mills, C.F. (1976). Zinc deficiency and the zinc requirements of calves and lambs. *Br. J. Nutrit.* 21: 751-754. Cited by Scott, D.W. (1988).
- Misra, S.S. (1981). Interdigital myxoma in a Haryana cow. *Vet. Med. Small Anim. Clin.* 76: 381-383.

- Mitchell, C.A. (1928). Bovine subcutaneous tuberculosis. *J. Am. Vet. Med. Assoc.* 73: 493-496.
- Mohan, M.C. (1979). Studies on lice infesting domestic animals and birds. M.V.Sc. thesis, Department of parasitology, College of Veterinary and Animal Sciences, Mannuthy, Trichur. pp.65.
- Morrow, A.N. and Compton, E.A.E. (1991). Occurrence of streptothricosis and its association with *Amblyomma variegatum* in St. Lucia. *J. Vet. Med. Series B.* 38(8): 635-638.
- Mohiyuddeen, S. and Rao, N.S.K. (1958). AN epidemic of cutaneous anthrax among bovines in North Kanara District. *Indian Vet. J.* 35: 55-57.
- Moulton, J.E. (1978). *Tumours in domestic animals*. Berkeley, University of California Press, London.
- Mullenax, C.H. (1957). A dietary cause of hair loss in Bahamian livestock. *J. Am. Vet. Med. Assoc.* 131: 302-306.
- Murray, M. (1968). Neoplasms of domestic animals in East Africa. *Br. Vet. J.* 124: 514-516.
- Murray, M.D. (1976). Demodeotic mange of cattle. *Aust. Vet. J.* 52: 49-50.
- Nagington, J., Lauder, I.M. and Smith, J.S. (1967). Bovine popular stomatitis pseudocowpox and milkers' nodules. *Vet. Rec.* 81: 306-313.

- Naik, S.N. (1969). Epidemiology of horn cancer in Indian Zebu cattle breed incidence. *Br. Vet. J.* 125: 222-225.
- Naik, S.M. and Randelia, H.P. (1978). Carcinoma of the horn in Indian cattle an epidemiological aspect. *Indian J. Cancer.* 15: 28
- Nair, K.P.C. and Sastry, G.A. (1954). A survey of neoplasia in the Madras state (bovine) *Indian Vet. J.* 30: 325-328.
- Nicholls, T.J. and Rubira, R.J. (1981). Staphylococcal dermatitis and mastitis. *Aust. Vet. J.* 57: 54.
- O'connor, P.J. (1972). On the association between salmonellosis and the occurrence of ostcomyclitis and terminal dry gangrene in calves. *Vet. Rec.* 90: 459-462.
- Odaye, O.O. (1971). Stephernofilarial dermatitis in cattle of Nigeria. *J. Comp. Path.* 81: 581-583.
- Otteley, M.L. and Moorhouse, D.E. (1978). Bovine onchocerciasis. Aspects of carcass infection. *Aust. Vet. J.* 54: 528.
- Otteley, M.L. (1980). Biology of onchocerciasis in Australia, Ph.D. thesis, University of Queensland Brisbane Australia.
- Padawer, J. (1959). A stain for mast celss and its application in various vertebrates and in a mastocytoma. *J. Histochem. Cytochem.* 7: 352-353.

- Pal, M. (1989). Clinical and microbiological studies of *Dermatophilus congolensis* infection in cattle. *Acta Vet. hung.* 37(3): 197-199. Cited in *Vet. Bull.* (1990) 60. Abstr. 4544.
- Parihar, N.S., Charan, K. and Bhargave, A.K. (1977). Cutaneous actinobasillosis in a bull. *Indian Vet. J.* 54: 431-432.
- Patnaik, B. and Roy, S.P. (1968). Studies on stephanofilariasis in Orissa. II. Dermatitis due to *S. assamensis* Pande, 1936 in the Murrah buffalo and betal buck with remarks on the morphology of the parasite. *Indian J. Vet. Sci. Anim. Husb.* 38: 455.
- Pianta, C. (1987). Bovine dermatophilosis in the State of Rio Grande do Sul. *Boletim do Instituto de pesquisas Veterinarias "Desiderio Finamer"* 10: 23-27. Cited in *Vet. Bull.* (1989) 59. Abstr. 3927.
- Platzen, R. (1988). Studies on the occurrence, frequency and causes of skin lesions in slaughter cattle and the resulting damage to hides and leather at the sluttgart abbatoir. Thesis Justus-Liebig-Universitat Giessen, German Federal Republic. pp. 88. Cited in *Vet. Bull.* (1989) 59 (2). Abstr. 974.
- Prasad, M.C. and Nair, C.K.P. (1972). A survey of lymphoid neoplasm in cattle in Tamil Nadu. *Indian J. Anim. Sci.* 41: 33-36.
- Purchase, H.S. (1944). Out break of ulcerative lymphangitis in cattle caused by *Corynebacterium ovis* J. *Comp. Pathol. Ther.* 54: 238. Cited by Scott, D.W. (1988).

- Rajan, A., Nair, M.K., Alikutty, K.M. and Valsala, K.V. (1977). Pathology of necrosis of extrimitics in bovines. A disease resembling Degnalo disease. *Kerala J. Vet. Sci.* 8: 77-86.
- Rajan, A., Varghese, K., Sreekumaran, T., Valsala, K.V., Gangadhiaran, B. and Manomohan, C.B. (1990). Prevalence and pathology of a syndrome resembling Lumpy skin disease in cattle in Kerala. *J. Vet. Anim. Sci.* 21(2): 61-66.
- Rajan, A., Vikram, M.V. and Sreekumaran, T. (1982). Evaluation of the cell-mediated immune response in goats employing BCG. *Kerala J. Vet. Sci.* 13(1): 99-106.
- Rajmohan, K. (1980). Studies on common ticks affecting livestock in Kerala. Ph.D. thesis submitted to Department of Parasitology, College of Veterinary and Animal Sciences, Mannuthy, Trichur. pp.124.
- Ramkumar, V. (1978). Resection of the anterior nares in a bullock. *Indian Vet. J.* 55: 583-584.
- Rebhun, W.C., Richard, M.P., King, J.M., Wolfe, M. and Begg, S.N. (1980). Interdigital papillomatosis in dairy cattle. *J. Am. Vet. Med. Assoc.* 177(5): 437-438.
- Reddy, M.V. and Rajan, A. (1984). An assessment of the cell-mediated immunity in cattle bearing carcinoma of the mucosa of the ethmoid employing 2-4 Dinitrochlorobenzene and phytohaemagglutinin. *Indian Vet. J.* 61(7): 549-554.

- Reddi, M.V., Rajan, A. and Sulochana, S. (1981). Evaluation of the cell-mediated immune response in cattle induced by Dinitrochlorobenzene. *Vet. immunol. immuno. pathol.* 2: 483-489.
- Reddy, J.N.R., Chandrashekar, V. Jayanath, M.S. Placid E.D. Souza, Madhavarao, P. (1992). Generalized chorioretinitis in a cow a case report. *Indian Vet. J.* 69(6): 547-549.
- Richardson, A. (1972). Osteomyelitis in calves caused by *Salmonella dublin*. *Vet. Rec.* 90: 410-413.
- Rosenthal, S.R.C. (1957). BCG vaccination against tuberculosis. Little Brown, Boston, Massachusetts (1957). Cited by Baldwin and Pimm, M.V.
- Rothwell, T.L.W., Windon, R.G., Horsburgh, B.A. and Davies, H.I. (1991). Some cutaneous responses to mitogen injection in sheep with special reference to eosinophil leucocytes. *Res. Vet. Sci.* 51: 44-47.
- Scott, D.W. (1988). *Large animal dermatology*, WB Saunders Company, Washington, Philadelphia. 1st Ed.
- Sharma, D.R., Kwatra, M.S. and Jand, S.K. (1991). An outbreak of dermatophytosis (ring worm) in buffaloe calves. *Indian Vet. J.* 68(12): 1173-1174.
- Sharma, D.R., Kwatra, M.S., Sunani, S.S., Dhillon, S., Gill, B.S. and Singh, J. (1992). Epidemiological studies on dermatophilosis outbreak in Punjab. *Indian J. Comp. Immunol. infect. dis.* 13 (1): 5-9.

- Sartin, E.A., Doran, S.E., Tennyson, G.S., DAndrae, G., Whitley, R.D. and Collins, F.S. (1994). Characterization of naturally occurring cutaneous neurofibromatosis in Holstein cattle. *Br. Vet. J.* **145**: 1116-1174.
- Sellers, K.C. (1956). Preliminary observations on natural and experimental ring worm in cattle. *Vet. Rec.* **68**: 729-732.
- Simon, J. and Brewer, R.L. (1963). Multiple neurofibromas in a cow and calf. *J. Am. Vet. Med. Assoc.* **142**(10): 1102-1104.
- Sivadas, C.G., Nair, M., Krishnan and Rajan, A. (1971). Congenital melenoma in a calf: A review and a case report. *Br. Vet. J.* **127**: 289-292.
- Slingenbergh, J., Mohammed, A.N. and Bida, S.A. (1980). Studies on bovine demediosis in Northern Nigeria specification and host parasite relationship. *Tijdschr. Diergeneesk.* **2** (2): 90-94. Cited in *Vet. Bull.* (1980) **50**. Abstr. 5810.
- Soulsby, E.J.L. (1982). *Helminths, arthropods and protozoa of domesticated animals VII*, London, Bailliere Tindall.
- Sreekumaran, T. (1980). Pathology of the neoplasm involving the paranasal sinuses in bovines. Ph.D. thesis, Kerala Agricultural University. pp. 54-59.

- Srivastava, H.D. (1939). Cutaneous microfilariasis in Indian cattle (Priliminary report). *Indian J. Vet. Sci. Anim. Hus.* 9: 389-391.
- Stromberg, P.C., Fisher, W.F., Guillot, F.S., Pruett, J.H., Price, R.E. and Grun, R.A. (1986). Systemic pathologic responses in experimental *Psoroptes ovis* infestation of Hereford calves. *Am. J. Vet. Res.* 47: 1326-1329.
- Udayasankar, D. (1986). Clinico-biochemical and theraputic studies on panters. M.V.Sc. thesis, Andra Pradesh Agricultural University, Hyderabad.
- Valentine, A., Glaser, B., Matthes, H.F. (1991). Pathology of hair follicle lesion in the nodular form of demodetic mange in cattle. *Moratshefte far Veterinarmedizin* 46(3): 82-85. Cited in *Vet. Bull.* (1991) 61 (8). Abstr. 5757.
- Valsala, K.V. and Bhaskaran, R. (1975). Melenoma in a bullock. *Kerala J. Vet. Sci.* 4(1): 48-50.
- Vaidyanath, S.N. (1952). A case of acute lymphocytic leukemia in a bullock. *Indian Vet. J.* 28: 351-352.
- Vijayasarithi, S.K., Mohiyudeen, S. and Seshadri, S.J. (1976). Histopathological studies of bovine neoplasms. *Indian J. Vet. Path.* 1: 23-26.
- William, B.J., Kirubaharan, J.J., Uthuman, K.M., Kumaran, K. and Balachandran, S. (1992). Survey of incidence and complications of cutaneous papillomatosis. *Indian Vet. J.* 69(9): 843-844.

- Williams, M., Shaffer, S.R., Garner, G.B. and Yates, S.G. (1975). Induction of fescue foot syndrome in cattle by fractionated extracts of toxic fescue hay. *Am. J. Vet. Res.* **36** (9): 1353-1357.
- Wiseman, M., Breeze, R.G. and Pirie, N.M. (1977). Melanotic neuro-ectodermal tumor of infancy (melanotic progonoma) in two calves. *Vet. Rec.* **101** (13): 264-266.
- Wolter, R. (1980). Aetiological hypothesis for a new syndrome of dairy cows pruriginous dermatitis *Bulletin Mensuel de la Societe Veterinaire Pratique de France.* **64** (4): 333-335. Cited in *Vet. Bull.* (1981) 51. Abstr. 740.
- Wyllie, T.D. and Morchouse, L.G. (1978). *Mycotoxic Fungi, Mycotoxins and Mycotoxicosis II*, New York, Marcel Dekker, Inc.
- Xavier, C.J. (1989). Prevalance and pathology of necrosis of extrimitics in cattle, M.V.Sc. Thesis submitted Centre of Excellence in Pathology, College of Veterinary and Animal Sciences.
- Yeruham, I. and Braverman, Y. (1993). Field observation in Israel on hypersensitivity in cattle by culicoides. *Aust. Vet. J.* **41**: 1537. Cited in *Vet. Bull.* (1994) **84**. Abstr. 4871.

Yeruham, I., Perls, S., Yacobson, S., ben-yosef, H. and Lampert, M. (1993). Skin tumors in cattle following tattooing by liquid nitrogen. *Israel J. Vet. Med.* 43 (1): 38-40. Cited in *Vet. Bull.* (1994) 64. Abstr. 369.

Yilma, T. (1980). Morphogenesis of vesiculation in foot and mouth disease. *Am. J. Vet. Res.* 41: 1537-1539.

Zwahlen, R.D., Tontis, A. and Schneider, A. (1989). Cutaneous lymphosarcoma of helper/inducer T-cell origin in a calf. *Vet. Path.* 26 (6): 504-508.

15485

PREVALENCE AND PATHOLOGY OF DERMATOLOGICAL DISORDERS IN CATTLE

By
R. ANILKUMAR

ABSTRACT OF A THESIS


Submitted in partial fulfilment of the
requirement for the degree

Master of Veterinary Science

Faculty of Veterinary and Animal Sciences
KERALA AGRICULTURAL UNIVERSITY

Centre of Excellence in Pathology
COLLEGE OF VETERINARY AND ANIMAL SCIENCES
MANNUTHY - THRISSUR

1996



ABSTRACT

A study was undertaken to assess the prevalence and pathology of dermatological disorders encountered in cattle in Kerala.

To study the prevalence of various types of skin disorders data were collected from the Disease Surveillance Report published by the Directorate of Animal Husbandry during the period 1989-1993. The various skin disorders encountered according to this data were tail necrosis (1.44 per cent), cutaneous mycosis (10.58 per cent), Eczematosis (6.09 per cent), pox (4.75 per cent), tick infestation (37.22 per cent), lice infestation (25.72 per cent), mangy dermatitis (13.82 per cent), wart (0.36 per cent). In this study tick infestation was found to be highly prevalent.

During the course of this investigation skin biopsies collected from 97 cattle were subjected to detailed gross and histopathological examination. They were classified as Cutaneous ulceration (22.68 per cent), Fly bite dermatitis (15.46 per cent), Decubitus ulcers (12.47 per cent), Hyperkeratosis (9.3 per cent), Papillomatosis (9.27 per cent), Hypertrichosis (8.25 per cent), Ectoparasitic injury (6.19 per cent), Teat lesions (6.19 per cent), Fibroma (2.07 per cent), Dermatophilosis (1.03 per cent), Squamous cell carcinoma (1.03 per cent), and Fibrosarcoma (1.03 per cent).

Cutaneous ulceration was the most common disorder encountered and Biopsies revealed epidermal lysis.

In fifteen animals, fly bite dermatitis was noticed with greyish white necrotic papules and wheals on the neck, shoulder, ears and around eyes. Perivascular changes were seen microscopically.

Nine cases of hyperkeratosis were studied which may be associated with hypovitaminosis A.

Udder and teat papillomatosis was encountered in nine animals with ballooning degeneration and clumping of keratohyalin granules microscopically.

Eight crossbred cattle recovered from the foot and mouth disease had hypertrichosis. Hair coat was shaggy and wavy.

Ectoparasitic injury was encountered in cattle mainly due *Boophilus* infestation.

Teat lesions encountered were mainly due to traumatic injury and chapping.

Two cases of fibroma and one case of fibrosarcoma were encountered on the teat of cattle.

A growth on the vulval region was diagnosed as squamous cell carcinoma.

An experimental study on the cutaneous hypersensitivity reaction in cattle to PHA, 2,4-DNCB and BCG was carried out. Mast cell response to these mitogens was also studied.

Effect of Agropesticides Furadan and BHC on local application on the skin of calves were studied. Dermatitis was the characteristic response. The need for taking care to avoid pesticide contamination on the skin of animals was stressed.