

SURGICAL CORRECTION OF EVERTED MEMBRANA NICTITANS IN THROUGH ANTERIOR CONJUNCTIVAL APPROACH IN A DOG

C. Ramani¹, Sooryadas, S.², Rajib Das³ and R. Suresh Kumar⁴,

Dept. of Veterinary Surgery and Radiology, Madras Veterinary College, Chennai – 7.

Eversion of the membrana nictitans was recorded commonly in large breeds of dogs (Gelatt, 1970; Gelatt, 1972 and Martin, 1970). It was attributed to result from a more rapid growth of the posterior portion of the cartilage compared with that of the anterior portion (Martin, 1970) or due to prominence of the nictitans and adherent conjunctival surfaces (Gelatt and Gelatt, 1994). The everted cartilage appeared as an anterior folding of the leading edge of the nictitating membrane with exposure of the posterior aspect. Standard surgical method for the correction of the condition is to remove the scrolled portion of the cartilage from the posterior side while the anterior conjunctival surface, the leading margin, and the gland were left intact (Moore, 1993). In this report a case of successful surgical correction of everted membrana nictitans in seven-month-old Labrador Retriever, through an anterior conjunctival approach is recorded.

A four-and-a-half month old Labrador was presented to the Small Animal Ophthalmology Unit of Madras Veterinary College Teaching Hospital with a raised pink deformity on the medial canthus of the right eye, which upon closer examination revealed curled nictitans (Fig. 1). The posterior leading margin was exposed and the posterior conjunctiva was inflamed. The condition was present since two weeks. The physiological and the blood biochemical parameters were normal. Since the bulbar-side-conjunctiva was severely inflamed, surgical

correction through the palpebral side conjunctiva was resorted to.

After induction of general anaesthesia, with Propofol @ 5 mg/kg body weight and maintenance with 1.5% Isoflurane, the corneal and conjunctival surfaces of the right eye were carefully cleaned with sterile cotton-tipped applicator and the area irrigated with 0.5% povidone iodine solution. After draping, the third eyelid margin was stabilised using two stay sutures around the short arm of the T-cartilage, and the membrana nictitans was gently spread to expose the anterior conjunctiva. A small linear incision, parallel to the long arm of the T-cartilage, was then made through the conjunctiva. The conjunctiva was tunelled using a small tissue scissors, to free it from the cartilage and expose its surface. The long arm of the cartilage was bluntly dissected from the posterior third-eyelid conjunctiva and resected by incising near its base and at the junction with its wings. Care was taken to remove only the bent portion of the long arm of the T-cartilage. The incised conjunctiva was not sutured, and left to heal by second intention. After surgery, the stay sutures were removed and the membrana nictitans was allowed to take up its normal position. Post-operatively, Flurbiprofen (PENFEN, Hicare Pharma Ltd., Chennai) and Moxifloxacin (HIMOX, Hicare Pharma Ltd., Chennai) eyedrops were administered topically, one drop each, thrice daily for one week. The case was re-evaluated on the third post-operative day. The membrana nictitans had re-established its normal position and conformed to the corneal curvature, but

1. Associate Professor 2. Ph.D.Scholar 3. P.G. Scholar 4. Professor & Head

there was mild hyperaemia of the anterior conjunctiva (Fig. 2). Recovery was uneventful with no loss of function.

Eversion of the membrana nictitans usually occurred in dogs during the first year of age and usually presented unilaterally (Gelatt and Gelatt, 1994), as noticed in this case. The defect affected the upper portion of the stem of the T-cartilage resulting in a U-shaped abnormality that reflected forward the leading margin of the nictitans, exposing the conjunctiva on the bulbar side, resulting in secondary chronic conjunctivitis and epiphora. Epiphora was not noticed in this case, but the conjunctiva on the bulbar side was severely inflamed. It has been suggested that any surgical procedure should seek to conserve, or restore, the normal anatomical relationship between the membrana nictitans and the cornea (Crispin, 1986). It was reported that the dissection for approaching the kinked cartilage should not involve the outer surface of the membrana nictitans (Crispin, 1991 and Moore, 1993). But in the present case, the anterior conjunctival approach

was selected because the conjunctiva on the bulbar side was severely inflamed. The result was highly satisfactory. Surgical removal of the curved portion of the T-cartilage through the palpebral side conjunctiva with highly satisfactory results in 10 cases of eversion/inversion, had earlier been reported (Stades, 1976).

It was concluded that the palpebral side conjunctival approach provided excellent result comparable to that of the bulbar side conjunctival approach with two advantages namely - the already inflamed bulbar side conjunctiva can be spared from incision, dissection and further trauma; and, the scar tissue arising out of the second intention healing of the dissected conjunctiva can be confined away from the cornea, which may otherwise rub on to the cornea and cause a mild keratitis.

Fig.1
Everted Membrana Nictitans

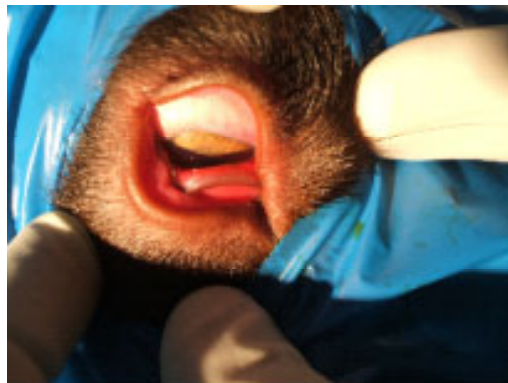
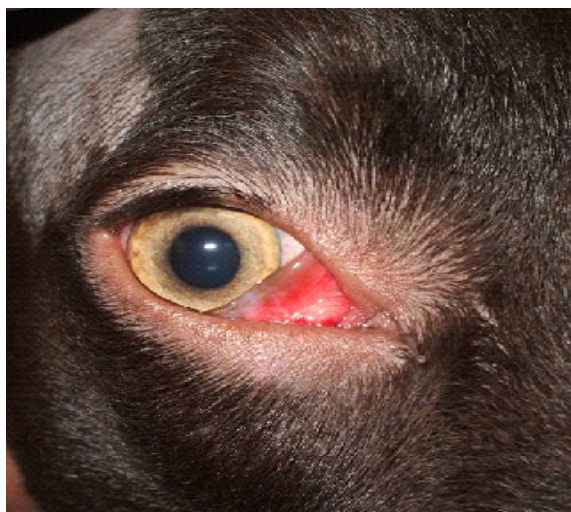


Fig.2

Third Post-op Day



REFERENCES

- Crispin, S. (1986). Treating the everted membrane nictitans in the dog. *In Pract.* 8(2):66-67.
- Gelatt, K.N. (1970). Eversion of the nictitating membranes. *Vet. Med. Small Anim. Clin.* 65:674-675.
- Gelatt, K.N. (1972). Surgical correction of everted nictitating membrane in the dog. *Vet. Med. Small Anim. Clin.* 67:291-292.
- Gelatt, K.N. and Gelatt, J.P. (1994). Surgery of the Nictitating Membrane In: *Handbook of Small Animal Ophthalmic Surgery*, 1st ed., Vol. 1 – Extraocular Procedures, Elsevier, pp. 146-148.
- Martin, C.L. (1970). Everted membrana nictitans in German Short-haired Pointers. *J. Am. Vet. Med. Assoc.* 157:1229-1232.
- Moore, C.P. (1993). Third Eyelid In: *Textbook of Small Animal Surgery*, 2nd ed., Vol. 2, Slatter, D. (Ed.), W.B. Saunders Company, p. 1195.
- Stades, F.C. (1976). Modified surgical treatment of eversion and inversion of the third eyelid in dogs (author's translation). *Tijdschr Diergeneeskd.* 101(19):1079-83.