

7 3 4 0



**“CLINICAL STUDIES ON ETIOPATHOLOGY AND MEDICO-SURGICAL MANAGEMENT OF RECURRENT GENITAL PROLAPSE IN COWS”**

**A  
THESIS  
SUBMITTED TO THE  
ANAND AGRICULTURAL UNIVERSITY  
IN THE PARTIAL FULFILMENT OF THE REQUIREMENTS  
FOR THE AWARD OF THE DEGREE**

**OF**

***Doctor of Philosophy***

**IN**

**VETERINARY SURGERY**

**BY**

**BADGUJAR CHANDRAVADAN LAXMAN**

**M.V.Sc.**

**(Reg. No. 04-0599-2007)**

**DEPARTMENT OF VETERINARY SURGERY AND RADIOLOGY  
COLLEGE OF VETERINARY SCIENCE & ANIMAL HUSBANDRY  
ANAND AGRICULTURAL UNIVERSITY  
ANAND - 388 001  
(GUJARAT)**

**2011**

7340 - 4

*Dedicated*  
*To*  
*Cows*

7340



**Dr. P.H. Tank**

Professor of Surgery,  
Department of Veterinary Surgery and Radiology,  
College of Veterinary Science and Animal Husbandry,  
Anand Agricultural University,  
Anand- 388 001

## CERTIFICATE

*This is to certify that the thesis entitled "CLINICAL STUDIES ON ETIOPATHOLOGY AND MEDICO-SURGICAL MANAGEMENT OF RECURRENT GENITAL PROLAPSE IN COWS" submitted by BADGUJAR CHANDRAVADAN LAXMAN (Reg. No. 04-0599-2007) in partial fulfillment of the requirements for the award of the degree of DOCTOR OF PHILOSOPHY in the subject of VETERINARY SURGERY of the Anand Agricultural University is record of bonafide research work carried out by him under my guidance and supervision and the thesis has not previously formed the basis for the award of any degree, diploma or other similar title.*

Place: Anand

Date <sup>27</sup> / 07 / 2011

(Dr. P.H. Tank)

Major Advisor

**Professor of Surgery**

Department of Surgery & Radiology  
Veterinary College, A. A. U., ANAND



## CERTIFICATE

*This is to certify that I have no objection for supplying to any scientist only one copy of any part of this thesis at a time through reprographic process, if necessary, for rendering reference service in a library or documentation center.*

Place: Anand  
Date ~~21~~ / 07 / 2011

*Badgujar C.L.*

(Badgujar C.L.)

*Anand*

(Dr. P. H. Tank)

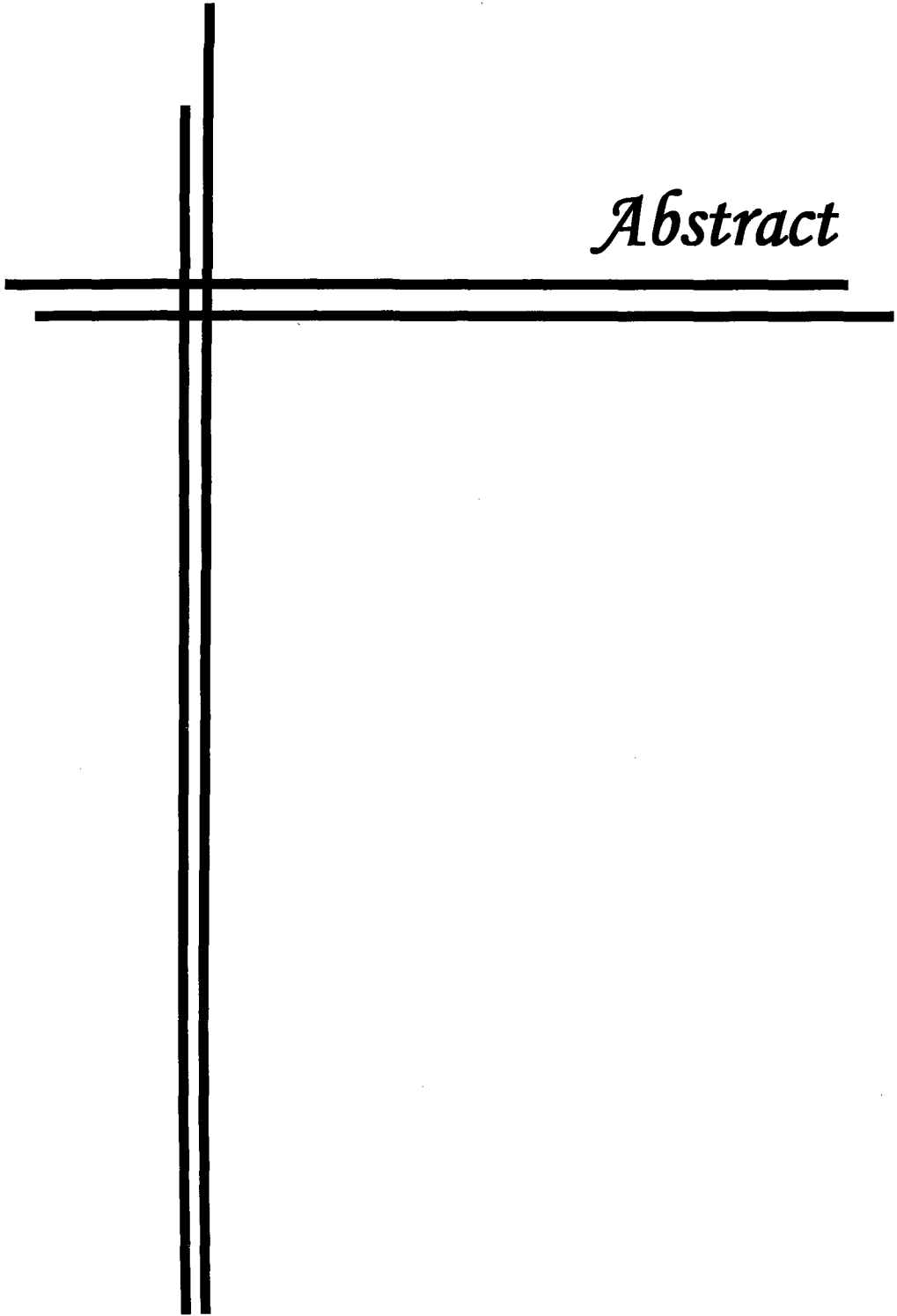
Major Advisor

**Professor of Surgery**

Department of Surgery & Radiology  
Veterinary College, A. A. U., ANAND



*Abstract*





## ABSTRACT

### CLINICAL STUDIES ON ETIOPATHOLOGY AND MEDICO-SURGICAL MANAGEMENT OF RECURRENT GENITAL PROLAPSE IN COWS

Name of Student:  
C.L.BADGUJAR

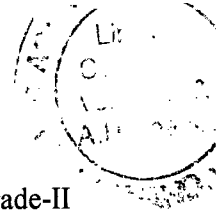
Major Advisor:  
Dr. P.H.TANK

Department of Veterinary Surgery and Radiology  
College of Veterinary Science and Animal Husbandry  
Anand Agricultural University  
ANAND-388001

---

Incidences of periparturient cervico-vaginal prolapse (CVP) have been recorded in dairy cows all over the world by many workers. However, rarely there has been a mention of cases of chronic prolapse occurring beyond three months of parturition. On the contrary, it was experienced to be occurring in high number in the Gaushalas and Panjarapoles of Gujarat. A majority of the affected cows were from Gir or Kankrej breeds and their crosses. They had suffered repeated episodes of the problem. Conventional methods of treatment were unsuccessful to address this problem. Hence, a clinical study was undertaken to evaluate various aspects of CVP including medico-surgical management by different approaches in 46 cows of Gaushalas and Panjarapoles in Saurashtra region of Gujarat.

A novel method of 100 point score for each character was evolved to assess the health of cow and severity of prolapse. The cows that fell in the range of aggregate points between 0-25, were graded as Grade-I; between 26-50, graded as Grade-II; between 51-75, graded as Grade-III, and cows with score from 75-100, were graded as Grade-IV.




None of the cases under study fall in the Grade I category. The cases of Grade-II were subjected to surgical treatment utilizing Technique No. 1 (Fixation to prepubic tendon) or No. 2 (Button suture fixation). Cases falling under the Grade-III were treated with the use of surgical Technique No. 3 (Amputation of prolapsed mass) or No. 4 (Submucosal resection of vagina). In cases of Grade-III, the cows that had irreducible adhesions of the prolapsed mass or abnormalities of os cervix in the form of kinked, hardened, fibrosed or extensive enlarged cervix were subjected to Technique No. 3 (Amputation of prolapsed mass). Cases of Grade-III that had less changes of the os cervix as mentioned but had more of vaginal proliferation and fibrosis were subjected to Technique No. 4 (Submucosal resection of vagina). The cases of Grade-IV were put to treatment by Technique No. 5 (Pervaginum Panhysterectomy). These cases were advanced, unmanageable, highly suffering and with non-viable appearance of prolapse. Those cows which showed ovarian abnormalities were subjected to Technique No. 6 (Pervaginum Bilateral ovariectomy). They came in Grade II prolapse. After supportive therapy, anaesthesia was performed in the form of caudal epidural analgesia and pudendal nerve block under xylazine sedation. Appropriate surgical treatment was applied to each cow.

The 46 affected cows were grouped as per the surgical technique provided from Group I to VI. In Group I to V, eight cases were operated, while in Group VI, six cases were operated. In addition to this, blood and serum samples were collected for comparison, from eight healthy lactating normal cows as a control group.

For fixation of vagina to prepubic tendon, insertion of the needle in the prepubic tendon required lot of skill to retrieve the needle back between the main and lateral branch of the prepubic tendon. Although this technique appeared very promising, the entire procedure was to be performed blindly only by palpation in the cul-de-sac of

vagina. In view of a limited bite in the vaginal floor and the prepubic tendon, the chances of rupture of the suture or the tearing of the vaginal wall could not be overlooked. Considering the complexity in execution, this technique is recommended only in the hands of an experienced worker. Button suture fixation was used on 8 cows. Commercially available suture needle (triangular and straight needle No.1) worked satisfactorily to put these sutures. Since the vaginal insertion of the suture was preplaced on the prolapsed mass, there was adequate visibility and a very little haemorrhage occurred in the placement of the suture. Amputation of prolapsed mass was easy in this technique as the entire mass was presented at the vulva for handling. However, due to the large size and irreparable changes in the vagina and the cervix, the wall of the organ was considerably thick making it difficult to cut. Submucosal resection of vagina was fairly simple than amputation. As the surgical dissection was restricted only to the submucosa of the exposed portion, haemorrhage from the dissection was comparatively less. Since the technique did not involve extensive dissection or ligation of blood vessels, the procedure could be completed in comparatively lesser time. In cases of per vaginum panhysterectomy, the dorsal wall of the vagina bled considerably. Further dissection for the uterine junction and ovarian stumps had to be done blindly by palpation with fingers. It was felt necessary to put two ligatures on the stump to ensure complete obliteration of the ovarian blood vessels. After having completed this procedure, small length of vagina was left behind so that there was no chance of recurrence of prolapse. Per vaginum bilateral ovariectomy was performed in the similar manner as in pervaginum panhysterectomy. The uterus and cervix were left intact. For performing the ovariectomy, a specially designed Richards' ovariectome was used to crush the ovarian




blood vessels and to cut the pedicle. Suturing of the vaginal incision (colpotomy) did not pose major problem and the entire surgery could be completed in 20 to 30 minutes.

In Group I and II, recurrence of prolapse was noted in one cow each due to rupture of sutures. In one more case of group II, pyometra was noted due to foreign body i.e. buttons. In Group III, all the animals showed mild to moderate bleeding from vagina and mild straining. This was treated by local infusion of Betadine solution and application of Ceftriaxone powder. This bleeding disappeared towards 7-8 days and effectively stopped at 10 days. One cow showed recurrence of prolapse. In Group IV, minor haemorrhage through vagina was noted in all the cases for 1 or 2 post-operative days. All the animals recovered uneventfully, except one cow that suffered prolapse at 24<sup>th</sup> post-operative day. In Group V, all the animals, except one cow, showed slight haemorrhage for a period of 3 to 4 days followed by slight mucous discharge for next 3 to 4 days, but recovered uneventfully by 15 days.

Prepubic tendon fixation and Button suture fixation were performed in those cows where the prolapse was mild to moderate type (Grade II) with no complications like oedema, necrosis, gangrene and other secondary complications like maggots infestation. As such these two techniques were useful in conserving the genitalia. However, button suture fixation method was preferred to address the clinical condition.

Two cows treated with button fixation technique conceived subsequently. Thus, these animals would have become useful for reproduction in future. Submucosal resection was comparatively easier to perform and resulted into less serious haemorrhage.

In those cases where the changes in the prolapsed organ appeared irreversible, it was decided to remove entire reproductive tract per vaginum (Panhysterectomy). This



surgical technique also was quite demanding owing to large number of engorged blood vessels in the dissection.

Per vaginum bilateral ovariectomy was reserved for those cases where ovarian changes were marked. It was postulated that the prolapse was primarily due to ovarian dysfunction. This was proved when the ovariectomy was performed and the prolapse was repositioned. No recurrence was noted in any of the six cases until eight days. However, this procedure was performed in ox cases and only had moderate Grade II prolapse. Therefore it requires further study.

Haemato-biochemical and serum endocrinological assessment paved a clinical way of understanding the etiopathology, stress and therapeutic resolution of this complex malady in cows by contemplating the findings to the clinical merits of the cases retrospectively.

Various micro organisms were isolated from the vaginal swabs from these cows. Antibiotic sensitivity test indicated that Ceftriaxone and Enrofloxacin were both effective against these organisms while Amoxirum was not as effective. Urinalysis can be used as one indicator to assess pre-operative status and effect of surgical treatment.

Histopathological studies of genital tissue on surgical removal in Group I and II, did not show significant lesions while Group III, IV and V cases revealed, variable degrees of inflammatory lesions, characterized by degeneration, edema necrosis and fibrosis.

Moderate to severe infiltration of mononuclear cells in the vaginal and cervical mucosa were found in groups III and IV. Group V indicated necrosis of superficial mucosal lining with the presence of bacterial colonies. Hyperplasia of glands of vaginal

and cervical mucosa showed neutrophils and mononuclear cells infiltration with cystic dilatation. The group V cases revealed chronic inflammatory changes of adhesions, lacerations, necrosis and perivascular fibrosis, hyperplasia of uterine glands along with congestion and haemorrhage.

The group VI cases, (with abnormalities of ovaries) revealed cystic dilation with fluid filled cavity, with single layered cysts. Few specimens revealed multicystic ovaries which had thick, multilayered wall and cyst within the wall.

The histological signs correlated with the clinical signs and helped in prognosis of repair and cure of the case.



*Acknowledgement*

## ACKNOWLEDGEMENTS

---

On the accomplishment of the present study, I would like to take this opportunity to extend my deepest sense of gratitude and words of appreciation towards those, who helped me during the pursuit of study. I shall ever, remain thankfully indebted to all those learned souls, my present and former teachers, known and unknown hands who directly or indirectly motivated me to achieve my goal and enlightened me with the touch of their knowledge and constant encouragement. I feel this is an extremely significant and joyous opportunity bestowed upon me by the goddess of learning, to think about and thank all those persons.


I heartily thank to **Lord** for being with me, guiding and providing me enough patience and perseverance to successfully complete my thesis work.

At the outset, I take the privilege in expressing my deep sense of gratitude and indebtedness to my Major advisor Dr. P. H. Tank, Professor of Surgery, Department of Veterinary Surgery and Radiology, College of Veterinary Science and Animal Husbandry, AAU, Anand for his valuable and critical suggestions, scientific acumen, perspicacious remarks, scholarly guidance, keen interest, sustain encouragement, excellent co-operation, prudent planning, active persuasion and supervision, which served as a constant source of inspiration throughout the course of my study and research work.

I extend sincere heart felt gratitude to my minor advisor Dr. Y. L Vyas, Professor & Head, Department of Anatomy for valuable guidance and suggestions during the period of study.

I am equally grateful to the members of Advisory Committee Dr. K. S. Prajapati, Dr. A.J. Dhami, Dr. M.K. Jhala, and Dr. N.P. Sarvaiya for their constant spirited guidance, supportive attitude and timely help with professional dexterity during the course of my research programme.

I am highly grateful to Dr. Mayande, Worthy Hon. Vice Chancellor, and Dr. A.T. Sherikar, Ex-Vice Chancellor, Dr. Dandge, Registrar, Dr. L.B. Sarkate, Head, Dept. Surgery and Gynaecology, MAFSU, Dr. **Abdul** Samad, Dean, Veterinary Faculty and Director of Instructions, Dr. R.L. Dhoble, Director of Research, Dr. P.D. Deshpande,



Director of Extension Education, and Dr. A.D. Deshmukh, Asstt. Registrar, MAFSU, Nagpur, and Associate Deans, COVAS, Udgir and BVC, Mumbai for sanctioning Study leave and administrative support.

I am also thankful to Hon. Vice Chancellor, Dean and Directors, and Registrar, Anand Agricultural University, Anand for providing me the opportunity to pursue my higher studies at this premier institute.

I am sincerely indebted to Dr. S.Z. Sharma, Dr. P.L. Dhande, Dr. C.L. Deshmukh and Mr. Shekh, BVC, Mumbai, for moral support.

I am equally grateful to Dr. J. V. Solanki, Principal, College of Veterinary Science and Animal Husbandry, Anand for his generous attitude in providing necessary support in completing my studies and the research work.

I owe special thanks to Dr. A.J. Dhami, Professor & Head, Dept. of ARGO, and I/C, Research Scientist & Head, LRS, College of Veterinary Science and Animal Husbandry, AAU, Anand for his meticulous editing and giving final shape to this manuscript. Dr. C.C. Wakankar, Ex-Professor of Surgery, BVC, Mumbai, and Dr. Nainan Jacob, Ph.D. Scholar, Veterinary College, Anand also deserve special thanks for technical support in writing the manuscript.

I extend sincere heart felt gratitude to Dr. M.G. Maradia, Zoo Superintendent, Rajkot Zoo, Rajkot for time to time help in conducting the operations.

The trustees, Managers and the volunteers of three Gaushalas in Saurashtra, viz., Purushottamlalajibhai Gaushala, Keshod; Bapa Sitaram Gaushala, Gundala, and Gokulesh Gaushala, Junagadh, deserve my lifetime indebtedness. Shri Vinubhai, Jamanbhai, Maheshbhai, Kana, Jitubhai, Ashok, Brahmhat, Odedara and all volunteers of the Gaushala, Keshod; Shri Rajubhai, Soanki Guruji, Praful and all the volunteers of Junagadh Gaushala, and Vipul, Rajubhai, Rajbha, Mahendra, Solanki and all the volunteers of Gondal Gaushala also owe my heartfelt gratitude.

I respectfully acknowledge the untiring help rendered by Dr. Kelawala, Dr. D.B. Patil, Dr. P.V. Parikh and Dr. D.R. Barvaliya, Dept. of Surgery and Radiology; Dr. D.S. Nauriyal, Dept. of Medicine; Dr. M.T. Panchal, Dept. of Gynaecology; Dr. D.M. Bhayani, Dr. K.M. Panchal, Dept. of Anatomy; Dr. D.J. Ghodasara, Dr. C.J. Dave, Dept. of Pathology; Dr. D.N. Rank, Dept. of Animal Genetics and Breeding, and Dr. Ankita

Killedar, RBRU; for providing me ever willing help, guidance, inspiration, sustained encouragement, valuable advice and constructive suggestions for successful completion of my entire studies.


On the way to completion, the friends who have shared the moments of laughter and sorrow can never be forgotten. I am cordially thankful to my friends Dr.(s) Pragnesh, Dhawal Fefar, Vadaliya, Miss Karlet, Mahida, Mehul Dhami, Pranay Roy, Dhamna Patil, Tushar Ahire, Maulik Upadhyay, Mahendra Bagate, Anis Khan, Jana-Dar, Prashant Nikam, Chirag Javia and others for their constant support, inspiration and whole hearted co-operation during my entire course work and research.

Words are just not sufficient to express my feeling for love, affections and encouragement extended by my beloved parents, wife Anita, son Nimish, and daughter Ishwari. They have always been my perennial source of inspiration. Truly they deserve more than a word of thanks, because without their psychological support higher study for me would have remained a mere dream.

Last, but not the least, I thank all those who helped directly or indirectly in completion of this study. My most sincere thanks to the Almighty God, who made everything possible.

Place: Anand

Date: 27/07/2011



(Badgujar C.L.)

## LIST OF TABLES

Table No.	Title	Page No.
1	Scoring system and points used to grade the individual cows with CVP for adopting appropriate medico-surgical management	38
2	Total score points obtained on different characters / factors of CVP by individual cows	41
3	Classification of cases of different grades/groups and surgical techniques and antibiotics used their on	43
4	Mean ( $\pm$ SE) pre-operative and 7 <sup>th</sup> day post-operative haematological profile of cows with cervico-vaginal prolapse	88
5	Mean ( $\pm$ SE) pre-operative and 7 <sup>th</sup> day post-operative differential leucocytes count of cows with cervico-vaginal prolapse	89
6	Comparison of haematological profile of cows with cervico-vaginal prolapse and normal healthy cows (Mean $\pm$ SE)	90
7	Mean ( $\pm$ SE) pre-operative and 7 <sup>th</sup> day post-operative serum biochemical profile of cows with cervico-vaginal prolapse	95
8	Mean ( $\pm$ SE) pre-operative and 7 <sup>th</sup> day post-operative serum hormonal profile of cows with cervico-vaginal prolapse	100
9	Comparison of serum biochemical and hormonal profile of cows with cervico-vaginal prolapse and normal healthy cows (Mean $\pm$ SE)	101
10	Bacterial isolates from the genital swabs and their antibiotics sensitivity pattern in cows with cervico-vaginal prolapse	104
11	Findings of macro- and microscopic examinations of urine of cows with cervico-vaginal prolapse before operation and on 7 <sup>th</sup> day after operation	107

## LIST OF FIGURES

Figure No.	Title	After Page No.
1	Pre- and post-operative haemoglobin concentration (g%) in cows under different groups of medico-surgical management for cervico-vaginal prolapse	88
2	Pre- and post-operative packed cell volume (%) in cows under different groups of medico-surgical management for cervico-vaginal prolapse	88
3	Pre- and post-operative Total erythrocyte counts (million/cmm) in cows under different groups of medico-surgical management for cervico-vaginal prolapse	88
4	Pre- and post-operative Total leucocyte counts (thousand/cmm) in cows under different groups of medico-surgical management for cervico-vaginal prolapse	88
5	Pre- and post-operative serum aspartate aminotransferase (IU/L) in cows under different groups of medico-surgical management for cervico-vaginal prolapse	95
6	Pre- and post-operative serum alanine aminotransferase (IU/L) in cows under different groups of medico-surgical management for cervico-vaginal prolapse	95
7	Pre- and post-operative serum calcium (mg/dl) in cows under different groups of medico-surgical management for cervico-vaginal prolapse	95
8	Pre- and post-operative serum inorganic phosphorus (mg/dl) in cows under different groups of medico-surgical management for cervico-vaginal prolapse	95
9	Pre- and post-operative serum progesterone (ng/ml) in cows under different groups of medico-surgical management for cervico-vaginal prolapse	101
10	Pre- and post-operative serum estradiol (pg/ml) in cows under different groups of medico-surgical management for cervico-vaginal prolapse	101
11	Pre- and post-operative serum cortisol (ng/ml) in cows under different groups of medico-surgical management for cervico-vaginal prolapse	101
12	Bacterial isolates from cervico-vaginal swabs for cervico-vaginal prolapse cases	101

## LIST OF PLATES

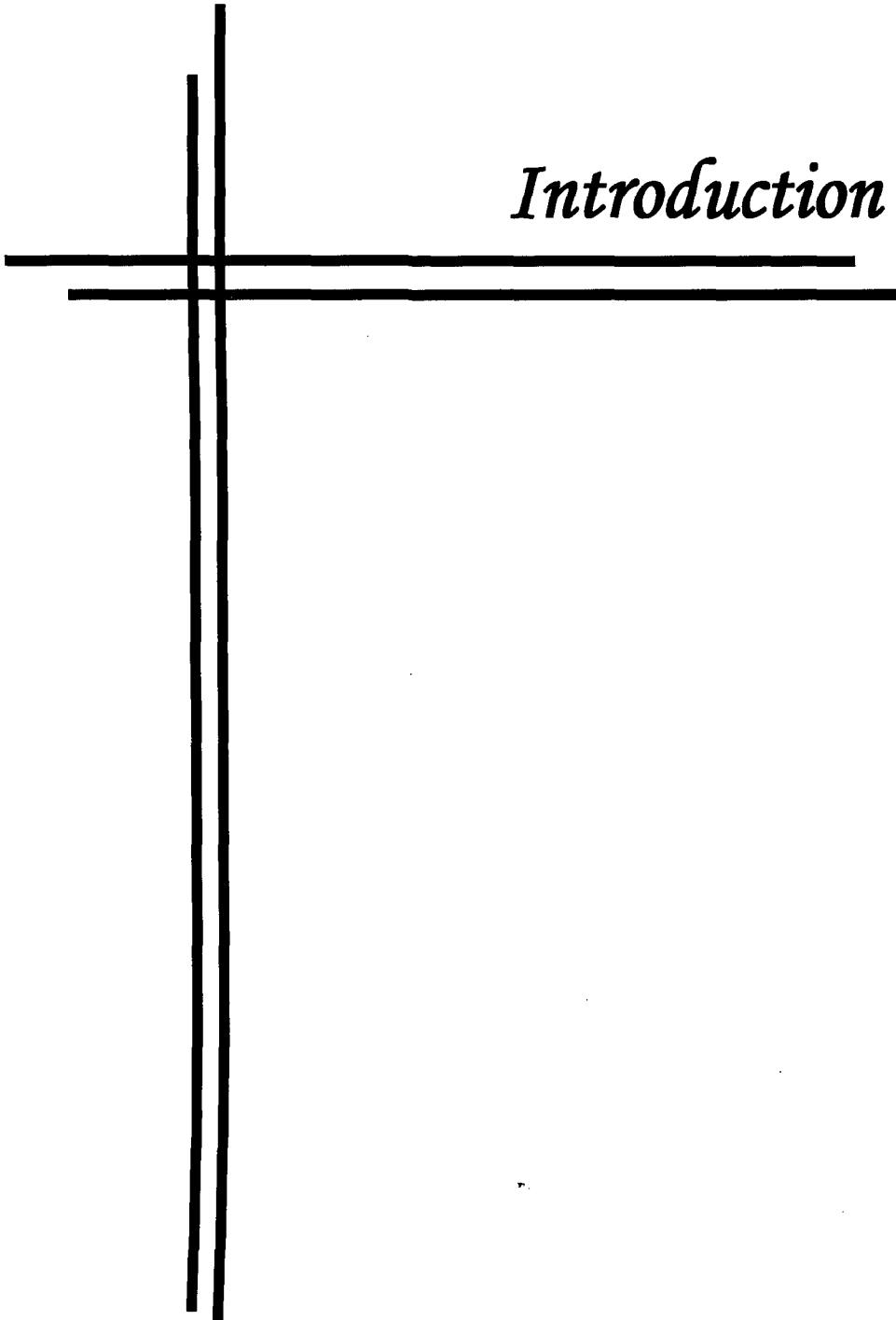
Plate No.	Title	After Page No.
1	Different grades of cervico-vaginal prolapse (Plate 1: A-J)	43
2	Clinical symptoms in cows with CVP (Plate 2: A-D)	43
3	Technique 2: Button suture fixation (Plate 3: A-E)	47
4	Technique 3: Amputation of prolapse (Plate 4: A-D)	48
5	Technique 4 : Submucosal resection of vagina (Plate 5: A-C)	49
6	Technique 5: Pervaginum panhysterectomy (Plate 6: A-I)	50
7	Technique 6: Pervaginum bilateral ovariectomy (Plate 7: A-B)	51
8	Gross changes in ovaries of CVP (Plate 8: A-C)	114
9	Histopathological observations in genitalia of CVP (Plate 9: A-H)	114

# Contents

<b>CHAPTER NO.</b>	<b>TITLE</b>	<b>PAGE NO.</b>
<b>I</b>	<b>INTRODUCTION</b>	<b>1-6</b>
<b>II</b>	<b>REVIEW OF LITERATURE</b>	<b>7-33</b>
<b>III</b>	<b>MATERIALS AND METHODS</b>	<b>34-56</b>
<b>IV</b>	<b>RESULTS AND DISCUSSION</b>	<b>57-114</b>
<b>V</b>	<b>SUMMARY AND CONCLUSIONS</b>	<b>115-124</b>
	<b>REFERENCES</b>	<b>i-xii</b>



*Introduction*



## CHAPTER – I

### INTRODUCTION

---

Cow is the foster mother of mankind and therefore a holistic animal. Human infants start feeding with cow milk. From the ancient times (Vedas and Samrat Ashoka) the value of cows as a means of wealth and prosperity and their importance in human society has been accepted (Shukla, 1972). If these animals suffer from any serious and painful disease, it is a moral duty of a veterinarian to provide a humane treatment to them.

The cow population is large in Gujarat. In addition to cattle owners, cows are also maintained by various non-profitable social trusts and animal welfare organizations. There are hundreds of Gaushalas and Panjarapoles in the Saurashtra region of Gujarat, where the cows are provided shelter.

Veterinary clinical services are being provided by the College on extension basis to animal husbandry sector and Gaushalas in Saurashtra region. While on the extension services, it was found that many cows were suffering from one of the serious ailment of cervico-vaginal prolapse (CVP). A majority of affected cows were from Gir or Kankrej breeds and their crosses.

The CVP is a condition in which the vagina and cervix evert out over the caudal attachment and protrude out from the vulvar commissure with the inside layer out (Whittier, 2007). In one type of prolapse only the vagina and cervix are prolapsed and in another type the uterus is prolapsed (Powell, 2007). Accordingly the prolapse can be called as vaginal prolapse, cervico-vaginal prolapse or uterine prolapse. The prolapse

usually begins with bulging of the floor of vagina, then the lateral walls and a portion of the roof of the vagina bulging through the vulva with the cervix and uterus moving caudal. As per the portion of protrusion from the caudal end, the remaining cranial part get displaced and usually invaginated under the everted layer (Roberts, 1971; Gustafsson *et al.*, 2004).

The cervico-vaginal prolapse occurs in the cows usually during peripartum, occasionally it occurs away from parturition and in nonpregnant cows. The cases of peripartum CVP are mainly related to the causes of gravid uterus, dystocia and retained placenta (Roberts, 1971; Arthur *et al.*, 2001; Youngquist and Threlfall, 2007). The prolapsed genital organs are physiologically enormously enlarged and lead to the lesions of acute inflammatory changes, viz., oedema, congestion, haemorrhage from the wounds and mucus discharge. The cases of CVP at the Gaushalas were away from parturition and they were not directly related to dystocia or retained placenta. The signs observed were depending upon the duration of prolapse. In the chronic cases, the prolapsed mass was severely damaged with lacerations and necrosis. So the conventional treatment of reposition and application of truss or stay sutures on the commissure of vulva would not be sufficient. Obviously some suitable and radical surgical treatment was required to alleviate the pathology and solve the cases of prolapse in this region.

The gravity of the problem lied in the fact that the incidence of CVP cases here was significantly more than that mentioned by the workers abroad (Woodward and Quesenberry, 1956; Arthur *et al.*, 2001; Wolfe and Carson, 2007). In one busy Gaushala, 6 - 8 cases were presented with CVP in a month. After the treatment, 3 - 4 cases recurred second time in the next 20 - 25 days. In spite of the repeated treatment, these cases used to show prolapse repeatedly. Some cases even suffered prolapse phenomenally at the

successive oestrous cycles. Thus, a Gaushala with average strength of 450 - 500 adult cows was happened to be stagnated with 8 - 10 cases of chronic CVP, always.

The treatment was provided on the basis of common principles to the cases of CVP in the Gaushalas. It included antiseptic wash and repositioning of prolapsed mass, application of some means of truss on perineum and commissure of vulva, and administration of streptopenicillin or oxytetracycline and anti-inflammatory drug. In spite of various conventional measures there were recurrence<sup>s</sup> of the prolapse with chronic and aggravated signs at the subsequent episodes, making it highly difficult to manage these cases.

The cows with a tendency of recurrent genital prolapse usually remained infertile and maintenance of such cows was not only uneconomic, but unmanageable for the livestock owners due to the risk of mutilation, spread of diseases and nuisance caused by dirty prolapsed mass. The cows with this intractable syndrome were frequently sent to Panjarapoles and Gaushalas. The cows with vicious cycle of pathology established due to CVP lived a miserable life. The exposed prolapsed mass lead to mutilation by self and other predators as dogs, crow pricking, fly affections and so on. The cows were in an agony of pain, constant irritation, severe discomfort and suffered until death. The disease in cows created very unhygienic and unaesthetic circumstances and became matter of social concern. There was constant demand from veterinary clinicians, livestock owners and persons involved in the management of Gaushalas, Panjarapoles and Animal welfare organizations to provide a practicable solution to this entity. This intrigued to conduct a study on the clinical cases of chronic CVP in Saurashtra region of Gujarat State.

Literature did not reveal much information on the CVP in cows that was not related with parturition. Roberts (1971), Arthur *et al.* (2001), and Youngquist and



Threlfall (2007) have all described the condition of genital prolapse in cattle. They mentioned that the CVP occurred usually during parturition and occasionally away from parturition in cows. They considered both situations analogues and dealt with it in a similar manner. Arthur *et al.* (2001) and Wolfe and Carson (2007) classified the CVP from first to fourth degree according to the duration and severity of the condition. In the present work, classification was attempted by a more precise method depending on both, the inflammatory changes in the prolapsed mass and their effects on the general health of the animal.

Examination of blood was important to assess the systemic or internal changes caused by a disease condition in the animals and to provide supportive medication (Arthur *et al.*, 2001; Gustafsson *et al.*, 2004; Ahmed *et al.*, 2005). Hence, the haematological examination was included in the work.


Hypocalcaemia was considered as one of the factors to interfere with tone of the genital organs leading to genital prolapse (Richardson *et al.*, 1981; Misra, 1998; Youngquist and Threlfall, 2007). Estimation of serum calcium and inorganic phosphorus was necessary to find out their role in the pathophysiology of prolapse. Estimations of aspartate aminotransferase (AST) and alanine aminotransferase (ALT) were essential to know the systemic status of the animal, functioning of the liver, and the hepatic and muscle damage in the toxæmic or septicaemic genital disorders (Chavan and Agrawal, 2006).

Infection by the microorganisms was one of the major causes of any genital disorder and metritis (Patel *et al.*, 2009; Singh *et al.*, 2009). Metritis and genital prolapse were linked together and interfered with fertility and health of the animal. There were reports on the culture and sensitivity test of the cervico-vaginal swab in metritis and

genital disorders but not actually in the condition of prolapse. Moreover, gross and microscopic urine examination is a simple method to evaluate the inflammatory changes in uro-genital system due to dysuria and urine retention (Benjamin, 1978).

Hormones were the substances that governed all the functioning of the genital organs (Hafez and Hafez, 2010). Increased estrogen levels were recognized as a predisposing cause of genital prolapse in cows. Progesterone controlled the variations in the uterus with its rise related to uterine proliferation and decrease to the uterine involution (Woodward and Quesenberry, 1956; Hafez and Hafez, 2010). Plasma cortisol was used to indicate the stress and trauma through which the animal passed during the disease or surgical procedure. Physiological and therapeutic effects of these hormones have been studied extensively in various reproductive disorders including metritis and pyometra, but rarely in the cases of prolapse. Hence, these fundamental aspects were included in the study.

Treatment and repair of individual cases of genital prolapse have been quoted long back. Benesch (1930) used laparotomy approach to correct the prolapse, which required two surgeries. Pierson (1961) used perivulval stay suture technique. Bouckaert *et al.* (1956) and Misra (1998) described the button fixation type sutures through the vaginal roof over the gluteal region. Winkler (1966) advocated cervicopexy through prepubic tendon. These techniques were used mostly in nonrecurrent and peripartum prolapse cases. It was essential to assess their feasibility and utility in chronic recurrent cases in the field. Tank *et al.* (2006) pioneered the technique of pervaginum panhysterectomy to alleviate the root cause and pain in the cases of chronic recurrent prolapse that was virtually a salvage procedure.



It was emphasized that the work should be field oriented. The surgical techniques evolved were attempted in the field to assess their feasibility and tolerance in animals without any sophisticated infrastructure and equipment to perform, to monitor or to revive. In view of the overall scenario, a clinical research was envisaged to cover the various aspects of CVP under field conditions with following objectives:

1. To know the etiopathology of recurrent genital prolapse by undertaking methodical investigation using clinical, haemato-biochemical, endocrinological, histopathological and microbial parameters.
2. To ascertain and develop the criteria to grade the nature and severity of recurrent genital prolapse with general health of animal.
3. To design and evolve medico-surgical protocols for the management of various grades of recurrent genital prolapse.
4. To investigate and find out suitability of the surgical procedures for the alleviation of pain and suffering of the cows affected with various degrees of recurrent genital prolapse.



*Review of Literature*

## CHAPTER - II

### REVIEW OF LITERATURE

---

Prolapse of vagina, cervix and uterus has been extensively reported in animals. Although existing in females of most species like mare, bitch, ewe and goat, its occurrence has been very common in cows and buffaloes especially in pleuriparous animals. Most of the times, prolapse is found *peri-parturient*. Incidence in dry animals has not been well reported. The present review therefore relies more on *peri-parturient* prolapse in bovine and has been briefly presented under the following sub-heads.

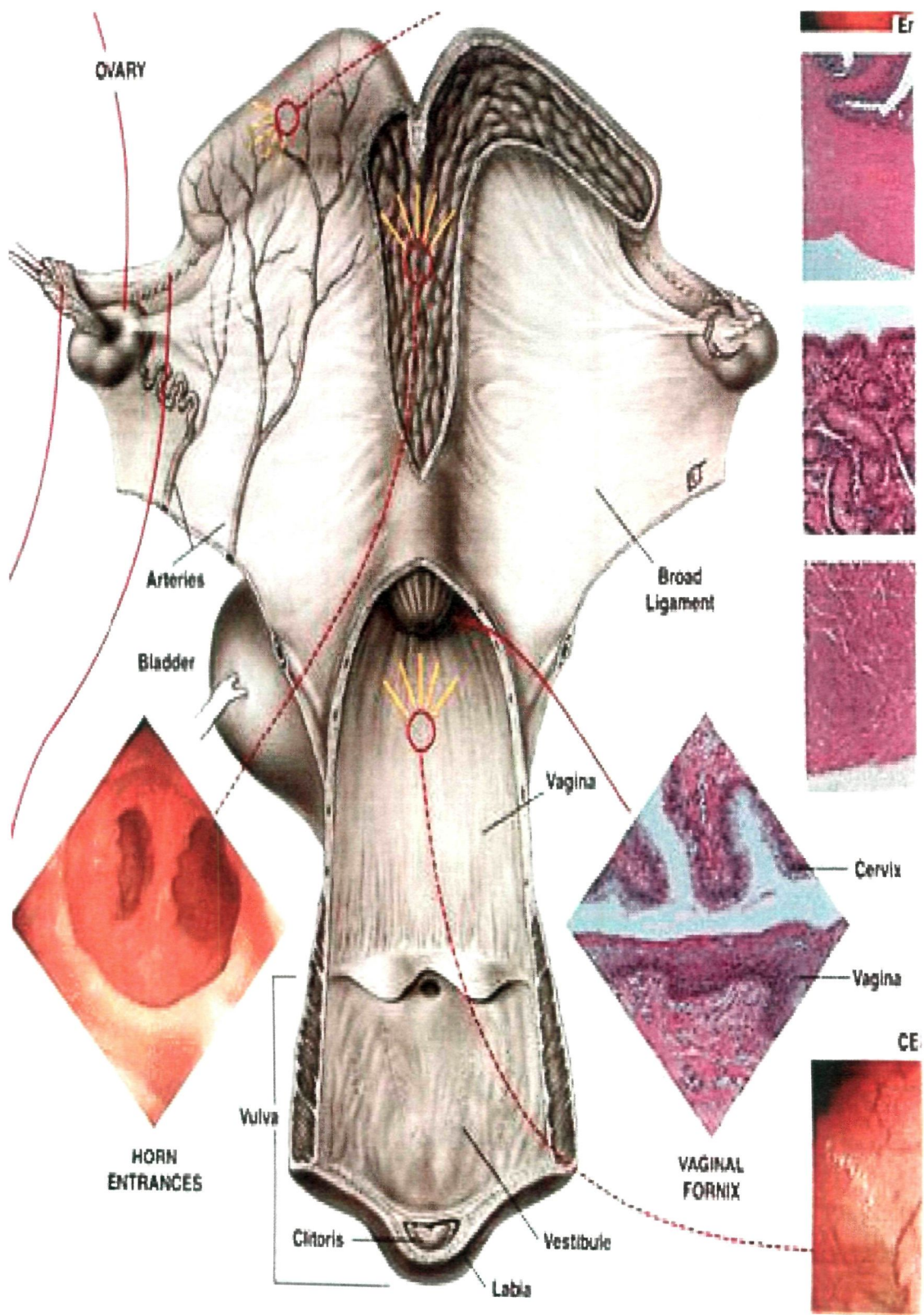
- 2.1 Applied Anatomy of the Cow's Reproductive Organs
- 2.2 Incidence of Cervico-Vaginal Prolapse (CVP)
- 2.3 Etiological Factors of CVP
- 2.4 Haematological Changes in CVP and Peripartum Disorders
- 2.5 Blood Biochemical Changes in CVP and Peripartum Disorders
- 2.6 Hormonal Changes in CVP and Peripartum Disorders
- 2.7 Genital Flora and Drug Sensitivity in CVP and Genital Disorders
- 2.8 Urine Analysis
- 2.9 Clinical Signs and Grading of CVP
- 2.10 Prognosis of CVP
- 2.11 Medico-Surgical Management of CVP
- 2.12 Histopathological changes in CVP and Genital Disorders

## 2.1 Applied Anatomy of the Cow's Reproductive Organs

Ghosh (2006) described applied and functional anatomy of cow's reproductive organs as under.

**Ovary:** The normal, mature cow possesses two almond shaped ovaries which are suspended in the abdominal cavity by a ligament (the mesovarium) and are partially surrounded by the infundibulum. They are situated a little above the middle of lateral margins of pelvic inlet. It is attached to the lateral abdominal wall by anterior part of broad ligament of uterus, **mesovarium**. Each measures 3.5 cm X 2.5 cm X 2.5 cm and weighs about 15 – 20 gm. The size and shape vary with age, ovarian follicle and corpus luteum. The anterior or tubal extremity is rounded and related with fimbriated end of fallopian tube. The uterine or posterior extremity is narrow and connected with uterus by **ovarian ligament**. Blood supply is through ovarian branch of utero-ovarian artery and nerve supply through renal and aortic plexus. It performs dual function of production and release of the female reproductive cell, the egg or ovum; and the ovarian hormones (estrogen, progesterone, inhibin, oxytocin and relaxin).

**Fallopian tube:** They are excretory ducts of the ovaries since they convey the ova from the ovaries to the uterus. They are not directly attached with ovaries but partly attached to them. Each is 12 – 15 inches long extending from anterior extremity of the ovary to the uterine horn. It is small but becomes wider and funnel shaped towards the ovary. Each is enclosed in peritoneal fold derived from broad ligament of uterus-**mesosalpinx**. The uterine extremity communicates with uterine horn by large, funnel shaped **ostium uterinum tubae**, while the ovarian end is wide and forms the **infundibulum** whose margin is irregular and fimbriated. It presents a small opening – the **ostium abdominale tubae** by which it communicates with the peritoneal cavity.



Anatomy of Cow's Reproductive Organs  
 (Primary Veterinary Anatomy, by Ghosh, 2006)

**Uterus:** It is a musculo membranous sac continuous with fallopian tube in front and vagina behind. In adult it lies almost in the abdominal cavity and attached with it by a **broad ligament** of uterus. It consists of horns, body and cervix. The horns are situated in the abdomen and are about 35 – 40 cm long. They taper gradually to the free end so that its junction with fallopian tube is not abrupt. The horns are directed forward, downward, outwards and turns backward and upward thus forming a spiral coil. The body is about 3 – 4 cm long. It is related to rectum above and bladder below. The cervix is about 10 cm long and its wall is very dense and more than 3 cm thick. Part of it projects into the vagina and is not visible externally but may felt through the vaginal wall. The space around it is called **fornix**, ventral to this, the wall fused with the vaginal wall. So fornix is present dorsally and almost absent ventrally. The lumen of cervix is spiral, narrow and difficult to dilate. The cervix and body communicate through **orificium internum uteri**.

The cavity of neck opens into vagina at the **orificium externum uteri** or **os uteri**. The mucosa of the body and horn present a large number of oval prominences called cotyledons, about 100 in number. They are irregularly scattered or arranged in four rows each of a dozen or more.

The broad ligament attaches uterus with the lateral wall of flank. It contains blood vessels and nerves of uterus and ovaries, connective tissue and large amount of unstripped muscles, which are continuous with the uterus. The broad ligaments on either side gives a fold to the uterus, which extends up to the abdominal inguinal ring known as **round ligaments**.

**Vagina:** It is a tubular passage extending from the os uterus to the vulva. It is about 25 – 30 cm long and there is no line of demarcation between it and vulva. It is

related above with the rectum, below to the bladder and urethra and laterally to the pelvic wall. Half of the vagina is retroperitoneal. The mucosa is highly elastic and devoid of any gland.

There are two **Gartner's canal**, which open on either side of external urethral orifice on the floor of vagina. The cervix partly occupies the anterior end of vagina. Caudally it continues with vulva. The only line of demarcation is a transverse fold-**hymen**, which covers the external urethral orifice. It is related above with the rectum, below to the bladder and urethra and laterally to the pelvic wall. Half of the vagina is retroperitoneal. The mucosa is highly elastic and devoid of any gland.

**Vulva:** The vulva or urogenital sinus is the terminal part of the genital tract and is continuous in front with the vagina and opens externally at the vulvar cleft below the anus. It is about 10 - 12 cm long and is related above to the rectum and anus and below to the floor of the pelvis and laterally to the sacrosciatic ligaments. The **vulvar cleft** is a vertical slit 10 – 12 cm high, margined by two prominent **vulvar lips**. They are thick, wrinkled and unite above and below the level of ischial arch and has number of long hairs on it.

**Clitoris:** The clitoris is composed of erectile tissue and is homologue of the penis. When the lips are drawn apart a fossa is noticed at the ventral commissure called **fossa clitoridis**, which lodges the free end of clitoris, **glans clitoridis**. Below and in continuation with the glans is the corpus clitoridis formed by union of two crura clitoridis, which are attached to ischial symphysis by suspensory ligaments.

The **external urethral orifice** is in the form of a longitudinal slit about 10 – 12 cm, from the ventral commissure on the ventral wall. A fold of mucous membrane, the free end of which is directed backwards, covers it. Beneath this is a blind pouch, **sub-**

**urethral diverticulum**, about 3.5 cm long. The vulvar mucosa is pink or yellowish red in color. At the floor a pair of large and some small **Vestibular glands** are present.

## 2.2 Incidence of Cervico-Vaginal Prolapse

Incidence of genital prolapse has been more in beef cattle. Woodward and Quesenberry (1956) carried out extensive survey on data of cases of prolapse in cows for years 1935-1954. Their estimate of peripartum prolapse was 1.2 per cent.

Roberts (1971) mentioned that the incidence of cervico-vaginal prolapse is more in pleuri-parous cows.

In Scandinavian countries, Odegaard (1977) and Roine and Soloniemi (1978) reported the incidence of genital prolapse at 3.0 per cent, while in America, Patterson *et al.* (1979) found it as 0.2 per cent in beef cattle.

In the observations of Richardson *et al.* (1981), 69.2 per cent (18) of the animals with prolapse were alert and ambulatory when treated and 57.7 per cent (15) were known to have required help to deliver the calf. Of the cattle group with uterine prolapse, 53.8 per cent (14) were two years old, 23.1 per cent (6) were three years old and 23.1 per cent (6) were four years of age or older.

Jubb *et al.* (1990) recorded 68 cases in Macalister District of Australia during 1986-1987. Similarly, Gardner *et al.* (1990) found 200 cases in a 12 months study.

Mishra *et al.* (1998) attended 634 cases of genital prolapse in cows as well as in buffaloes of both pre- and post-parturient period between 1988 and 1998.

Prasad and Agrawal (2000) treated 2 cases of prolapse in cows, whereas Bhattacharya *et al.* (2007) treated 4 cases.

Saha and Nakao (2003) recorded the highest incidence in August with 77 per cent cases between June and October. Bhattacharya *et al.* (2007) found high prevalence in Jersey crossbred cows (91.67%) aged around 6 years (54.54%) and in 2<sup>nd</sup> to 4<sup>th</sup> parity (77.22%).

Ishii *et al.* (2010) studied 76 cases of prolapse to evaluate effects of different postures on prolapse.

### **2.3 Etiological Factors of CVP**

Several aetiological factors have been mentioned as causes for prolapse. Vandeplasche and Spincemaille (1963) opined that at parturition, the pregnant horn does not undergo progressive inversion from its anterior extremity; only the posterior third inverts. Actual protrusion of this portion can occur in one bout of straining.

Tyagi and Singh (1993) remarked that prolapse may be associated with follicular cysts. Kochhar *et al.* (1996) encountered a recurrent prolapse of vagina that was due to lipoma. Singh *et al.* (1998) also treated a case of prolapse due to fibrosarcoma of uterus.

Prasad and Agrawal (2000) reported a case of cervico-vaginal prolapse caused because of multifollicular cysts in both the ovaries in a cow. Rai and Prabhakar (2000) remarked that the causes for prolapse be many, but it is most important to prevent trauma to the prolapsed mass.

Agrawal and Prasad (2001) mentioned that cystic ovary may lead to cervico-vaginal prolapse in cattle and buffalo.

Arthur *et al.* (2001) indicated oestrogen containing pastures as a cause of genital prolapse. Fubini and Ducharme (2004) opined that prolapse is more common in stabled animals due to lack of exercise.

Gustafsson *et al.* (2004) gave a detailed account of causes in periparturient cases. They mentioned several hormones including changing levels of progesterone, oestrogens, cortisol and oxytocin and pregnancy associated glycoproteins (PAGs). They also indicated microbial invasion as one of the causes. Added to these were other factors like dystocia, stillbirth and retained foetal membranes.

Cynthia and Scott (2005) remarked that cows subjected to superovulation repeatedly may suffer from vaginal prolapse.

Ghuman *et al.* (2008) reported a case of recurrent vaginal prolapse associated with cystic Gartner's duct due to cystic ovary in a crossbred cow.

Potter (2008) suggested factors like prolonged dystocia, fetal oversize, retained membranes and paresis as causes for genital prolapse.

#### **2.4 Haematological Changes in CVP and Peripartum Disorders**

Many haematological changes occur concurrent with prolapse. Kinney (1967) stated that the decrease in PCV in prolapsed animals could be due to release of antidiuretic hormones as a result of stress.

Sindhu (1975) studied various clinical laboratory aspects in normal and abnormal periparturient genital conditions in buffaloes. He observed higher TLC and neutrophils % in affected animals which he remarked were due to stress.

According to Benjamin (1978), the degree of leucocytosis depended upon several factors such as nature of the causative agent, severity of the infection, resistance of the animal and localization of the inflammatory response. Decrease in the Hb concentration could be due to reduction in size of RBC than the number of RBCs.



Mohy *et al.* (1985) reported that increased WBC count in prolapsed animals was due to release of adrenocorticotropic hormones from the adrenal gland.

Agarwal (1987) observed a significant decrease in PCV in uterine torsion in buffaloes and mentioned that it was due to anorexia and toxemia.

Verma *et al.* (1989) reported that the increase in TLC count and neutrophil count and the decrease in lymphocyte and monocyte counts in prolapsed animals can be due to increased levels of cortisol due to stress; while Malik *et al.* (1990) mentioned it could be due to inflammatory process in the genital prolapse.

Tarjinder and Singh (1993) studied hematology in 15 cases of uterine torsion, 4 cases of genital prolapse and 8 of dystocia in buffaloes. They found that the mean Hb concentration was decreased in cases of uterine torsion ( $10.2 \pm 0.3$  gm/dl) and increased in 3 out of 4 cases of prolapse ( $12.2 \pm 0.2$  gm/dl) compared to  $11.5 \pm 0.2$  gm/dl in normal animals. They opined that oedema of genital tract and loss of vascular fluids contributed haemoconcentration, which lead to the increase in Hb concentration. They observed decrease in RBC count in the cases of uterine torsion and genital prolapse as compared to normal animals, with the values  $5.4 \pm 0.2$ ,  $6.5 \pm 0.2$  and  $6.7 \pm 0.6$  million/cmm, respectively. They also observed decrease in PCV per cent in the uterine torsion and genital prolapse as compared to normal buffaloes with the values  $29.5 \pm 0.8$  (%),  $33.0 \pm 1.5$  (%) and  $34.0 \pm 1.0$  (%), respectively. They found higher TLC ( $10^3$ /cmm) count, in cases of uterine torsion ( $14.3 \pm 0.3$ ) and genital prolapse ( $13.5 \pm 0.2$ ) as compared to normal animals ( $9.9 \pm 1.1$ ). Neutrophilia and lymphocytopenia was also noted in the affected animals. They attributed these findings to increased levels of cortisol, stress and inflammatory process in the genital tract.

Ahmed *et al.* (2005) investigated clinical and haematological changes in 20 buffaloes suffering from genital prolapse and 10 normal pregnant (control group) buffaloes. They observed a significant decrease ( $P < 0.001$ ) in mean haemoglobin concentration in prolapsed animals ( $11.25 \pm 1.1$  gm/dl) ( $n = 20$ ), as compared to control group ( $14.05 \pm 0.8$  gm/dl), and attributed this to loss of body fluids or reduction in the size of erythrocytes. They observed highly significant decrease in PCV % in prolapsed buffaloes ( $35.70 \pm 2.70$ ) than in control group ( $42.10 \pm 2.23$ ), and attributed it to anorexia and toxæmia. The RBC count was increased non-significantly in affected animals ( $6.31 \pm 0.69 \times 10^6 / \text{cmm}$ ), than in control group ( $6.10 \pm 0.43 \times 10^6 / \text{cmm}$ ). The mean WBC count ( $10^3 / \text{cmm}$ ) was significantly higher in prolapsed animals ( $12.82 \pm 1.10$ ) than control group ( $6.63 \pm 2.56$ ). The neutrophils were significantly increased in prolapsed animals ( $37.50 \pm 4.95$  %), than in the control group ( $31.20 \pm 3.46$  %). The lymphocytes and monocytes were significantly decreased in prolapsed animals ( $50.15 \pm 4.30$  % and  $4.20 \pm 4.58$  %) as compared to control group ( $54.2 \pm 4.57$  % and  $9.20 \pm 1.53$  %) respectively. These changes were attributed to increased levels of cortisol and due to stress.

Yilmaz *et al.* (2006) carried out Hb, PCV, TEC and TLC on 30 periparturient recumbent cows. They could not find any variation in their values in comparison to 20 healthy cows of the same breed and concluded that recumbency was not due to septic or inflammatory causes. Mudasir *et al.* (2009) failed to see remarkable changes in the values of Hb, TLC and DLC in cases of genital prolapse.

## **2.5 Blood Biochemical Changes in CVP and Peripartum Disorders**

Several changes in blood biochemicals, enzymes and minerals profile occur in animals concurrent with genital prolapse.

### **2.5.1 Enzymatic Changes**

Significant increase in the levels of AST and ALT in buffaloes with uterine torsion was recorded by Pattabiraman and Pandit (1980), Khatri *et al.* (1986) and Verma *et al.* (1989).

Murray *et al.* (1982) reported similar results in cattle and buffaloes with reproductive disorders. They suggested that the increase in AST and ALT was occurred due to toxemia resulting in damage to parenchymatous organs.

Tarjinder and Singh (1993) revealed significant increase in AST (IU/L) and ALT (IU/L) levels with the values of  $152.0 \pm 13.3$  and  $56.4 \pm 3.4$ , respectively, in cases of uterine torsion, and  $173.0 \pm 15.7$  and  $45.4 \pm 2.7$  in cases of uterine prolapse as compared to  $116.0 \pm 6.2$  and  $40.0 \pm 2.2$  in normal animals. Significant increase in ALP level was also observed by them. They opined that these increased levels were due to hepatic and muscular cell damage due to toxemia. These elevated levels confirmed the liver damage due to altered permeability of hepatic cells. The reproductive disorders led to the development of acute passive hyperaemia which led to the congestion in parenchymatous organs. The congestion resulted in hypoxia and degeneration of liver. The degeneration of the hepatocytes and also the muscular coat of uterus was expected to lead leakage of enzymes, thereby leading to increase in the serum levels of enzymes.

Dadarwal *et al.* (2009) found no difference in the levels of AST ( $159.0 \pm 7.7$  U/L and  $148.4 \pm 14$  U/L) and ALT ( $40.8 \pm 2.7$  U/L and  $42.9 \pm 3.4$  U/L) in the pluriparous anestrous and cycling buffaloes.

### **2.5.2 Blood Minerals profile**

Richardson *et al.* (1981) studied serum samples from 26 beef cows with uterine prolapse and compared to those animals having dystocia from other causes. The serum

had significantly ( $P \leq 0.01$ ) lower calcium concentration ( $8.22 \pm 0.69$  mg/dl), higher phosphorus concentration ( $4.78 \pm 1.75$  mg/dl) and lower calcium to phosphorus ratio ( $1.99 \pm 0.88$ ) than for the control animals ( $8.91 \pm 0.75$  mg/dl,  $3.54 \pm 1.41$  mg/dl and  $2.99 \pm 1.41$ , respectively). Mild hypocalcaemia ( $6.9 - 7.9$  mg/dl) was present in 11 (42.3%) of the cows with prolapse as compared to only one (6.7%) of the controls. Hypophosphatemia was present in 11 (42.3%) of the animals with prolapse and in 10 (66.7%) of the controls. Thus, it was concluded that mild hypocalcaemia was associated with the uterine prolapse.

Pandit *et al.* (1982) suggested that hypocalcaemia led to atony of genital organs that led to prolapse. Risco *et al.* (1984) also noted that cows with uterine prolapse had significantly lower levels of serum calcium.

Risco *et al.* (1984) collected blood samples from 53 dairy cows with uterine prolapse and from 53 cows with normal parturition (controls) for various management programs among dairies. Cows with uterine prolapse had significantly lower total serum calcium content than did controls ( $P < 0.01$ ) Mean ( $\pm$ SEM) serum calcium content (mg/dl) for affected cows and controls were  $6.08 (\pm 0.25)$  and  $6.96 (\pm 0.20)$ , respectively. Severe hypocalcaemia ( $< 4$  mg/dl) was found in 10 (19%) of the affected cows, compared to 1 (1.8%) of the controls. Fifteen (28%) of the affected cows had moderate hypocalcaemia (4.1 to 6.0 mg/dl), compared to 14 (26%) of the controls; 19 (36%) of the affected cows were mildly hypocalcemic (6.1 to 7.9 mg/dl), compared to 25 (47%) of the controls. Nine (17%) of the affected cows and 13 (25%) of the controls were within the normal range of calcium content ( $> 8$  mg/dl). It was concluded that hypocalcemia was associated with uterine prolapse in multiparous dairy cows and, along with other factors, is involved as an etiologic factor, for this puerperal condition.

According to Gardner *et al.* (1990), serum calcium levels were not prognostic as a cause of recumbency in cattle, since survival was better in cows with severe hypocalcaemia than with those having higher or normal levels.

Paul *et al.* (2000) collected blood samples from Nili Ravi heifers, lactating buffaloes and advanced pregnant buffaloes showing various reproductive disorders like anestrus, repeat breeding and prolapse of uterus. Serum values for Ca, P, Mg, Fe, Zn and Cu in all animals having such problems were much above the critical levels and comparable to those of normal animals. The study provided evidence of dietary adequacy of these minerals and indicated that the reproductive problems were due to the causes other than dietary deficiency of any of the minerals studied.

Ahmed *et al.* (2005) found a considerable decrease in serum calcium ( $6.42 \pm 1.05$  mg/dl), phosphorus ( $2.90 \pm 0.85$  mg/dl) and magnesium ( $1.50 \pm 0.53$  mg/dl) in prolapsed buffaloes as compared to controls ( $P < 0.01$ ). They concluded that deficiency of calcium, phosphorus and magnesium was one of the causes for prolapse.

Yilmaz *et al.* (2006) found no significant change in the levels of Na, K and chloride, but there was decreased Ca and P levels and altered Ca:P ratio leading to periparturient recumbency. Bhattacharya *et al.* (2007) noted hypocalcaemia in cases of prolapse.

Mudasir *et al.* (2009) found low serum calcium (6 mg/dl) in advance pregnant (9 months) Murrah buffalo with cervico-vaginal prolapse. Kumar *et al.* (2009<sup>a</sup>) observed insignificantly lower calcium level in anestrus crossbred cows (7.20 mg/dl) than in normal cyclic cows (10.03 mg/dl). The inorganic phosphorus level was significantly higher in subestrus cows (9.32 mg/dl) than in normal cows (7.26 mg/dl).

## 2.6 Hormonal Changes in CVP and Peripartum Disorders

In female farm animals, growth and reproduction are vital processes governed by hormones. Hormones are the substances that govern all the functioning of the genital organs. Estrogen and progesterone are having a crucial role in the alteration of vagina, cervix and uterus (Koren and Smith, 1945; McErlean, 1952; Woodward and Quesenberry 1956). Cortisol is used to indicate the stress and trauma.

Misra (1998) and Agarwal and Prasad (2001) reviewed the condition of cervico-vaginal prolapse in cows. They mentioned that increased amount of estrogen, due to various factors, was the predisposing factor leading to prolapse in cows. Some fodder plants, and certain conditions as cystic ovary, nymphomania were known to cause increase in estrogen levels in blood. It caused relaxation of the pelvic ligaments and adjacent structures, vulva and vulval sphincter muscles, which predisposed to prolapse. Prolapse was more common in last 2 to 3 months of gestation, when large amount of estrogenic hormone was secreted by the placenta. Low level of progesterone in the animal was found to be associated with cervico-vaginal prolapse.

Siddiquee *et al.* (2006) suggested that changes in the ratio of estradiol and progesterone increased the risk of vaginal prolapse in buffaloes.

Ali (2008) extensively surveyed the calving related disorders, viz., distokia, retention of placenta and uterine prolapse, in three agroecological zones of Pakistan. They observed that the progesterone concentration in the postpartum uterine prolapse of buffalo was higher ( $0.77 \pm 0.02$  ng/ml) than the postpartum normal buffaloes ( $0.22 \pm 0.01$  ng/ml). The estradiol 17- $\beta$  concentration in the postpartum uterine prolapse was lower ( $29.76 \pm 1.42$  pg/ml) than the postpartum normal buffaloes ( $35.88 \pm 0.71$  pg/ml).

Dugwekar *et al.* (2008) studied circulating serum progesterone (P4) and estradiol-17 $\beta$  (E2) levels during different phases of reproduction, viz. puberty, oestrous cycle, pregnancy, parturition, and postpartum period in Jafarabadi buffaloes. The progesterone level at estrous (n=6) was 0.55 $\pm$ 0.22 ng/ml, which increased to 2.90 $\pm$ 0.46 ng/ml during diestrous and remained elevated at 3.23 $\pm$ 0.160 ng/ml in conceived animals. The estradiol concentration on day of estrous was 40.20 $\pm$ 19.68 pg/ml, which fell to 2.07 pg/ml by 7 days of oestrus and remained low for rest of the 21 days of the oestrous cycle.

Kumar *et al.* (2009<sup>b</sup>) studied estradiol 17 $\beta$  concentrations in 15 buffaloes having prepartum vaginal prolapse and five normal pregnant buffaloes. The time of prepartum prolapse varied from 8 to 10 months of gestation for the individual animal. A normal pregnant animal with the similar time of gestation was compared with the prolapsed animal. There was significant increase in the estradiol level in the prolapsed animals than the normal pregnant animals. The overall concentration of estradiol-17 $\beta$ , from 8 to 10 months of gestation in normal pregnant animals was 40.46 pg/ml with the range from 33.89 to 44 pg/ml. It ranged from 303.5 to 379.75 pg/ml in prepartum prolapsed animals. They suggested that estrogen was a cause of prepartum vaginal prolapse in buffaloes. The role of estrogen as a cause of prepartum vaginal prolapse in bovine was highlighted by many workers, but information regarding the concentration of estradiol in causing the disease was scanty.

## **2.7 Genital Flora and Drug Sensitivity in CVP and Genital Disorders**

Sharma *et al.* (1977) treated one case of prolapse that was not peripartum. On bacteriological examination of urine, *Shigella* species was isolated which was sensitive to erythromycin, tetracycline, chloramphenicol, streptomycin and oxytetracycline. They suggested that urinary infection should be ruled out as a cause of prolapse.

Azawi *et al.* (2007) reported *E. coli*, *Archanobacterium pyogenes*, *Staphylococcus aureus* and *Fusobacterium necrophorum* as the main isolates from 42 buffaloes with toxic puerperal metritis caused by retained placenta, dystocia or uterine prolapse.

Ghosh *et al.* (2007) studied swabs from vagina, cervix and uterus of 65 infertile cows having apparent infection. They found *E. coli* and *Staphylococcus* species infections separately in 22.22 to 28.88 per cent swabs. The organisms were sensitive to gentamicin (100%), kenamycin, amikacin (95%), ciprofloxacin (90%) and sulfafurazole (77.5%). The isolates were resistant to methicillin, cefixime, vancomycin and erythromycin.

Mohanty *et al.* (2007) noted that ceftriaxone sodium with broad spectrum activity seemed more suitable for intrauterine use for combating uterine infections.

Patil *et al.* (2007) treated 40 clinical cases of infectious repeat breeder animals. Twenty four cows and sixteen buffaloes were treated with 20 mg of levofloxacin hemhydrate and 5 mg of alphatocopherol by intrauterine administration. Treated animals were bred only in the next oestrus after confirmation of negative white side test. The treatment was found to be effective culturally in 17 cows (70.83 %) and 11 buffaloes (68.75%). Non-responded animals were re-administered the same drug. Five cows and four buffaloes responded promptly to the repeat treatment. Overall, the treatment was found to be effective in 91.67 per cent cows and 93.75 per cent buffaloes. The sensitivity zone of livofloxacin was the highest followed by other antibiotics. Alpahtocopherol by intrauterine route along with antibiotic proved to be effective in improving natural uterine defense and health of superficial endometrial layer.

As per the observations of Sharma *et al.* ((2007), bacterial isolates of vaginal swabs from 42 cows yielded Streptococci in 14 cases, Staphylococci in 9 cases, *E. coli* in 9, *Corynebacterium pyogenes* in 3, Staphylococci + *E. coli* in 4 cases, Proteus + *E. coli* in 1 cases, Streptococci + *Corynebacterium* in 3 cases and Staphylococci + *E. coli* in 1 case.

Singh *et al.* (2009) expressed that rationale use of antimicrobials after culture and sensitivity test in chronic endometritis cases is impractical in veterinary field. They felt that treatment with systemic antibiotics for both aerobic and anaerobic bacteria, based on conventionally used intrauterine treatments was a wise option.

Mane *et al.* (2009) collected 32 cervical mucus samples from repeat breeder bovines (19 cattle and 13 buffaloes) to know the bacterial spectrum, antibiotic sensitivity pattern and conception rate. Overall results of different isolates obtained were *E. coli* (59.37%), *C. pyogenes* (37.50%), *Ps. Aeruginosa* (28.12%), *Staphylococcus aureus* (21.87%), Streptococcus (9.23%), *Klebsiella aerogenes* (6.25%), and unidentified Gram positive rods (3.12%). Ciprofloxacin (93.75%) was most effective drug followed by gentamicin (84.37%) and chloremphenicol (78.12%). The animal treated based on sensitivity test, with ciprofloxacin, gentamicin and chloramphenicol and untreated group revealed conception rates of 87.50, 75.00, 50.00 and 25.00, respectively.

## **2.8 Urine analysis**

Sharma *et al.* (1977) presented a case of vaginal prolapse in a buffalo caused by urinary infection of *Shigella* species.

Benjamin (1978) and Jain (1986) have described the changes in urine, which reflect not only the status of urinary system but functioning of other body systems also.

## 2.9 Clinical Signs and Grading of CVP

Clinical signs in cases of prolapse vary depending on number of factors. Accordingly, the prolapse has been classified in different degrees by various authors. White (1987) described prolapsed uterus as collar like structure ventral to vulva.

Cow presented to Singh *et al.* (1998) for treatment of vaginal prolapse was listless, anorectic and straining violently for three days.

In the observations of Prasad and Agrawal (2000), the cow suffered prolapse 3 months post-calving, which went on increasing towards 5 months when large everted mass of vagina and cervix was visible at vulva. The cow showed frequent micturition and raised tail.

Thomas (2000) described appearance of prolapse in different degrees. Mild prolapse (bulge of size of an orange) usually goes back when the cow gets up. If she strains while lying, it recurs.

According to Arthur *et al.* (2001), prolapse may first appear when the cow sits down. As it becomes bigger, straining may start and the organ becomes swollen so much that it does not return. If untreated, it can get traumatized and infected. They recommend grading of genital prolapse as first degree when the mass is small and protrudes only when the cow sits. If the portion is all the time protruding even in a standing cow, it is of second degree. In the third degree, cervix and majority of vagina are protruding, while in the fourth degree, necrosis and fibrosis of the vaginal wall is noted. Further, the portions of digestive tract or urinary bladder may be encountered in the prolapsed mass. Straining, abdominal pain, restlessness, anorexia and increased pulse and respiratory rates are the common findings in the affected animals.

Saha and Nakao (2003) graded cases of prolapse according to severity. When a part of vaginal prolapse appeared in a lying buffalo, they classified it as Degree I. In Degree II, whole vagina was prolapsed while the buffalo was lying. When whole vagina was seen outside even in a standing animal, they put it in Degree III. Those buffaloes, having prolapse with inflammation, wounds, oedema and cyanosis were classified into Degree IV. In all degrees, straining was a common feature.

Fubini and Ducharme (2004) explained the events of prolapse. According to them, prolapse started as an intussusception of vaginal floor just cranial to vestibulo-vaginal junction. Increased abdominal pressure, discomfort due to everted mass and swelling and oedema of the mass led to straining and further prolapse. Eventually, entire vagina could prolapse. Urinary bladder and loops of intestines were occasionally entrapped resulting into urethral stricture.

Bhattacharya *et al.* (2007) found severe tenesmus and bleeding in two cows with prolapse. In one of them, the mass was infected, oedematous, lacerated and necrotic. In the second cow, they noted rapid respiration, grunt and pale mucous membrane.

Wolfe and Carson (2007) observed prolapse ranging from small mass to extreme necrosis and fibrosis of the mass. The mass had gone septic. They classified prolapse as first degree if there was an intermittent prolapse of vaginal floor when the cow sat down. When the prolapse was persisting continuously, they termed it as second degree. Often in these cases, there was involvement of urinary bladder preventing urination. When there was cervix in addition to whole vagina, they termed it as third degree. In cases of fourth degree, prolapsed mass was exposed long enough to cause necrosis and fibrosis.

According to Jana and Ghosh (2009), prolapsed uterus was highly prone to mechanical injury, contamination, laceration and subsequent haemorrhage, necrosis and



sometimes urinary incontinence. In the opinion of Ishii *et al.* (2010), if the case was not recent, the organ became swollen, hardened and friable making replacement more difficult.

### **2.10 Prognosis of CVP**

The prognosis of the case may vary depending upon time of presentation, degree of prolapse and laboratory findings.

Jubb *et al.* (1990) followed eight cases of prolapse for two consecutive calving seasons. They concluded that cows suffering from prolapse have less chances of recurrence, could conceive and the treatment was cost effective.

According to Arthur *et al.* (2001), prognosis depends on the type of case, duration of prolapse and injury if any. If attended in a couple of hours, prognosis is good and the animals could conceive. Occasionally, death occurs due to internal haemorrhage. They also remarked that thrombosis, ulceration, necrosis accompanied by toxæmia lead to death of the cow.

Powell (2007) felt that although not life threatening, it may be difficult to reduce the prolapsed mass if left untreated long. When the uterus was involved, shock and bleeding could be life threatening and even after survival, such cows were difficult to breed.

### **2.11 Medico-Surgical Management of CVP**

Numbers of methods of treatment for prolapse have been described in the literature. Several other methods explain retention of the mass in situ and held by fixation sutures. Others have suggested mucosal resection, amputation of the mass, and ovariectomy with or without these procedures.

Benesch (1930) carried out laparotomy in cows having prolapse of uterus with ligation and separation of the uterine vessels and mesometrium from their dorsal attachments. A circular incision was made at the base of the prolapsed stump and the ovaries, broad ligaments were pulled out, and the cranial portion of the vagina was closed with Connell suture followed by Lembert.

According to Roberts (1949) amputation of uterus in cows was done when replacement was impossible. Prognosis was always guarded to poor. Uterine amputation could be accomplished by making a long longitudinal incision on the prolapsed mass. Vessels were carefully ligated and broad ligament was severed between the ligatures from the uterus. The cranial portion of vagina anterior to the prolapsed cervix was easily drawn out of the vulva and ligated with fixation ligatures. The uterus and part of all cervix was removed and the stump was replaced in the vaginal cavity. Administration of saline solution, blood transfusion, antihistamines, and other stimulants was considered very essential to prevent shock and reduce fatality. Post-operative administration of parenteral antibiotics for 3-4 days was advised to control the infection. He also suggested Casick's operation under caudal epidural anaesthesia.

Farquharson (1949) performed submucosal resection or reefing on the prolapsed organ. In this, excision of the mucosa which forms the bulk of the everted mass was performed and the cut edges were sutured to each other. Under posterior epidural anaesthesia, circumferential areas of mucous membrane of everted organ near urethral orifice was removed in separated segments. Haemorrhage from cut mucous membrane was controlled and the edges were approximated with continuous suture of absorbable suture material.

Bouckaert *et al.* (1956) modified the Minchev's technique of controlling prolapse of vagina by surgically fastening of the cranial portion of vaginal wall through the lesser sciatic foramen to the dorsolateral wall of the sacrosiatic ligament, muscles and skin of croup. They additionally placed the stay sutures cranial to the lesser sciatic foramen. In this technique firm attachment frequently did not occur, so prolapse of vaginal may reoccur.

Hogg (1960) employed a technique of vaginopexy to the gluteal region by using an unspecified instrument (like a double set of spaying needles). He passed the needle from within vagina to outward on gluteal region. His technique was primarily indicated for vaginal ballooning.

In 1961, Pierson modified "Buhner's Method" in that buried or hidden purse-string type suture were taken following replacement of prolapsed mass.

Gibbons (1962) supplanted the umbilical tape – vaginopexy technique of Hogg, by stainless steel propalse pins.

Winkler (1966) suggested fixation of the cervix to the prepubic tendon with non-capillary suture material in prolapses of longer duration in which there was extensive contamination and necrosis of the vagina mucous membrane, but his result indicated danger of peritonitis.

Misra and Angelo (1981) devised a special vaginopexy needle to perform this procedure. The needle was driven through skin and soft tissues of gluteal region. It was palpated with another hand in the vagina. By directing the tip, it was pierced through vaginal wall at fornix.

Vaginal lipoma attached to ventral wall and causing recurrent prolapse was removed by ligating the base, and dissecting and cauterizing the bleeding vessels (Kochhar *et al.* 1996).

Misra (1998) made a detailed account of treatment for recurrent prolapse. They used a stout needle with a large bevel specially designed for this purpose. Suture was made from the material of shoe lace that was treated with a water proof hardener. Two lengths each of 75 cm was kept ready. A pair of 3 cm long polythene tubing was also kept ready for threading onto this tubing. After replacing the cleaned prolapsed mass and an epidural analgesia, the needle threaded with the suture was introduced deep into vagina. It then penetrated the dorso-lateral vaginal wall to exit at the gluteal skin on the same side. The needle was released from the suture. Now the polythene tube was threaded onto the suture end in the vaginal lumen. The needle was threaded on this end now. It was reintroduced through the vagina at a distance of about 3-4 cm from the first bite. It was taken out through the dorso-lateral vaginal wall and exited at the gluteal skin at about 3-4 cm from the first end of the suture. Both the emerged ends of suture were tightened to make sure that the polythene tubing was fixed tight along the vaginal wall. Free ends of the suture were tied with a support of suture pad. Another similar suture was placed on the contralateral side. Appropriate dressing was given subsequently.

Singh *et al.* (1998) performed amputation of the prolapsed mass in a fibrosarcoma of uterus in a cow. They applied a bandage at the base of prolapsed mass to minimize bleeding. Five encircling sutures, each of about two inches, were placed along the circumference on the uterine wall. A three inch longitudinal incision was given on the prolapsed wall to expose broad ligament. Blood vessels along the broad ligament were isolated and tied individually. The ends were left long enough to hold at this point.



Uterine wall was now incised leaving broad ligament intact. The long ends of sutured vessels were checked for bleeding before leaving free while the broad ligament was cut. The ends of vaginal wall were sutured completely to close the peritoneal cavity. Routine follow up was done.

After reduction of the mass, vulvar sutures or use of West's clamp to close vulvar opening has been advocated by Arthur *et al.* (2001). They recommend amputation of the prolapsed portion as a last resort in those cases where uterus has undergone severe pathological changes thereby increasing the chances of death on replacement of the organ.

Wolfe and Carson (2007) gave a very good comparative account of different suture patterns for the fixation of the prolapsed mass. They preferred Buhner technique as it offered quick removal. In this, a heavy nylon Buhner tape was used to close the vulvar commissure. They also used modified Winkler's technique to fix the cervix and vagina to prepubic tendon. They preferred two surgeons doing the procedure; one doing the vaginal portion and another to do abdominal portion through a standing laparotomy. They also described Minchev's technique to anchor both sides of anterior dorsal vagina through sacrosclatic ligament into the skin of gluteal area. A heavy nylon tape is used for the purpose. They, however, felt that cervicopexy was a permanent procedure that will fix cervix to the prepubic tendon.

Tank *et al.* (2006) successfully managed chronic recurrent genital prolapse in cows using pervaginal ovariohysterectomy technique under epidural analgesia and xylazine sedation in lateral recumbancy. All the cows recovered uneventfully without any complication.

Pathak *et al.* (2009) also applied similar technique to remove vaginal lipoma causing recurrent prolapse in a crossbred cow.


## **2.12 Histopathological Changes in CVP**

Study of histopathological changes in the prolapsed uteri, cervix or vagina was not available. Study of changes is pertinent for throwing light on the extent of damage in the genital organs due to the chronic prolapse.

Malik *et al.* (1990), however, commented that uterine torsion was the major obstetrical condition in pregnant buffaloes. They investigated 12 buffaloes with uterine torsion for the histopathological changes. The different histological changes were found as follow.

The endometrial thickness observed during their study was quite varying between 450 microns to 2550 microns, indicating variety of proliferative activity of the endometrium in different remnants of placental structures such as chorionic villi and trophoblast in different areas. The uterine tissue and endometrium showed coagulative necrosis which was due to vascularization, pressure and hypoxic degeneration. In most cases, the endometrial epithelium was lost. This was in order with the anatomic norms of the buffaloes. Lining of the epithelium measured 20-24 microns in length and 4-8 microns in width and was hypertrophied like in the luteal phase. The structure of basement was variable in half of the cases, whereas in rest, it was very prominently seen and even reinforced with collagen fibres. It was calculated that circulatory arrest leading to hypoxia might have led to these changes.

Roberts (1971) has opined that in advanced cases uterine gangrene, uterine rupture, septicemia and toxemia may also be observed which might lead to shock, collapse and death. The following histopathological changes have been reported.



Lamina propria also showed varying degree of degeneration. Sometimes exudates with oedema, haemorrhage and congested blood vessels were also noted. Thrombus and clot formation was observed in 25 cases. This was due to trauma to uterine vessels. The inflammatory cells observed were fibroblasts, macrophages, plasma reticulocytes, monocytes and giant cells. Most characteristic feature was the leucocytosis by the giant cells and other similarly potential phagocytic cells.

Uterine glands were in degenerated stage. They were deformed and often when few of them which were preserved, these appeared dilated, hypertrophied and lined with simple or pseudostratified columnar epithelium measuring 10-24 microns. The glandular lumen presented a lot of cells which had migrated inside from surrounding tissues. They included RBCs and mononuclear cells.

Myometrium was generally extremely thickened and range 4-6 mm in thickness. The muscular cells showed hypertrophy. Muscle fibers were stretched and were found fragmented along with haemorrhage caused by strangulation. Coagulative necrosis, various degrees of degeneration, haemorrhage and congestion was usually evident. Most often the muscle fibres were extremely vacuolated probably due to exhaustion. Intermuscular and intramuscular places were occupied by reticulin. The tissue indicated in the stratum vasculare in a frayed and fragmented form and the collagen of adventitia was also degenerated. Intervascular and intermuscular tissue was also infiltrated with polymorph and mononuclear cells.

Most characteristic changes were observed in the vascular layer of the submucosa. Besides rupture of blood vessels, congestion, thrombosis, aneurisum, elastolysis, periarterial connective tissue hyalinization and also endothelial degeneration were observed.

Epimetrium was variably thick (60-450 microns) and was fibrous in nature. Sometimes it showed the indication of fibrosis and adhesion with the tissues. Roberts (1971) has also observed adhesions in cases of uterine torsion. Sometimes the adhesions were so strong that cornual detorsion was not possible and smooth muscle fibres of the broad ligament extended in to the serosa. The muscle fibres also showed exhausted appearance as of muscle fibres of myometrium.

Azawi *et al.* (2007) conducted histopathological examination of the endometrium from 42 buffaloes with toxic puerperal metritis. It showed acute endometritis associated with massive infiltration of multinucleated inflammatory cells around uterine glands and blood vessels. Hyperaemia and thrombus formation in blood vessels with haemorrhage in different sites of trauma were noted.



*Materials and Methods*



## CHAPTER – III

### MATERIALS AND METHODS

---

The project work was executed through the Department of Surgery and Radiology, College of Veterinary Science and Animal Husbandry, AAU, Anand. It was conducted at the below listed selected Gaushalas from Saurashtra region.

1. Shri Purushottam Laljibhai Gaushala Trust At Keshod, District- Junagadh.
2. Shri Gokulesh Gaushala Trust, Near Moti Haveli, Junagarh.
3. Shri Bappa Sitaram Gaushala, At Gundala, Taluka- Gondal, District- Rajkot.

The cows (46) affected with genital prolapse at the Gaushalas were observed under the conditions they lived with previous treatment, if any. A project was planned with thoughtful preparation for the treatment of these cows and to conduct under the limited infrastructures of field conditions. It was substantiated further with the laboratory investigations.

#### **3.1 Clinical Approach**

The project work was based on 46 cases of recurrent Cervico-Vaginal Prolapse (CVP) in cows. Medical history and clinical signs were noted in each case. All these cows were non pregnant and not related with parturition or parturiated more than 75 days before. The work was carried by organizing frequent clinical camps at the Gaushalas for a group of 8 to 9 cases. The cows were examined clinically. The prolapsed mass was

examined after washing with povidone iodine<sup>1</sup>. Ovaries were studied by per rectal palpation. Laboratory specimens were collected one day before the operation and also on 7<sup>th</sup> day after operation. On an average three cases were operated on one day for a period of three consecutive days. The post operative care was provided for one week. They were observed until the clinical healing, usually for a month and followed by intermittent visits and feedback up to four months.

### **3.2 Collection of Samples for Laboratory Examination**

Following samples were collected before and after operation such as blood, serum, cervical swabs and urine.

#### **3.2.1 Blood and Serum:**

Blood and serum was collected before surgery and at 7 days after surgery from the affected cows. Addition to this, it was collected from 8 normal lactating cows which were not affected with the prolapse of genitalia. About 20 ml of blood was collected aseptically from the jugular vein with 20 ml disposable syringe and 18 gauge needle. Six ml of blood was transferred to the vacuette with potassium EDTA as an anticoagulant. The remaining blood was allowed to clot in the syringe for 4-6 hours. The serum was separated in a sterile 5 ml plastic vial. One drop of 0.01% merthiolate was added as a preservative to the blood and serum samples. These specimens were sent on ice packs to the laboratory for processing. The blood samples were kept in refrigerator until processing. Serum samples were centrifuged at 3000 rpm for three minutes and the supernatant preserved in the deep freeze at -20°C until the estimations.

#### **3.2.2 Collection of cervical swabs:**

---

<sup>1</sup> Betadine scrub: Povidone Iodine 5% w/v, 500 ml, Win-Mdicare

The cervical swabs were collected one day before any treatment. The samples were collected carefully through the central portion of the prolapsed mass from vaginal fornix and os cervix aseptically. Postoperatively, the swabs were collected on 7 day from a few cases of group 4, 5 and 6. They were stored in refrigerator until processing.

### **3.2.3 Urine samples:**

Fifty ml urine was collected before the day of surgery and on 7<sup>th</sup> day after surgery. Usually, the voided urine samples were collected in a clean jar or collected by catheterization. Two-three drops of 40 % formaldehyde were added as a preservative.

### **3.2.4 Histology specimens:-**

Tissues for the histological examinations were collected from the surgically excised mass of the genitalia on the day of operation. They were preserved in 10 % Formalin solution.

## **3.2 Assessment of Health, Severity of Prolapse and Grading of Prolapse**

A very precise and practicable, 100 point score method was developed to evaluate the severity of the CVP and the general health status of the cow (**Table 1**). The extent of severity of the CVP could be then expressed as Grade I to Grade IV in order of increasing severity of the case (**Plate 1, A-J**). The method was based on the history, signs and symptoms of the disease, examined by clinical and physical (per rectal and per vaginal) examination of the case (**Plate 2, A-D**). For this purpose of assessment, all the possible signs, symptoms and lesions (referred to as a character or feature) found or anticipated until the extreme stage of the prolapse were enumerated, e.g. presentation and posture, general appearance of the body and skin coat, appetite, urinary difficulties, straining and pain, inflammatory changes in the prolapsed mass and so on. Each of these characters was assigned a due weightage of 4 credits depending upon its importance in the disease pathogenesis.

In the literature the grading of genital prolapse was usually done by giving more attention to the three features, viz., (i) duration of prolapse, (ii) Extent or size of the genital structures (vagina and cervix) prolapsed, and (iii) amount of straining or involvement of urinary bladder. Hence in the present method, these three features were given more (double) weightage by taking them second time in combination with other features.

Now, on the basis of examinations, each cow was assigned 0 to 4 points for each of the feature depending on its increased nature of severity from mild, moderate, more or high. Thus, each of the affected cows was assigned a numerical point for each of the character. The addition of these points for each case would arrive to a total number, which was the score of the case out of 100 points. Depending upon the score, the case of CVP was graded as grade I (0-25 point score), Grade II (26-50 point score), Grade III (51-75 point score) and Grade IV (76-100 point score). The description of the features and points assigned to each of them are given in **Tables 1 to 3 and Plate 1, A-J**.

### **3.3 Selection of Cases for Surgery and Formation of Groups**

Six types of surgical protocol were designed to meet various types of cases of the cervico-vaginal prolapse in the cows. All the techniques were performed through per vaginal approach. These included,

1. Fixation to prepubic tendon
2. Button suture fixation
3. Amputation of the prolapsed mass
4. Submucosal resection of the prolapsed vagina.
5. Per vaginum panhysterectomy
6. Per vaginum bilateral ovariectomy

**Table 1. Scoring system and points used to grade the individual cows with CVP for adopting appropriate Medico-Surgical management**

SR NO.		DESCRIPTION OF CHARACTER OF PROLAPSE	WEIGHTAGE ASSIGNED IN POINTS	
<b>1</b>		<b>No. of episodes of prolapse</b>	<b>4</b>	
1	a	One		1
1	b	Two		2
1	c	Three to five		3
1	d	More than five (Habituated)		4
<b>2</b>		<b>Duration of the present prolapse</b>	<b>8</b>	
2	a	Eight hours		0
2	b	Upto one day		1
2	c	One to three days		2
2	d	Three to seven days		4
2	e	Seven to fifteen days		6
2	f	More than fifteen days		8
<b>3</b>		<b>Period since first prolapse</b>	<b>4</b>	
3	a	Three months		1
3	b	Six months		2
3	c	Twelve months		3
3	d	More than twelve months		4
<b>4</b>		<b>No. of calvings in relation to age</b>	<b>4</b>	
4	a	Age upto five years, one or more calvings		1
4	b	Age upto five years, no calvings		2
4	c	Age upto ten years, more than three calvings		2
4	d	Age upto ten years, less than three calvings		3
4	e	Age above ten years, more than five calvings		3
4	f	Age above ten years, less than five calvings		4
<b>5</b>		<b>Parturition related causes</b>	<b>4</b>	
5	a	No specific cause		0
5	b	Traction or untrained handling		1
5	c	Retained placenta		2
5	d	Dystocia and retained placenta		3
5	e	Premature calving		4
<b>6</b>		<b>Posture and presentation</b>	<b>4</b>	
6	a	Standing		1
6	b	Standing ( low rump / knuckling) and Mild Emaciation		2
6	c	Sitting		3
6	d	Sitting, reluctant to stand or Recumbent and Emaciation		4
<b>7</b>		<b>Appetite</b>	<b>4</b>	
7	a	Normal		0
7	b	Moderate feeding		1
7	c	Marked reduction		2
7	d	Irregular		3
7	e	Reduced with digestive disorder or ketosis		4

Table 1. Contd....

<b>8</b>		<b>Temperature</b>	<b>4</b>	
8	a	100 to 102 °F		0
8	b	100 to 204 °F		2
8	c	Subnormal, less than 100 °F		3
8	d	More than 104 °F		4
<b>9</b>		<b>Pulse rate per minute</b>	<b>4</b>	
9	a	Normal, 50 to 70		0
9	b	Below 50		2
9	c	Upto 70 to 90		3
9	d	Above 90		4
<b>10</b>		<b>Respiration rate per minute</b>	<b>4</b>	
10	a	Normal, 20 to 28		0
10	b	Upto 28 to 40		2
10	c	More than 40		3
10	d	Below 20		4
<b>11</b>		<b>Colour of mucus membrane</b>	<b>4</b>	
11	a	Normal		0
11	b	Congested		1
11	c	Pale		2
11	d	Injected		3
11	e	Pigmented		4
<b>12</b>		<b>Signs of toxæmia</b>	<b>4</b>	
12	a	None		0
12	b	Depressed		2
12	c	Lethargic or Comatose		4
<b>13</b>		<b>Organs involved in prolapse</b>	<b>8</b>	
13	a	Vaginal floor		2
13	b	Vagina complete		4
13	c	Vagina with os cervix		6
13	d	Vagina with complete cervix		8
<b>14</b>		<b>Size of prolapse mass</b>	<b>8</b>	
14	a	Small		2
14	b	Moderate		4
14	c	More with vaginal proliferation or enlargement		6
14	d	More with cervix proliferation or enlargement		6
14	e	Large		8
<b>15</b>		<b>Appearance of prolapse</b>	<b>8</b>	
15	a	Healthy		0
15	b	Oedematous, mild lacerations		2
15	c	Second degree lacerations		4
15	d	Necrotic with thick or fibrosed vagina		6
15	e	Necrotic with hard, kink or fibrosed cervix		6
15	f	Complicated		8

Table 1. Contid....

Table 1. Contid....				
<b>16</b>		<b>Adhesions</b>	<b>4</b>	
16	a	None		0
16	b	Few		1
16	c	More		2
16	d	Extensive		3
16	e	Irreducible		4
<b>17</b>		<b>Discharge from genitalia</b>	<b>4</b>	
17	a	Mucus		1
17	b	Mucopurulent		2
17	c	Purulent		3
17	d	Foetid		4
<b>18</b>		<b>Straining</b>	<b>8</b>	
18	a	Mild		2
18	b	Moderate		4
18	c	Severe		6
18	d	Severe and frequent		8
<b>19</b>		<b>Involvement of urinary bladder and dysurea</b>	<b>4</b>	
19	a	No bladder involvement		0
19	b	Bladder not involved but distended		1
19	c	Bladder displaced caudally with mild dysurea		2
19	d	Bladder displaced caudally with severe dysurea		3
19	e	Bladder distended or everted, and dysurea		4
<b>20</b>		<b>Changes in the ovaries</b>	<b>4</b>	
20	a	Apparently normal		0
20	b	Uneven size		1
20	c	Smooth surface and hard texture		2
20	d	Cystic		3
20	e	Structural abnormalities, unluteinized mass, unregressed CL or other disorder		4
		<b>TOTAL SCORE POINTS IN EACH COW</b>		
		<b>TOTAL WEIGHTAGE IN POINTS</b>	<b>100</b>	

Table 2. Total score points obtained on different characters / factors of CVP by individual cows

Character/ Factor	Score points of Individual cow with CVP																						
	1	2	3	4	5	6	7	8	9	10	11	12	13	14	15	16	17	18	19	20	21	22	23
1	2	3	3	3	3	2	3	3	3	3	2	2	3	3	3	2	3	3	3	2	4	3	3
2	4	2	4	2	2	2	2	4	2	2	2	2	2	4	4	4	4	4	6	6	6	6	2
3	1	2	2	2	2	3	3	2	2	3	3	2	2	3	3	1	2	2	3	2	4	3	3
4	1	1	2	2	1	2	1	2	1	2	1	1	2	2	2	1	4	2	3	1	2	3	3
5	2	1	1	2	1	3	1	1	2	2	3	1	1	2	2	1	3	2	3	4	2	1	3
6	1	2	2	2	2	1	1	1	1	2	1	1	2	2	2	1	3	2	2	3	2	2	3
7	1	2	2	1	1	1	1	1	3	2	1	1	2	2	2	1	2	1	1	2	1	1	2
8	2	0	0	2	0	0	0	0	0	0	0	2	0	2	2	2	2	4	2	3	4	2	2
9	2	2	2	2	2	2	3	2	2	3	2	2	2	3	3	2	2	3	3	2	3	3	3
10	2	2	2	2	2	3	3	2	0	0	2	0	2	0	0	2	2	3	2	2	3	2	2
11	1	1	1	1	1	1	2	2	3	1	2	1	2	1	1	1	3	2	1	1	2	1	1
12	0	0	2	2	2	0	2	2	2	2	0	0	0	2	2	0	2	4	2	2	4	2	2
13	8	6	4	4	6	4	4	8	6	6	4	4	4	6	6	6	8	8	8	8	6	8	6
14	6	4	4	4	6	4	4	6	4	6	4	4	4	4	4	6	8	8	8	6	8	6	6
15	2	2	2	2	4	4	4	4	4	2	2	4	4	2	2	4	4	4	6	8	6	8	6
16	2	2	0	0	1	1	1	1	1	1	0	2	2	0	0	1	4	4	2	2	4	4	3
17	1	2	1	1	1	2	1	1	1	2	1	1	1	2	2	1	3	3	3	3	2	2	3
18	4	4	4	4	6	6	4	4	4	6	4	4	6	4	4	4	4	4	2	6	4	2	2
19	1	2	2	2	3	2	2	1	2	3	2	2	3	2	2	3	3	3	2	4	3	2	2
20	1	1	0	0	2	0	1	1	1	2	0	2	2	1	1	2	1	1	2	2	1	2	1
Total	44	42	40	40	48	43	46	46	46	50	36	38	46	47	47	45	67	67	64	69	71	63	58

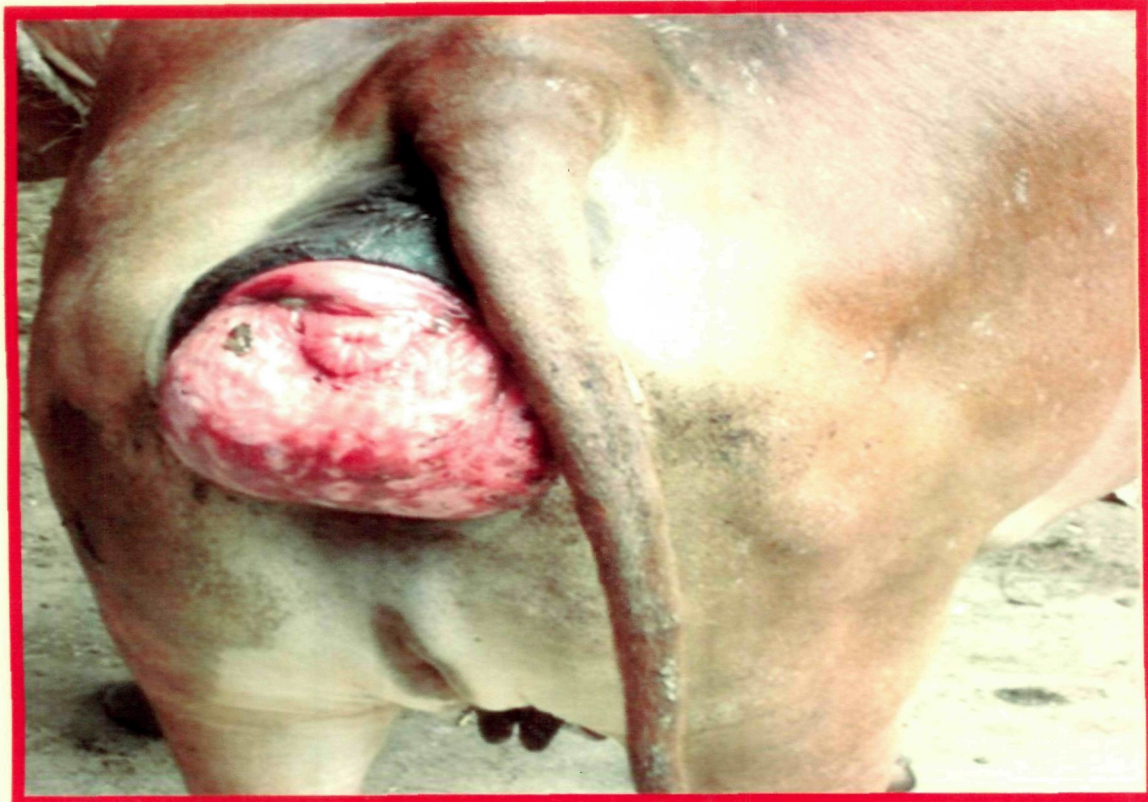Table 2. Contd...

Character/ Factor	Score points of Individual cow with CVP																						
	24	25	26	27	28	29	30	31	32	33	34	35	36	37	38	39	40	41	42	43	44	45	46
1	3	3	3	4	3	3	3	4	4	4	4	3	3	3	3	4	4	4	4	3	3	3	3
2	6	6	6	6	6	4	4	4	4	6	6	8	8	8	8	6	6	2	2	4	4	4	4
3	4	2	2	4	3	3	3	4	4	4	4	3	3	3	3	4	4	3	3	2	2	2	2
4	3	2	1	3	3	3	2	2	3	4	4	3	3	3	4	3	3	2	2	1	1	2	3
5	2	2	3	3	2	2	2	2	3	3	2	4	2	2	2	3	3	2	2	1	1	1	1
6	1	3	2	2	3	3	2	2	2	3	3	3	2	2	2	3	3	1	1	2	2	2	2
7	3	4	3	2	3	2	4	3	2	3	3	3	3	2	2	2	4	1	1	1	1	2	2
8	2	3	2	2	2	2	3	2	2	3	3	4	3	3	4	3	2	2	2	2	2	2	2
9	2	2	3	3	3	3	2	3	3	3	3	4	3	3	3	3	2	2	2	3	3	3	3
10	2	4	3	3	3	3	3	3	3	4	3	4	3	3	3	3	2	2	2	2	2	2	2
11	3	4	3	3	3	3	3	3	2	2	2	2	3	3	2	3	3	1	1	1	1	3	3
12	2	2	2	4	4	4	2	4	2	4	4	4	4	4	4	2	2	2	2	0	0	0	0
13	6	8	8	6	6	8	8	8	8	8	8	8	8	8	6	6	8	8	8	6	6	6	4
14	6	6	8	6	6	8	6	8	6	8	8	6	6	8	8	8	8	4	4	4	4	4	4
15	6	6	6	4	4	6	6	6	6	8	8	6	6	6	8	8	8	2	2	2	2	2	2
16	3	2	2	3	3	2	2	2	2	3	3	4	4	3	3	4	4	0	0	1	1	0	0
17	2	3	3	3	3	3	2	2	3	3	3	4	4	4	3	3	3	2	2	1	1	1	1
18	6	6	8	8	6	8	8	6	8	8	8	6	6	6	6	8	8	2	2	4	4	4	4
19	4	3	3	4	3	4	3	3	4	3	3	3	4	4	3	3	3	1	1	2	2	2	2
20	0	2	2	2	2	1	1	4	2	2	2	2	1	1	2	2	2	3	3	3	3	4	1
<b>Total</b>	<b>66</b>	<b>73</b>	<b>73</b>	<b>72</b>	<b>71</b>	<b>75</b>	<b>71</b>	<b>72</b>	<b>73</b>	<b>86</b>	<b>84</b>	<b>84</b>	<b>79</b>	<b>79</b>	<b>79</b>	<b>81</b>	<b>82</b>	<b>47</b>	<b>47</b>	<b>46</b>	<b>46</b>	<b>48</b>	<b>48</b>

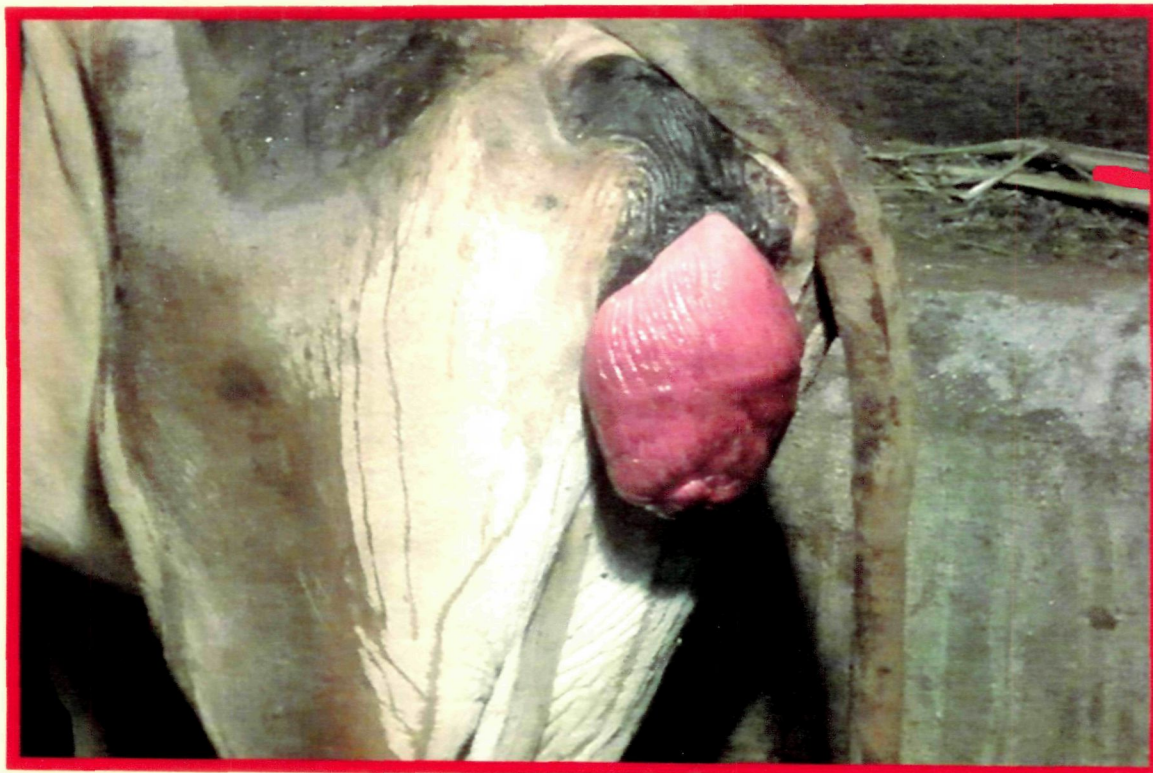**Table 3. Classification of cases of different grades/groups and surgical techniques and antibiotics used their on.**

COW NO.	TOTAL SCORE POINTS	GRADE OF PROLAPSE	SURGICAL TECHNIQUE USED	GROUP OF ANIMAL	ANTIBIOTICS USED
COW NO. 1	44	TWO	(1)- Fixation to Prepublic Tendon	I	Inj. Amoxirum
COW NO. 2	42				
COW NO. 3	40				
COW NO. 4	40				
COW NO. 5	48				
COW NO. 6	43				
COW NO. 7	46				
COW NO. 8	46				
COW NO. 9	46				
COW NO. 10	50	TWO	(2)-Button Suture Fixation	II	Inj. Amoxirum
COW NO. 11	36				
COW NO. 12	36				
COW NO. 13	46				
COW NO. 14	47				
COW NO. 15	47				
COW NO. 16	45				
COW NO. 17	67	THREE	(3)-Amputaion of Prolapse	III	Inj. Cefriaxone
COW NO. 18	67				
COW NO. 19	64				
COW NO. 20	69				
COW NO. 21	71				
COW NO. 22	63				
COW NO. 23	58				
COW NO. 24	66				
COW NO. 25	73				
COW NO. 26	73	THREE	(4)- Submucosal Resection of Vagina	IV	Inj. Cefriaxone
COW NO. 27	72				
COW NO. 28	71				
COW NO. 29	75				
COW NO. 30	71				
COW NO. 31	72				
COW NO. 32	73				
COW NO. 33	86	FOUR	(5)- Pan-hysterectomy	V	Inj. Enrofloxacin
COW NO. 34	84				
COW NO. 35	84				
COW NO. 36	79				
COW NO. 37	79				
COW NO. 38	79				
COW NO. 39	81				
COW NO. 40	82				
COW NO. 41	47	TWO	(6)-Bilateral Ovariectomy	VI	Inj. Enrofloxacin
COW NO. 42	47				
COW NO. 43	46				
COW NO. 44	46				
COW NO. 45	48				
COW NO. 46	48				

**Plate 1 : Different Grades of Cervico-Vaginal Prolapse**

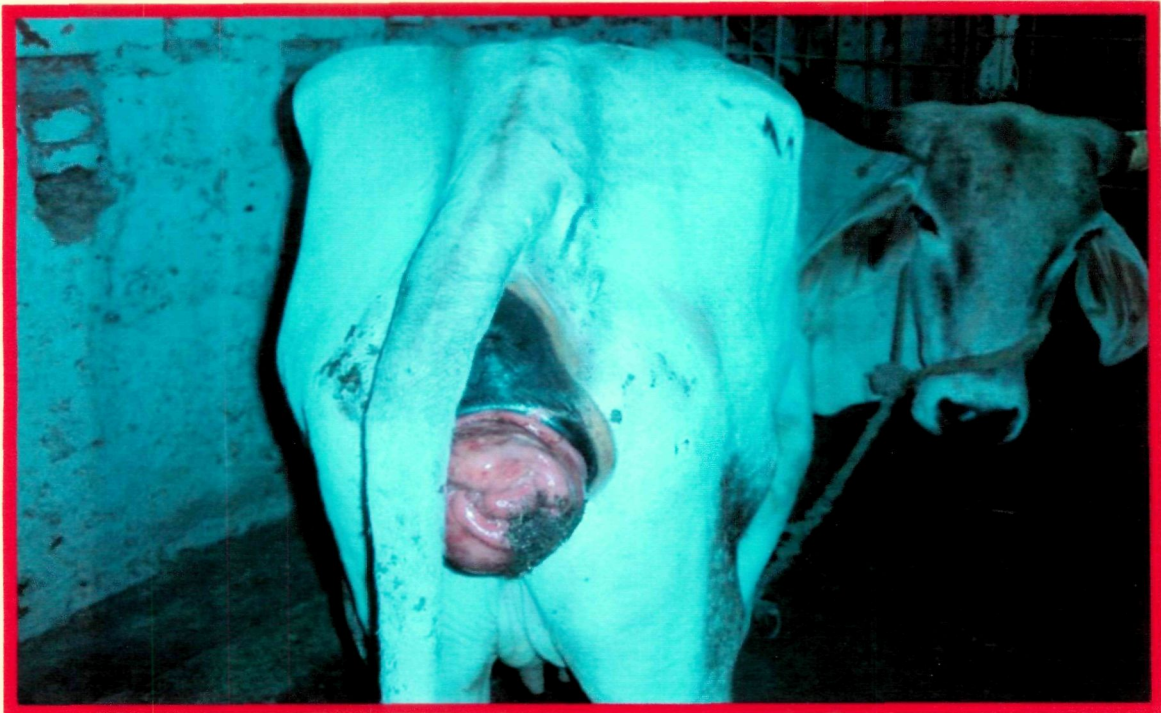

**A) Grade I cervico-vaginal prolapse**

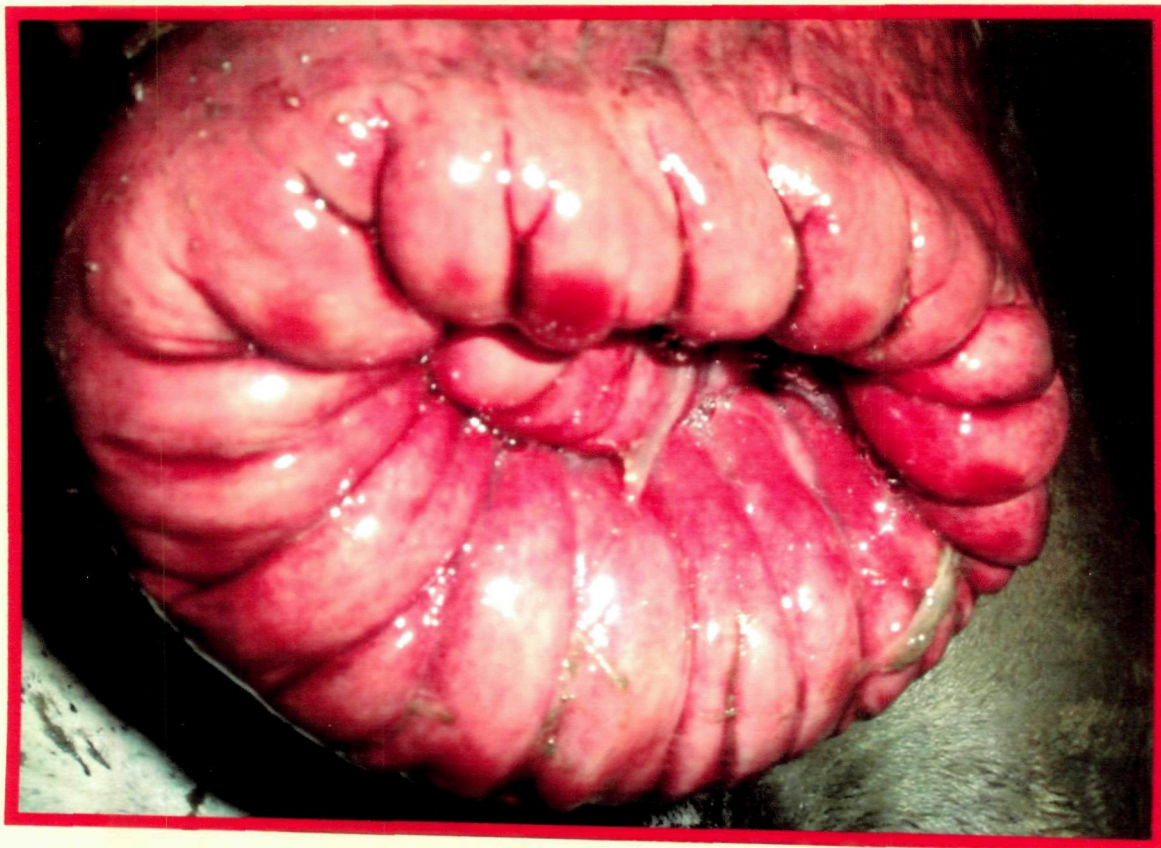

**B) Grade II moderate cervico-vaginal prolapse**

## **Plate 1: Different Grades of Cervico-vaginal Prolapse**

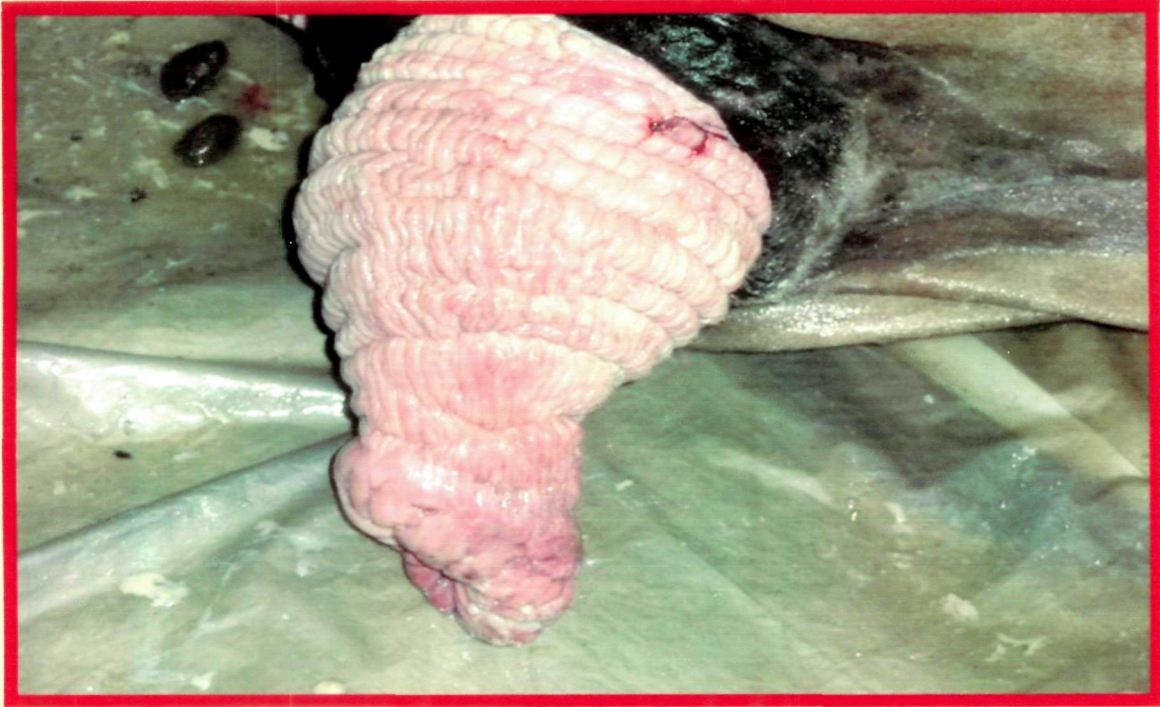

**C) Grade II prolapse with os cervix near proximal commissure of vulva**

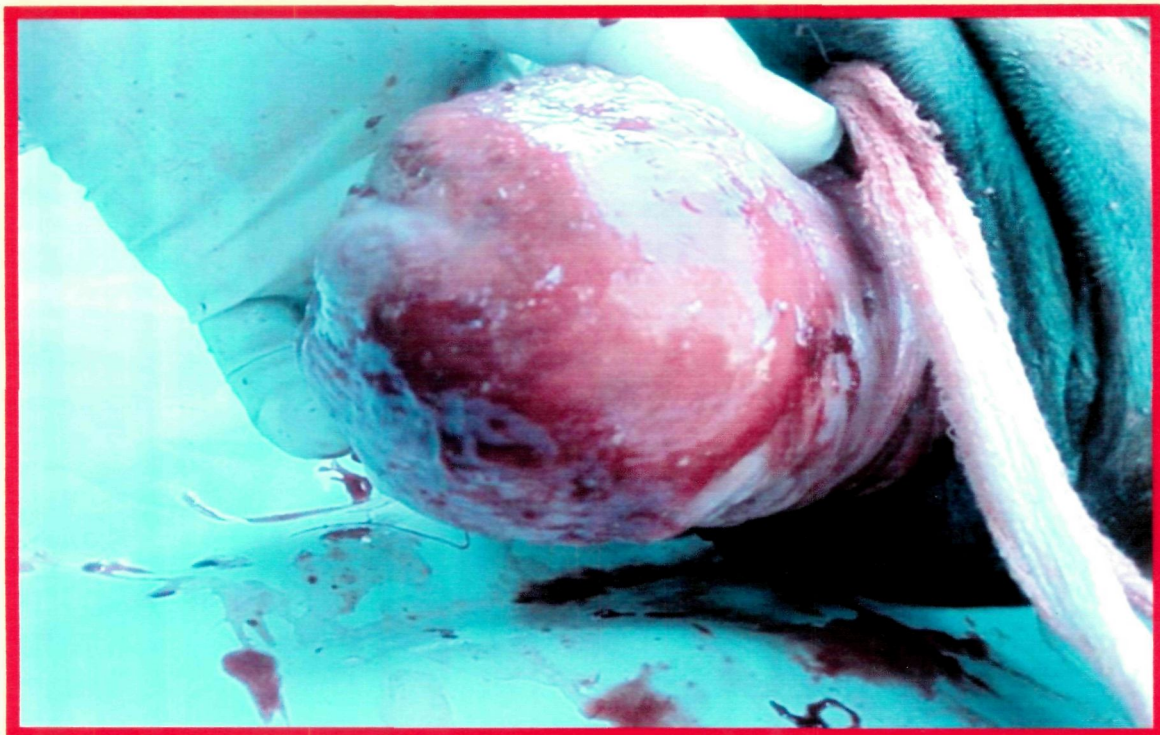


**D) Grade III prolapse with enlarged os cervix**

## **Plate 1: Different Grades of Cervico-vaginal Prolapse**

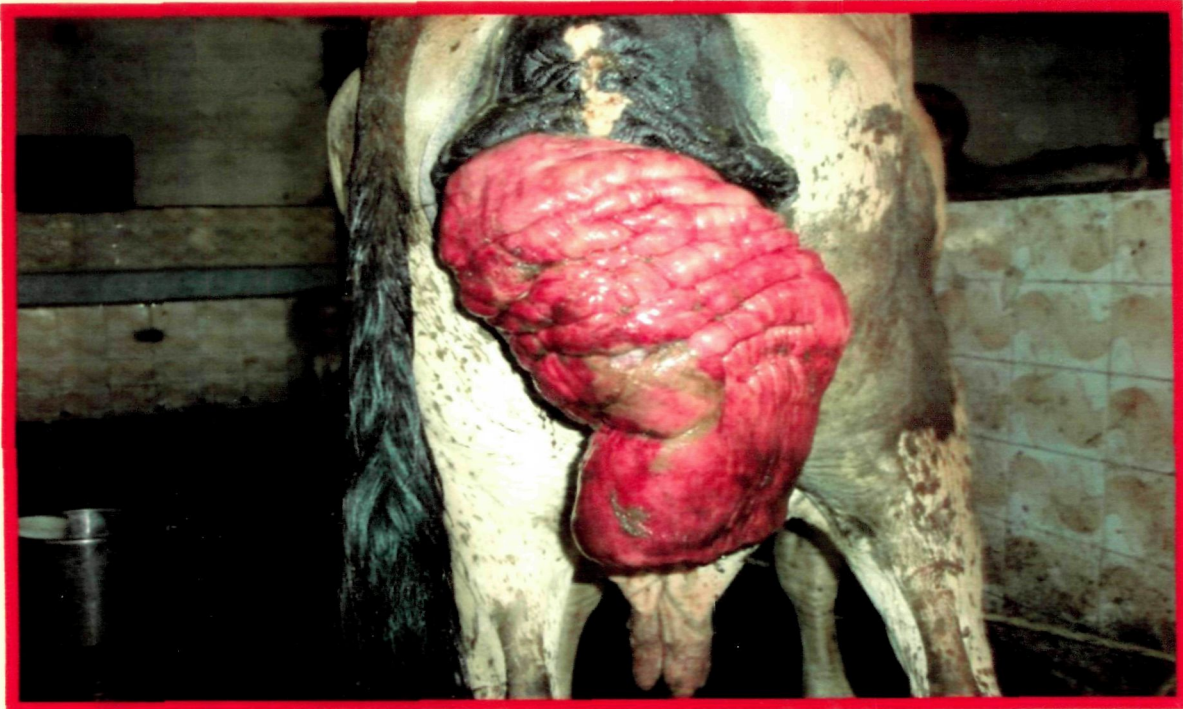


**E) Grade III prolapse with extensive vaginal enlargement**

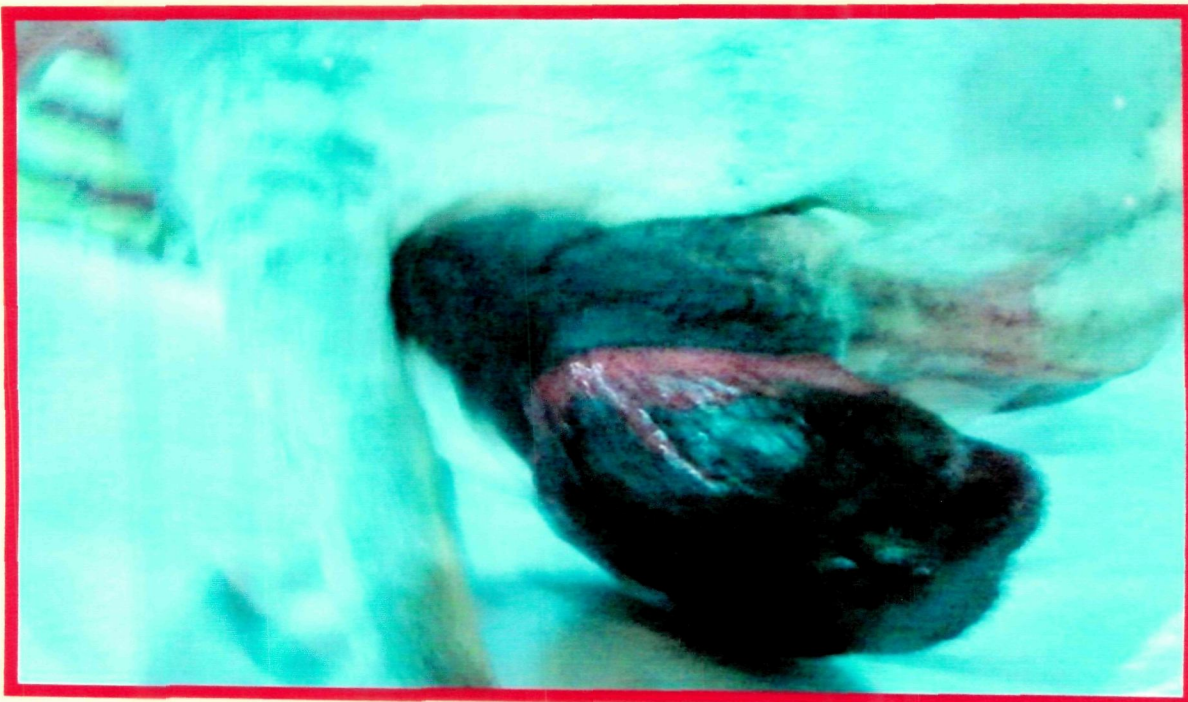


**F) Grade III prolapse with fibrosed thick vagina**

## **Plate 1: Different Grades of Cervico-vaginal Prolapse**

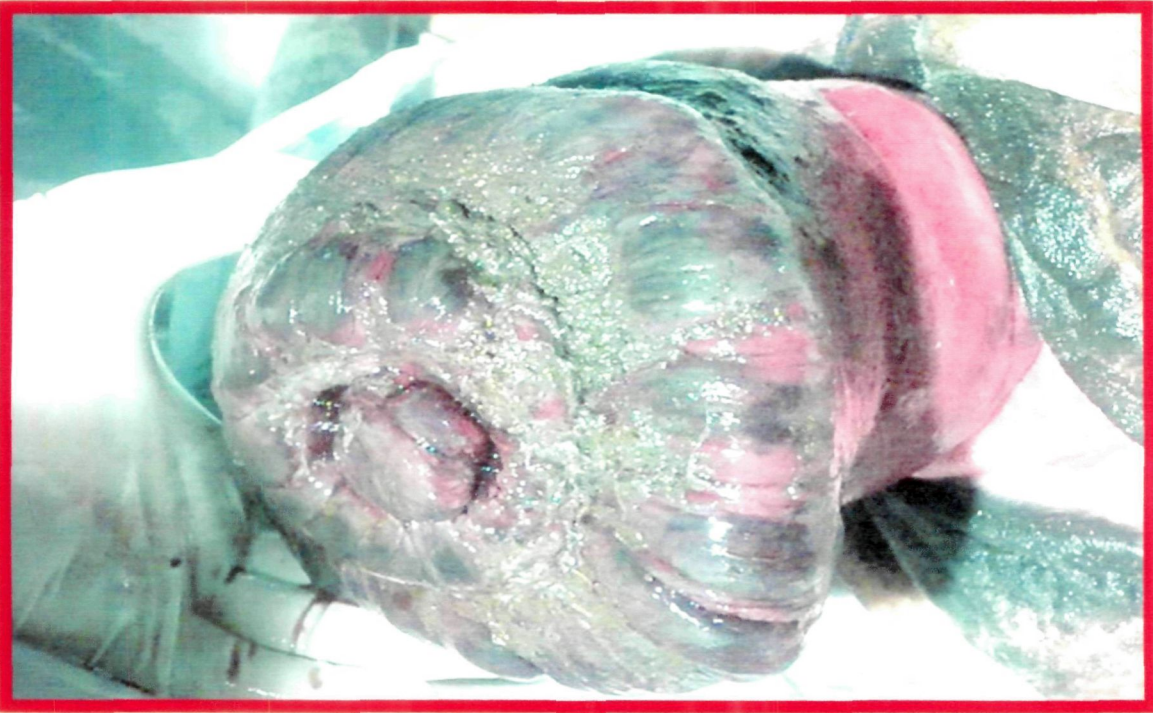


**G) Grade IV prolapse with extensive size and inflammatory changes**

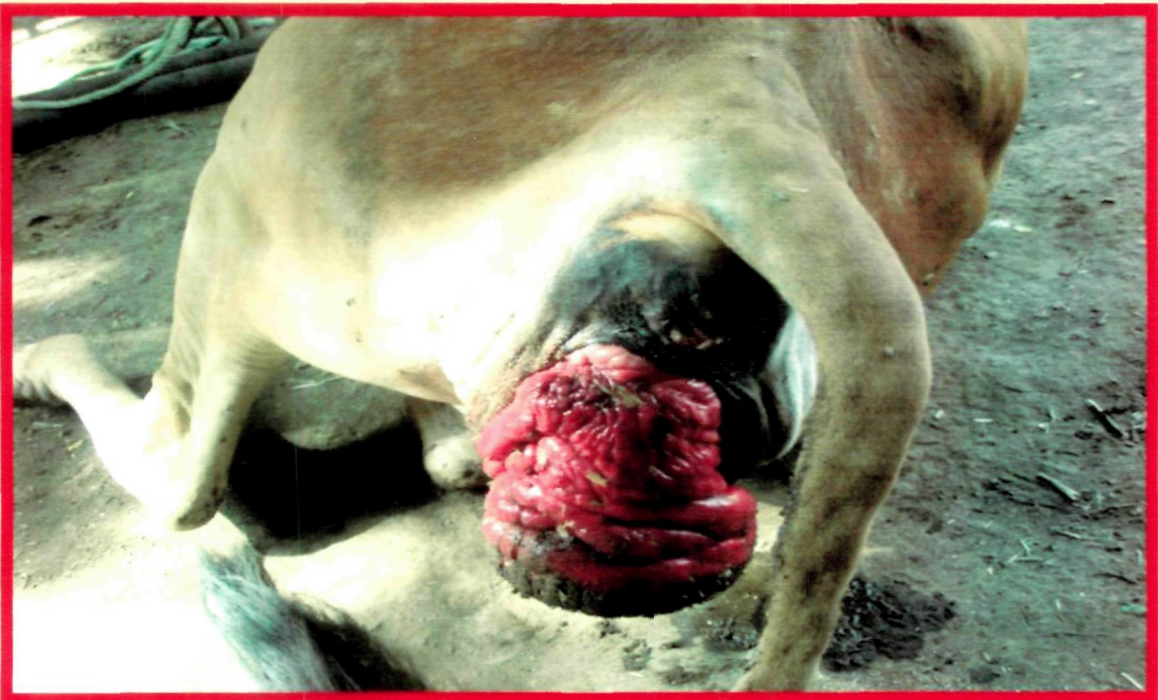

**H) Grade IV prolapse with sever necrosis and gangrene**

## **Plate 1: Different Grades of Cervico-vaginal Prolapse**



**I) Grade IV prolapse with extensive enlarged and necrosed os cervix**

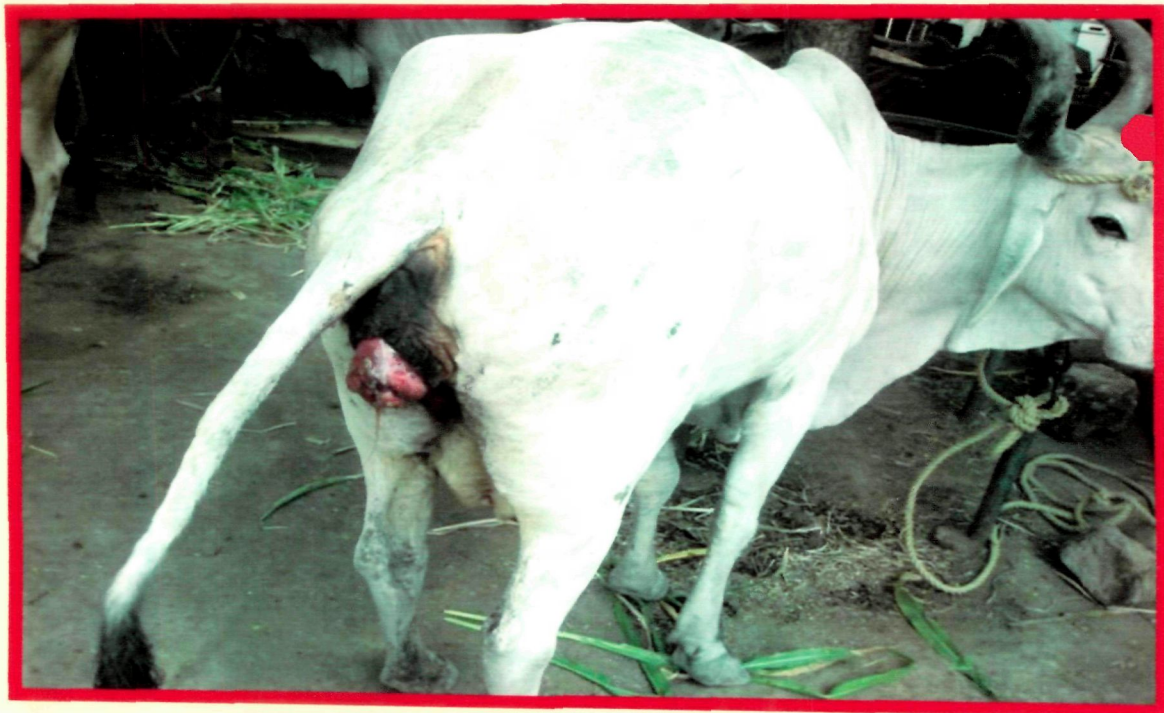

**J) Grade IV prolapse with enlargement, necrosis and lacerations**

## **Plate 2: Clinical Symptoms in Cows of CVP**

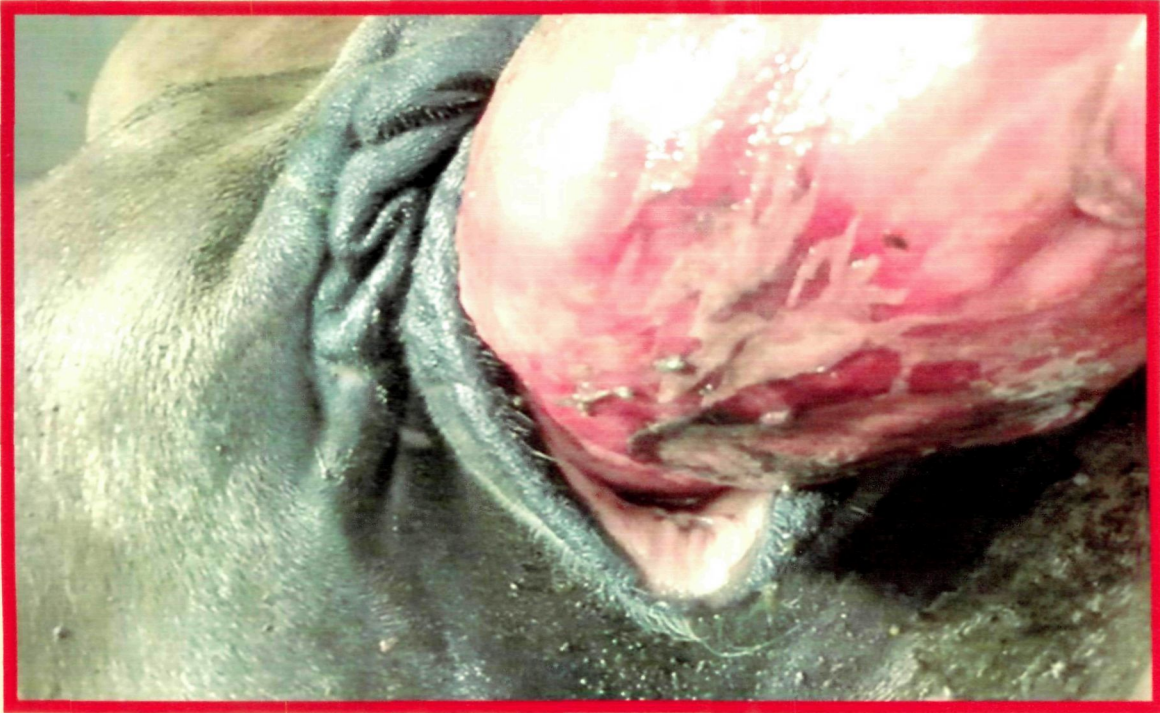

**A) CVP with mucopurulent discharge**

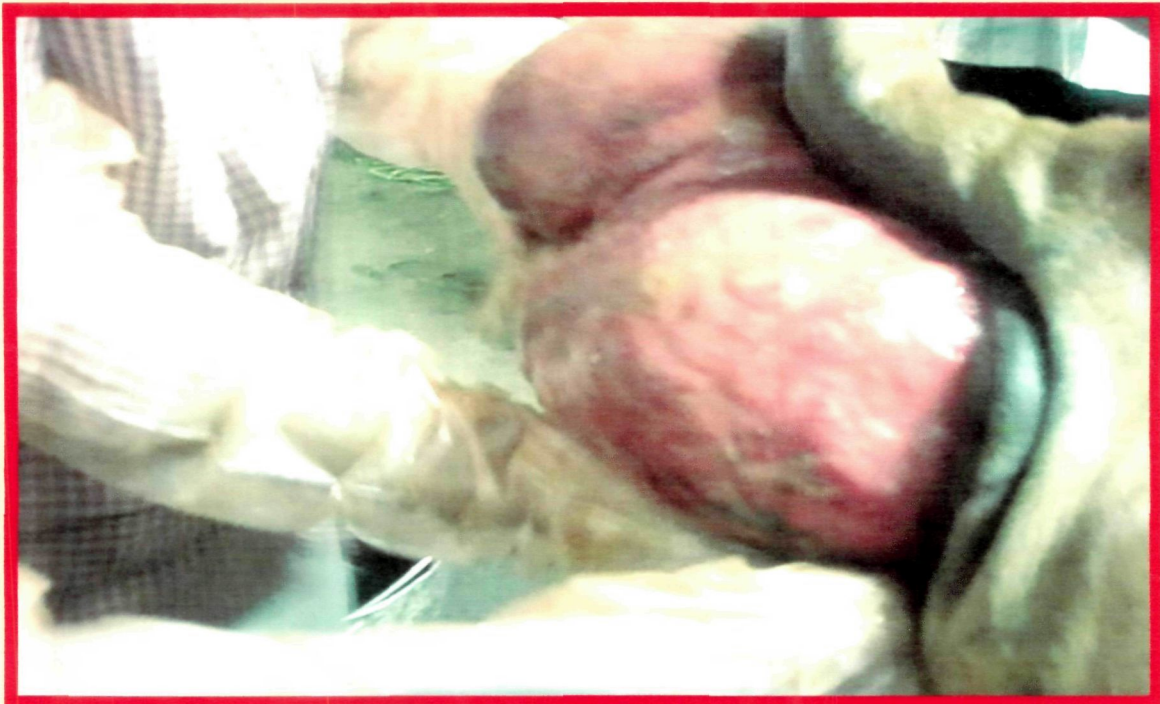


**B) Cow showing straining with discharge**

## **Plate 2: Clinical Symptoms in Cows of CVP**



**C) Distended and displaced bladder in the prolapsed vagina**



**D) Eversion of urinary bladder in prolapsed mass**

Prior to surgery, general health of the animal and nature of the prolapse were accessed by clinical and physical examination. The cases were graded as per the method mentioned above, in increasing order of severity of prolapse from Grade I to VI. No case fell in Grade I in this work. The cases were grouped from I to VI as per the surgical technique utilized. In group I to V, eight cases each and in Group VI, six cases were included (**Table 3**).

Technique 1 and 2 were fixation (retention suture) type technique. They were employed in less severe cases of prolapse as Grade II. (**Plate 1 B**) The excision type technique, 3 and 4 were utilized in the cases of severe prolapse Grade III and IV.

When the prolapsed mass was mainly involved with hyperplasia, fibrosis, and proliferation of the outer vaginal layer, technique 4 was utilized (**Plate 1 D**). In these cases, the prolapsed involved superficial lacerations on the outer layer, but it was viable and reducible without strong adhesion. Technique 3 was employed in the cases where the prolapsed mass was not completely reducible due to adhesions. There were deep lacerations on the prolapsed mass and abnormalities of the cervix, such as kink cervix, hard thickening, gross enlargement of the cervix, excess growth or projections on the os cervix. Cases were not assigned only on the grade of prolapse, but within the grade what kind of excision technique was required to conserve the genital tissue.

Technique 6 was employed in the cases when the ovaries were found abnormal and suspected to predispose for genital prolapse. Technique 5 was indicated for advanced and unmanageable case of CVP. These were highly suffering and with nonviable appearance of the prolapsed mass. The intention was to evaluate these techniques to prevent recurrence of prolapse and conserve these organs in not so old and healthy animals.

### 3.3 Surgical Procedures / Techniques Followed

#### 3.3.1 Preparation of Animal

The cow was fasted for 24 hours, and water withheld for 15 hours prior to surgery. The cow was secured in a trevis, urine removed by catheterization, back racking done and hind quarters were cleaned. Site of epidural injection was shaved and prepared aseptically. Prolapsed genitalia was thoroughly scrubbed.

#### 3.3.2 Peri-operative Medication

The cow was premedicated with dexamethasone<sup>2</sup> 20 mg, meloxicam<sup>3</sup> 15 ml and profenvet<sup>4</sup> 15 ml. Depending on antibiotic assigned to each group, the loading dose was given. In addition metronidazole<sup>5</sup> @ 5 mg/ kg was given intravenously. The I/V line was maintained to give 10 % Dextrose normal saline<sup>6</sup> (2 litres), Ringer lactate solution<sup>7</sup> (one litre). Injection calciplus<sup>8</sup> (10 ml), Tonophosphon<sup>9</sup> (10 ml), Haemaccel<sup>10</sup> (1 litre). Carbazochrome<sup>11</sup> (15 ml) was also given in needy cases.

#### 3.3.3 Anaesthesia and Restraint

Xylazine<sup>12</sup> 0.05 mg/kg was given intravenously 10 minutes before the procedure. Both pudic nerves were blocked with McFarlane's technique (1963) using 20 ml

---

<sup>2</sup> Inj. Dexamethasone 10 ml : Dexamethasone 4 mg/ml, Vetindia

<sup>3</sup> Inj. Melonex : Meloxicam 5mg/ml, 30 ml, Benzyl Alcohol B. P. 2% w/v, Intas Pharmaceutica l Ltd. Ahmedabad

<sup>4</sup> Inj Profenvet : Ketoprofen 100 mg/ml, 100 ml, Benzyl alcohol I.P. 1 % w/v., Vetindia

<sup>5</sup> Inj. Metren : Metronidazole I. P. 5 mg/ml, 100 ml, Vetsfarma, Waer for injection I.P

<sup>6</sup> Inj. 10% Dextrose normal saline : Inj. Dextrose 10% , sodium chloride 0.9%, 500 ml, Prem

<sup>7</sup> Inj. Ringer Lactate : Inj. Ringer Lactate; 500 ml Baxter Ringer Lactate solution for injection

<sup>8</sup> Inj. Calciplus : Calcium Gluconolactobionate 137.5 mg, Vitamine D3 5000 IU, Vitamine B12 50 mcg/ml, Vetindia

<sup>9</sup> Inj. Tonophosphan Vet.-Inj. Tonophosphan, sodium salt of 4 dimethylamine 2-methyl phenyl phosphonic acid 0.2gm/ml, 30 ml, Intervet (SPAH). Intervet India. Pvt. Ltd. Pune-412207

<sup>10</sup> Inj. Haemaccel + Haemaccel I.V. fluid. Polymer from degraded gelatine 3.5gm equivalent to nitrogen content of 0.639m electrolytes and sterile distilled water to 100 ml. Made isotonic with polypeptides. 500ml. Piraml HC, New Delhi

<sup>11</sup> Inj. Adchrome 10. Adrenochrome Monosemi CARbazone I.P. 10 mg/ml, 30ml, G. Loucats

<sup>12</sup> Inj. Xylazine : 20 mg/ml, Indian immunologicals Ltd, Hydrabad- 500002

lignocaine hydrochloride<sup>13</sup> on each side. The site of insertion of needle for pudic nerve block was determined by using the anterior tuberosity of the tuber ischii as a fix point and the length of the sacro-tuberous ligament as a radius. This distance was used on a line parallel to the midline anterior to the fix point. A skin wheel was made with 2 ml of local analgesic. Left hand was introduced into the rectum and the lesser sciatic foramen was located. A 18 gauge 12 cm long spinal needle was inserted on the right side at the skin site and directed towards the middle finger held in the foramen until the point could be felt to lie along side the nerve. Fifteen ml of analgesic was injected at the site. The needle was withdrawn to 5 cm and redirected caudally and dorsally, so that it penetrated the sacro-sciatic ligament at a point about 2 cm above and behind the first injection. Five ml of local analgesic was injected at this point to block the haemorrhoidal nerve. The procedure was repeated by changing the hand on the opposite site.

Epidural injection was administered between 1<sup>st</sup> and 2<sup>nd</sup> coccygeal vertebrae using 10-15 ml of lignocaine hydrochloride. The animal was secured either in standing or cast position raising its hind quarters with supports.

### **3.4 Clinical Groups and Surgical Techniques Followed**

#### **3.4.1 Group I (Fixation to Prepubic Tendon)**

After repositioning the prolapsed mass, it was checked for anatomical disposition. A half circle triangular cutting needle of 10 cm length was bent into U shape. A long silk No. 3 of about 75 cm was attached to the needle. The threaded needle was carried into the vagina by protecting in the palm of right hand. The attachment of left prepubic tendon was palpated on floor of pelvis. The short band of the tendon on each

---

<sup>13</sup> Inj. Lignocaine : Lignocaine HCL 2%, 30 ml Cadila vet, Ahemedabad

side arising from iliopectineal eminence was felt extending anterior and ventral to pelvis. With the right hand, the urinary bladder was catheterized. Now the point of the needle was inserted in the vaginal floor close to vaginal end of cervix. The needle was directed through the triangular area bounded by attachment of prepubic tendon on the anterior border of pubis and onto the iliopectineal eminences. It was then brought through to the mid line, back up through the tendon and into the vaginal floor. A bite of about 2 cm was taken into the prepubic tendon while that in the vaginal floor was of 5 cm. The needle and the long end of the suture were pulled out through vagina. Before finally tying the suture, it was ascertained by per vaginal palpation if the vaginal wall was secured to the tendon and then the knot was tied. Similar procedure was repeated on the right prepubic tendon.

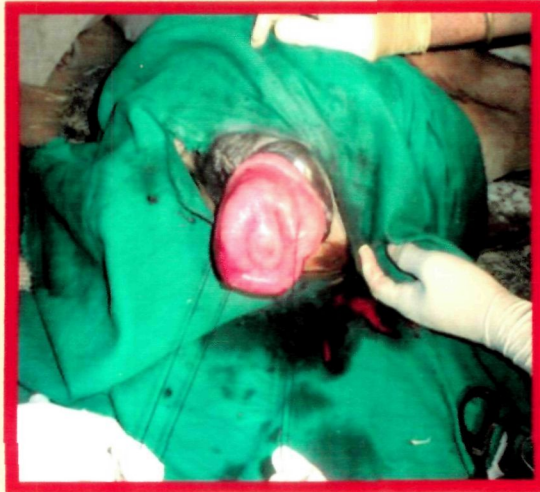#### **3.4.2 Group II (Button Suture Fixation – based on Minchev’s Technique) (Plate 3)**

Straight triangular cutting needle of size 1 was used for this procedure. No. 3 non absorbable suture (silk)<sup>14</sup>, about 75 cm long, was threaded to the needle. Before repositioning the prolapse mass, a bite of the suture was placed in the fornix of vagina just caudal to cervix by entering the mucosa and submucosa. It was taken out at a distance of about 5 cm. A heavy duty plastic button was threaded through this suture to lie against the prolapsed mass. Two such sutures were placed on either side (left and right) of the vaginal wall. Now, the prolapsed mass was repositioned. Another needle of same pattern was now placed on the second end of the suture. Each needle was carried into the vagina. The needle was directed through the dorsolateral vaginal wall close to cervix to emerge through sacrosciatic ligament to emerge at gluteal region. Sufficient

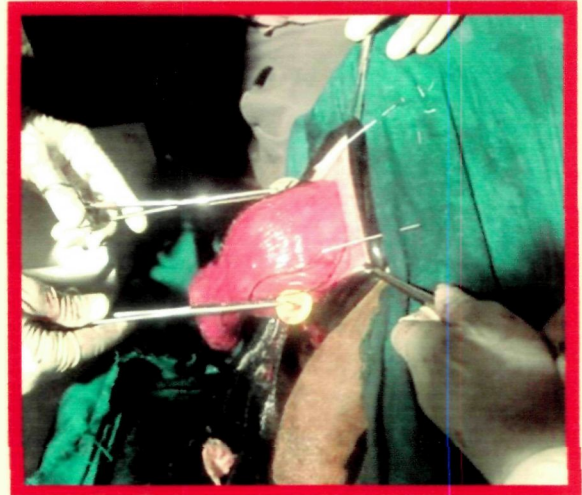
---

<sup>14</sup> Silk suture- Silk suture 2-0, Black braided silk, Non- Absorbable suture, Eticon. Johnson and Johnson

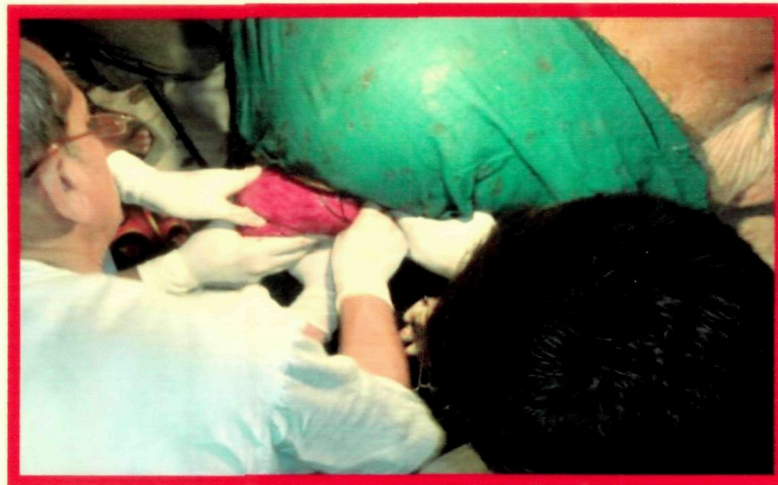## Plate 3: Technique 2-Button Suture Fixation



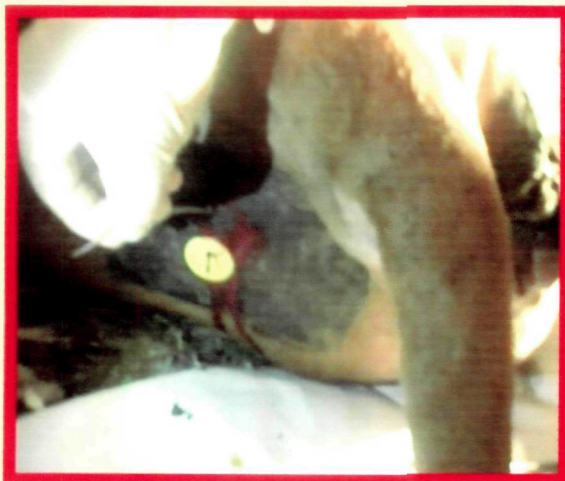**A) Sutures placed in the fornix of vagina**



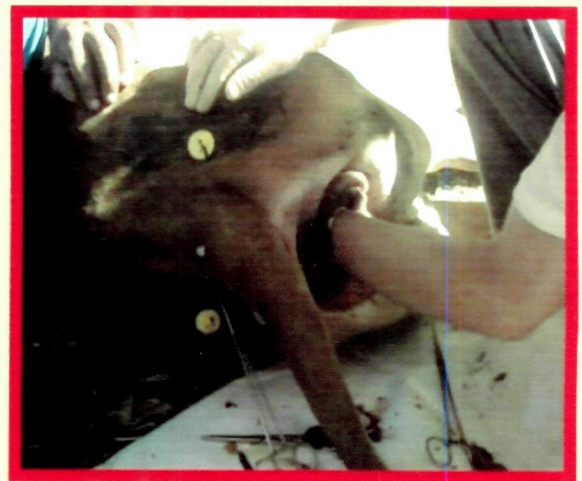**B) Internal buttons preplaced on the prolapse mass**



**C) Reposition of prolapse**



**D) External left button fixation**



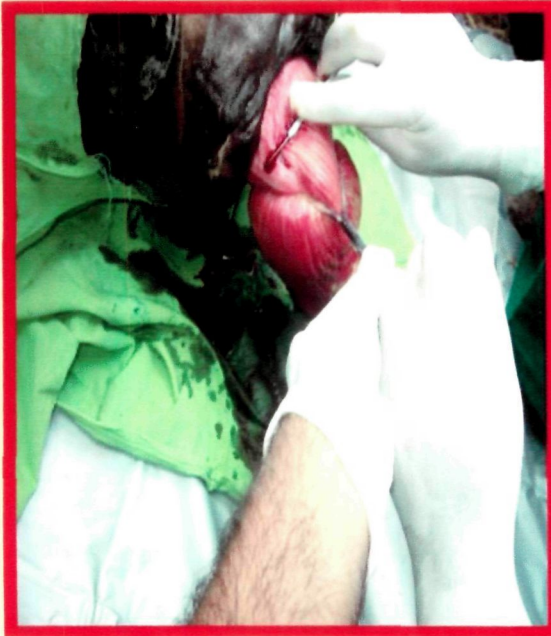**E) Both external buttons fixation**

care was exercised to avoid bite in the rectal wall and also avoid iliac artery and vein. As both the ends of the suture emerged out at the gluteal region another plastic button was inserted through the two free ends. Finally, a tie was made over the button on the gluteal region.

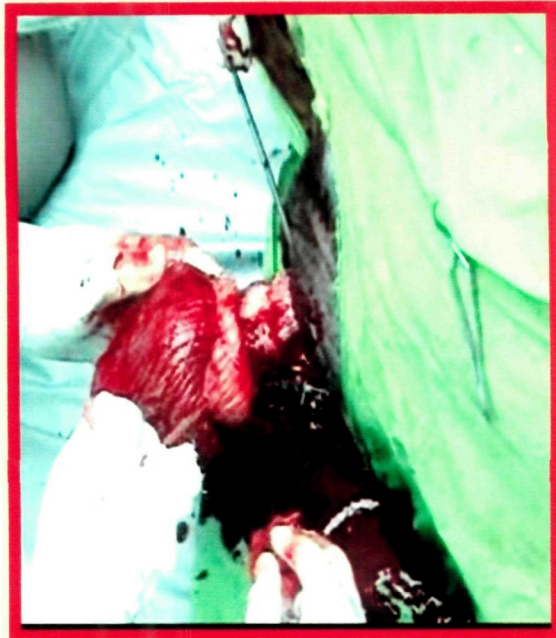### **3.4.3 Group III (Amputation of Prolapsed Mass)(Plate 4)**

In this group, amputation of the prolapsed mass was carried out. After washing the mass, further portion of the mass was everted by manipulation to bring healthy wall outside at the vulva. A tourniquet was applied around the prolapsed mass as high as possible near the vulvar commissure to control the bleeding. The ends of the tourniquet were kept long enough to keep traction so as to facilitate access to the prolapsed mass. The ventral wall of the vagina was checked to keep the urethral meatus ahead of the tourniquet. A semilunar incision from nine to three O'clock position was made in the dorsal vaginal wall, three inches below the tourniquet. It was deepened through complete thickness of the outer layer of prolapsed mass. This outer layer was grasped with tissue forceps and dissected so as to allow fingers through the incision to feel the structures within. Any blood vessels traversing the field were ligated. The incision was extended over the dorsal half curve of the vaginal wall. This incision was placed five to 7 cm cranial to the vulvar commissure; so that genital tube distal to the incision would retain all three layers of the mucosa, submucosa and serosa in an invaginated manner. Full thickness of outer layer of vagina was incised carefully over the half circular dorsal portion of the prolapsed mass. Any visceral structures like bladder or intestine was pushed back into the abdominal cavity. The incision in the outer layer was carried over the remaining lower half circumference preserving the urethra and the meatus. Strong transfixation ligature was placed on the lateral vascular areas. The incision was further carried in the same transverse manner now through the inner layer. The cut portion of the

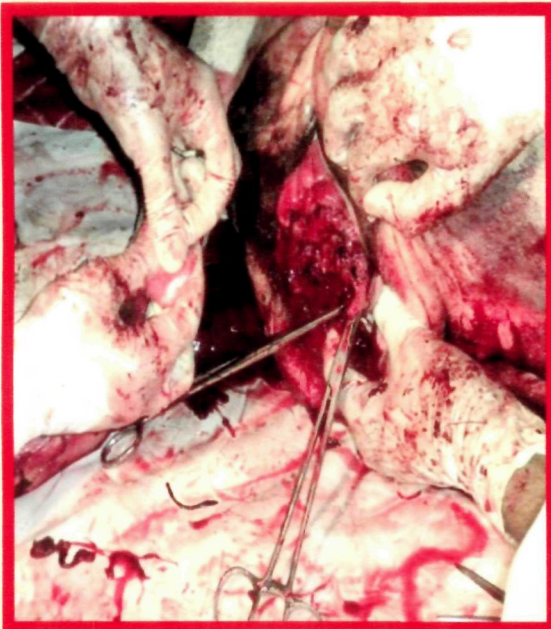
## **Plate 4: Technique 3 - Amputation of Prolapse**



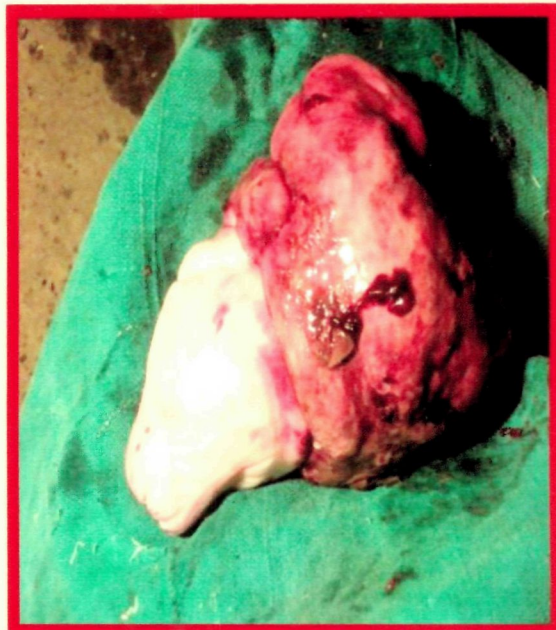**A) Dorsal crescent incision on prolapse mass**



**B) Dissection for amputation of prolapse mass**



**C) Circular closure of outer vaginal layer to inner cervix**



**D) Amputated mass of the os cervix**

prolapsed mass was turned away from the site of incision with Allis forceps. An assistant was presenting the prolapsed mass to facilitate the dissection by the operator. The bleeding was checked. Two ml of Sepgard solution<sup>15</sup> was frequently poured on the site for clotting of the blood and reducing haemorrhage. The transverse incision was carried through the inner invaginated tube of enlarged and hard caudal portion of cervix. The incised mass was separated from the loose connective tissue by blunt dissection. Thus about two third portion of the prolapsed mass was incised in a transverse manner. What remained at the stump was the outer rim of the vaginal wall and the inner ring of healthy cervix. The tourniquet was loosened to check any bleeding. The borders of the two tubes were sutured together in two circular layers of the sutures. Suturing was commenced from right to left with the triangular cutting needle No. 3 and Vicryl No. 2<sup>16</sup> in a continuous lock stitch manner. The needle was passed from outside to include all thickness of the outer vaginal wall and then the full thickness of the rim of cervix. After completion of suturing, an additional layer of continuous sutures was placed to reinforce the remaining structures. Diseased portion was amputated with scalpel. Haemorrhage was prevented by ligatures. The vagina was then repositioned in its natural disposition.

#### **3.4.4 Group IV (Submucosal Resection of Prolapsed Mass)(Plate 5)**

Submucosal resection or reefing of the everted mass was performed and the cut edges were sutured to each other as follows. A semilunar incision was commenced at 9 O'clock position and carried to 3 O'clock of the prolapsed mass near vulvar lips. It was carried through the mucous membrane and submucosa. Another longitudinal incision perpendicular to previous incision was given starting at 9 O'clock and finishing just in front of the cervical end of the prolapse leaving about five cm of the free margins of the

---

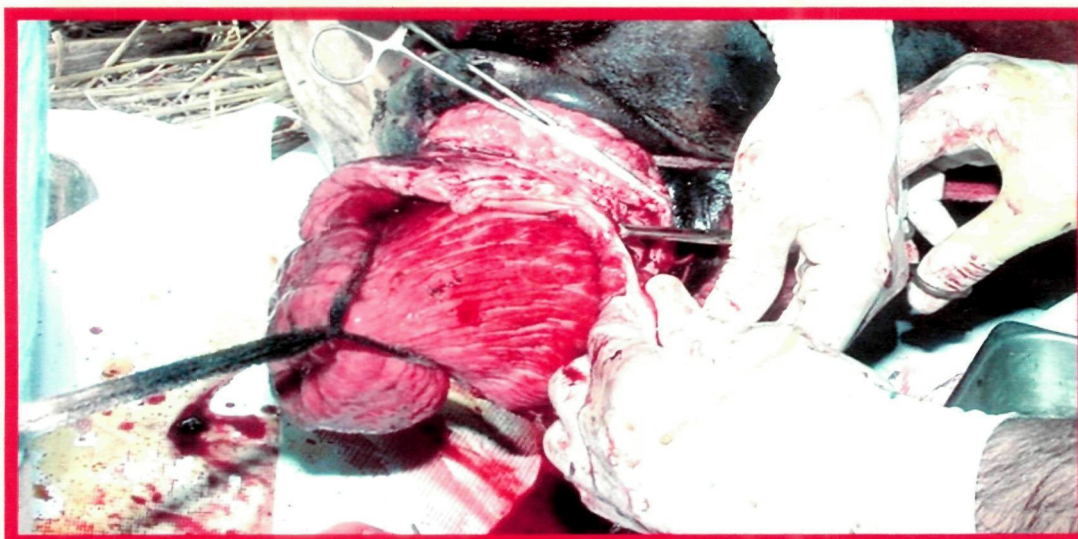<sup>15</sup> SEPGARD Solution, Feracrylum 1% w/v, Themis Medicare Ltd., Goregaon(west), Mumbai.

<sup>16</sup> Vicryl Suture- Vicryl 2-0 suture-synthetic Absorbable suture, 90 cm, Ethicon, Johnson and Johnson

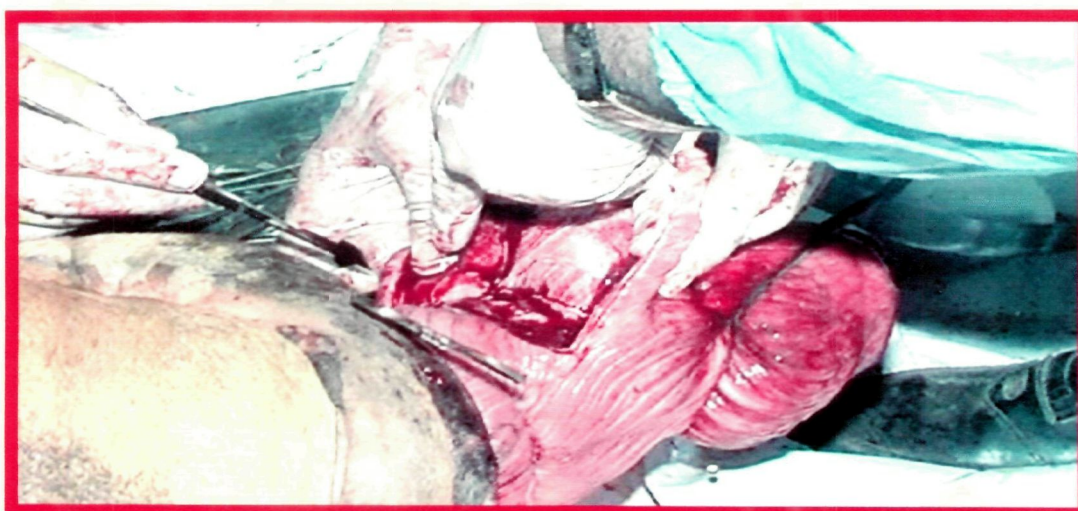
## **Plate 5: Technique 4- Submucosal Resection of Vagina**



**A) Incisions on vaginal mucosa to begin the resection**



**B) Continuation of resection of vaginal submucosa**



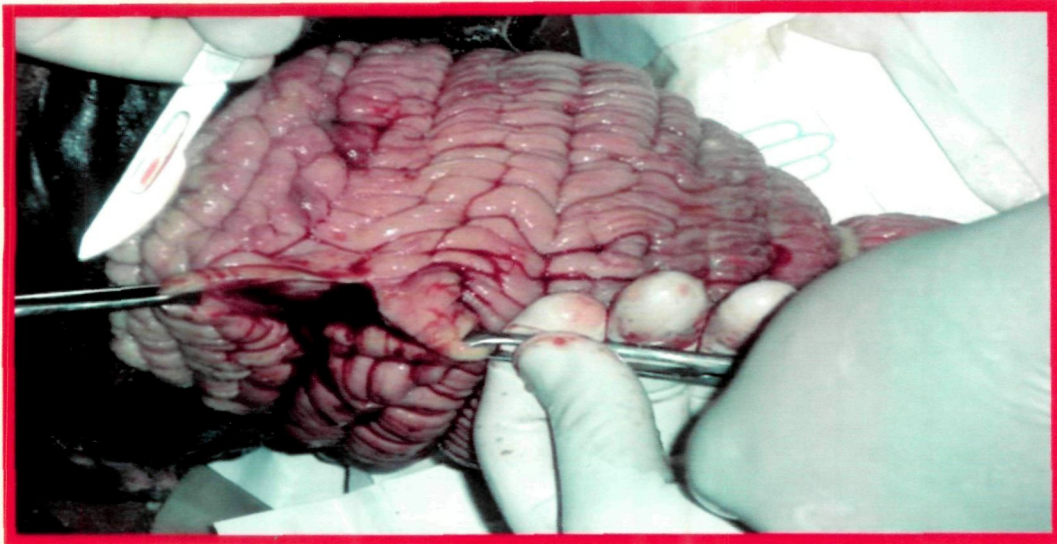**C) Part of the outer vaginal layer resected**

prolapse. Haemorrhage from cut mucous membranes was controlled by ligation and forcipressure. Another parallel longitudinal incision was taken at the other end of the semilunar incision. Free edges of the incisions were carefully undermined to carry out dissection of mucosa and submucosa of the remainder of the prolapsed mass. The undermined mucosa and submucosa were cut to leave a border of distal edge at the cervix. Similar resection was carried out at the ventral wall of the prolapsed mass. Inner invaginated mass was pushed cranially so that the cervical rim was brought close to proximal semilunar incisions. These free edges of the vaginal mucous membrane and the invaginated mass were sutured to each other. Continuous lock stitch pattern of suture was used for this purpose and Vicryl No. 2 was used.

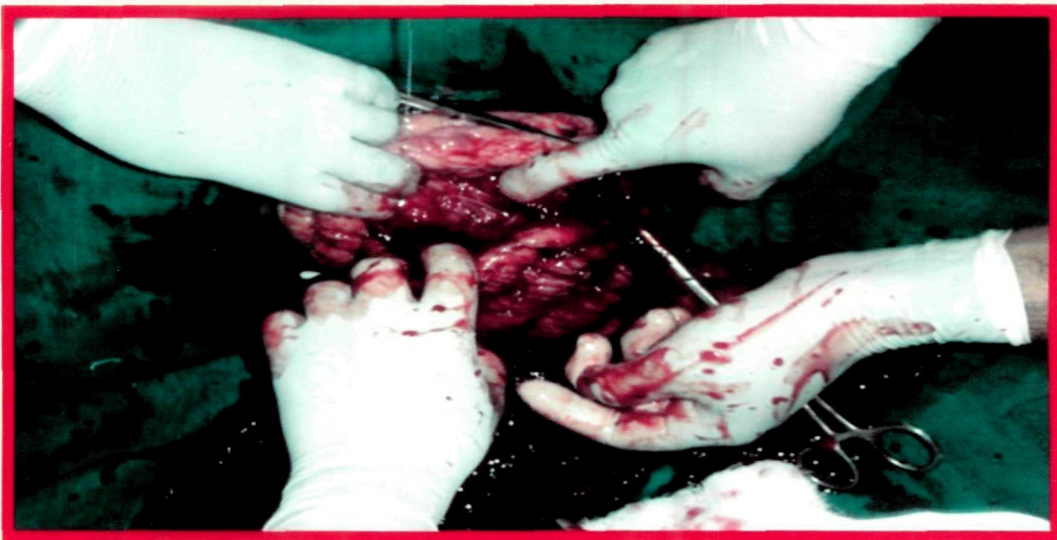#### **3.4.5 Group V (Per vaginum Panhysterectomy)(Plate 6)**

The animal was maintained in right lateral recumbancy. The prolapsed mass was washed and cleaned. A tourniquet was applied closed to vulvar commissure taking care to exclude urethral meatus. An incision between 9 O'clock to 3 O'clock position was given on prolapsed vagina. The incision was carried through the mucosa and submucosa while ligating major vessels and clamping the minor ones. This incision was carried through the full thickness of the vaginal wall to gain access to invaginated cervix. The cervix was gradually and firmly pulled towards the incision allowing palpation of uterine horns and the junction. The cervix, horns and the ovaries were released by blunt dissection with fingers. These structures were dragged to the vaginal incision by constant firm tension. The left ovarian stump was identified and held in tension. A half circle suturing needle threaded with No. 2 Vicryl was passed around the stump and transfixed. The suture was then completed by tying firmly. Another additional suture was passed around the stump to strengthen the previous ligature. During this procedure a constant

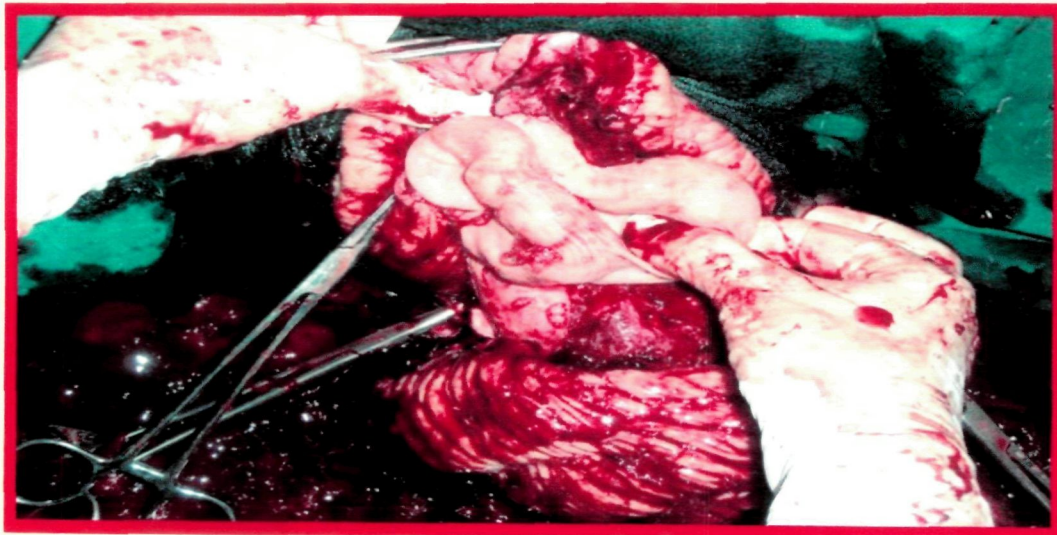
## Plate 6: Technique 5- Panhysterectomy



**A) Incision in the dorso-lateral wall of vagina**

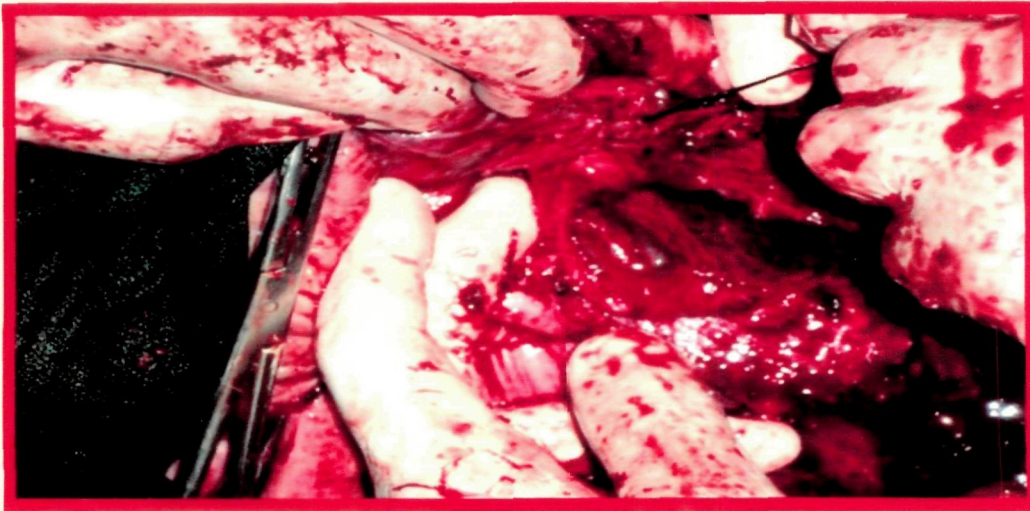


**B) Dissection continued to expose inner tube of genitalia**

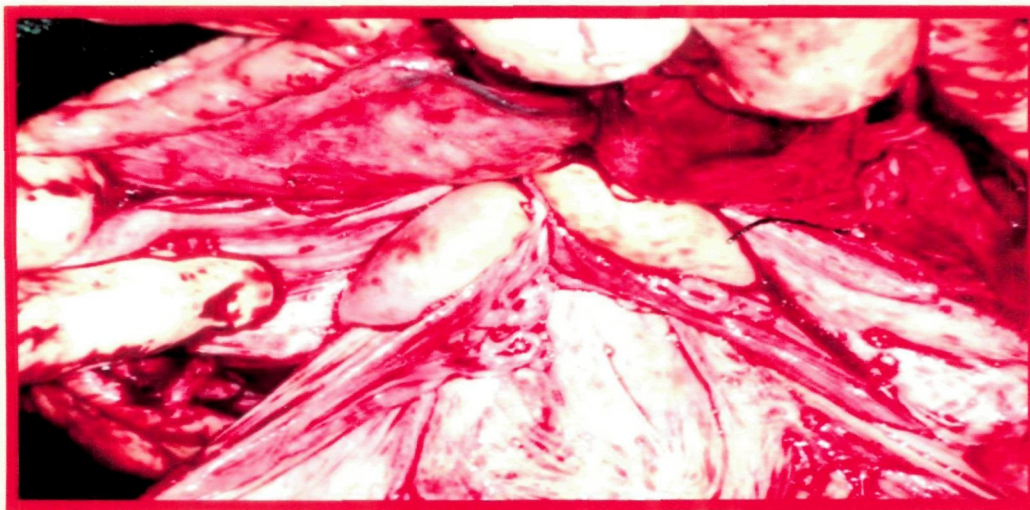


**C) Exteriorization of uterine horns**

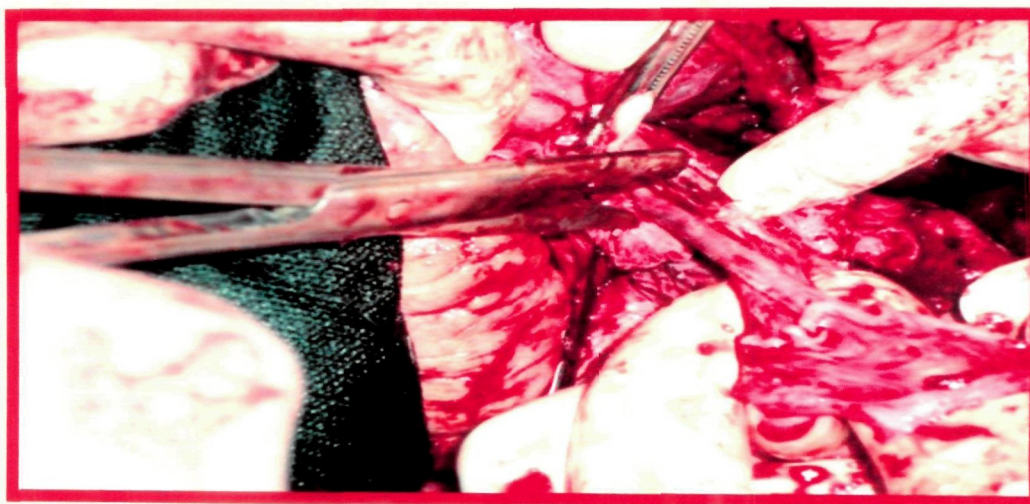
## Plate 6: Technique 5- Panhysterectomy Continued



**D) Ligation of utero-ovarian blood vessels**

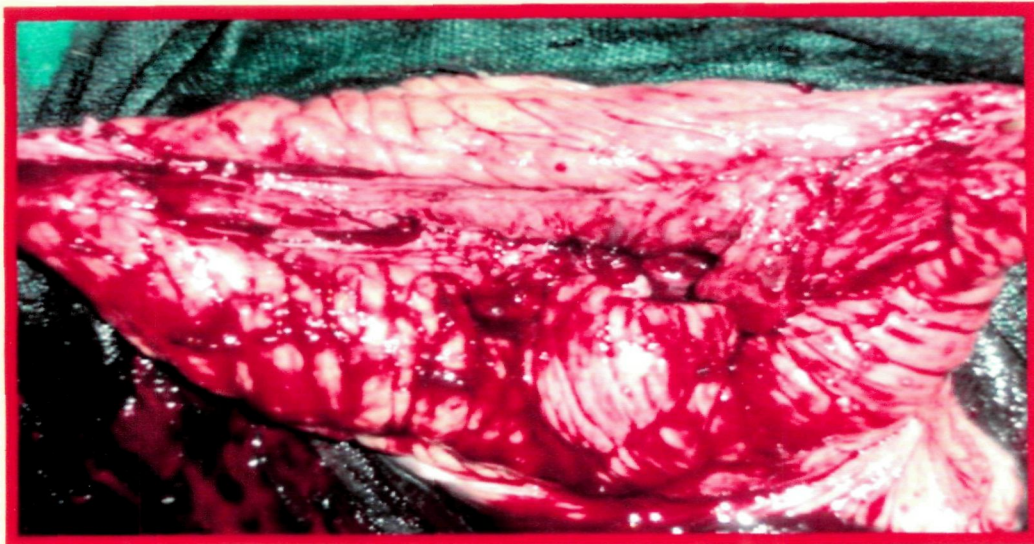


**E) Exposure of both the ovaries**

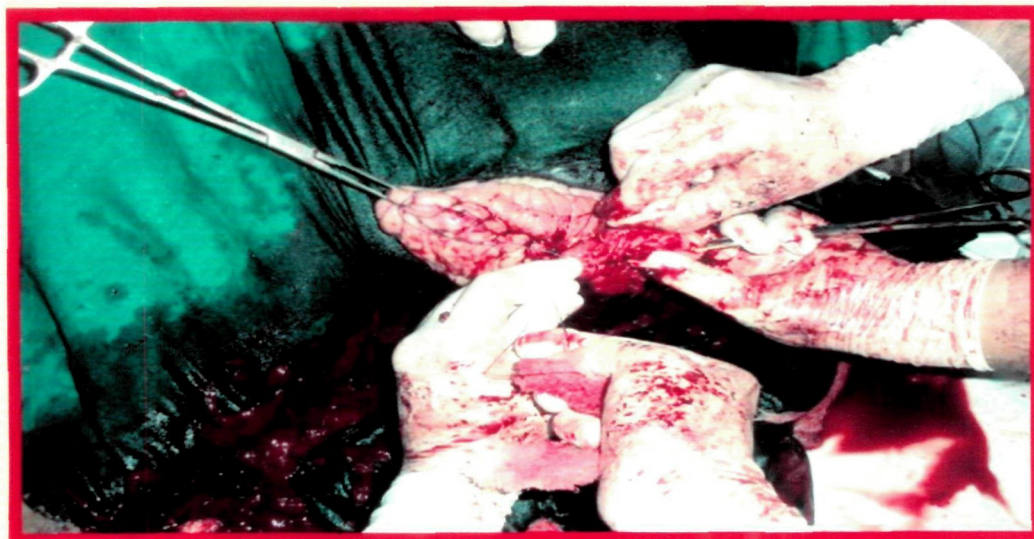


**F) Clamping, ligation and cutting ovarian pedicle**

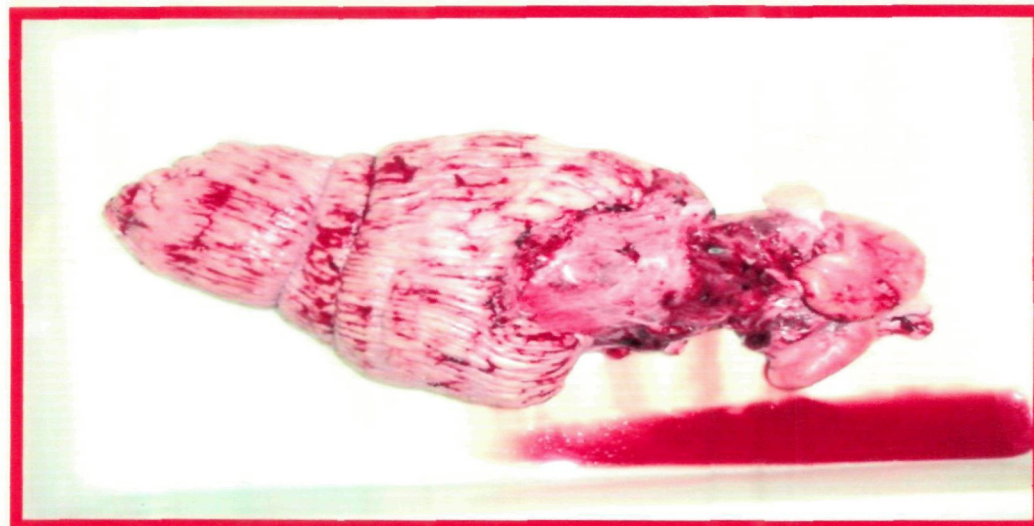## Plate 6: Technique 5- Panhysterectomy Continued



**G) Approximation of vaginal layers for closure**



**H) Closure of vaginum with continuous lock stitch suture**



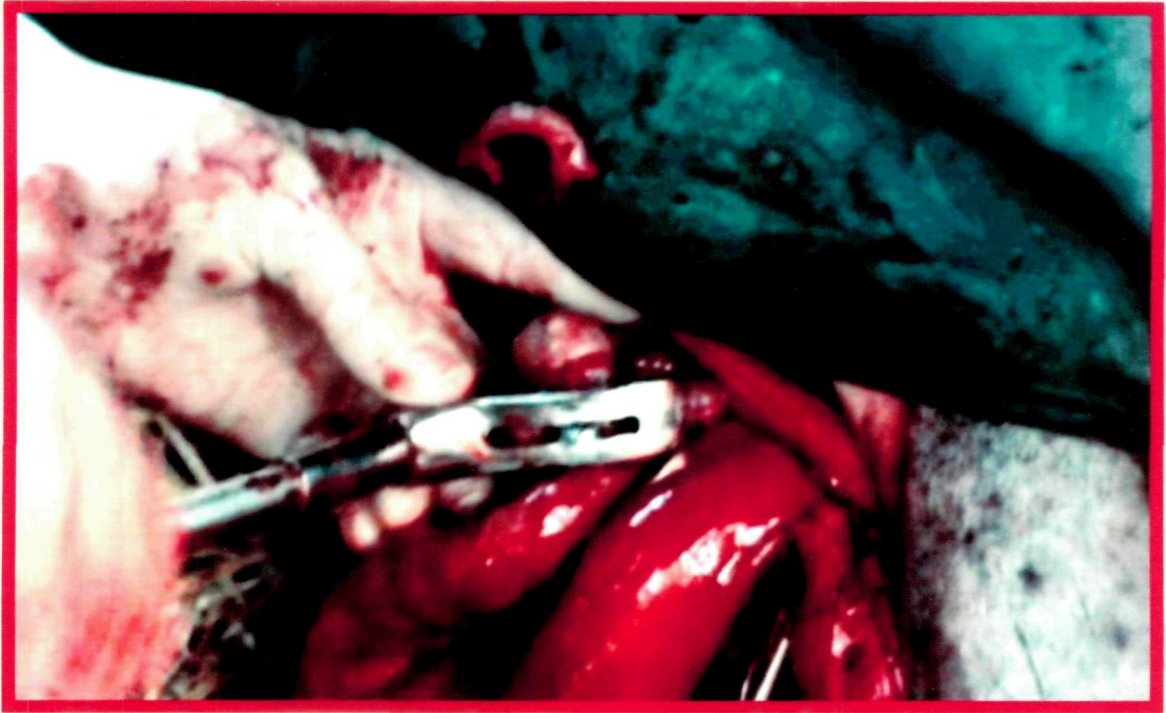
**I) Completely removed genital organs**

firm pressure was maintained. A large crushing clamp was placed distal to the ligatures and held in place. Another clamp was placed beyond the ovary at the junction of bursa and the fallopian tubes. The stump was transected between the clamp and the ovary to release the latter. The stump was released after checking for any bleeding. The broad ligament was carefully dissected ligating major vessels so as to reach the junction of the horns. The right ovary was also dealt similarly. This allowed sufficient mobilization of the horns and ovaries caudally through the vaginal incision. Further, the blunt dissection allowed retraction of the cervix attached with the uterus and the ovaries. The ventral wall of the vagina was cut taking care to retrieve the inner tube of vaginal wall. All bleeders were carefully ligated to ensure complete haemostasis. Care was taken to place this incision beyond urethral meatus. The inner and outer layer of the cut ends of vaginal wall were sutured by using continuous lock stitch suture of Vicryl No. 2, commencing at 9 O'clock position.

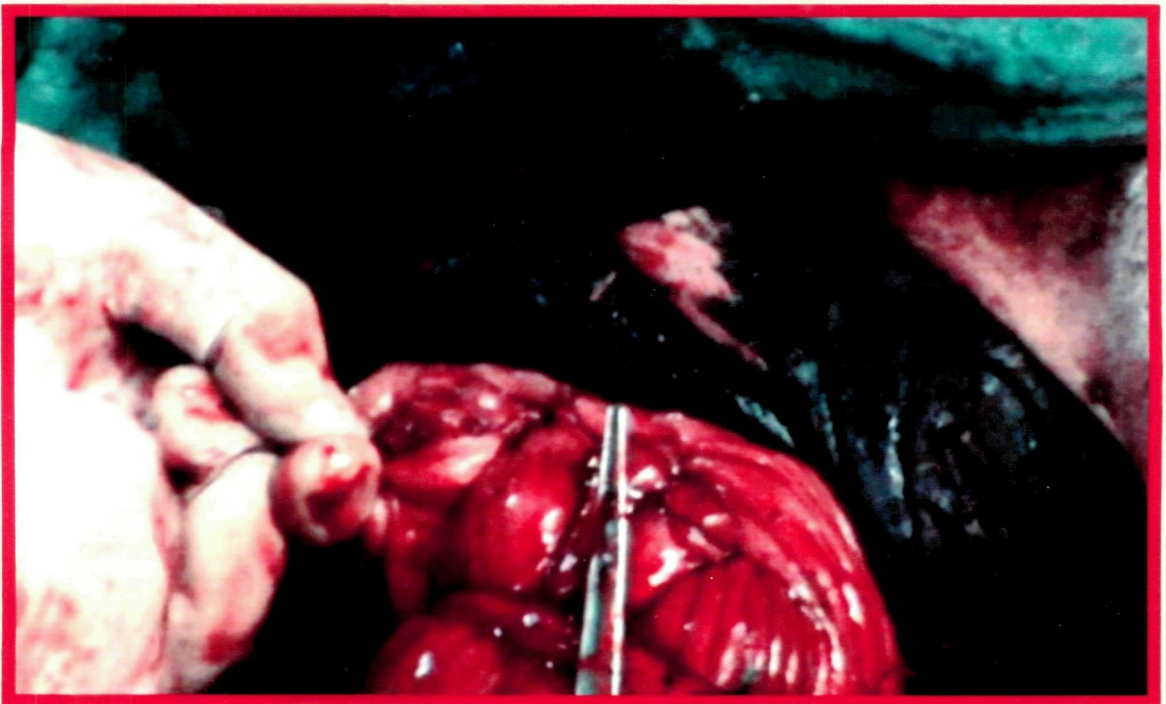
#### **3.4.6 Group VI (Per vaginum Bilateral Ovariectomy)(Plate 7)**

The technique was based on method described by Tank *et al.* (2006). A tourniquet was placed on the distal part of the prolapse so as to retract the prolapsed mass out. A four inch crescent shaped incision was taken on the dorsal prolapsed vagina. The bleeding was controlled by ligation or clamping the vessels. The inner invaginated tube was reached by blunt dissection using fingers passing through the incision. It was carefully examined for the structures involved in the prolapse. The loose connective tissue and fasciae were pushed aside to expose the part of the cervix and uterus. The inner tube of the cervix was grasped with the left hand through the incision to retract caudally and forefinger was placed between the junction of the uterine horns. Thus the inner tube of cervix and uterus was mobilized to have access to the ovaries. Half a minute pause was given for the animal to adjust with the stress of handling. Lignocaine hydrochloride

## **Plate 7: Technique 6- Bilateral Ovariectomy**



**A) Ovariotomy in place**



**B) Closure of vaginal incision**

5 ml was injected at the cranial ends of the uterus close to the ovary. The uterine horns were dragged caudally to expose the right ovary near the vaginal rent. The ovarian pedicle was grasped firmly with the fingers so as to place haemostat on the stump. It was difficult to expose the ovary and the pedicle at the incision for full sight of the operator owing to the tension on the attachments to the sublumbar pelvic wall. The ovarian end of the ovariectomy was passed parallel to the uterine horns through the incision to reach the ovarian pedicle. The base of the ovary was passed in the arch of the ovariectomy. The ovary was held firmly in the arch with complete mass above the cutting edge and the pedicle below. The instrument was always kept parallel to the uterine horns to avoid any damage to the tissues. The knob on the outer end of the ovariectomy was operated to slide the blade on the inner rod slowly over the arched end of the outer rod. The action was like an emasculator. The ovary was detached from the ovarian pedicle. The ovarian stump was checked for any bleeding. The instrument was released and retracted out. The ovarian stump was released in the pelvic cavity. The procedure was repeated on the left side of the uterine horn to remove the left ovary. The tourniquet and the forceps were removed and genitalia were reposed to the normal position. The incision in the vaginal wall was closed with Vicryl No. 2 in a lock stitch pattern with needle No. 3.

In groups III, V and VI, formalized samples of vagina, cervix and ovaries were collected for histological examination.

### **3.5 Post-operative Care and Treatment:**

The animals were given one of the randomly selected antibiotics assigned to the particular group (Amoxirum forte<sup>17</sup> 3 g, in group 1 & 2; Vetaceph Plus<sup>18</sup> 4.5 g, in group

---

<sup>17</sup> Inj. Amoxirum Forte- Inj. Amoxirum Forte : Amoxicillin 3 gm, Sulbactum 1.5gm. virbac, Mumbai

<sup>18</sup> Ceftriaxone, Inj Vetaceph Plus : Ceftriaxone 3gm, Sulbactum 1.5gm vial, Vetcare, Bangalore

3 & 4 and Enrocare<sup>19</sup> 15 ml, in group 5 & 6, all intramuscularly). Supportive treatment used included injections of metren(intra venous), meloxicam, profenvet, calciplus, tonophosphon, intramuscular for 5 days. Surgical site was cleaned with betadine lotion<sup>20</sup>, and dressed with the local application of powder or solution of the same antibiotic as parenteral, until healing.

Four cows in Group IV, were given injection P depot<sup>21</sup> (Progesterone 500 mg) intramuscularly on 8<sup>th</sup> day of surgery.

### **3.6 Post-treatment Observations:**

Animals were closely observed until complete recovery and then followed by feed back or intermittent visit up to 100 days. Observations were made with regards to urination, defecation, and straining, feeding and general behaviour of the animal. The wound was observed for any dehiscence, discharge, haemorrhage and healing. Animals were observed for any recurrence of the prolapse.

### **3.7 Laboratory Analysis**

#### **3.7.1 Haematological Analysis**


Haematological analysis included determination of Haemoglobin (Sahlis' acid haematin method), Packed Cell Volume (Wintrobe's tube centrifugation), Total Erythrocyte Count (TEC), Total Leucocyte Count (TLC) and Differential Leucocyte Count (DLC) as described by Brar *et al.* (2002).

---

<sup>19</sup> Inj. Enrocare : inj. Enrofloxacin 100 mg/ml, 100 ml, Vetcare, Bangalore

<sup>20</sup> Betadine lotion- Betadine microbicial Povidone iodine 5% w/v, 500 ml, Win-medicare, Ahmedabad

<sup>21</sup> Inj. P-depot : Inj. Hydroxyprogesterone caproate 250 mg/ml, 3 ml Ampoule, Zydus Animal Health Limited, Ahmedabad




### 3.7.2 Serum Biochemistry

From the serum samples, enzymes, viz., aspartate aminotransferase (AST) [Modified-IFCC UV Kinetic Method], and alanine aminotransferase (ALT) [Modified-IFCC UV Kinetic Method], and macro-minerals, viz., calcium (Arsenazol-III method; Smith *et al.*, 1979) and inorganic phosphorus (Molybdate UV method; Fiske and Subbarow, 1925) were estimated using standard procedures and kits procured from Coral Clinical Systems, Goa, with the help of Chemwell auto-blood analyzer (Awareness Technology, Germany).

### 3.7.3 Endocrinology

Serum progesterone and oestradiol-17 $\beta$  were estimated by RIA employing standard technique of Kubasik *et al.* (1984). Labeled antigen (with I<sup>125</sup>), antibody coated tubes and standards were procured from Immunotech-SA, Marsielle Cedex, France. Coated tubes after addition of samples and tracer were incubated for one hour at room temperature while continuously shaking (300-350 rpm). After incubation the material was decanted carefully on absorbing rack. These tubes were read in gamma counter (IC 4702, I<sup>125</sup> gamma counter ECIL, India). The values of progesterone and oestradiol-17 $\beta$  were calculated against standard curves of 0.1 to 90 ng/ml and 10 to 2000 pg/ml, respectively, on the logit log paper and represented as ng/ml and pg/ml.

The sensitivity of the progesterone assay was 0.1 ng/ml. The intra- and inter-assay coefficients of variation were 5.4 and 9.1 per cent. Cross-reactivity of the antibody with progesterone, 20 $\alpha$ -dihydroprogesterone and 17 $\alpha$ -hydroxyprogesterone was 100, 0.96 and 0.13 per cent, respectively.



The sensitivity of the oestradiol-17 $\beta$  assay was 4 pg/ml. It's intra-assay variation was 15.1 per cent, while inter-assay variation was 14.4 per cent, and the cross reactivity of antisera against oestradiol-17 $\beta$ , estrone and estriol was 100.00, 1.30 and 0.23 per cent, respectively. The sensitivity of the cortisol assay was 3.62 ng/ml. It's intra-assay variation was 5.8 per cent, while inter-assay variation was 9.2 per cent.

### **3.7.5 Urine analysis**

Urine samples were subjected to gross and microscopic examinations as per the method laid down by Benjamin (1978).

### **3.7.6 Cultural Isolation and Drug Sensitivity Pattern of Genital Bacteria**

The cervico-vaginal swab collected was put to culture as described by Cruickshank (1965). Sensitivity examinations of the organisms cultured was done for Amoxirum, Enrofloxacin and Ceftriaxone.

For isolation of Gram positive and Gram negative bacteria, sterile cotton swabs (HI-MEDIA Lab. Ltd., Mumbai) were used for collection of genital swabs from vaginal fornix/cervix of all 46 cows with chronic CVP a day before operation and subjected for cultural and sensitivity test, whereas random swabs collected from a few cases of group 4, 5 and 6 on 7<sup>th</sup> days post-operative were subjected to cultural isolation only.

Isolation work was done as per Cruickshank (1965) up to the level of colony characters and Gram's staining. The isolates were subjected to *in vitro* antibiotic sensitivity test as per the method recommended by Bauer *et al.* (1966). Antibiotic discs supplied by HiMedia Laboratories Pvt. Ltd., Mumbai were used and the results were interpreted as per the chart furnished by manufacturer. The isolates were tested for their sensitivity to 6 antibiotics, viz. amoxirum, ceftriaxone, enrofloxacin, gentamicin,

ciprofloxacin and oxytetracycline. This work was done at the Department of Veterinary Microbiology of the College.

### **3.7.7 Histopathological Examination**

Histological examination of specimens from the excised portions of cervix, vagina and ovaries collected during operation in groups 3, 4, 5 and 6 was carried as per standard procedure. The formalin fixed tissues were processed and embedded in paraffin. Sections of 5-6 micron thickness were cut, stained with routine haematoxylin and eosin (H & E) stain (Luna, 1960), and interpreted for histopathological changes, if any.

### **3.8 Statistical Analysis**

Paired 't' test was applied to compare values of pre- and post-operative samples of ALT, AST, Ca, P, Hb, TEC, TLC, PCV and DLC. Independent 't' test was applied to compare the pre-operative values of affected cows with the values of normal cows (Snedecor and Cochran, 1986).



*Results and Discussion*

## CHAPTER – IV

### RESULTS AND DISCUSSION

---

Cervico-vaginal prolapse (CVP) has been noted in dairy cows all over the world by many workers. The incidence has been nearby periparturient period in all those reports. None of them have mentioned cases of chronic prolapse occurring beyond three months of parturition. On the contrary, it was experienced to be occurring in high number in the Gaushalas and Panjarapoles of Gujarat. Hence the present study was undertaken to evaluate various aspects of CVP including medico-surgical management in cows of Gaushalas and Panjarapoles of Saurashtra region of Gujarat. The findings are presented in various tables, illustrations and photos, and are discussed under the following sub-heads.

#### 4.1 Incidence and Etiology of CVP


A number of foreign workers including Woodward and Quesenberry (1956) and Patterson *et al.* (1979) have reported the incidence of peripartum prolapse at different locations in different numbers. In the present study in three Gaushalas housing about 500 cows each, 10 cases of CVP were present at a time, suggesting average 2 per cent incidence of CVP. Such cases kept repeating on number of occasions. As experienced, 4 to 5 cases of genital prolapse were presented at each Gaushala during a particular visit. Upon conventional treatment some of them were handled successfully but a number of them were presented for repeat treatment on subsequent visits, indicating the chronic nature of the malady.

Among the affected cows under study, 22 (47.82%) were Gir, 15 (32.60%) were Kankrej and 9 (19.56%) were non-descript. The high incidence in Gir and Kankrej was mainly due to the rich population of these breeds in the Saurashtra region of Gujarat. So also, these breeds were more susceptible for CVP. Woodward and Quesenberry (1956) reported high incidence in the western range of United States in Hereford breed of cattle. Arthur *et al.* (2001) reported high incidence in Hereford, Simmental and Charolais breeds of cattle.

Mishra *et al.* (1998) attended 634 cases of CVP in both cows and buffaloes over a period of ten years (1988 to 1998), the cases being pre- and post-parturient nature. Since they did not specify the incidence in relation to the exact time, it is difficult to consider these as chronic cases similar to the one found in the present study.

Seasonal and geographical incidence has been reported by different workers (Jubb *et al.*, 1990). As the present work was restricted to selected Gaushalas in Saurashtra region of Gujarat, it was not possible to compare the incidence with their findings. Similarly the seasonal incidence of CVP reported by other workers was also not taken into consideration for comparison with the present study, because the study of other workers included mainly the calving seasons, while the cases offered / available for treatment in the current work were not close to the calving, as sufficient time had lapsed from the calving and quite a few of these cases repeated before being subjected for the treatment.

Several etiological factors have been postulated to cause CVP. Vandeplasche and Spincemaille (1963) considered the physiological pattern of inversion of uterine prolapse as a reason for prolapse. According to them, the anterior portion underwent the



inversion, later than the posterior one, making it prone for prolapse due to the bouts of straining.

Singh *et al.* (1998) encountered fibrosarcoma of the uterus leading to the prolapse. Potter (2008) pointed out factors like prolonged dystocia, foetal oversize and retained foetal membranes as the factors responsible for prolapse. In the present study many of the above reasons were not applicable as all the cases were away from parturition. According to the data collected, causes such as retained placental membranes and human interference in the process of parturition were reported as history. It is presumed that chronic irritation persisting out of infection from retained placental membranes and handling lead to subclinical inflammation and further prolapse. It was also observed that the affected animals had been bred indiscriminately before suffering from prolapse, and were subjected to very unhygienic services from unknown bulls, and handling by untrained health workers.

Hormones have been long blamed to be responsible for prolapse in cows. Tyagi and Singh (1993) identified follicular cyst in cases of prolapse. Gustafsson *et al.* (2004), considered changing levels of progesterone, estrogens, cortisol, oxytocin and pregnancy related glycoproteins playing a key role in the occurrence of CVP.

According to Cynthia and Scott (2005), cows utilized for superovulation were subsequently prone for vaginal prolapse.

In the present work, when the values of progesterone and estradiol were studied in the affected cows, they were very low than normal group of cows, suggesting that the hormones had no significant role in causing chronic/recurrent genital prolapse in the cows.

## **4.2 Observations on Clinical Signs / Symptoms of Prolapse**

### **4.2.1 Number of episodes of prolapse:**

Out of 46 cows, 6 cows had two episodes of prolapse, while 30 had 3 to 5 episodes and remaining 10 had more than five times recurrence.

### **4.2.2 Duration of the present prolapse:**

Thirteen cows had shown the prolapse for 1 to 3 days, 16 were having the prolapse up to 3 to 7 days. Another 13 had the prolapse over a period of 7 to 15 days, and the rest 4 had the malady for more than 15 days.

### **4.2.3 Period since first prolapse:**

In 2 cows, the first appearance of prolapse was within previous three months, in 17 cows, it was since previous 6 months, in 18 cows, it was since previous 12 months and in the remaining 9 cows, the prolapse started appearing more than 12 months before.

### **4.2.4 Number of calving in relation to age:**

Out of 46 cases included in the treatment plan of the current work, 10 cows (21.73 %) were up to five years old, 24 cows (52.17 %) were between five to ten years of age, while 12 (25.08 %) being older cows above ten years of age. Middle age cows suffered maximum prolapse followed by older and younger cows. The observations were similar to those of the previous workers (Roberts, 1971 and Arthur *et al.*, 2001). Bhattacharya *et al.* (2007) found prolapse to be prevalent in Jersey crossbred cows (91.67%), which were around six years of age (54.54%) and in their 2<sup>nd</sup> to 4<sup>th</sup> parity (77.22%).

Among the affected cows, 23 (50%) had 1-2 calvings, 15 (32.60%) were with 3-5 calvings and 8 (17.39%) were with more than 5 calvings. It was observed that more than



50 per cent cows with CVP were pluriparous (Roberts, 1971). However the reproductive efficiency (parity) was found less in the affected cows.

#### **4.2.5 Parturition related causes:**

In 13 cows, the calvings were handled by untrained personnel, probably using manual force to extract the foetus. Thus, it was possible that the resultant uterine injury / trauma caused sensitization of the organ for prolapse. Rai and Prabhakar (2000) also remarked such trauma.

Twenty cows had a known history of retained placental membranes which may have left subclinical infection in the organ causing persistent irritation and prolapse. Potter (2008) indicated retained membranes as one of the causes of prolapse.

On ascertaining the history from owners, 11 cows had suffered dystocia and subsequent retained placentas. The care taker gave a history that the two cows had premature calving, toward the last trimester of pregnancy.

#### **4.2.6 Postures at the time of presentation:**

Eleven cows were seen standing with exhibition of variable grades of prolapse. While 24 cows were standing with distress on presentation and 11 cows were found sitting at the time of presentation.

#### **4.2.7 Appetite:**

Out of 46 cows, 17 showed moderate appetite, other 17 showed marked reduction in appetite, 9 of the cows had reduced appetite with digestive disorder and 3 were having anorexia.

#### **4.2.8 Temperature:**

Eight cows showed rectal temperature within normal limit (100 to 102°F), 26 had elevation in temperature (102 to 104°F), 8 animals showed subnormal temperature (below 100 °F) and 4 cows had very high temperature (pyrexia) that was above 104°F.

#### **4.2.9 Pulse:**

The pulse rate in 20 animals was below 50 per minute, it was between 70-90 per minute in 25 cows and in 1 cow, it was beyond 90 per minute.

#### **4.2.10 Respiration:**

The respiratory rate recorded revealed that 5 animals had normal rate (20-28 per minute), 23 had little increase in the respiratory rate (28-30 per minute) and in 14 animals, the rate was more than 30 respirations per minute. In four cows, respiratory rate had fallen below normal (20 per minute).

#### **4.2.11 Colour of mucous membrane:**

In 19 cows, the cervico-vaginal mucous membrane appeared congested. In 11, these were pale; in 14 they appeared injected, whereas in 2 cows, they showed variable degree of pigmentation.

#### **4.2.12 Signs of toxæmia:**

Eleven cows did not reveal signs of toxæmia, like depression to lethargy or recumbency, while 24 cows were depressed and 11 showed lethargy and comatose.

#### **4.2.13 Organs involved in prolapse:**

In 9 cows entire vagina had prolapsed, in another 16 cows os cervix appeared at the vulvar commissure in addition to the complete prolapse of vagina. In the remaining 21 cows entire vagina with complete cervix was noted in the prolapsed mass.

#### **4.2.14 Size of prolapsed mass:**

In 17 cows, the size of prolapsed mass was considered as moderate. In 10 cows, the prolapse was large and involved entire vagina. In another 6 cows, the large prolapse contained entire vaginal as well as enlarged cervical os. In the remaining 13 animals, the prolapse was very extensive involving entire vagina and complete cervix, both having inflamed.

#### **4.2.15 Appearance of prolapse:**

In 14 cows, the prolapsed mass was oedematous and showed mild lacerations of the superficial layers. Twelve cows had second degree lacerations on the prolapsed mass. In 7 cows, the prolapsed mass showed thick, necrotic wall of vagina. In 6 cows, in addition to necrotic and fibrotic changes of vagina, the cervix also had become hard, kinked and fibrosed. In 7 cows the above pathological lesions / features were further complicated with formation of maggots, sloughing, recurring haemorrhages and gangrene.

#### **4.2.16 Adhesions:**

The prolapse did not show adhesions in 9 cows, whereas few adhesions were noticed in another 9 cows. In 12 cows, there were considerable amount of adhesions. In 8 cows, the adhesions observed were extensive and in another 8 cows the adhesions were so extensive that they were irreducible.

#### **4.2.17 Discharge from genitalia:**

All the cows showed variable degree and nature of discharge from genitalia. The discharge was mucoïd in 15 animals, mucopurulent in 12 animals, purulent in 16 animals and had foetid odour in 3 animals.



#### **4.2.18 Straining:**

Five animals showed mild straining, 19 showed moderate straining, 13 showed severe straining and 9 other showed severe continuous straining.

#### **4.2.19 Involvement of urinary bladder and dysurea:**

Four animals showed distention of urinary bladder, but there was no involvement of urinary bladder. In 17 cows, urinary bladder had displaced caudally and the animals had mild dysurea. In another 18 cows, the bladder had displaced caudally with severe dysurea. In 7 cows, the bladder was significantly distended or everted resulting in to severe dysurea.

#### **4.2.20 Changes in the ovaries:**

On per rectal examination, the ovaries appeared normal in 5 cows. The ovaries were apparently normal but unequal in size in 16 cows. Although the ovaries were apparently normal, they had smooth surface and hard feel in 19 cows. Four cows showed follicular cysts on their ovaries, while 2 animals had luteal cyst on the ovary.

### **4.3 Overall Grading of CVP for Surgical Management**

After the assignment of appropriate points for every character as given in **Table 1**, the total of aggregate points for each cow was considered for grading of the case and subsequent plan of treatment. The cows that fell in the range of aggregate points between 0-25, were graded as Grade-I; between 26-50, graded as Grade-II; between 51-75, graded as Grade-III, and cows with score from 75-100, were graded as Grade-IV (Table 3).

None of the cases under study fall in the **Grade I** category, hence question was handling/treatment did not arise. Plate 1A is shown from an extra cow to depict the Grade I prolapse.

**The cases of Grade-II** were subjected to surgical treatment utilizing Technique No. 1 (Fixation to prepubic tendon) or No. 2 (Button suture fixation). Cases falling under the Grade-III were treated with the use of surgical Technique No. 3 (Amputation of prolapsed mass) or No. 4 (Submucosal resection of vagina).

**In cases of Grade-III**, the cows that had irreducible adhesions of the prolapsed mass or abnormalities of os cervix in the form of kink, hard, fibrosed, or extensive enlarged cervix were subjected to Technique No. 3 (Amputation of prolapsed mass). Cases of Grade-III that did not have above changes in prolapsed mass were subjected to Technique No. 4 (Submucosal resection of vagina).

**The cases of Grade-IV** were put to treatment by Technique No. 5 (Panhysterectomy), and those cows which showed ovarian abnormalities were subjected to Technique No. 6 (Bilateral ovariectomy).

Arthur *et al.* (2001) classified the prolapse, mainly on the basis of size, involvement of the organs and pathological changes in the prolapsed mass. Saha and Nakao (2003) also classified the prolapse depending on its severity.

In the present study an attempt was made to consider the changes occurring in the prolapsed mass and the animal in totality. Specific points were assigned to each character and changes occurring in the animal. In addition to the reproductive tract, consideration was given to degree of straining by the animal, to the duration of prolapse, general physiological status of the cow, and its posture at the time of presentation (**Table 1**). Thus a complete assessment of the cow was made. It was felt that this system would benefit in planning of treatment regimen and successful outcome in each case. The present study therefore will offer future guideline for the clinician in the field.

#### **4.4 Anaesthesia and Restraint**

In the initial cases, the prolapsed mass was handled for preparation under caudal epidural anaesthesia. The animals resisted the preoperative handling, washing of the organ, as well as repositioning for technique 1 and 2. It was also impossible / hectic to perform the surgical procedure of fixation to prepubic tendon or button sutures under epidural analgesia. The struggling by the animal in the form of knuckling on the knees, dropping down, and forceful straining resulted into contamination, laceration of prolapsed mass and interference in the surgical procedure. In view of these difficulties, pudendal nerve block in addition to caudal epidural anaesthesia was given to avoid these complications. Since the pudendal nerve is known to innervate the clitoris (Ghosh, 2006), it was advantageous to block the nerve.

In the experience during the present work, even after the pudendal nerve block and the epidural analgesia, the animal showed tendency to wobble on the hind legs, occasionally leading to recumbency. It was also difficult to control the animal in a fix position in the trevis due to unwarranted movements of the animal. This made handling of the organ and the surgical procedure a tedious job. Taking a note of this, as the animal became unsteady on the hind legs, it was cast in the lateral recumbency and further surgical procedure was completed.

In the experience of Risco *et al.* (1997), pudendal nerve block was also used in cows for urogenital procedure, where extreme straining was not addressed by epidural analgesia alone.

#### **4.5 Pre-medication**

The medicinal treatment was useful. Administration of cortisone and fluid therapy stabilized the animals and helped to prevent hypovolumic shock. In the cases of prolapse,

histamine and histamine like substances tend to develop profusely and lead to tenesmus. The use of anti-inflammatory drug in the form of Ketoprofen and Meloxicalm helped to manage unusual inflammation, pain and pyrexia. The antibiotics were essential to control and combat the infection. The calcium and phosphorus preparations corrected the imbalance of these minerals that could have improved the tone of genitalia and helped to prevent recurrence. Misra and Angelo (1998) have mentioned that supportive therapy was mandatory in the management of cases of genital prolapse. The role of anti-inflammatory and antibiotics was crucial to control the inflammation and infection. Parenteral supplementation of calcium preparations have been clinically assessed to have significant role in minimizing tenesmus and help retention of the viscus (Odegaard, 1977; Risco *et al.*, 1984)

## **4.6 Surgical Treatment**

### **4.6.1 Technique No. 1: Fixation to Prepubic Tendon**

The  $\frac{1}{2}$  circle needle was manually bent to  $\frac{3}{8}$  circle to allow easy maneouvering within the vaginal lumen and into the prepubic tendon.

Since the vaginal vestibule in the cows is considerably long, it was necessary to thread a 75 cm long suture material to the needle, keeping it traceable for further tying of knot beyond the vulvar commissure. Further insertion of the prepared needle was performed carefully by protecting it in the palm of right hand to avoid unwanted injury to the pelvic structures, This needle was carried with the tip of the needle rested in the vaginal floor and then the anatomical structure of the prepubic tendon were palpated. The needle was further pushed in these structures in the prepubic tendon. Although the insertion in the prepubic tendon required lot of skill to retrieve back between the main and lateral branch and bands of the prepubic tendon. Further difficulty was encountered



in pushing the needle back into the vaginal floor due to ballooning of the vaginal wall with the penetration by tip of the needle, making it unable to penetrate. Several attempts were required to push the needle back in the vaginal floor, while sometimes it was necessary to press the vaginal floor with the help of long vulselum forceps on the inserted needle. Even after this, it was not possible to ensure to include sufficient breadth /width of the prepubic tendon in the suture. As a result, the suture gave away in two cases.

Youngquist and Threlfall (2007) mentioned a modification of Winkler's cervicopexy, which utilized second surgeon assisting the fixation through left frank laparotomy. They also mentioned a modification in the form of a colpotomy. However, taking into consideration the limited resources available at field level for the present study, their modifications were not considered.

Winkler (1966) used non-capillary suture material and umbilical tape for the fixation. However in his experience peritonitis resulted in the cases of umbilical tape. He therefore dissented the umbilical tape.

Although the technique 1 appeared very promising (Winkler, 1966), the experience during the study indicated that the entire procedure has to be performed blindly only by palpation in the cul-de-sac of vagina. In view of a limited bite in the vaginal floor and the prepubic tendon, the chances of rupture of the suture or the tearing of the vaginal wall could not be overlooked. It was also experienced that the bite on the right side was more difficult than the left side for the right handed worker.

Even though recurrence was noted only in one case (No. 2) of this group, secured fixation of vagina to the prepubic tendon was not satisfactorily accompanied in four cases (No. 1, 2, 3 and 4).

Considering the overall difficulties in the technique 1 and a possibility of rupture of the suture from the already affected wall of the vagina, the possibility of failure was rated high.

In 2 cows (No. 3 and 4), in spite of passing urethral catheter and taking care to avoid bite in to the urethra, the peri-urethral tissues were involved in the suture inadvertently causing a kink in the urethra and resultant dysuria. It was exhibited subsequently by the animal in the form of frequent urination and straining while urination and defecation. This required the catheterization and blunt separation to the urethra from the bite of the suture.

Considering the difficulties encountered in the fixation of vagina to the prepubic tendon, it was experienced that the technique required careful palpations of structures to place the suture exactly, to avoid the bites in the surrounding organs, like urethra, urinary bladder and rectum. Surprisingly, other authors have not given their experience in detail about this surgical procedure (Wolfe and Carson, 2007).

Fubini and Ducharme (2004) preferred suturing the cranial vagina to the iliopsoas muscle. It could be done blindly via the vagina or by open surgery with a caudal celiotomy. In the later case, an assistant inserted a hand into the cranial vagina to guide it toward the surgeon working through the celiotomy. The cranial vagina was secured to the muscle by placement of several sutures through both the structures.

#### **4.6.2 Technique No. 2: Button Suture Fixation**

The button fixation technique was used on 8 cows of this study. It was to fix suture and the button on the vaginal side of the prolapse at the fornix. It was necessary to identify and isolate the suture on either side so that they did not cross over each other or

the ends of either suture were tied together. This was accomplished by holding the ends of each suture in the stout forceps while the prolapse was repositioned. Suturing needle used for passing through dorsal wall of pelvis was not specially designed like the one described by Misra (1998). Commercially available suture needle (triangular and straight needle No.1) worked satisfactorily to put these sutures. This needle was to be carried into the vaginal lumen guarded firmly with the palm of right hand in the limited space available in the vagina. It was easy to direct the needle through the dorsolateral wall into sacrosclatic ligament and then through the skin on gluteal region. This could be accomplished with little experience taking adequate care to avoid other tissues like rectum, pudendal nerve and blood vessels. However, passing of the needle through the dorsolateral pelvic wall on the right side was not possible by the right hand of the operator, and therefore it was performed by using the left hand.

Minchev (1956) and Misra and Angelo (1981) described another technique which involved passing of the needle from the gluteal skin into the pelvic canal which was then palpated per vaginum and extracted through the vaginal lumen. Although this technique appeared to be easy to perform, it was likely that sufficient bite could not be placed in the vaginal wall leading to cutting of the suture through the vaginal wall. The technique used for the current study was similar to that used by Misra (1998), which ensured a large bite into the vaginal wall preplaced before repositioning of the prolapsed mass.

In this work, initially the buttons suture fixation was attempted by first reposition of the prolapse mass. Then by passing the straight needle No.1 from outside the gluteal region to inside the vagina. However, the needle was embedded in the gluteal musculature, and it was difficult to pull or push the needle to retrieve in the vagina; so also to direct the needle caudally to take out from vagina. It was cumbersome to

manipulate the needle to reach at a desired point in the vaginal roof and to include a desired amount of tissue from vaginal fornix in the bite for fixation. From the next cases the internal buttons were preplaced on both sides of prolapse mass at the desired level on vaginal fornix with sufficiently large bite. The prolapsed mass was properly replaced. The needle was passed from inside vagina through the sacrosciatic ligament to bring outside on gluteal region. This way it was very convenient and easy to pass the suture ends outside and fix the button on gluteal region. Hogg (1960) also placed the fixation suture by passing the needle from inside the vagina to come out on gluteal region. The technique supported the principle of the management of prolapse to a great extent. Gibbons (1962) supplanted the umbilical tape vaginopexy technique of Hogg, by stainless steel prolapse pins.

Pierson (1961) mentioned both Minchev's through and through technique and modified Minchev's technique for treatment of prolapse of vagina. The original technique as described by Minchev using umbilical tape was described by Youngquist and Threlfall (2007). They used specially devised rigid pin for the vaginal fixation.

Since the vaginal insertion of the suture was preplaced on the prolapsed mass, there was adequate visibility and a very little haemorrhage occurred in the placement of the suture. None of the cows operated by this technique 2 showed apparent bleeding.

Fubini and Ducharme (2004) also mentioned of the button suture fixation of vagina to the roof through the sacrosciatic ligament and skin on gluteal region. They opined that any pexy technique should be performed only on one side to prevent chronic pneumovagina.


#### **4.6.3 Technique No. 3: Amputation of Prolapsed Mass**

The exposure and dissection of the prolapsed tissue was easy in this technique as the entire mass was presented at the vulva for handling. However due to the large size and irreparable changes in the vagina and the cervix, the wall of the organ was considerably thick making it difficult to cut. Because of the inflammation and oedema the tissues also included large number of blood vessels, which bled spontaneously upon cutting and necessitated immediate control by multiple ligatures. As a result, there was a considerable blood loss obscuring the surgical site. It was also experienced during the surgery that, correct appreciation of the inner and outer tube of the prolapsed mass was very important, in order to approximate the cut edges. Large number of sutures along the entire margin needed to be placed to hold the cut edges together. Upon completion of the sutures, the everted mass could be easily placed back to its normal disposition for further retention. Immediate post-operative haemorrhage was not noted in any of the cases.

Fubini and Ducharme (2004) recommended amputation of prolapsed mass as a last resort in cases where the uterus had undergone irreversible changes. Singh *et al.* (1998) and Pathak *et al.* (2009) performed amputation of the prolapsed mass in cases of vaginal tumours. Kochhar *et al.* (1996) removed the vaginal lipoma by ligating at the base and cauterizing the bleeding vessels in a cow.

#### **4.6.4 Technique No. 4: Submucosal Resection of Vagina**

In this technique too, the handling and dissection of tissues was fairly simple as technique 3. As the surgical dissection was restricted only to the submucosa of the exposed portion, haemorrhage from the dissection was comparatively less than in the technique 3. The haemorrhage occurring in the form of oozing or mild haemorrhage was easily controlled by application of Ferycrilate solution or digital compression with gauze



pieces. The suturing of the cut edges of the mucosa required sufficient push back exerted by the assistant to avoid tension on the sutures.

Since the technique did not involve extensive dissection or ligation of blood vessels, the procedure could be completed in 40 to 45 minutes.

Farquharson (1949) performed reefing of the prolapsed organ. According to him, the bulk of the everted mass was formed by the mucosa and excision of the same in the form of circumferential areas reduced the size considerably to approximate the cut edges by a continuous suture and repositioning of the organs. He opined that, in view of the prolapsed mass becoming considerably small after the submucosal resection; an assistant was needed to hold the cervix under traction so that the inner tube did not retract back before suturing. Similar was the experience in the present work.

#### **4.6.5 Technique No. 5: Pervaginam Panhysterectomy**

As in the above two techniques, the dorsal wall of the vagina bled considerably when the dorsal incision was placed between 9 O'clock and 3 O'clock position. Use of forceful pressure and ligation was required to control the bleeding. Further dissection for the uterine junction and ovarian stumps had to be done blindly by palpation with fingers. When the ovary was grasped, the animal exhibited a sign of discomfort by shivering, kicking and lumbar kyphosis. Gentle firm traction was continued to fatigue the ovarian ligament. Five ml of local anaesthetic infused locally also helped in relaxation of ovarian ligament and reduction of pain. It was felt necessary to put two ligatures on the stump to ensure complete obliteration of the ovarian blood vessels. In none of the cases bleeding was observed after the release of the stump. Further the broad ligament was dissected and transacted after the ligation of major blood vessels and clamp on the smaller vessels. Once the sufficient portion was separated between the ovarian end and the cervix the

entire organ on the left side was set free for further dissection. Similar procedure was performed on the right ovary and uterine horn.

After having freed both the sides of the entire organ it was easy to bring the structure up to the vaginal incision and remove it. Suturing of the vaginal wall in a continuous lock stitch pattern required sufficient traction on both the cut edges by an assistant to bring them in close approximation. After having completed this procedure, small length of vagina was left behind so that there was no chance of recurrence of prolapse. A number of blood vessels were encountered during this dissection. Similarly, there was abundant fat in the broad ligament which posed some difficulty in the dissection.

#### **4.6.6 Technique No. 6: Pervaginum Bilateral Ovariectomy**

Ovariectomy was performed in the similar manner as in technique 5. The uterus and cervix were left intact. For performing the ovariectomy, a specially designed ovariator was used to crush the ovarian blood vessels and the pedicle. The ovary was held with firm traction allowing space to apply the ovariator between the ovaries and the uterus. The blades of the instrument were maintained parallel so as to avoid incorporating unwanted tissue. The instrument worked on the principle of an emasculator crushing the ligament and its blood vessels and cutting beyond the crush surface. This eliminated use of any suture and offered satisfactory arrest of haemorrhage. The ovary became free quickly once the pedicle was crushed and cut, so that the entire procedure of ovariectomy on both the sides was completed in 10 to 15 minutes. Suturing of the vaginal incision (colpotomy) posed no major problem and the entire surgery could be completed in 20 to 30 minutes. There was considerably less haemorrhage than the other techniques.

#### 4.7 Post-Operative Observations:

In Group I, in one cow (No. 2), the vaginal wall tore away from the fixation suture which was placed in the vaginal wall and prepubic tendon and caused recurrence of prolapse on 8<sup>th</sup> day post-operatively. Mild dysuria and straining was observed for a week.

Arthur *et al.* (2001) in their experience opined that the attachment of vagina to prepubic tendon required general anaesthesia.

In Group II, in one cow (No. 10), recurrence of prolapse was noted on 21<sup>st</sup> day post-operatively. On per vaginal examination, sutures on both the sides were ruptured leaving both the inside buttons falling in the vagina, while the outer buttons in the gluteal region were in place with the broken suture and on manipulation it could be easily freed. This case was later subjected to per vaginum panhysterectomy.

Further, two cows (No. 14 and 15) of this group showed infection on both the sides of suture bites, the vaginal and gluteal sides, causing mild vaginal and gluteal discharge by 30 days. Local dressing, release of the buttons and administration of the antibiotics did not give any relief and led to accumulation of large amount of pus in the vagina and further pyometra at the end of 90 days. The remaining five animals showed no complications, and their buttons were removed by 60 days after operation by cutting the sutures on the outside and pulling it out through the vagina, along with the inner buttons. No recurrence of prolapse was noted in these animals.

In Group III, all the animals showed mild to moderate bleeding from vagina and mild straining. This was treated by local infusion of Betadine solution and application of Ceftriaxone powder. Injection Stadren was also given I/M for 2-3 days. However this

bleeding disappeared toward 7-8 days and effectively stopped at 10 days. One cow (No. 24) showed recurrence of prolapse at 25<sup>th</sup> post-operative day, and was subjected to per vaginum panhysterectomy. In the remaining seven cases, no recurrence was noted till 100 days of follow-up.


Kochhar *et al.* (1996) excised a lipoma from the vagina of a cow which had recurrent prolapse. According to Arthur *et al.* (2001), amputation of the everted mass could be adopted as a last resort in those cases in which the uterus had undergone such severe changes that replacement of the organ would inevitably result in death. In occasional long standing cases, it was found physically impossible to replace the mass because of the unfavourable texture of the organ. The prognosis was grave, and it was doubtful on welfare grounds.

According to Risco *et al.* (1997), several techniques have been described, but there was no one perfect technique for the repair of vaginal/cervical prolapse. Youngquist and Threlfall (2007) pronounced amputation of genitalia as the only method for chronic prolapse of vagina, cervix and uterus with extensive oedema and necrosis.

In Group IV, minor haemorrhage through vagina was noted in all the cases for 1 or 2 post-operative days, after which neither haemorrhage nor any discharge was observed. All the animals recovered uneventfully, except one cow (No. 32) suffered prolapse at 24<sup>th</sup> post-operative day, which was treated by per vaginum panhysterectomy.

Agrawal and Prasad (2001) suggested submucosal resection in cases of oedematous and devitalized mucous membrane of the prolapsed portion.

Regarding the technique 4 (submucosal resection), Arthur *et al.* (2001) mentioned that in order to control the haemorrhage and facilitate suturing; the



submucosal dissection could be best performed by the circumferential segment. Simultaneously, the cut edges were co-opted with continuous absorbable sutures. The curve was permanent.

In Group V, all the animals, except one cow (No. 37), showed slight haemorrhage for a period of 3 to 4 days followed by slight mucous discharge for next 3 to 4 days, but recovered uneventfully by 15 days.

Roberts (1971) advocated hysterectomy (amputation of the prolapsed uterus) when the replacement of the prolapsed organ was almost impossible or the prognosis in such cases was poor owing to severely torn lacerated necrotic and infected uterus. He removed the uterus and the entire cervix and replaced the stump in vaginal cavity. According to him, the vagina and peritoneal cavity were tightly closed by this method.

Fubini and Ducharme (2004) recommended amputation of the severely traumatized and necrotic uterus for salvaging the life of the affected cow.

Per vaginum hysterectomy was also recommended by Tank *et al.* (2006) to alleviate the pain due to prolapse and salvage the cows.

Pathak *et al.* (2009) applied a circumscribed ligation at the base of everted portion. The everted mass which included part of uterus was surgically excised after applying a circumscribed incision.

Singh *et al.* (1998) performed amputation of the prolapsed uterus due to fibroma in a cow. They approached the broad ligament through a longitudinal incision on the wall of prolapsed mass, and ligated the blood vessels within the broad ligament. After ensuring proper ligature they excised the uterus and sutured the vaginal wall completely to close the peritoneal cavity.

Technique 1 and 2 (Prepubic tendon fixation and Button suture fixation) were performed in those cows where the prolapse was mild to moderate type (Grade II) with no complications like oedema, necrosis, gangrene and other secondary complications like formation of maggots. As such these two techniques were useful in conserving the genitalia; the clinical condition was addressed by one of the two techniques mentioned above.

Two cows (No. 11 and 13) treated with technique 2 conceived subsequently. Thus, these animals would have become useful for reproduction in future. When these two techniques were compared between each other, it was experienced that technique 1 was more demanding and could end in failure as exhibited by signs of dysurea, and the deviation of urinary tract, that had to be subsequently treated to correct the problem in 2 cows (Case No. 3 and 4), whereas technique 2 was comparatively easy to perform and more successful as evidenced by reaction to the foreign body, i.e. suture material and/or the button within the vagina. This reaction might have aggravated the already present subclinical bacterial infection that led to pyometra in 2 cows (No. 14 and 15).

Whenever there were marked changes in the prolapsed mass in the form of severe oedema, adhesions and necrosis (gangrene) falling in Grade III prolapse, these cases were assigned to techniques 3 or 4 as already recommended by other workers.

The prolapsed mass was difficult to relocate in its natural disposition because of changes in the size and shape, in view to relieve the agony of the animal; it was thought least important whether these cows would breed in future. Therefore, they were treated with either submucosal resection or amputation of the prolapsed mass, as in both the techniques the primary problem of discomfort of the animal was eliminated. Since these cows were looked after by the Gaushalas on humanitarian grounds, no consideration was

required to be given about their reproductive performance. When the two techniques (3 and 4) were compared between each other submucosal resection was comparatively easier to perform and resulted into less serious haemorrhage. Cows treated by the technique 4 also showed complete recovery, except in one cow (No. 32). It can be concluded that this was the satisfactory method of surgical treatment for cases of prolapse in Grade III. A slight distinction can be made in the decision for selecting between the two techniques was that, when considerable adhesions were present in the prolapsed mass, technique 3 (amputation of prolapsed mass) must be preferred over the technique 4 (submucosal resection).

In those cases where the prolapse was falling in Grade IV, the changes in the prolapsed organ appeared irreversible, it was impossible to relocate the organ in its natural disposition. Due to the changes mentioned above, it could have lead to septicaemic condition and eventual death. In such cases, it was decided to remove entire reproductive tract (Per vaginum panhysterectomy, technique 5). This surgical technique also was quite demanding owing to large number of engorged blood vessels in the dissection. It was also necessary to exert sufficient traction on the ovarian pedicle to expose them for ligation and dissection. Because of the considerable size of the prolapsed mass, the entire dissection was clumsy requiring constant assistance to avoid contamination. After complete removal of the organ closure of the vaginal incision was difficult because of loss of considerable vaginal tissues.

In all groups of CVP, after the surgical treatment there was recumbency in either case of prolapse, except group 6 of ovarian disorders and group 5 of per vaginum panhysterectomy. Risco *et al.* (1997) mentioned that no single technique was satisfactory for various grades of CVP. However, in comparable cases there was no choice left than

to let the animal die on natural suffering, the per vaginum panhysterectomy was the only solution. Although it was risky, but once the operation was done carefully and it was tolerated, the animal's quality of life improved markedly.

Technique 6 (Per vaginum bilateral ovariectomy) was reserved for those cases where ovarian changes were marked. There were cystic ovaries, i.e. multiple follicular cysts (Case No. 41 to 44) or luteal cysts (Case No. 45 and 46) (**Plate 8**), leading to chronicity of the prolapse. The signs of these cases were not severer to consider for techniques 3, 4 or 5. It was postulated that the prolapse was primarily due to ovarian dysfunction. This was proved when the ovariectomy was performed and the prolapse was repositioned. No recurrence was noted in any of the six cases until eight days. Further administration of progesterone would have helped in prevention of recurrence as described by Roberts (1971) and Kumar *et al.* (2009<sup>b</sup>) in prepartum prolapse.

#### **4.8 Haematological and Blood Biochemical Profile**

##### **4.8.1 Haematology**

###### **4.8.1.1 Haemoglobin (Hb, g %) :**

The average preoperative haemoglobin (Hb – g%) values in Groups I to VI were recorded to be  $9.54 \pm 0.61$ ,  $8.18 \pm 0.46$ ,  $7.93 \pm 0.38$ ,  $7.64 \pm 0.34$ ,  $7.34 \pm 0.32$  and  $8.73 \pm 0.36$ , respectively. The corresponding postoperative values were observed to be  $9.68 \pm 0.65$ ,  $9.29 \pm 0.67$ ,  $7.40 \pm 0.27$ ,  $8.00 \pm 0.24$ ,  $8.49 \pm 0.30$  and  $9.32 \pm 0.29$ , respectively (**Fig. 1**). The average Hb value in the control group was found to be  $10.44 \pm 0.80$  g per cent (**Tables 4 and 6**).

The preoperative Hb (g%) values in the affected groups II, III, IV and V were observed to be significantly ( $P < 0.05$ ) lower, whereas the values in groups I and VI were

non-significantly lower than the corresponding value in the control group. Statistical analyses of the pre- and post-operative data on Hb levels in the six affected groups revealed a highly significant ( $P < 0.01$ ) increase in post-operative Hb levels in Groups II, V and VI and a significant ( $P < 0.05$ ) increase in Group IV, whereas there was a non-significant increase in the post-operative Hb value in Group I. However, a non-significant decrease was observed in the post-operative Hb value in Group III.

Haemoglobin levels are a reflection of the erythrocyte count in the body. It has been observed in our study that the postoperative total erythrocyte counts were higher in all the groups studied, except in Group III, where even the post-operative Hb levels were lower than the preoperative levels. Decrease in Hb concentration in prolapsed animals may be due to loss of body fluid (Maxwell and Kleeman, 1972) or reduction in size of erythrocyte rather than the number of RBCs (Benjamin, 1978). Here it was mainly due to more haemorrhage associated with the technique 3 (amputation of prolapse mass) in the already inflamed and moderately severe Grade III prolapse cases. The increase in Hb levels post-operatively may be because sampling was done six days after surgery. The loss of blood constituents through the trauma and exposure of the large area of the vital genitalia of the cows was stopped or checked with the medico-surgical treatment. The supportive treatment given to the animal after surgery would have helped in the regeneration of health of the animal, raising Hb level to near the control group.

#### **4.8.1.2 Packed Cell Volume (PCV - %) :**

The average pre-operative values of packed cell volume (PCV - %) in Groups I to VI were noted to be  $31.54 \pm 1.01$ ,  $30.72 \pm 1.55$ ,  $28.71 \pm 1.55$ ,  $25.70 \pm 0.71$ ,  $24.75 \pm 1.47$  and  $30.72 \pm 1.05$ , respectively. The corresponding post-operative values were  $33.91 \pm 0.83$ ,  $33.85 \pm 1.72$ ,  $28.59 \pm 0.87$ ,  $28.13 \pm 0.75$ ,  $27.99 \pm 1.54$  and  $32.75 \pm 0.92$ ,

respectively (Fig. 2). The average PCV value in the control group was  $35.03 \pm 22.01$  per cent (Tables 4 and 6).

On comparing the pre-operative PCV values in the six affected groups with that of the control group, it was found that the values in all the groups were lower than that of the control group. This could possibly be due to the corresponding decrease in TEC values in the affected groups studied in our experiment. The trauma and infective pathogenesis relative to the severity of the CVP contributed the decrease in the TEC in the affected groups of prolapse. PCV is a reflection of the cellular elements, mainly the number of erythrocytes in relation to the blood plasma.

On statistical analyses, it was deduced that the increase in post-operative values in Groups I, II, IV, V and VI over the pre-operative values were highly significant ( $P < 0.01$ ), whereas there was a non-significant decrease in the post-operative values in Group III.

The increase in the postoperative values in the affected groups could be due to the recoument of body condition by six days of surgery, supported by haematinics administration and elimination of stress. The comparative low preoperative values (in prolapsed animals) may be due to the release of ADH as a result of stress (Kinney, 1967) and may be due to anorexia and toxaemia (Agrawal, 1987). Ahmed *et al.* (2005) also noted that the PCV values decreased in prolapsed animals.

#### **4.8.1.3 Total Erythrocyte Count (TEC – $10^6/\text{cmm}$ ) :**

The mean pre-operative values of total erythrocyte count (TEC –  $10^6/\text{cmm}$ ) in Groups I to VI were observed to be  $7.05 \pm 0.33$ ,  $6.49 \pm 0.41$ ,  $6.19 \pm 0.49$ ,  $5.99 \pm 0.60$ ,  $5.14 \pm 0.60$  and  $7.30 \pm 0.28$ , respectively, whereas the post-operative values were

observed to be  $8.29 \pm 0.48$ ,  $7.24 \pm 0.49$ ,  $5.60 \pm 0.41$ ,  $6.41 \pm 0.28$ ,  $6.39 \pm 0.49$  and  $7.82 \pm 0.23$ , respectively (**Fig. 3**). The mean TEC value in the control group was noted to be  $8.03 \pm 0.41 \times 10^6/\text{cmm}$  (**Tables 4 and 6**).

The decrease in the TEC values in the affected Groups II and III were significant ( $P < 0.05$ ) and in Groups IV and V were highly significant ( $P < 0.01$ ), whereas in Groups I and VI the decrease was non-significant as compared to the control group's TEC value.

Statistical analyses revealed that the increase in post-operative TEC values over that of the pre-operative values in Groups I, II, IV, V and VI were highly significant ( $P < 0.01$ ) and the decrease in Group III was noted to be highly significant ( $P < 0.01$ ).

The finding of lower TEC values in prolapsed animals as compared to control group in our study is similar to the findings of Tarjinder and Singh (1993), but contrary to Ahmed *et al.* (2005), who found a non-significant or slight increase in TEC levels in prolapsed animals. It has been found in our study that the Hb, PCV and TEC levels in all the affected groups are lower than the control group values. The trauma and toxaemia caused due to prolonged prolapse might have caused haemolysis leading to reduced TEC levels.

#### **4.8.1.4 Total Leucocyte Count (TLC – $10^3/\text{cmm}$ ) :**

The mean pre-operative values of total leucocyte count (TLC –  $10^3/\text{cmm}$ ) in Groups I to VI were  $13.88 \pm 0.94$ ,  $15.36 \pm 1.34$ ,  $10.99 \pm 1.03$ ,  $11.83 \pm 0.76$ ,  $7.55 \pm 0.43$  and  $8.61 \pm 0.72$ , respectively. Correspondingly, the post-operative values were observed to be  $18.31 \pm 1.11$ ,  $17.85 \pm 0.85$ ,  $13.24 \pm 0.90$ ,  $13.67 \pm 0.75$ ,  $9.78 \pm 0.35$  and  $11.25 \pm 0.43$ , respectively (**Fig. 4**). The mean TLC value observed in the control group was  $10.73 \pm 0.54 \times 10^3/\text{cmm}$  (**Tables 4 and 6**).

Comparison between the control group value and the pre-operative values in the affected groups revealed that the rise in the TLC values of Groups I and II was highly significant ( $P < 0.01$ ) and in Groups III and IV was non-significant. The decline in the TLC values in Groups V and VI was highly significant ( $P < 0.01$ ). The highly significant increase in Groups I and II might be due to profound inflammatory response of bone marrow (with pumping of storage pool of neutrophils in blood) to the comparatively recent CVP. The non-significant increase (or less response of WBC) in Groups III and IV could be due to depletion of circulating pool of neutrophils and less production from bone marrow, because of the longer duration and severe inflammatory condition of prolapse. In Group V, the TLC reduced significantly, which could be because of the above, and continuing loss of neutrophils from tissues in the chronic inflammatory condition of Grade IV CVP (Benjamin, 1978 and Jain, 1986). In Group VI, the inflammation and infection was mild (Grade II prolapse, with ovarian disorder), so there was no increase in TLC, rather a decrease was there, which could be due to loss of neutrophils from the tissues (Benjamin, 1978).

Statistical analyses of the pre- and post-operative values indicated that the increase in the post-operative values were highly significant ( $P < 0.01$ ) in all the six affected groups. This could probably be due to the increase in the number of leucocytes as a response to stress hormone and to the postoperative inflammation and infection. In our study, a highly significant ( $P < 0.01$ ) rise in the post-operative cortisol levels was recorded. The post-operative inflammation and infection was more in Groups I to IV, where surgical dissection, tissue handling was more and the genitalia was restored (Roberts, 1971). In Group V, body's compensatory mechanism was activated after the

treatment (pr vaginum panhysterectomy), rising the TLC to near normal. In Group VI, mild pathology and minimum surgery increased the TLC to near normal.

The above findings are in line with those of Mohy *et al.* (1985), who reported that increase in WBC count in prolapsed animal was due to the release of adrenocorticotrophic hormone from the adrenal gland. Similarly, Sindhu (1975) stated that increase in TLC is suggestive of stress reaction. The degree of leucocytosis depends on the severity of the infection, resistance of the animal and localization of inflammatory response (Benjamin, 1978). Higher WBC counts in the prolapsed animals were also reported by Verma *et al.* (1989) and Ahmed *et al.* (2005).

#### **4.8.1.5 Differential Leucocyte Count (DLC %) :**

The pre- and post-operative numbers of differential leucocyte cells (%), *viz.*, Neutrophils, Lymphocytes, Monocytes, Eosinophils and Basophils are presented in **Table 5**. The control group values for the above mentioned cells are given in **Table 6**

The preoperative **Neutrophil** values were found to be significantly ( $P < 0.05$ ) higher in the affected animals as compared to the control group\*, except in Group V, indicating Neutrophilia. Statistical comparison between pre- and post-operative groups revealed that there was a significant ( $P < 0.05$ ) increase in post-operative values in Group I to V, while significant decrease in Group VI (**Table 5**). The increase ~~was due to~~ surgical complication and dysuria in Group I, transient infection to the non-absorbable silk suture along the suture tracks (in gluteal region and vagina), in Group I and, abscessation and vaginitis in cow Nos. 14 and 15 and compensatory reactions to the traumatized genitalia in all the four groups – the surgical dissections was more in Group III and IV. The stress of repair and regeneration and more ~~of~~ corticosteroids could also have contributed (Benjamin, 1978 and Jain, 1986. In Group V, although the surgery was major, the

genitalia was removed, that curbed the inflammation and infection pathology, keeping the values low post operatively. Preoperatively the value was low due to exhaustion of neutrophils pools and body's defense. In Group VI, the limited pathology and minimal surgery with medication decreased the Neutrophil to normal.

The pre-operative **Lymphocyte** values in the affected groups were lower than that of the control group values, except in Group III, where the values were at par. This reflected lymphocytopenia in the pre-operative groups. Statistical analysis showed that there was a significant ( $P < 0.05$ ) decrease in post operative values in Groups I, II, III and nonsignificant decrease in Group IV (**Table 5**). The redistribution of circulating cells, in corticosteroids effect, hyperadrenocorticism and systemic or surgical stress, resulted in lymphocytopenia. So also, the neutrophilia due to inflammatory regenerative stress and corticosteroids, caused lymphocytopenia and eosinopenia (Benjanin, 1978). The post operative non-significant rise in lymphocytes in Group V might be due to prolonged antigenic stimulation through chronic infectious prolapse and in Group VI due to degenerative changes in ovaries.

The pre-operative **Monocyte** values in the Groups I, II, III and IV were highly significantly ( $P < 0.01$ ) lower and the values in Group VI was non-significantly lower than the control group values. Significant ( $P < 0.05$ ) increase in post-operative values over the pre-operative values were observed for Group I, II and IV with a non-significant increase in Group III. Significant ( $P < 0.05$ ) decrease in the post-operative values were found in Groups V and VI (**Table 5**). Taking into consideration the overall picture of monocytes in all the groups, we can conclude that a condition of varying degree of monocytopenia existed in all the affected animals, except in pre-operative stage of Group V.

However, if the mean values compared with the referral range for cattle, 2 to 5 (Cynthia and Scott, 2005), it were more, but within the normal range. The increase in monocyte count in Group V preoperative and Groups I to V post-operative could be due to stress of the prolapse, and surgery, tissue debris, either with the chronic prolapse or surgical trauma, vaginitis and cervicitis. Post-operatively the value decreased in Groups V and VI, as there was abolition of stress, tissue debris and infection (Benjamin, 1978; Jain, 1986), requiring no macrophage activity.

The **eosinophil** values of affected Groups I, II, III, IV and VI were significantly lower ( $P < 0.01$ ) than the control group, whereas values of Group V was significantly ( $P < 0.05$ ) higher than the control group (Table 6). Eosinophilia was associated with systemic stress, hyperadrenocorticism and use of corticosteroids. Group V was seemed to have exhausted to have favourable physiological response due to advanced grade of prolapse. Post-operative values in Group I, II, III, IV and VI were found to be significantly ( $P < 0.05$ ) higher than the corresponding pre-operative values. However, in Group V there was a significant ( $P < 0.05$ ) decrease in post-operative value as compared to pre-operative value. Post-operatively the eosinophil values were normal indicating loss of systemic stress.

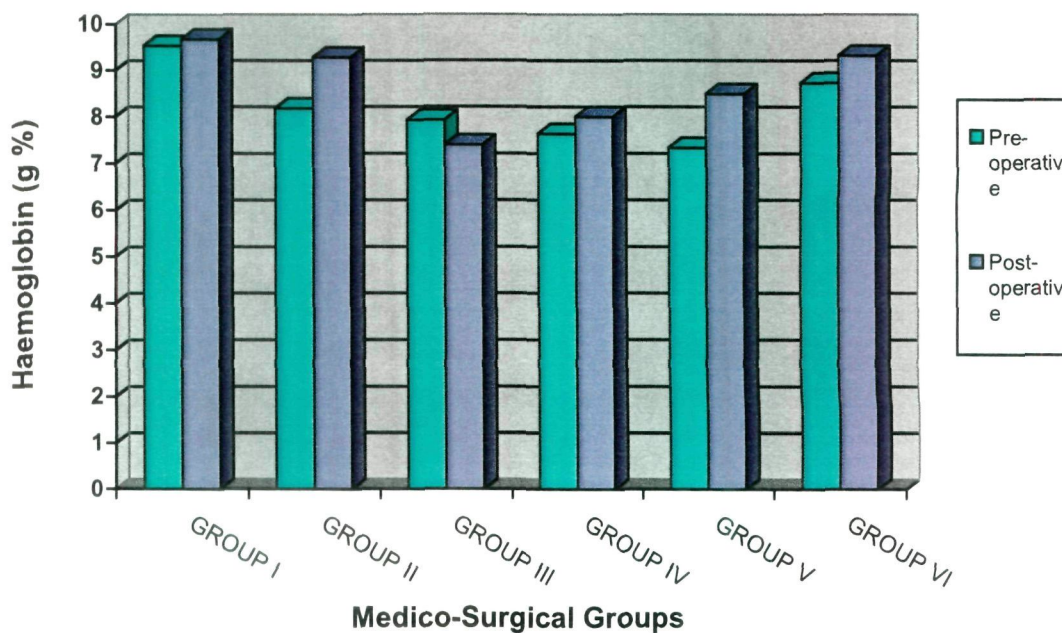
The pre- and post-operative values of **Basophils** both in the affected groups and in the control group were found to be within the normal range for the species. However, a significant ( $P < 0.05$ ) increase was noted in Group V over the control group. Non-significant increase in post-operative values was found in Groups II and III, whereas a non-significant decrease in post-operative value was found in Groups V and VI. The pre-operative and post-operative values were found to be at par in Groups I and IV. Basophilia may be associated with hyperadrenocorticism.

**Table 4. Mean ( $\pm$ SE) pre-operative and 7<sup>th</sup> day post-operative haematological profile of cows with cervico-vaginal prolapse**

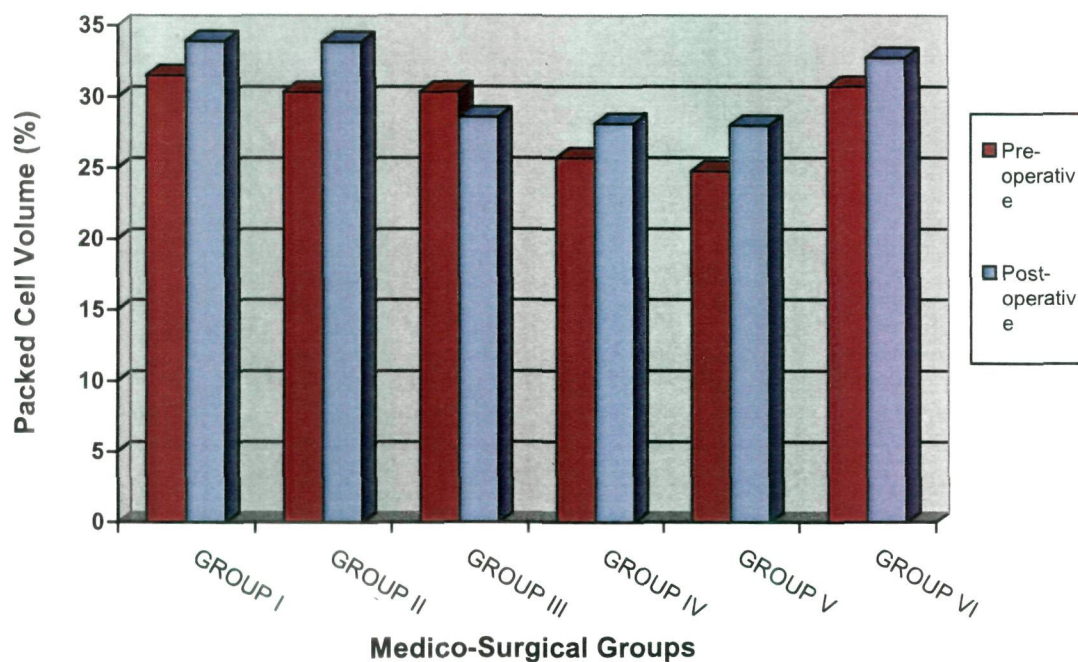
Group	No. of animals	Hb (g/dl)		PCV (%)		TEC (million/cmm)		TLC (thousand/cmm)	
		Pre-operative	Post-operative	Pre-operative	Post-operative	Pre-operative	Post-operative	Pre-operative	Post-operative
1. Prepubic tendon fixation	8	9.54 $\pm$ 0.61	9.68 $\pm$ 0.65	31.54 $\pm$ 1.01	33.91** $\pm$ 0.83	7.05 $\pm$ 0.33	8.29** $\pm$ 0.48	13.88 $\pm$ 0.94	18.31** $\pm$ 1.11
2. Modified Button suture fixation	8	8.18 $\pm$ 0.46	9.29** $\pm$ 0.67	30.35 $\pm$ 1.35	33.85** $\pm$ 1.72	6.49 $\pm$ 0.41	7.24** $\pm$ 0.49	15.36 $\pm$ 1.34	17.85** $\pm$ 0.85
3. Amputation of prolapsed mass	8	7.93 $\pm$ 0.38	7.40 $\pm$ 0.27	30.35 $\pm$ 1.35	28.59 $\pm$ 0.87	6.19 $\pm$ 0.49	5.60** $\pm$ 0.41	10.99 $\pm$ 1.04	13.24** $\pm$ 0.90
4. Submucosal reefing	8	7.64 $\pm$ 0.34	8.00* $\pm$ 0.24	25.70 $\pm$ 0.71	28.13** $\pm$ 0.75	5.99 $\pm$ 0.26	6.41** $\pm$ 0.28	11.83 $\pm$ 0.76	13.67** $\pm$ 0.75
5. Pan-hysterectomy	8	7.34 $\pm$ 0.32	8.49** $\pm$ 0.30	24.75 $\pm$ 1.44	27.99** $\pm$ 1.54	5.14 $\pm$ 0.60	6.39** $\pm$ 0.49	7.55 $\pm$ 0.43	9.78** $\pm$ 0.35
6. Bilateral ovariectomy	6	8.73 $\pm$ 0.36	9.32** $\pm$ 0.29	30.72 $\pm$ 1.05	32.75** $\pm$ 0.92	7.30 $\pm$ 0.28	7.82** $\pm$ 0.23	8.61 $\pm$ 0.72	11.25** $\pm$ 0.43

't' test : \* P < 0.05, \*\* P < 0.01 between pre- and post-operative values of a particular traits of a group.

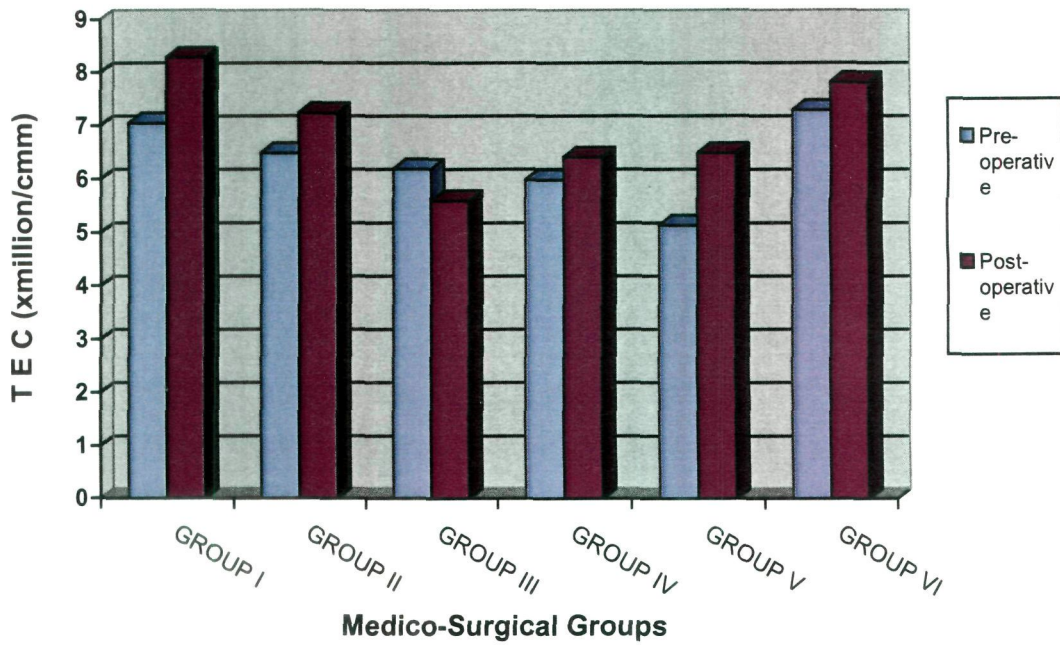
**Fig. 1. Pre- and post-operative Haemoglobin concentration (g%) in cows under different groups of medico-surgical management for cervico-vaginal prolapse**



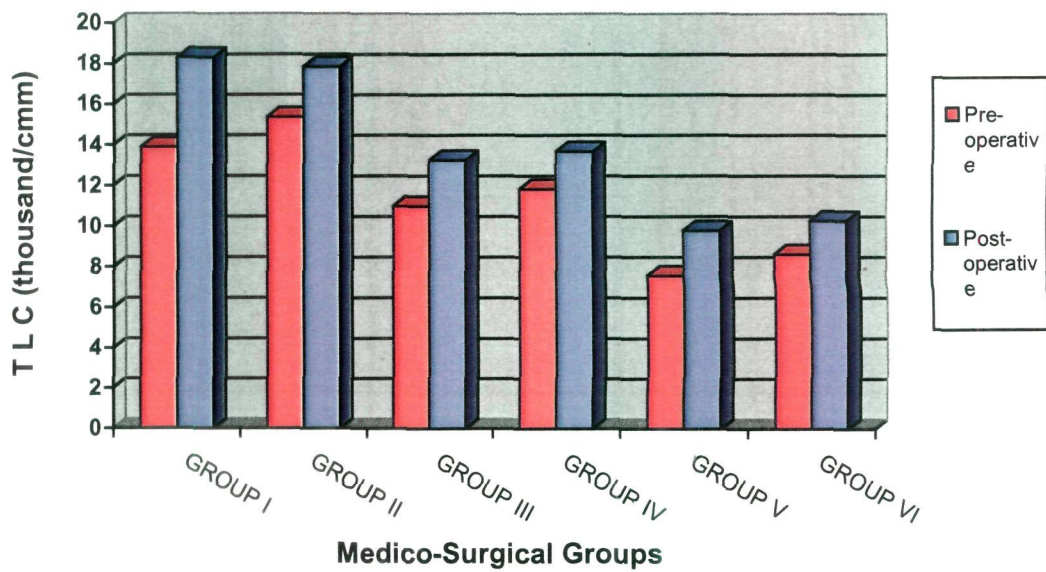
**Fig. 2. Pre- and post-operative PCV (%) in cows under different groups of medico-surgical management for cervico-vaginal prolapse**



**Fig. 3. Pre- and post-operative Total erythrocytes count (million/cmm) in cows under different groups of medico-surgical management for cervico-vaginal prolapse**



**Fig. 4. Pre- and post-operative Total leucocytes count (thousand/cmm) in cows under different groups of medico-surgical management for cervico-vaginal prolapse**



**Table 5. Mean ( $\pm$ SE) pre-operative and 7<sup>th</sup> day post-operative differential leucocytes count of cows with cervico-vaginal prolapse**

Group	No. of animals	Neutrophil (%)		Lymphocyte (%)		Monocyte (%)		Eosinophil (%)		Basophil (%)	
		Pre-operative	Post-operative	Pre-operative	Post-operative	Pre-operative	Post-operative	Pre-operative	Post-operative	Pre-operative	Post-operative
1. Prepubic tendon fixation	8	51.88 $\pm$ 2.98	54.50 $\pm$ 2.67	42.00 $\pm$ 2.75	34.88** $\pm$ 1.99	3.50 $\pm$ 0.38	5.88** $\pm$ 0.44	2.50 $\pm$ 0.19	4.25** $\pm$ 0.37	0.38 $\pm$ 0.18	0.38 $\pm$ 0.18
2. Modified Button suture fixation	8	53.50 $\pm$ 3.00	56.38 $\pm$ 1.96	40.00 $\pm$ 2.65	32.00** $\pm$ 1.56	3.50 $\pm$ 0.33	6.38** $\pm$ 0.38	2.63 $\pm$ 0.26	4.75** $\pm$ 0.49	0.37 $\pm$ 0.18	0.50 $\pm$ 0.19
3. Amputation of prolapsed mass	8	39.13 $\pm$ 3.58	43.75** $\pm$ 3.02	52.38 $\pm$ 3.15	46.25** $\pm$ 2.35	4.63 $\pm$ 0.49	5.37 $\pm$ 0.42	3.50 $\pm$ 0.33	4.50* $\pm$ 0.38	0.38 $\pm$ 0.18	0.75 $\pm$ 0.16
4. Submucosal reefing	8	43.88 $\pm$ 3.31	47.50* $\pm$ 2.52	45.38 $\pm$ 3.28	40.88 $\pm$ 2.14	5.25 $\pm$ 0.31	6.63** $\pm$ 0.37	3.00 $\pm$ 0.27	4.38** $\pm$ 0.26	0.63 $\pm$ 0.18	0.63 $\pm$ 0.18
5. Pan-hysterectomy	8	32.88 $\pm$ 2.40	36.86** $\pm$ 2.39	48.38 $\pm$ 3.34	55.29* $\pm$ 2.46	11.50 $\pm$ 0.57	6.43** $\pm$ 0.42	6.38 $\pm$ 0.46	3.57** $\pm$ 0.17	0.87 $\pm$ 0.13	0.71 $\pm$ 0.16
6. Bilateral ovariectomy	6	47.83 $\pm$ 2.50	36.83 $\pm$ 2.82	41.50 $\pm$ 2.81	52.00 $\pm$ 2.61	6.67 $\pm$ 0.49	5.67* $\pm$ 0.42	3.17 $\pm$ 0.31	3.83* $\pm$ 0.31	0.83 $\pm$ 0.17	0.67 $\pm$ 0.21

't' test : \* P < 0.05, \*\* P < 0.01 between pre- and post-operative values of a particular traits of a group.

**Table 6. Comparison of haematological profile of cows with cervico-vaginal prolapse and normal healthy cows (Mean  $\pm$  SE)**

Blood Parameter	Groups of animal with and without cervico-vaginal prolapse						
	1. Prepubic tendon fixation	2. Modified Button suture fixation	3. Amputation of prolapsed mass	4. Submucosal reefing	5. Pan-hysterectomy	6. Bilateral ovariectomy	7. Normal healthy control
Hb (g/dl)	9.54 $\pm$ 0.61	8.18 * $\pm$ 0.46	7.93* $\pm$ 0.38	7.64** $\pm$ 0.34	7.34** $\pm$ 0.32	8.73 $\pm$ 0.36	10.44 $\pm$ 0.80
PCV (%)	31.54 $\pm$ 1.01	30.35 $\pm$ 1.35	30.35* $\pm$ 1.35	25.70** $\pm$ 0.71	24.75** $\pm$ 1.44	30.72 $\pm$ 1.05	35.03 $\pm$ 2.01
TEC (x10 <sup>6</sup> /cmm)	7.05 $\pm$ 0.33	6.49* $\pm$ 0.41	6.19* $\pm$ 0.49	5.99** $\pm$ 0.26	5.14** $\pm$ 0.60	7.30 $\pm$ 0.28	8.03 $\pm$ 0.41
TLC (x10 <sup>3</sup> /cmm)	13.88** $\pm$ 0.94	15.36** $\pm$ 1.34	10.99 $\pm$ 1.04	11.83 $\pm$ 0.76	7.55** $\pm$ 0.43	8.61** $\pm$ 0.72	10.73 $\pm$ 0.54
Neutrophil (%)	51.88** $\pm$ 2.98	53.50** $\pm$ 3.00	39.13 $\pm$ 3.58	43.88 $\pm$ 3.31	32.88 $\pm$ 2.40	47.83** $\pm$ 2.50	36.25 $\pm$ 2.37
Lymphocyte (%)	42.00** $\pm$ 2.75	40.00** $\pm$ 2.65	52.38 $\pm$ 3.15	45.38 $\pm$ 3.28	48.38 $\pm$ 3.34	41.50** $\pm$ 2.81	51.75 $\pm$ 1.74
Monocyte (%)	3.50** $\pm$ 0.38	3.50** $\pm$ 0.33	4.63** $\pm$ 0.49	5.25** $\pm$ 0.31	11.50** $\pm$ 0.57	6.67 $\pm$ 0.49	7.00 $\pm$ 0.46
Eosinophil (%)	2.50** $\pm$ 0.19	2.63** $\pm$ 0.26	3.50* $\pm$ 0.33	3.00** $\pm$ 0.27	6.38** $\pm$ 0.46	3.17** $\pm$ 0.31	4.63 $\pm$ 0.32
Basophil (%)	0.38 $\pm$ 0.18	0.37 $\pm$ 0.18	0.38 $\pm$ 0.18	0.63 $\pm$ 0.18	0.87* $\pm$ 0.13	0.83 $\pm$ 0.17	0.38 $\pm$ 0.18

't' test : \* P < 0.05, \*\* P < 0.01 between affected and healthy groups for a particular trait.



The findings on DLC are in line with the observation of Ahmed *et al.* (2005) and Tarjinder and Singh (1993). The condition of neutrophilia, lymphocytopenia and monocytopenia in the affected groups as compared to the control group may be due to increased levels of cortisol hormone due to stress (Verma *et al.*, 1989) or inflammatory process involved in genital prolapse (Malik *et al.*, 1990) and also due to stress of surgery on the animals. Neutrophilia may also be due to excitement and adrenaline release (Sastry, 1989).

#### **4.8.2 Serum Biochemistry**

##### **4.8.2.1 Serum Aspartate Transaminase (AST – IU/L) :**

The mean pre-operative serum aspartate transaminase (AST – IU/L) activities noted in the affected Groups I to VI were  $87.88 \pm 7.09$ ,  $91.00 \pm 6.83$ ,  $111.75 \pm 7.39$ ,  $99.00 \pm 6.89$ ,  $104.75 \pm 7.60$  and  $96.50 \pm 5.88$ , respectively. The corresponding post-operative values were recorded to be  $100.63 \pm 7.94$ ,  $101.63 \pm 6.96$ ,  $133.88 \pm 5.13$ ,  $109.87 \pm 7.80$ ,  $96.29 \pm 6.83$  and  $75.17 \pm 5.00$ , respectively (Fig. 5). The mean value in the control group was  $79.13 \pm 10.49$  IU/L (Tables 7 and 9).

Statistical comparison of the AST activity in the control group with the corresponding pre-operative values in the affected groups indicated that the activity in the affected Groups I, II, IV, V and VI was non-significantly higher and the activity in Group III was significantly ( $P < 0.05$ ) higher than that in the control group.

Statistical analyses of the pre- and post-operative data in the six affected groups showed higher post-operative AST activity in Groups I, II, III and IV, which was highly significant ( $P < 0.01$ ). Significantly ( $P < 0.01$ ) lower post-operative activity in Group VI and non-significantly lower post-operative activity in Group V was observed.



The pre-operative increase in AST activity over that of the control group may be due to hepatocellular damage (Kaneko, 1990) due to toxæmia resulting from long standing prolapse condition. The post-operative increase in AST levels is due to cellular damage as a result of surgery. The lower post-operative activity in Groups V and VI as compared to the activity in the prolapsed animal may indicate recovery of the animal after surgery. In Group VI the post-operative activity is on par with the control group, suggesting near to complete recovery of the animals in this group.

Azawi *et al.* (2007) examined AST activities in 42 buffalo cows with toxic puerperal metritis due to various calving disorders, including the uterine prolapse in six of them. They found significantly higher AST activities in affected buffaloes ( $242.7 \pm 12.9$  IU/L) than the control group ( $166.8 \pm 11.5$  IU/L) which they attributed to destruction of the cells in the uterine wall. They opined that estimation of AST values could be a valuable aid for the determination of uterine tissue destruction.

#### **4.8.2.2 Serum Alanine Transaminase (ALT – IU/L) :**

The average pre-operative serum alanine transaminase (ALT – IU/L) activities (Table 7) in the affected Groups I to VI were observed to be  $34.13 \pm 2.23$ ,  $34.88 \pm 3.29$ ,  $40.00 \pm 2.57$ ,  $38.00 \pm 2.05$ ,  $35.88 \pm 2.42$ ,  $34.00 \pm 2.72$ , respectively and the corresponding post-operative values were  $39.13 \pm 1.96$ ,  $40.75 \pm 2.55$ ,  $46.50 \pm 2.14$ ,  $43.38 \pm 2.43$ ,  $31.71 \pm 1.35$  and  $33.17 \pm 3.55$ , respectively (Table 7, Fig. 6). The average serum ALT activity in the control group was noted to be  $31.75 \pm 3.26$  IU/L (Table 9).

Comparison of ALT activity of the control group with that of the pre-operative affected groups revealed that the serum ALT (IU/L) activity in all the affected groups was non-significantly higher, except in Group III, where it was significantly ( $P < 0.05$ ) higher than in the control group.



Statistical analyses highlighted that the increase in post-operative ALT activity over that of the pre-operative value, in Groups I, II, III and IV was highly significant ( $P < 0.01$ ). However, in Group V there was a significant ( $P < 0.05$ ) decrease and in Group VI there was a non-significant decrease in the post-operative ALT activity from the pre-operative activity.

The higher pre-operative values as compared to the control group value may be due to degeneration of hepatocytes and also the muscular coat of the gravid uterus leading to the leakage of the enzyme into the blood (Tarjinder and Singh, 1993). Increase in ALT activity in post-operative cases and in pre-operative prolapse cases over that observed in the control group, may also be due to hepatic or muscular cell damage (Kaneko, 1990) occurring due to surgical trauma. The tissue cellular damage causes the enzymes to move into the blood, increasing its activity in the circulation.

#### 4.8.2.3 Serum Calcium (Ca – mg/dl) :

The average pre-operative levels of serum calcium (mg/dl) were recorded to be  $8.65 \pm 0.19$ ,  $9.35 \pm 0.42$ ,  $8.91 \pm 0.28$ ,  $8.85 \pm 0.26$ ,  $8.86 \pm 0.25$ ,  $9.68 \pm 0.42$  in the six affected Groups I to VI, respectively. The corresponding post-operative levels were  $10.59 \pm 0.48$ ,  $10.66 \pm 0.34$ ,  $10.54 \pm 0.45$ ,  $10.86 \pm 0.43$ ,  $11.21 \pm 0.27$ ,  $10.25 \pm 0.57$ , respectively (Fig. 7). The mean serum calcium level noted in the control group was  $11.18 \pm 0.50$  mg/dl (Tables 7 and 9).

On comparing the control group value with those of the affected Groups I to VI, it was deduced that there was a highly significant ( $P < 0.01$ ) decrease in serum Ca levels in all the affected groups.

Statistical analyses showed that the increase in post-operative serum Ca (mg/dl) levels over that of the pre-operative values were highly significant ( $P < 0.01$ ) in Groups I, II, III, IV and V, whereas it was non-significantly higher in Group VI.

The low levels of serum calcium observed in all the groups as compared to the control group, is one of the main causes for prolapse. Decreased calcium levels lead to atony of the uterus and a delay in cervical involution, both of which could predispose to uterine prolapse in dairy cows (Odegaard, 1977 and Roberts, 1971). Similarly, Risco *et al.* (1984) reported that hypocalcaemia resulted in loss of muscular contractions and ultimately uterine prolapse in buffaloes. Moreover, estrogen hormone suppresses the blood calcium levels causing relaxation of pelvic ligaments leading to genital prolapse (Richardson *et al.*, 1981). However, Richardson *et al.* (1981) were of the view that hypocalcaemia could have been a result of the uterine prolapse rather than a cause of it. This could probably explain the increased calcium levels in the post-operative animals as compared to the pre-operative animals. Post-operative (after 6 days of surgery) increase in Ca levels to near control group values, indicate the recoupment of the general health of the animal.

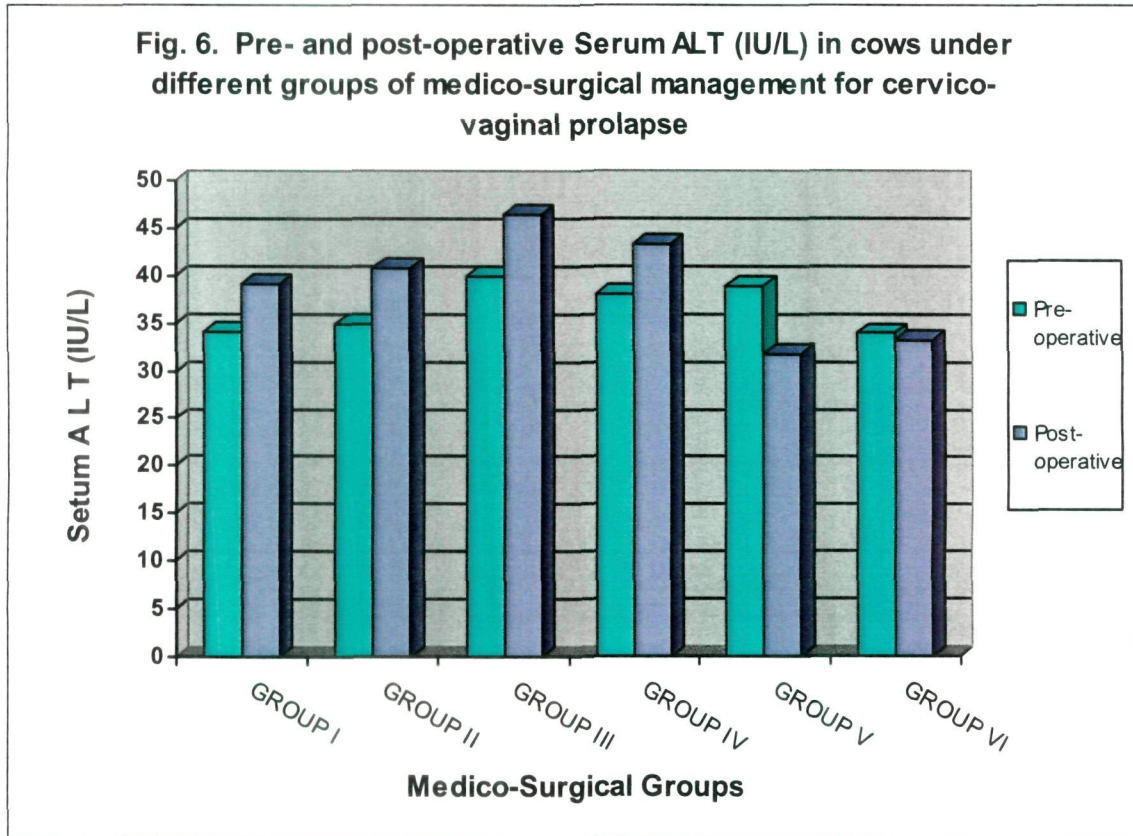
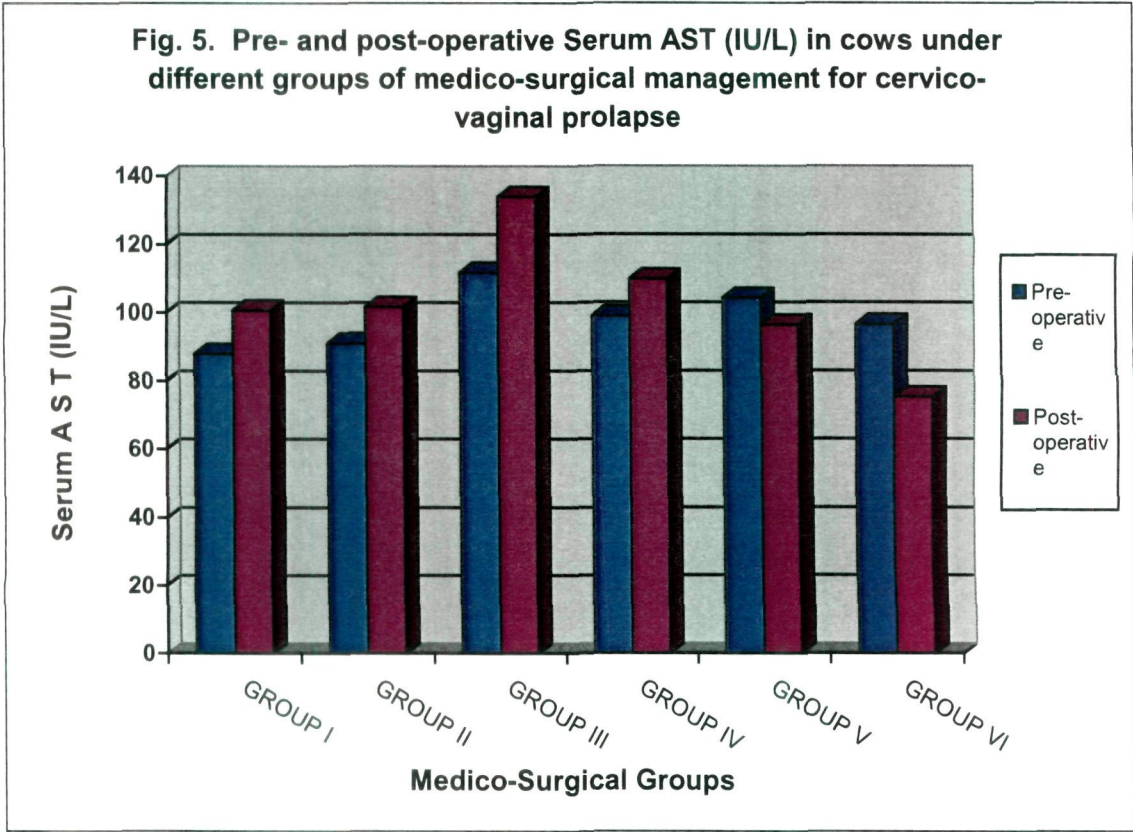
#### **4.8.2.4 Serum Inorganic Phosphorus (Pi – mg/dl) :**

The average pre-operative levels of serum inorganic phosphorus (mg/dl) in the six affected Groups I to VI were found to be  $5.06 \pm 0.21$ ,  $5.14 \pm 0.24$ ,  $4.66 \pm 0.30$ ,  $4.73 \pm 0.36$ ,  $4.76 \pm 0.25$  and  $5.13 \pm 0.34$ , respectively. The corresponding post-operative levels were noted as  $6.03 \pm 0.19$ ,  $5.65 \pm 0.24$ ,  $5.19 \pm 0.23$ ,  $5.50 \pm 0.20$ ,  $5.75 \pm 0.23$  and  $5.85 \pm 0.31$ , respectively (**Fig. 8**). The mean serum inorganic phosphors level noted in the control group was  $5.88 \pm 0.21$  mg/dl (**Tables 7 and 9**).

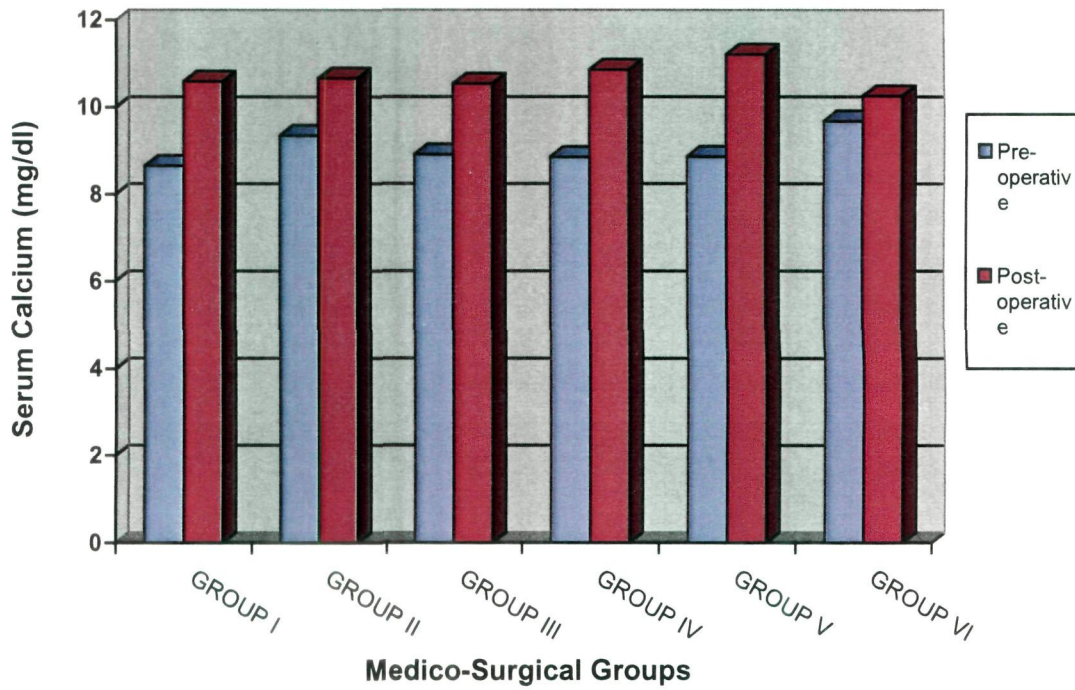
Table 7. Mean ( $\pm$ SE) pre-operative and 7<sup>th</sup> day post-operative serum biochemical profile of cows with cervico-vaginal prolapse

Group	No. of animals	AST (IU/L)		ALT (IU/L)		Calcium (mg/dl)		Phosphorus (mg/dl)	
		Pre-operative	Post-operative	Pre-operative	Post-operative	Pre-operative	Post-operative	Pre-operative	Post-operative
1. Prepubic tendon fixation	8	87.88 $\pm$ 7.09	100.63** $\pm$ 7.95	34.13 $\pm$ 2.33	39.13** $\pm$ 1.96	8.65 $\pm$ 0.19	10.59** $\pm$ 0.48	5.06 $\pm$ 0.21	6.03* $\pm$ 0.20
2. Modified Buton suture fixation	8	91.00 $\pm$ 6.88	101.63** $\pm$ 6.96	34.88 $\pm$ 3.29	40.75** $\pm$ 3.06	9.35 $\pm$ 0.42	10.66* $\pm$ 0.35	5.14 $\pm$ 0.24	5.65** $\pm$ 0.24
3. Amputation of prolapsed mass	8	111.75 $\pm$ 7.39	133.88** $\pm$ 5.13	40.00 $\pm$ 2.58	46.50** $\pm$ 2.14	8.91 $\pm$ 0.28	10.54** $\pm$ 0.45	4.66 $\pm$ 0.30	5.19 $\pm$ 0.23
4. Submucosal reefing	8	99.00 $\pm$ 6.89	109.87** $\pm$ 7.80	38.00 $\pm$ 2.05	43.38** $\pm$ 2.43	8.85 $\pm$ 0.26	10.86** $\pm$ 0.44	4.73 $\pm$ 0.36	5.50* $\pm$ 0.21
5. Pan-hysterectomy	8	104.25 $\pm$ 7.60	96.29 $\pm$ 6.83	35.88 $\pm$ 2.42	31.71* $\pm$ 1.35	8.86 $\pm$ 0.25	11.21** $\pm$ 0.27	4.76 $\pm$ 0.26	5.75** $\pm$ 0.23
6. Bilateral ovariectomy	6	96.50 $\pm$ 5.88	75.17** $\pm$ 5.00	34.00 $\pm$ 2.72	33.17 $\pm$ 3.55	9.68 $\pm$ 0.42	10.25 $\pm$ 0.57	5.13 $\pm$ 0.34	5.85* $\pm$ 0.32

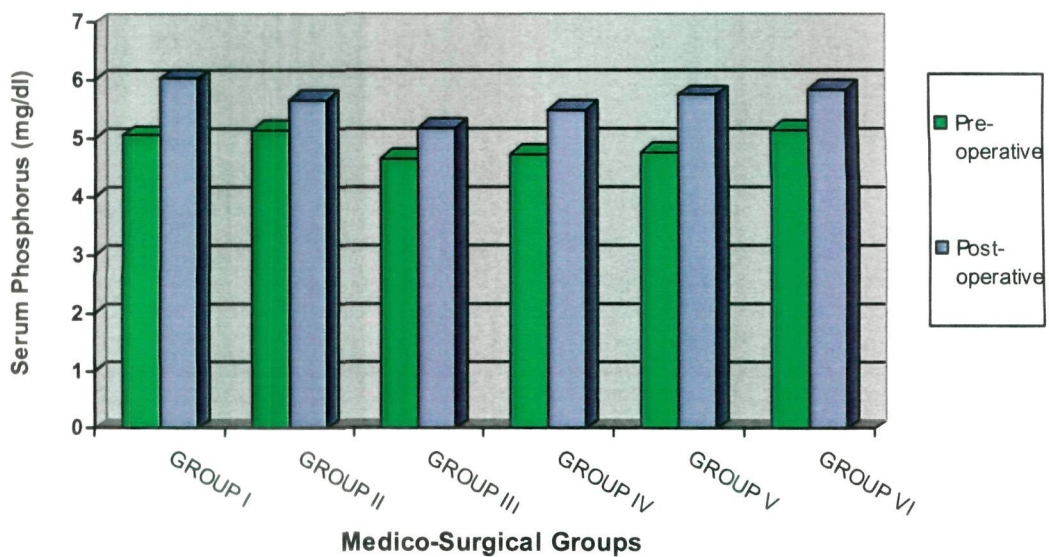
't' test : \* P < 0.05, \*\* P < 0.01 between pre- and post-operative values of a particular traits of a group.



**Fig. 7. Pre- and post-operative Serum Calcium levels in cows under different groups of medico-surgical management for cervico-vaginal prolapse**



**Fig. 8. Pre- and post-operative Serum inorganic Phosphorus (mg/dl) in cows under different groups of medico-surgical management for cervico-vaginal prolapse**



The pre-operative serum Pi (mg/dl) levels in the affected Groups I to V were found to be significantly ( $P < 0.05$ ) lower and in Group VI to be non-significantly lower than in the control group.

Statistical analyses revealed that the higher post-operative than the corresponding pre-operative levels of serum Pi (mg/dl) were significant ( $P < 0.05$ ) in Groups I, IV and VI, highly significant ( $P < 0.01$ ) in Groups II and V and non-significant in Group III.

Ahmed *et al.* (2005) opined that deficiency of phosphorus might be a possible cause of genital prolapse. Renault (1980) observed that vaginal prolapse in cows and ewes were associated with phosphorus deficiency in certain areas of France. Pathak and Janakiraman (1987) reported calcitonin and progesterone insufficiency to cause hypophosphemia in cattle. However, Paul *et al.* (2000) found Pi levels in buffaloes having uterine prolapse similar to normal pregnant buffaloes.

#### **4.8.3 Serum Hormones**

##### **4.8.3.1 Serum Progesterone (ng/ml) :**

The average pre-operative serum progesterone (ng/ml) levels determined in the affected Groups I to VI were  $2.11 \pm 0.72$ ,  $2.50 \pm 0.57$ ,  $1.93 \pm 0.55$ ,  $2.48 \pm 0.56$ ,  $1.47 \pm 0.31$  and  $1.55 \pm 0.36$ , respectively. The corresponding post-operative concentrations were recorded to be  $1.40 \pm 0.18$ ,  $2.78 \pm 0.55$ ,  $2.24 \pm 0.53$ ,  $3.09 \pm 0.68$ ,  $1.18 \pm 0.29$  and  $1.48 \pm 0.18$ , respectively (**Fig. 9**) The mean value in the control group was  $4.27 \pm 0.21$  ng/ml (**Tables 8 and 9**).

The pre-operative serum progesterone levels in all the six affected groups were found to be highly significantly ( $P < 0.01$ ) lower as compared to the control group. Statistical analyses of the data showed that the post-operative levels in Groups I, V and

VI were non-significantly lower than the corresponding pre-operative levels. However, in Group II, III and IV significantly higher postoperative levels over the pre-operative levels were observed.


Low level of progesterone in the animals was found to be associated with cervico-vaginal prolapse (Agrawal and Prasad, 2001). Matsas (1993) found that the blood progesterone concentration was low (< 2 ng/ml) in cows with cervico-vaginal prolapse. The findings in the present study are in line with the above reports.

#### **4.8.3.2 Serum Estradiol-17 $\beta$ (pg/ml) :**

The average pre-operative serum estradiol-17 $\beta$  (pg/ml) levels observed in the affected Groups I to VI were  $13.25 \pm 1.52$ ,  $16.88 \pm 3.03$ ,  $13.38 \pm 1.51$ ,  $15.37 \pm 1.93$ ,  $16.00 \pm 2.28$  and  $38.16 \pm 1.18$ , respectively. The corresponding post-operative levels were recorded to be  $11.00 \pm 0.68$ ,  $16.37 \pm 2.62$ ,  $12.50 \pm 1.45$ ,  $12.50 \pm 1.34$ ,  $12.43 \pm 1.18$  and  $19.83 \pm 2.91$ , respectively (Fig. 10). The mean value noted in the control group was  $23.64 \pm 2.46$  pg/ml (Tables 8 and 9).

The pre-operative estradiol-17 $\beta$  levels in all the Groups, except Group VI, were lower than the control group levels. The pre-operative values were non-significantly lower in Group II, IV and V, and significantly ( $P < 0.05$ ) lower in Groups I and III than the control group. In Group VI (ovariectomy) the pre-operative estradiol-17 $\beta$  levels were highly significantly more ( $P < 0.01$ ) than the control Group.

Statistical comparison between the pre- and post-operative values of estradiol-17 $\beta$  revealed that there was non-significant decrease in the post-operative values in all the groups, except Group-IV. In Group-IV, the post-operative decrease was highly significant ( $P < 0.01$ ). The significantly high pre-operative values of estradiol-17 $\beta$  in the



Group-VI could be due to cystic ovarian changes. It corroborated the clinical finding of cystic ovarian changes in this group. Cystic ovaries are known to cause CVP in cows (Agarwal and Prasad, 2001; Arthur *et al.*, 2001). Prasad and Agarwal (2000) and Ghuman *et al.* (2008) reported cases of CVP caused because of the cystic ovarian disease. In the remaining group, I to V, the pre-operative values of estradiol-17 $\beta$  were not higher than the control group. Actually, this pre-operative values in the present study were after a few days of prolapse as the cases were chronic. The values might have been higher on the day of prolapse, however, that is an assumption. From the values observed, the role of estrogen could not be determined in causing the prolapse. Ali (2008) also reported low values of estradiol-17 $\beta$  ( $29.76 \pm 1.42$  pg/ml) in postpartum uterine prolapse than in the normal postpartum buffaloes ( $35.88 \pm 0.71$  pg/ml).

Decrease in the post-operative values of estradiol-17 $\beta$  than that of the pre-operative values may suggest the reforming of physiological events in these animals.

Endocrine disturbances are considered as one of the etiology for prolapse (Kumar *et al.*, 2009<sup>a</sup>). High level of blood estrogen in the last trimester of pregnancy causes relaxation of pelvic ligaments and birth canal (Hudson, 1986), there by favouring prolapse. Misra (1998) and Agarwal and Prasad (2001) reported estrogen as one of the important etiological factors causing prolapse. Siddiquee *et al.* (2006) suggested that changes in the ratio of estradiol and progesterone increases the risk of vaginal prolapse in buffaloes. The altered estradiol-17 $\beta$  levels may be due to increased placental secretion (Kumar *et al.*, 2009<sup>b</sup>).

#### **4.8.3.3 Serum Cortisol (ng/ml) :**

The average pre-operative serum cortisol (ng/ml) levels in the six affected Groups I to VI were estimated to be  $14.01 \pm 1.89$ ,  $16.61 \pm 1.96$ ,  $17.06 \pm 2.11$ ,  $22.02 \pm$

2.47,  $22.04 \pm 0.84$  and  $15.64 \pm 1.04$ , respectively. The corresponding post-operative levels were  $7.11 \pm 0.85$ ,  $5.60 \pm 0.79$ ,  $6.82 \pm 1.17$ ,  $11.17 \pm 2.32$ ,  $7.46 \pm 1.44$ ,  $10.99 \pm 1.73$ , respectively (Fig. 11). The average value recorded in the control group was  $11.40 \pm 0.66$  ng/ml (Tables 8 and 9).

Comparison of the pre-operative serum cortisol levels in the six affected groups to that of the control group showed very high levels in all six Groups. The increase in the pre-operative groups I, II and VI which were with Grade III of prolapse, was significant ( $P < 0.05$ ), while in pre-operative Groups III, IV and V, which were with Grade IV of the prolapse was highly significant ( $P < 0.01$ ) than the control Group. This could be the direct reflection of the amount of stress the animals were going through with the chronic CVP as per the severity of the grade of prolapse.

Statistical analyses of the pre- and post-operative serum cortisol levels revealed severe drop in all the post-operative groups of prolapse that was even below the levels of control group. The decrease in the post-operative Group I to V was highly significant ( $P < 0.01$ ) and in Group VI it was significant ( $P < 0.05$ ). This suggested that the cows were relieved of the stress from the condition of the chronic CVP by the provision of the medico-surgical treatments.

The present data is not in a large number of cases and there were lot of variations in various aspects, like reproductive cycles, infections and severity of lesions. So the role of hormones in the chronic CVP could not be evaluated from the study. Cortisol is the major stress hormone in ruminants. Goff *et al.* (1990) reported that cortisol causes immune-suppression, hypocalcaemia and loss of muscular contractions.

**Table 8. Mean ( $\pm$ SE) pre-operative and 7<sup>th</sup> day post-operative serum hormonal profile of cows with cervico-vaginal prolapse**

Group	No. of animals	Progesterone (ng/ml)		Estradiol-17 $\beta$ (pg/ml)		Cortisol (ng/ml)	
		Pre-operative	Post-operative	Pre-operative	Post-operative	Pre-operative	Post-operative
1. Prepubic tendon fixation	8	2.11 $\pm$ 0.72	1.40 $\pm$ 0.18	13.25 $\pm$ 1.52	11.00 $\pm$ 0.68	14.01 $\pm$ 1.89**	7.11 $\pm$ 0.85
2. Modified Button suture fixation	8	2.50 $\pm$ 0.57	2.78 $\pm$ 0.55	16.88 $\pm$ 3.03	16.37 $\pm$ 2.62	16.61 $\pm$ 1.96**	5.60 $\pm$ 0.79
3. Amputation of prolapsed mass	8	1.93 $\pm$ 0.55	2.24 $\pm$ 0.53*	13.38 $\pm$ 1.51	12.50 $\pm$ 1.45	17.06 $\pm$ 2.11**	6.82 $\pm$ 1.17
4. Submucosal reefing	8	2.48 $\pm$ 0.56	3.09 $\pm$ 0.68*	15.37 $\pm$ 1.93	12.50 $\pm$ 1.34	22.02 $\pm$ 2.47**	11.17 $\pm$ 2.32
5. Panhysterectomy	8	1.47 $\pm$ 0.31	1.18 $\pm$ 0.29	16.00 $\pm$ 2.28	12.43 $\pm$ 1.18	22.04 $\pm$ 0.84**	7.46 $\pm$ 1.44
6. Bilateral ovariectomy	6	1.55 $\pm$ 0.36	1.48 $\pm$ 0.18	38.16 $\pm$ 1.82**	19.83 $\pm$ 2.91	15.64 $\pm$ 1.04*	10.99 $\pm$ 1.73

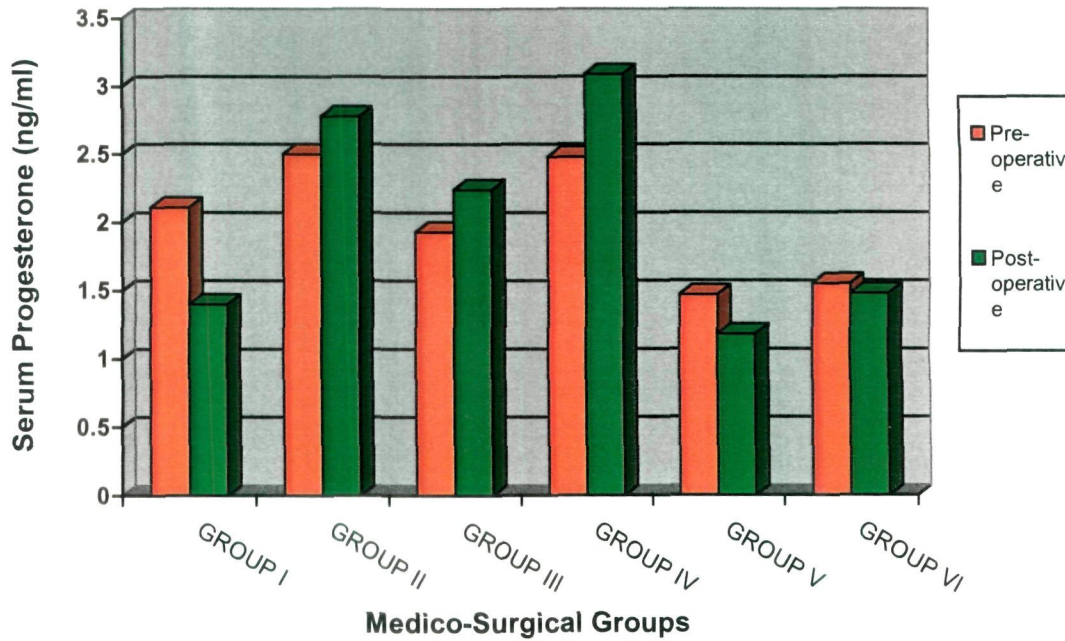
't' test : \* P < 0.05, \*\* P < 0.01 between pre- and post-operative values of a particular traits of a group.

**Table 9. Comparison of serum biochemical and hormonal profile of cows with cervico-vaginal prolapse and normal healthy cows (Mean  $\pm$  SE)**

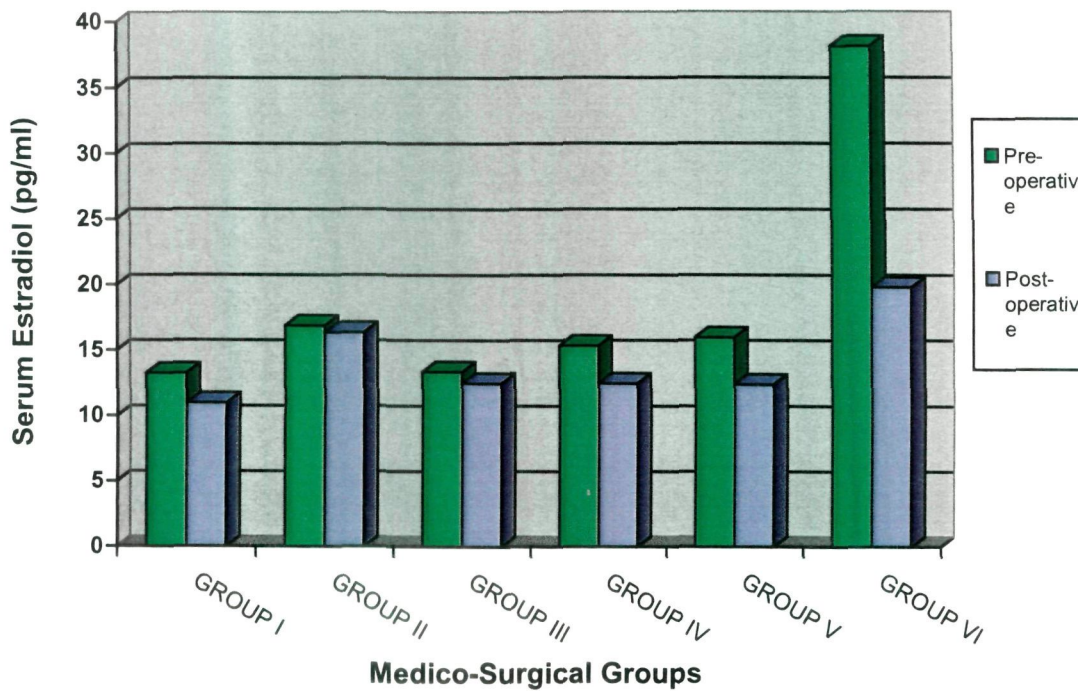
Serum profile	Groups of animal with and without cervico-vaginal prolapse						
	1. Prepubic tendon fixation	2. Modified Button suture fixation	3. Amputation of prolapsed mass	4. Submucosal reefing	5. Pan-hysterectomy	6. Bilateral ovariectomy	7. Normal healthy control
AST (IU/L)	87.88 $\pm$ 7.09	91.00 $\pm$ 6.88	111.75* $\pm$ 7.39	99.00 $\pm$ 6.89	104.25 $\pm$ 7.60	96.50 $\pm$ 5.88	79.13 $\pm$ 10.49
ALT (IU/L)	34.13 $\pm$ 2.33	34.88 $\pm$ 3.29	40.00* $\pm$ 2.58	38.00 $\pm$ 2.05	35.88 $\pm$ 2.42	34.00 $\pm$ 2.72	31.75 $\pm$ 3.26
Calcium (mg/ml)	8.65** $\pm$ 0.19	9.35* $\pm$ 0.42	8.91** $\pm$ 0.28	8.85** $\pm$ 0.26	8.86** $\pm$ 0.25	9.68* $\pm$ 0.42	11.18 $\pm$ 0.50
Phosphorus (mg/ml)	5.06* $\pm$ 0.21	5.14* $\pm$ 0.24	4.66** $\pm$ 0.30	4.73* $\pm$ 0.36	4.76** $\pm$ 0.26	5.13 $\pm$ 0.34	5.88 $\pm$ 0.21
Progesterone (ng/ml)	2.11 $\pm$ 0.72**	2.50 $\pm$ 0.57**	1.93 $\pm$ 0.55**	2.48 $\pm$ 0.56**	1.47 $\pm$ 0.31**	1.55 $\pm$ 0.36**	12.63 $\pm$ 1.40
Estradiol (pg/ml)	13.25 $\pm$ 1.52*	16.88 $\pm$ 3.03	13.38 $\pm$ 1.51*	15.37 $\pm$ 1.93	16.00 $\pm$ 2.28	38.16 $\pm$ 1.82**	23.64 $\pm$ 2.46
Cortisol (ng/ml)	14.01 $\pm$ 1.89*	16.61 $\pm$ 1.96*	17.06 $\pm$ 2.11**	22.02 $\pm$ 2.47**	22.04 $\pm$ 0.84**	15.64 $\pm$ 1.04*	11.40 $\pm$ 0.66

't' test : \* P < 0.05, \*\* P < 0.01 between affected and healthy groups for a particular trait.

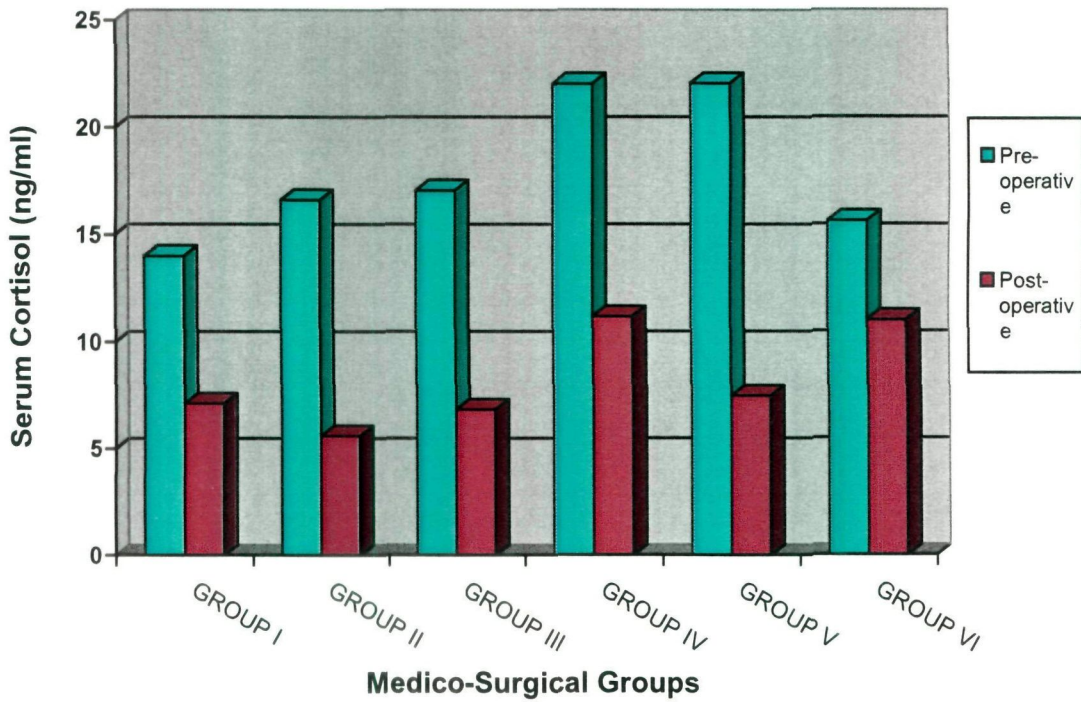
**Fig. 9. Pre- and post-operative Serum Progesterone (ng/ml) in cows under different groups of medico-surgical management for cervico-vaginal prolapse**



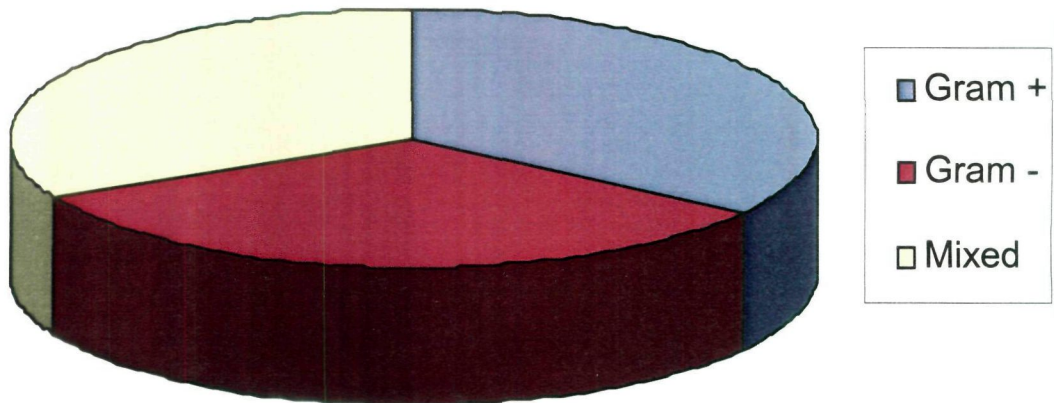
**Fig. 10. Pre- and post-operative Serum Estradiol concentration (pg/ml) in cows under different groups of medico-surgical management for cervico-vaginal prolapse**



**Fig. 11. Pre- and post-operative Serum Cortisol concentration (ng/ml) in cows under different groups of medico-surgical management for cervico-vaginal prolapse**



**Fig. 12. Bacterial isolates from cervico-vaginal swabs of CVP cases**



#### 4.9 Cultural Isolation and Antibiotics Sensitivity of Genital Microflora

Cervico-vaginal swabs collected from the cases of prolapse before (46) and after (29) medico-surgical management were put to culture and antibiotic sensitivity test as per the method described by Cruickshank (1965). Gram staining of the organisms was performed. The results of pre-treatment swabs of 46 cases cultured revealed that cent per cent swabs gave one or the other type of bacterial isolate.

Out of total 46 cases, 16 cows (34.78%) had Gram +ve cocci and rods, and 15 (32.61%) had Gram -ve cocci and rods, while in 15 (32.61%) cows mixed culture of both Gram +ve and Gram -ve cocci and rods was obtained (Table 10, Fig. 12). Gram -ve and mixed organisms were more prevalent in Group III and IV. Azawi *et al.* (2007) found *E. coli*, *Archanobacterium pyogenes*, *Staphylococcus aureus* and *Fusobacterium necrophorum* as the main isolates from 42 buffaloes with toxic puerperal metritis.

The sensitivity spectrum of the antibiotics and the severity of the microbial pathogens in the various groups were given considerations for the selection of antibiotics. Group I and II included the cases of Grade II severity of prolapse. In these groups, surgical intervention was not major, it did not involve dissection of tissues. So comparatively less severe pathogens were expected in these groups. Hence a broad spectrum antibiotic, Amoxirum, was used. In Groups III, IV and V the cases were of Grade III and Grade IV severity of prolapse. The Group III, IV, V and VI involved major surgical intervention, more dissection of the tissues. So, comparatively more infection and pathogenesis was expected, hence the higher antibiotics, Enrofloxacin and Cefriaxone, were used in these groups. The uterine environment is comparatively anaerobic. The antibiotic selected for the genital organs is required to be active in the absence of oxygen, and it should reach the deep layers of genitalia (Risco *et al.*, 1997).

Further, we require antibiotics that can be used parenterally as well as topically. Accordingly, Amoxicillin with Sulbactam, Enrofloxacin and Ceftriaxone were used.

Among the 16 gram positive samples, 12 were highly sensitive and 4 were moderately sensitive to Amoxicillin. All the sixteen gram positive samples were highly sensitive to Enrofloxacin and Ceftriaxone. Out of the 15 gram negative isolates, 5 were moderately sensitive, 10 were resistant to Amoxicillin. Eight of the gram negative isolates were highly sensitive and 7 were moderately sensitive to Enrofloxacin. Fourteen gram negative isolates were highly sensitive and one was moderately sensitive to Ceftriaxone. From the 15 mixed isolates, one was moderately sensitive and 14 were resistant to Amoxicillin. Seven mixed isolates were highly sensitive, 6 were moderately sensitive and 2 were resistant to Enrofloxacin. Eight of the mixed isolates were highly sensitive, 6 were moderately sensitive and one was resistant to Ceftriaxone.

Overall sensitivity pattern for 46 isolates, regardless of the type was as follows. 12 (26.08%) isolates were highly sensitive, 10 (21.73%) were moderately sensitive and 24 (52.17%) were resistant to Amoxicillin. Thirty one (67.39%) isolates were highly sensitive, 13 (28.26%) were moderately sensitive and 2 (4.34%) were resistant to Enrofloxacin. Thirty eight (82.61%) isolates were highly sensitive, 7 (15.21%) were moderately sensitive and 1 (2.17%) isolate was resistant to Ceftriaxone.

The group-wise details are shown in **Annexure-I**. In group 1, the organisms isolated were highly sensitive to Amoxicillin in 4 cases (50%), to Enrofloxacin in 6 (75%) and to Ceftriaxone in 8 (100%) cases. They were moderately sensitive to Amoxicillin in 1 case (12.5%), to Enrofloxacin in 2 cases (25%), and resistant to Amoxicillin in 3 cases (37.5%).

**Table 10. Bacterial isolates from the genital swabs and their antibiotics sensitivity pattern in cows with cervico-vaginal prolapse**

Group	Samples Tested	Isolates (pre-operative)			Antibiotics sensitivity (HS/MS/R)			Isolates (post-operative)			
		Gram +	Gram -	Mixed	Amoxicirum	Enro-floxacin	Ceftriaxone	Samples	Gram +	Gram -	Mixed
1. Prepubic tendon fixation	8	4	3	1	4/1/3	6/2/0	8/0/0	0	-	-	-
2. Modified Button suture fixation	8	4	2	2	4/1/3	6/2/0	7/1/0	0	-	-	-
3. Amputation of prolapsed mass	8	2	3	3	0/3/5	6/2/0	8/0/0	8	0	1	1
4. Submucosal reefing	8	1	3	4	0/3/5	4/4/0	6/1/1	8	0	0	1
5. Pan-hystere-ctomy	8	1	2	5	0/2/6	2/4/2	4/4/0	7	0	1	2
6. Bilateral ovariectomy	6	4	2	0	4/0/2	6/0/0	6/0/0	6	0	0	0
<b>Overall</b>	<b>46</b>	<b>16 (34.78)</b>	<b>15 (32.61)</b>	<b>15 (32.61)</b>	<b>12/10/24</b>	<b>31/13/02</b>	<b>38/07/01</b>	<b>29</b>	<b>0</b>	<b>2</b>	<b>4</b>

**Note:** For Groups I and II, genital swabs were not examined post-operatively.  
 HS highly sensitive, MS moderately sensitive, R resistant to particular antibiotic/s.

In group II the isolates were highly sensitive to Amoxicillin in 4 cases (50%), to Enrofloxacin in 6 cases (75%) and to Ceftriaxone in 7 cases (87.50%). These were moderately sensitive to Amoxicillin in 1 case (12.5%), to Enrofloxacin in 2 cases (25%), to Ceftriaxone in 1 case (12.5%), and resistant to Amoxicillin in 3 cases (37.5%).

In group III, the organisms isolated were highly sensitive to Enrofloxacin in 6 cases (75%) and to Ceftriaxone in 8 cases (100%). They were moderately sensitive to Amoxicillin in 3 cases (37.5%), to Enrofloxacin in 2 cases (25%), and resistant to Amoxicillin in 5 cases (62.5%).

In group IV, the isolates of organisms were highly sensitive to Enrofloxacin in 4 cases (50%) and to Ceftriaxone in 6 cases (75%), moderately sensitive to Amoxicillin in 3 cases (50%), to Enrofloxacin in 4 cases (50%), to Ceftriaxone in 1 case (12.5%) and resistant to Amoxicillin in 5 cases (62.5%), to Ceftriaxone in 1 case (12.5%).

In group V, the isolates were highly sensitive to Enrofloxacin in 2 cases (25%) and to Ceftriaxone in 3 cases (37.5%), moderately sensitive to Amoxicillin in 2 cases (25%), to Enrofloxacin in 5 cases (62.5%), to Ceftriaxone in 4 cases (50%), and resistant to Amoxicillin in 6 cases (75%), to Enrofloxacin in 2 cases (25%).

In group VI, the isolates of organisms were highly sensitive to Amoxicillin in 4 cases (66.66%), to Enrofloxacin in 6 cases (100%) and to Ceftriaxone in 6 cases (100%). These were resistant to Amoxicillin in 2 cases (33.33%).

Singh *et al.* (2009) remarked that in veterinary field, it was not feasible to use antibiotics rationally on the basis of culture and sensitivity test. They therefore recommended commercially available systemic administration of both aerobic and anaerobic antibiotics. In the experience of many workers (Mohanty *et al.*, 2007; Sharma

*et al.*, 2007 and Patel *et al.*, 2009), third generation cephalosporins were the most effective drugs in the treatment of infections of reproductive tract in cows and buffaloes. Similar was the experience in the present study. Sharma *et al.* (2007) also noted that single isolates were susceptible to antibiotics while mixed isolates showed resistance.

The above antibiogram clearly indicates that in cases of vaginal prolapse, Ceftriaxone was the antibiotic of first choice since resistance was seen only in 1 case, while the organisms were moderately sensitive to Enrofloxacin in 16 cases and resistant in 4 cases. The organisms were resistant to Amoxicillin in 17 cases and moderately sensitive to it in 7 cases. Although Amoxicillin is widely popular in veterinary fraternity due to its availability, and its indiscriminate widespread use, might have caused this resistance.

#### **4.10 Observations on Urine Analysis**

The observations on overall and group wise urine analysis are presented in **Table 11, and Annexure-I**, respectively. The macroscopic and microscopic examination of urine samples was made before and seven days after surgery. The colour of urine varied from pale yellow to dark yellow or reddish brown, and the transparency was clear, cloudy or flocculent. The pH was mostly alkaline, except in few cases. Absence or traces of protein were detected in pre- and post-operative urine samples. Pus cells, RBCs and epithelial casts per high power field (HPF) ranged from 2-3 to 15-20 or even more in some cases. The average specific gravity before surgery was a little higher than in the healthy cattle. It was improved and reduced to near normal after the surgical treatment.

**Table 11. Findings of macro- and microscopic examinations of urine of cows with cervico-vaginal prolapse before operation and on 7<sup>th</sup> day after operation**

Groups	Stage of Sampling	Colour	Transparency	Sp. Gravity	pH	Protein	Blood	Microscopic Examination		
								Pus cells/HPF	RBCs/HPF	Epithelial casts/HPF
1. Prepubic tendon fixation	Pre-operative	Pale yellow to Dark yellow	Clear or Cloudy	1.032 to 1.044	Alkaline	Traces to ++	Absent	3-4 to 8-10	2-3 to 4-6	3-4 to 8-10
	Post-operative	Yellow	Clear or Cloudy	1.032 to 1.047	Alkaline	Traces to ++	Absent	2-3 to 12-14	1-2 to 4-5	1-2 to 8-10
2. Modified Button fixation	Pre-operative	Yellow to Dark yellow	Clear or Cloudy	1.034 to 1.048	Alkaline	Traces to +	Absent	2-3 to 15-16	2-3 to 8-10	4-5 to 10-12
	Post-operative	Yellow to Dark yellow	Clear or Cloudy	1.032 to 1.048	Alkaline	Traces to +	Absent	2-3 to 18-20	1-2 to 4-5	1-2 to 16-18
3. Amputation of prolapsed mass	Pre-operative	Dark yellow to Reddish brown	Cloudy or Flocculent	1.033 to 1.054	Acidic or Alkaline	Traces to +	Absent to ++	5-6 to 24-26	3-4 to 25-28	4-5 to 14-18
	Post-operative	Yellow to Dark yellow	Cloudy or Flocculent	1.030 to 1.050	Acidic or Alkaline	+ to ++	Absent to +	3-4 to 10-12	1-2 to 6-8	8-10 to 20-22
4. Sub-mucosal reefing	Pre-operative	Yellow to Reddish brown	Clear or Flocculent	1.035 to 1.055	Acidic or Alkaline	Traces to ++	Absent to ++	5-6 to 16-20	5-6 to 16-18	5-6 to 10-12
	Post-operative	Pale yellow to Yellow	Clear or Flocculent	1.030 to 1.050	Acidic or Alkaline	Traces to ++	Absent to +	1-2 to 6-8	1-2 to 5-6	8-10 to 18-20
5. Pan-hysterectomy	Pre-operative	Dark yellow to Reddish brown	Cloudy or Flocculent	1.033 to 1.058	Acidic or Alkaline	Traces to +++	Absent to ++	5-6 to 22-24	4-5 to 14-16	8-10 to 18-20
	Post-operative	Pale yellow to Dark yellow	Clear to Cloudy	1.032 to 1.054	Acidic or Alkaline	Traces to ++	Absent to +	2-3 to 8-10	2-3 to 6-8	4-5 to 18-20
6. Bilateral ovariectomy	Pre-operative	Pale yellow to Dark yellow	Clear to Cloudy	1.030 to 1.038	Alkaline	Traces to +	Absent	4-6 to 8-10	2-3 to 5-6	4-6 to 10-12
	Post-operative	Yellow	Clear	1.030 to 1.035	Alkaline	Traces to +	Absent	1-2 to 4-5	2-3 to 4-5	2-3 to 6-8

## **Group I**

The colour of the preoperative urine samples in group I was yellow (in 5 cows) to dark yellow (in 3 cows) and the transparency was cloudy, except in 2 cows (Nos. 1 and 3), where it was clear. The postoperative samples were yellow in all 8 cows, cloudy in 2 cows (Nos. 1 to 4) and clear in 2 cows (Nos. 5 to 8). The samples were cloudy due to presence of suspended particles, cells, and trace amount of protein, which were to a mild extent before operation because of low grade (Grade II) CVP. In 4 cows (Nos. 1 to 4), the urine remained cloudy because of improper prepubic tendon suture fixation, causing dysuria and retention of urine for some time.

Blood was absent and the pH reaction was alkaline in all pre- and post-operative samples. Proteinuria was to a trace amount (i.e. normal) in pre- and post-operative samples except in 3 cows (Nos. 2, 4 and 8). In 2 cows (Nos. 4 and 8), it reduced from '+' to trace. In 1 cow (No. 2), proteinuria remained ++, before and after operation, that could be due to vaginitis and mild glomerulitis (Benjamin, 1978).

Microscopic examination revealed that in 4 cows (Nos.1 to 4), pus cells were increased a little from preoperative range of 3-8 to postoperative range of 5-12 cells /HPF. It could be due to the improper tendon fixation and dysuria. The number of pus cells, RBCs and epithelial casts were within normal limits and were reduced to negligible from pre-operative to post-operative samples. The average specific gravity before surgery was 1.038, a little higher than in the healthy cattle (1.028) (Cynthia and Scott, 2005). It was improved and reduced to near normal, 1.031, after the surgical treatment.

Thus, the urine analysis indicated improvement in the cows after surgery and was correlating to the clinical and laboratory findings.

## **Group II**

Preoperative urine samples in Group II were dark yellow in colour and cloudy in consistency, except in 2 cows (Nos. 12 and 16), in which these were normal yellow and clear. Postoperatively the samples improved to normal yellow colour and clear in transparency, except in 3 cows (Nos. 10, 14, 15), in which the transparency remained cloudy. It may be due to the suspended particles, cells and mild proteinuria (+), which might be due to mild glomerulitis, genital infection and mild genital trauma (Benjamin, 1978).

One cow (No. 10) showed recurrence of CVP and 2 cows (No 14 and 15) suffered from, pyometra, later on. Blood was absent and pH reaction was alkaline in all pre- and post-operative samples.

Microscopic examination of pre-operative samples revealed presence of pus cells (2-8), RBCs (2-5) and epithelial casts (4-6) in normal limits which reduce to negligible in numbers /HPF post-operatively, except in 3 cows (Nos. 10, 14, 15). In these cows, post-operatively the pus cells increased up to 12-20 and epithelial casts up to 14-18 per HPF, because of the reasons mentioned above.

The average specific gravity before operation (1.040) and after operation (1.037) revealed no significant change; it was little higher than the average specific gravity (1.028) in cattle, but in normal range (**Table 11, Annexure-I**).

As such there were no significant changes in the urine analysis indicating the limited pathogenesis in the Grade II cases of CVP and less surgical trauma with the technique 2 (Button suture fixation).

### **Group III**

In Group III preoperatively the urine was dark yellow and cloudy in 5 cows (Nos. 17, 19, 20, 23, 24). Post-operatively urine colour of these cows improved to yellow but the transparency remained cloudy due to the persistent mild proteinuria and increase in the epithelial casts from 4-8 (pre-operative) to 8-14/HPF (post-operatively). The pre-operative urine was reddish brown in colour and flocculent in transparency in 3 cows (Nos. 18, 21 and 22), because of the presence of blood, moderate proteinuria (++) and pus cells (12-28), RBCs (20-234/HPF) and epithelial casts (12-18/HPF). Postoperatively, in these cows (18, 21 and 22), the redness was reduced the reddish brown colour was disappeared to dark yellow, because of reduction of blood (haematuria, haemoglobinuria), RBCs (5-8/HPF) in urine. However, the transparency remained flocculent because of the persistent moderate proteinuria (++) and increase in the number of epithelial cast (18-22/HPF), after surgery. Due to the same reasons the pH reaction of these samples (cow Nos. 18, 21 and 22) pre- and post-operatively, was acidic. The numbers of pus cells and RBCs /HPF were reduced to 6 to 12 and 5-8, respectively, because of the effect of the antibiotic and the surgical treatment (amputation of the prolapse). The presence of protein (++) , blood (++) , and more of various cells in the pre-operative samples of this Group III could be attributed to the moderately severe inflammatory changes and trauma to the genitalia, bacterial infection leading to toxæmia and alterations in the renal function and pyrexia (Benjamin, 1978 and Jain, 1986).

### **Group IV**

In group IV, preoperatively the urine was reddish brown and flocculent in cow Nos. 26, 27, 31 and 32 because of presence of protein (++) and blood (+ or ++).

Microscopic examination revealed presence of 14-20 pus cells, 10-18 RBCs, and 6-12 epithelial casts per HPF. It indicated more trauma, infection and toxemia, and inflammatory changes due to prolonged exposure and recurrent CVP (Benjamin, 1978; Jain, 1986).

Post-operatively the colour reduced to dark yellow because of reduction of blood (+), pus cells (5-8) and RBCs (3-6), per HPF in the urine. However, the transparency was flocculent due to proteinuria (++) and increased epithelial casts (10-20) per HPF. This could be attributed to submucosal resection of the large vaginal area, a regenerative process and alteration in renal function (Jain, 1986). One cow (No. 32) showed recurrence of the prolapse 25 days after surgery.

The pH reaction was acidic pre- and post-operatively, in these cows which may be due to proteinuria.

The specific gravity ranged from 1.046 to 1.054 for the 4 cows. In the remaining 4 cows (Nos. 25, 20, 29 and 30) similar changes were observed but to a lesser extent than the above 4 cows. Proteinuria was mild (+) and pH reaction was alkaline before and after surgery. The specific gravity ranged from 1.030 to 1.046.

#### **Group V**

In group V preoperatively, the urine was reddish brown in 3 cows (No. 33, 37 and 40) and dark yellow in others; while the transparency was flocculent. Mild to moderate proteinuria (+ to +++) and occult blood (+) were present in six cows and were negligible in 2 cows (No. 39 and 37). There was high number of pus cells (8-22) per HPF and epithelial casts (8 to 20 Per HPF) in the same six cows.

The pH reaction was acidic in 3 cows, in which proteinuria was present. The average specific gravity was above normal (1.037). These changes were relevant to the severe nature (Grade IV) of CVP. Cow No. 37 with  $+++$  proteinuria and haematuria (RBCs 14-16 per HPF), succumb to death few hours after surgery.

In the seven cows postoperatively, the urine became clear, proteinuria was reduced, blood was absent and cellular elements reduced to normal range. The mean specific gravity was 1.029 after operation. This indicated the restriction of pathogenesis and improvement in health because of the complete removal of genitalia.

### **Group VI**

In group VI, the urine analysis was within a normal range for the tests performed, before and after surgery. The main specific gravity before operation was 1.033 and after operation 1.028.

As such the urine analysis revealed the gross effects of severity of prolapse, inflammatory process, infection and surgical trauma on the health of animals which would be helpful to adopt the treatment measures. Sharma *et al.* (1977) performed gross and bacteriological examination of urine in a case of vaginal prolapse in a buffalo and found urinary tract infection of *Shigella spp.* They advised to carry out urine analysis to rule out urinary tract infection in cases of vaginal prolapse before institution of vigorous treatments.

#### **4.11 Histopathological Changes in the Prolapsed Genitalia**

The cases of prolapse of genitalia were studied in six groups formed on the basis of their grade and the surgical technique used to manage the prolapse.

Group I and Group II were noted to possess healthy viable tissue; hence the vagina and cervix were reset to its normal position. The tissue of the animals in these groups did not show any lesions or necrosis or degeneration except for moderate degree of oedema, which was due to inflammation and congestion which may have occurred due to outside exposure for a few days. Hence, no histopathological study was conducted on the prolapse mass of the animals in these groups.

The histopathological examination was carried out on the specimens of the surgically excised portion of prolapsed genitalia of the animals in Groups III, IV, V and VI. Severity of lesions like oedematous swelling of the prolapsed vaginal and cervical tissues differed as per the gradation of prolapse in these groups.

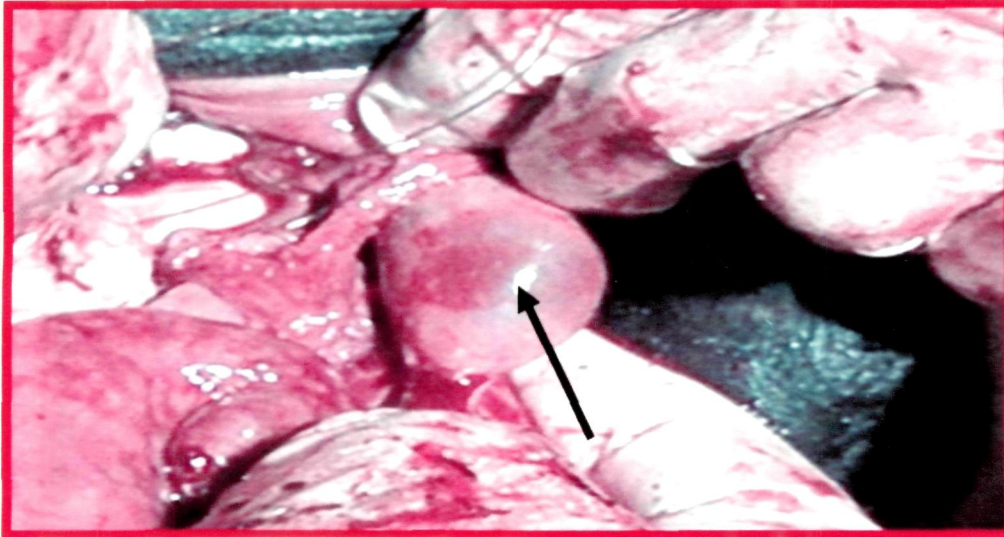
In the prolapsed genital tissues of Group III and Group IV, different lesions of degeneration and necrosis with severe oedematous swelling of the vaginal and cervical mucosa were observed. The microscopic examination revealed changes of varying severity characterised by degeneration, oedema, necrosis and fibrosis. The moderate to severe infiltration of mononuclear cells in the vaginal and cervical mucosa was found in most of the cases. In severe cases, necrosis of superficial mucosal lining with the presence of bacterial colonies was observed (**Plate 9 A, B, C**). Hyperplasia of cervical glands of vaginal and cervical mucosa was manifested during different stages of prolapse (**Plate 9 B**). Neutrophils and mononuclear cell infiltration with cystic dilation of cervical mucosal glands were noted in almost all the cases. Few specimens revealed aggregation of lymphocytes in the cervical and vaginal mucosa and muscular coats (**Plate 9 A**). Ghuman *et al.* (1998) observed prolapse in buffalo due to presence of vaginal cyst. Increase in the vaginal tissue, causing continuous irritation, may lead to the occurrence of vaginal prolapse (Agrawal and Prasad, 2001). Infections of the genito-urinary tract

with pathogenic microorganisms also serve as an important contributory factor for the genital prolapse (Agrawal and Prasad, 2001).

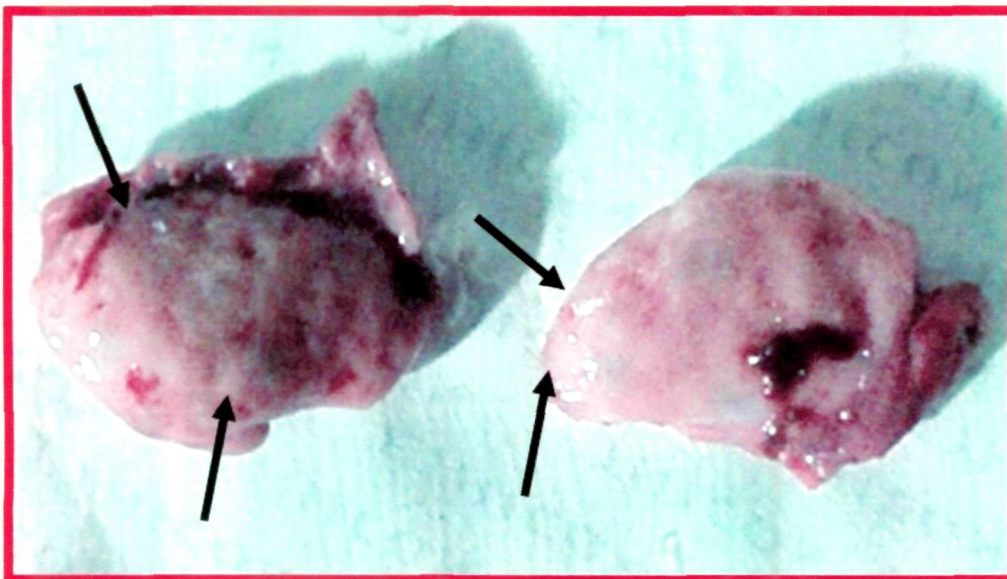
In the Group V, chronic inflammatory changes and adhesions were observed. The mucosa of vagina and cervix revealed lesions of laceration, necrosis and perivascular fibrosis (**Plate 9 A**). The infiltration of mononuclear inflammatory cells, mostly lymphocytes and plasma cells, were observed in a diffused and focal manner in the stroma and around the cervical mucus glands. Hyperplasia of uterine glands along with congestion and haemorrhage was noticed in the uterine tissue (**Plate 9 D, E**). Cystic dilation of the cervical glands was observed in chronic cases of prolapse (**Plate 9 E**). Moderate to severe perivascular fibrosis in chronic cervicitis and vaginitis plays an important role in the reduction of mucous secretion and protein synthesis. Atrophy and hyperplasia of glands can be attributed to the chronic changes that occur (Gonzalez *et al.*, 1985; Saha and Nakao, 2003).

In the Group VI, the ovarian samples showed cystic dilation with fluid filled in the cavity (**Plate 9 F**). Such ovaries were single layered fluid filled cyst (**Plate 9 G**). However, few specimens revealed multicystic ovaries which had thick, multilayered wall (**Plate 9 H**) and a cyst within the wall.

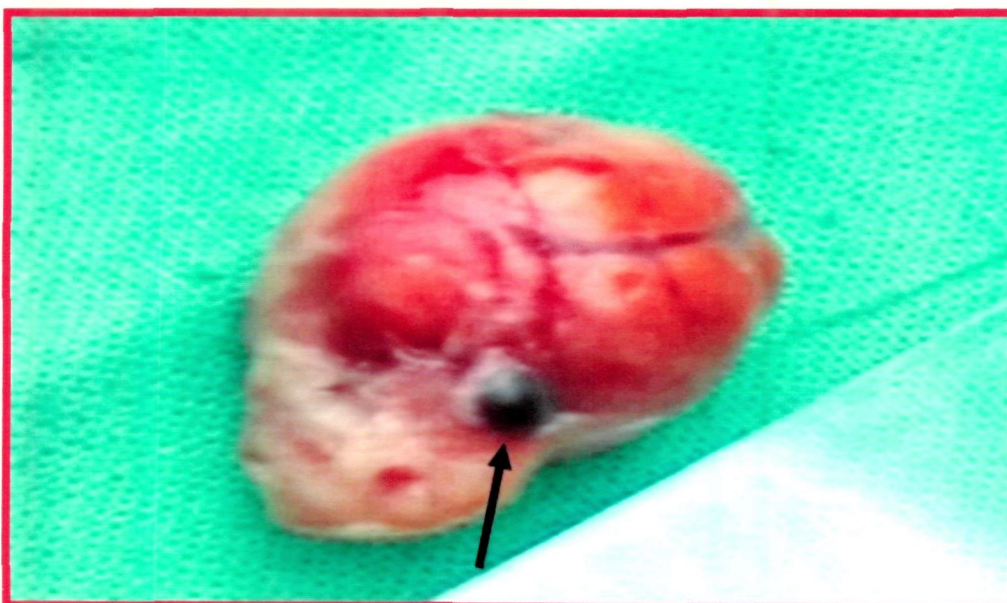
## **Plate 8: Gross changes in the ovaries of CVP**



**A) Cystic Ovary**




**B) Follicular Cysts**

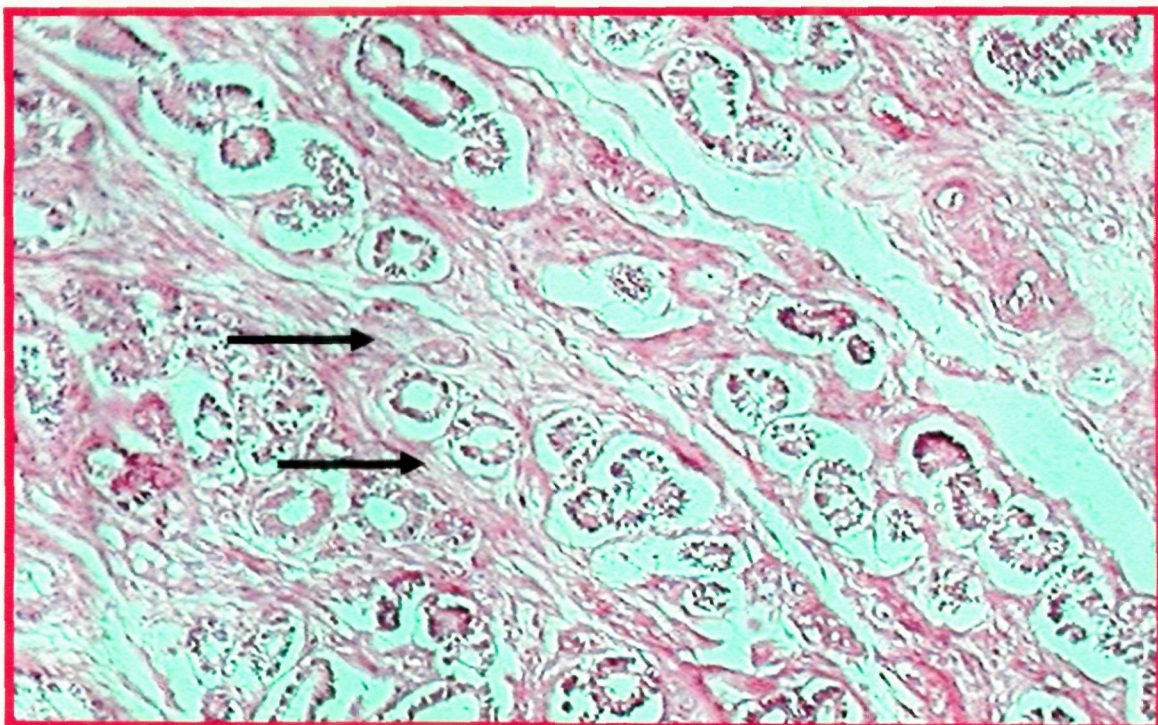


**C) Unregressed structure on ovary**

**Plate 9: Histopathological observations in the genitalia of CVP**



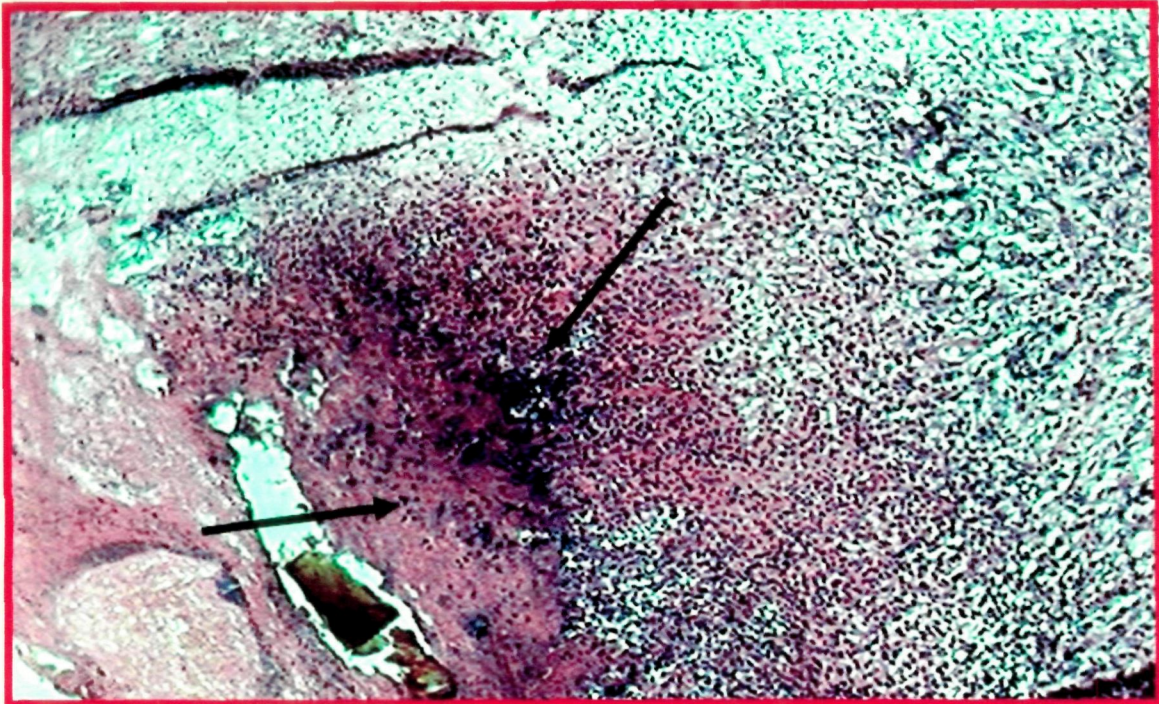
**A) Section of vagina showing extensive infiltration of neutrophils (arrow) along with degeneration and desquamation of epithelium. (H & E X 150)**



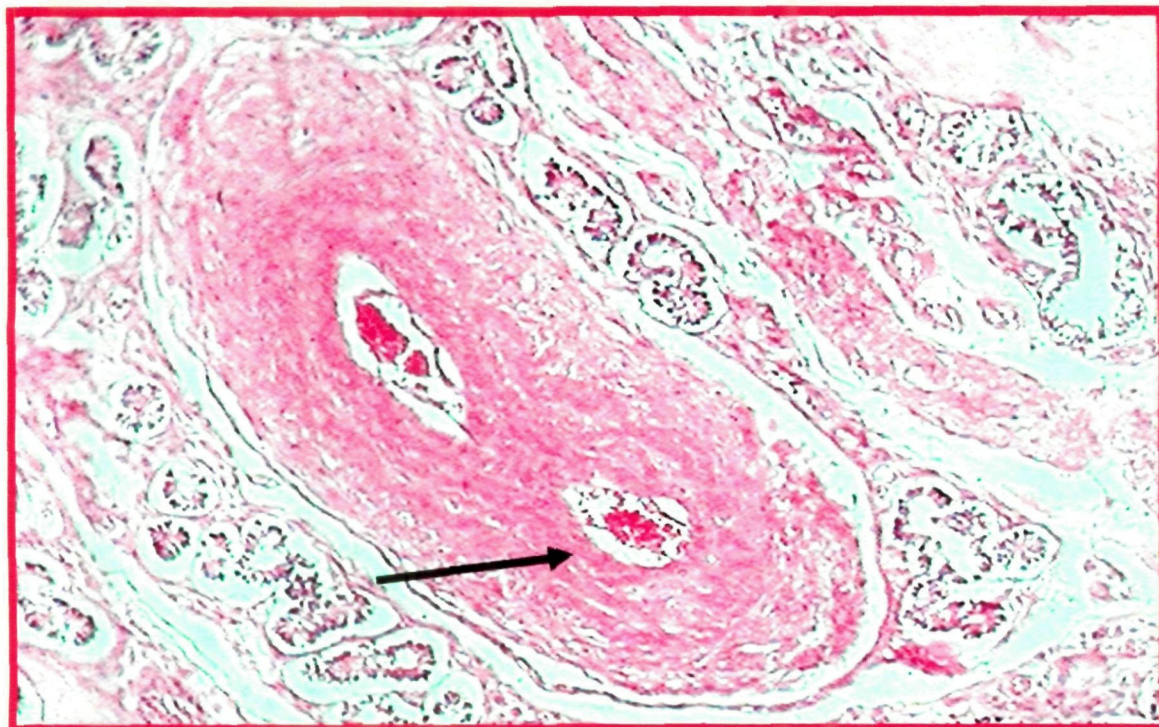
**B) Section of cervix showing congestion and hyperplasia of cervical glands. (H & E X 150)**

**Note: Perivascular fibrosis around cervical glands (arrow)**

**Plate 9: Histopathological observations in the genitalia of CVP**

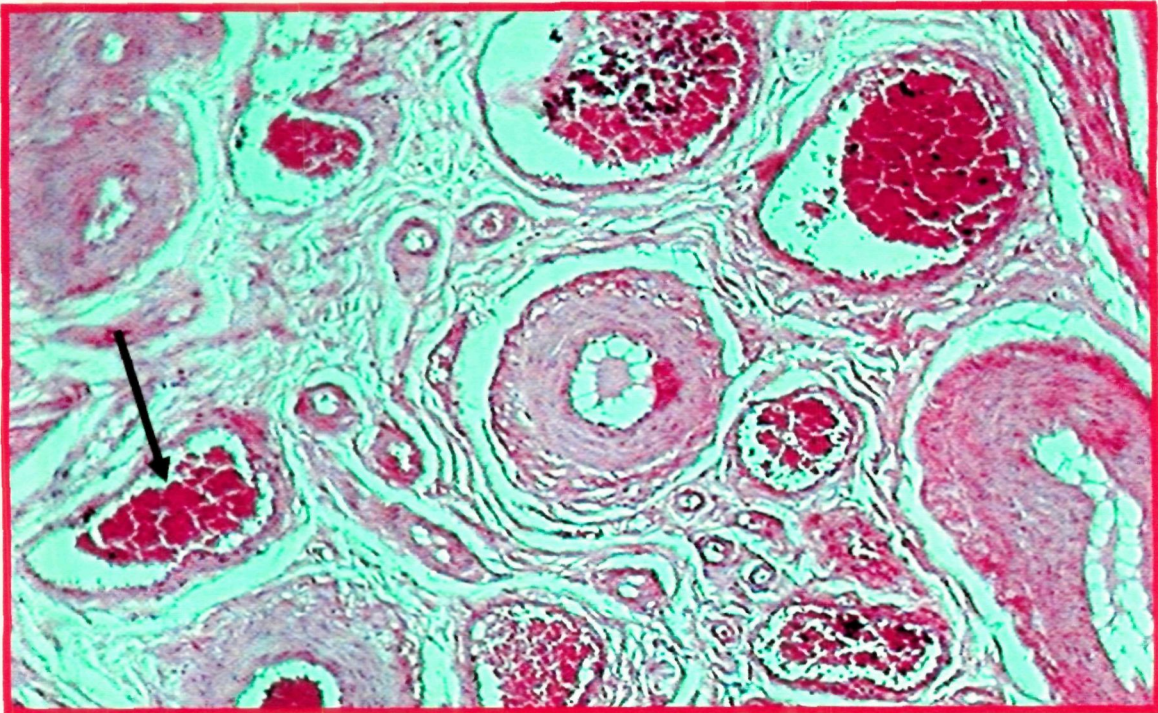


**C) Section of vagina showing marked necrosis along with haemorrhages and infiltration of neutrophils. (H & E X 150)**

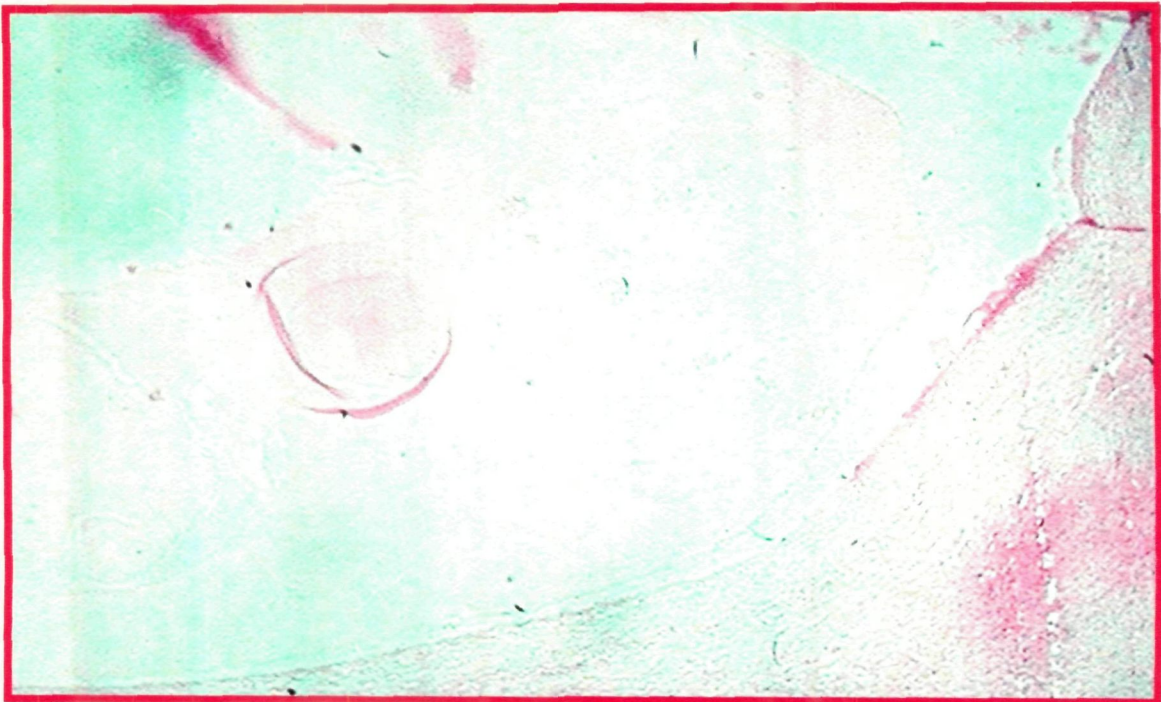


**D) Section of uterus showing engorgement of blood vessels (arrow) in the endometrium. (H & E X 150)**

**Plate 9: Histopathological observations in the genitalia of CVP**

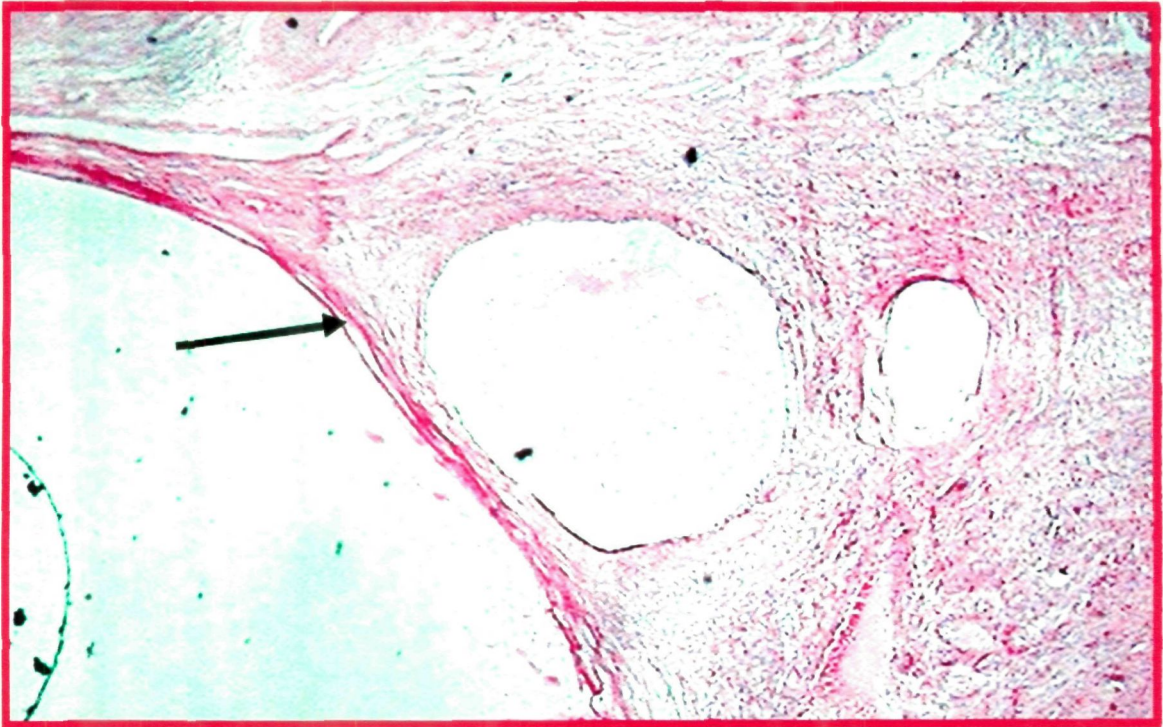


**E) Section of uterus showing marked congestion and areas of haemorrhages. (H & E X 150)**



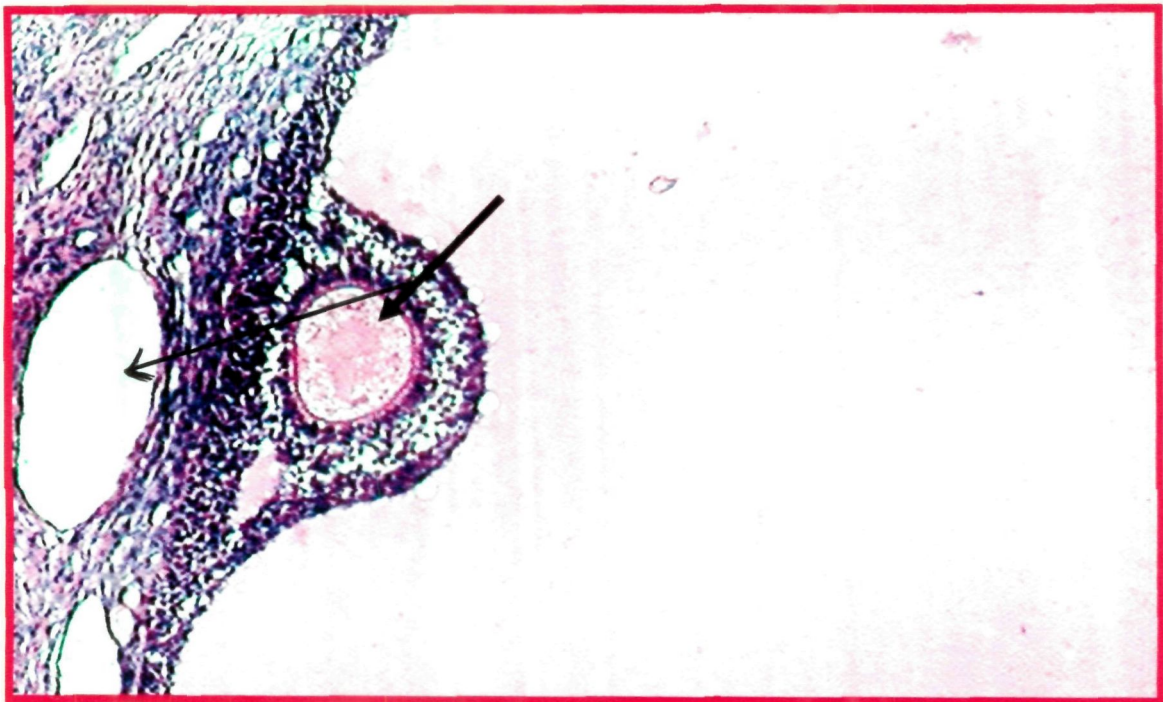
**F) Section of ovary showing formation of cyst. (H & E X 60)**  
**Note: The cavity is filled with fluid (eosinophilic mass).**

**Plate 9: Histopathological observations in the genitalia of CVP**



**G) Section of ovary showing developmental stages of follicular cyst. (H &E X 60)**

**Note: Single layer of cystic wall (arrow)**



**H) Section of ovary showing cystic dilation. (H & E X 150)**

**Note: Thickening of wall with formation of new cyst within the wall (arrow).**



*Summary and Conclusions*

## CHAPTER-V

### SUMMARY AND CONCLUSIONS

---

Cervico-vaginal prolapse (CVP) has been noted in dairy cows all over the world by many workers. The incidence has been nearby periparturient period in all those reports. None of them have mentioned cases of chronic prolapse occurring beyond three months of parturition. On the contrary, it was experienced to be occurring in high number in the Gaushalas and Panjarapoles of Gujarat. A majority of the affected cows were from Gir or Kankrej breeds and their crosses. They had suffered repeated episodes of the problem. Conventional methods of treatment were unsuccessful to address this problem. Hence the present study was undertaken to evaluate various aspects of CVP including medico-surgical management by different approaches in 46 cows of Gaushalas and Panjarapoles in Saurashtra region of Gujarat.

Based on the detailed history, and clinical evaluation, a novel method of score for each character was evolved. After assigning appropriate points for every character, the total of aggregate points for each cow was considered for grading of the case and subsequent plan of treatment. The cows that fell in the range of aggregate points between 0-25, were graded as Grade-I; between 26-50, graded as Grade-II; between 51-75, graded as Grade-III, and cows with score from 75-100, were graded as Grade-IV.

None of the cases under study fall in the Grade I category. The cases of Grade-II were subjected to surgical treatment utilizing Technique No. 1 (Fixation to prepubic tendon) or No. 2 (Button suture fixation). Cases falling under the Grade-III were treated with the use of surgical Technique No. 3 (Amputation of prolapsed mass) or No. 4

(Submucosal resection of vagina). In cases of Grade-III, the cows that had irreducible adhesions of the prolapsed mass or abnormalities of os cervix in the form of kink, hard, fibrosed, or extensive enlarged cervix were subjected to Technique No. 3 (Amputation of prolapsed mass). Cases of Grade-III that did not have above changes in prolapsed mass were subjected to Technique No. 4 (Submucosal resection of vagina). The cases of Grade-IV were put to treatment by Technique No. 5 pervaginum (Pervaginum Panhysterectomy), and those cows which showed ovarian abnormalities were subjected to Technique No. 6 per vaginum (Pervaginum bilateral ovariectomy). After supportive therapy, anaesthesia was performed in the form of caudal epidural analgesia and pudendal nerve block. Appropriate surgical treatment was applied to each cow.

In technique 1, i.e. fixation to prepubic tendon it was necessary to thread a 75 cm long suture material to the needle, keeping it traceable for further tying of knot beyond the vulvar commissure. Insertion of the prepared needle was performed carefully by protecting it in the palm of right hand to avoid unwanted injury to the pelvic structures. This insertion in the prepubic tendon required lot of skill to retrieve back between the main and lateral branch and bands of the prepubic tendon. Several attempts were required to push the needle back in the vaginal floor, while sometimes it was necessary to press the vaginal floor with the help of long vulselum forceps on the inserted needle.

Although this technique appeared very promising, the experience during the study indicated that the entire procedure has to be performed blindly only by palpation in the cul-de-sac of vagina. In view of a limited bite in the vaginal floor and the prepubic tendon, the chances of rupture of the suture or the tearing of the vaginal wall could not be overlooked. It was also experienced that the bite on the right side was more difficult than the left side for the right handed worker.

Considering the difficulties encountered in the fixation of vagina to the prepubic tendon, and need of avoiding the bites in the surrounding organs, like urethra, urinary bladder and rectum, this technique is recommended only in the hands of an experienced worker.

Technique No. 2 (Button Suture Fixation) was used on 8 cows. Commercially available suture needle (triangular and straight needle No.1) worked satisfactorily to put these sutures. Since the vaginal insertion of the suture was preplaced on the prolapsed mass, there was adequate visibility and a very little haemorrhage occurred in the placement of the suture.

Amputation of prolapsed mass was easy in this technique as the entire mass was presented at the vulva for handling. However, due to the large size and irreparable changes in the vagina and the cervix, the wall of the organ was considerably thick making it difficult to cut. Because of the inflammation and oedema, the tissues also included large number of blood vessels, which bled spontaneously upon cutting and necessitated immediate control by multiple ligatures. There was a considerable blood loss obscuring the surgical site. Large number of sutures along the entire margin needed to be placed to hold the cut edges together.

Submucosal resection of vagina was fairly simple, as technique 3. As the surgical dissection was restricted only to the submucosa of the exposed portion, haemorrhage from the dissection was comparatively less than in the technique 3. The haemorrhage occurring in the form of oozing or mild haemorrhage was easily controlled. Since the technique did not involve extensive dissection or ligation of blood vessels, the procedure could be completed in comparatively lesser time.

In cases of pervaginum panhysterectomy, the dorsal wall of the vagina bled considerably. Further dissection for the uterine junction and ovarian stumps had to be done blindly by palpation with fingers. When the ovary was grasped, the animal exhibited a sign of discomfort. Five ml of local anaesthetic infused locally helped in relaxation of ovarian ligament and reduction of pain. It was felt necessary to put two ligatures on the stump to ensure complete obliteration of the ovarian blood vessels. After having completed this procedure, small length of vagina was left behind so that there was no chance of recurrence of prolapse.

Pervaginum bilateral ovariectomy was performed in the similar manner as in technique 5. The uterus and cervix were left intact. For performing the ovariectomy, a specially designed Richards' ovariometer was used to crush the ovarian blood vessels and the pedicle. The instrument worked on the principle of an emasculator crushing the ligament and its blood vessels and cutting beyond the crush surface. This eliminated use of any suture and offered satisfactory arrest of haemorrhage. The entire procedure of ovariectomy on both the sides was completed in 10 to 15 minutes. Suturing of the vaginal incision (colpotomy) posed no major problem and the entire surgery could be completed in 20 to 30 minutes. There was considerably less haemorrhage than the other techniques.

In Group I and II recurrence of prolapse was noted in one cow each due to rupture of sutures. In one more case of group II, pyometra was noted due to foreign body i.e. buttons. In Group III, all the animals showed mild to moderate bleeding from vagina and mild straining. This was treated by local infusion of Betadine solution and application of Ceftriaxone powder. This bleeding disappeared towards 7-8 days and effectively stopped at 10 days. One cow showed recurrence of prolapse. In Group IV,

minor haemorrhage through vagina was noted in all the cases for 1 or 2 post-operative days. All the animals recovered uneventfully, except one cow that suffered prolapse at 24<sup>th</sup> post-operative day. In Group V, all the animals, except one cow, showed slight haemorrhage for a period of 3 to 4 days followed by slight mucous discharge for next 3 to 4 days, but recovered uneventfully by 15 days.

Technique 1 and 2 (Prepubic tendon fixation and Button suture fixation) were performed in those cows where the prolapse was mild to moderate type (Grade II) with no complications like oedema, necrosis, gangrene and other secondary complications like infestation with maggots. As such these two techniques were useful in conserving the genitalia; the clinical condition was addressed by one of the two techniques mentioned above.

Two cows treated with technique 2 conceived subsequently. Thus, these animals would have become useful for reproduction in future. When these two techniques were compared between each other, it was experienced that technique 1 was more demanding and could end in failure as exhibited by signs of dysuria, and the deviation of urinary tract, that had to be subsequently treated to correct the problem in 2 cows, whereas technique 2 was comparatively easy to perform and more successful.

Whenever there were marked changes in the prolapsed mass in the form of severe oedema, adhesions and necrosis (gangrene) falling in Grade III prolapse, these cases were assigned to techniques 3 or 4 as already recommended by other workers.

The prolapsed mass was difficult to relocate in its natural disposition because of changes in the size and shape, in view to relieve the agony of the animal; it was thought least important whether these cows would breed in future. Therefore, they were treated with either submucosal resection or amputation of the prolapsed mass, as in both the

techniques the primary problem of discomfort of the animal was eliminated. When the two techniques (3 and 4) were compared between them, submucosal resection was comparatively easier to perform and resulted into less serious haemorrhage. Cows treated by the technique 4 also showed complete recovery, except in one cow. It can be concluded that this was the satisfactory method of surgical treatment for cases of prolapse in Grade III. A slight distinction can be made in the decision for selecting between the two techniques, was that, when considerable adhesions were present in the prolapsed mass, technique 3 (amputation of prolapsed mass) must be preferred over the technique 4 (Submucosal resection).

In those cases, where the changes in the prolapsed organ appeared irreversible, it was decided to remove entire reproductive tract per vaginum (Panhysterectomy, technique 5). This surgical technique also was quite demanding owing to large number of engorged blood vessels in the dissection. After complete removal of the organ, closure of the vaginal incision was difficult because of loss of considerable vaginal tissues.

Technique 6 (Pervaginum bilateral ovariectomy) was reserved for those cases where ovarian changes were marked. There were cystic ovaries, i.e. multiple follicular cysts or luteal cysts, leading to chronicity of the prolapse. It was postulated that the prolapse was primarily due to ovarian dysfunction. This was proved when the ovariectomy was performed and the prolapse was repositioned. No recurrence was noted in any of the six cases until eight days.

The improvement in haematological profile post-operatively was suggestive of recouplement of the body status. However, serum biochemical and endocrinological status were conclusive to evaluate the etiopathology, stress and complexity of the syndrome pre-operatively, and the therapeutic resolution of the malady post-operatively.

Various micro-organisms were isolated from the vaginal swabs from these cows. Antibiotic sensitivity test indicated that Ceftriaxone and Enrofloxacin were both effective against these organisms while Amoxirum was not as effective.

Urinalysis did give valuable information with regards to pre and post operative changes and can be used as one indicator to assess pre-operative status and effect of surgical treatment.

It may be **concluded** from the present study as under.


1. High incidence of CVP in Gir and Kankrej was mainly due to the rich population of these breeds in the Saurashtra region of Gujarat. So, also, these breeds were more susceptible for CVP.
2. It is presumed that chronic irritation persisting out of infection from retained placental membranes and handling lead to subclinical inflammation and prolapse. It was also observed that the affected animals had been bred indiscriminately before suffering from prolapse, and were subjected to very unhygienic services from unknown bulls, and handling by untrained health workers.
3. Specific points assigned to each character and changes occurring in the animal helped to develop a score card after complete assessment of the cow. It was felt that this scoring system would benefit in planning of treatment regimen and successful outcome in each case.
4. Although the technique 1 appeared very promising, experience during the study indicated that the entire procedure has to be performed blindly only by palpation in the cul-de-sac of vagina. In view of a limited bite in the vaginal floor and the prepubic tendon, the chances of rupture of the suture or the tearing of the vaginal

wall could not be overlooked. It was also experienced that the bite on the right side was more difficult than the left side for the right handed worker.

5. Since the vaginal insertion of the suture was preplaced on the prolapsed mass, there was adequate visibility ~~with~~ very little haemorrhage occurred in the placement of the suture in technique 2.
6. Amputation of the everted mass could be adopted as a last resort in those cases in which the uterus had undergone such severe changes that replacement of the organ would inevitably result in death. In occasional long standing cases, it was found physically impossible to replace the mass because of the unfavourable texture of the organ. The prognosis was grave, and it was doubtful on welfare grounds.
7. The improved haematological profile postoperatively in the affected groups could be due to the recoument of body condition by six days of surgery, supported by haematinics administration and elimination of stress. Comparative low preoperative values (in prolapsed animals) may be due to the release of ADH as a result of stress and may be due to anorexia and toxemia.
8. Highly significant increase neutrophils in Groups I and II might be due to profound inflammatory response of bone marrow (with pumping of storage pool of neutrophils in blood) to the comparatively recent CVP. The non-significant increase (or less response of WBC) in Groups III and IV could be due to depletion of circulating pool of neutrophils and less production from bone marrow, because of the longer duration and severe inflammatory condition of prolapse. In Group V, the TLC reduced significantly, which could be because of the above, and continuing loss of neutrophils from tissues in the chronic inflammatory condition of Grade IV CVP. In Group VI, the inflammation and infection was mild (Grade II prolapse,

with ovarian disorder), so there was no increase in TLC, rather a decrease was there, which could be due to loss of neutrophils from the tissues.

9. The condition of neutrophilia, lymphocytopenia and monocytopenia in the affected groups as compared to the control group may be due to increased levels of cortisol hormone due to stress or inflammatory process involved in genital prolapse and also due to stress of surgery on the animals. Neutrophilia may also be due to excitement and adrenaline release.
10. The low levels of serum calcium observed in all the groups as compared to the control group, is one of the main causes for prolapse. Decreased calcium levels lead to atony of the uterus and a delay in cervical involution, both of which could predispose to uterine prolapse in dairy cows. Post-operative (after 6 days of surgery) increase in Ca levels to near control group values, indicate the recoument of the general health of the animal.
11. The higher pre-operative values of AST and ALT as compared to the control group value may be due to degeneration of hepatocytes and also the muscular coat of the gravid uterus leading to the leakage of the enzyme into the blood. The higher pre-operative ALT may be due to hepatocellular damage, due to toxemia resulting from longstanding prolapse condition. Thus, the estimation of AST values could be a valuable aid for the determination of uterine tissue destruction.
12. The role of hormones in the chronic CVP could not be evaluated for limited number of animals in each group under study. Cortisol is the major stress hormone in ruminants and causes immune-suppression, hypocalcaemia and loss of muscular contractions.



13. Histopathological studies of genital tissue on surgical removal in Group I and II , did not show significant lesions while Group III, IV and V cases revealed, variable degrees of inflammatory lesions, characterized by degeneration, edema necrosis and fibrosis.
14. Moderate to severe infiltration of mononuclear cells in the vaginal and cervical mucosa were found in groups III and IV. Group V indicated necrosis of superficial mucosal lining with the presence of bacterial colonies. Hyperplasia of glands of vaginal and cervical mucosa showed neutrophils and mononuclear cells infiltration with cystic dilatation. The group V cases revealed chronic inflammatory changes of adhesions, lacerations, necrosis and perivascular fibrosis, hyperplasia of uterine glands along with congestion and haemorrhage.
15. The group VI cases, (with abnormalities of ovaries) revealed cystic dilation with fluid filled cavity, with single layered cysts. Few specimens revealed multicystic ovaries which had thick, multilayered wall and cyst within the wall.
16. The histological signs correlated with the clinical signs and helped in prognosis of repair and cure of the case.



*References*

## REFERENCES

- Agarwal, P. and Prasad, S. (2001). Managing cervico-vaginal prolapse in cattle and buffaloes – A review. *Indian Vet. Med. J.*, **25**: 313-316.
- Agarwal, R.G. (1987). *Some studies on uterine torsion with reference to its aetiology and treatment in buffalos*. Ph.D. Dissertation, Punjab Agril. Univ., Ludhiana, India.
- Ahmed, S., Ahmad, I., Lodhi, L.A., Ahmad, N. and Samad, H.A. (2005). Clinical, haematological and serum macro mineral contents in buffaloes with genital prolapse. *Pakistan Vet. J.*, **25** (4): 167-170.
- ✓ Ali, Amjad (2008). Studies on calving related disorders (dystocia, uterine prolapse and retention of fetal membranes) of the river buffaloes (*Bubalus bubalis*) in different agro-ecological zones of Punjab province, Pakistan. Ph.D. Thesis, Agri Univ., Faisalabad, Pakistan.
- Arthur, G.H., Noakes, D.E., Parkinson, T.J. and England, G.C.W. (2001). *Veterinary Reproduction and Obstetrics*. 8<sup>th</sup> edn, W.B. Saunders Co. Ltd., London.
- Azawi, O.I., Omran, S.N. and Hadad, J.J. (2007). Clinical, bacteriological and histopathological study of toxic puerperal metritis in buffalo. *J. Dairy Sci.*, **90**: 4654-4660.
- ✓ Bauer, A., Kirby, W., Sherris, J. and Turck, M. (1966). Antibiotic susceptibility testing. *Am. J. Clinical Path.*, **45**: 493.
- ✓ Benesch, F. (1930). Die graphische darstellung der normalen der medikamentell verstärkten und der abgeschwachten uterusbewegung an lebenden rind im involutionsstadium. *Proc. 11<sup>th</sup> International Vet. Congr.*, p. 351.


- Benjamin, M.M. (1978). *Outline of Veterinary Clinical Pathology*. 2<sup>nd</sup> ed., The Iowa State Univ. Press, Iowa, USA.
- Bhattacharyya, H.K., Fazili, M.R. and Buchoo, B.A. (2007). Management of uterine prolapse in cattle of Kashmir valley. *Proc. XXIII Annial Convention of ISSAR and National Symposium*, OUAT, Bhubaneshwar, India, Dec 7-9.
- Bouckaert, J.H., Oyaert, W., Wijverkens, H. and Meirhanghe, E. (1956). Prolapse of vagina in cow. *Vlaams Diergeneesk. Tijdschr*, **25**: 119.
- Brar, R.S., Sandhu, H.S. and Singh, A. (2002). *Veterinary Clinical Diagnosis by Laboratory Methods*. 2<sup>nd</sup> edn., Kayani Publishers, New Delhi, India.
- Chavan, R.S. and Agrawal, D.K. (2006). *Textbook of Veterinary Clinical and Laboratory Diagnosis*. J.P. Brothers, Lucknow, India.
- Cruickshank, R. (1965). *Medical Microbiology*. 11<sup>th</sup> edn. The English Language Book Soc. and E & S Livingstone Ltd., Great Britain.
- Cynthia, M.K. and Scott, L. (2005). Reproductive System. In: *The Merck Veterinary Manual*. 9<sup>th</sup> edn., Merck & Co., Inc. White House Station, New Jersey, USA, pp. 1148-1150.
- Dadarwal, D., Ghuman, S.P.S., Singh, J., Honparkhe, M., Dhaliwal, G.S. and Mehra, M.L. (2009). Blood metabolites with differential fertility under uniform feeding. *Indian J. Anim. Reprod.* **30**(2): 68-70.
- Dugwekar Y.G., Sarvaiya N.P., Patel M.D., Tajane K.R. and Shah R.R. (2008). Serum progesterone and estradiol levels in Jafrabadi buffaloes. *Indian J. Anim.. Reprod.*, **29** (2): 177-180.

- Farquharson, J. (1949). Vaginal prolapse in the bovine. *Proc. 14<sup>th</sup> Int. Vet. Congr.*, London, England, **3**: 264.
- Fiske, C.H. and Subbarow, Y. (1925). The colorimetric determination of phosphorus. *J. Biol. Chem.*, **66**: 375.
- Fubini, S.L. and Ducharme, N.G. (2004). *Farm Animal Surgery*. Saunders, an Imprint of Elsevier, USA
- Garndner, I.A., Reynolds, J.P., Risco, C.A. and Hird, D.W. (1990). Pattern of uterine prolapse in dairy cows and prognosis after treatment. *J. Am. Vet. Med. Assoc.*, **197**(8): 1021-1024.
- Ghosh, B.B., Singh, B. Ray, S.K. and Nandi, P.R. (2007). Studies on microbial isolation from different parts of genitalia of infertile cows along with antibiogram for drug sensitivity. *Proc. XXIII Annial Convention of ISSAR and National Symposium*, OUAT, Bhubaneshwar, India, Dec 7-9.
- Ghosh, R.K. (2006). *Primary Veterinary Anatomy*. 4<sup>th</sup> Edn., Current Book International, Mumbai, India.
- Ghuman, S.P.S., Nanda, A.S., Prabhakar, S., Gandotra, V.K. and Honparkhe, M. (2008). Recurrent vaginal prolapse in a crossbred cow due to cystic Gartner's duct. *Indian J. Anim. Reprod.*, **29**(2): 219.
- Gibbons, W.J. (1962). *Modern Vet. Pract.*, **43**: 82.
- Goff, J.P., Kehrli, M.E.Jr. and Horst, R.L. (1990). The pathology and prevention of cows. *J. Dairy Sci.*, **73**: 1182.


- Gonzalez, H.E., Crowell, W.A., Caudal, A.B. and Thompson, F.N. (1985). Morphometric studies of the bovine uterus: microscopic lesions and retrospective reproductive history. *Am. J. Vet. Res.*, **46**(12): 2588-2595.
- Gustafsson, H., Kornmatitsuk, B., Konigsson, K. and Kindahl, H. (2004). Peripartum and early postpartum in the cow – physiology and pathology. *23<sup>rd</sup> World Buiatrics Congress, Quebec City, Canada, July 11-16.*
- Hafez, B. and Hafez, E.S.E. (2010). *Reproduction in Farm Animals*. 7<sup>th</sup> Edn. Blackwell Publ., Iowa, USA.
- Hogg, A. (1960). *Modern Vet. Pract.*, **41**: 57 (Cited from Misra and Angelo, 1981).
- Hudson, R.S. (1986). Genital surgery in cows. In: *Current Therapy in Theriogenology*, Ed. D.A. Morrow, W.B. Saunders Co., Philadelphia.
- Ishii, M., Aoki, T., Yamakawa, K., Uyama, T., EL-Khodery, S., Matsui, M. and Miyake, Y. (2010). Uterine prolapse in cows: effect of raising rear end on the clinical outcomes and reproductive performance. *Veterinarni Medicina*, **55**(3): 113-118.
- Jain, N.C. (1986). *Schalm's Veterinary Haematology*. Lea and Febiger, Philadelphia, USA.
- Jana, D. and Ghosh, M. (2009). Postpartum uterine prolapse in indigenous pluriparous cow and its therapeutic management. *Intas Polyvet*, **10** (1): 20-21.
- Jubb, T. F., Malmø, J., Brightling, P., and Devis, J.M. (1990). Survival and fertility after uterine prolapse in dairy cows. *Australian Vet. J.*, **67**(1):22-24.
- Kaneko, J.J. (1990). In: *Clinical Biochemistry of Domestic Animals*. 3<sup>rd</sup> Edn., Academic Press Inc, London, UK.

- Khatri, C.K., Khar, S.K., Singh, J. and Luthra, R.A. (1986). Changes in biochemical blood constituents of buffaloes with uterine torsion and the effect of cesarean section and certain postoperative therapeutic measures. *Arch. Exp. Vet. Med., Leipzig*, **40**(3): 461-468.
- Kinney, J.M. (1967). The effect of injury on metabolism. *Br. J. Surg.*, **54**: 435-437.
- Kochhar, H.P.S., Prabhakar, S., Ghuman, S.P.S. and Nanda, A.S. (1996). Recurrent prolapse due to vaginal lipoma and its management in a buffalo. *Indian J. Anim. Reprod.*, **17**(1): 69-70.
- Koren, J.S. and Smith, H.C. (1945). An unusual case of genital involvement in swine associated with eating moldy corn. *Vet. Med.*, **40**(4): 131.
- Kubasic, N.P., Hallauer, G.D. and Brodows, R.G. (1984). Evaluation of direct solid-phase RIA for progesterone, useful for monitoring luteal function. *Clinical Chemistry*, **30** (2): 284-286.
- Kumar Rajesh, Butani, M.G., Dhani, A.J., Kavani, F.S., Patel, M.D. and Shah, R.G. (2009<sup>a</sup>). Progesterone, Metabolites and minerals in anestrus, subestrus, repeat breeding and cyclic cows. *Indian J. Anim. Reprod.*, **30**(2): 19-22.
- Kumar Suresh, R., Verma, H.K., Umapathi, L., Gandotra, V.K. and Kasrija, R. (2009<sup>b</sup>). Plasma estradiol concentrations during prepartum vaginal prolapse in buffaloes. *Indian J. Anim. Sci.*, **79**(10): 1001-1003.
- Luna, L.G. (1960). *Manual of Histologic Staining Methods of the Armed Forces' Institute of Pathology*. 3<sup>rd</sup> ed. Mc Graw Hill Book Co., New York, Toronto, London and Sydney.

- Malik, J.S., Verma, S.K. and Sharma, D.N. (1990). Histopathological studies on uterine torsion in buffaloes. *Indian Vet. J.*, **67** (7): 603-606.
- Mane, P.M., Dhoble, R.L., Chaudhari, R.J., Dawane, S.C. and Kolpe, A.B. (2009). Bacterial spectrum, antibiotic sensitivity pattern of bacterial isolates and conception rate in repeat breeders. *Intas Polivet*. **10** (1): 32-35.
- Matsas, D.J. (1993). Use of an on-farm progesterone test in the clinical management of parturient disorders in three cows. *J. Am. Vet. Med. Assoc.*, **202**: 610-612.
- Maxwell, M.H. and Kleeman, C.R. (1972). *Clinical Disorders of Fluid and Electrolyte Metabolism*. 2<sup>nd</sup> Edn, McGraw Hill Book Co., New York, USA.
- McErlean, B.A. (1952). Vulvovaginitis of swine. *Vet. Rec.* **64**(37): 539.
- McFarlane, L.S. (1963). *J. South African Vet. Med. Assoc.*, **34**: 73.
- Minchev, Peter (1956). The use of a new surgical method in eversion and prolapse of vagina in animals. *Veterinariya*, **33**:58-60 (Abstr in JAVMA 130: 1344).
- Mishra, U.K., Agrawal, R.G. and Pandit, R.K. (1998). Incidence of prolapse of genitalia in Murrah buffaloes in relation to season, pregnancy, parity and management. *Indian Vet. J.*, **75**(1): 254-255.
- Misra, S.S. (1998). Surgical and medicinal management of recurrent uterovaginal prolapse in the bovine, *Intas Polivet*, **1**(1): 51-54.
- Misra S.S. and Angelo, S.J. (1981): Vaginopexy technique for the management of recurrent utero-vaginal prolapse in bovine. *Indian Vet. J.*, **58**(7): 576-580.



- Mohanty, L.D., Mishra, B. and Mishra, P.C. (2007). Post-AI intrauterine administration of ceftriaxone sodium and its effect on conception rate in repeat breeding HF dairy herd. *Proc. XXIII Annual Convention of ISSAR and National Symposium*, OUAT, Bhubaneswar, India, Dec 7-9.
- Mohy, A.D.M., Elerz, A., Zahraa, M. and Hassan, A. (1985). Variations in haematological characteristics of crossbred goats during pregnancy, lactation and dry season. *World Rev. Anim. Prod.*, **21**: 39-43.
- Mudasir, Q., Shukla, S.P. and Nema, S.P. (2009). Haemato-biochemical changes during parturition cervicovaginal prolapse in a she buffalo. *Buffalo Bulletin*, **28** (3):148-150.
- Murray, R.K. Mayez, P.A., Granner, D.K. and Rodwell, V.W. (1982). *Harpar's Biochemistry*. 22<sup>nd</sup> edn., Prentice Hall, International Co., Inc. USA.
- Odegaard, S.A. (1977). Uterine prolapse in dairy cows. *Acta Vet. Scand. (Suppl)*, **63**: 1-124.
- Pandit, R.K., Gupta, S.K and Pattabiran, S.R. (1982). Utero-vaginal prolapse in relation to serum calcium, inorganic phosphorus, magnesium and alkaline phosphatase in buffaloes. *Indian Vet. J.*, **59**: 854-858.
- Patel, P.P., Panchal, M.T., Kalyani, I.H. and Kavani, F.S. (2009). Antibiotic sensitivity spectrum of bacterial isolates from cervico vaginal mucus of postpartum rural buffaloes. *Intas Polivet*, **10** (1): 29-31.



Pathak, M.M. and Janakiraman, K. (1987). Blood serum calcium, inorganic phosphorus and magnesium at different stages of pregnancy in Surti buffaloes. *Indian J. Anim. Sci.* **57**: 398-402.

Pathak, R., Singh, P. and Singh, S.K. (2009). Unusual chronic uterine prolapse treated by partial hysterectomy. *Intas Polivet*, **10**(1): 24.

Patil, A.D., Markandeya, N.M. and Bhonsle, A.V. (2007). Studies on treatment of infectious repeat breeder animals with intrauterine levofloxacin and alphatocopherol administration. *Proc. XXIII Annual Convention of ISSAR and National Symposium*, OUAT, Bhubaneswar, India, Dec 7-9.

Pattabiraman, S.R. and Pandit, R.K. (1980). Studies on haematological and biochemical constituents in blood of buffaloes with uterine torsion. *Cheiron*, **9**: 338-340.

Patterson *et al.* (1979). Cited from Richardson, G.F., Klemmer, A.D. and Knudsen, D.B. (1981). Observations on uterine prolapse in beef cattle. *Canadian Vet. J.*, **22** (6): 189-191.

Paul, S.S., Chawala, D.S. and Lall, D. (2000). Serum mineral profile and its relationship with reproductive disorders in Nili Ravi buffaloes. *Indian J. Anim. Nutr.* **17** (4):324-327.

Pierson, R.E. (1961). A review of surgical procedures for correction of vaginal prolapses in cattle. *JAVMA*, **139**(3): 352.

Potter, (2008). Prolapse of the uterus in the cow. *UK Vet. J.* **13**: 1-3.

Powell, J. (2007). Reproductive prolapses of cattle. *Livestock Health Series*, University of Arkansas, pp.1-2.

- Prasad, S. and Agrawal, P. (2000). Postpartum cervico-vaginal prolapse due to cystic ovarian degeneration in a cow. *Indian Vet. J.*, **77**(12): 1099-1100.
- Rai, C.S. and Prabhakar, S. (2000). *Indian Vet. J.*, **77**: 247-249.
- Renault, T. (1980). Etiology of vaginal prolapse in cows and ewes with reference to phosphorus deficiency in the upper torrentaire region of the France Alps. *Vet. Bull.* **55** : 67-73.
- Richardson, G.F., Klemmer, A.D. and Knudsen, D.B. (1981). Observations on uterine prolapse in beef cattle. *Canadian Vet. J.*, **22** (6): 189-191.
- Risco Carlos, A., Reynolds James, P. and Hird David (1984). Uterine prolapse and hypocalcemia in dairy cows. *J. Am. Vet. Med. Assoc.*, **185**(12): 1517-1519.
- Risco Carlos, A., Youngquist, R.S. and Down Shore, M. (1997). *Current Therapy in Large Animal Theriogenology. 1<sup>st</sup> edn.*, W.B. Saunders Co., Missouri, US, p. 434-467.
- Roberts, S.J. (1949). Amputation of prolapsed uterus. *Cornell vet.*, **39**: 434.
- Roberts, S.J. (1971). *Veterinary Obstetrics and Genital Diseases. 2<sup>nd</sup> ed.*, CBS Publishers and Distributors, New Delhi, India.
- Roine, K. And Soloniemi, H. (1978). Incidence of some diseases in connection with parturition in dairy cows. *Acta Vet. Scandinavia*, **19**: 341-353.
- Saha, S.K. and Nakao, T. (2003). Some characters of vaginal prolapse in Nepali buffaloes. *J. Vet. Med. Sci.*, **65**(11): 1213-1215.
- Sastry, G.A. (1989). *Veterinary Clinical Pathology. 3<sup>rd</sup> edn.* CBS Publishers and Distributors, Delhi, India.

- Sharma, A., Luthra, R.A., Munjal, V.K., Sindhu, N. and Jagra, P. (2007). *In vitro* antimicrobial sensitivity of different organisms isolated from uterine infection in cows and buffaloes. *Proc. XXIII Annual Convention of ISSAR and National Symposium*, OUAT, Bhubaneshwar, India, Dec 7-9.
- Sharma, R.D., Singh J.F., Ramakumar, V. and Prasad, V. (1977). Threatened vaginal prolapse due to urinary infection in a buffaloes. *Indian Vet. J.*, **54**: 758-759.
- Shukla, K.C. (1972). *Vyavaharoo Gopalan*. 1<sup>st</sup> Edn (Gujarati), University Granth Nirman Board, Gujarat State, Ahmedabad.
- Siddiquee, G.M., Bhatol, J.G. and Latif, A. (2006). Estradiol and progesterone concentrations in prepartum and postpartum vaginal prolapse in buffaloes (*Bubalus bubalis*). *Indian J. Field Vets.*, **2**(2): 1-3.
- Sindhu, S.S. (1975). *Clinico-laboratory studies in normal and abnormal conditions associated with prepartum period in buffaloes*. MVSc Thesis, Punjab Agril. Univ., Ludhiana, India.
- Singh, P., Prabhakar, S. and Nanda, A.S. (1998). Amputation of prolapsed uterus with fibrosarcoma in cow. *Indian J. Anim. Reprod.*, **19**(2):161-162.
- ✓ Singh J., Ghuman, S.P.S., Dadarwal, D., Honparkhe, M. and Singh, N. (2009). Evaluation of a systemic antibiotic treatment of chronic endometritis in buffaloes. *Intas Polivet*, **10** (1): 25-28.
- Smith, H.G.Jr. *et al.* (1979). *Biochem.*, **18**: 5067 (c.f. Product profile of diagnostic kit for total protein from Crest Biosystems Pvt. Ltd.).
- Snedecor, G.W. and Cochran, W.G. (1986). *Statistical Methods*. 8<sup>th</sup> edn. Iowa State University Press, Ames, Iowa, USA.



- Tank, P.H., Kasundra, J.K., Shirodkar, K.S., Mankad, M.Y., Wadke, S.S., Manvar, D.A. and Maradia, M.G. (2006). Surgical management of chronic recurrent genital prolapse in cows. *XXX Annual Congress and National Symposium of ISVS*, Veterinary College, KVAFSU, Bidar, Karnatakaka, India.
- Tarjinder Kaur and Singh, B. (1993). Reproductive disorders in buffaloes: Haemato-biochemical studies. *Indian J. Vet. Path.*, **17**(2): 118-121.
- Thomas, H.S. (2000). Prolapse problems. *American Cowman Magz*, Jan. 1.
- Tyagi, R.P.S. and Singh, J. (1993). The Genital System. In: *Ruminant Surgery, 1<sup>st</sup> ed.* CBS publishers, pp. 289-295.
- Vandep lasche, M. and Spincemaille, J. (1963). *Berl. Munch. Tiehzt. Wschr.*, **76** : 324.
- Verma, S.K., Khar, S.K., Gupta, R.C., Bugalia, N.S., Sharma, A.K., Manu, T.S., Khatri, C.K., Malik, J.B. and Chandolia, R.K. (1989). Uterine torsion in buffaloes. Biochemical, haematological and histopathological studies. *Proc. 2<sup>nd</sup> World Buffalo Congr.*, New Delhi, India, Vol. I: p. 390.
- White, M.E. (1987). Purse string suture of the cervix for prevention of repeated uterine prolapse in the cow. *Am. Vet. J.*, **26**(9): 604.
- Whittier, W.D. (2007). Prolapses in cattle – an ugly fact of life. *Livestock update*, Virginia State University.
- Winkler, J.K. (1966). Repair of bovine vaginal prolapse by cervical fixation. *J.A.V.M.A.*, **149**(6): 768.
- Wolfe, D.F. and Carson, R.L. (2007). In: *Current Therapy in Large Animal Theriogenology*. 2<sup>nd</sup> Edn. W.B. Saunders Co., Missouri, USA.

Woodward, R.R. and Quesenberry, A. (1956). A study of vaginal and uterine prolapse in Hereford cattle. *J. Anim. Sc.*, **15**: 119-124.

Yilmaz Zeki, Senturk Sezgin, Ilcol Yesim and Golcu Esin (2006). Periparturient recumbency in cows. *Indian Vet. J.*, **83**: 550-551.

Youngquist, R.S. and Threlfall W.R. (2007). *Current Therapy in Large Animal Theriogenology*. 2<sup>nd</sup> Edn., W.B. Saunders Co., Missouri, US, p. 469-471.

## ANNEXURE- I

### CULTURE AND SENSITIVITY FINDINGS IN COWS WITH PROLAPSE

#### GROUP 1

Sr No.	Isolates (pre-operative)			Antibiotics sensitivity (HS/MS/R)		
	Gram +	Gram -	Mixed	Amoxirum	Cephalexin	Ceftriaxone
1	+			HS	HS	HS
2		+		MS	MS	HS
3			+	R	HS	HS
4	+			HS	HS	HS
5		+		R	MS	HS
6	+			HS	HS	HS
7		+		R	HS	HS
8	+			HS	HS	HS
TOTAL	4	3	1	4/1/3	6/2/0	8/0/0

#### GROUP 2

Sr No.	Isolates (pre-operative)			Antibiotics sensitivity (HS/MS/R)		
	Gram +	Gram -	Mixed	Amoxirum	Cephalexin	Ceftriaxone
9	+			HS	HS	HS
10			+	R	HS	HS
11	+			HS	HS	HS
12	+			HS	HS	HS
13		+		R	MS	HS
14		+		MS	HS	HS
15	+			HS	HS	HS
16			Mix	R	MS	MS
TOTAL	4	2	2	4/1/3	6/2/0	7/1/0

#### GROUP 3

Sr No.	Isolates (pre-operative)			Antibiotics sensitivity (HS/MS/R)			Isolates (post-operative)		
	Gram +	Gram -	Mixed	Amoxirum	Cephalexin	Ceftriaxone	Gram +	Gram -	Mixed
17			Mix	R	MS	HS			
18	+			MS	HS	HS			
19		+		R	HS	HS		+	
20		+		R	HS	HS			
21	+			MS	HS	HS			
22			Mix	R	HS	HS			
23		+		MS	HS	HS			
24			Mix	R	MS	HS			Mix
TOTAL	2	3	3	0/3/5	6/2/0	8/0/0	0	1	1

**ANNEXURE- I Contd...**

**GROUP 4**

Sr No.	Isolates (pre-operative)			Antibiotics sensitivity (HS/MS/R)			Isolates (post-operative)		
	Gram +	Gram -	Mixed	Amoxirum	Cephalexin	Ceftriaxone	Gram +	Gram -	Mixed
25	+			MS	HS	HS			
26			Mix	R	MS	R			
27			Mix	R	MS	MS			Mix
28		+		MS	HS	HS			
29		+		R	MS	HS			
30		+		R	MS	HS			
31			Mix	MS	HS	HS			
32			Mix	R	HS	HS			
<b>TOTAL</b>	<b>1</b>	<b>3</b>	<b>4</b>	<b>0/3/5</b>	<b>4/4/0</b>	<b>6/1/1</b>	<b>0</b>	<b>0</b>	<b>1</b>

**GROUP 5**

Sr No.	Isolates (pre-operative)			Antibiotics sensitivity (HS/MS/R)			Isolates (post-operative)		
	Gram +	Gram -	Mixed	Amoxirum	Cephalexin	Ceftriaxone	Gram +	Gram -	Mixed
33			Mix	R	MS	MS			Mix
34		+		MS	MS	HS			
35		+		R	MS	MS		+	
36			Mix	R	R	MS			Mix
37			Mix	R	R	MS			
38			Mix	R	HS	HS			
39			Mix	R	MS	HS			
40	+			MS	HS	HS			
<b>TOTAL</b>	<b>1</b>	<b>2</b>	<b>5</b>	<b>0/2/6</b>	<b>2/4/2</b>	<b>4/4/0</b>	<b>0</b>	<b>1</b>	<b>2</b>

**GROUP 6**

Sr No.	Isolates (pre-operative)			Antibiotics sensitivity (HS/MS/R)			Isolates (post-operative)		
	Gram +	Gram -	Mixed	Amoxirum	Cephalexin	Ceftriaxone	Gram +	Gram -	Mixed
41		+		R	HS	HS			Mix
42		+		R	HS	HS			
43	+			HS	HS	HS			
44	+			HS	HS	HS			
45	+			HS	HS	HS			
46	+			HS	HS	HS			
<b>TOTAL</b>	<b>4</b>	<b>2</b>	<b>0</b>	<b>4/0/2</b>	<b>6/0/0</b>	<b>6/0/0</b>	<b>0</b>	<b>0</b>	<b>0</b>
<b>GRAND TOTAL</b>	<b>16 (34.78)</b>	<b>15 (32.61)</b>	<b>15 (32.61)</b>	<b>12/10/24</b>	<b>31/13/02</b>	<b>38/07/01</b>	<b>0</b>	<b>2</b>	<b>4</b>

## ANNEXURE- II, Observations on urine analysis

### Group- 1:

#### Preoperative Observations:

Sr. No.	Colour	Transpa rency	Sp. Gravity	pH	Protein	Blood	Microscopic Examination		
							Pus cells/HPF	RBCs/ HPF	Epithelial casts/HPF
1	Yellow	Clear	1.034	Alkaline	Trace	Absent	3 - 4	2 - 3	4 - 5
2	Dark yellow	Clear	1.042	Alkaline	++	Absent	6 - 8	2 - 3	3 - 4
3	Yellow	Clear	1.032	Alkaline	Trace	Absent	4 - 8	3 - 4	4 - 5
4	Dark yellow	Cloudy	1.034	Alkaline	+	Absent	8 - 10	4 - 5	5 - 6
5	Dark yellow	Cloudy	1.040	Alkaline	Trace	Absent	4 - 5	3 - 4	3 - 4
6	Yellow	Cloudy	1.040	Alkaline	Trace	Absent	3 - 4	2 - 3	4 - 6
7	Yellow	Cloudy	1.037	Alkaline	Trace	Absent	4 - 5	3 - 4	3 - 4
8	Yellow	Cloudy	1.044	Alkaline	+	Absent	6 - 8	4 - 6	8 - 10

#### Postoperative Observations:

Sr. No	Colour	Transpa rency	Sp. Gravity	pH	Protein	Blood	Microscopic Examination		
							Pus cells/HPF	RBCs/ HPF	Epithelial casts/HPF
1	Yellow	Cloudy	1.037	Alkaline	Trace	Absent	5 - 6	2 - 3	5 - 6
2	Yellow	Cloudy	1.047	Alkaline	++	Absent	12 - 14	4 - 5	8 - 10
3	Yellow	Cloudy	1.036	Alkaline	Trace	Absent	8 - 10	2 - 3	4 - 5
4	Yellow	Cloudy	1.040	Alkaline	Trace	Absent	10 - 12	2 - 3	6 - 8
5	Yellow	Clear	1.037	Alkaline	Trace	Absent	2 - 3	1 - 2	2 - 3
6	Yellow	Clear	1.032	Alkaline	Trace	Absent	2 - 3	1 - 2	1 - 2
7	Yellow	Clear	1.032	Alkaline	Trace	Absent	3 - 4	2 - 3	2 - 3
8	Yellow	Clear	1.038	Alkaline	Trace	Absent	4 - 5	2 - 3	4 - 5

**Group II:****ANNEXURE- II, Contd...**

## Preoperative Observations:

Sr. No.	Colour	Transparency	Sp. Gravity	pH	Protein	Blood	Microscopic Examination		
							Pus cells/HPF	RBCs/HPF	Epithelial casts/HPF
9	Dark yellow	Cloudy	1.038	Alkaline	Trace	Absent	6 - 8	3 - 4	5 - 6
10	Dark yellow	Cloudy	1.038	Alkaline	+	Absent	8 - 10	3 - 4	8 - 10
11	Dark yellow	Cloudy	1.035	Alkaline	Trace	Absent	4 - 5	2 - 3	4 - 5
12	Dark yellow	Clear	1.034	Alkaline	Trace	Absent	4 - 5	3 - 4	4 - 5
13	Dark yellow	Cloudy	1.042	Alkaline	Trace	Absent	8 - 10	3 - 5	5 - 6
14	Dark yellow	Cloudy	1.048	Alkaline	+	Absent	15 - 16	6 - 8	8 - 10
15	Dark yellow	Cloudy	1.045	Alkaline	-	Absent	12 - 14	8 - 10	10 - 12
16	Yellow	Clear	1.036	Alkaline	Trace	Absent	2 - 3	2 - 3	4 - 5

## Postoperative Observations:

Sr. No.	Colour	Transparency	Sp. Gravity	pH	Protein	Blood	Microscopic Examination		
							Pus cells/HPF	RBCs/HPF	Epithelial casts/HPF
9	Yellow	Clear	1.035	Alkaline	Trace	Absent	2 - 3	1 - 2	2 - 3
10	Dark yellow	Cloudy	1.042	Alkaline	+	Absent	10-12	4 - 5	8 - 10
11	Yellow	Clear	1.038	Alkaline	Trace	Absent	3 - 4	1 - 2	2 - 3
12	Yellow	Clear	1.036	Alkaline	Trace	Absent	1 - 2	1 - 2	2 - 3
13	Yellow	Clear	1.037	Alkaline	Trace	Absent	2 - 3	2 - 3	1 - 2
14	Yellow	Cloudy	1.045	Alkaline	+	Absent	12 - 14	4 - 5	16 - 18
15	Yellow	Cloudy	1.048	Alkaline	+	Absent	18 - 20	4 - 5	14 - 16
16	Yellow	Clear	1.032	Alkaline	Trace	Absent	2 - 3	1 - 2	2 - 3

## Group III

## ANNEXURE- II, Contd...

Preoperative Observations:

Sr. No.	Colour	Transparency	Sp. Gravity	pH	Protein	Blood	Microscopic Examination		
							Pus cells/HPF	RBCs/HPF	Epithelial casts/HPF
17	Dark yellow	Cloudy	1.038	Alkaline	+	+	8 - 10	6 - 8	8 - 10
18	Reddish Brown	Flocculent	1.054	Acidic	++	++	24 - 26	22 - 24	14 - 18
19	Dark yellow	Cloudy	1.034	Alkaline	Trace	Absent	5 - 6	3 - 4	6 - 8
20	Dark yellow	Cloudy	1.033	Alkaline	Trace	Absent	5 - 6	3 - 4	6 - 8
21	Reddish Brown	Flocculent	1.053	Acidic	++	+	12- 14	25 - 28	14 - 18
22	Reddish Brown	Flocculent	1.050	Acidic	++	++	14 - 28	20 - 24	12 - 14
23	Dark yellow	Cloudy	1.039	Alkaline	+	+	10 - 12	6 - 8	4 - 5
24	Dark yellow	Flocculent	1.048	Alkaline	+	+	10 - 12	6 - 8	6 - 8

Postoperative Observations:

Sr. No.	Colour	Transparency	Sp. Gravity	pH	Protein	Blood	Microscopic Examination		
							Pus cells/HPF	RBCs/HPF	Epithelial casts/HPF
17	Yellow	Cloudy	1.035	Alkaline	+	Absent	3 - 4	2 - 3	14 - 16
18	Dark yellow	Flocculent	1.048	Acidic	++	+	8 - 10	5 - 6	18 - 20
19	Yellow	Cloudy	1.036	Alkaline	+	Absent	3 - 4	2 - 3	8 - 10
20	Yellow	Cloudy	1.030	Alkaline	+	Absent	3 - 4	1 - 2	8 - 10
21	Dark yellow	Flocculent	1.048	Acidic	++	Absent	6 - 8	6 - 8	20 - 22
22	Dark yellow	Flocculent	1.045	Acidic	++	+	10 - 12	5 - 6	18 - 20
23	Yellow	Cloudy	1.034	Alkaline	+	Absent	4 - 5	2 - 3	10 - 12
24	Dark yellow	Flocculent	1.050	Acidic	++	+	4 - 5	2 - 3	10 - 12

**Group IV:**

**ANNEXURE- II, Contd...**

**Preoperative Observations:**

Sr. No.	Colour	Transparency	Sp. Gravity	pH	Protein	Blood	Microscopic Examination		
							Pus cells/HPF	RBCs/HPF	Epithelial casts/HPF
25	Dark yellow	Cloudy	1.042	Alkaline	+	+	10 - 12	5 - 6	6 - 8
26	Reddish brown	Flocculent	1.054	Acidic	++	+	14- 16	10 - 12	6 - 8
27	Reddish brown	Flocculent	1.055	Acidic	++	++	16 - 20	16 - 18	10 - 12
28	Yellow	Cloudy	1.037	Alkaline	trace	+	8 - 10	5 - 6	5 - 6
29	Dark yellow	Cloudy	1.043	Alkaline	+	+	10- 12	8 - 10	5 - 6
30	Yellow	Clear	1.035	Alkaline	Trace	Absent	5 - 6	6 - 8	6 - 8
31	Reddish brown	Flocculent	1.052	Acidic	++	++	12 - 14	16 - 18	10 - 12
32	Reddish brown	Flocculent	1.054	Acidic	++	+	14 - 16	10 - 12	8 - 10

**Postoperative Observations:**

Sr. No.	Colour	Transparency	Sp. Gravity	pH	Protein	Blood	Microscopic Examination		
							Pus cells/HPF	RBCs/HPF	Epithelial casts/HPF
25	Yellow	Cloudy	1.040	Alkaline	+	Absent	4 - 5	2 - 3	8 - 10
26	Dark yellow	Flocculent	1.046	Acidic	++	+	5 - 6	4 - 5	10 - 12
27	Dark yellow	Flocculent	1.050	Acidic	++	+	5 - 6	4 - 5	14 - 16
28	Pale yellow	Clear	1.038	Alkaline	Trace	Absent	4 - 5	1 - 2	8 - 10
29	Pale yellow	Clear	1.035	Alkaline	Trace	Absent	3 - 4	2 - 3	10 - 12
30	Pale Yellow	Cloudy	1.030	Alkaline	+	Absent	1 - 2	2 - 3	14 - 16
31	Dark yellow	Flocculent	1.050	Acidic	++	+	6 - 8	5 - 6	18 - 20
32	Dark yellow	Flocculent	1.048	Acidic	++	+	6 - 8	3 - 4	16 - 18

## Group V

## ANNEXURE- II, Contd...

## Preoperative Observations:

Sr. No.	Colour	Transparency	Sp. Gravity	pH	Protein	Blood	Microscopic Examination		
							Pus cells/HPF	RBCs/HPF	Epithelial casts/HPF
33	Reddish Brown	Flocculent	1.048	Alkaline	+	++	22 - 24	4 - 6	14 - 16
34	yellow	Cloudy	1.045	Alkaline	+	+	8 - 12	8 - 10	8 - 10
35	Dark yellow	Flocculent	1.054	Acidic	++	absent	22 - 24	5 - 6	14 - 16
36	yellow	Cloudy	1.038	Alkaline	trace	absent	5 - 6	4 - 5	8 - 10
37	Reddish Brown	Flocculent	1.058	Acidic	+++	+	14 - 16	14 - 16	18 - 20
38	Dark yellow	Flocculent	1.053	Acidic	++	+	18 - 22	8 - 10	12 - 14
39	Dark yellow	Cloudy	1.038	Alkaline	Trace	absent	6 - 8	5 - 6	8 - 10
40	Reddish Brown	Cloudy	1.049	Alkaline	+	+	20 - 22	14 - 16	10 - 12

## Postoperative Observations:

Sr. No.	Colour	Transparency	Sp. Gravity	pH	Protein	Blood	Microscopic Examination		
							Pus cells/HPF	RBCs/HPF	Epithelial casts/HPF
33	Yellow	Cloudy	1.042	Alkaline	+	+	8 - 10	3 - 4	8 - 10
34	Yellow	Clear	1.037	Alkaline	+	Absent	3 - 4	3 - 4	5 - 6
35	Yellow	Cloudy	1.048	Alkaline	++	Absent	8 - 10	2 - 3	5 - 6
36	Pale yellow	Clear	1.035	Alkaline	Trace	Absent	2 - 3	3 - 4	4 - 5
37	-	-	-	-	-	-	-	-	-
38	Dark yellow	Cloudy	1.045	Alkaline	+	Absent	6 - 8	3 - 4	6 - 8
39	yellow	Clear	1.032	Alkaline	Trace	Absent	2 - 3	3 - 4	4 - 5
40	Dark yellow	Cloudy	1.054	Acidic	++	+	8 - 10	6 - 8	18 - 20

**Group VI:****ANNEXURE- II, Contd...****Preoperative Observations:**

Sr. No.	Colour	Transpa rency	Sp. Gravity	pH	Protein	Blood	Microscopic Examination		
							Pus cells/HPF	RBCs/ HPF	Epithelial casts/HPF
41	Dark yellow	Cloudy	1.038	Alkaline	+	absent	8 - 10	4 - 6	8 - 10
42	Yellow	Clear	1.036	Alkaline	trace	absent	4 - 6	5 - 6	10 - 12
43	Yellow	Clear	1.030	Alkaline	+	absent	5 - 7	3 - 4	4 - 6
44	Yellow	Cloudy	1.038	Alkaline	+	absent	4 - 6	2 - 3	8 - 10
45	Pale yellow	Clear	1.028	Alkaline	trace	absent	4 - 6	3 - 4	5 - 6
46	Pale yellow	Clear	1.032	Alkaline	trace	absent	4 - 6	3 - 4	5 - 6

**Postoperative Observations:**

Sr. No.	Colour	Transpa rency	Sp. Gravity	pH	Protein	Blood	Microscopic Examination		
							Pus cells/HPF	RBCs/ HPF	Epithelial casts/HPF
41	Yellow	Clear	1.035	Alkaline	+	absent	4 - 5	3 - 4	4 - 5
42	Yellow	Clear	1.030	Alkaline	trace	absent	2 - 3	2 - 3	4 - 5
43	Yellow	Clear	1.032	Alkaline	trace	absent	3 - 4	4 - 5	6 - 8
44	Yellow	Clear	1.034	Alkaline	+	absent	1 - 2	2 - 3	6 - 8
45	Yellow	Clear	1.030	Alkaline	trace	absent	1 - 2	2 - 3	2 - 3
46	Yellow	Clear	1.028	Alkaline	trace	absent	3 - 4	3 - 4	2 - 3