

Occurrence of Avian Leucosis Complex in Commercial Layer Chicken Raised in Cages

R.Ravikumar¹, M.Saravanajayam, R.Madheswaran and T.V.Tamilam

Avian Disease Laboratory, Centre for Animal Health Studies, TANUVAS, Thalaivasal - 636 112. Tamil Nadu, India.

(Received : 06-06-2015; Accepted : 14-07-2015)

Abstract

Twelve dead commercial layer birds of 46 weeks age were examined to know the cause of the death. The total flock size was 10,000 and birds were raised in cages from day one of age. The total mortality over a period of 12 weeks was 7.6%. The birds appeared weak and emaciated. At necropsy, liver, spleen, kidneys revealed tumour nodules. The tumours were soft, smooth, glistening and the cut surface was greyish to creamy white in colour. Histopathology of liver, spleen and kidney lesions were corroborated the gross lesions. Avian Leucosis Complex (ALC) was confirmed by conducting multiplex PCR from the suspected cases.

Key words: Layer chicken, avian leucosis complex, multiplex PCR, histopathology.

The present paper describes the occurrence of Lymphoid Leucosis (LL) in layer birds raised entirely in cages.

Materials and Methods

Twelve dead commercial layer birds of 46 weeks age were examined to know the cause of the death, with a case history of weak, debilitated and 8% loss in production with 5% mortality over a period of 3 weeks. The total flock size was 10,000 and all the birds were raised in cages from day one of age. The persistent mortality (0.58% per week) was recorded from 35 to 40 weeks and it increased at the age of 41 weeks from 0.58% to 1.26% per week. The total mortality over a period of 12 weeks (35-46 weeks) was 7.60%.

A detailed necropsy was conducted on dead as well as on few weak birds and gross lesions were recorded. The tissue samples from different portions of the liver, spleen, kidney,

ovary and mesentery were collected in 10% formalin, processed and sections were stained with haematoxylin and eosin. Suspected liver and spleen samples were collected in dry ice for multiplex PCR confirmation.

Results and Discussion

The affected birds were appeared weak and emaciated. At necropsy liver revealed nodular coin like tumours, miliary, diffuse, grey and friable (Fig. 1). The tumours were soft, smooth and glistening. The cut surface of the tumour was greyish to creamy white in colour. Spleen was very much enlarged with miliary greyish white nodules. Kidneys were pale and enlarged with big whitish nodules. The gross changes in the liver, spleen and kidney observed in this study agreed with the findings of earlier workers (Balachandran *et al.*, 2009). The other changes observed were splenomegaly, atrophy of the bursa of Fabricius and congested pancreas.

Histopathologically liver samples showed severe mononuclear cell infiltration in the parenchyma and necrosis of adjacent hepatocytes (Fig. 2). In higher magnification single cell necrosis was evident. Spleen revealed lymphoid cell depletion and lymphocytolysis. Multiplex PCR was conducted for 5 samples of suspected cases along with known negative and positive controls provided in the kit and ALC was confirmed (Fig. 3).

Lymphoid leucosis was diagnosed in the commercial layer chicken of 46 weeks of age. Clinically birds showed 8% less egg production, weak, debilitated and 5 per cent mortality over a period of 3 weeks. Liver sections revealed diffuse and focal infiltration of uniform sized lymphoid cells resulting atrophy of the hepatocytes due to compression and replacement are in the agreement with the reports of earlier workers (Cooper

¹Corresponding author : Email : drravipath@yahoo.com



Fig 1. Liver showing enlarged coin like tumour and miliary greyish white nodules.

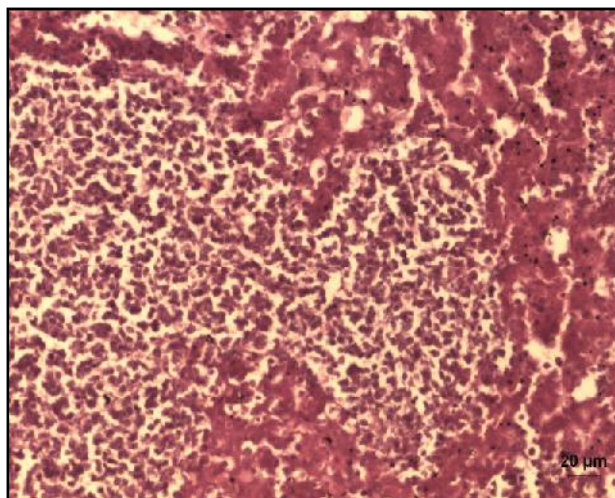


Fig 2. Histopathology of the liver revealed severe mononuclear cell infiltration in the parenchyma and necrosis in the adjacent hepatocytes. H&E x 20 µm

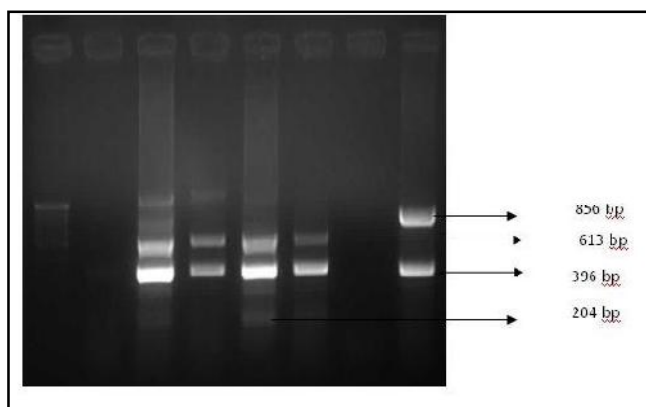


Fig 3. Multiplex PCR results showing the lanes 1 – Ladder; 2, 3, 4, 5 and 6 - ALV Positive; 7 - Negative control; 8 - Positive control.

et al., 1968; Calnek and Adidinger, 1971). Nodules were surrounded by a band of fibroblasts and consisted of aggregates of uniform large lymphoid cells or lymphoblasts of early developmental stages as reported by Calnek and Adidinger *loc. cit.* Depletion of lymphocytes in and around the germinal centres and clear nodule formation by neoplastic lymphoid cells in the spleen in the present study was also reported by Prukova *et al.*, (2007), who described that the depletion of lymphocytes in the thymus, bursa of Fabricius and spleen is an essential feature in the ALV infected birds. The multiplex PCR test was highly useful for rapid detection and differentiation of avian oncogenic viruses (Smith *et al.*, 1998; Latiff and Khalafalla, 2005).

Acknowledgement

Authors are thankful to the Department of Veterinary Pathology and Department of Biotechnology, Madras Veterinary College, Chennai – 600 007 for providing the facilities to carry out the part of this work.

References

- Balachandran, C., Pazhanivel, N, Vairamuthu, S. and Murali Manohar, B. (2009) Marek's Disease and Lymphoid Leucosis in Chicken - A Histopathological Survey. *Tamilnadu J. Vet. Anim. Sci.*, **5(4)**: 167-70.
- Calnek, B.W. and Adidinger, H.K. (1971) Some characteristics of cell free preparation of Marek's disease virus. *Avian Dis.*, **15**: 508-517.
- Cooper, M.D., Payne, L.N, Dent, B.R, Burmester, B.R. and Good, R.A. (1968) Pathogenesis of avian lymphoid leucosis. *J. Nat. cancer Inst.*, **41**: 373-389
- Latiff, M.M. and Khalafalla, A.I. (2005) Detection by PCR of multiple subgroups of Avian Leucosis Virus (ALC) in broilers in Sudan. *J. Anim. Vet. Advan.*, **4(3)**: 407-13.
- Prukova, D., Vernerova, Z, Pilik, T, Stepanets, V, Indrova, M, Geryk, J, Plachy, J, Hejnar J. and Svoboda, J. (2007) Differences in pathogenicity among strains of the same or different avian leucosis virus subgroups. *Avian pathol.*, **36**: 15-27
- Smith, L.M., Brown, S.R, Howes, K, McLoed, S, Arshad, S.S, Barron, G.S, Venugopal, K, McKay, J.C. and Payne, L.N. (1998) Development and application of Polymearse Chain Reaction (PCR) tests for the detection of subgroup J avian leucosis virus. *Virus Res.*, **54**: 87-98.