

**COMPARATIVE STUDIES ON DIAGNOSTIC  
AND THERAPEUTIC APPROACH FOR ANAL  
SAC DISORDERS IN DOGS**



**THESIS**

*Submitted to the*



**Jawaharlal Nehru Krishi Vishwa Vidyalaya, Jabalpur**

*In partial fulfillment of the requirements for  
the Degree of*

**MASTER OF VETERINARY SCIENCE AND  
ANIMAL HUSBANDRY**

*In*

**VETERINARY SURGERY AND RADIOLOGY**

*By*

**MRS. POOJA GUPTA**

**Department of Veterinary Surgery and Radiology  
Jawaharlal Nehru Krishi Vishwa Vidyalaya, Jabalpur  
College of Veterinary Science and Animal Husbandry  
Jabalpur (MP)**

2007



## CERTIFICATE - I

*This is to certify that the thesis entitled "COMPARATIVE STUDIES ON DIAGNOSTIC AND THERAPEUTIC APPROACH FOR ANAL SAC DISORDERS IN DOGS" submitted in partial fulfilment of the requirements for the degree of MASTER OF VETERINARY SCIENCE AND ANIMAL HUSBANDRY in VETERINARY SURGERY & RADIOLOGY of Jawaharlal Nehru Krishi Vishwa Vidyalaya, Jabalpur is a record of the bonafide research work carried out by Mrs. Pooja Gupta under my guidance and supervision. The subject of the thesis has been approved by the Student's Advisory Committee and the Director of Instruction.*

*No part of the thesis has been submitted for any other degree or diploma (Certificate awarded etc.) or has been published/published part has been fully acknowledged. All the assistance and help received during the course of the investigation has been acknowledged by her.*

  
**Dr. V.P. Chandrapuria**

Chairman of the Advisory Committee





### THESIS APPROVED BY THE STUDENT'S ADVISORY COMMITTEE

Chairman : (Dr. V.P. Chandrapuria)

Member : (Dr. M.K. Bhargava)

Member : (Dr. O.P. Shrivastava)

Member : (Dr. Y.P.S. Malik)


  
.....  
  
.....  
  
.....  
  
.....

## CERTIFICATE-II

This is to certify that the thesis entitled "COMPARATIVE STUDIES ON DIAGNOSTIC AND THERAPEUTIC APPROACH FOR ANAL SAC DISORDERS IN DOGS" submitted by Mrs. Pooja Gupta to the J.N. Krishi Vishwa Vidyalaya, Jabalpur in partial fulfilment of the requirements for the degree of **MASTER OF VETERINARY SCIENCE AND ANIMAL HUSBANDRY** in the Department of **VETERINARY SURGERY & RADIOLOGY** has been, after evaluation, approved by the External Examiner and by the Student's Advisory Committee after an oral examination on the same.

Place : Jabalpur

Date : 25 / 12 / 2007

  
Chairman  
Advisory Committee

### MEMBERS OF THE ADVISORY COMMITTEE

Chairman : (Dr. V.P. Chandrapuria)


Member : (Dr. M.K. Bhargava)

Member : (Dr. O.P. Shrivastava)

Member : (Dr. Y.P.S. Malik)

Head of the Department: (Dr. M.K. Bhargava)

Director of Instruction :

  
Director Instruction  
J.N. Krishi Vishwa Vidyalaya  
JABALPUR

## ACKNOWLEDGEMENT

I sincerely bow to the "Almighty" for showering his blessing and love upon me and for giving me an opportunity to write this manuscript.

"The satisfaction and euphoria that a company has in the successful completion of any task would be incomplete, without the mention of the people who made it possible and whose constant guidance and encouragement served as a beacon of light and crowned the effort with success". Thus, I consider it as my privilege to express through the pages of this a word of gratitude and respect to all those personalities who inspired me in the completion of this study.

The precious souvenir of learning is a debt that is difficult to pay; only gratitude can be felt. Indeed, the words at my command are inadequate in spirit to express my heart felt, deep sense of unbound gratitude and indebtedness to *Dr. V.P. Chandrapuria Professor* Department of Veterinary Surgery & Radiology and Chairperson of my Advisory Committee for laying out the guidelines of research work and training my mind to think systematically and logically. I have real admiration and regards for his keen interest, scholarly and judicious guidance, wholehearted, ever available and untiring help and painstaking efforts, more specially the kindness bestowed upon me and above all soothing parental affection, sense of forgiveness throughout my association with him. My working under him will always remain an unforgettable experience of my life.

I owe an everlasting debt of gratitude to *Dr. M.K. Bhargava Professor & Head* Department of Veterinary Surgery & Radiology and member of advisory committee for his valuable suggestion and consistent help during the course of investigation.

I wish to thank all amicable members of my Advisory committee *Dr. O.P. Shrivastava Professor*, Department of Animal reproduction gynecology & obstetrics and *Dr. Y.P.S. Malik*, Assistant Professor Department of Veterinary Microbiology for their constant encouragement constructive suggestions and valuable advice.

I would like to extend my heartiest thanks to **Dr. A. P. Singh**, Honorable Dean, College of Veterinary Science and Animal Husbandry, Jabalpur for his valuable comments, which were always helpful for improving this work.

I cordially put sincere thanks to **Dr. Gautam Kallu**, Honorable Vice Chancellor, **Dr. D. P. Singh**, former Vice Chancellor and **Dr. S.S. Tomar** Director of Instruction, J. N. Krishi Vishwa Vidyalaya Jabalpur (M.P.) for their kind support and facilities provided.

I wish to record my thanks to **Dr. (Mrs.) Apra Shahi** **Dr. (Mrs.) Shobha Jawre**, **Dr. Randhir Singh**, for their kind help in different way during the entire course of the work.

I also thank **Dr. Kavita Roy**, **Dr. D.K. Gupta**, **Dr. R.G. Agrawal**, **Dr. S.K. Jain**, **Dr. V.K. Bhatt** and **Dr. M. A. Quadri** for their ever willing help and co-operation.

I wish to thank the **Department of Veterinary Services (M.P.)** for providing permission for M. V. Sc. & A. H. degree, especially Deputy Director Veterinary Services **Dr. S.Q. Ali**.

I find this place best to thank **Dr. S.K. Shrivastava** for his time and guidance given to me.

"A friend in need is a friend indeed," these words were made true by my colleagues **Drs. Sanjay, Sunil, Smita, Deepali, Alok, Sachin, Sudhi, Deepak, Vikash, Manmeet, Vishnu, Vineet, Rohit, Dharmendra, Pravendra, Mahesh, Vishakha, Shweta, and Anuradha** by providing their whole hearted support to me in carrying out my research work.

I find this place the best to thank for the pains taken by **Harsh, Vivek, Dr. Neelesh** and **Atul Sharma** for their help at every step of the study.

I am also thankful to **M/s. Cyber Point, Sadar, Jabalpur** for neatly presenting my work in the right form.

I feel to express my thanks to my department employees **Shri H. D. Yadav, Tikaram, Dhan Singh, Ganesh** and **Daduram** for their help in many ways during the work.

I express my regards to my affectionate **parents and family members** whose blessings brought me up to this stage.

In the last but not the least I wish to record my indebtedness to my spouse **Dr. Ashutosh Gupta** without whose co-operation it would be have been impossible to make this manuscript.

Children are the blossoms who cheer ones life forever. I thanks to my children **Aditya and Aprajita** for their patience and affection shown by them during the course of the study.

**Place:** Jabalpur

**Date:** 28.12.2007

*Pooja Gupta*  
**POOJA GUPTA**

## CONTENTS

No.	Title	Page No.
1.	Introduction	1-2
2.	Review of literature	3-9
3.	Material and methods	10-17
4.	Results	18-35
5.	Discussion	36-47
6	Summary, conclusions and suggestions for further work	48-52
	6.1 Summary	48-50
	6.2 Conclusions	51
	6.3 Suggestion for further work	52
	References	53-56

## LIST OF TABLES

Table No.	Title	Page No.
1.	Age wise incidence of anal sac disorders	18
2.	Sex wise incidence of anal sac disorders	19
3.	Anamnesis and description of selected cases.	20
4.	Bacteriological examination of anal sac content on day 0 of group I A (Chloromphenicol)	23
5.	Bacteriological examination of anal sac content on day 0 of group I B (Tacrolimus)	24
6.	Clinical signs of anal sac disorders evaluated at different intervals of medicinal therapy	25
7.	Clinical examination of anal sac content at different intervals of medicinal therapy	29
8.	Diagnosis of anal sac disorders on the basis of sonography	30
9.	Comparative evaluation of surgical technique on the basis of packing materials.	33
10.	Evaluation of Inflammation in surgical technique	34
11.	Healing pattern in surgical groups at different intervals	35

## LIST OF PLATES

Plate No.	Title	Between Pages
1.	Impacted anal glands	20-21
2	Manual expression of left anal gland	20-21
3	Ultrasonography of anal sac of dog in situ	11-12
4	Sonogram with right impacted and left gland expressed.	11-12
5	Sonogram of normal anal sacs	30-31
6	Sonogram of expressed anal sacs	30-31
7	Sonogram of sacculitis showing three layers	30-31
8	Sonogram of impacted anal sacs	30-31
9	Sonograms of anal sac tumours	30-31
10	Pin point colony on nutrient agar	31-32
11	Medium size colony on nutrient agar	31-32
12	Green pigmentation on nutrient agar	31-32
13	Foley Balloon catheter	14-15
14	Hypodermic needle encapsulated with P.V.C. catheter	14-15
15	Foley Balloon catheter inflating anal gland	15-16
16	Site of sacculectomy incision	15-16
17	Exposed anal sac using foley catheter	15-16
18	Ligated anal duct	15-16
19	Instillation of dental mould in anal sac	15-16
20	Dental mould inflating the gland	15-16
21	Exposed anal sac with dental mould technique	15-16
22	Appearance of site on 3 <sup>rd</sup> P.O.D.	15-16
23	Characteristic internal grayish colour of anal sac	15-16
24.	Incised anal gland with dental mould	15-16
25	Sonogram of anal sac abscess	30-31
26.	Sonogram of impacted anal sac	30-31

## LIST OF ABBREVIATIONS

ABBREVIATION	STAND FOR
%	Percent
@	At the rate of
°	Degree
° F	Degree Fahrenheit
A.H.	Animal Husbandry
approx	approximately
b. wt.	Body weight
<i>et al.</i>	(et alli) and elsewhere
Fig.	Figure
hrs.	hours
i.e.	That is
i.v	intra venous
i/m	intramuscular
JNKVV	Jawaharalal Nehru Krishi Vishwa Vidyalaya
Kg	Kilogram
mg	Milligram
MHz	Megahertz
ml	Millilitre
mm	millimeter
No.	Number
POD	post operative day
TVCS	Teaching Veterinary Clinical Service Complex
v/s	versus
w/v	weight by volume

## INTRODUCTION

## 1. INTRODUCTION

Anal sacculitis is inflammation of anal sacs, located subcutaneously on each side of the anus at 5 and 7 o' clock positions. They connect to the anus via small ducts and produce and store a dark, greyish brown, foul smelling thin granular fluid. During defecation anal sacs are normally squeezed between the overlying anal sphincter and the stool present in the anal canal squirting 0.25-0.5 ml of the fluid (Ashdown, 1968).

Most of the dogs can empty these glands voluntarily for scent marking or in self defence, this enable the dog to mark its territory and to identify each other. Domestication provides non-threatening environment to dogs eliminating the need of the sacs for this purpose. Food rich in vegetable protein produces soft stool, which prevents squirting during defecation. The rarely emptied sacs fill up with fluid, which solidifies and becomes an ideal environment for bacterial growth. Anal sac disorders are seen predominantly in older dogs, and is frequently encountered in small breeds of dogs like Miniature Poodles, Toy Poodles, and Chihuahuas, however, not uncommon in other larger breeds.

Disorders of the anal sacs include Impaction, Infection, abscess and neoplasia (Anderson *et al.*,1987). Inflammation, obstruction or abscessation makes anal sac secretion change to a thick pasty material that may contain blood and suppurative material. The non-neoplastic conditions are probably variation of same process rather than separate disease. When the fluid becomes thick and solidified, the condition is called **impaction**. When bacteria grow in this material it produces a yellow pus, the condition is then called as **Anal abscess**. In complicated cases, **perianal adenoma** and **fistula** may also develop which are observed primarily in German shepherd dog (Drazner, 1985).

The treatment for anal sac disorders depends on its stage. Anal sac impaction and anal sacculitis are often treated conservatively by gentle expression of the anal sac. Severe anal sacculitis may require instillation of a antibiotic corticosteroid ointment. Recurrent episode of severe impaction, anal sacculitis, anal abscesses and adenoma are indications for anal saccullectomy

(Greiner,1975).However, there are certain complications of conventional surgical treatments especially sacculotomy. The excessive friability of anal sac results in incomplete removal of sac leading to recurrence or anal fistula formation. During the ablation by open method there might be injury to the anal sphincter, caudal rectal nerve or even rupture of rectum. While in close method proper outlining of sac with prevalent materials as silk, India ink, plaster of paris, or water is unsatisfactory and cumbersome. The use of dental mould material or Foley balloon catheter does not have any systematic scientific study, thus the present study was designed with the following objectives.

#### **OBJECTIVES**

1. To study the incidence of anal sac disorders at TVCSC, College of veterinary science and A.H. Jabalpur.
2. To diagnose, the extent of anal sac diseases/disorders especially with the help of ultrasonography.
3. To observe the efficacy of certain medicaments locally in anal sacculitis, impaction and fistula.
4. To evaluate and standardize an effective, easy and field oriented surgical procedure for anal sacculotomy.
5. To Compare the efficacy of medicinal v/s surgical procedure for anal sacculitis/ impaction and fistula.

## REVIEW OF LITERATURE

## 2. REVIEW OF LITERATURE

### INCIDENCE

Gerisch and Neurand (1973) stated that the anal sac glands are always present in juvenile dogs, it is difficult to regard their function as solely related to sexual behaviour.

Doty and Dunbar (1974) did not notice any correlation between the degree of masculinity of the dogs and the characteristics of their anal sac secretions, although some of the variables were interrelated with each other. In general the consistency of the secretions increased linearly with age.

Harvey (1974) recorded that out of 62 dogs suffering with anal disease, 61 were diagnosed as having anal sac disease. Anal sac disease occurred in dogs of both sexes with wide variation in ages. The representation of Poodle and Chihuahua breeds weighing less than 15 kg was significantly more as compared to German shepherd dogs. Impaction was seen more frequently than infection-abscessation of the anal sacs.

Halnan (1973) stated that out of 3053 dogs treated, 12.5% were affected with anal sacculitis. No predisposition in the dogs or selectivity on the part of the disease was found in relation to breed, sex, age or geographical distribution.

The findings of Elkins and Hobson (1982), indicated that perianal fistula occurs predominantly in middle aged, male German Shepherd dogs.

Walshaw (1983) stated that incidence of anal sac disease was common in small, pure bred dogs, and possible etiology of the disease was impaction or infection and abscessation.

### CLINICAL OBSERVATION AND DIAGNOSIS

Horney and Archibald (1974) stated that anal sac impaction causes the dog to lick or bite the area or rub the anus on the ground as an attempt to relieve the irritation and pain produced by inflammation and pressure. This self inflicted trauma leads to excoriation of the skin and perhaps to abscessation of the anal sac.

Halnan (1973) described a new approach for diagnosis of anal sac disease based on behavioural signs like licking, starting at the rump and asymmetrical sitting and scooting.

Rangnath *et al.* (1992) opined that anal sac impaction, infection and abscessation were the most common form of anal sac diseases in dogs. The important symptoms were scooting, tenesmus, blood stained faeces or blood stained area around the anus and licking of the anal region. They recommended surgical removal of the sacs when the condition became recurrent. For the proper identification of the sac during surgery, they used dental mould (calgin) as prepacking medium and successfully operated 10 dogs by taking 3-4 cms.linear incision over the distended sac.

Van Duijkeren (1995) stated that the colour and consistency of the anal sac contents were variable in healthy dogs and there were no pathognomonic signs of anal sac impaction or sacculitis.

#### **CLINICAL AND BACTERIOLOGICAL EXAMINATION OF ANAL SAC CONTENT**

Meeks (1978) reported that *Staphylococcus coagulase* was the causative agent for the anal sac infection in dog. Further he found that the family members who comes in contact with the dog having anal sac infection, had recurring boils and were positive for *Staphylococcus coagulase* infection and concluded that this might be a public health problem.

Dakshinkar (2002) indicated that anal sacculitis was most prevalent anal sac disease in middle age dogs with *Staphylococcus aureus* as the common pathogen.

Robson *et al.*(2003) concluded that the characteristics of normal anal sacs and their exudate varies but more than 70% showed similar features on cytological examination and physical characteristics. Exudate cytology was highly variable, though yeast were uncommon, and intracellular cocci and erythrocytes were extremely rare.

Lake *et al.* (2004) stated that the normal anal-sac secretions typically contained 41 (median) corneocytes, lots of basophilic background debris, and a mixture of Gram-positive cocci, Gram-positive rods, and Gram-

negative rods. Although no leucocytes or yeasts were found, many of the normal dogs had an occasional non-degenerate neutrophils and yeasts.

#### MEDICINAL THERAPY

Hobday (1953) advocated different types of treatment for obstruction of the anal sacs in dogs. He applied digital pressure to evacuate the sacs in early stages, opened the sac and scrapped to destroy the secreting lining in chronic inflammations. In cases offensive odour was due to anal sac, advised to inject a semi caustic or sclerosing fluid like Carnoy's solution (Absolute alcohol 1cc+ chloroform 3cc+ Glacial acetic acid 1cc+ Ferric chloride 1g) into the sac through the duct to obliterate the sacs. No postoperative complication was recorded.

Halnan (1973) described three principal methods of treatment: a medical regimen in which supervised administration of parenteral drugs and manual emptying of the sacs was performed over a 2-week period and found suitable in mild cases; a surgical regimen based on the well-known methods of excision with special attention to the surgical approach, and a pseudoradical method in which the sacs were sclerosed by a method of irrigation with suitable fixative solutions.

Walshaw (1983) treated the infected anal sac by flushing the sac with antiseptic solution and systemic antibiotics.

Lowenstein *et al.* (1988) reported electro coagulation as an alternative to the surgical removal of canine anal sacs in chronic cases. Histological examination showed that the cause of the subsequent drying up of secretion is the destruction of 80% of the glandular tissue, which is replaced by connective tissue, followed by functional damage to the remaining parts of the glands.

Komar (1989) reported chronic paraproctitis in dogs, not responding to medicinal treatment. He performed non surgical removal of anal sac by injecting 2 ml of 80% aqueous phenol solution into the evacuated sacs and observed 85% cure.

Matthiesen and Marretta (1993) suggested that anal sac impaction should be initially treated by gentle emptying of the anal sac. The anal sac are expressed every 3-4 days until inflammation has subsided. Severe anal sacculitis may require irrigation of the sac with saline solution and instillation of a corticosteroid antibiotic ointment.

Hummel *et al.* (1998) collected secretion from 28 animals with anal sac infection (anal sacculitis). Bacterial examination yielded anaerobic bacteria mixed with aerobic or facultative anaerobic gram negative bacteria. They further observed that dog treated with Clindamycin responded well to the treatment.

Tisdall *et al.* (1999) treated five German Shepherd dogs, suffering with perianal fistula weighing 31.5-35 kg, orally with azathioprine 50 mg and metronidazole 400 mg every 24 hrs. They concluded that the combined use of immunosuppressive and antimicrobial therapy followed by surgery minimize potential morbidity associated with aggressive use of either medical or surgical treatment alone.

Certain immunosuppressive agents like Tacrolimus has been reported to retard the autoimmune reactions in atopic dermatitis and indirectly corrects the anal sac disorders Pappalardo *et al.* (2002), carried out macroscopic, cytological and bacteriological evaluation of anal sac content in normal dogs and in dogs having dermatological diseases and observed no difference between the groups in anal sac dimension or in colour consistency or presence of granules in the content.

Emms (2005) suggested, role of anti cancer drug melphalan in the treatment of dogs with anal sac adenocarcinoma. When combined with cytoreductive surgery, above treatment increased the survival time with the decrease in local recurrence rate of the primary tumor.

Halnan (1973) used chemical cautery to treat inflamed anal sac, with 40% formaldehyde or a mixture of glacial acetic acid and methyl alcohol on 30 dogs. He reported that cauterization was advantageous over surgical excision.

## SURGICAL THERAPY

Hobday (1953) performed anal sacculotomy by using paraffin wax as prepacking material without any post operative complication.

Markowitz *et al.* (1959) performed open method of anal sacculotomy by using a groove director and opined that the closed method with the use of liquid paraffin, or cotton thread was more effective over open method.

Pickens (1977) reported the ablation of anal sac did not always eliminate rectal irritation and pruritus. He advocated use of Hydrocolloid (surgident) a dental mould as prepacking material and insertion of ice suppository into the rectum, to cool the surrounding tissues in order to hasten the solidification of the hydrocolloid, five minutes before packing the anal sac.

Rawlings (1979) suggested anal sacculotomy in cases of chronic anal sac impaction and infection in dogs. He further performed open method of anal sacculotomy by using groove director. He reported faecal incontinence occasionally as post operative complication.

Elkins and Hobson (1983) treated twenty-three dogs suffering with perianal fistula by superficial surgical excision of the involved skin, ano-rectal mucosa, and anal sacculotomy.

Tuntivanich (1982) suggested India ink to pack the anal sac for its convenient ablation, in order to distinguish anal sac from the surrounding tissues. He further discussed that it was less time consuming and complicated process, as compared to other packaging materials like paraffin, plaster of Paris, acrylic resin and silicon sealant.

Walshaw (1983) discussed various indication for surgical intervention as impaction or infection, abscessation with or without fistulous tracts and anal gland adenocarcinoma. He preferred a closed technique, along with duct ligation without packaing the sac with any material prior to anal sacculotomy.

Woodward (1983) recommended use of acrylic mixture for anal saccullectomy as prepacking medium because of its nature of adhering to the sac lining, facilitating its demarcation from surrounding tissue and its relative low cost. He further stated that there was no necrosis due to curing process

Tirgari (1988) reported a simple, clean method for the surgical ablation of anal sacs in dogs and suggested a surgical ablation of anal sac by impregnating the sac with dental mould wass an efficient, quick and simple method.

Komar (1989) removed anal gland in 156 chronic cases of paraproctitis by using 2ml of 80% aqueous phenol solution, success was obtained in 85% of the cases.

Manfra (1992) discussed that the most common indication for anal saccullectomy were chronic and recurrent episodes of anal sac impaction or infection and as an adjunctive surgical treatment of perianal fistulas. Anal sac adenocarcinoma were also treated by anal saccullectomy.

Rangnath *et al.* (1992) recommended surgical removal of the sacs in cases of recurrence of the condition.. For the proper identification of the sac during surgery, they used dental mould (calgin) as prepacking material and successfully operated 10 dogs by making 3-4 cms. linear incision over the distended sac.

Hill and Smeak (1994) studied, open versus-closed bilateral anal saccullectomy for the treatment of non-neoplastic anal sac disease in dogs, and suggested that conventional open technique was associated with greater number of complications as compared to closed and modified technique.

Kenawy *et al.* (1995) carried out surgical approach for infected anal sacs by filling the anal sacs with materials including duracryl, technovit, plaster of Paris, latex, liquid paraffin, gauze, cotton, distilled water or Indian ink and reported plaster of Paris as excellent, while duracryl and technovit were very good for filling the anal sac.

Downs and Stampley (1998) demonstrated use of a Foley catheter to facilitate anal sac removal in the dogs. In all the cases the balloon

of the catheter successfully distended the anal sac during its removal.

Unsalid *et al.* (1999) reported that when acrylic was applied for surgical removal of anal sac, bleeding was minimum, perforation of sacs did not occur in any of the cases, and the duration of operation was shorter than that of conventional operation method.

Goud *et al.* (2002) <sup>11</sup> conducted experimental studies on ablation of anal sacs in dogs and reported that dental impression material (Alginate) was superior to distill water, Indian ink and plaster of paris as prepacking material for anal sac dissection in dogs. Missy

### COMPLICATION

Woodward (1983) suggested the surgical removal of anal sac in cases of recurrent impaction, abscess formation and fistulization. He further suggested that when inadequate prepacking materials like wax or India ink were used resulted in loss of sphincter muscle control due to extensive soft tissue damage.

Walshaw (1983) stated that, faecal incontinence, formation of chronic fistulae and tenesmus were the main post operative complication after using closed technique of anal sacculotomy.

Elkins and Hobson (1982) initially observed faecal incontinence, as the most common postoperative complication, in 4 (20%) of cases out of twenty three cases of sacculotomy. Of these four animals two regained faecal continence by the sixth month postoperatively.

## MATERIALS AND METHODS

### **3. MATERIAL AND METHODS**

#### **3.1 LOCATION AND PLACE OF WORK**

The work has been carried out in the Department of Veterinary Surgery and Radiology, College of Veterinary Science and Animal Husbandry, JNKW, Jabalpur.

#### **3.2 METEOROLOGICAL DATA AND FEATURE OF PLACE**

Jabalpur is situated at 23.17° latitude and 79.57° longitude at 410.87 MSL in the southern part of second agro - climatic zone, including Satpura Plateau and Kymore hills. It has tropical climate having average rainfall of 1241mm.

#### **3.3 TECHNICAL DESIGN**

Clinical cases of thirty two dogs of different breeds, age and sex brought to the Teaching Veterinary Clinical Service Complex (TVCS), from November 2006 to April 2007 suffering from anal sac diseases were included in this study. These dogs were divided into two equal group, (Group I and II) each consisting of 16 dogs for medicinal and surgical therapy. These groups were further divided into two sub groups of 8 dogs each, (Group I A and I B Group II A and B). The study was undertaken on diagnostic and therapeutic approaches for anal sac disorders.

#### **3.4 DIAGNOSTIC STUDY**

Diagnosis of anal sac diseases in each dog was based on anamnesis, clinical observation, clinical examination of anal sac content, ultrasonography and bacteriological evaluation of anal sac content.

##### **3.4.1 Anamnesis and Description of Animal**

To find out probable etiological factor, age, sex, breed, feeding, management, course of illness and previous treatment with its response, were recorded for each dog in both the groups.

##### **3.4.2 Clinical Observation**

The clinical signs such as scooting (dragging the anal area), excessive licking under the tail, severe perianal pain, reluctance to walk,

fever, tenesmus, perianal pruritis, swelling on either side of the anus, serosanguinous or sticky drainage on either side of the anus, diarrhoea/constipation, straining during defecation, tail chasing, discharge, behavioural changes and pyotraumatic dermatitis were recorded. These observations were observed prior to treatment and subsequently post treatment on day 5, 10, and 15.

### 3.4.3 Clinical examination of anal sac content

Per rectal examination of anal sacs in all the dog was carried out using thumb and index finger. The anal sacs were gently expressed to evaluate the colour, consistency and quantity of the expressed anal sac contents.

### 3.4.4 Sonography

For pre and post expression sonography of anal sac, Triflupromazine hydrochloride @ 2-3 mg/ kg body weight (I/M or I/V) or Xylazine @ 1-2 mg/ kg body weight (I/M) was administered to reduce struggling of the dog during sonography. The ultrasonographic examination was done by using real time, B mode, grey scale, 8 MHz, linear array transducer of Famlco 5 (5 SA 510A) ultrasound machine (Plate 3). Gel was applied on the skin surface of both the glands at 5 and 7' 0 clock position and then transducer was placed in the transverse plane and the image of both the glands were frozen. The selected prints were also recorded on the thermal printing paper as described by Nyland and Matton (2002).

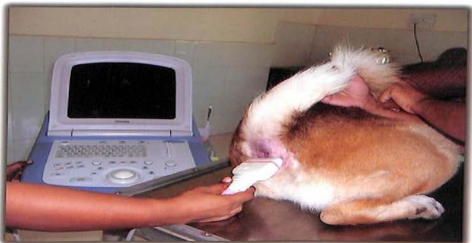### 3.4.5 Bacteriological examination of anal sac content

#### (i) Sample collection

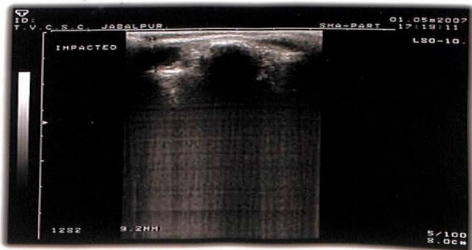
The perianal region of the selected dogs was scrubbed and cleaned with povidone solution. Later, gentle digital pressure was applied over the anal sac and a drop of secretion was collected on a sterile cotton swab. The swabs were processed for bacteriological analysis. A total of 41 samples were collected from the anal sac.

#### (ii) Isolation and identification of the bacteria

Isolates were identified on the basis of cultural characters, staining character, motility and biochemical tests. The samples were



**Plate 3. Ultrasonography of anal sac of dog in situ.**



**Plate 4. Sonogram with right impacted and left gland expressed**

inoculated in nutrient broth and subsequently streaked on nutrient agar, and incubated at 37°C overnight. On the next day plates showing colonies on nutrient agar were stained by Gram's staining method as described by Cruickshank *et al.*(1975), followed by streaking on selective, enrichment media. Colonies were streaked onto MacConkey agar plate and incubated at 37°C for 24 hrs. The lactose positive colonies were further streaked onto Eosin Methylene blue (EMB) agar plates and lactose negative colonies were streaked onto Brilliant Green Agar (BGA) plates. Typical *E.coli* colonies on EMB agar appearing as purple or green with metallic sheen and *Salmonella* sp. as pink coloured colonies on BGA were observed. Subsequently biochemical tests were performed such as indole, methyl-red, voges-proskauer, citrate, oxidase, catalase, triple sugar iron, and hydrogen sulphide production (Cruickshank *et al.*, 1975).

**a. Motility test**

The bacterial isolates were checked for their motility by the hanging drop preparation.

**b. Biochemical tests**

**Indole test**

Peptone water tube was inoculated with culture and incubated at 37°C for 24-48 hrs. Next day 1ml of ether was added to the culture broth and was shaken vigorously and allowed to stand till ether collected on the surface of the medium (peptone water). Ehrlich's reagent (1ml) was added by the side of test tube and observed for the development of deep red colour ring at the interface of the Ehrlich's reagent and ether.

**Methyl red test**

Tubes containing 5 ml of sterile glucose phosphate peptone water were inoculated with the test organism and incubated at 37°C for 48 hours. Methyl red indicator (5 drops) was added to each tube and the reading taken after thorough mixing. Development of a deep red colour indicated a positive reaction. An uninoculated medium tube was kept as control for comparison.

### **Voges-Proskauer test**

The test was conducted by inoculating the pure culture into 5 ml of glucose phosphate peptone water tubes. The tubes were inoculated for 72-96 hours at 37°C followed by addition of 0.2 ml of 40 per cent potassium hydroxide solution and 0.6 ml of alpha naphthol and mixed thoroughly. A positive reaction was indicated by the development of a cherry red colour.

### **Citrate utilization test**

The test was conducted to check ability of an organism to use citrate as the sole source of carbon for growth. The test organism was inoculated in to Koser's citrate medium and incubated for 96 hours at 37°C. The development of deep blue colour indicated a positive result.

### **Sugar fermentation test**

To test Sugar fermentation, the development of acid and / or gas in the sugar medium was checked. The media tubes with 1% sugar (glucose, lactose or mannitol) were inoculated with the test organism and incubated at 37°C for 48 hrs. Acid production was indicated by development of red colour and gas by the presence of a bubble in the Durham's tube.

## **3.5 THERAPEUTIC STUDIES**

The study was carried out on 32 dogs suffering from anal sac disorders, diagnosed by symptoms, clinical examination of the content, ultrasonography and, bacteriological examination of the anal sac content. Affected animals were divided in two groups of 16 dogs each as follows.

**Group I** consisted of 16 dogs showing following characters and were subjected to Medicinal therapy.

- Impaction of anal sac
- Sacculitis.
- Anal abscess.

## GROUP I MEDICINAL THERAPY

SUB GROUP	NO.OF ANIMALS	DRUGS AND TREATMENT	MODE OF APPLICATION
IA	8	Expression and flushing with Povidone Iodine and infusion With Chloromphenicol & Dexamethasone.	Local
IB	8	Expression and flushing with Povidone Iodine and infusion with Tacrolimus ointment.	Local

### 3.5.1 MEDICINAL THERAPY

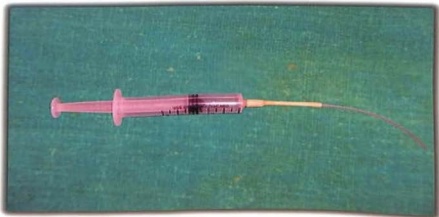Sixteen dogs subjected to medicinal therapy were further divided into two equal sub groups. In group IA the impacted anal sacs were expressed using thumb and index finger per rectally, followed by flushing with Povidone Iodine (5% w/v) and infusion of Chloromphenicol (100mg/ml) 0.5 - 1.0ml and Dexamethasone (4mg/ml) 0.5-1.0 ml. In group IB the impacted anal sacs were expressed, followed by flushing with Povidone Iodine (5% w/v) and infusion of Tacrolimus ointment (0.1 %). Expression and infusion in both the group (1A&1B) was repeated after every five days interval until the secretion becomes normal (Christie, 1985). The treatments were given on day 0, 5, 10 and 15. For infusion of these therapeutic agents disposable needles No. 20, 22 tightly enveloped by PVC tubes were used (Plate 14)

**Group -II** contained 16 dogs with following characters were subjected to surgical therapy

- Rupture of anal sac resulting in anal furunculosis.
- Rupture of anal sac on maturation of abscess.
- Anal sac tumour.
- Chronic or recurrent sacculitis or impaction after medicinal treatment



**Plate 13. Foley Balloon catheter**



**Plate 14. Hypodermic needle encapsulated with P.V.C. catheter**

## GROUP II SURGICAL THERAPY – SACCCULECTOMY

SUB GROUP	NO.OF ANIMALS	DRUGS AND TREATMENT	MODE OF APPLICATION
IA	8	Closed method	Foley balloon Catheter
IB	8	Closed method	Dental mould

### 3.5.2 SURGICAL THERAPY – SACCCULECTOMY

Sixteen dogs subjected to surgical therapy were further divided into two equal groups. In both, the surgical groups close method of anal sac ablation was performed using Foley balloon catheter and /Dental mould which ever was found suitable.

#### a. Pre-operative preparation

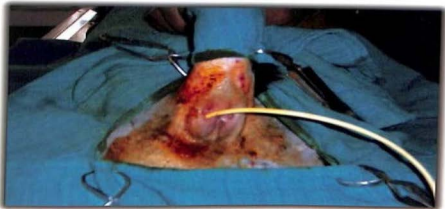
Pre-operative antibiotic (Amoxycillin 250 mg + Cloxacillin 250mg) was given 24 hours pre operatively and dogs were fasted 12 hours prior to surgery. In some cases sodium phosphate anema was also given prior to surgery. The area around anus was shaved and cleaned followed by application of Tincture Iodine.

#### b. Anaesthesia

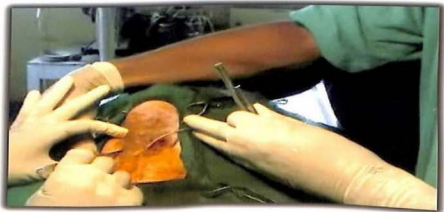Sacculectomy was performed under <sup>disociative</sup> general anaesthesia using Atropine sulphate @ 0.02mg-0.05 mg/kg body weight by I/M route and xylazine hydrochloride @1-2 mg/kg body weight I/M or Diazepam @ 1mg/ kg body weight I/V followed by ketamine hydrochloride @ 10 mg/kg body weight I/M or I/V.

#### c. Procedure for closed method:

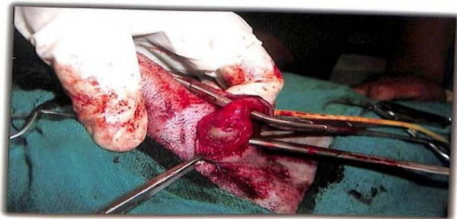
This technique involves excision of the intact anal sac without opening the lumen. In group IIA the Foley balloon catheter (Paediatric) No. 8 was used (Plate 13) to facilitate surgical dissection of the sac. The dog was placed in sternal recumbency with slightly elevated back. The anus was packed with surgical gauze. A lubricated Foley catheter was introduced into the duct of the anal sac until the entire 3-cc balloon was within the sac. The



**Plate 15. Foley balloon catheter inflating anal gland**



**Plate 16. Site of sacculotomy incision**



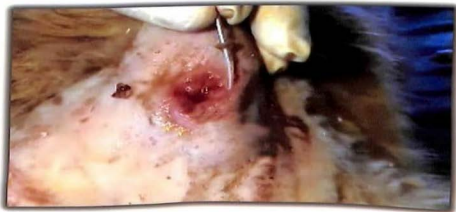**Plate 17. Exposed anal sac using Foley catheter**



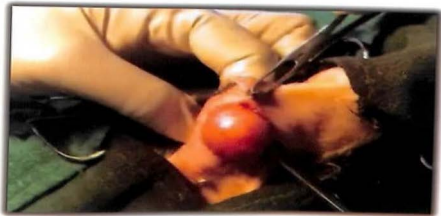**Plate 18. Ligated anal duct**



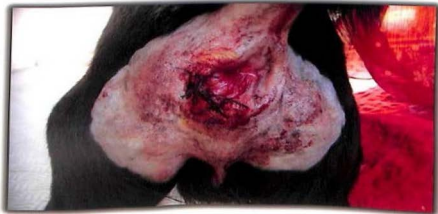**Plate 19. Instillation of dental mould in anal sac**



**Plate 20. Dental mould inflating the gland**



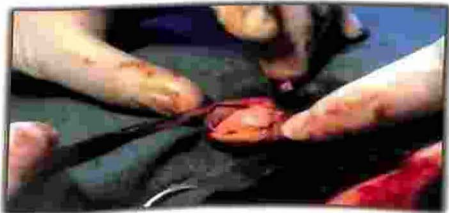**Plate 21. Exposed anal sac with dental mould technique**



**Plate 22. Appearance of site on 3<sup>rd</sup> P.O.D.**



**Plate 23. Characteristic internal greyish colour of anal sac.**



**plate 24. Incised anal sac with dental mould**

balloon was inflated with sterile saline 2-3 ml to the estimated size of the anal sac (plate 15) followed by vertical incision on the skin over the distended sac, approximately 1 to 2 cm lateral to the anus. (Plate 16) The muscle fibers of the external anal sphincter were separated from the sac. Once the sac was exteriorized, (Plate 17) the balloon of the Foley catheter was deflated and the catheter was removed. The anal sac was excised by ligating and transecting the duct with 1-0 absorbable, chromic catgut. (Plate 18) The excision site was lavaged with sterile saline. Closure was accomplished by apposing the subcutaneous tissues with 1-0 absorbable chromic catgut and skin by No. 1 braided silk in interrupted manner (Downs *et al.*, 1998) (Plate 22).

In group IIB dogs, in place of Foley catheter dental mould material was used to fill the sac completely for its clear demarcation during ablation (Goud *et al.* 2002).

#### **d. Preparation of dental mould material**

For the preparation of dental mould, dental impression material Alginate was used. Four gm of material was mixed with 10 ml of distill water and with the help of disposable syringe it was injected in the anal sac. (Plate 19, 20) After injection of material the opening of sac was closed by using artery forcep. The medium got solidified in about 1-2 minutes making the sac distinct. Procedure of anal sacculotomy was the same as in group IIA (Plate 20, 21)

#### **e. Open method**

Open method for sacculotomy was used in the cases having anal fistula or rupture of anal sac during the course of study. This technique permits exposure of the secretory lining of the anal sac. A groove director was placed through the opening of the duct into the anal sac pointing towards the surface of skin. The Incision was made over the director, exposing the sac lining. The gland was bluntly dissected from external anal sphincter muscle.

#### **f. Post operative management**

Antiseptic dressing with Povidone Iodine and parental administration of antibiotic, Amoxycillin-Cloxacin combination was done for 3-5 days.

### 3.6 POST -THERAPEUTIC PARAMETERS

#### 3.6.1 POST MEDICINAL

Following parameters were recorded post medicinal on day 0,5,10 and 15 and graded as mild, moderate and severe.

1. **Disappearance of clinical signs** – On which postoperative day clinical signs disappeared.
2. **Clinical examination of the contents** – changes in the colour, consistency and quantity of the content was recorded.
3. **Sonography** – Status of the gland whether impacted or empty was recorded.
4. **Bacteriological examination** – This was carried out to observe presence or absence of the bacteria.

#### 3.6.2 POST OPERATIVE

Following parameters were recorded post operatively on day 3, 7,14and 21.

1. **Inflammatory signs:** These were assessed as mild, moderate and severe.
2. **Ease of operation:** The superiority of technique was assessed on the basis of duration of operation, approach of gland, haemorrhage and other complications.
3. **Healing pattern** was graded as good, fair and poor
4. **Complications** if any such as Recurrence, fistula and inconsistency of faeces.

Comparisons of treatments in Group I and techniques in Group II were analyzed on the basis of grading obtained as qualitative data during the study.

### 3.7 EXPERIMENTAL LAY OUT

Qualitative data obtained from different sub-groups were evaluated and calculated as per sampling method for determining the superiority of treatment technique.

## RESULTS

## 4. RESULTS

In a period of over six month one hundred and thirty four dogs with anal sac diseases were referred to Department of Veterinary Surgery and Radiology, from Teaching Veterinary Clinical Service Complex (TVCS), College of Veterinary Science and Animal Husbandry, JNKW, Jabalpur. Out of these, only 32 cases were selected for the present study. The epidemiological survey was carried out in all these dogs. Various therapeutic (medicinal or surgical) regimes were undertaken according to diagnosis and severity (based on symptoms) of the condition.

### PARAMETERS OF STUDY

#### 4.1 INCIDENCES

A survey of cases was conducted at Teaching Veterinary Clinical Service Complex (TVCS) from November 2006 to April 2007. During this period total 3782 cases of dogs were presented in TVCS out of which 832 cases (552 male and 280 female) were referred to surgery OPD with various surgical affections. The anal sac affections were recorded in 134 dogs, thus the incidence of anal sac affection was 16.1%.

The highest incidence of anal sac disorders was observed in the age group between 9-12 years(50.39%) followed by 12 years and above (46.05%), 6-9 years (17.07%), 3-6 years (2.63%)and 0-3years (0.95%) respectively. (Table1). These 134 cases included 90 male and 44 female accounting to 16.30% male and 15.71% female incidence of anal sac disorders. (Table 2)

Table 1: Age wise incidence of anal sac disorders

Age group (years)	Surgery OPD	Percentage	Anal sac disorders	Percentage
0-3	313	37.62	3	0.95
3-6	152	18.26	4	2.63
6-9	164	19.71	28	17.07
9-12	127	15.26	64	50.39
12 & above	76	9.13	35	46.05

**Table 2: Sex wise incidence of anal sac disorders**

No. of cases	Total	Male	Percentage	Female	Percentage
Surgery OPD	832	552	66.30	280	33.70
Anal sac disorders	134	90	16.10	44	15.71

Out of these 134 dogs suffering from anal sac diseases 32 dogs were selected for the present clinical study and in these cases following studies were carried out.

#### **4.2 DIAGNOSTIC STUDY**

Diagnosis of anal sac diseases in each dog was based on anamnesis, clinical observations, clinical examination of anal sac content, ultrasonography and bacteriological examination.

These dogs were divided into four equal groups of eight dogs each, two medicinal (I A and I B) and two surgical (II A and II B). The dogs of Group I A were treated with chloremphenicol where as that of Group I B with Tacrolimus. In the surgical cases the dogs of Group II A the packing material used was Foley balloon Catheter while in Group II B Dental mould was used.

##### **4.2.1 ANAMNESIS AND DESCRIPTION OF ANIMAL (Table 3)**

###### **a. Age**

The age wise history of anal sac disorders in dogs ranged from 5 to 18 years. Maximum numbers of cases (43.7%) of anal sac disease were recorded in age group of 6-10 years followed by (28.1%) in age group 8-10 years. No case was observed in the dogs below 4 years of age.

###### **b. Sex**

Out of the 32 cases of anal sac disorders 28 (87.5%) were male and rest 4 (12.5%) were female.

###### **c. Breed**

Anal sac disorders was maximum 15 (47.1%) in Pomeranian followed by 7(21.8%) non descript, which was closely followed by German Shepherd 6 (18.07%) and Apso 4(12.5%) breeds.

#### d. Feeding

Anal sac disorders were found more in 17 (53.1%) dogs with vegetarian diet than on non vegetarian diet 13(46.6%), but most of the vegetarian dogs were also getting non vegetarian diet occasionally.

#### e. Course of illness

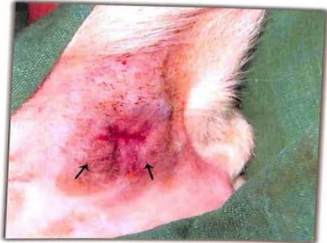The course of illness as revealed by the history indicated that *maximum course of illness* was below 1 month i.e. 15 (47.15%), followed by a period of 1-2 months 7(21.8%). Duration of illness was found as high as above 1 year in sporadic cases, especially associated with perianal fistulas and tumours.

**Table 3: Anamnesis and description of selected cases.**

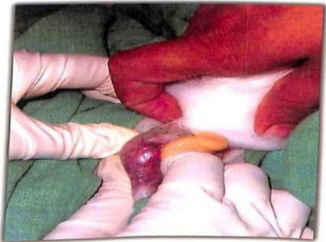
Group	No. of cases	Age group (years)	Sex		Feeding		Duration of illness (days)		
			Male	Female	Veg	Non veg	0-15	16- 30	31 & above
IA	8	6-10	4	4	6	2	3	5	-
IB	8	5-12	8	-	4	4	1	2	5
II A	8	5-12	8	-	5	3	1	3	4
II B	8	5-12	8	-	4	4	1	-	7
Total	32	-	28	4	19	13	6	10	16

#### 4.2.2 CLINICAL SIGNS / OBSERVATIONS

Clinical signs like scooting (dragging the anal area), excessive licking under the tail, occasionally severe perianal pain, fever, tenesmus, perianal pruritis, swollen area on either side of the anus, bloody or sticky drainage on either side of the anus, diarrhoea/constipation, tail chasing, behavioral changes and pyotraumatic dermatitis were observed prior to treatment and graded by their presence or absence (disappearance). (Table 6) On 0 day scooting, licking, perianal pain and swelling were seen in almost all the dogs of both the groups.



**Plate 1. Impacted anal glands**



**Plate 2. Manual expression of left anal gland**

### 4.2.3 CLINICAL EXAMINATION OF ANAL SAC CONTENT

#### Group I A

On squeezing the gland, content was seen in all the 8 animals on 0 day and was of yellow colour, with excessive quantity in 5 dogs, moderate in 3 dogs. The consistency was thick pasty in 7 dogs and thin pasty in 1 dog (Plate 2).

#### Group I B

On 0 day content was seen in all the 8 dogs on squeezing the gland which was excessive in 3, moderate in 4, and scanty in 1 dog. Colour was yellow and dark brown in 3 each, and cream in 2 dogs. Consistency was thick pasty in 6 dogs and thin pasty in 2 dogs.

### 4.2.4 ULTRA SONOGRAPHY

Sonographic examination of anal sac revealed different anal sac disorders, like impaction, sacculitis, tumours and abscess.

#### Normal anal gland

Sonographically, both the anal sacs were visualized in dorsal plane. Both right and left anal sac were seen as oval anechoic areas surrounded by thin hyperechoic outline suggestive of anal sacs. Rectum is seen between both the glands as hypoechoic area with distal acoustic shadow (Plate 5). After the expression of the anal gland very small indistinct hypoechoic to anechoic area surrounded by hypoechoic outline was visible. It was very difficult to identify glands sonographically at this stage (Plate 6).

#### Anal sac impaction

In anal sac impaction the gland became enlarged and hypoechoic than the normal. In later stage it is surrounded by thickened hyperechoic wall (Plate 26, 6).

#### Sacculitis

It was distinguished as oval anechoic area with hyperechoic structures indicative of cellular debris. The gland ~~outlining~~ <sup>hyperechoic</sup> was thick and inflamed giving three hyperechoic layer appearances (Plate 7).

### **Anal sac abscess**

It was seen only in one case, which was present on the right gland as hypoechoic area with hyperechoic patches outlined by thick hyperechoic circular band of fibrous tissue suggestive of anal sac abscess (Plate 25).

### **Tumour mass**

It was represented as ill defined hypoechoic areas with hyperechoic striations where tumour was solid, while in few cases appeared as hyperechoic area with hypoechoic patches. These tumours mass were present in the vicinity of anal sac (Plate 9).

#### **Group I A**

On 0 day two dogs were diagnosed having sever sacculitis while in 3 cases each had heavy and mild impaction.

#### **Group I B**

On 0 day sonographic evaluation revealed mild impaction in two dogs, one case was highly impacted, one had mild sacculitis while tumour with mild sacculitis and tumour with mild impaction, were seen in two cases each.

### **4.2.5 BACTERIOLOGICAL EXAMINATION**

Bacteriological examination of the anal sac contents was carried out in all the sixteen dogs of both the sub groups of **Group I** (Medicinal therapy). On day 0 bacteriological observation study of colony characteristics on nutrient agar or selective media, Gram's staining and biochemical tests was carried out

#### **Day 0 observations**

Out of total 8 samples from **Group I A** 4 samples yielded *Proteus vulgaris*, 2 *E. coli* and one each of *Salmonella* and *Pseudomonas*. (Table 4) while in group **I B** 3 samples were found positive for *Proteus vulgaris* 2 for *E. coli*, 2 *Salmonella* and one *Pseudomonas*. All these isolates gave typical culture, staining, and biochemical characters as described in Table 5.

Table 4: Bacteriological examination of anal sac content on day 0 of group I A (Chloromphenicol)

S. No.	Cultural characteristic		Gram Stain	Biochemical Properties									Suspected Org.
	Media	Character		Indole	MR	VP	Citrate	Catalase	Oxidase	TSI	H <sub>2</sub> S	Motility	
1	NA	Pin point white rounded	-ve	+ve	+ve	-ve	-ve	+ve	var	-ve	-ve	var	<i>E. coli</i>
	EMB	Metallic sheen											
	Mc Con	Pink Colony											
2	NA	Spreading transparent colonies	-ve	+ve	+ve	-ve	var	+ve	var	+ve	+ve	+ve	<i>Proteus vulgaris</i>
3	NA	Greenish pigment	-ve	-ve	-ve	-ve	+ve	-ve	+ve	Alk+ve	-ve	+ve	<i>Pseudomonas</i>
4	NA	Spreading transparent colonies	-ve	+ve	+ve	-ve	var	+ve	var	+ve	+ve	+ve	<i>Proteus vulgaris</i>
5	NA	Spreading transparent colonies	-ve	+ve	+ve	-ve	var	+ve	var	+ve	+ve	+ve	<i>Proteus vulgaris</i>
6	NA	Pin point white rounded	-ve	+ve	+ve	-ve	-ve	+ve	var	-ve	-ve	var	<i>E. coli</i>
	EMB	Metallic sheen											
	Mc Con	Pink Colony											
7	NA	Spreading transparent colonies	-ve	+ve	+ve	-ve	var	+ve	var	+ve	+ve	+ve	<i>Proteus vulgaris</i>
8	NA	Medium size whitish yellow	-ve	-ve	+ve	-ve	-ve	+ve	var	+ve	+ve	+ve	<i>Salmonella sp.</i>
	BGA	Pink colony											

NA- Nutrient agar, BGA- Brilliant green agar, McCon – Mac Conkey, EMB- Eosin Methylene blue, Alk- Alkaline TSI -Triple Sugar Iron

Table 5: Bacteriological examination of anal sac content on day 0 of group I B (Tacrolimus)

S No.	Cultural characteristic		Gram Stain	Biochemical Properties									Suspected Org.
	Media	Character		Iodine	MR	VP	Citrate	Catalase	Oxidase	TSI	H <sub>2</sub> S	Motility	
1.	NA	Greenish pigment	-ve	-ve	-ve	-ve	+ve	-ve	+ve	Alk+ve	-ve	+ve	<i>Pseudomonas</i>
2	NA	Medium size, whitish yellow	-ve	-ve	+ve	-ve	-ve	+ve	var	+ve	+ve	+ve	<i>Salmonella</i> sp.
	BGA	Pink colony											
3.	NA	Spreading transparent colonies	-ve	+ve	+ve	-ve	Var	+ve	Var	+ve	+ve	+ve	<i>Protau vulgaris</i>
4	NA	Pin point, white, round											<i>E. coli</i>
	EMB	Metallic sheen	-ve	+ve	+ve	-ve	-ve	+ve	var	-ve	-ve	var	
	McCon	Pink Colony											
5.	NA	Medium size, whitish yellow	-ve	-ve	+ve	-ve	-ve	+ve	var	+ve	+ve	+ve	<i>Salmonella</i> sp.
	BGA	Pink colony											
6.	NA	Spreading transparent colonies	-ve	+ve	+ve	-ve	var	+ve	var	+ve	+ve	+ve	<i>Proteus vulgaris</i>
7.	NA	Pin point white rounded											<i>E. coli</i>
	EMB	Metallic sheen	-ve	+ve	+ve	-ve	-ve	+ve	var	-ve	-ve	var	
	Mc C	Pink Colony											
8.	NA	Spreading transparent colonies	-ve	+ve	+ve	-ve	var	+ve	var	+ve	+ve	+ve	<i>Proteus vulgaris</i>

NA- Nutrient agar, BGA- Brilliant green agar, McCon - Mac Conkey, EMB- Eosin Methylene blue, Alk- Alkaline  
 TSI -Triple Sugar Iron.

### 4.3 POST MEDICINAL PARAMETERS

#### 4.3.1 CLINICAL SIGNS / OBSERVATIONS

Clinical signs like scooting (dragging the anal area), excessive licking under the tail, occasionally severe perianal pain, fever, tenasmus, perianal pruritis, swollen area on either side of the anus, serosanguinous or sticky drainage on either side of the anus, diarrhoea/constipation, tail chasing, behavioral changes and pyotraumatic dermatitis were observed prior to treatment and subsequently on post treatment interval i.e. 0, 5, 10, and 15 day. These signs were qualitatively graded by their presence or absence (disappearance). (Table 6)

**Table 6 Clinical signs of anal sac disorders at different intervals of medicinal therapy**

S No.	Groups	I A				I B			
		0	5	10	15	0	5	10	15
1	Scooting	8	4	2	0	8	7	3	2
2	Licking	7	2	1	0	8	5	4	0
3	Perianal pain/ Tenasmus	6	3	0	0	6	6	5	2
4	Fever	1	0	0	0	0	0	0	0
5	Pruritis	5	3	0	0	1	1	1	1
6	Swelling	8	2	0	0	7	7	5	4
7	Discharge	1	1	1	1	7	6	5	4
8	Stool	7	0	0	0	3	2	1	0
9	Tail chasing	4	2	0	0	7	6	3	3
10	Behavioural changes	5	0	0	0	2	1	1	1
11	Pyotraumatic Dermatitis	1	1	1	1	0	0	0	0

**a. Scooting**

**Group I A** - On 0 day all the 8 dogs were showing signs of scooting which gradually subsided with only 4 dogs of group I A on 5<sup>th</sup> day, followed by 2 on 10<sup>th</sup> day. None of the dogs showed signs of scooting on 15<sup>th</sup> day

**Group I B** - On 0 day, all the 8 dogs were showing signs of scooting which continued in 7 dogs upto 5<sup>th</sup> day, while on 10<sup>th</sup> day only 3 of them showed signs of scooting, but in 2 dogs signs never disappeared even on 15<sup>th</sup> post therapeutic day.

**b. Licking**

**Group I A** - Licking was observed in 7 dogs selected for treatment, but by 10<sup>th</sup> day the signs disappeared in 6 dogs, while none of them showed licking signs on 15<sup>th</sup> day.

**GROUP I B** - All the 8 dogs showed signs of licking, which continued in 5 dogs till 5<sup>th</sup> day and in 4 dogs till 10<sup>th</sup> day, while the signs disappeared completely in all the dogs by 15<sup>th</sup> day of observation after the treatment.

**c. Perianal pain / tenesmus**

**Group I A** - On 0 day 6 dogs had signs of pain which continued only in 3 dogs upto 5<sup>th</sup> day, while from 10<sup>th</sup> day none of the animal showed sign of perianal pain.

**Group I B** - Pain was evident in 6 dogs which continued till 5<sup>th</sup> day, one of them got relieved from pain on 10<sup>th</sup> day, while 2 dogs continued to show signs of pain even upto 15<sup>th</sup> day.

**d. Fever**

It was observed only in 1 dog of group I A which subsided within 5 days. None of the dogs of group I B showed sign of fever.

**e. Pruritis**

**Group I A** - Out of the 8 dogs, only 5 showed signs of pruritis, which continued in 3 dogs upto 5<sup>th</sup> day, while none of the dogs showed pruritic signs on 10<sup>th</sup> day.

**Group I B** - Only one of the animal showed signs of pruritis which continued till 15<sup>th</sup> day.

**f. Swelling**

**Group I A** - All the dogs showed swelling initially on perianal region, which subsided upto 5<sup>th</sup> day in 6 dogs and by 10<sup>th</sup> day all dogs showed disappearance of swelling.

**Group I B** - Out of the 8 dogs of this group, 7 showed signs of swelling, which continued upto 5<sup>th</sup> post treatment interval, while 5 animals showed signs upto 10<sup>th</sup> day and in 4 dogs swelling continue to persist even on 15<sup>th</sup> day.

**g. Discharge**

**Group I A** - Discharge was seen only in one case, which continued until 15<sup>th</sup> day.

**Group I B** - Discharge was recorded in 7 dogs, which continued in all of them until 5<sup>th</sup> day, in 5 dogs upto 10<sup>th</sup> day while in 4 dogs it continued even upto 15<sup>th</sup> day.

**h. Stool**

Constipated and loose motion was considered as abnormal.

**Group I A** - In seven dogs showed signs of abnormal motion, this became normal in all the dogs by 5<sup>th</sup> day.

**Group I B** - Abnormal motion was seen in 3 dogs which remained abnormal in 2 dogs even after 5<sup>th</sup> day, and returned to normal in 1 dog by 10<sup>th</sup> day, while in the remaining one it became normal upto 15<sup>th</sup> day.

**i. Tail chasing**

**Group I A** - Tail chasing was observed in 4 dogs on 0 day, which continued in 2 dogs on 5<sup>th</sup> day. By 10<sup>th</sup> day none of the dogs showed sign of tail chasing.

**Group I B** - This condition was seen in 7 dogs on the 0 day, which continued in 6 dogs till 5<sup>th</sup> day .On 10<sup>th</sup> day this was observed only in 3 dogs, which persisted till 15<sup>th</sup> day.

**j. Behavioral changes**

Behavioral changes which were recorded in dogs included reduced activity, anorexia, and aggressive behaviour.

**Table 7. Clinical examination of anal sac content at different intervals of medicinal therapy**

No.	GROUP I				GROUP II			
	0 day	5 day	10 day	15day	0 day	5 day	10 day	15day
1	Excessive	Moderate	Scanty	Nil	Excessive	Moderate	Moderate	Scanty
	Thick P	Thin P	Viscous	Nil	Thick P	Thin P	Viscous	Viscous
	Yellow	Yellow	L Yellow	Nil	D Brown	D Brown	Grey	Grey
2	Excessive	Scanty	Nil	Nil	Moderate	Scanty	Scanty	Nil
	Thick P	Viscous	Nil	Nil	Thick P	Thin P	Thin P	Nil
	Yellow	D Brown	Nil	Nil	Yellow	Yellow	Brown	Nil
3	Excessive	Excessive	Moderate	Nil	Excessive	Excessive	Moderate	Scanty
	Thick P	Thin P	Viscous	Nil	Thick P	Thin P	Thin P	Viscous
	Yellow	Yellow	D Brown	Nil	Yellow	Yellow	Yellow	D Brown
4	Excessive	Scanty	Scanty	Nil	Excessive	Nil	Nil	Nil
	Thick P	Thin P	Viscous	Nil	Thick P	Nil	Nil	Nil
	Yellow	Cream	G Brown	Nil	Cream	Nil	Nil	Nil
5	Moderate	Scanty	Nil	Nil	Moderate	Scanty	Scanty	Scanty
	Thick P	Viscous	Nil	Nil	Thick P	Viscous	Viscous	Viscous
	Yellow	Cream	Nil	Nil	Yellow	Yellow	Cream	D Brown
6	Moderate	Nil	Nil	Nil	Scanty	Scanty	Scanty	Scanty
	Thick P	Nil	Nil	Nil	Thin P	Thin P	Thin P	Viscous
	Yellow	Nil	Nil	Nil	D Brown	D Brown	D Brown	Grey
7	Excessive	Nil	Nil	Nil	Moderate	Scanty	Nil	Nil
	Thin P	Nil	Nil	Nil	Thick P	Thin P	Nil	Nil
	Yellow	Nil	Nil	Nil	Cream	Cream	Nil	Nil
8	Moderate	Nil	Nil	Nil	Moderate	Scanty	Scanty	Nil
	Thick P	Nil	Nil	Nil	Thin P	Viscous	Viscous	Nil
	Yellow	Nil	Nil	Nil	D Brown	D Grey	D Grey	Nil



Quantity



Consistency



Colour

### 4.3.2 ULTRA SONOGRAPHY

#### Group I A

On day 5, two cases had mild sacculitis and normal condition each while one case showed mild impaction. In the remaining 3 cases sac was not identified. On day 10 three cases showed normal sac while in remaining five the sac was not identified. In none of the cases anal sac was identified on 15<sup>th</sup> day. (Table 8)

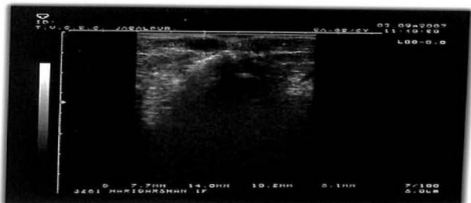#### Group I B

On day 5, mild impaction, mild impaction with tumour and mild sacculitis with tumour was seen in two cases each respectively, while normal gland was observed in one case. In the remaining one case sac was not identified. On day 10<sup>th</sup> observations were same as on day 5<sup>th</sup> with only one change, one of the two dogs showing mild impaction became normal while in the other sac was not identified. On 15<sup>th</sup> day sac was not identified in 4 cases while in 3 cases sac was normal but tumour was still indentifiable. The remaining one case showed mild sacculitis with tumour. (Table 8)

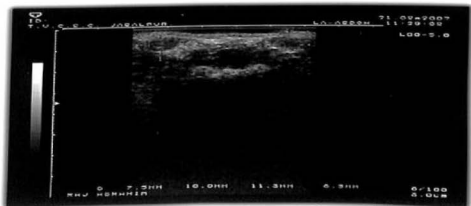**Table: 8 Diagnosis of anal sac disorders on the basis of sonography**

CASE No./ Day	GROUP I A				GROUP I B			
	0	5	10	15	0	5	10	15
1	SS	MS	N	GNI	HI & T	MI&T	MI&T	N&T
2	HI	N	GNI	GNI	MI	MI	N	GNI
3	HI	MI	N	GNI	HI & T	MI&T	MI&T	N&T
4	SS	MS	N	GNI	HI	GNI	GNI	GNI
5	MI	N	GNI	GNI	MS&T	MS&T	MS&T	N&T
6	MI	GNI	GNI	GNI	MS&T	MS&T	MS&T	MS&T
7	HI	GNI	GNI	GNI	MI	MI	GNI	GNI
8	MI	GNI	GNI	GNI	MS	N	N	GNI

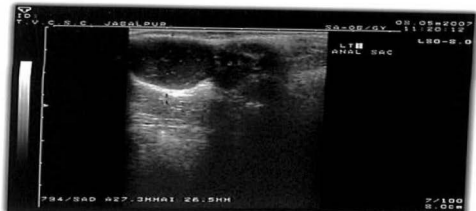SS- Sever sacculitis, MS- Mild sacculitis, HI- Heavily impacted, MI- Mild impaction, N- Normal, T-Tumour, GNI- Gland not identified.



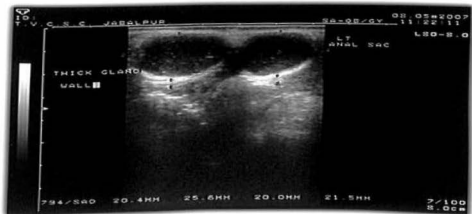
**Plate 5. Sonogram of normal anal sacs**



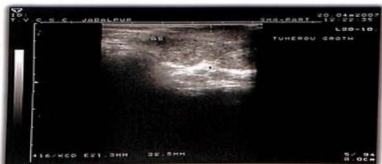
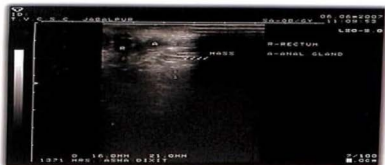**Plate 6. Sonogram of expressed anal sacs**



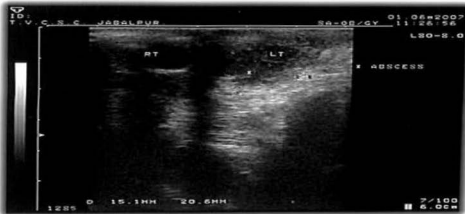**Plate 6. Sonogram of impacted anal sac**



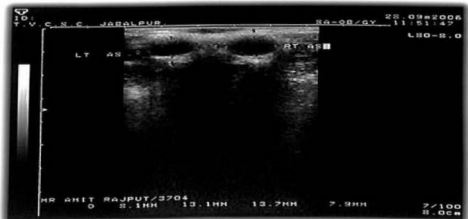**Plate 7. Sonogram of sacculitis showing three layers**



**Plate 9. Sonograms of anal sac tumours**



**Plate 25. Sonogram of anal sac abscess**



**Plate 26. Sonogram of impacted anal sac**

## **BACTERIOLOGICAL EXAMINATION**

On day 5, 10 and 15 of treatment, observations restricted to the study of colony characteristic on nutrient agar and Gram's staining to ascertain the presence of bacteria.

### **a. 5<sup>th</sup> day observations**

In group I A on 5<sup>th</sup> day, discharge was seen only in 5 dogs, out of which 3 anal sac samples showed transparent spreading colonies on nutrient agar with gram negative coccobacilli. One sample showed pin point white colour colonies in nutrient agar while greenish pigmentation (Plate 12) was visualized in nutrient agar with staining characteristic as gram negative coccobacilli in one sample. Anal sac discharge was observed in 7 dogs in group I B on 5<sup>th</sup> day, out of these 7 dogs sample 3 showed transparent spreading colonies on nutrient agar, 3 showed medium size, pin point whitish yellow colonies and one showed green colour colony. Gram's staining result revealed that all the samples were Gram negative in nature.

### **b. 10<sup>th</sup> day observations**

On 10<sup>th</sup> day, discharge was present only in 3 dogs in group I A and 6 dogs in group I B. One anal sac sample out of 3 dogs showed pin point white round colonies on nutrient agar, (Plate 10) second sample showed spreading white colonies, and the last one showed green colony on nutrient agar with Gram negative coccobacilli organism. Out of the 6 dogs showing discharge on 10<sup>th</sup> day in group I B, 2 showed spreading colonies, 2 showed medium size whitish yellow colonies, while in the remaining one was seen pin point white colour colony. On Gram's staining the samples were Gram negative in nature.

### **c. 15<sup>th</sup> day observations**

On 15<sup>th</sup> day anal sac discharge was absent in all the dogs of group I A while in group I B 4 dogs showed very small amount of anal sac content. Two samples out of these showed spreading colonies and one each showed green colour and medium size whitish yellow colonies, respectively indicating presence of bacterial agent. All the 4 samples were Gram negative in nature.



**Plate 10. Pin point colony on nutrient agar**



**Plate 11. Medium size colony on nutrient agar**



**Plate 12. Green pigmentation on nutrient agar  
(*Pseudomonas*)**

#### **4.4 SURGICAL EVALUATION**

##### **4.4.1 EASE OF OPERATION**

###### **a. Out lining**

This was classified as distinctive, moderate and not clear on the basis of demarcation of anal sac from the surrounding structures.(Table 9).

###### **Group II A**

Out of the eight operations performed in the present study, the out lining of the anal sac was very clear (distinctive) in seven cases, only in one case it was not clear.

###### **Group II B**

Outlining was partial in three cases, not clear in three, while in remaining two, it was distinctive.

Looking at the above result Foley catheter gives better outlining as compared to dental mould.

###### **b. Haemorrhage**

On the basis of amount of hemorrhage during the operation, it was classified as mild, moderate and extensive. (Table 9).

###### **Group II A**

Haemorrhage was mild in five cases, moderate in two, extensive in one case.

###### **Group II B**

Haemorrhage was moderate in four cases, mild in three cases, and extensive in one case.

This shows that there is no difference between the extent of haemorrhage in both the groups during the operation.

###### **c. Duration**

The time taken in carrying out the entire operative procedure leaving aside the preanaesthetic preparation was taken into consideration. (Table 9).

## Group II A

The average time taken to complete the operative procedure was in a range 25-40 min.

## Group II B

The operation was performed in a range of 45-55 min. With respect to duration, the time taken to complete operation is much less in group II A as compared to group II B.

The outcome of above observations regarding ease of operation is that the Foley catheter is better than dental mould material as the later is difficult to prepare because it requires accuracy in consistency, it is also cumbersome and more time taking to fill it in to the sacs, which increases the duration of surgery. The outlining was indistinctive in majority of cases of group II B, so the soft tissue damage was more.

**Table 9. Comparative evaluation of surgical technique on the basis of packing material**

Case No.	GROUP II A ( Foley catheter)			GROUP II B (Dental mould)		
	Outlining	Haemorrhage	Duration	Outlining	Haemorrhage	Duration
1	Not clear	Extensive	40 min	Moderate	Moderate	45 min
2	Distinctive	Mild	30 min	Not clear	Extensive	50 min
3	Distinctive	Moderate	35 min	Not clear	Moderate	45 min
4	Distinctive	Mild	30 min	Moderate	Moderate	55 min
5	Distinctive	Moderate	26 min	Distinctive	Mild	45 min
6	Distinctive	Mild	35 min	Distinctive	Mild	40 min
7	Distinctive	Mild	30 min	Moderate	Moderate	45 min
8	Distinctive	Mild	30 min	Not clear	Mild	45 min

## INFLAMMATORY SIGNS

Inflammatory signs were recorded on 3<sup>rd</sup>, 7<sup>th</sup>, 14<sup>th</sup> and 21<sup>st</sup> post operative day (POD) and were graded as mild, moderate and severe on the basis of cardinal signs of inflammation. (Table 12).

### Group II A

On 3<sup>rd</sup> day, inflammation was moderate in seven cases and mild in one case. On 7<sup>th</sup> post operative day, these signs were mild in five cases, while moderate in remaining three cases. On 14<sup>th</sup> and 21<sup>st</sup> post operative day, inflammation was mild in all the cases.

### Group II B

In 3<sup>rd</sup> day inflammation was moderate in four cases, severe in two cases and mild in two cases. On 7<sup>th</sup> post operative day, these signs were mild in four cases and moderate in remaining three cases. On 14<sup>th</sup> post operative day, inflammation was mild in six cases and moderate in two which continued to be same on 21<sup>st</sup> post operative day.

**Table 10: Evaluation of Inflammation in surgical technique.**

Case No./ day	GROUP IA( Foley Catheter)				GROUP II B (Dental mould)			
	3	7	14	21	3	7	14	21
1	Moderate	Mild	Mild	Mild	Moderate	Mild	Mild	Mild
2	Moderate	Mild	Mild	Mild	Mild	Mild	Mild	Mild
3	Moderate	Moderate	Mild	Mild	Moderate	Mild	Moderate	Moderate
4	Moderate	Moderate	Mild	Mild	Sever	Moderate	Mild	Mild
5	Mild	Mild	Mild	Mild	Sever	Moderate	Moderate	Moderate
6	Moderate	Mild	Mild	Mild	Moderate	Moderate	Mild	Mild
7	Moderate	Moderate	Mild	Mild	Moderate	Moderate	Mild	Mild
8	Moderate	Mild	Mild	Mild	Mild	Mild	Mild	Mild

### HEALING PATTERN

Healing of surgical wound was recorded on 3<sup>rd</sup>, 7<sup>th</sup>, 14<sup>th</sup> and 21<sup>st</sup> post operative day (POD) and was graded as good, fair and poor. (Table 13).

### Group II A

On 3<sup>rd</sup> POD healing was fair in five cases, poor in two cases and good in one case. On 7<sup>th</sup> post operative day this was good in five cases and fair in remaining three cases. On 14<sup>th</sup> post operative day healing was good in seven and fair in one case. On 21<sup>st</sup> POD healing was good in all the eight cases.

**Group II B**

On 3<sup>rd</sup> POD healing was fair in five cases, good in two cases and poor in one case, On 7th POD it was good in three cases while fair in remaining five cases. On 14th and 21<sup>st</sup> POD healing was good in all the cases except in two where it was fair.

**Table 11: Healing pattern in surgical groups at different intervals**

Case No./ day	GROUP II A ( Foley catheter)				GROUP II B (Dental mould)			
	3	7	14	21	3	7	14	21
1	Fair	Good	Good	Good	Fair	Good	Good	Good
2	Fair	Good	nGood	Good	Good	Good	Good	Good
3	Poor	Fair	Good	Good	Fair	Fair	Fair	Fair
4	Poor	Fair	Fair	Good	Poor	Fair	Good	Good
5	Good	Good	Good	Good	Fair	Fair	Fair	Fair
6	Fair	Good	Good	Good	Fair	Fair	Good	Good
7	Fair	Fair	Good	Good	Fair	Fair	Good	Good
8	Fair	Good	Good	Good	Good	Good	Good	Good

## DISCUSSION

## 5. DISCUSSION

The archaic anal sacs of the dog have no known function, however scent marking and anointing of territory is a well accepted behavioral pattern (Donovan, 1969). The anal sacs should be routinely checked, but unawareness of pet owners about the presence of glands or its disorders aggravate the condition.

Anal sac disease is common in dogs affecting approx 12% canine population and seen as impaction, sacculitis, abscessation and neoplasia. It has been proposed that the retained anal sac content causes severe cellulitis with abscess formation. Thus in present study, Tacrolimus (an immuno suppressive agent) has been used as therapeutic agent and compared with conventional antimicrobial and corticosteroid therapy. Surgical extirpation of anal sac remains as the only radical procedure, when anal sac impaction and sacculitis becomes recurrent, and in cases of perianal fistula and neoplasia.

Sacculotomy is not a popular procedure among Veterinarians because it is technically difficult, time consuming, and often followed by complication. Therefore the present study was designed to provide a rational medicinal therapy after diagnosing the condition, clinically and by ultrasonography. The effectiveness of the surgery has also been comparatively evaluated using dental mould material (alginate) and Foley balloon catheter as packing material to inflate the gland for identification during surgery.

### 5.1 Incidences

The study revealed anal sac disorder to be 16.1 per cent, out of 832 surgical cases of dogs attended in TVCSC during the period of study, out of which 16.30 per cent were males and 15.71 per cent were females. Study on the incidence of anal sac disorders is scarce in literature. Harvey (1974) diagnosed about 95 per cent of anal sac disease amongst animals with anal diseases. The present report is similar to the observations of Halnan (1975) and Van Duijkern (1995), who also reported, approximately 12 per cent canine population affected by anal sac diseases. The anal sac disorders were

recorded maximum 46-50% between the age of 9-12 years and above, while the incidence was less in young animals. Dakshinikar (2002), also reported that anal sac disorders were most prevalent in middle aged dogs, while Elkin and Hobson (1982) indicated that perianal fistulae also occur predominantly in middle aged dogs.

The anal gland does not serve any purpose in pet animals and infact became as a vestigial organ in domestic dogs. Because of home made soft food and gradual reduction of muscle tone owing to obesity, the frequent emptying of the sac does not take place which leads to anal sac disorders, especially in old age. The study revealed no sex predisposition in anal sac disorders. Harvey (1974), and Halnan (1976), also reported almost equal incidence in both the sexes. Robert and Bright (1995) stated that anal sac adenocarcinomas occur predominantly in old females between 5-17 years of age. Williams *et al.* (2003) reported an approximately equal sex distribution in 113 dogs which were histologically confirmed cases of carcinoma of apocrine glands of anal sac.

## **5.2 PRE-THERAPEUTIC PARAMETERS**

### **5.2.1 Diagnostic study**

#### **(A) Anamnesis and description of animals -**

Out of 32 selected cases of anal sac disorders for epidemiological study, 17 dogs were Pomeranian, 6 German shepherd, 6 non-descript and 3 apso. The incidence was noticed maximum in dogs with vegetarian feeding habits and the cases were of chronic nature with 1 month and above course of illness. The high incidence in Pomeranian breed may be attributed to, high number of Pomeranian visiting to TVCSC owing to the popularity of this small breed, followed by German shepherd and non-descript. Pet animals are usually fed on home made vegetarian diet which mostly comprises of soft food. Being luxative, it leads to easy evacuation of stool, thus not allowing the glands to squeeze. The unsqueezed gland leads to impaction and subsequent complications. The signs remains unnoticed in initial stage and pet owners remain unaware about the condition. With chronicity of the condition, the striking signs like scooting, licking, tenesmus,

straining during defecation are noticed frequently, leading the owner for pets veterinary checkup. Similar findings have also been stated by Wasrund (1999), who suggested that in ancient times, dogs ate large quantities of meat and bones, making faeces consistency hard.

#### **(B) CLINICAL OBSERVATION**

The clinical signs like scooting licking tenesmus perianal pain, pruritis, swelling and loose stool was observed on day zero in all the animals of both the group, Anal sacculitis being inflammatory condition causes swelling, which leads to perianal pain and tenesmus resulting to licking as also suggested by Hansen (1972) that an animal with impacted anal sac may rub the perineum on the ground, bite or chew at its rump and occasionally excoriate the skin aggravation of the anal area.

#### **(C) CONTENT OF ANAL SAC**

In majority of animal of both groups the contents were thick pasty in consistency with excessive quantity and yellowish colour on day 0. Similar observations were also made by Christie (1985), who stated that impaction is characterized by the accumulation of thick pasty secretion.

#### **(D) ULTRASONOGRAPHY**

The scanning features exhibited by 8 MHz real time B mode ultrasound machine were highly relevant with the clinical signs, and correlated by the characteristics of anal sac content expressed from the gland, after performing sonography.

Anal sacs are normally located at 5 and 7 o'clock position to the anus subcutaneously. When the transducer is placed transversely, just below the anus, at the above position normal anal glands appeared as two oval anechoic (dark) areas surrounded by thin normoechoic to hyperechoic outline, on either side of rectum. No reference of the ultrasonic structure of anal sac was available in the literature. Therefore the anechoic area of the sac was correlated with the anechoic area of distended urinary bladder, which is due to the presence of urine (fluid) as described by Nyland and Mattoon (1995). Christie (1985) stated that normal anal sac secretion is slightly granular liquid Ultrasonically normal anal glands after expression are not

identifiable, as the anechoic area diminishes to a very thin indistinct line as observed in collapsed urinary bladder.

In the present study sonographic examination of **impacted anal sacs** were observed as large anechoic to hypoechoic area surrounded by thick hyperechoic wall. It may be further graded as *severely impacted* when the content become inspissated giving an appearance of hypoechoic area with very thick hyperechoic wall, and *mild impacted* with, anechoic area having thick hyperechoic wall. Greiner *et al* (1983) characterized impaction by accumulation of thick pasty secretion in the anal sac, which appeared as hypoechoic area.

Sonographic examination of **sacculitis** revealed the infected anal sac as distended anechoic areas with hypoechoic to hyperechoic structures indicative of cellular debris. The wall of the gland was thick hyperechoic giving three layered appearance indicating inflammation of wall. Similar findings were observed by Gooding (1986) and Bhadwal (1997) in cases of cystitis where bladder wall gave three layered appearance on sonography.

**Anal sac abscess** was seen as clear hypoechoic area outlined by fibrous tissue lining seen as hyperechoic circular border. Konde *et al.* (1986), also suggested abscess as hypoechoic area with ill defined border or hyperechoic capsules. **Neoplasm** of the anal sac noticed in four cases represented a complex pattern showing combination of hyperechoic and hypoechoic or anechoic areas. Tumour was seen as hypoechoic area with hyperechoic striation in the vicinity of gland having poorly defined borders in one case, while other cases showed ill defined hyperechoic areas with hypoechoic patches (masses) indicative of tumour. Singh and Mohindroo (2007) in their study of tumours of urinary bladder also reported the nature of lesion as mixed, with hyperechoic and hypoechoic areas. Hyperechogenicity of the tumourous mass may be due to fibrous connective tissue and mineral deposition as described by Green (1996) who studied sonography of tumours in dogs.

## (E) BACTERIOLOGICAL EXAMINATION

The isolation and identification of bacteria on day 0 of the medicinal therapy in sixteen dogs of Group I revealed maximum samples to be suspected of *Proteus Vulgaris* 7 (43.7%) followed by *E Coli* 4 (25%), *Salmonella* 3 (18.7%) and *Pseudomonas sps* 2 (12.5%). These result are in accordance with the findings of Halnab (1976) who stated that bacteria flora involved in anal sac infection consist of *Micrococci*, *Diphtheroids*, *E Coli*, *Salmonella*, *Streptococcus faecalis*, *Clostridium Welchii*, *Staphylococcus*, *Pseudomonas* and *Proteus*. The result of present study are in contrast to the findings of Dakahinkar (2002) in which the highest percentage *Staphylococcus aureus* (54.54%) was isolated from anal sac infection in present study none of the samples (n=16), showed presence of *Staphylococcus aureus*.

Further, bacteriological examination of the anal sac contents on day 6, 10, and 15 indicated that Gram negative coccobacilli with similar cultural characteristic as on day 0 were present in the content of both the medicinal groups upto the day of presence of discharge. Thus in Group I A of Chloromphenicol, bacteria could be isolated only till day 10 in 3 cases while in Group I B of Tacrolimus bacterial isolates were observed upto day 15 of the treatment in 2 dogs indicative of persistence of infection, Thus indicating Chloromphenicol to be choice of drug in the therapy of anal sac disorders.

### 5.3 THERAPEUTICS STUDY

Therapeutics study was conducted to compare the response of two different medicinal treatment regimen, and surgical procedures in various anal sac disorders.

#### 5.3.1 MEDICINAL THERAPY

The study was conducted on 16 dogs, with anal sac disorders, divided equally into two sub groups. In group IA conventional treatment using antibiotic (Chloromphenicol) and corticosteroid (dexamethasone) was infused in impacted gland, while in group I B Tacrolimus ointment was infused in the gland. Recent success of medicinal treatment using immunosuppressive drugs

such as Prednisolone (Harking *et al.*, 1996) and Cyclosporin (Mathew and Sukjana, 1996) lend support to the hypothesis that perianal fistula may be an immune mediated condition.

Misseghers *et al.* (2000) in his study reported Tacrolimus, a relatively non immunosuppressive drug, 10-100 times more potent than cyclosporine, having fewer side effects, is effective when used topically and less expensive. Draznier (1985) suggested that an immune (probably cell mediated) reaction may take place within the anal sac causing severe cellulites with abscess formation with the concept that Tacrolimus may be effective against immune reaction as it was used for anal sac therapy.

Dakshinkar (2000) in his study of antibiogram of bacterial isolates of anal sac contents reported higher percentage (63.6%) of sensitivity to Chloramphenicol, therefore it has been used in the present work.

#### a. Clinical observation

The clinical signs observed on day zero in all the animals of both the group, which gradually declined and were almost mild to nil on day 10 to 15 in group IA. In animals of group IB, these signs declined comparatively less than in group IA on day 10 and remained mild till last day of observation i.e. day 15.

The Chloramphenicol with corticosteroids suppresses the infection and inflammation speedily which has been observed by relief from these signs on 5<sup>th</sup> to 10<sup>th</sup> day interval of observation.

Most of the cases of Group IB had furunculosis, perianal tumour and severe impaction, where Tacrolimus (immunosuppressive agent) was used. The immunosuppressive agent might not have directly acted upon infection and inflammation and also because of its slow mode of action. The response in this group was mild in comparison to Chloramphenicol and dexamethasone. Thus the relief from these symptoms was less as compared to group IA, on day 5 and 10. On day 15 in group IB the clinical signs subsided partially as the Tacrolimus therapy is advised for longer duration (two months) also as reported by (Misseghers *et al.*, 2000) who advocated

application of 0.1%. Tacrolimus ointment once to twice daily for 16 weeks can effectively manage perianal fistula in 50% cases and partial improvement in 40% cases. The persistence of sign on day 15 may also be attributed to the presence of condition like fistula and tumours upto day 15 of observation.

The pyrexia was observed only in one dog of group I A which responded well to the treatment and subsided by 5<sup>th</sup> day onwards. The pyotraumatic dermatitis and local discharge in the region were seen only in one animal of group I A and did not respond to Chloramphenicol and dexamethasone till day 15<sup>th</sup>. No specific treatment being used for dermatitis, Chloramphenicol and dexamethasone were used locally in the gland therefore appropriate response was not noticed upto 15<sup>th</sup> day of observation in this case.

#### **b. Content of anal sac**

In majority of animal of both groups the contents were thick pasty in consistency with excessive quantity and yellowish colour on day 0. Similar observations were also made by Thomas *et al* (1983), who stated that impaction is characterized by the accumulation of thick pasty secretion. The consistency became thin pasty in 3 and viscous in 2 dogs, while no discharge was noticed in 3 animals of group I A. The quantity reduced from moderate to scanty with creamish yellow colouration on 5<sup>th</sup> day of observation. In the later period of observation (day 10<sup>th</sup>), the consistency was viscous, with scanty and brownish discharge, indicative of normal secretion as also reported by Horney and Archibald (1975) and Mathiesian and Marretta (1993), which further remained absent on 15<sup>th</sup> day of observation.

In animal of Group, I B the nature of discharge showed almost the similar response from day 0 to day 10<sup>th</sup>, however on 15<sup>th</sup> day of observation the presence of viscous scanty grayish brown discharge was still noticeable. The manual expression of sac followed by flushing with povidone iodine and instillation of Chloramphenicol and dexamethasone causes suppression of infection and inflammation thus the colour and consistency of the anal sac content decline towards normalcy and was scanty or absent on 15<sup>th</sup> day.

In group IB presence of anal sac content till 15<sup>th</sup> day of treatment may be attributed to incomplete expression of the glands owing to the presence of fistula and tumours. Walshaw (1983), reported that severe pain is exhibited by patient during the examination of perianal region, if abscessation is present.

#### c. Sonography

Ultrasonographic examination of anal sacs were seen as anechoic oval areas with hyperechoic outline. On 0 day of medicinal therapy conditions were diagnosed as heavily impacted, mild impacted, showing severe sacculitis; mild sacculitis with tumours in 4 cases.

After expression of the glands the anechoic or hypoechoic anal sac area reduces greatly thus the identification becomes difficult. The thickness of the hyperechoic wall reduces to normalcy as infection/inflammation subsides following therapy as is evident in case of collapsed urinary bladder.

#### d. Bacteriological examination

Bacteriological examination of anal sac content was done on day 5, 10 and 15 of the medicinal therapy group. The indicated presence of bacterial colonies indicated persistence of infection.

### 6.3.2 SURGICAL THERAPY

Anal sac ablation is the ultimate remedy for neoplasia and recurring anal sac impaction or infection / abscessation, as well as adjunctive surgical treatment for perianal fistula. (Walshaw, 1983 and Marretta, 1992). In dog of surgical group clinical signs predominated as drainage, perianal pain, pruritis and swelling because the involved cases had either fistula, tumour or chronic recurrent impaction and sacculitis. Clinical and Bacteriological examination of anal sac contents in surgical cases had no relevance as sacculotomy removes the root cause (anal sac) of all the disorders. However on ultrasonography of the cases impaction sacculitis and perianal tumours were differentially diagnosed before undertaking surgery. Johnston (1985) in a study of 106 dogs with perianal fistulas reported ruptured anal sacs in 86 dogs



## **Haemorrhage**

The clear turgid demarkation of the sac outline by Foley catheter leads to minimal soft tissue damage causing mild to moderate haemorrhage as compared to Dental mould material.

## **Duration of operation**

The result of the study revealed that the average time required for unilateral anal sacculotomy by using Foley balloon catheter was 32 min, as compared to 48 min in technique using dental mould material. Foley balloon catheter does not require any preinstillation preparation. Sterilized catheter tip is lubricated and introduced inside the duct of the anal sac after the expression of the content and the balloon is inflated with 4-5 ml distilled water. Thus the catheter becomes fixed inside the sac. Dental mould material on the other hand requires pre-instillation preparation. The dental mould paste formed by mixing 4-5 gram Alginate powder in distill water should be of appropriate consistency. If, it is too thick then instillation becomes difficult, as it settles in the syringe or in the duct itself and if very thin the material may come out of the sac and obscure the field of surgery, thus increasing the total duration of operation.

In the present study, in two cases, in which there was fistula with rupture of anal sac, where dental mould material would have leaked out into the subcutaneous space, yet Foley balloon catheter was able to distend the sac.

Accidental rupture of the balloon of Foley catheter inadvertently with the anal sac during the surgery did not contaminated the surgical field because distill water/sterile saline solution was used to inflate the balloon. The catheter is relatively inexpensive, as it can be reused in several patients after sterilization. Thus Foley catheter effectively identify the gland and is a better packing material as compared to Dental mould, which can be used effectively in field.

Hill and Smeak (1994) studied open versus closed bilateral anal sacculotomy for the treatment of non-neoplastic anal sac disease in 95 dogs and suggested standard open technique to be associated with greater number.

of complications. Different packing material like Acrylic resin (Taylor and Cheswat, 1962), Silicon sealant (Frye *et al*,1970), Plaster of Paris or cotton (Horney and Archibald 1974)); Dental impression material (Pickens, 1977, Tigari, 1988 and Rangnath *et al.*, 1992), distilled water and Indian ink (Tuntivanich, 1983), Acrylic mixture (Woodard, 1983), coloured thread or melted paraffin (Christie, 1985), have been used but all have their drawbacks. A report of study on 4 cases of anal saccullectomy using balloon of Foleys catheter is indicated by Downs and Stampley (1998).

#### **(ii) DEGREE OF INFLAMMATION**

On the basis of cardinal signs, post operative inflammation was graded as mild, moderate and severe as observed on day 3,7,14 and 21.

In group IIA (Foley balloon catheter) inflammatory signs recorded were mild to moderate initially, which reduced to mild on day 14 while in group IIB (dental mould material),the signs of inflammation were moderate to severe on day 3 which declined to moderate in majority of dogs on day 7 and reduced further with only 2 dogs showing moderate inflammation on 21<sup>st</sup> day.

The difference in the degree of inflammation may be attributed to more soft tissue damage and greater haemorrhage in dental mould material group as compared to Foley balloon catheter group.

#### **(iii) ASSESSMENT OF HEALING PATTERN**

Healing was assessed as good, fair and poor. Good healing was observed in dogs, which were docile and cooperative with good post operative care of dog. Healing was fast and satisfactory in all the cases of group IIA (Foley balloon catheter) as compared to group IIB (dental mould material). Few owners were not able to prevent the dogs from licking, thus causing disruption of skin sutures. Christie (1985) suggested to avoid subcutaneous suture during saccullectomy because of the rapid healing properties of anorectal area, prevents seroma formation and related wound complication, however Horney and Archibald, (1975) further suggested that after complete removal of the sac, the skin incision may be left open to heal by granulation in 5-7 days. This supports the faster healing rate even in cases of disrupted skin sutures.

**SUMMARY, CONCLUSIONS AND**  
**SUGGESTIONS FOR FURTHER WORK**

## 6. SUMMARY CONCLUSIONS AND SUGGESTIONS FOR FURTHER WORK

### 6.1 Summary

The archaic anal sacs are paired organs located beneath the skin and anal sphincter muscles at about five and seven o'clock positions surrounding the rectum. Most of the dogs can empty these glands voluntarily for scent marking or in self defence. In pet dogs the rarely emptied sacs fill up with fluid, which solidifies and becomes an ideal environment for bacterial growth. Disorders of the anal sacs include impaction, infection, abscess and neoplasia. Anal sac impaction and anal sacculitis are often treated conservatively by gentle expression of the anal sac. Severe anal sacculitis may require instillation of antibiotics and corticosteroid. Anal sacculotomy is indicated in recurrent impaction, anal sacculitis, anal abscesses and tumours. It can be performed by open or closed methods. No thorough and systematic research work is traceable in the literature, therefore, the present work was designed to study the incidence, diagnosis and efficacy of medicinal and surgical treatment of anal sac disorders in dogs.

The present study was conducted on 32 clinical cases of dogs irrespective of sex, age and breed. These animals were divided into two equal groups, for Medicinal (I) and Surgical (II) therapy, on the basis of diagnostic tool i.e. anamnesis, clinical observation, clinical examination of content, sonography and bacteriological evaluation of the anal sac content. Dogs showing sign of impaction, sacculitis, and anal abscess were subjected to medicinal therapy and were further divided into two equal groups (A and B) of 8 dogs each. In Group I A the anal glands were expressed and flushed with povidone iodine followed by infusion of Chloramphenicol (100 mg/ml) 0.5-1.0 ml and Dexamethasone (4 mg/ml) 0.5-1.0 ml, while in Group I B Tacrolimus ointment (0.1%) was infused. In Group II A sacculotomy was performed for recurrent conditions and tumours using Foley catheter, while Dental mould was used in Group II B.

During the period of study out of the total surgery OPD cases 16.1% were the cases of anal sac disorders. No sex predisposition was noticed in anal sac disorders.

On clinical examination of anal sac content, thick pasty yellow content was observed in heavily impacted gland while thin pasty dark brown content was seen in severe sacculitis which became normal in all the cases of Group I A while in Group I B discharge was still persisted in four dogs.

Ultrasonography of the normal anal sac appeared as 2 oval anechoic areas surrounded by thin hyperechoic outline indicative of sacs on either side of rectum. Impaction and sacculitis could be differentially diagnosed as hypoechoic areas surrounded by thick hyperechoic outline in case of Impaction, while three hyperechoic layered outline with hypoechoic patches in anechoic area were seen in sacculitis. On the other hand anal sac abscess were differentially diagnosed as hypoechoic area outlined by thick hyperechoic circular band, indicated abscess, while tumours were seen as complex pattern having hyperechoic areas with hypoechoic masses.

The isolation and identification of bacteria on day 0 of the medicinal therapy in sixteen dogs of Group I revealed maximum samples to be suspected of *Proteus Vulgaris* 7, followed by *E Coli* 4, *Salmonella* 3 and *Pseudomonas sps*

The results revealed that clinical and bacteriological examination of the anal sac content and sonography of the anal sac is a better differential diagnostic tool for anal sac disorders.

The assessment of medicinal therapy was carried out on the post treatment day (0, 5, 10 and 15) on the basis of disappearance of clinical signs (scooting, licking, discharge, pain, tenesmus, swelling, tail chasing and fever), clinical examination of content, sonographic observation and bacteriological examination. The results revealed chloramphenicol dexamethasone therapy to be superior to Tacrolimus.

A comparative assessment of the two surgical techniques was done on the basis of identification of gland, ease, duration of operation and complications during and after the operation, study revealed that Foley

catheter provides better identification, requires less operative time and had more ease of operation as compared to dental mould material and can be easily adopted under field condition.

The study was concluded with the following parting words, anal sac disorders affects 50 per cent of pet dogs above the age of 5 years, without any sex discrimination. Sonography was used for the first time in diagnosing anal sac disorders successfully. Chloromphenicol is a better choice of drug for impaction and sacculitis, but the role of Tacrolimus in fistula and tumours can't be ignored. Foley balloon catheter seems to be the best packing material for sacculotomy. Sacculitis and impaction can be easily treated by medicinal therapy, while recurrent episode of the foresaid, tumours and fistula requires surgery.

## 6.2 CONCLUSION

On the basis of the result obtained in the present study it is concluded that:

1. The incidence of anal sac disorders in dogs is 16.1% of total surgical OPD cases. It is seen in both the sexes equally, affects 50 % dogs of age above 6 years.
2. Sonography was used for the first time in anal sac disorders successfully. It could be effectively used for differential diagnosis of conditions like impactions, sacculitis, tumours and abscess of anal sac.
3. Chloramphenicol is the treatment of choice in impaction & sacculitis; however Tacrolimus is helpful in fistula & tumour.
4. Foley catheter seems to be superior packing material and can be used for sacculectomy successfully.
5. For sacculitis and impaction medicinal therapy is effective, while for recurrent impaction, sacculitis, tumour and fistula surgical therapy is required.

## REFERENCES

## REFERENCES

- Anderson, R.K. (1984). Anal sac disease and its related dermatoses. *Comp Cont Ed* 5:829.
- Anderson, G.I. (1987). Rectal resection in the dog, A new surgical approach and the evaluation of its effect on fecal continence. *Vet. Surg.*, 16: 119.
- Ashdown, R.R. (1968). Symposium on canine recto-anal disorders-I : Clinical anatomy. *J. Small Anim. Pract.* 9:315.
- Baker, E. (1962). Diseases and therapy of the anal sacs of the dog. *J. Am. Vet. Med. Assoc.*, 141:1347.
- Bhadwal, M. S. (1997). Ultrasonographic studies on characteristics of abdominal organs, tendons and joints in health and disease in dog. Ph. D. Thesis, Punjab Agricultural University, Ludhiana, India.
- Christie, T.R. (1985). Anal Sac and Perianal Fistula Disease. In: I.M. Gourley and P.B. Vasseur General Small Animal Surgery., Publ. J. B. Lippincott Company, Philadelphia : pp 403-410.
- Cruickshank, R., J.P. Duguid, B.P. Marimon and R.H.A. Swain (1975). Medical Microbiology. 12 edn, Publ. Churchill and Livingstone, Edinburgh, London and NY pp 3142.
- Dakshinkar, N. P. (2002). Medical Management of Anal Sac disease in Dog. *Infra polivet.*, 301: 341-343.
- Donovan, C.A. (1989). Canine anal glands and chemical signals (Pheromons). *J.A.V.M.A.* 165: 1995.
- Doty, R.L. and I. Dunbar, (1974). Color, odor, consistency, and secretion rate of anal sac secretions from male, female, and early-androgenized female Beagles. *American Journal of Veterinary Research.*, 35(6): 729-731.
- Downs, M.O. and A.R. Stampley (1999). Use of a Foley catheter to facilitate anal sac removal in the dog. *J. Am. Anim. Hosp. Assoc.* 34 (5): 395-397.
- Drazner, F.H. (1985). Colon Rectum and Anal canal. In: I.M. Gourley and P.B. Vasseur General Small Animal Surgery., Publ. J. B. Lippincott Company, Philadelphia pp 385-401.
- Elkins, A.D. and H.P. Hobson (1982). Management of perianal fistulae a retrospective study of 23 cases. *Veterinary Surgery.*, 11(3): 110-114.
- Emms, S.G. (2005). Anal sac tumours of the dog and their response to cytoreductive surgery and chemotherapy. *Aust Vet J.*, 83 (6):340-343.
- Frye, F.L., D.J. Hoeft, J. P. Cucuel, and R.J. Hardy (1970). Silicone sealant for preoperative packing of canine anal sacs. *J. Am. Vet. Med. Assoc.*, 156:1030.
- Gensch, D. K. Neurand, (1973). Topography and histology of the glands of the anal region of the dog *Zentralblatt für Veterinärmedizin.*, 2(3): 280-294.

- Gooding, G. A. W. (1986). Varied sonographic manifestations of cystitis; *J. Ultrasound Med.*, 5: 61.
- Goud, M. B., E.L. Chandrasekhar and V. Haragopal (2002). Experimental studies on ablation of anal sacs in dogs; *Indian J. Vet. Surg.*, 23(2): 108-109.
- Green, R. W. (1996). Small Animal Ultrasound. Publ. Lippincott R. William & Wilkins, Inc. Philadelphia. p 367.
- Grelner, T.P., T.G. Johnson and C.W. Butts (1983). Disease of Rectum and Anus. In Text book of Veterinary internal medicine Disease of the dog & cat. S.J. Roberts Publ. W.B. Saunders Co. Philadelphia pp 1493-1521.
- Halnan, C.R.E. (1973). The diagnosis of anal sacculitis in the dog, and The frequency of occurrence of anal sacculitis in the dog. *Small Ani. Pract.*, 17 (8): 527-541.
- Hansen, J.H. (1972). A visual aid for clients the problem of anal sacs in dogs; *Veterinary Medicine/Small Animal Clinician* 67(2): 143-147.
- Harkin, K.R., R.W. Waishaw and T.P. Mullarney (1996). Association of perianal fistula and colitis in the German shepherds dog, response to high dose Prednisone and dietary therapy. *J. Am. Anim Hosp. Assoc.* 33: 515-520.
- Harvey, C.E. (1974). Incidence and distribution of anal sac disease in the dog. *J. Am. Anim Hosp. Assoc.* 10(6): 573-577.
- Hill, L.N. and D.D. Smeak (1994). Open versus closed bilateral anal sacculotomy for treatment of non-neoplastic anal sac disease in dogs. *J. Am. Vet. Med. Assoc.*, 221 (5): 662-665.
- Hobday, S. (1853). Obstruction of the anal glands. Hobday's surgical disease of the dog 4<sup>th</sup> Ed. James McCunn. Bailiere Tindal and Cox, 7 and 8 Henrietta Street. W.C. 2:249-250.
- Horney, F.D. and J. Archibald (1974). Colon, rectum and anus. In: Archibald J, ed. Canine surgery. Santa Barbara: American Veterinary Publications: 803-28.
- Hummel, P.H. K. Kohne, and S. Weiskopf. (1998). Use of clindamycin for the treatment of chronic wound infections, interdigital pyoderma and anal sac infections in dogs and cats. *Praktische-Tierarz.* 79(8): 718-726.
- Johnston, D.E. Rectum and anus. In: Slatler D, ed. Textbook of small animal surgery. Philadelphia: WB Saunders, 1985:770-94.
- Kenawy, A.A., A. Karkoura, M.M. Kassam, and M.A. Anwar (1995). Surgical and anatomical studies on the perineal region of the dog with special reference to extirpation of the anal glands. *Assiut Veterinary Medical Journal*; 33(66): 143-153.
- Komar, G. (1989). Non-surgical treatment of anal sac disorders in dogs. *Magyar-Allatorvosok-Lapja.* 44(2): 105-106.
- Konde, L. J., R. D. Park, R. H. Wrigley and J. L. Lebel (1986). Comparison of radiography and ultrasonography in the evaluation of renal lesions in the dog. *J. Am. Vet. Med. Assoc.* 188 (12): 1420 -1425.

- Lake, A. M., D. W. Scott, W.H. Miller and H. N. Erb (2004) - Gross and cytological characteristic of normal canine anal sac secretions. *J. Vet. Med. A Physiol Pathol Clin. Med.*, 51(6): 249-253.
- Loewenstein, C., M.D. Loewenstein, and J. Bertling, (1988). Electrocoagulation - a method of treatment for chronic anal sac inflammation, and its morphological changes *Kleinierpraxis.*, 33(11): 483-486.
- Manfra Marretta S. (1992) Anal sac removal. In: Sojrab JM, ed. Current techniques in small animal surgery. Publ. Philadelphia: Lea & Febiger, pp 270-274.
- Markowitz, J., J. Archibald and H.G. Downie (1959). Anal gland removal. Experimental surgery including surgical physiology. IV<sup>th</sup> Ed. Publ. The Williams and Wilkins Company pp 118-120.
- Mathews, K.A. and H.R. Sukaina (1996): Cyclosporine treatment of canine perianal fistulas, a prospective randomized double blind controlled study, abstract of the 31<sup>st</sup> Annual American College of Veterinary Surgeons Scientific Meeting San Francisco, 15-16.
- Matthieson D.T., and S.M. Marretta. (1993). Disease of the anus and rectum In: D. Slater, ed. Textbook of small animal surgery, Vol.1 Philadelphia: WB Saunders, Co. - pp 627-844.
- Meeks R.A. (1975). Anal sac infection in a dog as the possible cause of chronic staphylococcal infection in a family. *Veterinary Medicine/Small Animal Clinician* 73(5):580.
- Missegheers, B.S., A.G. Birnington and K.A. Mathews (2000). Clinical observation of the treatment of canine perianal fistulas with topical tacrolimus in 10 dogs. *Can. Vet. J.* 41(8): 623-627.
- Nyland, T.G. and J.S. Matton (2002). Small animal diagnostic ultrasound - In: 2nd edn. Publ. W. B. Saunders Co. Philadelphia, p46.
- Pappalardo, E., P. A. Martin and C. Noll (2002). Macroscopic, Cytological and Bacteriological evaluation of anal sac content in normal dogs and with selected dermatological disease. *Vet. Dermatol.*, 13 (6): 315-322.
- Pickens, G.E. (1977). A simple procedure for removal of canine anal sacs. *Veterinary-Medicine and Small Animal Clinician.* 72(9): 1454-1459.
- Rangnath B.M., L. Rangnath, Madhu Rao, C. Srinivas and S.M. Jaydevappa (1992). Use of dental mould in anal sac ablation. *Livestock advisor* 27(5):25-26.
- Rawling, C.A. (1979). Anal sac extraction. Small Animal Surgery. An atlas of operative technique. W.B. Saunders Company, Philadelphia London pp 105.
- Roberts, C.D. and R.M. Bright (1995). Recto-anal Disease. In: text book of Veterinary Internal Medicine diseases of the dogs and cat Ed. S.J. Ettinger Publ. W.B. Saunders Company Philadelphia, pp 1257-1270.
- Robson, D. C., G. G. Burton and M. F. Lorimer (2003) Cytological examination and Physical characteristic of the anal sacs in 17 clinically normal dogs. *Aust. Vet. J.* - 81 (1-2): 36-41.

- Singh, A. and J. Mohindroo (2007). Ultrasonographic and radiographic diagnosis of canine urinary bladder neoplasia. *Indian J. Vet. Surg.* 28(1) : 43-45.
- Taylor, D.C. and A.T. Chesworth (1962). The use of acrylic resins in anal gland resection. *Vet Rec*: 74:843.
- Tisdoll, P.L.C; G.B. Hunt, J.A. Beck, and R. Malik. (1995). Management of perianal fistulae in five dogs using azathioprine and metronidazole prior to surgery. *Australian-Veterinary-Journal.* 77(6): 374-378.
- Trigari, M. (1958). A Simple, clean method for the surgical ablation of anal sacs in the Dogs. *Vet. Rec.*, 123 (14) : 365-366.
- Tunivanich P. (1983) Distilled water compared to India ink as a packing medium for canine anal sacs. *Vet Med Sm Anim Clin*, 78:1400-1.
- Unsalı, E., S. Bulut, A.S. Durmus, and M. Kom, (1999). Using acrylic in the experimental extirpation of anal sacs in dogs *Sagık Bilimleri Dergisi, Fırat Universitesi.*, 13(2): 127-130.
- Van Duijksteren E. (1995) Disease conditions of the canine anal sacs. *J Sm Anim Pract*, 36:12.
- Walshaw, R., (1983). Removal of Anal sac disease. *In* Bojrab MJ(ed) Current Technique in Small animal Surgery, Publ. Lea and Febiger Philadelphia pp 196-201.
- Wasmund, (1999). Anal sac Disease Scooting. The pet stuff online News letter. 1 (9)
- Williams, L.E., J.M. Gilatto, R.K. Dodge, J.L. Johnson, R.M. Gamblin, D.H. Thamm, S.E. Lana, M. Szymkowski, and A.S. Moore, (2003) *Journal of the American Veterinary Medical Association.*; 223(6): 825-831.
- Woodard, D.C. (1983) Use of acrylic mixture in anal sac removal. *Vet Med Sm Anim Clin*, 78:1399-1400.

## VITAE

The author, Pooja Gupta was born on 11<sup>th</sup> November 1972 at Jabalpur (M.P.). She passed High School Certificate Examination in 1988 from Christ Church Girls Senior Secondary School Jabalpur (M. P.), with first division and 12<sup>th</sup> in 1990 from the same school with first division. She joined B. V. Sc. & A. H. in the year of 1992 in College of Veterinary Science and Animal Husbandry, Jabalpur (M. P.) and completed her degree in 1997 with first division. During this tenure she was class representative for two years. She got selected for the post of Veterinary Asst. Surgeon in 1999 in M. P. Government. During her service period she joined M. V. Sc & A. H. in 2005 in the Department of Veterinary Surgery and Radiology, College of Veterinary Science and Animal Husbandry, Jabalpur (M. P.) as a regular student. She is a life member of the Indian Society for Veterinary Surgery (ISVS) and JVC Alumni Association.