

College Library

**CLINICAL AND RADIOLOGICAL
EVALUATION OF FRACTURES IN
GOAT (*Capra hircus*)**

बकरियों (केपरा हिरकस) में अस्थिभंग का शयनिक
एवं क्षःरश्मिक मूल्यांकन

Sharad Arora

THESIS

**MASTER OF VETERINARY SCIENCE
(VETERINARY SURGERY AND RADIOLOGY)**



1996

**Department of Veterinary Surgery and Radiology
College of Veterinary and Animal Science
Rajasthan Agricultural University
BIKANER-334001**

**CLINICAL AND RADIOLOGICAL
EVALUATION OF FRACTURES IN GOAT
(*Capra hircus*)**

A THESIS

PRESENTED TO
THE FACULTY OF VETERINARY AND ANIMAL SCIENCE
RAJASTHAN AGRICULTURAL UNIVERSITY
BIKANER

IN THE PARTIAL FULFILMENT OF
THE REQUIRMENTS FOR THE DEGREE OF
MASTER OF VETERINARY SCIENCE
(*Veterinary Surgery and Radiology*)

BY

SHARAD ARORA
B.V.Sc. & A.H.

1996

RAJASTHAN AGRICULTURAL UNIVERSITY
BIKANER
COLLEGE OF VETERINARY AND ANIMAL SCIENCE, BIKANER

CERTIFICATE - I

Dated : 10.7., 1996

This is to certify that Dr. SHARAD ARORA has successfully completed the COMPREHENSIVE EXAMINATION held on 3rd July 1996 as required under the regulations for the degree of MASTER OF VETERINARY SCIENCE.



(Dr. D. S. Chouhan)

Head

Department of Veterinary Surgery and Radiology,
College of Veterinary & Animal Science,
Bikaner-334 001

RAJASTHAN AGRICULTURAL UNIVERSITY
BIKANER
COLLEGE OF VETERINARY AND ANIMAL SCIENCE, BIKANER
CERTIFICATE - II

Dated : 10.7.96

This is to certify that the thesis entitled, "CLINICAL AND RADIOLOGICAL EVALUATION OF FRACTURES IN GOAT (*Capra hircus*)", submitted for the degree of MASTER OF VETERINARY SCIENCE in the subject of VETERINARY SURGERY AND RADIOLOGY to the RAJASTHAN AGRICULTURAL UNIVERSITY, BIKANER embodies bonafide research work carried out by Dr. SHARAD ARORA, under my guidance and supervision and that no part of this thesis has been submitted for any other degree. The assistance and help received during the course of investigation have been fully acknowledged. The draft of the thesis was also approved by the advisory committee on 13 June, 1996.



(Dr. D. S. Chouhan)


Head

Department of Veterinary
Surgery and Radiology



(Dr. T. K. Gahlot)

Major Advisor



College of Veterinary &
Animal Science, Bikaner-334 001.

RAJASTHAN AGRICULTURAL UNIVERSITY

BIKANER

COLLEGE OF VETERINARY AND ANIMAL SCIENCE, BIKANER


CERTIFICATE - III

Dated: 3.9.1996.

This is to certify that the thesis entitled, "CLINICAL AND RADIOLOGICAL EVALUATION OF FRACTURES IN GOAT (*Capra hircus*), submitted by Dr. SHARAD ARORA to the RAJASTHAN AGRICULTURAL UNIVERSITY, BIKANER in partial fulfillment of the requirements for the degree of MASTER OF VETERINARY SCIENCE in the subject of VETERINARY SURGERY AND RADIOLOGY after recommendation by the external examiner was defended by the candidate before the following members of the examination committee. The performance of the candidate in the oral examination of his thesis has been found SATISFACTORY, we therefore recommend that the thesis be approved.



Dr. D.S. Chouhan
Head
Department of Veterinary
Surgery and Radiology



(Dr. T.K. Gahlot)
Major Advisor

(Dr. N.R. Purohit)
Advisor

Dean
Post Graduate Studies
Rajasthan Agricultural University,
Bikaner -334001



(Dr. S.S. Sharma)
Advisor

APPROVED

Approved
Dean Post Graduate Studies
DEAN
Post Graduate Studies
Rajasthan Agriculture University
BIKANER (RAJ.)
6/9/96

(Dr. P.R. Kothari)
Dean, PGS Nominee

ACKNOWLEDGEMENTS

I wish to express my deepest sense of gratitude and indebtedness to my advisor **Dr. T.K.Gahlot**, Assistant Professor, for his invaluable and timely guidance, moral support, constant inspiration and untiring endeavour at every step of this project. The scientific photography of radiographs by his personal camera while utilizing his rich photographic experience has helped greatly in compilation of various fractures of bones during the course of study.

I have no words to express my deep sense of gratitude to **Dr.D.S.Chouhan**, Professor and Head, for his expertised advise, constant inspiration and providing all the facilities during the course of study.

Sincere thanks are due to the Dean, College of Veterinary and Animal Science, for providing the necessary facilities during the course of study.

I am grateful to Dr. N.R.Purohit, Associate Professor, Department of Surgery and Radiology and Dr. S.S.Sharma, Professor and Head, Department of Obstetrics and Gynaecology for their constant supervision and encouragement as a member of advisory committee, during the course of study.

My sincere gratitude shall always remain for Drs. R.J.Choudhary, P.R.Dudi and (Mrs.) C.K.Sharma, Assistant Professor, Department of Surgery and Radiology for their constant inspiration, cooperation and valuable suggestion at various stages of the research work.

The help extended by Drs. Deepak Gupta, C.S.Bhatnagar, B.Bhardwaj, A.Juneja, M.Mathur, S.Saini, J.D. Parrah, H.Gupta, A. Swaroop, H.R.Choudhary, F.Akthar, S.Khare, Miss S.Srimali, D.Rana and P. Saraswat during the course of research is gratefully acknowledged.

The work would have been incomplete without assistance and cooperation of Shri N.S.Rathore, Technical Assistant, Shri G.B.Mehta, Lab technician and Shri Kailash, Ramlal, Sohanlal, Kishan Lal and Pinky Bai, non-technical staff of Department of Surgery and Radiology.

Financial support provided by Department of Science and Technology is duly appreciated.

I am highly indebted to my parents for their all time inspiration, affection and moral support for perusing the higher study. No lesser appreciation are deserved by my wife Sadhna and daughter Poonam for their patience during the lonely moments and strong moral support provided to me during the course of study.

"Camel Computers" is an important phase of my career. It has not only accomplished my thesis work but has given me the opportunity to learn the handling of various softwares which otherwise would have taken years to learn. My salutations shall always remain to Camel Computers.

Lastly, I shall be failing in my duties if sincere gratitude are not expressed to hundreds of goat owners who brought their animals for a periodical radiographic and clinical check up, which enabled me to accomplish this study.

SHARAD ARORA

LIST OF CONTENTS

	Page No.	
	←-----→	
	From	To
1. INTRODUCTION	1	4
2. REVIEW OF LITERATURE	5	45
3. MATERIAL AND METHODS	46	51
4. RESULTS AND DISCUSSION	52	86
5. SUMMARY	87	89
6. BIBLIOGRAPHY	90	100
7. APPENDIX	101	135

LIST OF TABLES

Table No.	Contents	Page No.
1.	Radiographic factors used for lateral or dorsopalmar/planter views for various bones.	48
2.	Clinical signs of fractures recorded for various bones.	66
3.	Sex wise classification of fractures of various bones in the animals of group A.	130
4.	Age wise distribution of fractures of various bones in animals of group A.	130
5.	Limb wise classification of fractures of various bones in the animals of group A and B.	131
6.	Classification of fracture line of various bones of group A.	132
7.	Various types of treatment adopted for the fractures of animals of group A.	133
8.	Results of external fixation treatment adopted for the various fractures in the animals of group A.	134
9.	Results of internal fixation treatment adopted for the various fractures in the animals of group A.	134
10.	Incidence of fractures of various bones of animals of group B.	135

LIST OF FIGURES

Figure. No.	Contents	Page No.
1.	Lateral radiograph of healed fracture of upper extremity of femur immobilized by double intramedullary pinning and cerclage wire (8 weeks).	101
2.	Right: Lateral radiograph of femur with fracture of mid-shaft immobilized by single intramedullary pinning and cerclage wire. Left: healed fracture showing large callus after one month.	101
3.	Lateral radiograph of fracture of neck of femur.	102
4.	Lateral radiograph of femur, the transverse fracture being immobilized with double intramedullary pinning.	103
5.	Left: Lateral radiograph of femur showing callus formation around fracture site after 1 month. Right: Lateral radiograph showing migration of pin through distal extremity after 45 days (same animal as figure 4).	103
6.	Right: Lateral radiograph of the same animal after 2 months showing completely healed fracture with only pin. Left: radiograph after 75 days showing distal migration of the second pin and complete obliteration of fracture line.	104
7.	Left: Lateral radiograph of oblique fracture of upper extremity of femur (Note the longitudinal splitting in the upper fragment). Right: Splitting of the upper fragment after single intramedullary pinning.	104
8.	Lateral radiograph of long oblique fracture of femur in a adult goat before and after immobilization with double intramedullary pinning and double cerclage wire.	105
9.	Right: Lateral radiograph of oblique mid-shaft fracture of femur. Left: healed fracture after one month (Note: pin was migrated out from distal extremity).	105
10.	Lateral radiograph of a healed fracture of femur showing impaction of lower fragment into upper one.	106

11. Lateral radiograph of multiple fracture of upper extremity of femur. 107
12. Lateral radiograph of multiple fracture of femur in a kid immobilized by single intramedullary pinning with pin driven more into distal cortex causing its migration through distal extremity after 5 days resulting in non-union. 108
13. Right: Lateral radiograph of a undisplaced fracture of humerus in a kid. Middle: Healing fracture after 2 weeks immobilized by Thomas splint. Left: Large callus after 3 weeks. 109
14. Lateral radiograph of the fracture of humerus immobilized with single intramedullary pinning. 109
15. Lateral radiographs showing various types of fracture lines of humerus fracture. 110
16. From Right to left : Lateral radiograph of transverse fracture of mid-shaft of humerus. Immobilized by single intra-medullary pinning showing lateral deviation of fracture fragment. Healing fracture after two weeks of immobilization showing callus formation. Completely healed fracture after 4 weeks. 110
17. Lateral radiograph of fracture of humerus immobilized by double intramedullary pinning. 111
18. Right: Completely healed fracture after 2 months. Left: Remodeling of the bone after 5 months with retention of pins. 111
19. Lateral radiographs of different types of fractures of the tibia. 112
20. Right to left: Lateral radiograph of different types of fractures of upper extremity of tibia. Extreme left: A.P and Lateral radiograph of fracture of upper extremity of tibia. 112
21. Lateral radiograph of a case of bilateral fracture of tibia in a 10 days old kid. 113
22. Lateral radiograph of different types of fracture of tibia. 113
23. Lateral radiograph of healed fracture of tibia showing malunion 4 weeks. 114
24. Lateral radiograph of healed fracture of tibia showing union in 3 weeks. Fracture line is still visible. 114
25. Lateral radiograph of a healed compound fracture of 115

tibia in 10 weeks and malunion of fracture of shaft of tibia.

26. Left: Lateral radiograph of upper extremity tibia fracture in a buck. Right: Fracture one month after immobilization with plaster of Paris cast showing healing. 116
27. Lateral radiograph showing various types of fracture of metatarsals. 117
28. Lateral radiograph showing various types of fracture of metacarpals. 117
29. Lateral radiograph of transverse fracture of metatarsal showing perfect immobilization with plaster of Paris cast. 118
30. Lateral radiograph showing transverse fracture of metatarsal and its healing with slight malunion in 4 weeks. 119
31. Lateral radiograph of distal extremity of metatarsal and its immobilization by plaster of Paris cast. 120
32. Lateral radiograph of an oblique fracture of mid-shaft of metatarsal and its perfect healing after 4 weeks with plaster of Paris cast. 121
33. Lateral and antero-posterior views of radiograph showing various types of fracture of metacarpals. 122
34. Lateral radiograph of transverse fracture of metacarpal before immobilization, after one week, two week and after opening of the plaster of Paris cast 3 weeks later. Note fracture line is still visible. 122
35. Lateral radiograph of a chip fracture of metacarpal and its immobilization with plaster of Paris cast. 123
36. Antero-posterior view of a 10 days old bilateral fracture of metacarpal showing slight periosteal reaction. 124
37. Antero-posterior view of the same animal after 15 days of immobilization with plaster of Paris cast showing healing. 124
38. Lateral radiograph of a fracture of radius ulna showing malunion. 125
39. From Right to left: Lateral radiograph of fracture of distal extremity of radius ulna, of upper extremity of radius ulna in a one day old kid, and anterior posterior view of epiphyseal separation of distal 126

extrimity of radius.

- 40. Lateral radiograph of the fracture of olecranon process and its immobilization with intramedullary pin and tension band wire. 126
- 41. A.P. view of fractures of third phalanx. Left: infection at the site was also present (Radiodense area). 127
- 42. A.P. view of fracture of both first phalanx in a goat, its immobilization with plaster of Paris cast, and after healing. 127
- 43. A.P. view of healed fracture of first phalanx. 128

INTRODUCTION

INTRODUCTION

The goat was earliest ruminant to be domesticated (Zeuner, 1963), and of all the species of domesticated animals except dog, has the widest ecological range (Epstein, 1965). When man began his farming operation in the dawn of history the goat was 'kingpin' of the pastoral life. The Harappan toy contains representation of a goat. Two seals from Mohenjo-daro show a wild bezoar goat with enormous curled and side spreading horns.

Goat is a very important livestock species in the developing countries, especially of Asia and Africa. Nearly 94% of the world population of 557 million goats exists in developing countries. Goat is essentially an asian animal although it is distributed all over the world and is available in all ecologies, ranging from cold arid to hot humid. The present world wide distribution of goats show that the number of milch type goats are more in the temperate zone and dual or chevon type are mostly located in subtropical Asian and African countries.

India ranks first in world's goat population with 116.75 million goats (FAO, 1993). In India most concentration is in arid and semi-arid north west region. In Rajasthan the goat population was about 150.62 lacs in 1992. Goats form about 20.4% of the total livestock population. In spite of 42% annual slaughter of the goats the population continues to increase at the rate of 1.2% annually.

Goats contribute to the subsistence of small holders and landless rural poor. They also produce marketable commodities viz. meat, milk, fibre (pashmina/mohair), skin, manure and transport power especially in high altitudes as in Himalayas. Goat along with sheep have an important role in income generation, capital storage, employment generation and improving household nutrition. Goats form an integral part of the rural socio-economic system and provide a dependable income of upto 40% to the rural population which is below poverty line in India.

Although, goat is blamed as an agent for soil erosion and desertification but in fact it materially contributes to the agriculture by enhancing the soil fertility and eating away unwanted bushes in range lands (Chopra, 1992).

The goat have religious and ritualistic importance in many countries. Goat has been worshipped for its creative and generative powers. Goat is known as "poor man's cow" or "foster mother" of man as its milk is cheap, wholesome, nutritious and easily digestible because of smaller sized fat globules. It has much less allergic problems than milk of other species of livestock (Acharya, 1992).

The habitat of goat in hilly areas and along side of roads in densely populated urban areas predisposes them to a variety of orthopaedic ailments causing lameness and subsequent decline in milk and flesh production, premature culling and treatment expenses. Commonest of these ailments is fracture which requires a greater attention in order to have an early osteosynthesis, rehabilitation and restoration of productivity.

Due to economic reasons, the animals particularly male is not brought for treatment and is slaughtered for meat, being small in size can be consumed by family and would not need refrigeration.

Fracture is partial or complete break in the continuity of bone or cartilage. External trauma seems to be most important factor in causing the fracture. Higher frequency of hind limb fractures could be fully justified because in vehicular accidents most of the goats are hit from behind (Singh et al, 1983). A fractured long bone, under normal circumstances heals by the initial production of a periosteal and endosteal callus. The function of callus is to stabilize the fragments and allow lamellar bone to grow and fill the fracture gap. The extent of periosteal and endosteal callus formation depend upon the degree of stability that is present at the fracture site.

Treatment of fracture is based on reduction, alignment and immobilization of the part, while maximum use of the limb should be permitted to prevent muscle atrophy and assist healing. The most important point is the effective immobilization of the fractured fragments. Depending upon the type of fracture and the bone involved the immobilization may be done either externally or internally. No one method can satisfy all requirements, so each case has to be considered on its individual merits.

Radiography play an important role in the diagnosis of fractures. The exact position and type of fracture, the degree and extent of the displacement and whether or not there are added complications such as involvement of a joint can easily be find out by radiography. It is also valuable in evaluating the response of fracture to treatment. The healing of fracture can

also be monitored radiographically.

Available literature suggests that scarce work has been done on caprine orthopaedics. Most of the reports are based on experimental work. In view of this present study was undertaken on clinical fractures while employing various external and internal immobilizing techniques in goats with following objectives :

1. To study the incidence of fractures of various bones in goat.
2. To carryout the clinical and radiological diagnosis of the fractures and its healing.
3. To immobilize the fractures with diverse external and internal fixation techniques.
4. To evaluate the efficacy of diverse techniques used to repair the fractures.

***REVIEW OF
LITERATURE***

REVIEW OF LITERATURE

Review of fractures in livestock revealed that the study conducted on fractures in goat is very scarce so the references used in the present study are mostly on cattle, sheep and dogs.

INCIDENCE

Reichel (1956) in an analysis of insurance company and slaughter house statistics on approximately 5,000 equine and bovine fractures over a period of ten years found highest incidence of phalangeal fracture (33%) followed by metacarpus (21%), tibia (18%), metatarsus (7%), radius-ulna (6%), humerus (5%), femur (7%), pelvis (2%) and spine, scapula and cranium (1%).

Peitel (1971) reported the frequency of limb fractures and the associated economic loss in horses and cattle. Of 5574 limb fractures and fissures in horse 27% involved first phalanx, 25% the tibia, 10% the radius, 9% the third metacarpus and 9% the third metatarsus. Of 269 cases in cattle 17% involved femur, 13% the tibia, 11% the metatarsus and 11% metacarpus. Losses in horses amounted to about 50% of the sum insured and in cattle about 33%.

Phillips (1979) made survey of 284 canine and 298

feline fractures over a period of 2 years. Approximately 80% of fractures occurred in animals less than 3 years old. Males were more commonly involved than females in both species. Road accidents were the main cause of fracture but falls and crush injuries were more common in dogs than cats. Bones most commonly affected in the cat were femur (28.2%), pelvis (24.8%) and mandible (11.4%), and in the dog radius and ulna (17.3%), pelvis (15.8%), femur (14.8%) and tibia (14.8%). 40% of fractures were treated conservatively or by external fixation, 46.8% by internal fixation and 13.1% were not treated. Results were satisfactory in 96.7% of treated cases.

Singh and Nigam (1981) examined 87 cases of bone and joint disorders of limb in sheep and goat in a radiographic study. These disorders included fractures of different bones, infectious arthritis, dislocation of tibio-tarsal joint and patella, osteomyelitis and congenital tibial agenesis. 78 cases of fracture of different bones were encountered in sheep and goats. The highest incidence of fracture involved the femur (32.0%), followed by tibia (21.7%), metacarpal (15.3%), metatarsal (10.2%), phalanges (6.4%), humerus (5.1%), radius and ulna (3.8%) and pelvic bones (2.6%).

Singh et al (1983) studied the incidence and anatomical locations of fractures in 511 clinical cases of canine, caprine, bovine, equine and camels. They found that fractures are more common in female goats than male as compared to other species where the incidence in male is greater than female. Most of the fractures were recorded in the age group of 1-3 years in bovine and caprine while in canine and equine occurrence of fractures

was more in younger animals below one year of age. Regardless of species, most of the fractures involved the shaft of the bones and were either comminuted, oblique or transverse in nature. They also found higher frequency of femoral fractures (32%) followed by tibial (21.7%), metacarpal (15.3%), metatarsal (10.2%), phalanx (6.4%), humerus (5.1%), radius ulna (3.8%) and pelvic bones (2.6%) fractures in goats.

Ferguson (1982) reported the incidence of fracture of humerus as less than 5%, radius-ulna (7%), scapula (rare), tibia (12%) and of metacarpal and metatarsal as 50% being more of metacarpal in cattle.

Adams (1985) in a survey of 93 cattle from 1979 to 1983 found the incidence of femur, humerus, radius ulna, tibia, metacarpal, metatarsal and phalanx fracture as 15.0, 4.3, 10.84, 15.0, 29.0, 8.6 and 1.1 %, respectively.

Dass et al (1985) in an analysis of 108 fractures of goats in the hilly terrain of Chhotanagpur found that over half of the fractures resulted from falls and only 20 from traffic accident. The most common bone involved was metacarpus (39 cases) followed by metatarsus (28), femur (13), tibia (12) and radius ulna in 11 cases.

Patil et al (1991) reported the incidence of fracture in a total 471 clinical cases of fractures brought to University Hospital, Anand from 1978 to 1988. Affected animals included cattle, buffalo, goat, sheep, horse, donkey, camel, dog, cat, avian and other species. The results showed higher incidence of fractures in females than in males except in donkey, camel and dog. In goats the frequency of tibial (24%), metacarpal (23.2%)

and metatarsal (23.2%) fractures was almost equal. Regardless of species most of the fractures involved shaft of the bones and were either comminuted, oblique or transverse in nature. The incidence of fracture was more in hind limb as compared to forelimb.

Tyagi and Singh (1993) found the incidence of fracture of scapula, humerus, radius, metacarpal, metatarsal, femur, tibia as rare, 5.0, 7-11, 21.2, 10.8, less than 5 and 28.0%, respectively.

Ganesh et al (1994) made retrospective study on the incidence and anatomical locations of orthopaedic problems in large animals. Out of 107 cases of large animals the common species involved were sheep and goat (62.6%), cattle (34.5%), buffalo (1%) and other species (1.9%). Fractures in the pectoral limbs were 30% and in the pelvic limbs were 70%. Out of 107 cases 69 animals (64.48%) were below one year of age, 33 animals (30.84%) were between 1-4 years of age and 5 animals (4.67%) were between 4-8 years of age.

Balagopalan et al (1995) reviewed fractures in 208 cases of dogs and found highest incidence of fracture of femur (38.9%) followed by tibia (18.8%). The lowest incidence was observed in scapula (0.5%). Amongst the different types of fractures, oblique (32.6%), transverse (23.2%) and epiphyseal separation (11.6%) were more common. Fractures of femur were seen mostly in the middle and distal third but in tibia it was in the middle and proximal third. Fractures of hind limb (65.9%) were more than that of the fore limb (21.2%).

DIAGNOSIS AND TREATMENT

Kendrick (1951) discussed the treatment of tibial and radial fractures in large animals with transfixation. Tibial fractures were found difficult to treat because tibia is at a point where soft tissue structures of the leg become thin and anteroposterior dimension of the leg at the proximal end of the tibia is twice that of the distal end. Therefore, if cast alone is applied the distal fragments can firmly be fixed but proximal fragments can't. The taper of the leg in the tibial region may allow a cast to slip. It was anatomically impossible to place a cast above the stifle in large animal and hence transfixation technique was used.

Ganis (1952) described the reduction to diagonal fracture in a 2 year old bull by external pin bar device. At each pin site a small incision to the bone was made and the pin was placed through the bone and the skin of the opposite side. Two pins were passed lateromedially through proximal tibia. The lower pin was then placed through the opposite side. Clamps and pin rods were applied. Before tightening the fixation bars in place, the leg was checked for rotation. The apparatus was left in place for 33 day and then was removed. Though healing took place but some suppuration developed from the proximal pin sites. Bending of the pins was noticed in last two weeks. Six months later most of the limping had vanished and the size of the leg was nearly normal.

Reichel (1956) described treatment of fractures of the long bones in large animals. The object was not only to achieve

bony union of the fragments, but also, full restitution of the patients so that they could resume their former tasks without impediment. He attempted unpadded plaster of Paris cast and the transfixation with Steinmann pins for the repair of long bone fractures in large animals. On hind leg the cast proved to be too cumbersome, immobilizing the whole animal. Fracture of radius ulna, tibia, metatarsus and the phalangeal bones in hind legs were treated by transfixation with Steinmann pins. This method gave more freedom of movement and was found in this way superior to the unpadded plaster of Paris cast. However, the application of two pins through the bone made it more dangerous. The animal suffered from a sequestering pin channel caused by a hot pin and recovered after several weeks.

In the treatment of fractures in farm animals Hickman (1957) pointed out the problems associated with the reduction, alignment and immobilization of fractures in farm animals and suggested the methods of overcoming these. He treated 17 fractures in cattle, 3 in sheep and 5 in pigs by both close and open reduction. The open reduction was used for fracture above the knee and hock joint while plaster of Paris cast was used for fractures below these joints.

Beckenhauer (1958) used the modified Thomas splint on 12 experimental and 18 clinical animals with fractures of long bones. One bull was killed following refracture and two bulls developed lateral angulation of the leg below the fracture and were non-serviceable. Half of the animals recovered functionally and continued breeding. While in 50% cases rate of recovery was low, but it demonstrated that euthanasia was not always necessary

or advisable for fracture cases in cattle.

Lundvall (1960) used Thomas splint, plaster of Paris casts, intramedullary pins, stainless steel plates and screws, through and through fixation pins with or without the concurrent use of plaster of Paris cast and supporting crate with no attempt at reduction in cattle and horses. Plaster of Paris cast was used as most common method of external fixation upto stifle and elbow joints both in horses (41%) and cattle (35.29%). Out of 99 horses and ponies 34 showed good, 29 fair and 7 poor functional recoveries. Out of 52 cattle 12 showed good, 15 fair and 5 poor functional recoveries.

Gabel (1961) used half pin device for the tibial fracture repair. Two pins each, were fixed at an acute angle to each other in tibia and femur and these were supported by plaster of Paris cast. Upper pin came out from leg and plaster. Animal recovered with slight abnormal gait which improved later on.

Lawson (1963) gave in detail the management of fractures in domestic animals and reviewed different methods of fracture treatment which were then employed and also described the complications associated with each technique. He also described the usefulness of plaster cast in fractures upto the level of the elbow and stifle joints and complication of plaster cast like slipping of the cast and plaster bite causing damage to the skin. The complications associated with intramedullary pinning were mostly as a result of improper diameter of the pin as compared to the medullary cavity causing lateral deviation in transverse and both lateral and longitudinal displacement in oblique fractures.

West (1963) used resin bonded fibre glass for the immobilization of fractured or damaged equine and bovine limbs. It was used with success to immobilize the forelegs of 4 young horses. The substance has a very high strength and low weight ratio and is both durable and inert.

Jenny (1965) described the following treatment of open fractures for rapid and complete recovery. General condition like shock should be treated first by minimizing the loss of blood and by restoring blood volume. Wound should be protected from external contamination to prevent infection. Body defenses should be supported with antibiotics and early debridement should be performed to remove all foreign matter and devitalized tissue. Unnecessary disturbances of the wound during the healing process should be avoided.

Vaughan and Osman (1967) observed that out of the 16 cases of fractures of third phalanx encountered in cattle, all involved the medial claws of forefoot and in eight the condition was bilateral. Treatment by the metal or wooden shoe showed rapid improvement in the condition of the animal.

Mohanty et al (1970) used different methods for treatment of fractures in an experimental and clinical study on cattle. Long bone fractures, 26 experimentally created and 40 clinical cases, were treated by plaster cast, modified Thomas splint, intramedullary pinning, stainless steel wire sutures and Kirschner's splint. The results though variable were successful in most cases especially with the first three techniques mentioned above. For compound fractures, however, meticulous

debridement, hot saline irrigation and use of antibiotics was advised.

Dingwall et al (1971) carried out compression plating for treatment of fractures of long bones in large animals. The major problem encountered were massive weight of the large animals and probably to a lesser degree the temperament of the large animal species. This technique offers the advantages of rigid internal fixation and early weight bearing. Because of the complexity of the technique, familiarity with the equipment and its application is essential.

Gill and Tyagi (1972) reported a study on the repair and management of long bone fractures in large animals with special reference to external fixation. Coaptation was found to be simplest and safest technique and it was observed that bandage in '8' fashion around the hock with subsequent ascending bandages kept the plaster in position for tibial fractures. Strong and pliable aluminium splints were found to be most suitable reinforcing material for tibial as well as metatarsal fractures. Aluminium being light in weight did not make the cast heavy and could easily be shaped according to contour of the limb. The technique of hanging pin cast proved ideal for preventing rotation in metatarsal fractures where inclusion of hock was not tolerated by the animal. This further avoided slipping of the cast. Modified Thomas splint found its value only in heavy animals to render an additional support during walk. In all the clinical and experimental animals- healthy calves, adequate union of bone was seen except in coaptation procedures slight rotation was observed. The animal started bearing weight on affected limb

by 15th to 20th day. Casts were removed after 35 days. The gait was slightly altered, yet no external deformity or rotation was observed in animals.

Similarly Tyagi and Gill (1972) conducted a study on the fracture repair and management of long bones in large animals by transfixation and bone plating. Transfixation proved useful in the treatment of tibial fractures especially in heavy animals. Oblique fractures which had a tendency to slide over were repaired with this technique. Bone plating proved efficacious in transverse fractures and healing occurred with minimum deformity and maximum alignment though it involved a major surgical intervention for the application and removal of the plate.

Montgomery (1972) described use of fiberglass with plaster of Paris in the fabrication of casts.

Hanselka *et al* (1972) used resin bonded fiberglass cast for external fixation in large animal fractures. These materials are resistant to chemicals and exudates and produce a cast which hardens within a reasonable period of time and is exceptionally strong in relation to its weight, thus requiring no metal reinforcement.

Verschooten *et al* (1972) treated transverse fractures of tibia in cattle by transfixation with Steinmann pins and an external methylmethacrylate bridge. Spiral fractures in the length of the tibia were treated by cerclage and a plaster of Paris bandage or by a combination of screwing and transfixation. Eighteen animals were treated, the results in 14 being good.

Ramkumar *et al* (1973) described the disadvantage of hanging pin cast for distal oblique fracture of tibia in a 4 year

old cow and found that the method had no advantage over simple coaptation technique as far as the prevention of over-riding of fractured fragments was concerned.

Rao and Rao (1973) employed specially fabricated multiple rush pins for tibial and metatarsal fractures in bovines. Both proximal and distal sites were tried for insertion of the pins. The use of only two pins driven through the distal sites were considered advantageous. Of 12 animals with experimental (10) and clinical (2) fractures of these bones thus treated, nine recovered and resumed normal gait.

Huttschenreuter et al (1973) conducted experimental studies on a plate osteosynthesis after shortening osteotomy of the metatarsus in 20 sheep. Fracture healing was proved radiographically and histologically and full use of the limb was regained after 3 weeks. With this method any additional dressing was unnecessary.

Northway (1973) described cross pinning for fracture immobilization in foal, dogs and cats. Use of 2 or more Steinmann pins in a crossed pattern proved very satisfactory in prevention of rotation of distal fragment. The technique was successfully used for immobilizing epiphyseal and Y shaped fractures. In most cases, the pins were removed after 6-10 weeks. Occasionally they were left indefinitely.

Wolff (1973) reviewed the ASIF techniques and implants for fracture repair. The complete system allows optimal treatment of animals with severe comminuted fractures, delayed unions and non-unions. In many such cases the patient was able to bear weight on the affected limb 48 hours after surgery.

Newton (1974) reported fracture non-union resulting from cerclage appliances when used simultaneously with intramedullary fixation. In most cases, non-union resulted from two problems.

- i) The intramedullary pin and wires, apparently stable at surgery, were inadequate and resulted in motion at the site.
- ii) The cerclage appliance impairs circulation.

Non-union resulting from the simultaneous use of cerclage wires and intramedullary fixation did not always occur. The amount of trauma, periosteal stripping, reduction of motion at the fracture site or impaired circulation prior to or during fixation seems to be the major consideration. Cerclage wires usually cause non-union because cortical circulation was impaired and fixation was poor.

The lack of a suitable fixation device led to the development of a technique which employs Kirschner pins and arc welding to hold broken bones rigidly (Connell, 1974). This technique overcomes the disadvantages of weight, pressure and covered fracture site. A major advantage of the procedure was that as soon as the bones were immobilized in apposition, pain was eliminated and the animal regained mobility of the limb. This technique was used successfully in more than 100 head of cattle and a few horses.

Rhineland (1974) observed that healing of tibial fractures particularly of distal extremity posed a problem as it was sparsely covered by the soft tissue which was the temporary

and immediate source of extraosseous blood supply during fracture healing.

Winstanley (1974) reviewed the aspects of the compression treatment of fractures and opined that the application of pressure to the fracture site provides rigid fixation. Healing took place by direct bony union and there was minimum formation of periosteal callus. Special precision instruments and implants were used to achieve compression. Failure to apply the technique in the recommended manner lead to unpredictable and disappointing results. The prime indication for the use of compression methods was the treatment of unstable and non-union fractures.

Rao (1975) described successful use of the plaster cast, short and modified Thomas splint for the treatment of metacarpal fracture in a 3 year old bull and metatarsal fracture in a 5 year old bullock.

Brown and Dicken (1975) showed the surgical procedure used for repair of fractures of the distal third of femur by intramedullary pinning in a 3 day old calf in a photo assay.

Bacher and Potkay (1975) accomplished internal fixation of radial and ulnar fractures in three goats using compression plating. The goats tolerated surgery well, were ambulatory on the first postoperative day and had full use of the fractured limbs within 5-7 days. Inadequate stabilization and rotation did not occur and external support device was not required. It was possible to return the goats to the herd within 4 weeks after surgery. Bone plates measuring 3/8" X 3" were best suited for use in goat weighing from 54-77 kg.

Rittmann and Ferren (1975) studied the effect of infection on cortical bone healing of long bone fractures in sheep after immobilization with either compression or non-compression plate technique. 6-8 days after surgery, a known number of penicillinase producing staphylococci were injected locally. The course of infection was monitored twice between the second and sixth weeks after the operation and at slaughter. The results indicated that even massive infection does not destroy the healing process in cortical bone under stable conditions and the stabilizing implants should be left *in situ* when infection occurs.

Satish et al (1975) used buffalo bone as a surgical plate and screws and found that buffalo cortical bone were not affected by sterilization and were easy to prepare and handle. The use of these was suggested in small animal surgery in place of standard metallic plates or screws.

Vaughan (1975) gave an account of some of the complications that arise following the internal fixation of fractures in dogs. Osteomyelitis was one of the most serious untoward sequelae and treatment by means of debridement, fracture immobilization and antibiotic therapy proved successful in the majority of cases. Stifle joint stiffness following the repair of femoral fractures arose most often in association with internal fixation methods particularly when complicated by infection, but may also follow direct damage to the joint due to penetration with an intramedullary pin during the operation or to its migration later. The commonest error resulting from

technical fault is using an implant, whether pin or plate, of insufficient size adequately to immobilize and support the fracture. Unless a pin fits the medullary cavity closely, it will not prevent rotation of the distal fragment. The movement interferes with fracture healing and non-union may result.

Rama Kumar et al (1976) described use of Kuntschner clover leaf nail in spiral fracture of humerus in a buffalo heifer in a case report. The animal could bear weight on the affected limb on the 8th postoperative day. At the end of 6 weeks the nail was removed and the X-ray showed complete bridging of the fracture line.

Bommaiah et al (1976) tested the efficacy of bone plates and screws prepared from macerated buffalo bone for the treatment of distal tibial fractures in dogs. Clinical and roentgenological observations revealed that bone plate and metal screw assembly was at par with metal plate and screws.

Grandage (1976) discussed four aspects of normal radiographic anatomy in relation to the diagnosis of bone pathology. Where two bones are superimposed the observer may perceive a phantom radiolucent line parallel and close to one of the bones. The radiolucent line is a Mach band and is an illusion which may simulate a fracture. Nutrient canals may also simulate fractures although subject to typical site, number and direction, exceptions are frequent. The normal appearance of cancellous bone varies from species to species. In the sheep and cat the spongiosa is coarse and sparing and may falsely tempt a diagnosis of osteoporosis. The trabeculae are delicate in the pig and abundant in horse.

Singh et al (1976) observed the time effect of intramedullary pinning in tibial fractures repair of the dog. The left tibia of 12 healthy dogs, divided randomly in 4 groups of 3 animals each, was fractured. The fractures were immobilized with intramedullary pinning on 0 day in I group, on 3rd, 7th and 10th post-fracture day in II, III and IV group, respectively. The animals were observed for 8 weeks. Healing rate was fastest in group II in comparison with other groups. However, at 6th week very little difference was observed in I, III and IV groups and the healing was complete by 8th week in all the dogs. It was suggested that the open reduction in clinical cases may be done on 3rd or 7th day post-fracture. However, if it is undertaken on zero day, additional stress due to surgery may be detrimental to the animal and there is little difficulty in breaking the soft callus if fracture is immobilized on 10th day post-fracture. The healing of fracture was complete by 8th week irrespective of the time of intramedullary pinning.

Braden and Brinker (1976) evaluated bone healing associated with 3 techniques of mid-shaft femoral fractures fixation by radiographic and gross pathoanatomic studies in 36 dogs. The radiographic evaluation was done in series. The first radiograph was taken during surgery and then taken immediately after surgery, to record the status of reduction, alignment and fixation. Radiographs were then taken at 4th and 10th postoperative weeks, to monitor healing. Gross examination was done after euthanizing the dogs at the 10th week and removing the normal and healing femur. Each type of fixation was

associated with a distinct mode of osteogenesis. Bony union and clinical union (that stage in the healing process when fixation can be removed) were defined as a successful conclusion to each case. Malunion and non-union were defined as unsuccessful conclusions. Delayed union was defined as neither successful nor unsuccessful. The intramedullary pin cases had a 64.2% success rate and 14.2% failure rate. The intramedullary pin and 1/2 Kirschner cases had a 100% success rate. The bone plate cases were 91% successful, with 0% failure. A problem with intramedullary pinning was axial rotation (6 of 14 or 42% cases). It was concluded that intramedullary pins should not be used alone for the fixation of femoral fractures in adult dogs.

Sanford and Rendano (1977) reported abscess formation and malunion complicating fracture healing in a calf. Osteomyelitis following trauma is usually associated with a break in skin continuity. Abscessation with a well formed abscess wall at the fracture site is rarely reported, even in a compound fracture.

Johnson (1977) presented a new system for fixation of bone fragments by wire which served to compress the fragments, prevented migration of wire and reduced the area of pressurized contact between the wire and bone. This method was used in conjunction with intramedullary pinning to successfully repair fractures in two dogs and a cat.

Chaffee (1977) described a technique to repair mid-shaft fractures of the humerus, middle and proximal third of the femur in dogs using multiple (stacked) intramedullary pin.

Pfeiffer (1977) described treatment and results of tibia fractures in dog recorded between 1970-74. 300 dogs with 303 fractures of tibia and/or fibula (74% diaphysis, 26% epiphysis or metaphysis) were treated. 12.5% were compound fracture. About half the dogs were less than one year old. 161 of 292 fractures were treated conservatively and 131 surgically (82% and 65%, respectively were shaft fractures). Both methods of treatment were 96% successful with fractures in diaphysis area. In the areas of epi- & metaphysis osteosynthesis were 65% successful, against 73% with conservative treatment.

Similarly Meyer (1977) described the treatment and results of radius and ulna fractures in the dog between 1970-1974. Transverse and compound fractures were the most frequent (23% and 11%). Most fractures were of diaphysis (64%) and the distal metaphysis (36%).

Ackerman and Silverman (1978) reported the importance of radiography in the diagnosis of fractures and evaluating the response of the fracture to treatment. The healing of a fracture can and should be monitored radiographically. The sequence of events which may be observed radiographically depends on the age of the animal, the type of fracture and post-treatment alignment, the blood supply to the fractured bone, the type of orthopaedic device used for fracture immobilization, the stability of fracture repair and the presence of complicating factors such as infection or sequestrum formation. In young animals fractures heal more readily and rapidly because bones are growing and more active. Callus formation is minimal with bone plates while the use of intramedullary pin or external splint may results in

fractures which heal with a large bony callus. Radiographic evidence of complete fracture healing occurs long after the fracture is clinically healed, thus clinical examination is best for evaluating fracture healing.

Singh and Nigam (1979) studied the fracture repair of metatarsus in bovine with special reference to homogenous bone plating. Radiological and macroscopic observations revealed that homogenous onlay bone plates could be an adequate substitute to metallic plates, if not superior replacement to them. The amount of periosteal callus formation was directly related to the degree of stabilization of fractured fragments. It was smaller in fractures treated with either metal or bony plates when compared to plaster cast alone.

Singh et al (1979) reported a case of successfully treated Monteggia fracture in a goat. The head of the radius which was dislocated cranially was reduced in the flexion. The fracture of ulna was reduced by use of intramedullary pin in extension. Radiological union of the olecranon process with distal end of ulna took place at the end of 5th week and the pin was removed.

Valdez et al (1979) performed compression plating of long bone fractures in foals aged 1-20 weeks and weighing 35-160 kg. Both dynamic compression plates and ASIF plates were used for internal fixation. External fixation was also used in nine cases. Of the 15 foals used, 4 were subsequently killed, 2 were lame and the remaining 9 were sound.

Chatre et al (1979) described a technique of successful bone setting of fractures by means of external pins, in calves of

less than 100 kg, in the lower leg and tibia. No success has been achieved in bones of the upper leg (femur, humerus). Rustless steel pins of 3-4 mm diameter were used for reduction and immobilization of fractures.

Walker (1979) recommended a highly successful coaptation splinting device for the management of tibial fractures, which are very common in the bovine. Such a device also stabilized stifle joint in cases of cranial cruciate rupture or torn menisci. The splints contained its own extension device and provided valgus fixation of the limb to prevent the natural tendency for the medial displacement of the fractured bone but the device was not recommended for recumbent animals.

Stick and Derksen (1980) successfully repaired a open comminuted proximal femoral fracture in a 7 day old foal using a large (0.5 inch) intramedullary pin. Radiographic evaluations of the fracture were made periodically. At 4 weeks postoperatively, periosteal callus formation could be seen radiographically. On 51st postoperative day, the pin was removed.

Hamilton and Tulleners (1980) reduced and stabilized tibial fractures in 3 newborn beef calves by transfixation pinning. Return to normal function was rapid in two calves, but one calf acquired septic arthritis of the stifle and was later euthanatized, however, the fracture had healed. Good radiographic and clinical evidence of stability was evident at 4-6 weeks, at which time the pins were removed.

Sharma et al (1980) studied the effect of immobilization time on fracture healing in buffaloes and concluded that the best time of immobilization in large animal

appears to be around 3rd post fracture day. A delay can complicate the fracture as the broken ends may sometime rupture the skin.

Marudwar and Kulkarni (1980) described a new technique for immobilization of bovine limb. This technique provided additional immobilization of limb with a rope by flexing through knee and shoulder joint in fore limb and through fetlock in hind limbs. It was used successfully for treatment of simple fractures of humerus, radius, metacarpus, femur and luxation of shoulder & hip joint and severed flexor tendon in bovine.

In a radiographic study of 104 clinical cases of bovine foot disorders Nigam and Singh (1980) found that 84 (80.8%) of the affected animals were males and most were ≥ 4 years old. Common conditions encountered were phalangeal fractures (38.5%), arthritis (34.6%), periostitis/exostosis (18.3%), dislocation (5.8%) and solar penetration (2.9%) of cases. Phalangeal fractures were most common in hind feet with higher incidence in P₁ and P₃.

Ames (1981) compared the methods of femoral fracture repair in 12 young calves repaired with intramedullary pins, half-pin assemblies or bone plates and screws. Nine calves survived the 6 week experiment. One calf with each type of internal fixation was equipped with either a modified Thomas splint, an Ehmer sling, or had no external fixation. At necropsy, 42 days after surgery, the femurs with intramedullary pins were healing with slight malalignment and overriding. The femurs with half-pin assemblies were considered nonunions, with severe overriding, malalignment and osteomyelitis. The femurs

with bone plates and screws were healing, although the screws had loosened and allowed overriding with rotational malalignment of the fractures. The calves equipped with the Thomas splints and those with no external fixation were able to stand and to walk earlier and with less difficulty than the calves with the limb placed in an Ehmer sling.

Vijaykumar (1981) carried out a radiographic survey based on 268 clinical cases of fracture of different bones and revealed high incidence of tibial fractures in bovines. His further experimental trials were performed on 50 buffalo calves, where tibial fractures were reduced and immobilized by hanging pin cast, double stainless steel plating and Kuntschner's clover leaf nailing. It was shown that internal fixation with double plate osteosynthesis gave better results than Kuntschner nailing or hanging pin cast.

Vijaykumar *et al* (1982) evaluated the four techniques of osteosynthesis based on 12 clinical cases of bovine tibial fractures. The four techniques were dual plate fixation, single plate fixation, Kuntschner nailing and hanging pin cast. It was concluded that dual plate fixation in combination with a plaster cast, though cumbersome, is an effective technique for repairing tibial fractures in adult cattle. Good interfragmentary contact, easy postoperative care, early ambulation and rigid fixation with primary bone union were some of the advantages of this technique.

Losslein (1982) reviewed the treatments and results of metacarpal and metatarsal fractures between 1975-1981. Results of clinical and radiological follow-up examinations showed that intramedullary pinning together with external splinting was the

most satisfactory technique when closed reduction was impossible. The use of metal plate sometime led to tendon irritation.

Rama Kumar *et al* (1983) studied angiographic patterns in large animal fracture healing in an experimental study. Surgically created mid-shaft fracture of humerus and femur in 18 buffalo calves were reduced and immobilized by intramedullary pinning with Kuntschner's clover leaf nail. Angiography was performed after 1, 2, 3, 7, 14, 21, 30 and 45 days to study vascular patterns as the healing progressed. The results indicated that the soft tissue vessels played a vital role in healing of these fractured bones following intramedullary pinning.

Singh *et al* (1983) reported intramedullary use of iron nails covered with methylmethacrylate in femur fracture repair in sheep and compared it with fractures immobilized by Kuntschner nail. No marked difference was observed clinically in both the groups of animals except that period of disability was longer and relatively large and irregular callus was observed indicating imperfect fixation in animals immobilized by K-nail. The radiographic observations at different intervals upto 160 days postoperatively revealed uninterrupted complete immobilization without any sign of metal corrosion or tissue damage in fractures immobilized with iron nails covered with methylmethacrylate. The gross and histological examination of bone at the end of observation period (160 days) showed a fibrous layer between the nail and bone without any infiltration of inflammatory cells, whereas no such layer was observed in animals where Kuntschner nail was used.

Chawla et al (1983a) evaluated tibial fracture healing in sheep on the basis of radiological examination. Comparatively marked periosteal reaction and bigger callus were seen in fractures immobilized by simple coaptation and intramedullary pinning than the plating.

Adams and Fessler (1983) treated radial-ulnar and tibial fractures in cattle using modified Thomas splint-cast combination. The cattle ranged in age from 1 day to 5 years and weighed from 46 to 775 kg. Eight cattle had radial-ulnar fractures and 7 had tibial fractures. The fractures healed in 14 cattle. The most frequent long term complication was deviation of the involved long bones after healing. The degree of deviation decreased over several months' time in most cases. 13 of the 14 cattle with healed fractures were used for breeding or milking and their capacity for those function was not diminished.

Chawla et al (1983b) studied vascular response during tibial fracture healing repaired by simple coaptation, intramedullary pinning and bone plating in 36 sheep. Generalized extra-osseous hypervascularity was observed in initial stages of fracture healing. However, it was more intense in fractures repaired with coaptation, followed by intramedullary pinning and bone plating. The vascularity returned to near normal after 6 weeks, except in displaced fractures where it persisted even upto 9th week. The callus was well vascularized by newly proliferated vessels of soft tissue origin between 6 and 9 weeks in all the techniques.

Rao et al (1983) conducted experimental studies on the

repair of metacarpal fractures in bovine with reference to use of allogenic onlay bone plates and compared it with standard metallic plate. The allogenic onlay bone plate offered good stabilization at the fracture site similar to that of metallic plate in young calves. Immobilization with simple coaptation resulted in higher percentage of postoperative complications, viz. angulation, delayed union and malunion. The use of frozen cancellous bone grafts in conjunction of either metallic or onlay bone plates resulted in better bone healing than that of autoclaved cancellous bone grafts.

Kagan (1983) used multiple intramedullary pin for the fixation of femur fracture in dogs and cats. A single intramedullary pin gave axial alignment, acting as an internal splint, embedded in the ends of the bone and contacting the inner face of the cortex near the fracture. The more completely the intramedullary pin fill the medullary canal at the fracture site, the better the reduction and alignment. Use of single large pin had some disadvantages. Thicker pins are not flexible and donot follow the shape of the medullary canal well and also does not confer rotational stability. Use of multiple intramedullary pins for fracture repair has several advantages. Thin, flexible pins may follow the curvature of the medullary canal. There are maximum number of contact points between the pins and the cortex. The entire unit (the pin bundle and contact points) acted as a torsion bar, protecting the fracture line from rotational stress.

Chawla et al (1983c) made histomorphological studies of tibial fracture healing following internal and external fixation

in 36 sheep immobilized by either simple coaptation, intramedullary pinning or stainless steel plating. Within 9 weeks, union of the bony fragments occurred with pinning and with the steel plating. With simple coaptation, microscopy revealed a callus formed of fibrovascular tissue, chondroblasts and osteoblasts, and little calcification. Fixation occurred more rapidly with intramedullary pinning than with stainless steel plating.

Singh et al (1984) described postoperative complications associated with fracture repair of long bones in bovine, equine and ovine. Malalignment and infection were the most common postoperative complications after external and internal fixation of fractures in 270 cases of bovine, equine and ovine. External immobilizations by simple coaptation, hanging pin cast and transfixation were mostly associated with complications like malunion, delayed union and non-union. Infection and elevation of plates were major complications with plate fixation. Internal fixation with intramedullary pin, K-nail and double plates fixation showed minimum postoperative complications.

Mbiuki and Byagagaire (1984) treated tibial shaft fractures in 7 calves and 5 goats by manual reduction and immobilization by full limb plaster of Paris cast. The cast was extended from the hoof to a point seven to ten centimeters above the stifle joint. Union of the fracture segments was confirmed in all 12 animals when casts were removed after six to eight weeks. Complications included muscle atrophy at the level of the fold of flank, pressure point lesions, and weakening of the

joints and tendons. After the cast was removed, a modified Robert Jones bandage was used for two weeks to support the weakened limbs and prevent swelling.

Vijaykumar *et al* (1984) evaluated simple coaptation, K-nailing and double plate fixation in 36 calves aged 1.5-2 years. After the operation the animals were observed for upto 12 weeks and radiography were made, after which the animals were killed. Simple coaptation provided inadequate immobilization, resulting in prolonged lameness and the formation of large areas of external callus with angular deformities and malunion. The fractures with K-nails healed satisfactorily but were associated with complications (slab fractures of the fragment, distal migration of the nail and cortical necrosis). Fixation with a double plate provided good interfregmantory contact, rigid stabilization and primary bone union resulting in early use of the repaired limb.

Moulvi *et al* (1986a) radiographically evaluated femoral fracture healing following xenogenic bone plating and neutralization plating in goats. With heterogenous bone plates, radiographic union of fragments was discernible at 4 weeks, while at 6 weeks the continuity of medullary canal was established. There was little periosteal reaction. Failure occurred in only one case due to the elevation of the plate. With neutralization plates two goats showed non-union and one delayed union. Out of 2 non-union cases, in one there was ectopic callus formation. In other animals radiographic studies revealed that the process of healing was not complete even by 6 weeks. The feasibility of failure with single plating was very less with HBP than with NF

in the repair of femoral fracture in goats.

Moulvi et al (1986b) made histological studies of femoral fracture healing under heterogenous bone plating and neutralization plating in goats. 12 clinically healthy goats, 12-18 months old, were used. They were divided in 2 groups of 6 each. Heterogenous bone plates (HBP) prepared from bovine ribs and stainless steel neutralization plates (NP) were employed for repairing femoral fractures in goats. The results suggested that HBP can be used as a substitute to conventional steel plates as HBP appeared to induce a process of faster healing than NP. Further, the chemical treatments of bone plates were adequate for deproteinization and defatting.

Ferguson et al (1986) in a retrospective study of 77 femoral fractures in newborn calves revealed that most occurred in the femoral shaft or in the proximal physis with thin cortices. Periosteal stripping was a significant problem in the fracture of femoral shaft. Most cases were related to forced extraction, with more left femurs being affected than right. The existence of concurrent disease reduced the treatment success rate by 50% and when significant additional trauma was present, no calves survived. When all cases were considered regardless of condition the long term success rate was 43%.

Buchoo and Sahay (1987) evaluated the efficacy of compression osteosynthesis for radial and ulnar fractures in goat on the basis of clinical and radiographic findings. Study was conducted on 12 goats, aged 2-3 years and weighing 15-20 kg. They were randomly divided into 2 groups. In group I compression plating was done, Group II was kept as control and fractured

bone was immobilized by applying plaster cast. The animals of group I became ambulatory the day after surgery, exhibited near normal movements with adequate weight bearing by 12th postoperative day. The animals of group II showed displacement of fracture fragments after 1 week of immobilization. Higher percentage of postoperative complications like delayed union, malunion and bigger callus formation was reported following simple coaptation. Therefore present study showed that plaster cast alone is not sufficient to provide rigid immobilization and stability in the repair of radial and ulnar fracture in goats. Contrarily, compression plating proved to be an ideal method and suitable for the management of such fractures.

Singh et al (1986) clinically, radiographically and histomorphologically evaluated mid-shaft femoral fracture repair by Kuntschner clover leaf nail (K-nail) and double Steinmann pins in calves. Calves with K-nail showed early ambulation and weight bearing capacity. Radiographic and histomorphological observations showed that healing of fractured bone was better with double pins.

Singh et al (1987) used bone plates prepared from bovine horn for the fixation of femoral fractures in goats without external immobilization. Radiographic assessment was facilitated in both views due to radiolucency of horn plates. Clinically, the animals did not show any abnormal reaction to horn plate at site of contact throughout the period of observation. Organisation of periosteal callus and obliteration of fracture line was observed at 45 days but remodelling of callus could be seen at 6 months postoperatively. It was

concluded that horn plates were well tolerated and proved strong enough to hold fracture fragments in alignment until fracture union in goats.

Bennett et al (1987) compared the strength and holding power of 4 pin designs for use in half pin (type I) external skeletal fixation. Pins tested were fully threaded, non-threaded, two cortices partially threaded and one cortex partially threaded. The results of this study suggest that one cortex partially threaded pins were better at maintaining holding power and resisting bending and breaking than non-threaded pins.

Whitney and Schrader (1987) evaluated 71 cases of distal femoral fractures in dogs and cats repaired by dynamic intramedullary cross pinning technique. The results were good or excellent in 66 of 71 animals (93%). The mean follow-up period was 22 months. Distal pin migration was the major complication (10 animals; 14%). The pin migrated in 8 animals after bony union and was associated with intermittent lameness. In 5 of these, pin removal was performed and the lameness resolved.

Vachon and DeBowes (1987) reported proximal metatarsal fracture repair in a calf by open reduction, internal fixation and external coaptation. The internal fixation was carried out by dynamic compression plate and then a full limb cast was applied. The calf recovered without complications.

Buchoo et al (1988) made histomorphological studies of compression osteosynthesis for radial and ulnar fractures in goats and compared it with conventional technique of plaster cast immobilization. Compression technique induced the process of early and organized callus formation resulting in complete union

by 6 weeks. Early initiation of osteogenic process was chiefly due to rigid immobilization and close apposition of the fractured ends. The histological picture of delayed union was conspicuous in the plaster cast immobilization.

Singh et al (1988a) used PVC (Polyvinyl Chloride) pipe for the external immobilization of metacarpal and metatarsal fractures in experimental cow calves. After immobilizing the fractures with the help of bamboo splints for a day, the fracture site was immobilized with only one 6 inch plaster bandage and after proper padding with wool cotton and bandages the limbs were fitted into PVC pipe upto the level of knee/hock joints.

Singh et al (1988b) evaluated three types of internal skeletal fixation for repair of experimental humeral fractures in 18 cow calves. The animals were divided into three groups (A, B and C) of six animals each. K-nails, single Steinmann pin and double Steinmann pins were used for immobilization in animals of group A, B and C, respectively. Radiographs were taken at different intervals upto atleast nine months. The radiographs were evaluated for osteogenic reactions, infection and any migration of internal fixation devices. The results were encouraging in all the groups except the migration of pins in groups B and C.

Singh et al (1989) in a case report described the repair of humeral fracture in a buck. A snugly fitting Kuntschner intramedullary nail of appropriate size was introduced into the proximal segment and then anchored into the distal segment after proper reduction and alignment of the fracture. After 2 months, the nail was found totally embedded in the

medullary cavity and clinical union of fracture had occurred. The buck started bearing full weight on the affected limb.

Dallman et al (1990) studied the rotational strength of double pinning techniques in repair of transverse fractures of femur in dogs. Transverse mid-shaft fractures of femurs from freshly killed dogs were stabilized by means of 6 methods : 35 mm bone plate and screws, single intramedullary pin, double intramedullary pins retrograded proximally and driven distally to the level of the femoral trochlea, double intramedullary pins retrograded distally and driven proximally into the trochenteric region, double intramedullary pinning in Rush pin fashion and multiple intramedullary pinning that filled the medullary cavity at the fractured site. All bones were subjected to torsional stress. The measured strain was converted to forces of torque and correlated with bone diameter to normalize the data. The force of torque from each fixation technique were compared with each other and with the mean torque force necessary to fracture intact femurs. Torsional shear applied to plated femurs resulted in a failure at a mean level of 33.8% of the calculated theoretical moment. Torsional forces were concentrated at one end of the plate and catastrophically failed at that point, whereas the fracture site remained rigidly fixed. There was no significant difference in the initial moment of torsional failure between the single intramedullary pin technique (0.05 Nm). The multiple pinning technique was 1.8 to 3 times as effective in resisting rotational forces compared with the other pinning techniques but not significantly so.

Iyer (1990) studied the effect of retained

intramedullary pin in the femur of a dog. The normal femur weighed 14.1 grams and the pinned one 11.8 grams without the pin. Compared with the normal femur, the shaft of the pinned femur was more flattened, the midshaft region appeared wider due to good callus formation, the distal ends curved slightly in both directions and labium laterale and mediale were not well defined. The length of the normal femur was 11.7 cm with mid-shaft circumference of 3 cm and that of pinned femur 10.7 cm and 6 cm, respectively. On radiological examination, the bone was found curved in both directions. There was decrease in the density of cortical bone of the shaft, well formed callus extending to both proximal and distal fragments with a zone of radiotransparent tissue indicating the presence of fibro cartilage and shadow of hallowness on the length of the bone with increased radiodensity. There was no appreciable difference between the marrow smears prepared from proximal end of normal and pinned femur.

Gahlot et al (1990) reported the use of modified iron splint for tibial fracture repair in bovines. The splint comprised of a ring, two parallel iron bars and a foot plate. A transverse bar connecting the two parallel bars was welded in a measured position just above the hock. The splint was padded with cotton and bandage. The splint being placed on medial aspect of the limb prevents medial deviation of fractured fragment and averts it to become compound in nature.

Köstlin et al (1990) reviewed treatment and results of metacarpal and metatarsal fracture in cattle. The cause of fracture was incorrect traction during assisted delivery in almost one third of cases. 59 out of 73 cattle treated

conservatively and 7 out of 9 treated surgically were healed. In 38 animals the fracture healed without malposition; 28 developed a shortening or bending of the affected limb, which with exception of one case, did not functionally impair the animals. Complications occurred in 22 patients; in closed fracture this was predominantly due to dislocation of the fragments within the cast, whereas an osteomyelitis was usually the cause in the case of the open fractures.

St-Jean *et al* (1991) reviewed medical records of 5 calves with tibial fracture that were reduced and stabilized by transfixation pinning and casting. Multiple Steinmann pins were placed transversely through proximal and distal fracture fragments and the pin ends were incorporated in fiberglass material after fracture reduction. Cast material served as an external frame to maintain pin position and fracture reduction. After surgery all calves were ambulatory within 24 hours. To improve tarsal fixation and achieve normal stance in 3 calves, cast revision was required on the caudal aspect of the limb. Good radiographic and clinical evidence of stability was observed in 5-10 weeks (mean 8 weeks), at which time the pins and casts were removed. Return of normal function was rapid and judged to be excellent at follow-up evaluation 3-12 months later. Advantages of transfixation pinning and casting in management of tibial fracture includes flexibility in pin positioning, adequate maintenance of reduction, early return to weight bearing status, joint mobility and ease of ambulation. The inability to adjust fixation and alignment after cast application is a disadvantage of this technique, compared with other external fixators.

Banner (1992) suggests a method of fracture stabilization under laboratory condition by Farley compression boot. Although the studies were conducted on a limited number of limbs, the device appeared to reduce stress, acting on the distal third of metacarpus and the first phalanx.

Mukherjea and Sahay (1992a) made clinico-radiographic evaluation of biological osteoinducers in the healing of compound fracture in goats. Radiographic signs of early osteogenesis, obliteration of fracture gap by osseous tissue in 4 weeks and complete union and normal periosteal contour after 6 weeks occurred.

Mukherjea and Sahay (1992b) made histomorphological studies of compound fracture healing with biological osteoinducers in goats. Two biological osteoinducers viz. fresh autologous bone marrow and homologous pulverized bone were used locally in cases of compound fracture in goats. The histological evidence suggested that bone marrow exerts salutary effects in the healing process to a moderate degree only. By 6th week newly formed bone tissue increased in the compact substance with marrow spaces and Haversian system were conspicuous but osseous activity was in progress. When pulverized bone with marrow was used the features of osteogenesis were appreciable by 4th week and by the end of 6th week abundance of osteons, thicker bony trabeculae with varying marrow spaces and significantly decreased vascularity of the periosteum were observed. In control animals compound fracture was associated with delayed healing and inadequate calcification by six weeks, apart from massive

infection and non-union in one animal each.

Steiner et al (1993a) retrospectively evaluated 58 shaft fractures of the metacarpal and metatarsal in cattle using a new radiographic scoring system. Open reduction and internal fixation provided significantly better long term results than external coaptation. A significant correlation was found between the quality of the fracture reduction and the long term result. A correlation was not found between age and body weight of the animal and the outcome, nor between the time that elapsed from trauma to treatment and the outcome.

Steiner et al (1993b) evaluated physeal fractures of the metacarpus and metatarsus in 16 cases of cattle retrospectively using a new radiographic score system. 13 animals were treated by full limb cast, 1 by modified walking cast and 2 by open reduction and internal fixation. A significant negative correlation was found between the body weight of the animals and the time that elapsed from trauma to treatment respectively, and the long term result. A correlation was not found between the quality of the fracture reduction and the long term result.

Auer et al (1993) reviewed internal fixation of long bone fractures in 46 farm animals. 21 animals (46%) were treated using external fixation and 16 (35%) with internal fixation, one case was treated without any fixation by simple stall rest. In 8 (17%) animals no therapy was performed because of economic reasons. The cases managed with external coaptation involved mainly closed reduction treatment of distal physeal fractures of metacarpal III/IV and metatarsal III/IV and healed without

complications. Out of the 16 animals treated with internal fixation, 15 were cattle and one was a sheep. In 14 AO implants namely dynamic compression plates and dynamic condylar screws were used. Ten of 16 cases (63%) resulted in successful outcome. One case had to be treated twice but eventually turned out successfully. In another case, partial breakdown of the fixation developed but the fracture healed with a minimal hyperextension deformity. Both humeral fractures (12.5%) and both proximal tibial fractures (12.5%) failed shortly after recovery from anaesthesia and initiation of weight bearing on the repaired bone. The greatest disadvantage of the described treatment are the costs of the surgery and implants.

Dubey *et al* (1993) used intramedullary nails prepared from bovine horn for management of transverse femoral fractures in 4 dogs in an experimental study. A disadvantage of the horn pin was the difficulty in visualizing them radiographically, but the advantages were the ability to shape the pins individually, the lack of reaction in contact with the endosteum and larger periosteal callus with better fracture healing than with metal pins.

Ross and Matthiesen (1993) successfully treated orthopaedic injuries in 74 dogs using multiple pin and methylmethacrylate external skeletal fixation. The major advantages associated with use of the technique included increased versatility in the location and angle of fixation pin placement and greater ease in placement of the connecting bar when compared with conventional clamp and connecting bar systems, particularly with transarticular placement of a device. The

major disadvantages associated with the technique included, increased difficulty compared with conventional K-E systems regarding postoperative adjustment of the device and difficulty in removing individual pins that were loose or infected. Generally, removal of the device was not a problem, provided sufficient space was left between the connecting bar and the skin surface. Complications associated with the technique were similar to studies which have evaluated other types of external fixation and include fixation pin loosening, pin tract drainage or infection, fixation failure, osteomyelitis, angular limb deformity, malunion, delayed union and non-union. The multiple pin and methylmethacrylate external fixator provides a useful and effective method of repair for a wide variety of orthopaedic injuries. The use of methylmethacrylate as a connecting bar is a helpful adjunct to standard external fixation systems.

Salem *et al* (1993) described adaptation of the Ilizarov method for bone surgery in sheep. A fracture of metacarpus was made in 24 sheep and fracture fixation was carried out using a simplified Ilizarov method in 12 sheep and using the Maynard method in other 12. Clinical, radiological and histological examination showed that healing was more rapid and more complete when Ilizarov method was used.

Dixon *et al* (1994) evaluated the effects of three different techniques of intramedullary pin placement on proximal pin location and incidence of stifle joint injury using 70 cadaver canine tibiae after mid-diaphyseal osteotomy. In 50 tibiae, pins were placed retrograde in either a nondirected (group A) or a craniomedially directed fashion (group B) with 25

tibiae in each group. Pins were driven normograde (group N) in 20 tibiae. All the stifles were dissected to qualitatively evaluate pin interference with different joint structures. End-on radiographs of the tibial plateaus were used to quantitatively evaluate pin location. Interference with the caudal cruciate ligament, medial meniscus, lateral meniscus or meniscal ligaments was not observed in any group. There was a significant association between pinning technique and incidence of involvement of the cranial cruciate ligament, patella, patellar ligament and femoral condyle. Pin location for group A was significantly different from either other group in a cranial-caudal direction and was significantly different from group N in a medial-lateral direction. No significant difference was observed between pin location for group B and N in either plane. It was concluded that although nondirected retrograde pinning cannot be recommended, retrograde pins directed craniomedially may be an acceptable technique for the repair of proximal to mid-diaphyseal tibial fractures if care is taken to properly seat the pins.

Doiphode (1994) made comparative study of different types of splintage in the treatment of long bone fractures of sheep and goats. Plaster of Paris bandage, outrigger methods using motor cycle spokes and resin impregnated bandage reinforced with bamboo splints were used for immobilization in 3 groups. The resin impregnated bandage reinforced with bamboo splints was simple, economical and effective method for treatment of fractures in sheep and goats.

Duhautois (1995) described the development of locked

intramedullary pinning to overcome some of the problems of classical intramedullary pinning. It was concluded that the technique may be used to stabilize fractures in the long bones of dogs and cats. The advantages of the technique are its simplicity, the stability of the pin and the elimination of sciatic nerve problems.

Mande et al (1995) clinically evaluated some of the plaster casts available in Kenya. The ease of cast breakage, the extent of cast wearing at the foot, the ability to bear weight on the cast limb, the severity of lameness and cast related complications were compared clinically in 3 groups of 6 calves each, cast with different plaster of Paris bandages (Plasrun-gyps, Veronese and Salvagyps) and observed for next 21 days. Cast breakage was seen only in one case in which Plasrun-gyps was used but was observed in most of the cases casted with Veronese and Salvagyps. Cast breakage was more often seen at the midshaft of the metacarpus than at the fetlock. There was marked cast wearing at the foot in all plaster casts. All casts enabled weight bearing in all calves and when lameness was seen to be severe this was due to broken casts whose edges imprinted on soft tissue causing pain. Since Plasrun-gyps had the lowest number of breakage on clinical application, it was considered to be the most suitable for use on calf limbs.

Anderson et al (1995) reviewed the use of a Thomas splint-cast combination for stabilization of tibial fractures in cattle in 21 cases between 1973-1993. The bones of 17 (81%) of the 21 healed. Research indicated that Thomas splint-cast combination was an effective and economical technique for

stabilization of tibial fractures in cattle.

Kofler and Stanek (1995) evaluated treatment of metacarpal and metatarsal fractures in cattle between 1984-1993 in a retrospective study. 19 metacarpal and 8 metatarsal fractures were treated. 24 fractures were closed and 3 were open. 24 cases were discharged after a recovery period of 6 weeks.

Sarkate et al (1995) reported a case of bilateral metacarpal fracture in a goat. Radiological examination demonstrated short oblique fracture of lower third of left metacarpus and transverse fracture of right metacarpus at its proximal third diaphysis. Open reduction and internal fixation with horn plates was performed in both the metacarpals. The horn plates were fixed on lateral surface of bone with one stainless steel screw on each side of fracture line on both the metacarpals. There was functional weight bearing by both the forelimb from 45th post-operative day. It was concluded that bilateral metacarpal fracture in goat could be successfully treated by cost effective horn plating.

***MATERIALS
AND
METHODS***

MATERIALS AND METHODS

The present study was carried out in two groups. Group A consisted of 143 goats which were examined at Surgery clinic of College of Veterinary and Animal Science, Bikaner from a period of July '94 to June '96.

Goats of either sex and various age groups were examined clinically and radiologically for the various fractures. These were treated by an appropriate method of external or internal immobilization technique depending upon the type of fracture and bone involved.

The goats of group B were part of a retrospective study derived from 1262 case records of last 15 years of Surgery clinic to find out the incidence of fractures in goats. This served not only as testimony to the incidence and occurrence of various fractures screened over the past years but also served as a useful data indicating a trend of fractures in goats. The animals of this group lacked elaboration on etiology, symptoms and diagnostic methods adopted, hence served as basal data only.

In order to maintain consistency in recording of clinical cases of various fractures among the animals of group A, a record sheet was prepared (Appendix I) and was filled accordingly. It incorporated the details of animal, history, clinical & radiological examination and treatment.

HISTORY

A detailed case history was recorded for every case in relation to age, sex, duration of injury, clinical signs and possible etiology of the fracture as per the proforma appended (Appendix I).

EXAMINATION

Each animal was thoroughly examined clinically and radiographically. For clinical examination the animal was first observed in standing position to see any difference in gait and weight bearing by the affected limb. The physical examination of the affected limb was done in lateral recumbancy keeping the fractured limb uppermost, for any swelling at the site and type of fracture.

All the cases which were showing no weight bearing and remained suspected for fracture were subjected to plain radiography to assess the type of fracture and possible treatment to be followed.

Lateral or dorsopalmar/dorsoplantar views of the fractured site was taken with radiographic factors as per shown in table 1.

For radiography of plastered limb the mAs was doubled keeping the kV same as on unplastered limb. The film was processed by routine procedure. The animals were also radiographed at regular intervals during the process of healing.

Table 1. Radiographic factors used for lateral or dorsopalmar / dorsoplantar views for various bones.

Limb	View	mAs	kV
A.FORELIMB			
Humerus (Adult)	ML	12	70
Humerus (Kid)	ML	8	60
Radius Ulna	L	8	60
Radius Ulna(Kid)	L	6	55
Carpus, Metacarpus & Digit	DPa	8	55
	L	6	55
B.HINDLIMB			
Femur	ML	10	70
Femur (Kid)	ML	8	60
Tibia	L	8	60
Tibia (Kid)	L	6	55
Tarsus, Metatarsus & Digit	DP1	8	55
	L	6	55

INSTRUMENTS USED

A routine surgical pack with orthopaedic instruments such as pin cutter, pin chunk, muscle separator, bone cutter, hammer, chisel, orthopaedic wire were also used for the internal fixation techniques.

For external fixation the simple coaptation splinting using plaster of Paris cast was used.

Modified Thomas splint was prepared from the aluminium hangers.

ANAESTHESIA

General anaesthesia was given only to the animals undergoing internal fixation. Atropine sulphate was given as preanaesthetic agent at a dose rate of 0.2 mg/kg body weight.

Ketamine and xylazine combination was used for general anaesthesia at the dose rate of 2-4 mg/kg and 0.2-0.5 mg/kg body weight, respectively. The animal was kept off feed for 24 hours prior to operation and no water was offered 12 hours prior to surgery.

TREATMENT

Animals brought to the surgery clinic having fracture of different bones were treated by suitable internal or external fixation techniques. The internal fixation technique was used only in a situation where external fixation was not feasible e.g., fracture of humerus, olecranon process of ulna and femur. For all other appendicular fractures plaster of Paris cast or Thomas splint were used.

IMMOBILIZATION BY INTERNAL FIXATION

Intramedullary pinning

Except for the difference in size and physical factors, the technique for intramedullary pinning in large animals is much the same as that described for small animals and was performed as per the technique described by Archibald (1974) in retrograde fashion with the modification that the pins were made pointed from other side also. Preoperative radiograph was taken to access the size and diameter of the pin. The operation was performed in general anaesthesia. In internal fixation technique single or double intramedullary pinning was done depending upon the age of the animal and diameter of the medullary canal.

Postoperatively animal was administered with

antibiotics for 5 days and antiinflammatory drug for 3 days. Skin suture were removed after 10 days postoperatively. Pin was removed after clinical and radiological union had occurred.

IMMOBILIZATION BY EXTERNAL FIXATION

For external fixation generally plaster of Paris cast was used. In one young animal modified Thomas splint was also used.

Plaster of Paris cast:

The external immobilization with plaster of Paris cast was done as per the technique described by Oehme and Prier (1974). In compound fractures a window was created at the fracture site after 48 hours to facilitate the local dressing. Animal was also given antibiotics for 5 days in cases of compound fractures only.

The plaster of Paris cast was removed after 3-4 weeks in young animal and 6-8 weeks in adult animal.

Modified Thomas splint:

It was used only in one case of fracture of humerus in young kid where there was no displacement of fractured fragments. Aluminium hanger was used for this purpose. The splint was prepared as per the technique described by Brinker et al (1983). The splint was removed after 3 weeks.

In one young animal with 7 day old undisplaced fracture of femoral neck Velpaeu bandage was applied as per technique described by Whittick (1974).

EVALUATION PARAMETERS

Healing of the fracture was evaluated clinically and radiographically at weekly interval in young animal and at 15 days interval in adult animal.

1. Clinical examination: The animals were observed clinically for lameness, weight bearing, local swelling, any complication etc. from the treatment day till the healing had occurred.

2. Radiological examination: The plain radiographs were taken immediately after internal fixation and after 7, 14 and 21 or 28 days in young and 15, 30, 45 and 60 days in adult animals. The radiographs were taken mediolaterally for all bones except for phalanx fracture where anterior-posterior view were taken.

In cases of external fixation the radiographs of plastered limb were taken at 7, 14 and 21 or 28 days interval in young animal and 15, 30, 45 or 60 days interval in adult animal.

OTHER TREATMENT

In one animal having fracture of third phalanx with infection at site surgical amputation of the third phalanx was done.

In one adult animal having fracture of ileum the blister (bin iodide of Mercury) was applied at the fracture site.

In one animal with old fracture of mandible external support was provided.

***RESULTS
AND
DISCUSSION***

RESULTS AND DISCUSSION

In the present study 966 cases of various caprine surgical ailments were screened of which 143 showed fracture and were categorized as group-A. In a 15 years retrospective study out of 10515 caprine cases of various surgical ailments screened, 1262 showed fractures and these comprised group-B.

INCIDENCE

The incidence of fractures was 14.80% and 12.0% in animals of group A and B, respectively. The overall incidence of fractures was 12.23%.

Hind limbs sustained more fractures than forelimb as reflected in the incidences viz. 41.25% and 40.96% for the fore limb and 56.64 and 56.10% for the hind limb, in the animals of group A and B, respectively (Appendix IV). Similar findings were observed by Singh *et al* (1983) in their study on 78 clinical cases of fractures in caprine. Patil *et al* (1991) studied 471 clinical cases of fractures of domestic animals and aves and also found higher incidence of hind limb fractures (69.4%) as compared to fore limb (30.6%). Similarly Ganesh *et al* (1994) found higher incidence of orthopaedic ailment of pelvic limb (70%) than of pectoral limb (30%) in a survey conducted on 107 large animals.

The incidence of open fracture was 6.29% and 6.65%, in

the animals of group A and B, respectively. However, Brinker *et al* (1983) reported 5% incidence of open fractures in canines.

A sex ratio vis-a-vis fractures revealed higher incidence of fractures in females (71.32%) than males (28.67%) in the animals of group A (Appendix II). Similar findings were recorded by Singh *et al* (1983), who also found higher incidence of fractures in females (69.23%) than in males (30.76%). Patil *et al* (1991) also observed higher incidence of fracture in females than males in domestic animals except donkey, camel and dog, where males showed higher incidence. Contrarily Phillips (1979) found higher incidence of fracture in male (58.1 and 68.3%) as compared to female (41.3 and 31.7%) in cats and dogs, respectively.

An age vis-a-vis fractures comparison revealed higher incidence of fracture in animals of age group below 1 year in the animals of group A (Appendix III). The incidence of fracture below 1 year, between 1-3 year and above 3 year was 52.44, 38.46 and 9.09%, respectively. Similarly Phillips (1979) found higher frequency of fractures in age group below 1 year (51.7 and 49.5%) than between 1-3 year (26.5 and 30.32%) and above 3 years (21.8 and 20.1%) in dogs and cats, respectively. Ganesh *et al* (1994) also reported higher incidence of orthopaedic ailments below 1 year of age (64.68%) than between 1-4 year (30.84%) and 4-8 year of age (4.67%) in a survey conducted on 107 cases of large animals.

Contrary to the present finding Singh *et al* (1983) found incidence of fracture as 32.05, 46.15, 16.66 and 5.12% in animals of age group below 1 year, between 1-3 year, between 3-6

year and above 6 years of age, respectively in caprine. They also found higher incidence of fracture in age group of 1-3 years in bovine but in equine and canine it was higher in animals upto 1 year of age.

Higher incidence of hind limb fractures, as observed in the present study may be due to frequent traumatization of hind quarter as a result of hitting on hindquarter, overrun by cycles/ automobile in narrow streets and close habitations and falling, thus such fractures could be accounted more to the managerial problems.

The lower incidence of fracture in male animals and between 1-3 years of age group could well be accounted to the reason that such animals are frequently slaughtered and at times despite of orthopaedic traumatization slaughtering is preferred over treatment, hence incidence of male animals accrue less for fractures than females.

In the animals of group A most of fractures line were oblique (36.02%), transverse (34.55%) or comminuted (18.24%) in nature where as most of the fractures were across the middle third (66/116), lower third (29/116) and upper third (21/116) of the diaphysis (Appendix V and Figure 4, 8, 9, 11, 15, 19, 20, 21, 22, 26, 27, 28 and 33).

Singh et al (1983) also reported that most of the fractures involved shaft of the bones and were either comminuted, oblique or transverse in nature. They found higher incidence of comminuted (38.5%), followed by oblique (30.5%) and transverse (12.2%) fractures in cattle. These together constitute 81.2% of all the fractures recorded. In goat they found 25.6, 40.0 and

29.7% of fractures to be transverse, oblique or comminuted, respectively while in dogs percentage of these fractures were 45.1, 35.0 and 14.6, respectively.

Pfeiffer (1977) also reported higher incidence of diaphyseal fracture (74%) of tibia in dogs as compared to epi or metaphyseal fracture (26%).

Patil et al (1991) also found that most of the fractures involved shaft of the bones and were either comminuted, oblique or transverse in nature, regardless of the species.

Majority of fractures of femur, tibia and phalanx involved proximal and middle third (Figure 4, 7, 8, 9, 11, 20, 21, 22, 26, 39, 41, 42 and 43) while in metatarsal, humerus, radius ulna and metacarpal middle and distal third of the diaphysis was involved (14, 15, 16, 17, 27, 29, 30, 31, 33, 36 and 38). Singh et al (1983) recorded majority of fractures of humerus and tibia in the proximal and middle third, whereas, radius ulna, metacarpal, femur and metatarsal fractures were mostly across the middle and distal third.

Owing to the lack of information on the record sheet in the animals of group B, the sex ratio, age wise distribution and type of fracture could not be determined.

FORE LIMB

The various bones in order, upper to lower ones, will be discussed.

SCAPULA

The incidence of fracture of scapula was found as minimal as 0.47% in the animals of group B, where as animals of

group A did not reveal these fractures. The lower incidence of scapula fracture has been reported by Reichel (1956) in equine and bovine (1%), Phillips (1979) in dogs and cats (1.4 and 0.3%, respectively) and Singh *et al* (1983) in bovine (0.37%). Ferguson (1982) and Tyagi & Singh (1993) also reported rare occurrence of these fracture in cattle.

HUMERUS

The incidence of humerus fracture was found to be 8.39% in the animals of group A, whereas it was 6.10% in the animals of group B. Out of 12 animals of humerus fracture in group A, 4 were male and 8 were female. 6 animals were below 1 year, 5 were between 1-3 years and 1 was above 3 years of age group.

Incidence of humerus fracture was found to be 5% by Reichel (1956) in equine and bovine; 4.4 and 7.7% in cats and dogs, respectively, by Phillips (1979); 5.1% in sheep and goat by Singh and Nigam (1981); 5.1, 7.5 and 13.2 % in caprine, bovine and canine, respectively, by Singh *et al* (1983); less than 5% in cattle by Ferguson (1982); 4.3% in cattle by Adams (1985); 7.3 and 13.3% in bovine and canines, respectively by Patil *et al* (1991) and 5% in cattle by Tyagi and Singh (1993).

RADIUS ULNA

During the course of present study the incidence of fracture in radius ulna was 7.69% in the animals of group A and 6.97% in the animals of group B. Out of 11 animals of group A, 3 were male and 8 were female. 4 animals were below 1 year of age, 6 were between 1-3 year of age and one was above 3 year of age

group.

Reichel (1956) observed slightly lower incidence of radius ulna fracture (6%) in equine and bovine. Peital (1971) found incidence of radius ulna as 10% in equine. Relatively higher incidence of radius ulna fracture was observed by Phillips (1979) in cats (8.4%) and dogs (17.3%).

Contrarily, Singh and Nigam (1981) found lower incidence of radius ulna fracture in sheep and goat (3.8%). Similarly, Singh et al (1983) also found lower incidence of radius ulna fracture in caprine (3.8%) but higher in bovine (11.1%), equine (18.1%) and canines (16.5%).

Incidence of radius ulna fracture was found to be 7% and 10.84% as reported by Ferguson (1982) and Adams (1985), respectively in bovines.

Dass et al (1985) found comparatively higher incidence of radius ulna fracture (10.18%) in goats.

Patil et al (1991) found the incidence of radius ulna fracture to be 7.2% in goats which is similar to the findings of present study. But they found higher incidence of these fractures in bovine (18.7%) and canine (11.4%).

Tyagi and Singh (1993) found 7-11% incidence of radius ulna fracture in cattle and buffalo.

METACARPAL

The animals of group A showed 21.67% incidence of metacarpal fracture, whereas it was 27.41% in the animals of group B. Out of 31 animals of metacarpal fracture of group A, 10 were male and 21 were female. Seventeen animals were below 1

year of age, 12 were between 1-3 years of age and 2 were above 3 years of age group. 4 out of 31 animals showed open fracture.

Reichel (1956) also found higher incidence of metacarpal fracture (21%) in equine and bovine.

Peital (1971) observed lower incidence (9 and 11%) of metacarpal fracture in equine and bovine, respectively.

Lower incidence of metacarpal fracture in dogs (4.6%) and cats (1.3%) was observed by Phillips (1979).

Singh and Nigam (1981) reported 15.3% incidence of metacarpal fracture in sheep and goat. Singh et al (1983) reported the incidence of caprine, bovine, equine and canine metacarpal fracture to be 15.3, 10.8, 18.1 and 1.6%, respectively.

Ferguson (1982) reported combined incidence of metacarpal and metatarsal fracture to be 50% with more involvement of metacarpal bone.

Adams (1985) found higher incidence (29%) of metacarpal fracture in cattle. Dass et al (1985) found highest incidence of metacarpal fracture (36.11%) in an analysis of 108 cases of fractures in goat.

Patil et al (1991) found 23.2% incidence of metacarpal fracture in goats which is similar to the observation of present study. They also reported incidence of metacarpal fracture to be 16.4 and 46.6% in bovine and sheep, respectively.

Tyagi and Singh (1993) reported lower incidence (10.8%) of metacarpal fracture in bovine.

HIND LIMB

FEMUR

The incidence of femur fracture in the animals of group A and B was 11.18 and 9.82%, respectively. Out of 16 animals of femur fracture in group A, 2 were male and 14 were female. 6 animals were below 1 year of age group, 8 between 1-3 year age group and 2 were above 3 years age group.

Reichel (1956) found lower incidence (7%) of femoral fracture in equine and canine.

Contrarily Peital (1971) found higher incidence (17%) of femur fracture in bovine.

Phillips (1979) also observed higher frequency of femur fracture in cats and dogs as 28.2 and 14.8%, respectively.

Singh and Nigam (1981) reported highest incidence of femur fracture (32%) in sheep and goat. Singh et al (1983) also reported highest incidence of femur fracture in caprines (32%). They also reported incidence of femur fracture to be 4.8, 22.7 and 35.5% in bovine, equine and canines, respectively.

Adams (1985) reported 15% incidence of femur fracture in cattle. Dass et al (1985) reported 12.03% incidence of fracture of femur in goats.

Patil et al (1991) reported lower incidence of femoral fracture in goats. It was below 7.2% as reported for radius ulna fractures but they found higher incidence of femur fracture 19.0 and 35.0% in bovine and canines, respectively.

Tyagi and Singh (1993) found less than 5% incidence of femur fracture in cattle.

TIBIA

The incidence of tibial fracture was found to be highest (25.17%) in animals of group A, while it was 16.71% in the animals of group B. Out of 36 animals of group A with tibia fracture 13 were male and 23 were female. 22 animals were below 1 year of age, 11 were between 1-3 year of age and 3 were above 3 years of age group. 2 out of 36 animals showed open fracture.

Reichel (1956) reported incidence of tibial fracture in equine and bovine to be 18%. Peital (1971) found the incidence of tibial fracture in equine and bovine as 25 and 13%, respectively.

Phillips (1979) reported lower incidence of tibial fracture in dogs (14.8%) and cats (5.4%).

Singh and Nigam (1981) found the incidence of tibial fracture in sheep and goat to be 21.7%. Similarly Singh *et al* (1983) also reported 21.7% incidence of tibial fracture in caprine. They also reported the incidence of tibial fracture in bovine, equine and canine as 28.7, 13.8 and 22.3%, respectively.

Ferguson (1982) and Adams (1985) reported 12 and 15% incidence of tibial fracture in cattle and equines, respectively.

Contrarily, Dass *et al* (1985) reported comparatively lower incidence of tibial fracture (11.11%) in goats.

Patil *et al* (1991) observed almost equal incidence of tibia (24%), metacarpal (23.2%) and metatarsal (23.2%) fracture in goats. They also reported 27.3 and 34% incidence of tibial fracture in bovine and canine, respectively.

Tyagi and Singh (1993) also reported higher incidence of tibial fractures in cattle (28%) and sheep (22%).

METATARSAL

The incidence of metatarsal fracture was found to be highest among the animals of group B. The incidence of metatarsal fracture was 16.08 and 27.73% in the animals of group A and B, respectively. Out of 23 animals of group A with metatarsal fracture 8 were male and 15 were female. 15 animals were below 1 year of age, 7 were between 1-3 year of age and 1 was above 3 year of age. 2 out of 23 animals showed open fracture.

Lower incidence of metatarsal fracture (7%) was observed by Reichel (1956) in equine and bovine whereas Peital (1971) found it to be 9 and 11% in equine and bovine. Phillips (1979) found it 3.5 and 2.0% in canine and feline, respectively.

Singh and Nigam (1981) reported 10.2% incidence of metatarsal fracture in sheep and goats. Singh et al (1983) found 10.2, 21.2 and 9.0% incidence of metatarsal fracture in caprine, bovine and equine, respectively.

Adams (1985) reported lower incidence (8.6%) of metatarsal fracture in cattle.

Dass et al (1985) reported higher incidence (25.92%) of metatarsal fracture in goats. Patil et al (1991) also found higher incidence of metatarsal fractures (23.2%) in goats.

Tyagi and Singh (1993) recorded 21.2% incidence of metatarsal fracture in bovine.

PHALANX

The incidence of phalanx fracture was 5.59% in the animals of group A, while it was 1.58% in the animals of group B.

Out of 8 cases of phalangeal fracture one was male and 7 were females. 2 animals were below 1 year of age, 3 animals between 1-3 years of age and 3 animals were below 3 years of age group.

Reichel (1956) observed highest incidence (33%) of phalangeal fractures in cattle.

Phillips (1979) observed lower incidence (2.8 and 0.7%) of phalangeal fracture in dogs and cats, respectively.

Singh and Nigam (1981) found comparatively higher incidence of phalanx fracture (6.4%) in sheep and goat as compared to the present study. Similar findings were observed by Singh et al (1983) in caprine. They also found the incidence of phalangeal fracture in caprine, bovine and equine as 6.4, 13.4 and 9.0%, respectively.

The lower incidence of phalangeal fracture in cattle (1.1%) and equines (2.90%) were reported by Adams (1985) and Singh (1992), respectively.

OTHER BONES

The incidence of fractures of other bones was very low in animals of both groups A and B viz. **tarsals** (1.39 and 1.34%), **pelvis** (0.69 and 0.47%), **mandible** (0.69 and 0.63%), **ribs** (0.69 and 0.23%) and **vertebra** (0.69 and 0.47%), respectively.

Reichel (1956) reported the incidence of pelvis as 2% and of spine, scapula and cranium as 1% in equine and bovine.

Phillips (1979) reported higher incidence of tarsals, pelvis, mandible and rib as 5.6 and 4.0%, 15.8 and 24.6%, 2.5 and 11.4% and 1.8 and 0.6% for dogs and cats, respectively.

Singh and Nigam (1981) found higher incidence of pelvis

fracture (2.6%) in sheep and goats. Similarly, Singh et al (1983) also reported incidence of pelvis fracture as 2.6% in caprine. They also found the incidence of pelvis and mandible fracture as 0.3% in bovine and of vertebra as 2.4% in canines.

The minimal incidence of fracture of scapula could be explained on the analogy of its advantageous anatomical location where it remains surrounded by the ribs and muscles hence not commonly predisposed to the direct traumatization which other limb bones are predisposed to.

The higher incidence of fracture of tibia, metacarpal and metatarsal can be explained on the basis that these bones are covered only by skin and fascia with a thin muscular layer, so even a slight external trauma can cause fracture of these bones. The lower incidence of femur and humerus fracture could be due to massive and abundant muscles covering these bones. Comparatively lower incidence of humerus fracture as compared to femur is because the bone is relatively thick and short so it is not easily predisposed to fracture. Lower incidence of radius ulna fractures may be due to its paired nature.

Higher incidence of fractures in young animal below 1 year could be due to thin cortex of the young animals as compared to the adult ones. The young animals, being naughty are more prone to external traumatization by falling or other means.

ETIOLOGY

In the animals of present study, the various etiological agents causing fractures in goats, recorded as per history were : contusion (51), accidental injury (28), falling on ground from height (21), trapping in the cow catcher (8), dog bite (3) and unknown etiology (32).

The incidence of orthopaedic problem in sheep and goat is highest. Ganesh *et al* (1994) found incidence of orthopaedic problem in sheep and goat, cattle, buffalo and other species as 62.6, 34.5, 1.0 and 1.9%, respectively.

The most common cause of fracture remained external trauma in animals of present study. Contusion injuries like lathi blow while goats are taken to open pastures, stone throwing by the children or while grazing in others field, falling of brick or stone and stepping by cows/buffalo over legs where common husbandry practices are adopted, constitute the major cause of fracture in the animals of group A.

Goat is a poor man's cow and is being kept as a milch and meat animal. Males are sold out for meat purposes. Most of the goat owners live under hardship and in close habitation. Goats are usually kept on road/street side thus are more predisposed to cycle/automobile accident, dog bite etc. In the animals of present study cycle, motor cycle, auto-rickshaw, scooter, tonga and camel cart wheel accident causing fractures were brought for treatment. Generally the animal is hit from behind by these objects or they overrun the animals leg while they were sitting, thus causing more hind limb injuries

particularly of tibia and cannon region. Similar findings of higher number of hind limb fractures and more incidence of tibia and cannon bones fracture were observed during the course of present study.

Falling on ground from height was also a common cause of fractures in the animals of group A. Falling of the animals from boundary wall, stairs and roof of the house were observed during the course of this study. Goat, particularly kid, being naughty frequently step up on stairs, roof or boundary wall and when they fall from height get traumatized and fractured.

Stepping in a hole or a trench while running or when leg is caught in a cow catcher or in a gate have also been reported to cause trauma leading to fracture during the course of present study.

Goats often fall pray of street dog. Fractures due to dog bite injury or trauma resulting from running of animal due to fear of a dog and subsequently falling or accident were also recorded in the present study.

Dass et al (1985) in an analysis of 108 cases of fractures in the hilly terrain of the Chhotanagpur showed that over half of the fractures resulted from falls and only 20 from traffic accidents.

Spontaneous or pathological fracture were not recorded in the present study. Although these may be sequel to the tumor and cyst, osteoporosis, localized bone infection and rickets etc. (Tyagi and Singh, 1993).

CLINICAL SIGNS

Table 2: Clinical signs of fractures recorded for various bones.

	Weight bearing	Abnormal deviation	Local Swelling	Pain on Palpation	Crepitation
Femur	No	Less	More	Less	Less
Humerus	No	Less	More	Less	Less
Tibia	No	More	Less	More	More
Radius-					
Ulna	No	More	Less	More	More
Metatarsal	No	More	Less	More	More
Metacarpal	No	More	Less	More	More
Phalanx	No	Less	More	Severe	Less

Following symptoms were commonly observed in all the animals of group A which were presented for treatment.

- i) Absence of weight bearing
- ii) Abnormal deviation
- iii) Local swelling
- iv) Pain on palpation
- v) Crepitation

Absence of Weight bearing

All the animals which were brought for the treatment did not bear weight by the affected limb. Affected limb was kept in semi flexed stance with toe touching the ground while standing, but during locomotion animal limped with the affected limb with partial to complete absence of weight bearing.

Abnormal deviation

The pathognomic sign - abnormal deviation was observed

in all fractures of long bones. It was inappreciable in digital fractures. Amongst long bones such an abnormal deviation was visibly evident in fractures of radius ulna, tibia, metacarpal, metatarsal but was confirmed on palpation in fractures of femur and humerus. The reason for this was that humerus and femur are covered with thick muscles and associated inflammation restricts movement of the fractured fragment. In humerus and femur fractures the limbs showed excessive abduction and adduction. Digital fractures did not reveal such deviation possibly because of their small size and lack of space in neighbouring area.

Local swelling

A swelling was most marked in the fractures of the femur followed by humerus, phalanx, radius ulna, tibia and cannon bones. Swelling at the fracture site occurs as a result of tearing of soft tissue including the periosteum and surrounding muscles and rupturing of blood vessels across the fracture line resulting in formation of haematoma.

Pain

Pain was evidenced on palpation of fractured fragment. Degree of pain was comparatively less in humerus and femur fractures than radius ulna, tibia, metacarpal and metatarsal fractures. Pain was severe in cases of phalangeal fracture as evidenced by flinching and groaning by the animal on palpation of digital area.

Crepitation

It was produced by moving the proximal and distal fractured fragment against each other. The crepitation was heard more pronounced in tibia, metatarsal, radius ulna and metacarpal fracture than femur and humerus fractures. This may be due to interposition of soft tissue between the fractured end in the femur and humerus fracture as these are covered by heavy muscles while other long bones lack abundance of soft tissue around them.

In the present study one animal with fracture of lumbar vertebra accompanied with paralysis was seen. This animal didnot recover even after removal of fractured fragment causing compression. However, animal survived for two weeks but died later on.

Open fracture

In these fractures an open skin wound extended down to the bone injury. Fresh wounds were sutured under aseptic condition before applying the plaster of Paris cast.

TREATMENT

The fractures of animals of group A were treated by either external or internal fixation technique (Appendix VI). The internal fixation was performed in 22 out of 143 animals (15.38%) while 110 out of 143 animals (76.92%) were treated by external fixation technique. Rest of the animals were either

treated surgically or by other methods. The animals of group B lacked adequate information on treatment, hence the treatment will be discussed in respect of group A only.

INTERNAL FIXATION

The internal fixation technique was accomplished by using stainless steel intramedullary pin of 2 or 3 mm diameter for immobilization of fractures of humerus, olecranon process and femur in 22 animals. Femur and humerus fracture were treated by single intramedullary pinning technique in 7 and 6 animals, respectively while double intramedullary pinning technique was used for repair of femur and humerus fracture in 5 and 2 animals, respectively. The cerclage wire was used in 5 animals having oblique/multiple fractures along with intramedullary pinning. Out of 2 animals with fracture of olecranon process of ulna one was treated by intramedullary pin using tension band wire while other without it. Three animals of humerus and femoral fracture each were not presented for treatment by the owner.

Out of 7 animals with fracture of femur immobilized by single intramedullary pinning technique clinical and radiological union occurred in 4 weeks in 3 animals (Fig. 2 and 9). Remaining four cases showed complications viz impaction of fracture fragment (Fig.10), splitting of the upper fragment (Fig.7), migration of pin with (Fig. 9) or without union (Fig.12) and seroma formation beneath the skin.

Out of the 5 fractures of femur immobilized by double intramedullary pinning technique 3 animals showed clinical and radiological union in normal duration of 6-8 weeks (Fig.1, 4, 5

and 6). Two animals showed complications viz. migration of both pins from distal extremity gradually (Fig. 5 and 6) and migration of pin from upper extremity after infection and tearing of skin resulting in non-union.

Out of 6 animals of humerus fracture treated by single intramedullary pinning 3 showed clinical and radiological union after 3 to 4 weeks (Fig.14 and 16). One animal showed complication viz. lateral deviation of the fracture fragment (Fig.16). Follow up examination of two animals could not be made.

Two animals of humerus fracture treated by double intramedullary pinning showed clinical and radiological union with massive callus formation in 6-8 weeks (Fig.17 and 18). One animal showed retention of intramedullary pin in the medullary cavity without any ill effect (Fig.18).

Out of 2 animals of fracture of olecranon process, one treated by intramedullary pin (2 mm) with tension band wire showed good immobilization and healing (Fig.40) The other animal where only intramedullary pin was used for reduction, fractured fragment could not be reduced resulting in non-union.

In all the animals the operated wound healed by first intention. In the young animal the follow up was done after 7 day while in the adult animal the follow up was done after 15 day. In the young animal partial weight bearing was started after 2nd week postoperatively while in the adult it started after about one month. Complete weight bearing was observed after 3 weeks. Such animals showed all signs of clinical union.

Radiologically the periosteal reaction was observed at

second week. Partial obliteration of the fracture gap was observed at this time by formation of anchoring and sealing callus but at this time fracture line was still demonstrable. A complete obliteration of fracture line and formation of a bridging and uniting callus was observed at 4th week. The density of this callus was comparable to the normal cortex. Grossly well developed internal callus was palpable at the fracture site suggestive of the clinical union.

A well developed external callus in the animals of present study suggested little movement at the fracture site following intramedullary pinning. This finding is in corroboration with the findings of the Braden and Brinker (1976) in dogs, Chawla et al (1983a) in tibial fracture of sheep and Dubey et al (1993) in femoral fractures of dogs immobilized with intramedullary nail prepared from bovine horn.

Immobilization using intramedullary pin is a popular method of treating a variety of fractures particularly transverse and oblique fractures of long bones such as femur and humerus in small animals. Although intramedullary pin provide immobilization of the fracture fragment not as rigid as obtained in compression plating hence little movement at the fracture site makes external callus more pronounced. In the animals of group A most of the fractures of femur and humerus were diaphyseal (27/28) and were either transverse (8/28) and oblique (15/28) in nature so intramedullary pinning was preferred for internal fixation of fractures of these bones. Plating though offers the advantage of rigid internal fixation, early weight bearing and primary bone healing, is a complex technique and requires special

tools for its application thus becomes uneconomical too for a marginal farmer who keeps goats.

In the present study 3 animals which underwent single (2) and double (1) intramedullary pinning showed migration of intramedullary pin from distal extremity and one animal had migration from proximal extremity. In the animals with single intramedullary pin the migration of pin occurred after clinical and radiological union in one animal (Fig.9) while other showed migration without healing resulting in non-union (Fig.12). The animal with double intramedullary pinning showed migration of first pin after 4 weeks of immobilization with slight periosteal reaction. The second pin showed migration after 8 weeks till such time clinical and radiological union had occurred (Fig.5 and 6).

In one animal with double intramedullary pinning both pins migrated from proximal extremity on 3rd post operative day and appeared subcutaneously. These were driven back but next day it got loosened and came out through the necrosis of the skin forcing its removal resulting in infection at the site and non-union of the fracture. Vaughan (1975) also observed migration of pin causing stifle joint stiffness. Selection of improper size of the pin, not fitting in the medullary cavity closely, causes movement at the site resulting in interference with healing and non-union may result. A loosely fitting pin tend to rise up the medullary cavity, especially in femur and a painful swelling is produced by its protrusion beneath the skin. The pin can be driven back into the shaft but the problem recurs and may enforce early removal of the pin with the risk of producing non-union.

Similarly, a colleague of Hickman (1957) who used 1/2 inch diameter intramedullary pin for repair of fracture of femur in cattle observed distal migration of the pin as weight of the pin forced its way through the distal extremity of the bone and protruded through the skin in the stifle region.

Chawla et al (1983a) also observed slight distal migration of pin in 3 out of 12 animals. Radiological union of the bone occurred at 9th week, with more discrete and radiodense osseous callus, the density of which was comparable to the normal cortex.

Singh et al (1984) also observed proximal or distal migration of pin as a major complication associated with intramedullary pin fixation in tibial fractures. The two main factors causing migration of the pin observed by them were firstly insufficient size and diameter of pin not filling the medullary cavity and secondly, improper embedding of the pin in the distal fragment or pin is driven too far in the distal fragment.

Pin migration and infection was also observed in 2 out of 3 cases of femur fracture in cattle resulting in non-union by Tulleners (1986).

Singh et al (1987) also observed proximal migration of both pin in a mid shaft femur fracture created in an experimental calf leading to displacement of fractured end by 10th day. Slight proximal or distal migration was also observed in 2 animals.

Whitney and Schrader (1987) observed distal pin

migration as major complication of dynamic intramedullary crosspinning technique. The pin migrated before bony union in two animals because of the instability and collapse at the fracture site. The pin migrated in 8 animals after bony union and was associated with intermittent lameness which resolved after removal of the pin in 5 of these cases.

Singh et al (1988b) also observed migration of pin in internal fixation of humeral fractures in 18 experimental cow calves immobilized by single or double intramedullary pinning.

Infection seen in the animal with the double intramedullary pinning with proximal migration is also observed by many workers. Lundvall (1960) and Vaughan (1975) observed osteomyelitis as most common complication of intramedullary pinning in large animals and dogs, respectively. Mohanty (1970) also reported overriding and infection as most common complications associated with intramedullary pinning in calves.

Rittmann and Parren (1975) found that 20% of the internally fixed bone fractures became infected. They also concluded that even massive infection doesnot destroy the healing process in cortical bone under stable conditions and the stabilizing implant should be left *in situ*.

Ames (1981) also observed slight infection associated with double intramedullary pinning in 1 out of 3 cases of repair of femur fracture in calves.

In one animal of group A, where intramedullary pinning was performed for the repair of femur fracture seroma formation around the proximal end of pin beneath the skin was observed. The fracture healed with the impaction of the fractured fragment

(Fig.10). The seroma resolved after the removal of pin. Seroma formation following repair of femur by intramedullary pin has been attributed to the swinging motion of the proximal end of the pin during ambulation (Stick and Derksen, 1980). This complication resolves following the removal of the pin.

Impaction of the fractured fragment occurs in the oblique fracture treated with intramedullary pinning as it caused both lateral and longitudinal displacement of the fractured fragment. Similar findings were observed by Lawson (1963) and Mohanty (1970).

Lateral displacement of the fractured fragment immobilized with single intramedullary pinning resulted in malunion in one case of transverse fracture of humerus in the present study (Fig.16). Lawson (1963) also opined that lateral displacement of the fractured fragment occurs in transverse fracture if the diameter of the pin is too small as compared to the medullary cavity.

Splitting of the upper fragment was observed in one case of fracture of femur in the animals of the present study immobilized with single intramedullary pin (Fig.7). True splitting was not observed in this case as there was longitudinal fracture in the proximal fragment which got detached and appeared as splitting. Lawson (1963) described splitting of the fractured fragment as a result of large diameter of the pin as compared to the medullary canal.

In the present study cerclage wire was used effectively to immobilize the fractures along with single or double intramedullary pinning in 5 cases of oblique fracture of femur

(4) and humerus (1).

Hinko and Rhinelanders (1975) effectively used cerclage in the treatment of long bone fractures in dogs. Similarly Withrow and Holmberg (1977) successfully used cerclage wire and refuted all the controversy of the past regarding the complications of cerclage wire.

Contrary to this finding Newton and Bruce Hohn (1974) observed non-union when cerclage appliances were used with intramedullary pinning in dogs. They opined that cerclage wire interferes in circulation and provides inadequate stabilization and ultimately results in motion.

In the animals of present study fractures of femur and humerus immobilized by double intramedullary pinning showed less complication as compared to the single intramedullary pinning. In animals which underwent double intramedullary pinning, though healing occurred at par with animals underwent single intramedullary pinning but the complications were minimum as compared to single intramedullary pinning. This might be due to better stabilization of the fractured fragments, lesser tendency of rotation and greater strength of the implant. Lawson (1963) advocated use of more than one pin for the repair of fractured fragment as complications of intramedullary pinning were associated with improper size of the pin. The intramedullary pin must neither be too slack that it fails effectively to immobilize the fracture nor so large that it is liable to split the cortex of the bone when inserted into the medullary canal. Use of a single large pin instead of multiple pin causes breaking of the fractured fragment and also distal migration of the pin due to

its weight.

Kagan (1983) also found several advantages of using multiple intramedullary pin. Thin, flexible pin may follow the curvature of the medullary canal. Each pin is immobilized in the proximal and distal metaphyseal region as well as by contact with diaphyseal cortex and other pins in the canal. The entire unit acts as a tension bar protecting the fracture line from rotational stress.

Singh et al (1986) also used double intramedullary pin for repair of fracture of femur in experimental calves and reported that use of double pins is not inferior to K-nail provided that migration of pin does not occur.

Tyagi and Singh (1993) also advocated use of two or more pins together in adult animal, especially for the repair of femur and humerus fracture.

EXTERNAL FIXATION

Simple coaptation splinting was the preferred method of external immobilization in 108 out of 143 cases where fractures occurred below the stifle and elbow joint. The coaptation was done in 36, 9, 31, 23, 7 and 2 animals with fracture of tibia, radius ulna, metacarpal, metatarsal, phalanx and tarsal bones, respectively.

Thomas splint was applied in only one animal with undisplaced humerus fracture (Fig.13), while one animal with fracture of femur neck was treated by applying Velpaeu bandage and stall rest (Fig.3).

Simple coaptation cast is the most common, economic and

effective method of external fixation. In spite of its disadvantages simple coaptation cast is most widely adopted and standard technique of external fixation in fractures upto the level of stifle and elbow joint. Plaster of Paris cast has a disadvantage of being heavier and is not resistant to moisture and loses its strength after coming in contact with water. Although light weight cast materials like fiberglass overcome these disadvantages but are expensive limiting its use in clinical cases and is also difficult to mould according to shape of limb.

Normal healing with simple coaptation cast was observed in 5, 18, 20, 13 and 6 animals having radius ulna, tibia (Fig.24 and 26), metacarpal (Fig.34, 35, 36 and 37), metatarsal (Fig.29, and 31) and phalanx fracture (Fig.42 and 43), respectively.

The healing was monitored clinically and radiographically at weekly intervals in young animals below 1 year of age group upto 3-4 week while at 15 days interval in adult animals upto 45-60 days.

Soon after the application of simple coaptation cast animal did not bear weight on the plastered limb and showed limping or dragging of limb during locomotion. It was probably due to inconvenience to the animal due to weight of the cast, extended limb or inability to flex and pain as a result of interfragmentary movement.

Inclusion of hock joint in the simple coaptation cast in the hind limb restricted the movement of the animal as it kept the limb in extended position without touching the ground.

By the end of the first week in young animal and 15 days in adult animal partial weight bearing was seen in the affected limb but animal continued to drag its limb. By the end of second week in young animal and 4 week in adult, animal showed near normal weight bearing with slight limping during locomotion. By the end of 3rd week in young and 6th week in adult when the animal was presented for opening of simple coaptation cast full weight bearing was seen. Grossly after removal of plaster of Paris cast well organized callus was palpable at the fracture site and mobility at the fracture site was not observed suggestive of clinical union.

Radiograph taken at week interval in young and at 15 days post fracture in adult showed beginning of formation of anchoring callus near fractured end. On second week in young animal and 4th week in adult there was formation of bridging and anchoring callus. By the end of third week in young animal and 6 week in adult, the bridging and anchoring callus become more compact with partial obliteration of fracture line. By the end of 4th week in young and 8th week in adult there was complete obliteration of fracture line. There was formation of sealing and uniting callus suggestive of radiological union.

Similar clinical and radiological findings were reported by Gill and Tyagi (1972) in large animals, and Chawla et al (1983a) in tibial fracture healing in sheep.

Even though a perfect weight bearing was observed in animals where clinical union had occurred in cases where fracture was immobilized with simple coaptation cast, the limping

persisted for 3-5 days after removal of the cast and disappeared later on. It may be attributed to the disuse atrophy of muscle and stiffness of the joints during plaster cast immobilization.

Plaster of Paris cast has been considered to be safest method of immobilization for fractures below knee and hock joints in large animals (Kendrick, 1950; Reichel, 1956; Jenny, 1965; Gill and Tyagi, 1972 and Singh and Nigam, 1979).

Reichel (1956) used plaster of Paris cast in 21 animals. The cast was removed after 6 weeks. The lameness after removal of cast usually lasted for 2-4 days. No case of skin damage was observed.

Full limb cast have been used successfully to immobilize fractures of the radius and ulna (Mohanty, 1970; and Mbiuki and Byagagaire, 1984). Least satisfactory results have been achieved in stabilizing tibial fractures in large animals.

Despite significant advances in large animal orthopaedics, the fracture repair of tibia has been problematic. Peculiar anatomical placement of the bone, magnitude of forces, the size and the nature of the animal involved lead either to implant failure or frequent comminution of the fracture. Cast application alone has not proven sufficient and caused joint stiffness and muscle inactivity, sometime making the animal recumbent for prolonged period. Therefore, coaptation splinting particularly in large animal has a distinct disadvantage as stifle joint cannot be incorporated in the cast due to heavy musculature and peculiar anatomy of the tibia. On contrarily the stifle can be incorporated in the cast for tibial fracture repair in goats and these fractures heal with least complication, thus

bear an advantage of the technique as compared to cattle.

Considering these demerits of coaptation cast for tibia fracture repair in large animal various techniques viz. modified Thomas splint (Beckenhauer, 1958; Mohanty, 1970; and Gahlot et al, 1990), transfixation technique (Ganis, 1951; Reichel, 1956; Mohanty, 1970; Gill and Tyagi, 1972; Hamilton and Tulleners, 1980) and hanging pin cast (Lawson, 1963; Gill and Tyagi, 1972) were used with variable results.

In the animals of group A compound fractures of tibia, metacarpal, metatarsal and tarsal bones were observed in 2, 4, 2 and 1 animals. These fractures were treated by creating a window 48 hours later. Dressing was done aseptically with Nebasulf powder (Composition per gram : Neomycin sulphate- 5mg; Bacitracin- 250 units and Sulphacetamide 60 mg; Pfizer Ltd, Bombay) for 7-10 days daily and thereafter on alternate days. Parenterally these animal were given injection oxytetracycline (Oxystecline- Sarabhai, India Ltd.). Compound fractures of tibia were seen in animals between 1-3 years of age group. These animals showed osteomyelitis and delayed union as a result of infection at the fracture site. Oedema occurred at the wound site due to uneven pressure of the cast that ultimately resulted in excessive granulation. One of these animal didnot show union upto 8th week. Plaster cast was though opened at 10th week but signs of delayed union were still present. Medial deviation of the leg at the window site and lack of full weight bearing were observed on 10th week (Fig.25-Left). Other case showed radiological union by 9th week. Skin wound healed in both the cases.

Out of 4 animals with compound fracture of metacarpal bone, two showed delayed union viz. <1 year age group (1) and >3 year age group (1). The other two animals having fresh injuries were sutured aseptically and were then immobilized with plaster of Paris cast. Healing in fresh injuries occurred with first intention. The animal below 1 year of age group showed radiological union by the end of fourth week while other animal showed it by 9th week. The skin in both of these cases healed by second intention.

Out of 2 animals with compound fracture of metatarsal one animal was between age group of 1-3 years of age group showed delayed union while other animal below one year of age group had fresh injury and showed union of the fracture in normal time.

The animal with tarsal bone fracture was not presented for treatment after the application of plaster of Paris cast and creation of window.

Hickmen (1957) also treated one case of compound fracture of metatarsal and metacarpal in cattle and one animal with metatarsal fracture in sheep by application of plaster of Paris cast and creating window. Complication of compound metatarsal fracture were slight contracture of flexors leading to knuckling of the fetlock joint and formation of anchoring callus only at upper end of metatarsal while compound metacarpal fracture showed radiological union after 4 week but the limb remained crooked.

Lundvall (1960) and Jenny (loc.cit) did not recommend plaster cast window in cases of compound fractures because of

uneven pressure leading to oedema, excessive granulation and necrosis but Singh and Nigam (1979) didnot encountered such complications.

Mohanty (1970) observed normal healing in 2 cases of compound fractures one each of metacarpal and metatarsal in experimental calves in 57 days while in 6 clinical cases of compound fracture healing was normal in 5 animal except in one cow in which limb had to be amputed.

Denny *et al* (1988) observed development of osteomyelitis in 2 out of 6 animals immobilized with plaster of Paris cast which were subsequently destroyed.

Complications of simple coaptation splinting during the course of study observed were : viz. malunion, plaster bite, breaking of plaster of Paris cast and tearing of plaster of Paris cast at hoof.

Displacement of fractured fragment and malunion were the most common complications of plaster of Paris cast and were observed in 3, 11, 5 and 6 cases of radius ulna, tibia, metacarpal and metatarsal fractures (Fig.23, 25 Left, 30 and 38). The high incidence of malunion could be attributed to faulty reduction and inadequate immobilization by simple coaptation at the fracture site. Elimination of air spaces of padding material might cause loosening of plaster cast and excess movement during later stages.

However, Rudy and Tharp (1950) considered fracture healing to be satisfactory with faulty alignment leading to malunion for the tibia fracture immobilized by simple coaptation.

Singh and Nigam (1979) observed comparatively larger

periosteal callus formation with plaster of Paris cast and opined that it is directly related to the degree of stabilization of the fractured fragment.

Chawla *et al* (1983a) also observed complications like displacement of fracture fragments, malunion, delayed union and osteomyelitic changes in fracture immobilized by plaster of Paris cast and attributed this to inadequate immobilization and loosening of plaster of Paris cast due to use of thick padding in tibial fracture in sheep.

Rao *et al* (1983) also observed higher percentage of complications like angulation, delayed union and malunion with plaster of Paris cast in buffalo calves.

Singh *et al* (1984) observed that most of the postoperative complication of fracture repair were associated with external immobilization being highest with simple coaptation. The incidence of malunion was highest (18/31). They also attributed faulty union and malalignment of the fractured bone to inadequate stabilization of the fracture site with plaster of Paris cast.

Vijaykumar *et al* (1984) also reported that simple coaptation provides inadequate immobilization, resulting in prolonged lameness and formation of large areas of external callus with angular deformities and malunion. Similar findings were observed by Buchoo and Sahay (1987) in goats.

Denny *et al* (1988) also observed malunion in two calves and non-union in one calf treated by plaster of Paris cast.

Plaster bite occurred in 3 animals of the present study and can be attributed to the excessive pressure applied to the

limb particularly first 2-3 layer of plaster of Paris cast. This causes damage to the skin which subsequently healed after antiseptic dressing.

Lundvall (1960) and Lawson (1963) also reported cases of plaster bite and attributed this to improper padding or application of excessive pressure while putting layers of plaster of Paris.

In one animal of this study the plaster of Paris cast broke due to its poor quality after 10 days. It was removed and reapplied and the animal showed normal healing.

In more than 50% of the cases plaster cast developed cracks and broke from the bottom of the limb due to dragging of the limb by the animal but as only solar surface of the plaster of Paris was broken it had no ill effect on the healing of the fracture. Mande et al (1995) also observed marked cast wearing at the foot in plaster casts.

OTHER TREATMENT:

One case each of fracture of third phalanx with infection at the site (Fig. 41-Left) and fracture of spine of lumbar vertebra were treated by surgical operation. In the case of phalangeal fracture the third phalanx was amputated while in the case of fracture of spine of lumbar vertebra the fractured piece of the bone was removed. But due to injury to the spinal cord the paralytic signs persisted and the animal eventually died. Ferguson (1982) advised amputation of 3rd phalanx particularly when infection is present.

One animal with accidental injury showed fracture of

the ribs, but the animal died due to internal haemorrhage and resultant shock soon after it was brought in for treatment.

The animal with fracture of ileum of pelvis was treated by application of blister at the site and follow up of the animal could not be made. The animal with mandible fracture was presented for treatment after 6 days and was treated by applying external support only. The external support was removed temporarily during suckling. The animal being young made uneventful recovery.

One case of undisplaced fracture of humerus in a kid was treated by Thomas splinting technique (Fig.13). The splint was fabricated by standard technique. At 7 days after application of Thomas splint animal neither bear weight nor showed periosteal reaction at the site radiographically. At second week animal started bearing slight weight on the limb and there was marked anchoring callus around the fracture site as evidenced radiographically. There was formation of bridging callus by the end of the third week and at this time the Thomas splint was removed and animal started bearing weight on the limb. An external callus was palpable clinically with no movement of the fractured fragment suggestive of clinical union. One animal with 7 day old undisplaced fracture of femoral neck was treated by application of Velpeau bandage and follow up could not be made of this animal.

SUMMARY

SUMMARY

In the present study out of 966 cases of various caprine surgical ailments screened 143 showed fractures (group A). In a simultaneous retrospective study of past 15 years, out of 10515 caprine cases of various surgical ailments, 1262 showed fracture (group B). The incidence of fracture was 14.80 and 12.0% in animals of group A and B, respectively and overall incidence was 12.23%

The hind limb sustained more fracture (56.64 and 56.10%) than fore limb (41.25 and 40.96%), in animals of group A and B, respectively. The incidence of open fractures was 6.29 and 6.65% in animals of group A and B, respectively. The animals of group A showed higher incidence of fractures in female (71.32%) than males. The fracture was found to occur more in animals below 1 year of age (52.44%) in this group. Most of the fractures were oblique (36.02%), transverse (34.55%) or comminuted (18.24%) in nature and were across the middle third (66/116), lower third (29/116) and upper third (21/116) of the diaphysis in the animals of group A. Majority of the femur, tibia and phalanx involved proximal and middle third while metatarsal, humerus, radius ulna and metacarpal fracture involved middle and distal third of the diaphysis.

In animals of group A the highest incidence of fracture was found in tibia (25.17%), followed by metacarpal (21.67%), metatarsal (16.08%), femur (11.18%), humerus (8.39%), radius ulna (7.69%), phalanx (5.59%), tarsal (1.39%) and other bones (<1%).

The incidence of metatarsal and metacarpal fractures

(27.73 and 27.41%, respectively) was almost equal in animals of group B, followed by tibia (16.71%), femur (9.82%), radius ulna (6.97%), humerus (6.10%), phalanx (1.58%), tarsals (1.34%) and other bones (<1%).

The compound fractures were mostly found in tibia, metacarpal and metatarsal bones and rarely in other bones.

The fractures of tarsals, pelvis, mandible, ribs and vertebra were though recorded but were rare in occurrence.

The most common etiological agent causing fracture recorded as per history was contusion (51/143), followed by accidental injury (28/143), falling from height (21/143), trapping in cow catcher (8/143) and dog bite etc..

All fractures were treated either with external or internal fixation technique. Internal fixation was performed in 22/143 cases (15.38%) while external fixation was carried out in 110/143 cases (76.92%).

Internal fixation was carried out by single intramedullary pinning (15) and double intramedullary pinning (7) technique. In 5 cases of oblique and multiple fractures cerclage wire was used and in one case of olecranon fracture tension band wiring was done along with intramedullary pinning.

External fixation was accompanied by simple coaptation cast in 108 animals while Thomas splint and Velpaeu bandage was used in one case each.

The compound fracture was treated by creating a window 48 hours after plaster of Paris cast application for regular dressing while the fresh wounds were sutured under aseptic condition before applying plaster of Paris cast.

Healing was monitored clinically and radiologically at one week interval in young animal while at 15 days interval in adult animal. In young animal the healing occurred in 3-4 weeks while in adult it occurred in 6-8 weeks.

The complications encountered with internal fixation were viz. migration of pins from proximal/distal extremity with or without union, impaction of fracture fragment, splitting of the upper fragment, seroma formation and lateral displacement.

The complication of simple coaptation cast observed during the course of study were viz. malunion, plaster bite, breaking of the cast and tearing of the cast at hoof.

Amongst internal fixation the double intramedullary pinning proved efficacious than single intramedullary pinning.

Simple coaptation cast was an effective and economic method for repair of fractures below stifle and elbow joint.

Goat is a good subject for a better and effective postoperative care as compared to large animals because of its light weight and temperament.

CONCLUSION

The following conclusions were drawn from the present study.

1. The overall incidence of fracture was 12.23%.
2. The hind limb sustained more fracture than fore limb.
3. The incidence of open fractures was 6.29 and 6.65% in animals of group A and B, respectively.
4. The animals of group A showed higher incidence of fractures in female than males.
5. The fracture was found to occur more in animals below 1 year of age.
6. Most of the fractures were oblique, transverse or comminuted in nature.
7. In animals of group A the highest incidence of fracture was found in tibia, followed by metacarpal, metatarsal, femur, humerus, radius ulna, phalanx, tarsal and other bones.
8. The incidence of metatarsal and metacarpal fractures was almost equal in animals of group B, followed by tibia, femur, radius ulna, humerus, phalanx, tarsals and other bones.
9. The compound fractures were mostly found in tibia, metacarpal and metatarsal bones and rarely in other bones.
10. The most common etiological agent causing fracture recorded as per history was contusion, followed by accidental injury, falling from height, trapping in cow catcher and dog bite etc..
12. In young animal the healing occurred in 3-4 weeks while in adult it occurred in 6-8 weeks.
13. Amongst internal fixation the double intramedullary pinning proved efficacious than single intramedullary pinning.
14. Simple coaptation cast was an effective and economic method for repair of fractures below stifle and elbow joint.

BIBLIOGRAPHY

BIBLIOGRAPHY

- Acharya, R.M. (1992). Goat production. Proceedings of Fifth International Conference on Goats, New Delhi (India). March 2-8, p. 49.
- Ackerman, N. and Silverman, S. (1978). Radiographic interpretation. Fracture healing. Modern Veterinary Practice 59(5) : 381-384.
- Adams, S.B. and Fessler, J.F. (1983). Treatment of radial-ulnar and tibial fractures in cattle, using a modified Thomas splint-cast combination. Journal of the American Veterinary Medical Association 183(4): 430-433.
- Adams, S.B. (1985). The role of External Fixation and Emergency Fracture Management in Bovine Orthopaedics. In: Symposium on Bovine Lameness and Orthopaedics. Veterinary Clinics of North America 1(1) : 109-129.
- Ames, N.K. (1981). Comparison of methods for femoral fracture repair in young calves. Journal of the American Veterinary Medical Association 179(5) : 458-459.
- Anderson, D.E., St. Jean, G., Vestweber, J.G. and Desrochers, A. (1995). Use of a Thomas splint-cast combination for stabilization of tibial fractures in cattle : 21 cases (1973-1993). Agricultural Practice 15(8) : 16-23. (Vet. Bull. 65(7) : 5067).
- Archibald, J. (1974). Canine Surgery. American Veterinary Publications INC, Drawer KK, Santa Barbara, California.
- Auer, J.A., Steiner, A., Aselin, U. and Lischer, C. (1993). Internal fixation of long bone fractures in farm animals. Veterinary and Comparative Orthopaedics and Traumatology 6(1) : 36-41. (Vet. Bull 64(4) : 2623).
- Bacher, J.D. and Potkay, S. (1975). Compression plating of radial and ulnar fractures in the goat. Veterinary Record 96(25): 538-539.
- Balagopalan, T.P., Devanand, C.B., Rajankutty, K., Sarada Amma, T., Raveendran Nayer, S., Abraham Varkey, C., Jalaluddin, A.M., Murleendharan Nayer, K.N. and George, P.O. (1995). Fractures in dogs - A review of 208 cases. Indian Journal of Veterinary Surgery 16(1) : 41-43.
- Banner, T.A. (1992). A fracture stabilization method. Equine Athlete 5(6) : 14-15. (Vet. Bull. 64(6) : 3956).

- Beckenhauer, W.H. (1958). A practical large animal splint. *Journal of the American Veterinary Medical Association* 132: 284.
- Bennett, R.A., Egger, E.L., Hestand, M. and Ellis, A.B. (1987). Comparison of the strength and holding power of 4 pin designs for use in half pin (type 1) external skeletal fixation. *Veterinary Surgery* 16(3): 207-211. (Vet. Bull. 58(1): 607)
- Bommaiah, C., Singh, Ratan, Sahu, S. (1976). The use of bone plates and screws in treatment of fractures. I. Preparation of bone plates and screws; clinical and roentgenological observations. *Indian Veterinary Journal* 53(6) 456-460.
- Braden, T.D. and Brinker, W.O. (1976). Radiologic and gross anatomic evaluation of bone healing in the dog. *Journal of the American Veterinary Medical Association* 169(12): 1318-1323.
- Brinker, W.O., Piermattei, D.L. and Gretchen, L. (1983). *Handbook of Small Animal Orthopaedics and Fracture Treatment*. W.B.Saunders Company, West Washington Square, Philadelphia p. 34.
- Brown, C.M. and Dicken, J.R. (1975). Intramedullary pinning of a femoral fracture in a calf - a photo assay. *Veterinary Medicine and Small Animal Clinician* 70(4) : 456-57.
- Buchoo, B.A. and Sahay, P.N. (1987). Clinico-radiographic evaluation of compression osteosynthesis for radial and ulnar fractures in goats. *Indian Journal of Animal Sciences* 57(7): 703-705.
- Buchoo, B.A., Sahay, P.N. and Prasad, J. (1988). Histomorphological studies of compression osteosynthesis for radial and ulnar fractures in goats. *Indian Journal of Animal Sciences* 58(2): 164-167.
- Chaffee, V.W. (1977). Multiple (stacked) intramedullary pin fixation of humeral and femoral fractures. *Journal of the American Animal Hospital Association* 13(5): 599-601. (Vet. Bull. 48(4) : 2736).
- Chatre, J.L., Chatre, A., Chavand, J.P., Jouanin, R. and Sollogoub, C. (1979). Reduction and immobilization of fractures in the calf. Part I. *Point Veterinaire* 8(39): 33-37. (Vet. Bull. 50(2) : 1070).
- Chawla, S.K., Chandna, I.S., Singh, A.P. and Nigam, J.M. (1983a). Radiographic evaluation of tibial fracture healing in sheep. *Indian Journal of Animal Sciences* 53(8) : 852-857.

- Chawla, S.K., Chandna, I.S., Singh, A.P. and Nigam, J.M. (1983b). Angiographic evaluation of tibial fracture healing in sheep. *Indian Journal of Animal Sciences* 53(11): 1242-1245.
- Chawla, S.K., Chandna, I.S., Bhatia, K.C. and Singh, A.P. (1983c). Histomorphological studies of tibial fracture healing following internal and external immobilization in sheep. *Haryana Agricultural University Journal of Research* 13(1) : 11-18. (*Vet. Bull.* 54(1) : 224).
- Chopra, V.L. (1992). Welcome Address. *Proceedings of Fifth International Conference on Goats*. New Delhi (India) March 2-8, p. 95.
- Connell, M.R. (1974). Welding in repair of bone fractures in large animals. *Veterinary Medicine and Small Animal Clinician* 69(5) : 631-633.
- Dallman, M.J., Martin, R.A., Self, B.P. and Grant, W. (1990). Rotational strength of double-pinning techniques in repair of transverse fractures in femurs of dogs. *American Journal of Veterinary Research* 51(1): 123-127. (*Vet. Bull.* 60(6) : 4391).
- Dass, L.D., Sahay, P.N., Khan, A.A., Deokiouliyr, U.K. and Ehsan, M. (1985). Incidence of fractures in goats in the hilly terrain of Chhotanagpur. *Indian Veterinary Journal* 62(9) : 766-768.
- Denny, H.R., Sridhar, B., Weaver, B.M.O. and Waterman, A. (1988). The management of bovine fractures: a review of 89 cases. *Veterinary Record* 123(11) : 289-295.
- Dingwall, J.S., Duncan, D.B. and Horney, F.D. (1971). Compression plating in large animal orthopaedics. *Journal of the American Veterinary Medical Association* 158: 1651-1657.
- Dixon, B.C., Tomlinson, J.L. and Wager Mann, C.C. (1994). Effect of three intramedullary pinning techniques on proximal pin location and articular damage in the canine tibia. *Veterinary Surgery* 23(6): 448-455.
- Doiphode, J.M. (1994). Comparative study of different types of splintage in the treatment of long bone fractures of sheep and goats. *Indian Veterinary Journal* 71(1): 70-72.
- Dubey, I.K., Patil, S.N., Marudwar, S.S. and Dhakate, M.S. (1993). Repair of transverse femoral fracture in canines using intramedullary nails prepared from bovine horn - an experimental study. *Indian Veterinary Journal* 70(5): 445-448.

- Duhautois, B. (1995). Locked intramedullary pinning : from its development to the first clinical cases. *Pratique Medicale & Chirurgicale de l' Animal de Compagnie* 28(6) : 657-683. (Vet. Bull. 65(1) : 569).
- Epstein, H. (1965). Domestic animals in China. CAB, Farnham Royal, Bucks, England.
- FAO (1993). Animal Health Year Book. Editor V.R. Walte. ISSN 0066-1872. p. 123.
- Ferguson, J.G. (1982). Management and Repair of Bovine Fractures. Continuing Education Article 4(3): 5128-5135.
- Ferguson, J., Dehghani, S. and Petralli, E. (1986). Femur fractures in new born calves. Femurfrakturen beim neugeborenen Kalb. *Wiener Tierarztliche Monatsschrift* 73(9): 320, 322-325. (Vet. Bull. 57(1) : 348).
- Gabel, A.A. (1961). Articular proximal tibial fractures of a Hereford bull. *Bull speculum* 15(9): 29.
- Gahlot, T.K., Chawla, S.K. and Singh, Prem, Krishnamurthy, D. and Singh, Jit (1990). Modified iron splint for tibial fracture repair in bovines. *Indian Veterinary Journal* 67(6) : 566.
- Ganesh, T.N., Sathish, T., Thilager, S., Ramesh Kumar, B., Ameerjan, K., Pattabiraman, S.R. and Balasubramanian, N.N. (1994). Retrospective study on the incidence and anatomical locations of orthopaedic problems in large animals. Paper presented in 17th ISVS congress, Mathura. 17-19, February.
- Ganis, R. (1952). Reduction of tibial fracture in a Bull. *Journal of the American Veterinary Medical Association* 120(902): 306.
- Gill, B.S. and Tyagi, R.P.S. (1972). A study on the fracture repair and management of long bones in large animals with special reference to external fixation. *Indian Veterinary Journal* 49(4) : 387-393.
- Grandage, J. (1976). Interpretation of bone radiographs : Some hazards for the unwary. *Australian Veterinary Journal* 52(7) : 305-311.
- Hamilton, G.F. and Tulleners, E.P. (1980). Transfixation pinning of proximal tibial fractures in calves. *Journal of the American Veterinary Medical Association* 176(8): 725-727.
- Hanselka, D.V., Boyd, C.L. and Joyce, J.R. (1972). External fixation of a large animal fracture with a resin bonded fiberglass cast. *Veterinary Medicine and Small Animal Clinician* 67(5): 519-526.

- Hickman, J. (1957). The treatment of fractures in farm animals. *Veterinary Record* 69 : 1227-1233.
- Hinko, P.J. and Rhinelander, F.W. (1975). Effective use of cerclage in the treatment of long bone fractures in dogs. *Journal of the American Veterinary Medical Association* 166(5): 520-524.
- Huttschenreuter, P., Baltensperger, A., Ruter, A. and Ferren, S.M. (1973). Experimental studies on a plate osteosynthesis in sheep. *Deutsche Tierärztliche Wochenschrift* 80(5): 105-107. (*Vet. Bull.* 43(8) : 3795).
- Iyer, M.R.K. (1990). Studies on the effect of retained intramedullary pin in the femur of a dog. *Indian Veterinary Journal* 67(3) : 272-273.
- Jenny, J. (1965). Treatment of open fractures. *Journal of the American Veterinary Medical Association* 147(12): 1444-1446.
- Johnson, R.A. (1977). Fracture fixation by cerclage wiring utilizing cortical bone tracks and a pull-out tension device. *Journal of the American Animal Hospital Association* 13(1) : 105-113. (*Vet. Bull.* 47(8) : 4772).
- Kagan, K.G. (1983). Multiple intramedullary pin fixation of the femur of dogs and cats. *Journal of the American Veterinary Medical Association* 182(11) : 1251-1255.
- Kendrick, J.W. (1951). Treatment of tibial and radial fractures in large animals. *Cornell Vet* 41: 219-230.
- Kofler, J. and Stanek, C. (1995). Treatment of metacarpal and metatarsal fractures in cattle - a retrospective study (1984-1993). *Wiener Tierärztliche Monatsschrift* 82(3) : 75-89. (*Vet. Bull.* 65(11) : 7873).
- Köstlin, R.G., Nuss, K. and Elma, E. (1990). Metacarpal and metatarsal fracture in cattle- Treatment and results. *Metakarpal und metatarsalfrakturen beim Rind. Behandlung und Ergebnisse. Tierärztliche Praxis* 18(2) : 131-144. (*Vet. Bull.* 61(8) : 5830).
- Lawson, Donald D. (1963). The management of fractures in domestic animals- I and II. *British Veterinary Journal* 119: 409-421, 492-511.
- Losslein, L.K. (1982). Metacarpal and metatarsal fractures in dogs and cats. Treatment and results between 1975 and 1981. Inaugural Dissertation, Tierärztliche Fakultät, Ludwig-Maximilians-Universität, München p. 96. (*Vet. Bull.* 53(11) : 7312).

- Lundvall, R.L. (1960). Observation on the treatment of fractures of long bones in large animals. *Journal of the American Veterinary Medical Association* 137(5) : 308-312.
- Mande, J.D., Mbithi, P.M.F., Mbiuki, S.M. (1995). Clinical evaluation of some plaster casts available in Kenya. *Bulletin of Animal Health and Production in Africa* 42(2) : 103-107. (Vet. Bull. 65(5) : 3535).
- Marudwar, S.S. and Kulkarni, P.E. (1980). A new technique for immobilization of bovine limb. *Indian Journal of Veterinary Surgery* 1(2) : 79-82.
- Mbiuki, S.M. and Byagagaire, S.D. (1984). Full limb casting: A treatment for tibial fractures in calves and goats. *Veterinary Medicine and Small Animal Clinician* 79: 243-244.
- Meyer, J. (1977). Radius and ulna fractures in the dog. Treatment and results (1970-1974). Inaugural Dissertation, Fachbereich Tiermedizin, Munchen p.62. (Vet. Bull 48(10) : 6196).
- Mohanty, J., Ojha, S.C., Mitra, A.K. and Das, A.C. (1970). Treatment of fracture in cattle- an experimental and clinical study. *Indian Veterinary Journal* 47: 1118-1124.
- Montgomery, J.F.(1972). The use of fiberglass with POP in the fabrication of casts. *Newzealand Veterinary Journal* 20(9) : 169-170.
- Moulvi, B.A., Sahay, P.N., Khan, A.A. and Dass, L.L. (1986a). Radiographic evaluation of femoral fracture healing following xenogenic bone plating and neutralization plating in goats. *Indian Journal of Animal Sciences* 56(12) : 1190-1195.
- Moulvi, B.A., Sahay, P.N., Prasad, J. and Buchoo, B.A. (1986b). Histological studies of femoral fracture healing under heterogenous bone plating and neutralization plating in goats. *Indian Journal of Animal Sciences* 56(11) : 1147-1149.
- Mukherjea, R. and Sahay, P.N. (1992a). Clinico-radiographic evaluation of biological osteoinducers in the healing of compound fracture in goats. *Indian Veterinary Journal* 69(12) : 1122-1124.
- Mukherjea, R. and Sahay, P.N. (1992b). Histomorphological studies of compound fracture healing with biological osteoinducers in goats. *Indian Veterinary Journal* 69(8): 721-723.

- Newton, C.D. and Hohn, R.B.(1974). Fracture nonunion resulting from cerclage appliances. *Journal of the American Veterinary Medical Association* 64(5) : 503-508.
- Nigam, J.M. and Singh, A.P.(1980). Radiography of bovine foot disorders. *Modern Veterinary Practice* 61(7): 621-625.
- Northway, R.B. (1973). Cross pinning for fracture immobilization. *Modern Veterinary Practice* 54(6) : 45.
- Dehme, F.W. and Prier J.E. (1974). A Text Book of Large Animal Surgery. In Musculo skeleton system; Eds The Williams and Wilkins Company, Baltimore, USA. p.
- Patil, D.B., Jani, B.M. and Parsania, R.R. (1991). A note on the incidence of fractures in animals. 10 years survey. *Indian Journal of Veterinary Surgery* 12(2) :126.
- Peitel, M. (1971). The frequency of limb fractures and the associated economic loss in horses and cattle. *Wein tierärztl. Mschr.* 58: 158-163. (*Vet. Bull.* 41(11) : 6074).
- Pfeiffer, C. (1977). Tibia fractures in the dog. Treatment and results in 1970-1974. Inaugural Dissertation. Fachbereich Tiermedizin, Munchen p. 69. (*Vet. Bull* 48(9) : 5563).
- Phillips, I.R. (1979). A survey of bone fractures in the dog and cat. *Journal of Small Animal Practice* 20(11) : 661-674.
- Ram Kumar, V., Murli Manohar and Tyagi, R.P.S. (1973). Hanging pin cast for oblique fracture of tibia in a cow - A disadvantage. *Indian Veterinary Journal* 50(7) : 714-716.
- Rama Kumar, V., Datt, S.C. and Singh, Gajraj (1976). Use of Kuntschner nail in spiral fracture of humerus in a buffalo heifer - a case report. *Indian Veterinary Journal* 53 : 64-65.
- Rama Kumar, V. Prasad, B. and Kohli, R.N. (1983). Angiographic pattern in large animal fracture healing - an experimental study. *Indian Journal of Veterinary Surgery* 4(1) : 16-20.
- Rao, K.V. and Rao, S.V. (1973) Rush pins for tibial fractures in bovines. *Indian Veterinary Journal* 50(7): 702-713.
- Rao, N.R. (1975). Metacarpal and Metatarsal fractures, their treatment with plaster cast and short and modified Thomas splints. *Indian Veterinary Journal* 52(3): 232-233.
- Rao, R.L.N., Nigam, J.M. and Singh, A.P. (1983). Experimental studies on the repair of metacarpal fractures in bovine

- with reference to use of allogenic onlay bone plates. Indian Journal of Animal Sciences 53(12) : 1303-1309.
- Reichel, Ernest C. (1956). Treatment of fractures of the long bones in large animals. Journal of the American Veterinary Medical Association 129: 8-15.
- Rhineland, F.W. (1974). Tibial blood supply in relation to fracture healing. Clin. Ortho. Rel. Res. 105:34-81.
- Rittmann, W.W. and Ferren, S.M. (1975). Cortical bone healing after internal fixation and infection. Biomechanics and biology. Berlin, German Federal Republic; New York, U.S.A. (Vet. Bull. 45(9) : 5435).
- Ross, J.T. and Matthiesen, D.T. (1993). The use of multiple pin and methylmethacrylate external skeletal fixation for the treatment of orthopaedic injuries in dog and cat. Veterinary and Comparative Orthopaedics and Traumatology 6(2): 115-121.
- Rudy, R.L. and Thorp, V.L. (1950). Tibial fracture in a aged stallion. Journal of the American Veterinary Medical Association 117(882): 199-201.
- Salem, D., Barreira, Y., Haverbeke, G.Van. and Cazieux, A. (1993). Adaptation of the Ilizarov method for bone surgery in sheep. Revue de Médecine Veterinaire 144(1) : 43-48. (Vet. Bull. 63(6) : 4289).
- Sanford, S.E. and Rendano, V.T. (1977). Abscess and malunion complicating fracture healing in a calf. Journal of the American Veterinary Medical Association 171(2): 185-187.
- Sarkate, L.B., Aher, V.D. and Salunke, V.M. (1995). Bilateral metacarpal fracture in a goat - a case report. Indian Journal of Veterinary Surgery 16(1) : 66-68.
- Satish, C., Singh, Ratan, Sahu, S.(1975). Buffalo bone serves as a surgical plate and screws. Current Research, University of Agricultural Sciences, Bangalore 4(3): 52. (Vet. Bull. 45(9) : 5407).
- Sharma, V.K., Singh, Harpal, Kumar, A. and Singh, Bharat (1980). A note on the effect of immobilization time on fracture healing in buffaloes. Indian Journal of Veterinary Surgery 1(2) : 90-92.
- Singh, A.P. and Nigam, J.M. (1979). Study on the fracture repair of metatarsus in bovine with special reference to homogenous bone plating. Indian Veterinary Journal 56(3) : 214-218.

- Singh, A.P. and Nigam, J.M. (1981). Bone and joint disorders of limb in sheep and goat : a radiographic report. Indian Journal of Veterinary Surgery 2(2) : 62-65.
- Singh, A.P., Mirakhur, K.K. and Nigam, J.M. (1983). A study on the incidence and anatomical locations of fractures in canine, caprine, bovine, equine and camel. Indian Journal of Veterinary Surgery 4(1) : 61-66.
- Singh, A.P., Nayer, K.N.M., Chandna, I.S., Chawla, S.K. and Nigam, J.M. (1984). Postoperative complications associated with fracture repair of long bones in bovine, equine and ovine. Indian Journal of Veterinary Surgery 5(1) : 47-57.
- Singh, G.R., Singh, A.P., Mogha, I.V. and Bhargava, A.K.(1979). A case of Monteggia fracture in goat. Indian Veterinary Journal 56(6): 509-511.
- Singh, G.R., Mogha, I.V. and Chattopadhyay, S.K. (1983). Intramedullary use of iron nails covered with methylmethacrylate in fracture of femur in sheep. Indian Journal of Veterinary Surgery 4(1): 1-5.
- Singh, G.R., Bhargava, A.K. and Mogha, I.V. (1987). Use of bone plates prepared from bovine horn for the fixation of femoral fracture in goats. Indian Journal of Animal Sciences 57(11): 1166-1169.
- Singh, Harpal, Kumar, Amresh and Pandiya, S.C. (1976). Time effect of intramedullary pinning in tibial fractures of the dog. Indian Veterinary Journal 53(4) : 286-290.
- Singh, Mohinder, Sharma, S.K. and Vashist, N.K.(1989). Repair of humeral fracture in a buck - a case report. Indian Journal of Veterinary Surgery 10(2): 144-145.
- Singh Prem, Singh, Jit, Singh, A.P. and Peshin, P.K. (1986). Repair of femoral fracture in calves. Indian Journal of Animal Sciences 56(5): 494-497.
- Singh, Sukhbir, Singh, Kuldeep, Chawla, S.K., Gahlot, T.K., Bisla, R.S. and Krishnamurthy, D. (1988a). Use of PVC (Polyvinyl Chloride) pipe for the external immobilization of metacarpal and metatarsal fractures in experimental cow calves. Paper presented in 12th ISVS symposium, Izatnagar. 7-9 December.
- Singh, Sukhbir, Chawla, S.K., Singh, Kuldeep and Krishnamurthy, D. (1988b). Evaluation of 3 types of internal skeletal fixation for repair of experimental humeral fractures in cow calves. Paper presented in 12th ISVS symposium, Izatnagar. 7-9 December.
- Singh, Y.P.(1992). Study on foot disorders in goats. M.V.Sc. Thesis presented to Rajasthan Agricultural University, Bikaner.

- Stick, J.A. and Derksen, F.J.(1980). Intramedullary pinning of a fractured femur in a foal. *Journal of the American Veterinary Medical Association* 176(7): 627-629.
- St-Jean, G., Clem, M.F. and DeBowes, R.M. (1991). Transfixation pinning and casting of tibial fractures in calves- five cases (1985-1989). *Journal of the American Veterinary Medical Association* 198(1): 139-143. (*Vet. Bull* 61(6) : 4620).
- Steiner, A., Iselin, U., Auer, J.A. and Lischer, C.J. (1993a). Shaft fractures of the metacarpus and metatarsus in cattle. *Veterinary and Comparative Orthopaedics and Traumatology* 6(3): 138-145. (*Vet. Bull.* 64(4) : 2337).
- Steiner, A., Iselin, U., Auer, J.A. and Lischer, C.J. (1993b). Physeal fractures of the metacarpus and metatarsus in cattle. *Veterinary and Comparative Orthopaedics and Traumatology* 6(3): 131-137. (*Vet. Bull.* 64(4) : 2336).
- Tulleners, E.P. (1986). *Journal of the American Veterinary Medical Association* 189:463.
- Tyagi, R.P.S. and Singh, Jit (1993). *Ruminant Surgery. A Textbook of the Surgical Diseases of Cattle, Buffaloes, Camels, Sheep and Goats. The Musculoskeletal System :* by A.P.Singh. Gajraj Singh and Prem Singh. CBS Publishers and Distributors, Delhi. p. 338-379.
- Tyagi, R.P.S. and Gill, B.S. (1972). A study on the fracture repair and management of long bones in large animals by internal fixation. *Indian Veterinary Journal* 49: 592-599.
- Vachon, A. and DeBowes, R.M. (1987). Internal fixation of a proximal metatarsal fracture in a calf. *Journal of the American Veterinary Medical Association* 191(11): 1465-1467.
- Valdez, H., Morris, D.L. and Auer, J.A. (1979). Compression plating of long bone fractures in foals. *Journal of Veterinary Orthopaedics* 1(1) : 10-18. (*Vet. Bull.* 50(11) : 7923).
- Vaughan, L.C. and Osman, M.A.R. (1967). Fracture of the third phalanx in cattle. *Veterinary Record* 80(18): 537-543.
- Vaughan, L.C. (1975). Complications associated with the internal fixation of fractures in dogs. *Journal of Small Animal Practice* 16 : 415-426.
- Verschooten, F., Moor, A.de, Desmet, P. and Steenhaut, M. (1972). Surgical treatment of tibial fractures in cattle. *Veterinary Record* 90(2) : 24-29.

- Vijaykumar, D.S. (1981). Studies on experimental osteosynthesis for tibial fractures in calves. Ph.D. Thesis, Haryana Agricultural University, Hisar.
- Vijaykumar, D.S., Singh, A.P., Nigam, J.M. and Chawla, S.K. (1982). Repair of bovine tibial fractures. *Veterinary Medicine and Small Animal Clinician* 77(7): 1109-1114.
- Vijaykumar, D.S., Nigam, J.M., Singh, A.P. and Chawla, S.K. (1984). Experimental studies on fracture repair of the tibia in the bovine. *Journal of Veterinary Orthopaedics* 3(1) : 6-12. (Vet. Bull. 54(6) : 3854).
- Walker, D.F. (1979). Coaptation splinting of the bovine rear limb. *Modern Veterinary Practice* 60: 629.
- West, W.R.G.(1963). The application of Resin-bonded fibre glass for the immobilization of fractured or damaged equine and bovine limbs. *Veterinary Record* 75(16): 424-425.
- Whitney, W.D. and Schrader, S.C. (1987). Dynamic intramedullary crosspinning technique for repair of distal femoral fractures in dogs and cats: 71 cases (1981-1985). *Journal of the American Veterinary Medical Association* 191(9): 1133-1138.
- Whittick, W.G. (1974). *Canine Orthopaedics*. Lea and Febiger, Philadelphia.
- Winstanley, E.W. (1974). Aspects of the compression treatment of fractures. *Veterinary Record* 95(19) : 429-433.
- Winthrow, S.J. and Holmberg, D.L. (1977). Use of full cerclage wires in the fixation of 18 consecutive long bone fractures in small animals. *Journal of American Animal Hospital Association* 13: 735-743.
- Wolff, E.F. (1973). Repair of a comminuted fracture using ASIF technique and implants. *Veterinary Medicine and Small Animal Clinician* 68(9): 997-1000.
- Zeuner, F.E. (1963). *A History of Domesticated Animals*. Hutchinson and Co. (Publishers) Ltd, London p. 129

CLINICAL AND RADIOLOGICAL EVALUATION OF FRACTURES IN GOAT
(*Capra hircus*).

M.V.Sc. Thesis
Department of Veterinary Surgery and Radiology
College of Veterinary and Animal Science
Rajasthan Agricultural University
Bikaner- 334001

Submitted by : Dr. Sharad Arora
Major Advisor: Dr. T.K.Gahlot

ABSTRACT

In the present study 143 caprine cases showed fracture and were categorized as group A. In a 15 years retrospective study 1262 goats showed fractures and these comprised group B. The overall incidence of fracture was 12.23%. The highest incidence of fracture was found in tibia (25.17%), followed by metacarpal (21.67%), metatarsal (16.08%), femur (11.18%), humerus (8.39%), radius ulna (7.69%) etc., in animals of group A. The incidence fracture of metatarsal and metacarpal bones (27.73 and 27.41%, respectively) were almost equal in animals of group B, followed by tibia (16.71%), femur (9.82%), radius ulna (6.97%), humerus (6.10%) etc. Hind limbs sustained more fractures than forelimb. The incidence of open fracture was 6.29 and 6.65% in the animals of group A and B, respectively. The animals of group A revealed higher incidence of fractures in females (71.32%) and in age group below 1 year (52.44%). Most of the fracture lines

were oblique (36.02%), transverse (34.55%) or comminuted (18.24%) in nature and was across the diaphysis.

Fractures in goats occurred due to: contusion, accidental injury, falling on ground from height, trapping in the cow catcher, dog bite and unknown etiology.

Internal fixation was performed in 22 animals while external fixation was done in 110 cases.

Simple coaptation splinting was the preferred method of external immobilization and was done where fracture occurred below stifle and elbow joint. Healing occurred in 3-4 weeks in young animals while it occurred in 6-8 weeks in adult.

The complications encountered with internal fixation were viz. migration of pins from proximal/distal extremity with or without union, impaction of fracture fragment, splitting of the upper fragment, seroma formation and lateral displacement.

The complication of simple coaptation cast were viz. malunion, plaster bite, breaking of the cast and tearing of the cast at hoof.

Amongst internal fixation the double intramedullary pinning proved efficacious than single intramedullary pinning. Simple coaptation cast was an effective and economic method for repair of fractures below stifle and elbow joint.

बकरियों <केपरा हिरकस> में अस्थिभंग का शयनिक एवं क्षः रश्मिक मूल्यांकन

स्नातकोत्तर शोधग्रन्थ
पशु शल्य चिकित्सा एवं विकिरण विभाग,
पशुचिकित्सा एवं पशुविज्ञान महा विद्यालय,
राजस्थान कृषि विश्वविद्यालय,
बीकानेर

प्रस्तुतकर्ता
प्रमुख उपदेष्टा

डा. शरद अरोडा
डा. तरुण कुमार गहलोत

अनुक्षेपण

वर्तमान अध्ययन में 143 बकरियों में अस्थिभंग पाया गया व उन्हें समूह "ए" में रखा गया। 15 वर्षों के अतीत प्रभावी अध्ययन में 1262 बकरियों में अस्थिभंग पाया गया व उन्हें समूह "बी" में रखा गया। अस्थिभंग का कुल आपात 12.23 प्रतिशत था। समूह "ए" में अस्थिभंग का आपात क्रमशः सबसे ज्यादा टिबिया (25.17%) व उसके बाद मेटाकार्पल (21.67%), मेटाटार्सल (16.08%), फीमर (11.18%), ह्यूमरस (8.39%), रेडियस अलना (7.69%) व अन्य अस्थियों में पाया गया। समूह "बी" में मेटाकार्पल व मेटाटार्सल अस्थियों (क्रमशः 27.73 व 27.41%) में अस्थिभंग का आपात लगभग समान था, उसके बाद यह क्रमशः टिबिया (16.71%), फीमर (9.82%), रेडियस अलना (6.97%), ह्यूमरस (6.10%) व अन्य अस्थियों में पाया गया।

पिछले पाँव में अस्थिभंग का आपात अगले पाँव की तुलना में ज्यादा पाया गया। विकृत अस्थिभंग का आपात समूह "ए" एवं "बी" में क्रमशः 6.29 व 6.65 प्रतिशत पाया गया। समूह "ए" में मादा पशुओं (71.32%) व एक वर्ष से कम आयु वर्ग (52.44%) में अस्थिभंग का आपात ज्यादा पाया गया। ज्यादातर अस्थिभंग रेखा आड़ी (34.55%), तिरछी (36.02%) या बहुवर्णित (18.24%) व अस्थिदण्ड के पार थी। बकरियों में अस्थिभंग पृष्ठवर्ण, दुर्घटना, ऊंचाई से नीचे गिरने से, गाय अवरोधक में पाँव फँसने से, कुत्तों के काटने व अन्य अज्ञात कारणों से हुआ।

आन्तरिक स्थिरीकरण 22 पशुओं में व बाहरी स्थिरीकरण 110 पशुओं में किया गया।

कोहनी व जानु के नीचे के अस्थिभंग में साधारण कोऑपटेशन स्पील्लिंग बाहरी स्थिरीकरण का उत्तम तरीका था। अस्थिभंग विहोरण बच्चों में 3-4 सप्ताह व बड़ों में 6-8 सप्ताह में हुआ।

आन्तरिक स्थिरीकरण में पिन का अस्थि के समीपान्त व दुरस्थ अन्त से जुड़ने के बाद या बिना जुड़े प्रवास, अस्थिखण्ड का अंतर्घट्टन, उपरी भाग के विपाटन, सीरोमा का बनना व पार्श्व खसकना जैसी जटिलताएं पाई गईं।

साधारण कोऑपटेशन कास्ट में टेडा जुड़ना, प्लास्टर घाव, प्लास्टर का टूटना व खुर के यहाँ से प्लास्टर का फटना जैसी जटिलताएं पाई गईं।

दो अंतःमज्जा पिन द्वारा आन्तरिक स्थिरीकरण की तकनीक एक अंतःमज्जा पिन तकनीक से प्रभावी साबित हुई। साधारण कोऑपटेशन कास्ट तकनीक कोहनी व जानु के नीचे के अस्थिभंग को ठीक करने में प्रभावी व सस्ती पाई गई।

APPENDIX

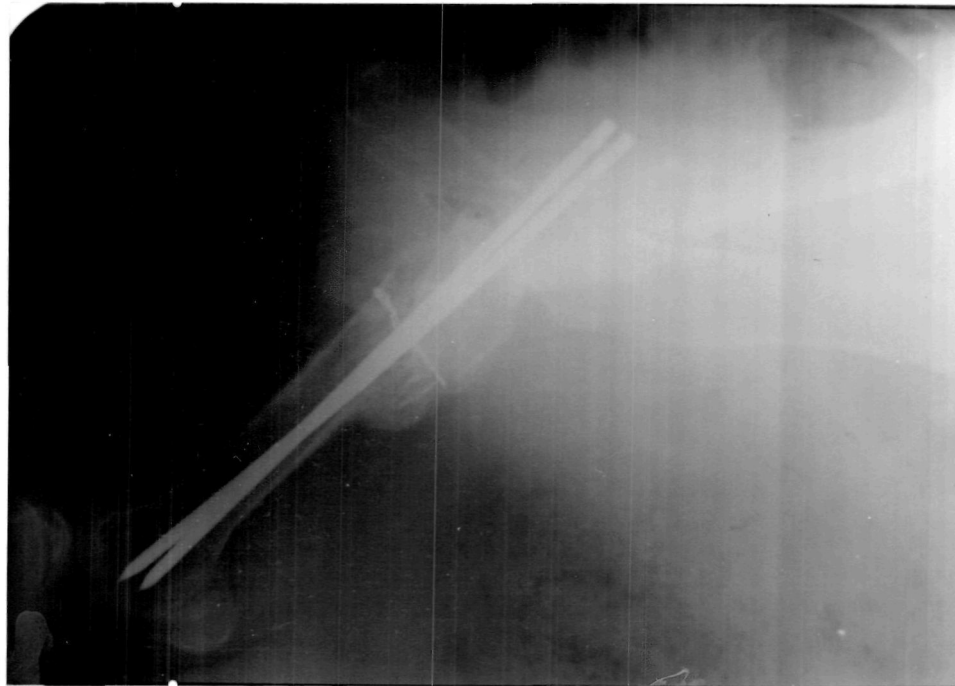


Figure 1. Lateral radiograph of healed fracture of upper extremity of femur immobilized by double intramedullary pinning and cerclage wire (8 weeks).

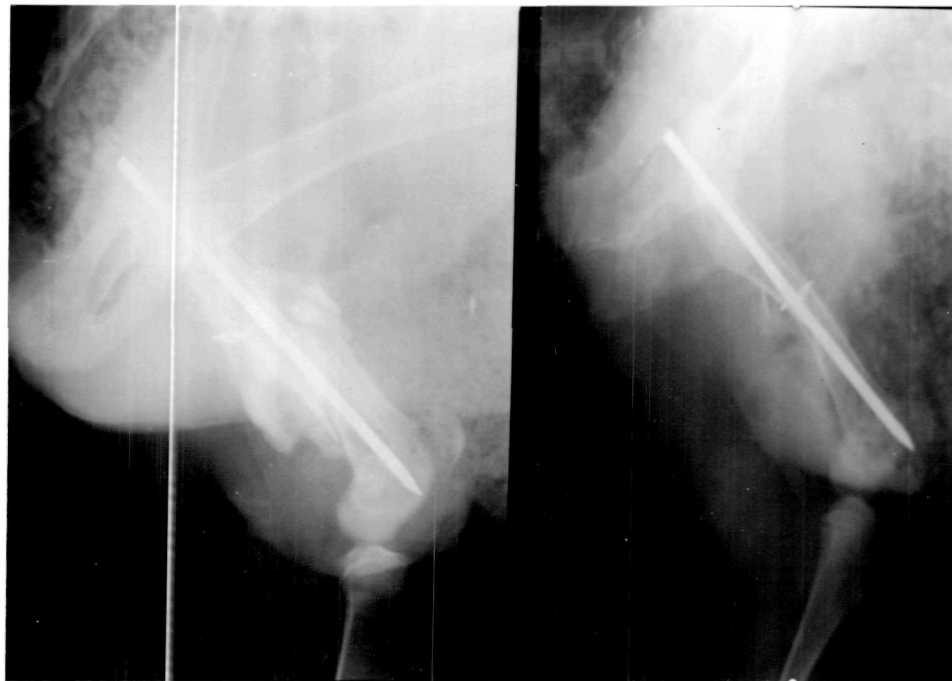

Figure 2. Right: Lateral radiograph of femur with fracture of mid-shaft immobilized by single intramedullary pinning and cerclage wire. Left: healed fracture showing large callus after one month.

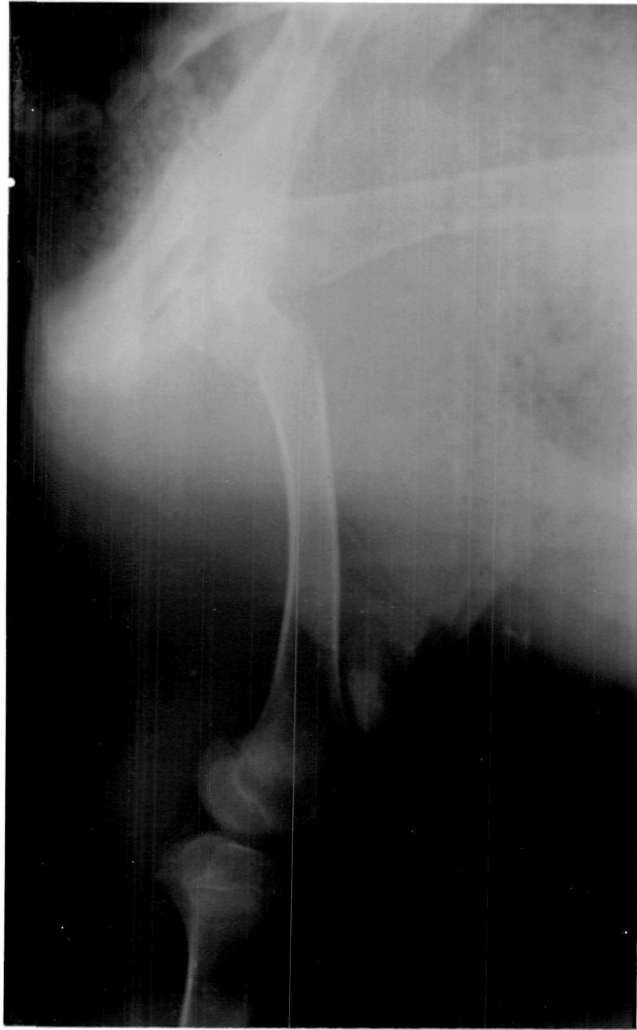

Figure 3. Lateral radiograph of fracture of neck of femur.

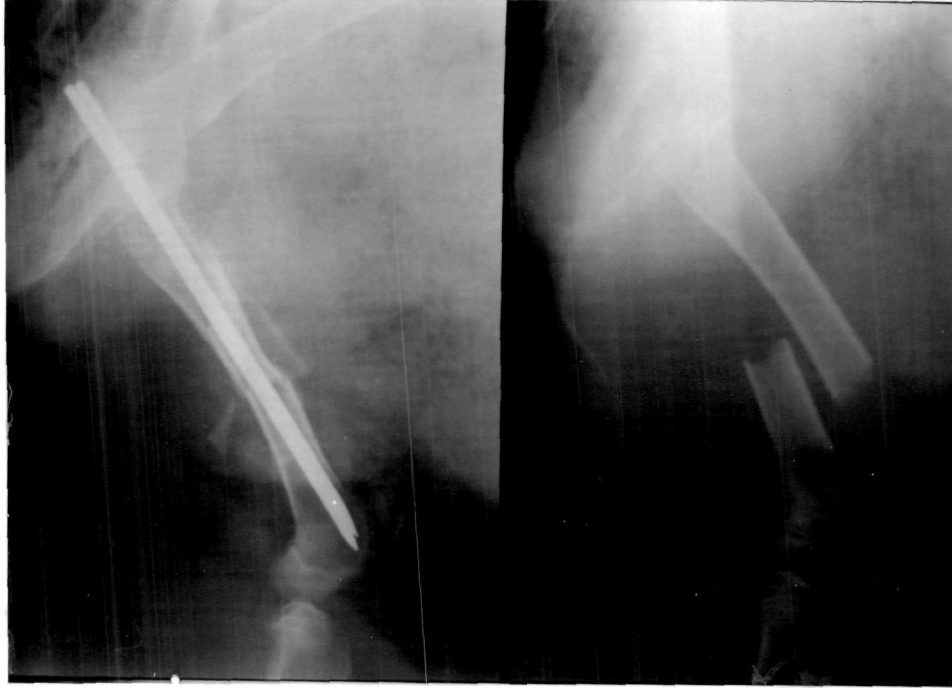

Figure 4. Lateral radiograph of femur, the transverse fracture being immobilized with double intramedullary pinning.

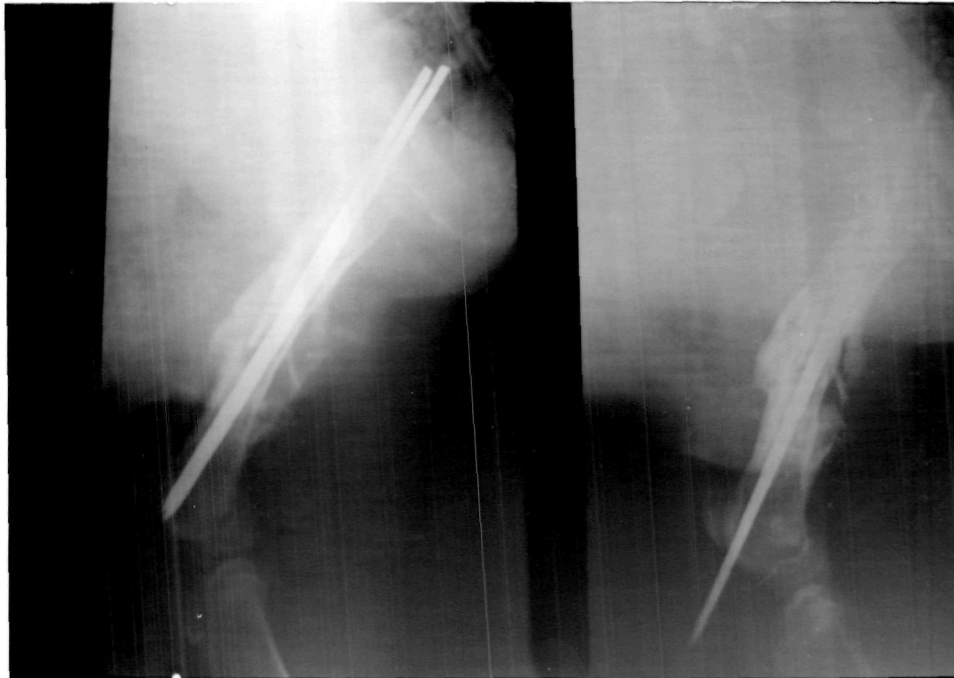


Figure 5. Left: Lateral radiograph of femur showing callus formation around fracture site after 1 month. Right: Lateral radiograph showing migration of pin through distal extremity after 45 days (same animal as figure 4).

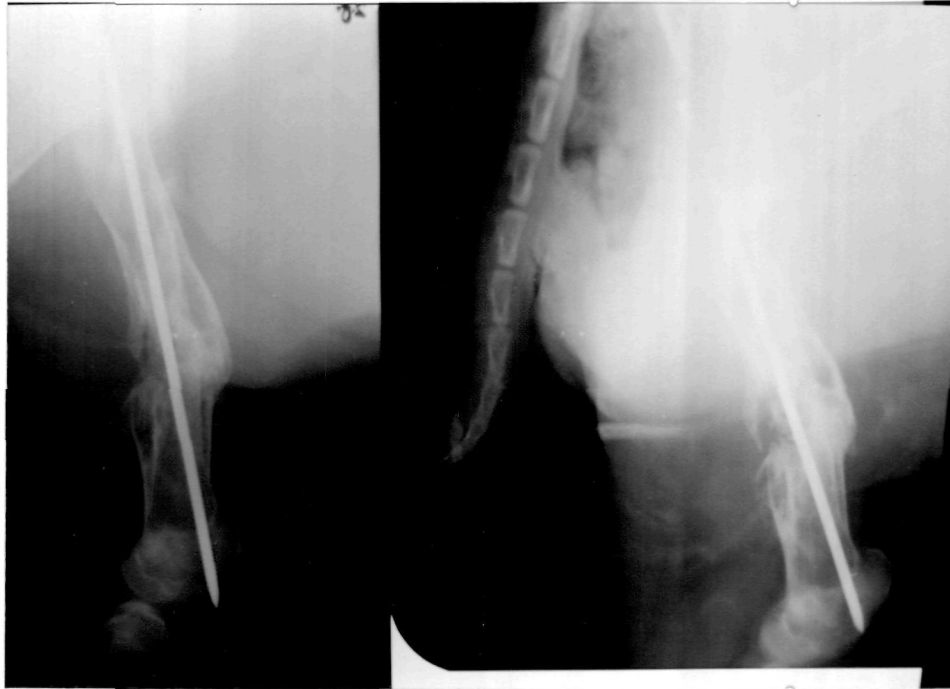

Figure 6. Right: Lateral radiograph of the same animal after 2 months showing completely healed fracture with only pin. Left: radiograph after 75 days showing distal migration of the second pin and complete obliteration of fracture line.

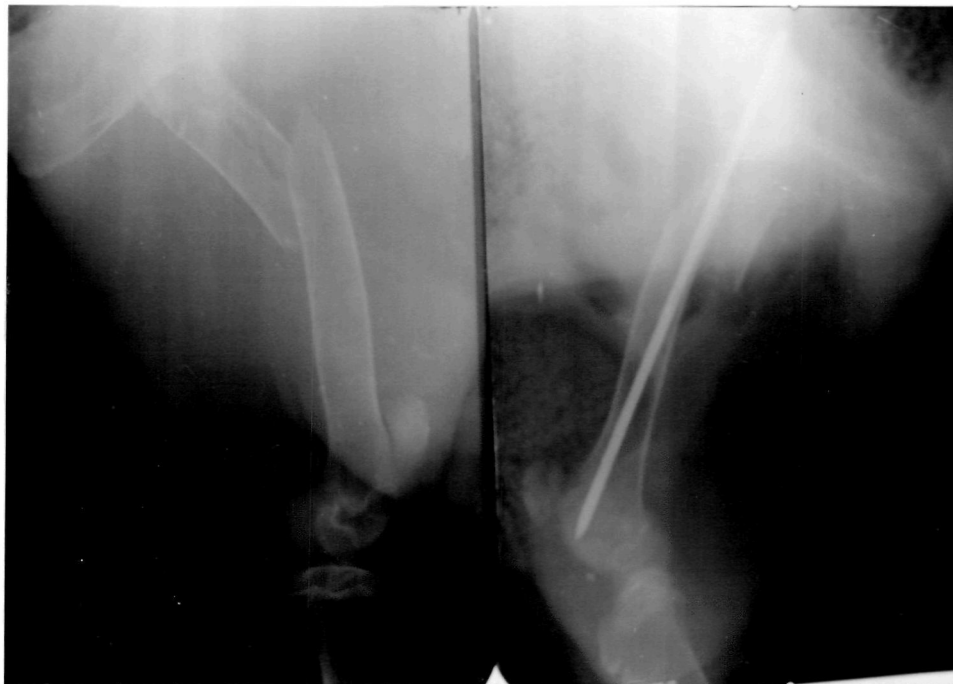

Figure 7. Left: Lateral radiograph of oblique fracture of upper extremity of femur (Note the longitudinal splitting in the upper fragment). Right: Splitting of the upper fragment after single intramedullary pinning.

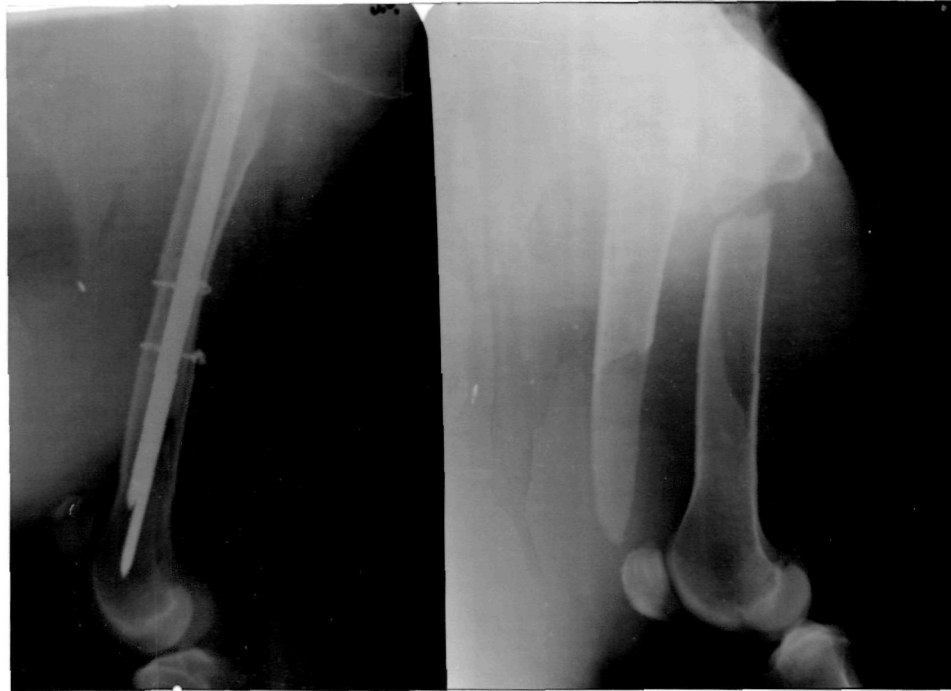

Figure 8. Lateral radiograph of long oblique fracture of femur in a adult goat before and after immobilization with double intramedullary pinning and double cerclage wire.

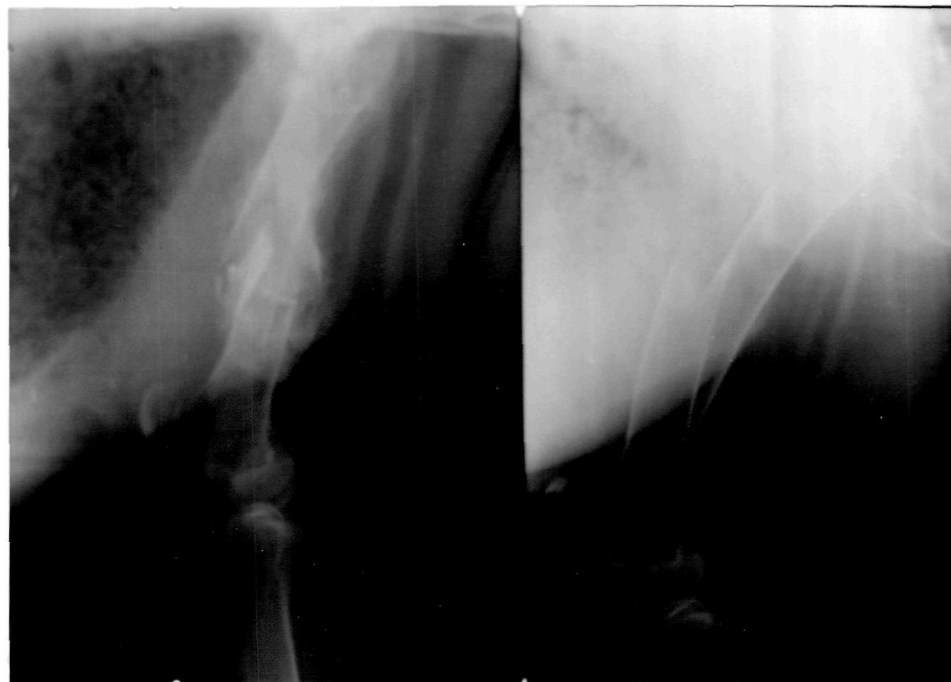

Figure 9. Right: Lateral radiograph of oblique mid-shaft fracture of femur. Left: healed fracture after one month (Note: pin was migrated out from distal extremity).

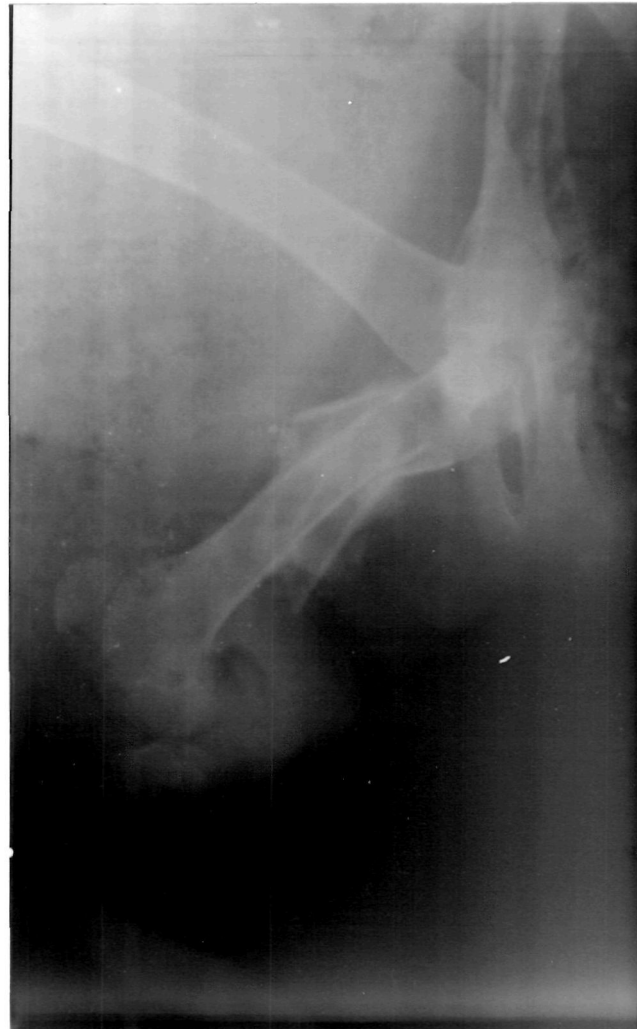

Figure 10. Lateral radiograph of a healed fracture of femur showing impaction of lower fragment into upper one.

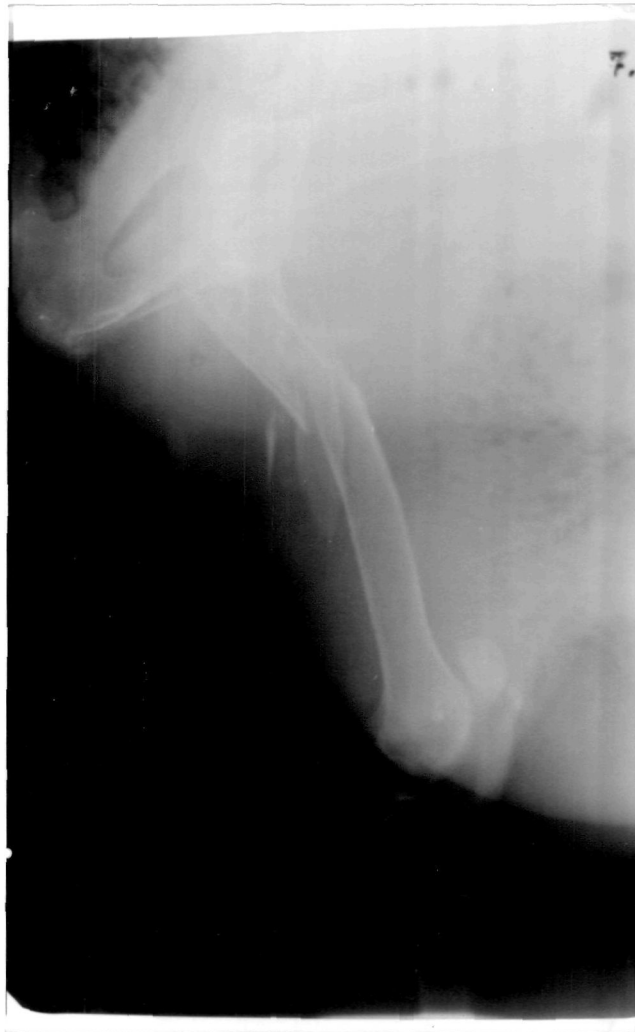

Figure 11. Lateral radiograph of multiple fracture of upper extremity of femur.

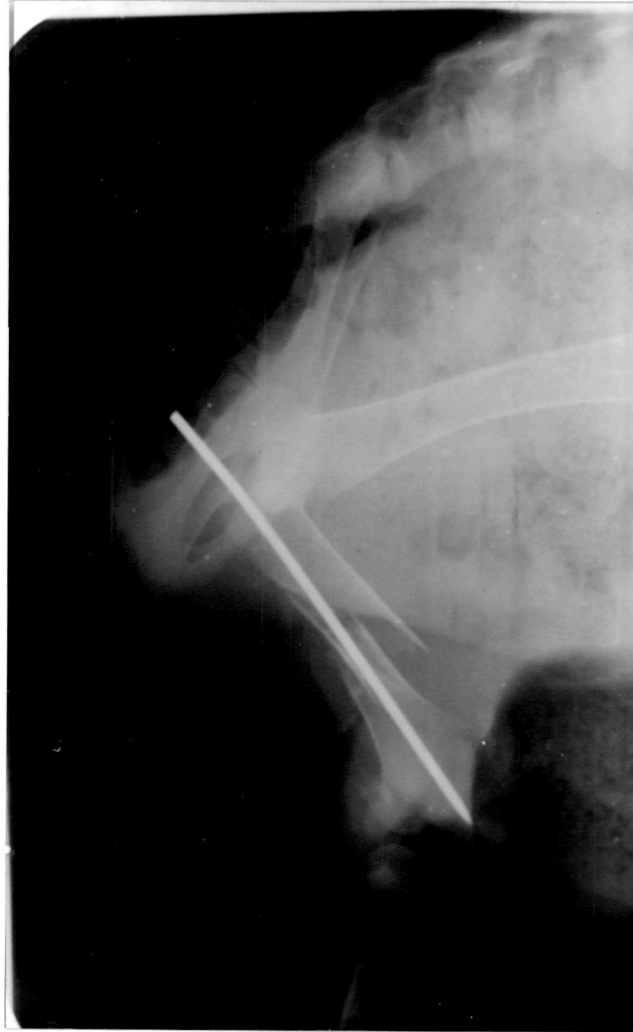

Figure 12. Lateral radiograph of multiple fracture of femur in a kid immobilized by single intramedullary pinning with pin driven more into distal cortex causing its migration through distal extremity after 5 days resulting in non-union.

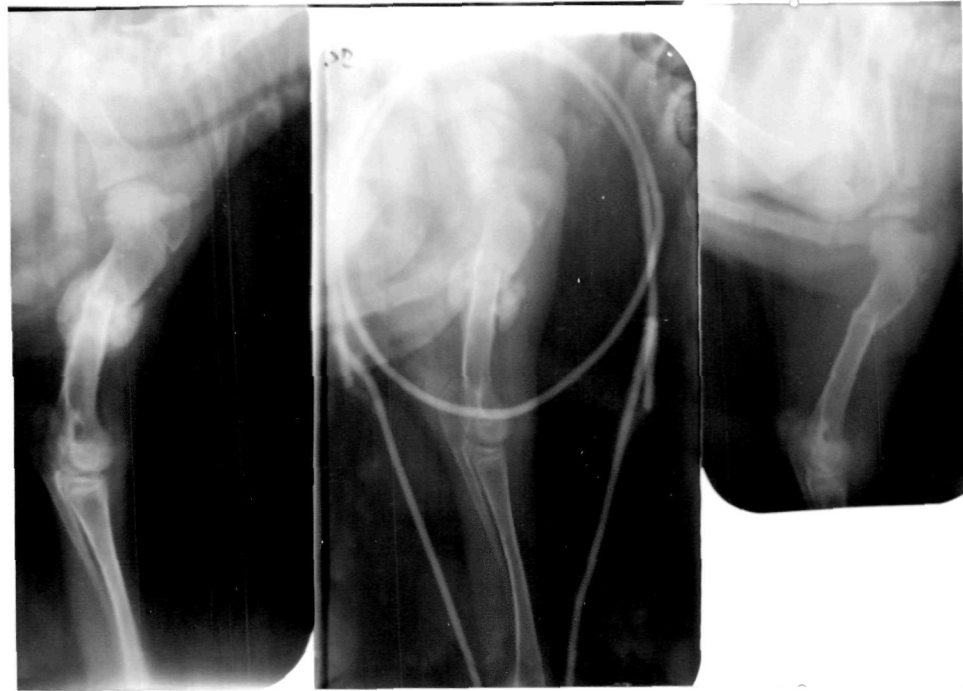

Figure 13. Right: Lateral radiograph of a undisplaced fracture of humerus in a kid. Middle: Healing fracture after 2 weeks immobilized by Thomas splint. Left: Large callus after 3 weeks.

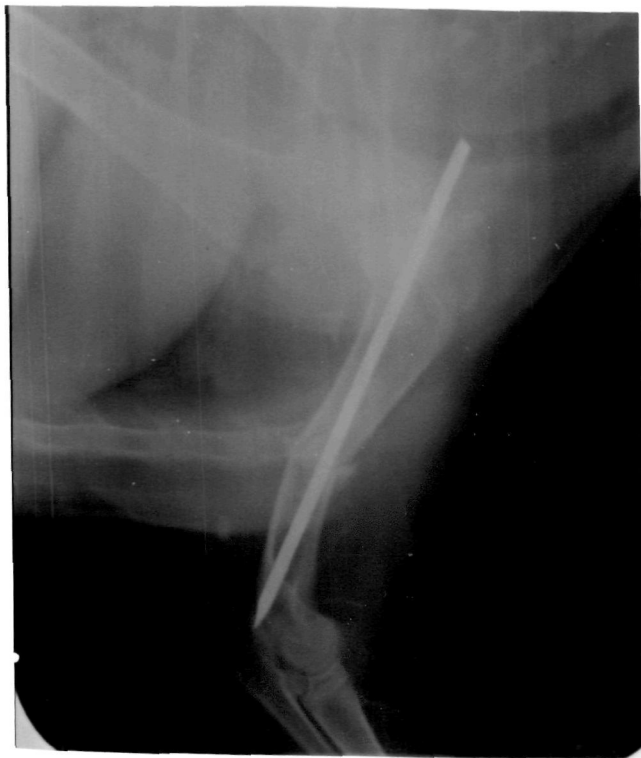

Figure 14. Lateral radiograph of the fracture of humerus immobilized with single intramedullary pinning.

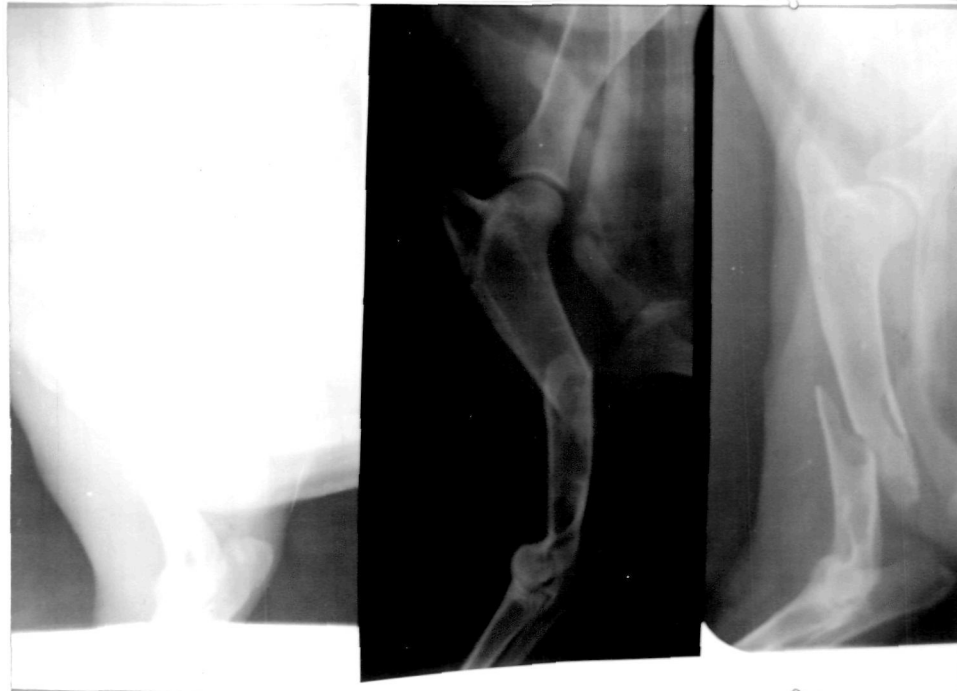

Figure 15. Lateral radiographs showing various types of fracture lines of humerus fracture.

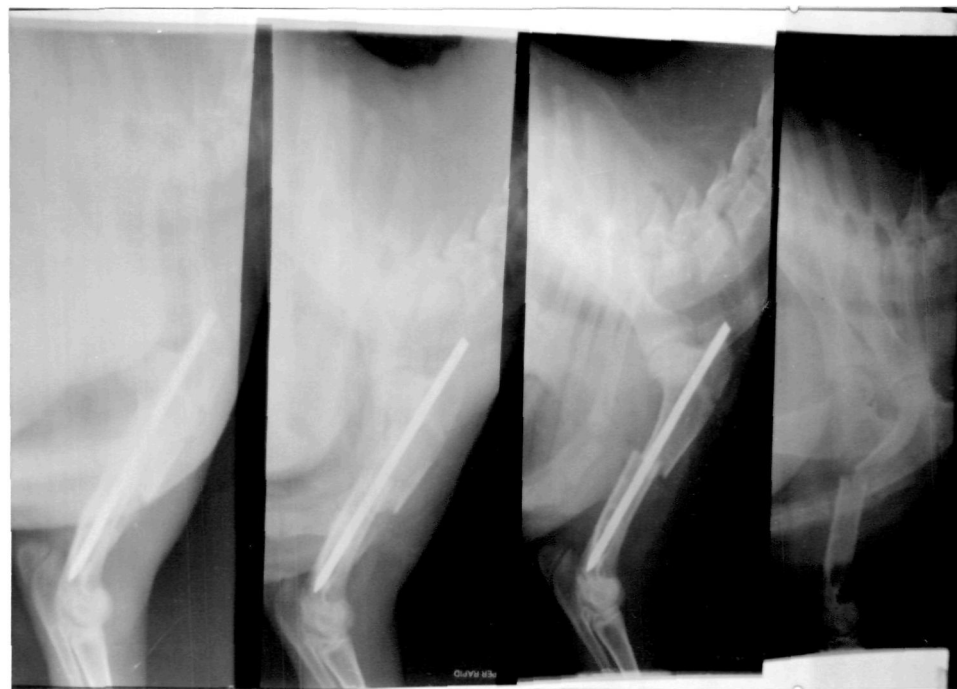

Figure 16. From Right to left : Lateral radiograph of transverse fracture of mid-shaft of humerus. Immobilized by single intramedullary pinning showing lateral deviation of fracture fragment. Healing fracture after two weeks of immobilization showing callus formation. Completely healed fracture after 4 weeks.

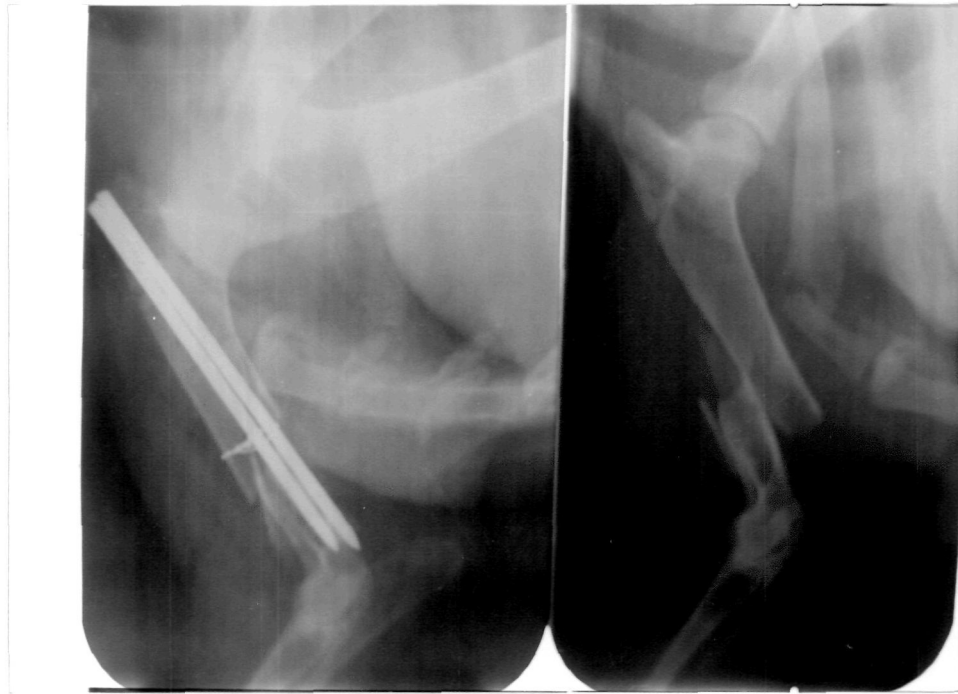

Figure 17. Lateral radiograph of fracture of humerus immobilized by double intramedullary pinning.

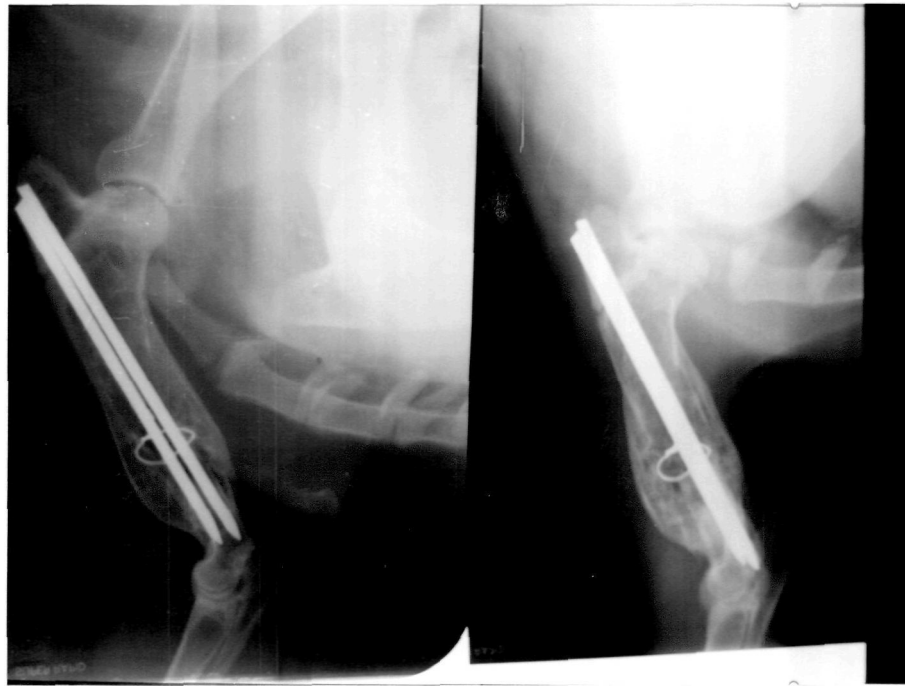

Figure 18. Right: Completely healed fracture after 2 months. Left: Remodeling of the bone after 5 months with retention of pins.

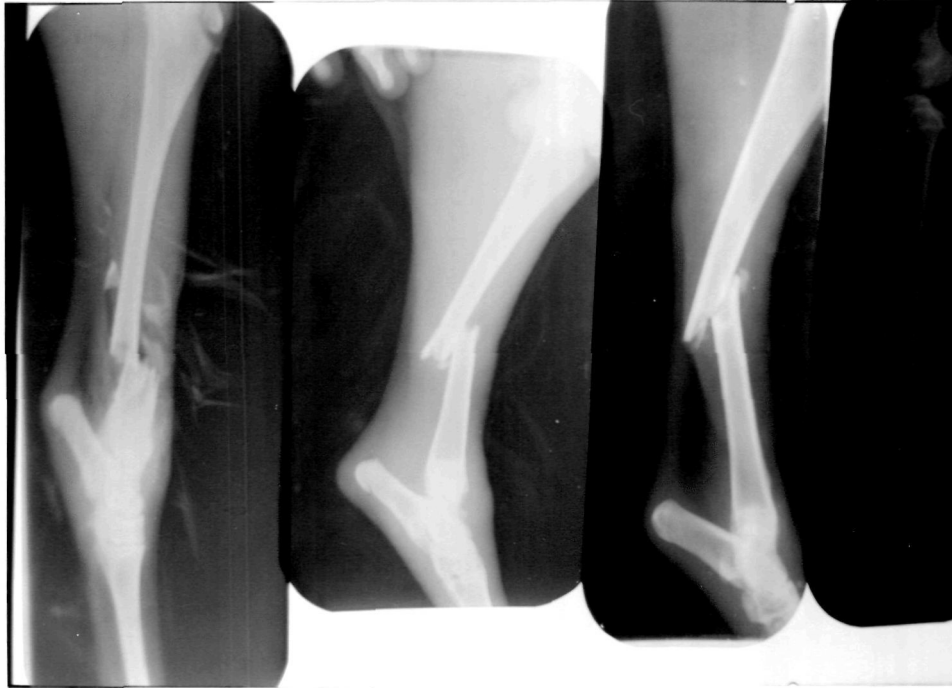

Figure 19. Lateral radiographs of different types of fractures of the tibia.

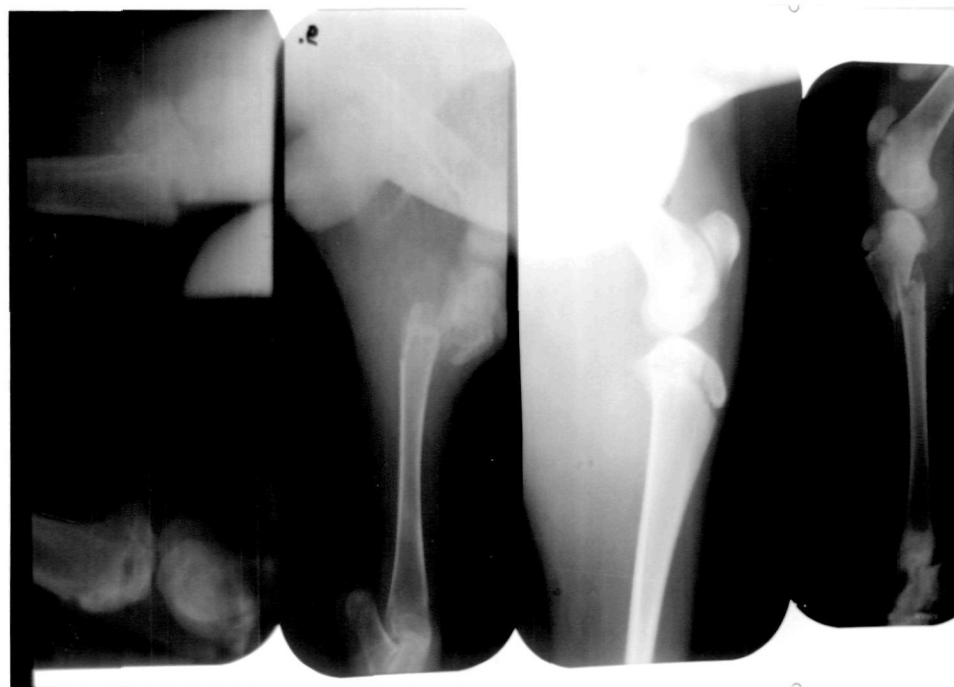

Figure 20. Right to left: Lateral radiograph of different types of fractures of upper extremity of tibia. Extreme left: A.P. and Lateral radiograph of fracture of upper extremity of tibia.

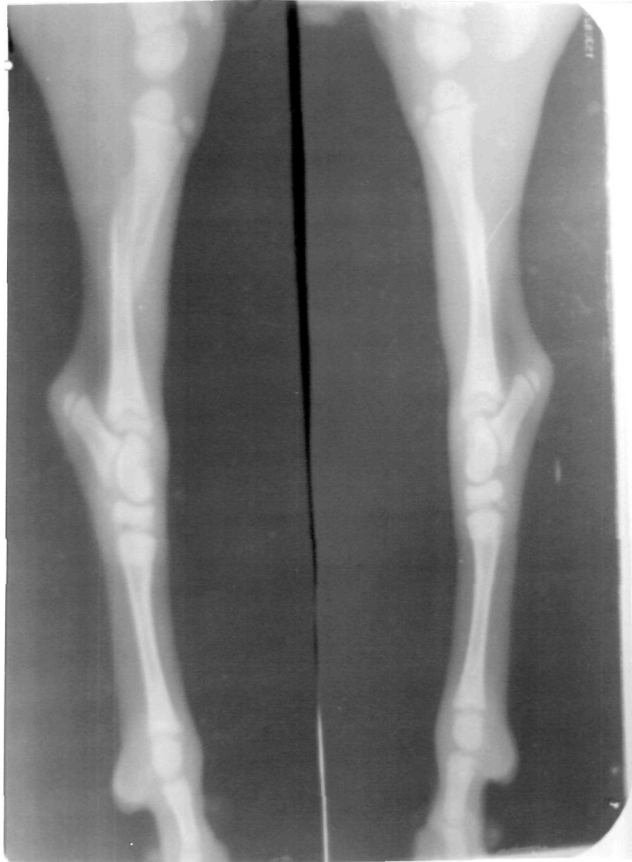

Figure 21. Lateral radiograph of a case of bilateral fracture of tibia in a 10 days old kid.

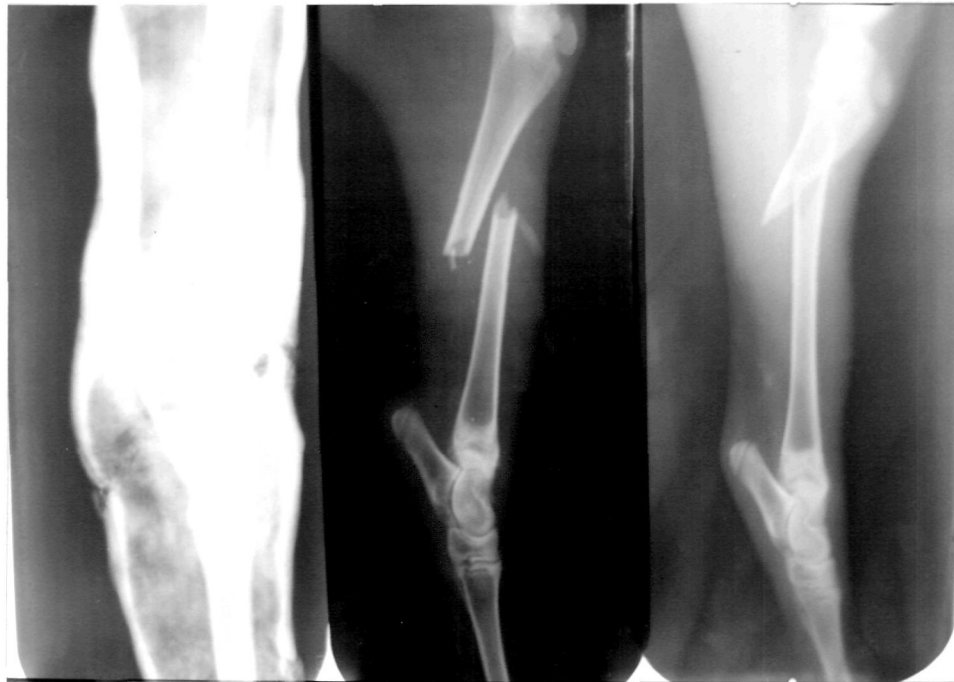

Figure 22. Lateral radiograph of different types of fracture of tibia.

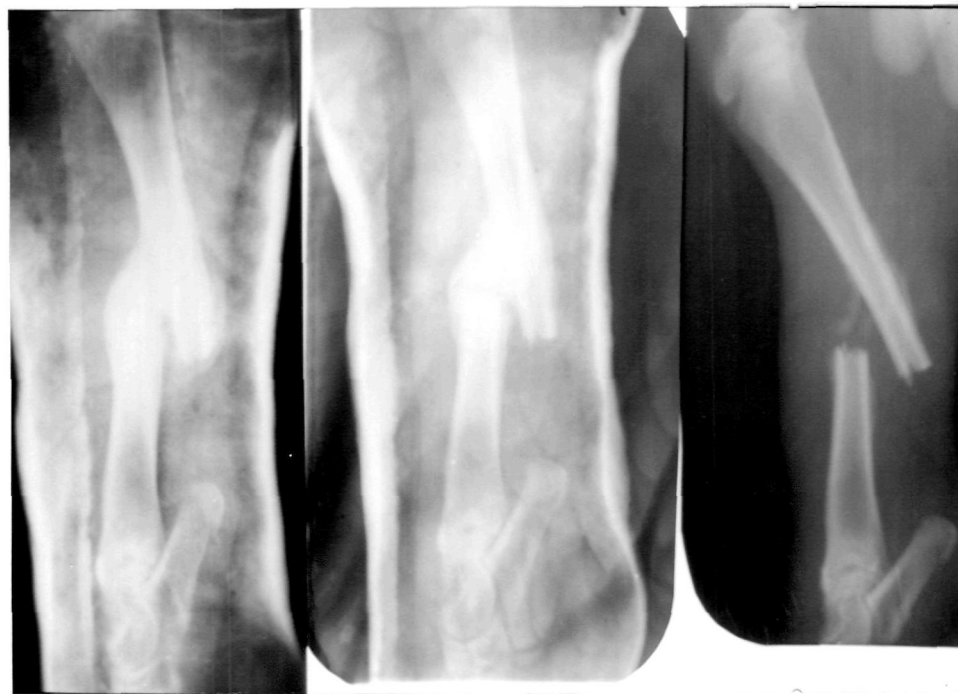

Figure 23. Lateral radiograph of healed fracture of tibia showing malunion 4 weeks.

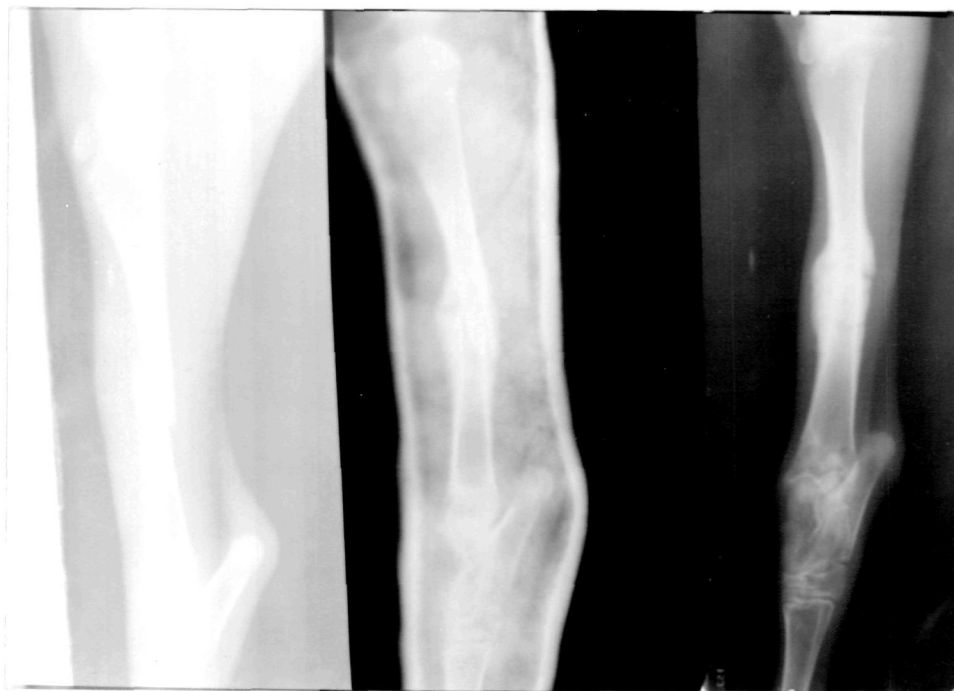

Figure 24. Lateral radiograph of healed fracture of tibia showing union in 3 weeks. Fracture line is still visible.

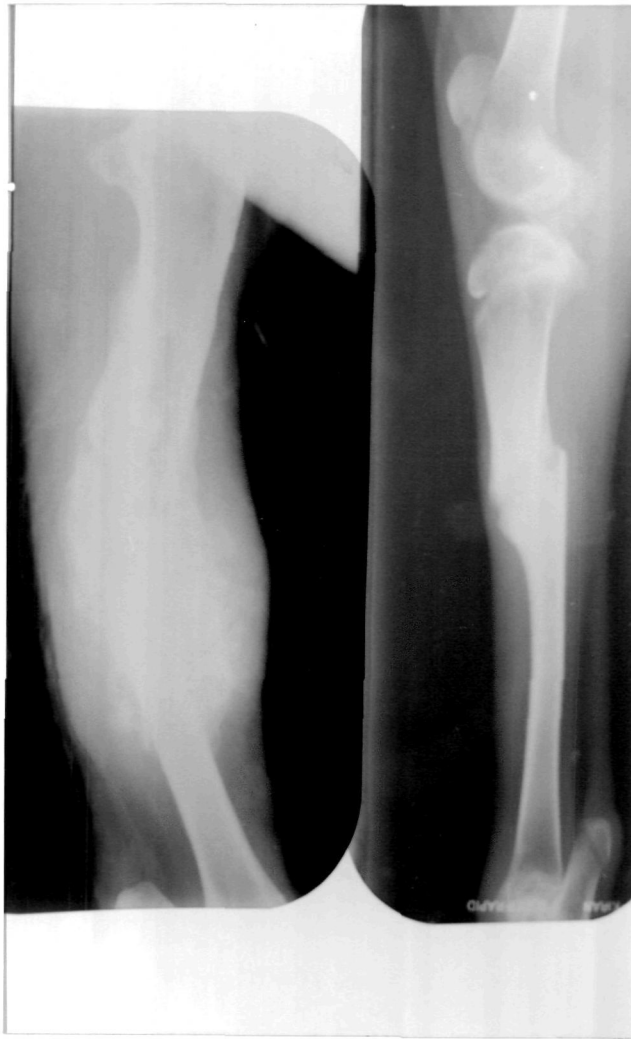

Figure 25. Lateral radiograph of a healed compound fracture of tibia in 10 weeks and malunion of fracture of shaft of tibia.

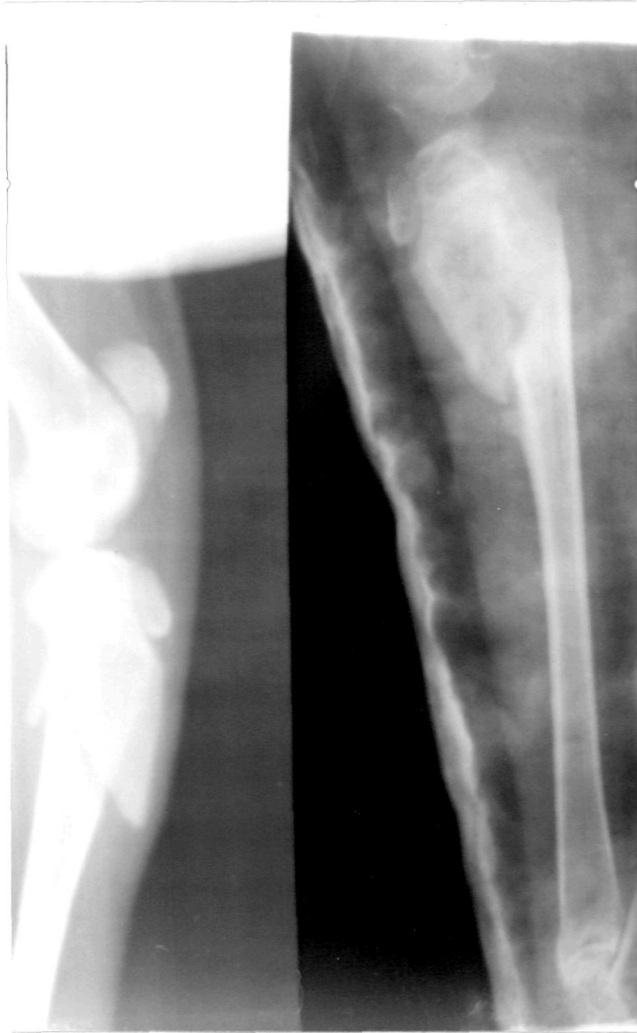

Figure 26. Left: Lateral radiograph of upper extremity tibia fracture in a buck. Right: Fracture one month after immobilization with plaster of Paris cast showing healing.

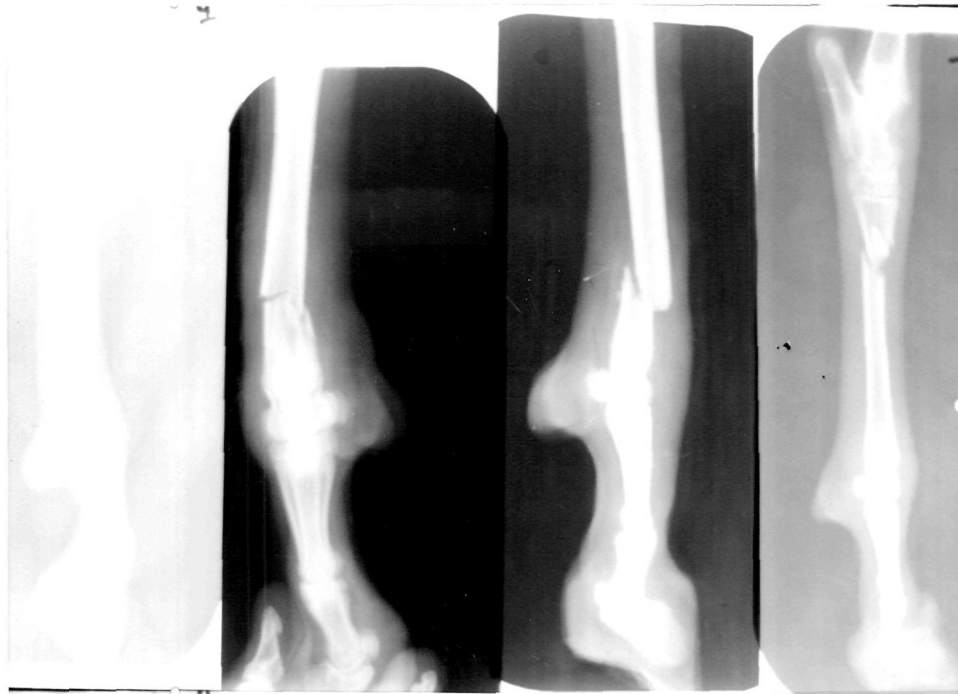


Figure 27. Lateral radiograph showing various types of fracture of metatarsals.

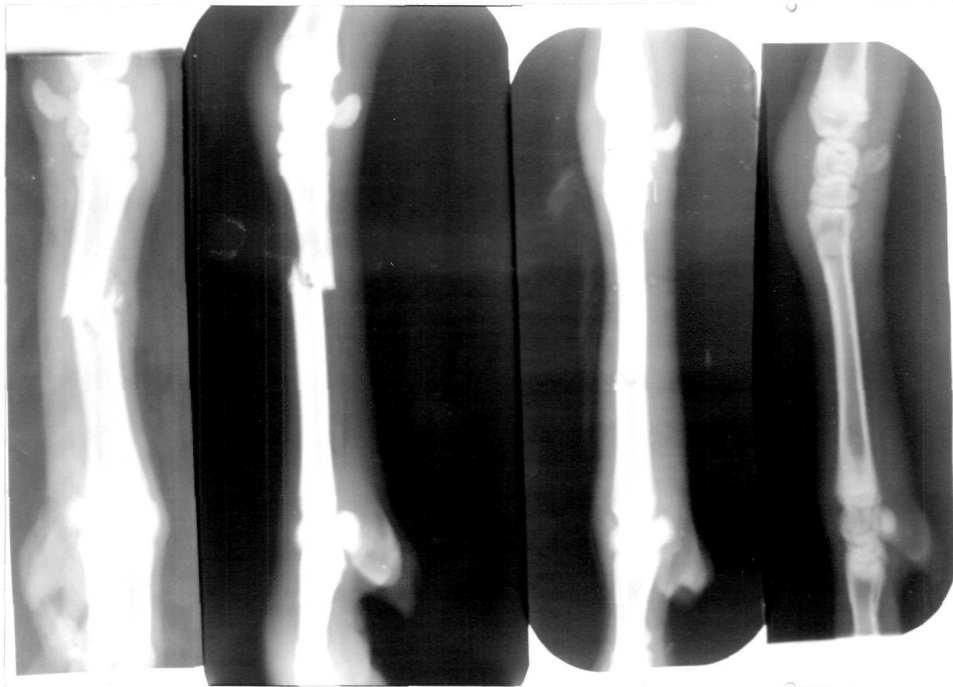


Figure 28. Lateral radiograph showing various types of fracture of metacarpals.

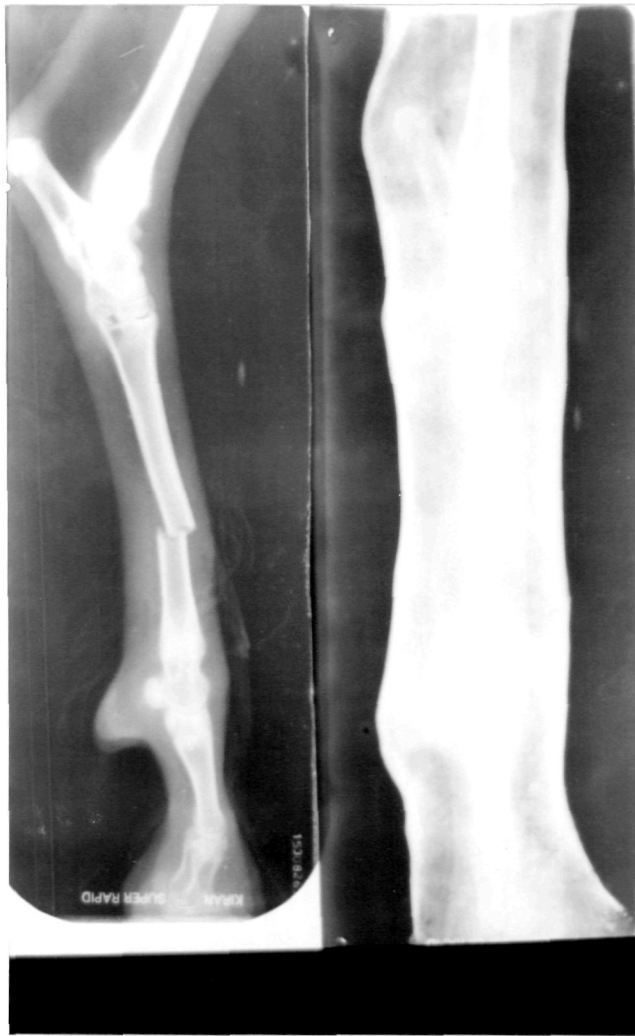

Figure 29. Lateral radiograph of transverse fracture of metatarsal showing perfect immobilization with plaster of Paris cast.

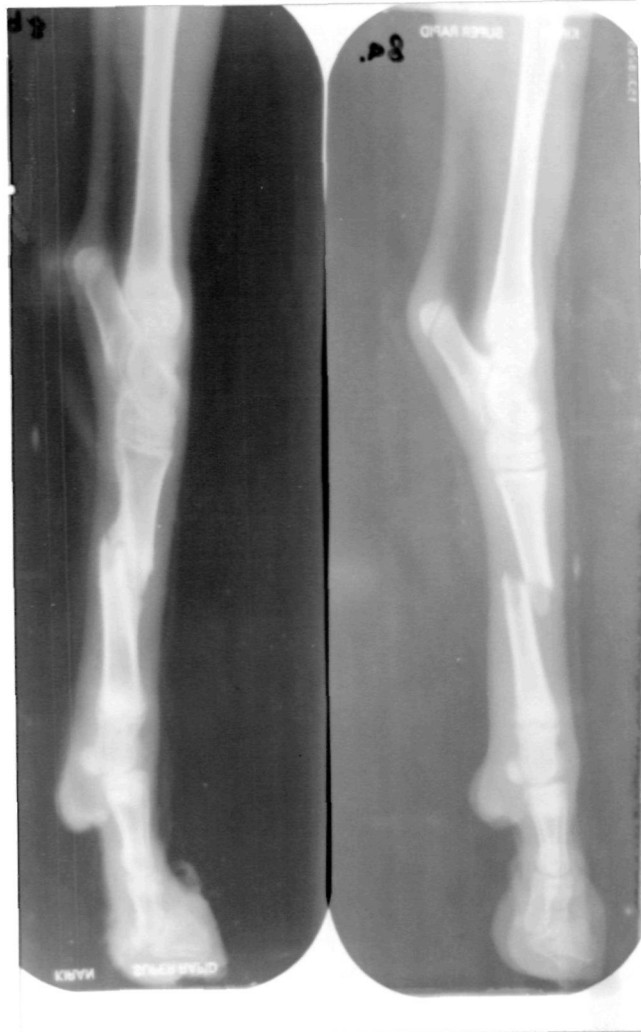

Figure 30. Lateral radiograph showing transverse fracture of metatarsal and its healing with slight malunion in 4 weeks.

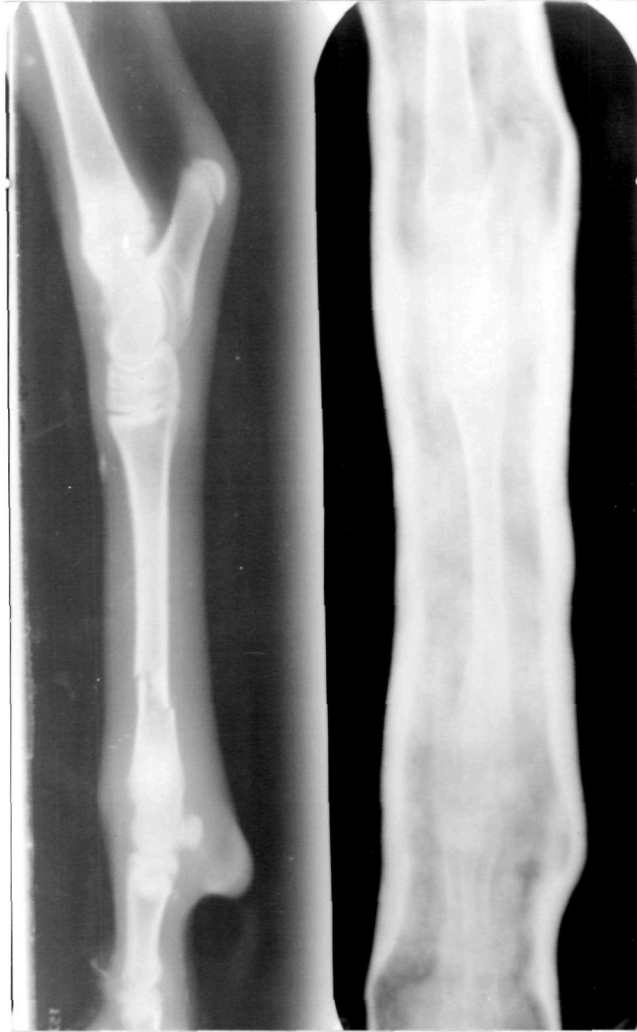

Figure 31. Lateral radiograph of of distal extrimity of metatarsal and its immobilization by plaster of Paris cast.

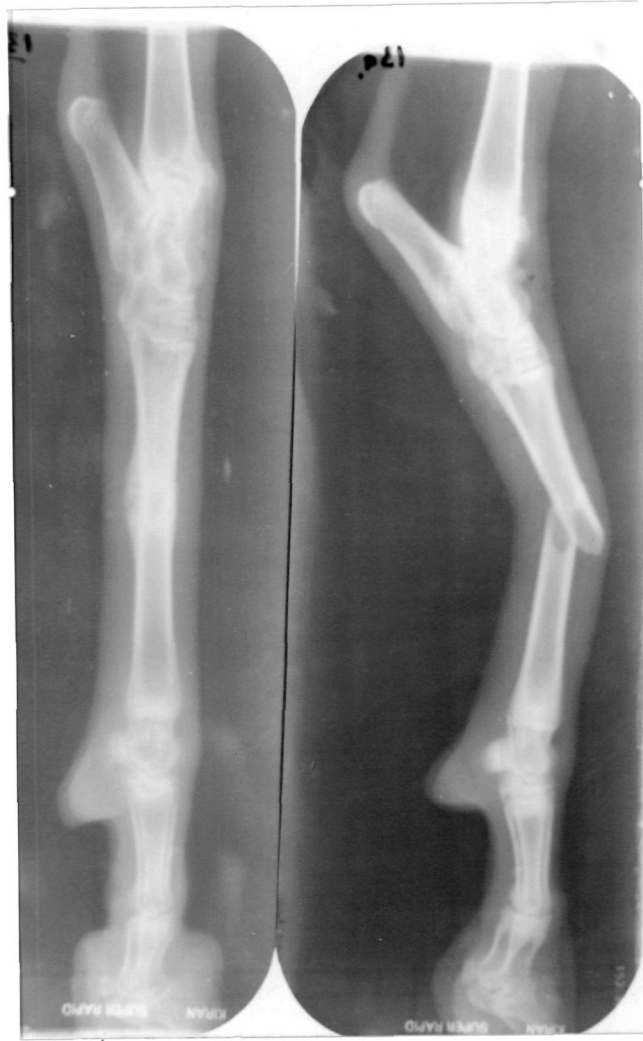

Figure 32. Lateral radiograph of an oblique fracture of mid-shaft of metatarsal and its perfect healing after 4 weeks with plaster of Paris cast.

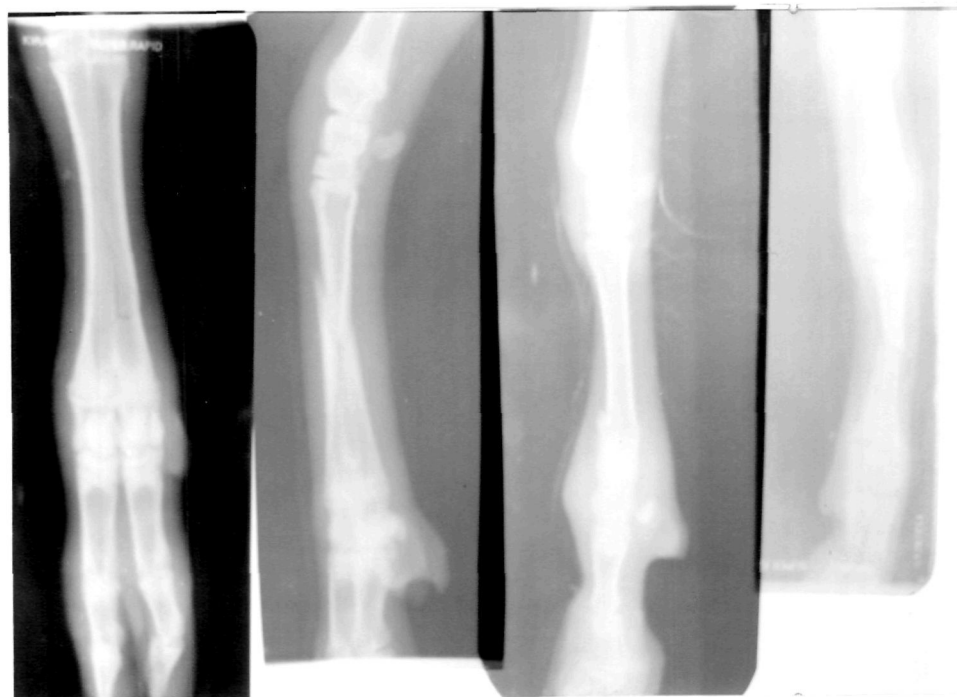


Figure 33. Lateral and antero-posterior views of radiograph showing various types of fracture of metacarpals.

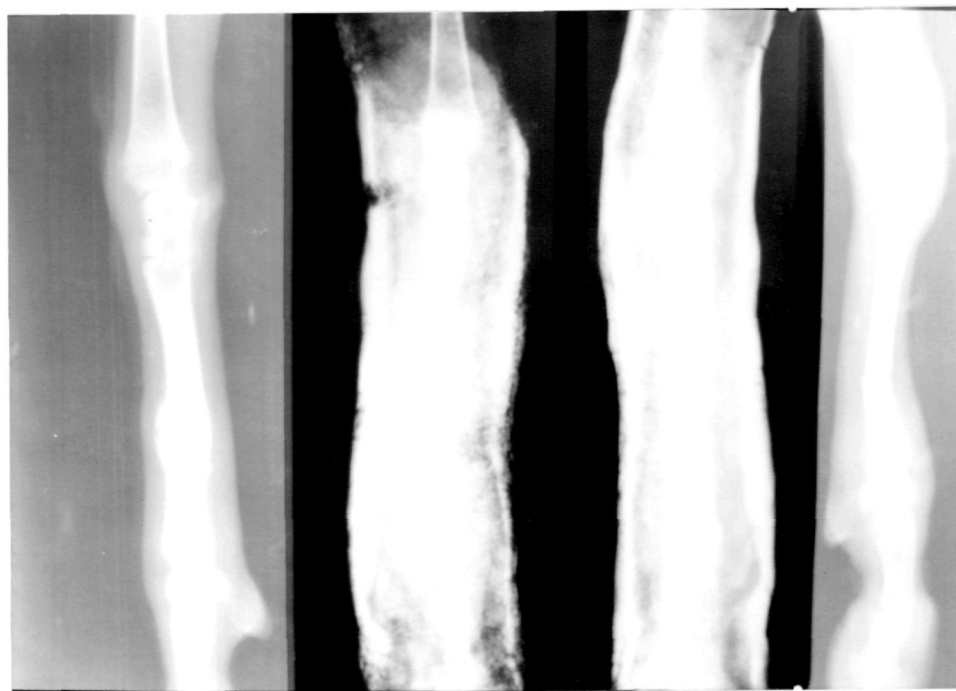


Figure 34. Lateral radiograph of transverse fracture of metacarpal before immobilization, after one week, two week and after opening of the plaster of Paris cast 3 weeks later. Note fracture line is still visible.

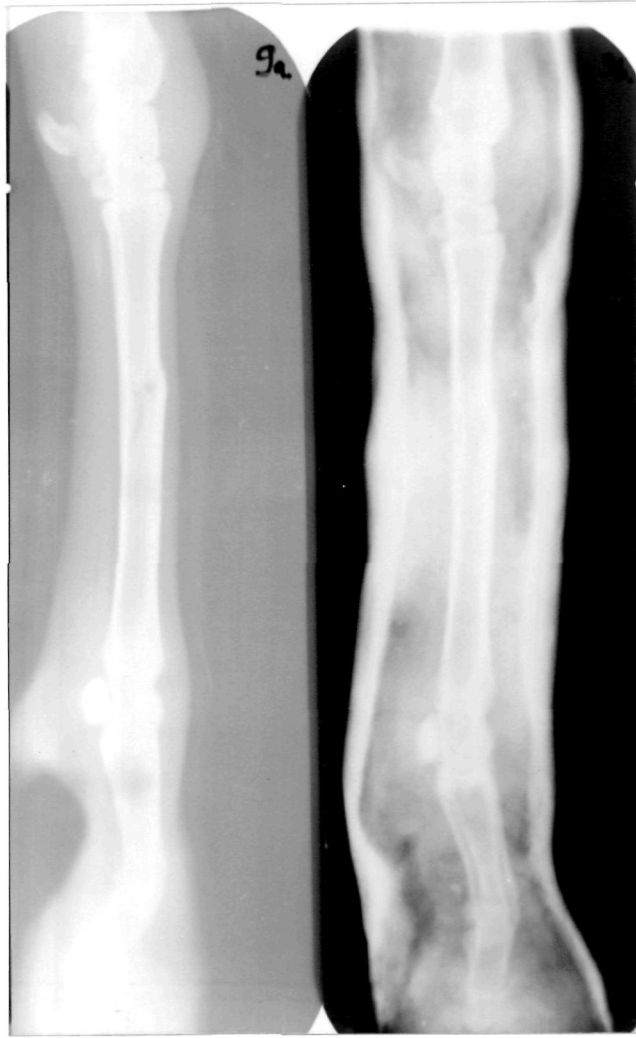

Figure 35. Lateral radiograph of a chip fracture of metacarpal and its immobilization with plaster of Paris cast.

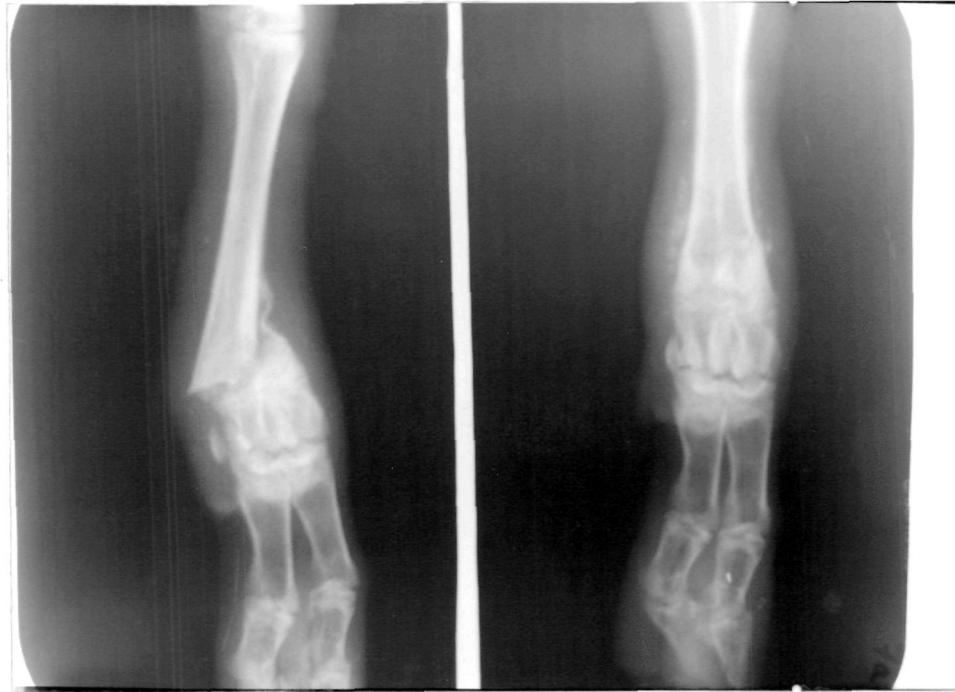

Figure 36. Anterio-posterior view of a 10 days old bilateral fracture of metacarpal showing slight periosteal reaction.

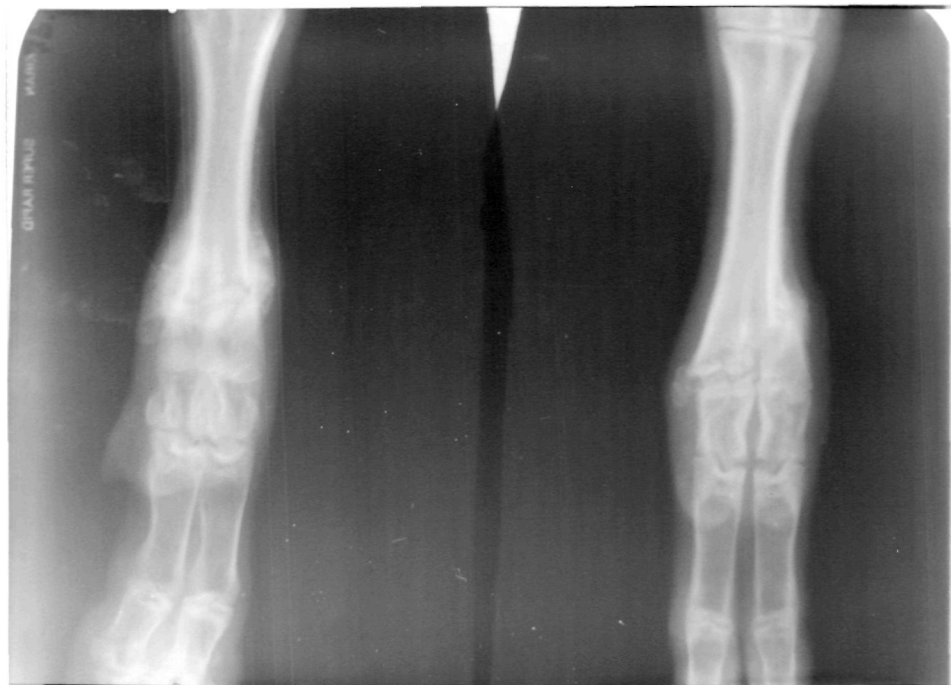

Figure 37. Anterio-posterior view of the same animal after 15 days of immobilization with plaster of Paris cast showing healing.

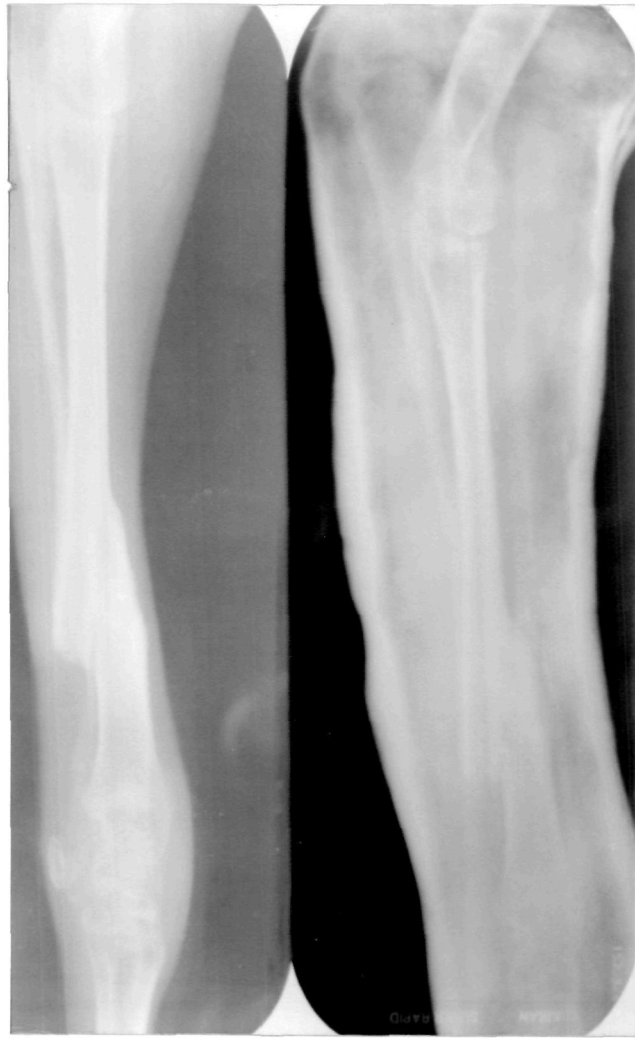

Figure 38. Lateral radiograph of a fracture of radius ulna showing malunion.

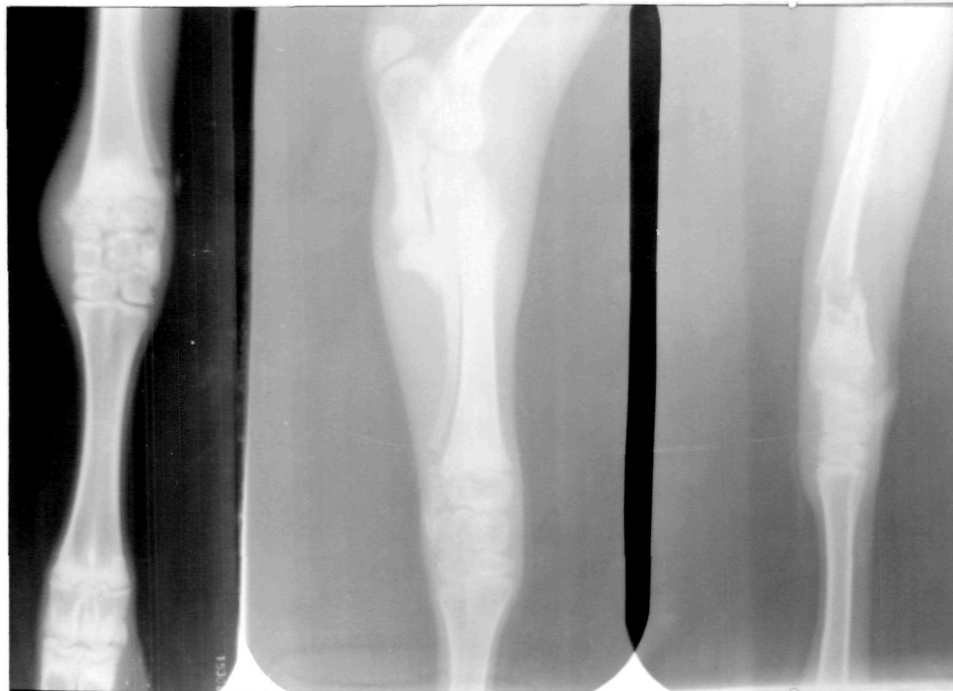


Figure 39. From Right to left: Lateral radiograph of fracture of distal extremity of radius ulna, of upper extremity of radius ulna in a one day old kid, and anterior posterior view of epiphyseal separation of distal extremity of radius.

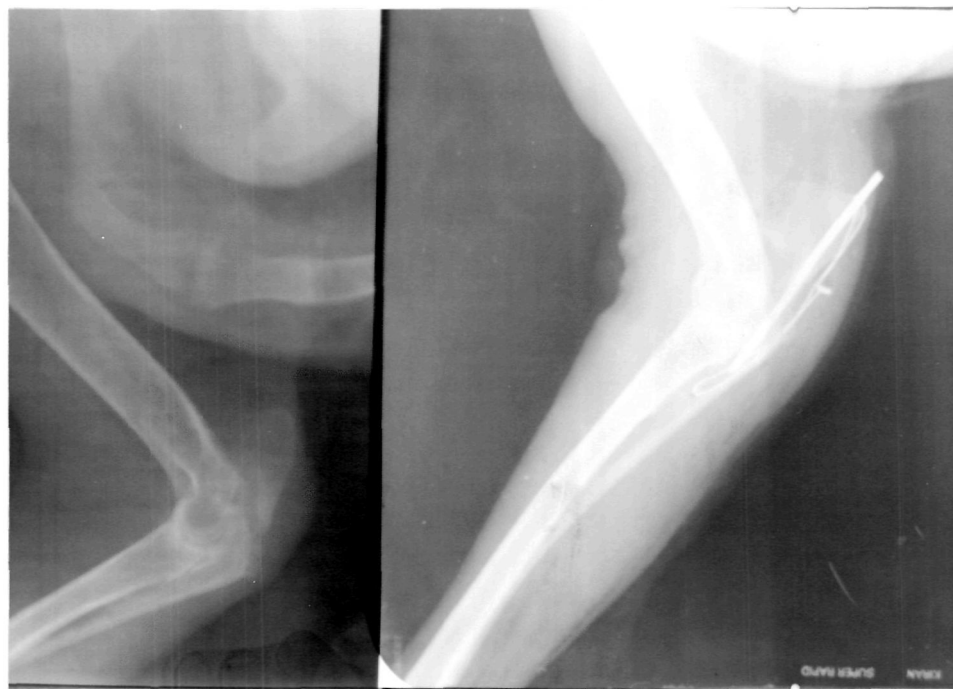

Figure 40. Lateral radiograph of the fracture of olecranon process and its immobilization with intramedullary pin and tension band wire.

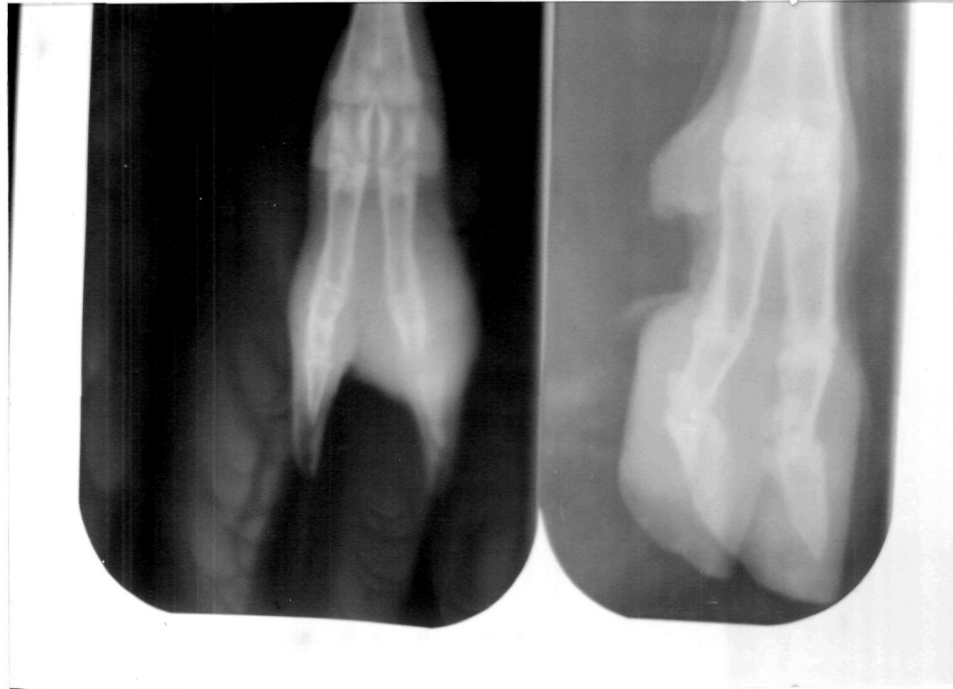

Figure 41. A.P. view of fractures of third phalanx. Left: infection at the site was also present (Radiodense area).

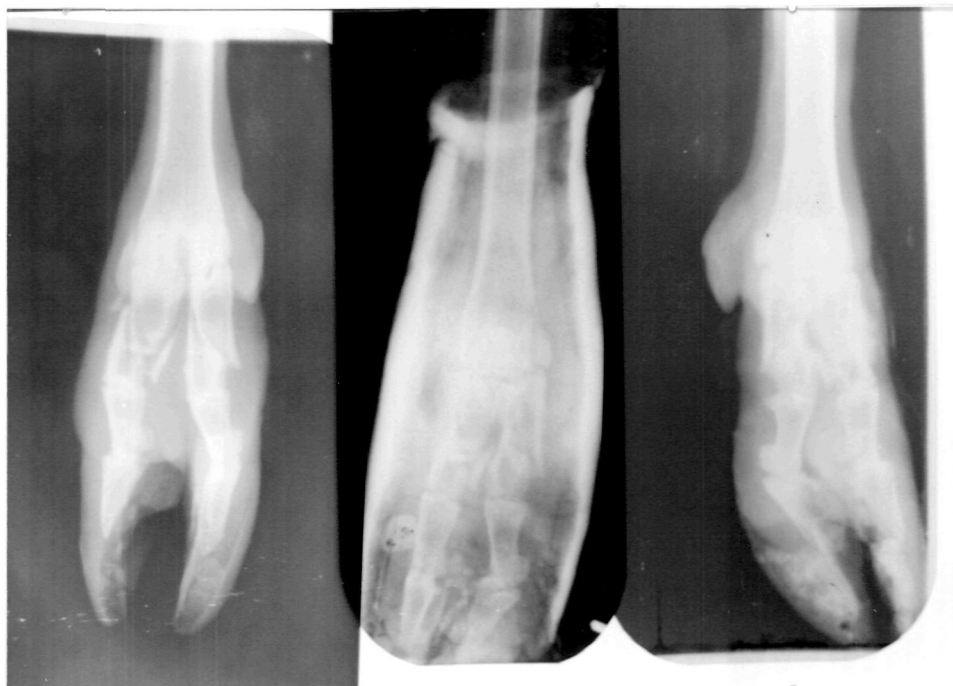

Figure 42. A.P. view of fracture of both first phalanx in a goat, its immobilization with plaster of Paris cast, and after healing.

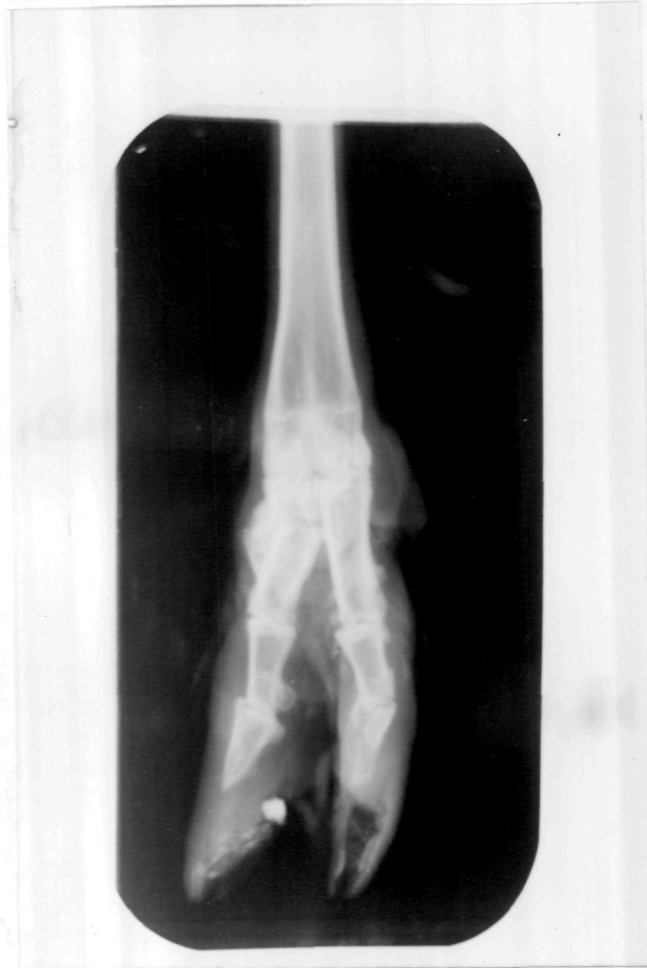

Figure 43. A.P. view of healed fracture of first phalanx.

APPENDIX I : CASE RECORD PROFORMA

COLLEGE OF VETERINARY AND ANIMAL SCIENCE, BIKANER

CLINICAL AND RADIOLOGICAL EVALUATION OF FRACTURES IN GOAT
(*Capra hircus*)

Out Door No. Date :

1. Owner's Name and Address:

2. Age: Breed:.....Sex:.....

3. Brief history :.....

4. Classification of Fractures:

A. Fracture of	Type of	Fracture of	Type of
Fore limb	Fracture	Hind limb	Fracture
	closed/open		closed/open
i. Scapula		Pelvis	
ii. Humerus		Femur	
iii. Radius Ulna		Tibia	
iv. Metacarpal		Metatarsal	
v. Carpals		Tarsals	
vi. Phalanx I		Phalanx I	
	II		II
	III		III

Other bones

5. Clinical Signs:

6. Radiographic details:

i. Factors

ii. Position

iii. Radiographic signs (including nature of fracture)

7. Treatment adopted:

8. Follow up and Prognosis:

APPENDIX II: SEX WISE CLASSIFICATION OF FRACTURES OF VARIOUS BONES IN THE ANIMALS OF GROUP A.

Bone	Male	Female	Total	Percentage
Tibia	13	23(2)	36(2)	25.17
Metacarpal	10	21(4)	31(4)	21.67
Metatarsal	8	15(2)	23(2)	16.08
Femur	2	14	16	11.18
Humerus	4	8	12	8.39
Radius Ulna	3	8	11	7.69
Phalanx	1	7	8	5.59
Tarsal	-	2(1)	2(1)	1.39
Pelvis	-	1	1	0.69
Mandible	-	1	1	0.69
Rib	-	1	1	0.69
Vertebra	-	1	1	0.69
Total:	41	102	143(9)	
Percentage	28.67%	71.32%		

APPENDIX III- AGE WISE DISTRIBUTION OF FRACTURES OF VARIOUS BONES IN ANIMALS OF GROUP A

Bone	0-1 year	1-3 year	3 year above	Total
Tibia	22	11(2)	3	36(2)
Metacarpal	17(1)	12(2)	2(1)	31(4)
Metatarsal	15(1)	7(1)	1	23(2)
Femur	6	8	2	16
Humerus	6	5	1	12
Radius Ulna	4	6	1	11
Phalanx	2	3	3	8
Tarsal	1(1)	1	-	2(1)
Pelvis	-	1	-	1
Mandible	1	-	-	1
Rib	-	1	-	1
Vertebra	1	-	-	1
Total:	75	55	13	143
Percentage	52.44%	38.46%	9.09%	

Number in the parentheses indicates compound fractures.

APPENDIX IV - LIMB WISE CLASSIFICATION OF FRACTURES OF VARIOUS BONES IN THE ANIMALS OF GROUP A and B.

Bone	Group A	Group B*
A. Fore limb		
1. Scapula	-	6
2. Humerus	12	77
3. Radius Ulna	11	88
4. Metacarpal	31(4)	346
5. Phalanx	5	-
Total:	59(4)	517
Percentage:	41.25%	40.96
B. Hind limb		
1. Pelvis	1	6
2. Femur	16	124
3. Tibia	36(2)	211
4. Metatarsal	23(2)	350
5. Tarsal	2(1)	17
6. Phalanx	3	-
Total:	81(5)	708
Percentage:	56.64%	56.10

* = Due to lack of information the phalangeal fractures could not be divided into fore and hind limb.

APPENDIX V : CLASSIFICATION OF FRACTURE LINE OF VARIOUS BONES OF GROUP A.

Bone	Diaphysis												
	T	O	Co.	E	M	C	T	U	M	L	N	L.E.	T
1.Femur	4	8	1	-	3	-	16	4	10	1	1	-	16
2.Tibia	13	10	8	3	-	2	36	10	15	6	3	2	36
3.Metatarsal	5	12	5	-	1	-	23	-	11	8	2	2	23
4.Humerus	4	7	1	-	-	-	12	2	6	4	-	-	12
5.Radius ulna	6	1	1	2	1	-	11	1	4	2	2	2	11
6.Metacarpal	10	9	8	3	-	1	31	2	15	8	2	4	31
7.Phalanx	5	2	1	-	-	-	8	2	5	-	1	-	8
Total:	47	49	25	8	5	3	137	21	66	29	11	10	137
Percentage	34.5	36.0	18.2	5.8	3.6	2.2		15.3	48.1	21.1	8.0	7.3	

T= Transverse, O= Oblique, Co. = Comminuted, E= Epiphyseal,
M= Multiple, C= Chip, U = Upper M= Middle
L= Lower N= Neck, L.E.= Lower extrimity.

APPENDIX VI: VARIOUS TYPES OF TREATMENT ADOPTED FOR THE FRACTURES OF ANIMALS OF GROUP A

Bone	Internal Fixa.		External Fixa.		Not Presen- ted for treatment	Total
	Single IMP	Doulbe IMP	Coapta- tion	Other		
1.Femur	7	5	-	1 (Velpeau)	3	16
2.Humerus	6	2	-	1 (Thomas Splint)	3	12
3.Radius ulna	2	-	9	-	-	11
4.Tibia	-	-	36	-	-	36
5.Metacarpal	-	-	31	-	-	31
6.Metatarsal	-	-	23	-	-	23
7.Phalanx	-	-	7	1 (Amputation)	-	8
8.Tarsal	-	-	2	-	-	2
9.Pelvis	-	-	-	1 (Blistering)	-	1
10.Mandible	-	-	-	1 (External Support)	-	1
11.Rib	-	-	-	1 (Died)	-	1
12.Vertebra	-	-	-	1 (Operated)	-	1
Total:	15	7	108	7	6	143
Percentage:	10.18	4.89	75.52	4.89	4.19	

IMP = Intramedullary Pinning

APPENDIX VII: RESULTS OF EXTERNAL FIXATION TREATMENT ADOPTED FOR THE VARIOUS FRACTURES IN THE ANIMALS OF GROUP A.

	F	H	RU	T	MC	MT	Ph	T	Total
A. Union	1	1	5	18	20	13	6	-	64
B. Complication									
a)Delayed Union	-	-	-	2	2	1	-	-	5
b)Malunion	-	-	3	11	5	6	-	-	25
C. No follow up	-	-	1	5	4	3	1	2	16
Total:	1	1	9	36	31	23	7	2	110

F= Femur H= Humerus RU= Radius ulna
T= Tibia MC= Metacarpal MT= Metatarsal
Ph= Phalanx T= Tarsal

APPENDIX VIII: RESULTS OF INTERNAL FIXATION TREATMENT ADOPTED FOR THE VARIOUS FRACTURES IN THE ANIMALS OF GROUP A.

	Femur*		Humerus*		Olecranon	Total
	Single IMP	Double IMP	Single IMP	Double IMP		
A. Union	3	3	3	2	1	12
B. Complications						
a)Pin Migration	1	1	-	-	-	2
b)Non-union	1	1	-	-	1	3
c)Impaction	1	-	-	-	-	1
d)Splitting	1	-	-	-	-	1
e)Malunion	-	-	1	-	-	1
C. No follow up	-	-	2	-	-	2
Total:	7	5	6	2	2	22

* = Three animals each of humerus and femur fracture were not presented for treatment.

APPENDIX IX: INCIDENCE OF FRACTURES OF VARIOUS BONES OF ANIMALS
OF GROUP B.

Bone	No. of Animal	Percentage
1. Metatarsal	350 (17)	27.73
2. Metacarpal	346 (52)	27.41
3. Tibia	211 (11)	16.71
4. Femur	114 (2)	9.82
5. Radius Ulna	88 (1)	6.97
6. Humerus	77 (1)	6.10
7. Phalanx	20	1.58
8. Tarsal	17	1.34
9. Mandible	8	0.63
10. Vertebra	6	0.47
11. Pelvis	6	0.47
12. Scapula	6	0.47
13. Ribs	3	0.23
Total :	1262 (84)	

Numbers in the parentheses indicates compound fractures.