PATHOLOGICAL CONDITIONS AFFECTING THE DOMESTIC PIGEONS (*COLUMBA LIVIA*) IN JAMMU REGION

BY

SYED MEHMOOD

(J-14-MV-406)

Thesis submitted to Faculty of Postgraduate Studies

In partial fulfillment of requirements

for the degree of

MASTER OF VETERINARY SCIENCE

IN

VETERINARY PATHOLOGY

Division of Veterinary Pathology

Sher-e-Kashmir University of Agricultural Sciences & Technology of Jammu

Main Campus, Chatha, Jammu 180009

2017

CERTIFICATE-I

This is to certify that the thesis entitled **"Pathological Conditions Affecting the Domestic Pigeons (*Columba livia*) in Jammu Region"** submitted in partial fulfillment of the requirements for the degree of **Master of Veterinary Science** in the subject of **Veterinary Pathology** to the Faculty of Post-Graduate Studies, Sher-e-Kashmir University of Agricultural Sciences and Technology of Jammu is a record of bonafide research carried out by **Mr Syed Mehmood,** Regd. No. **J-14-MV-406,** under my supervision and guidance. No part of the thesis has been submitted for any other degree or diploma. It is further certified that such help and assistance received during the course of investigation have been duly acknowledged.

29/3/17

Dr. Nawab Nashiruddullah
(Major Advisor)

Place: Jammu

Date: 29/03/2017

Endorsed

29/03/17

Dr. Shagufta Azmi
Head of the Division
Date:

CERTIFICATE-II

We, the members of the Advisory Committee of **Mr. Syed Mehmood,** Regd. No. **J-14-MV-406,** a candidate for the degree of **Master of Veterinary Science** in the subject of **Veterinary Pathology,** have gone through the manuscript of the thesis entitled **"Pathological Conditions Affecting the Domestic Pigeons (*Columba livia*) in Jammu Region "** and recommend that it may be submitted by the student in partial fulfillment of the requirements for the degree.

Dr. NawabNashiruddullah
Major Advisor
Advisory Committee

Place: Jammu

Date: 29th March 2017

Advisory Committee Members

Dr. Shafiqur Rahman,
Asstt. Prof.,
Div. of Vety. Pathology

Dr. Anand K. Pathak,
Asstt. Prof.,
Div. of Animal Nutrition

Dr. A. K. Taku (Dean PGS Nominee)
Professor,
Division of Veterinary Microbiology

CERTIFICATE-III

This is to certify that the thesis entitled **"Pathological Conditions Affecting the Domestic Pigeons (*Columba livia*) in Jammu Region"** submitted by **Mr. Syed Mehmood,** Regd No **J-14-MV-406** to the Faculty of Post-Graduate Studies, Sher-e-Kashmir University of Agricultural Sciences and Technology of Jammu in partial fulfillment of the requirement for the degree of **Master of Veterinary Science** in the subject of **Veterinary Pathology** was examined and approved by the Advisory Committee and External Examiner on 29.03.17

29.3.17.

External Examiner

29/3/17

Dr. NawabNashiruddullah
Major Advisor

29/03/17

Dr. Shagufta Azmi
Head
Division of Veterinary Pathology

03/4/2017

Dr. M.M.S Zama
Dean
F.V.Sc. & A.H, R.S. Pura

First of all, I bow my head with great reverence to the Omnipresent, Omnipotent and Omniscient for giving me this opportunity to add another achievement to my professional profile as he is the only cause behind every effect. Next come my parents without whose inspiration I wouldn't have completed this journey. They are the greatest forces of my mind, never letting me stop in the way and their untiring efforts since my childhood pushed me to reach this juncture.

It's my great fortune and luck that gave me the privilege of completing this research work under the amicable guidance of ***Dr. Nawab Nashiruddullah****, Associate Professor, Department of Veterinary Pathology. To work under him was awesome and the experience of research work gained under his advisory was totally incomparable. I simply feel myself blessed being provided with an academic advisor like him.*

I feel bereft of words in expressing my heartiest gratitude and indebtedness to the members of my advisory committee ***Dr. Shafiqur Rahman,*** *Assistant professor, Division of Veterinary Pathology,* ***Dr. A. K. Taku,*** *(Dean PGS Nominee) Professor and Head, Professor, Division of Microbiology,* ***Dr. A K Pathak****, Asstt. Prof., Div. of Animal Nutrition, for their valuable suggestions, generous help, sincere advice, and excellent encouragement in conducting this research work.*

I am highly obliged to faculty of my Department to ***Dr. Shagufta Azmi*** *(Head Division of Veterinary Pathology) and* ***Dr. Shilpa Sood****, (Asstt. Professor, Division of Vety. Pathology) for their suggestions and guidance throughout the period of study.*

I would like to extend my sincere thanks to ***Dr. Jafrin Ara Ahmed*** *(Asstt. Professor, Division of Vety. Physiology)* ***Dr. Sanku Borkataki*** *(Asstt. Professor, Division of Vety. Parasitology)* ***Dr. Mohd Altaf Bhat*** *(Professor, Division of Vety. Microbiology) for their technical support.*

Words are not enough to express my internal feelings towards my friends Drs. Mir Mudasir, Menakshi Bhagat, Sanak Sharma, Bhavesh Sharma and my junior Stuti Sharma, Navrose Sangha for their enthusiastic moral support, affection and constant encouragement throughout.

My sincere thanks to ***Hon'ble Vice Chancellor*** *of SKUAST-Jammu for allowing me to undertake the study and for providing necessary facilities. It is rearest to thank* ***Director Education, Dean*** *(FVSc. & A.H) and* ***Associate Dean*** *(FVSc & A.H) for their courteous & indulgent moral, , for the necessary help and facilities provided during this study.*

I shall fail in my duty, if I don't thank the non teaching staff members of the Division of Vety. Pathology, Joginder Ji, Mohinder Ji and Kiran mam who were ever ready to help me.

I humbly acknowledge the unconditional and unlimited love of my parents (Syed Hadi Rizvi & Leela Rizvi), brothers and sisters who continuously inspired me to reach this stage.

Indeed the words at my command are not adequate to express my special thanks to Dr. Mir Muddasir, Mamu Ali Rizvi, Chocho Khaira and very close friends Dr. Javid Jameel, Dr. Anwar, Dr. Shafat Hussain, without them my life would have been incomplete.

I will be failing in my duty if I don't express my sympathy to all those experimental birds to which I gave sufferings for the sake of science and knowledge.

Going through this research work and writing this manuscript has been very important event of my life which I can never forget for the bright and dark phases of life showed to me. Finally, I am again thankful to all those known and unknown hands that helped me to reach this destination and also express my apology that I could not mention them personally one by one.

Last but not least, I feel pleasure in thanking Global Village, Kachi Chawni, Jammu for their intense endeavour and for giving final shape to my thesis.

Place:Jammu

Syed Mehmood.
Signature of Student

Date_29/03/2017

ABSTRACT

Title of the Thesis	:	**"Pathological Conditions Affecting the Domestic Pigeons (*Columba livia*) in Jammu Region"**
Name of Student	:	**Syad Mehmood**
Registration No.	:	**J-14-MV-406**
Major Subject	:	Veterinary Pathology
Name and Designation of Major Advisor	:	**Dr. Nawab Nashiruddullah** Associate Professor Division of Veterinary Pathology, F.V.Sc. & A.H, R.S Pura, Jammu
Degree to be awarded	:	Masters of Veterinary Science, Veterinary Pathology
Year of award of Degree	:	2017
Name of the University	:	Sher-e-Kashmir University of Agricultural Sciences & Technology of Jammu (J&K)

In the present study, a total of approximately 3980 domestic pigeons belonging to various pigeon fanciers were screened for clinical cases of disease affection. Twelve areas were selected for the survey, out of which ten were in the RS Pura sector and two were within the Jammu city limits. Out of the population of pigeons observed, approximately 608 birds were found to be clinically affected with some form of clinical disease or other, based on flock history, clinical examination and laboratory investigation. The overall estimate of disease prevalence amongst pigeons was observed at 15.28%, with the highest prevalence in Banota area and least in Ranbir Singh Pura town area. Mortality was accounted only for birds that were accessed for necropsy examination and 60 pigeons were necropsied with overall mortality of 1.51% between July 2015-June 2016. The predominant cause of death diagnosed was due to *Haemoproteus columbae* induced pneumonia and hepatitis (45.00%); Newcastle disease (20.00%); mycotoxicosis (13.33%); aspergillosis (8.33%); traumatic injury (6.67%); pigeonpox (3.33%); Salmonellosis and colibacillosis (1.67% each). Haemoproteosis (45.00%; 27/60) caused a high mortality amongst pigeons with severe and consistent hepatic and pneumonic lesions. Lung and liver tissue revealed various stages of protozoan parasite development and apparently was target organs of schizogony within vascular endothelium and accompanied by

severe vascular and tissue reaction. A typical round cell granuloma could be seen around blood vessels. Newcastle disease (ND) infection was manifested predominantly in a severe neurological form with characteristic malacia and demyelination of brain parenchyma. Satellitosis, microgliosis and neuronophagia were also seen. Serum samples collected from 10 out of 12 affected pigeons were found positive by haemagglutination inhibition test with high titres (1/32 to 1/64) of circulating antibodies. Two outbreaks of mycotoxicosis (13.33%; 8/60) were suspected amongst pigeons, with typical hepatic degeneration and lesions. Concurrently, renal degenerative lesions were also seen. *Aspergillus flavus* could be isolated and differentiated from feed grains. Tissue and grain samples were positive for Aflatoxin B1, while as citrinin and ochratoxin was also found in the feedgrains. Presence of aflatoxin in feeds and fungal cultures were also detected by UV light. In an outbreak of aspergillosis (8.33%; 5/60) severe granulomatous pneumonia and systemic affections of tissues with typical nodules were seen. Microscopically, both an encapsulated lymphohistiocytic granulomatous pneumonia and a non-encapsulating invasive infection were seen. Sporulating elements invading the bronchial mucosa and lumen of the airways was typical. *Aspergillus fumigatus* organsims were also isolated from the lesions. Four birds were found to have died due to fatal traumatic (6.67%; 4/60) and haemorrhagic injury caused by infighting and killed by raptors. Pigeon pox (3.33%; 2/60) was easily recognizable with scabby lesions on the unfeathered parts of the. Two mortalities amongst young birds with both cutaneous and severe diptheritic form of the disease were observed. Typical lesion was characterized by ballooning degeneration of keratinocytes containing eosinophilic A-type intracytoplasmatic inclusions. Isolation of *Pigeon pox* virus revealed pock lesions on the chorioallantoic membrane (CAM) on 14th day developing chicken embryo. Colibacillosis (1.67%; 1/60) and salmonellosis (1.67%; 1/60) was diagnosed in one bird fatalities each and confirmed with isolation of bacteria, biochemical tests and morphological characteristics. Both live and dead pigeons were examined externally revealed numerous ectoparasites and as many as six species of ectoparasites were collected from the pigeons or their lofts. They included the chewing lice *Columbicola columbae*, small pigeon louse *Campanulotes bidentatus*, pigeon flatfly or louse fly *Pseudolynchia canariensis*, mite *Psoroptes* sp. and a flea tentatively identified as *Ctenocephalides* sp. Besides, there were many mosquito and fly species which were not identified. Gastrointestinal parasites

included the tapeworm *Raillietina* sp. (25%; 15/60), the large roundworm *Ascaridia* sp. (5%; 3/60) and the hairworm *Capillaria* sp. (6.67%; 4/60 Besides, *Eimeria* sp (58.3%; 35/60), *Cryptosporidia* sp. (50.0%; 5/10) and *Haemoproteus columbae* gametocytes (26.6%; 8/30) were recorded. Both macrogametocytes, microgametocytes, immature stages, extra-corpuscular forms could be detected in the blood. Haematological studies of *Haemoproteus* infected and non-infected pigeons revealed a significant decrease ($p<0.05$) in Hb, PCV and eosinophilia in diseased birds. Twenty-four pooled faecal samples examined from six select villages of Jammu district in the four recognized seasons (Monsoon, post-monsoon, winter, summer) revealed presence of different parasitic ova with Ascarid eggs least prevalent whereas, *Eimeria* sp. was highest. *Capillaria* eggs were relatively abundant with no particular seasonal prevalence. *Raellietina* sp. was the most common metazoan enteric infestation but its observed prevalence apparently was lowered in the peak summers.

Keywords: Bacteria, disease, fungus, mycotoxin, parasite, pathology, pigeon, protozoa, virus

Signature of Major Advisor

Signature of Student

DETAILS OF CHAPTERS

CHAPTER	PARTICULARS	Page No.
I	INTRODUCTION	1-3
II	REVIEW OF LITERATURE	4-20
III	MATERIALS AND METHODS	21-29
IV	RESULTS	30-68
V	DISCUSSION	69-84
VI	SUMMARY AND CONCLUSIONS	85-91
	BIBLIOGRAPHY	92-111
	VITA	

LIST OF TABLES

TABLE NO.	PARTICULARS	PAGE NO.
4.1	Study area with number of birds reared and affected with clinical disease.	31
4.2	Cause of mortality in pigeons due to various pathological conditions and disease affection.	33
4.3	Haemagglutination Inhibition (HI) test on suspected clinical samples of New Castle Disease (NCD) in pigeons.	39
4.4	Mycotoxin analysis of feed and tissue samples of pigeons (PLAFFS, TANUVAS, Chennai).	49
4.5	Relative prevalence of different pigeon ectoparasites.	53
4.6	Helminthic parasites recovered from GIT of pigeons in Jammu region.	54
4.7	Relative prevalence of protozoan parasites in pigeons from clinical and post-mortem samples	54
4.8	Haematological indices of domestic pigeons affected by various disease (*Columba livia*) in Jammu region (Mean ± S.E.)	62
4.9	Seasonal prevalence of parasitic load in pooled faecal samples from pigeons of six different villages	66

LIST OF FIGURES

FIGURE NO.	PARTICULARS	PAGE NO.
4.1	A typical pigeon loft on the terrace near the International Indo-Pakistan border, Jammu.	32
4.2	Lesions of Newcastle disease in various visceral organs of affected pigeons (*Columba livia*).	35
4.3	Neural lesions of Newcastle disease in affected pigeons (*Columba livia*).	36-37
4.4	Serological diagnosis of and confirmation of Newcastle disease in pigeons (*Columba livia*) using HA and HI assay	38
4.5	Pigeon pox lesions in affected pigeons (*Columba livia*).	41
4.6	Lesions observed in pigeon (*Columba livia*) colibacillosis, culture of *Escherichia coli* and biochemical characteristics for confirmation of *E. coli*	42
4.7	Lesions observed in pigeon (*Columba livia*) salmonellosis, culture of *Salmonella* and biochemical characteristics for confirmation of *Salmonella* sp.	45
4.8	Lesions of aspergillosis caused by *Aspergillus fumigatus* in affected pigeons (*Columba livia*).	46-47
4.9	Hepatic and nephritic lesions associated with spontaneous mycotoxicosis in pigeons (*Columba livia*).	48
4.10	Fungal culture from feeds and detection of aflatoxin in fungal culture and feedgrains by UV light.	51
4.11	Different ectoparasites recovered from pigeons (*Columba livia*).	52
4.12	Cestodes recovered from intestine of pigeons (*Columba livia*).	55
4.13	*Cryptosporidium* sp. observed from cloacal content of pigeons (*Columba livia*). Acid-fast (ZN) stain,100x.	58

4.14	Tissue pathology of *Haemoproteus columbae* infection in pigeons (*Columba livia*).	59-60
4.15	Peripheral blood smears of pigeons (*Columba livia*) showing *Haemoproteus columbae* gametocytes within erythrocytes.	63
4.16	Mean seasonal prevalence (on a relative scale ranging from 0-4) of different parasites in faecal samples of pigeon (*Columba livia*).	64
4.17	Parasitic ova prepared from pooled faecal samples of pigeons (*Columba livia*).	65
4.18	Mortality of pigeons (*Columba livia*) due to traumatic injury.	68

ABBREVIATIONS

%	Percent
µ	Micron
µg	Microgram
@	At the rate of
<	Less than
°C	Degree Celsius
ADA	Aspergillus Differentiation Agar
bp	Base pair
BW	Body weight
CAM	Chorioallantoic Membranes
DLC	Differential Leukocyte Count
DNA	Deoxyribonucleic acid
e.g	For example
ECEs	Embryonated chicken eggs
EDTA	Ethylene diamine tetra acetic acid
EMB	Eosin Methylene Blue
et al.	And other people
Fig.	Figure
FPV	Fowl pox virus
FWPV	Fowl Pox Virus
FP	Fowl Pock
fl	femtoliter
g %	Gram percent
GIT	gastrointestinal tract
gm/dl	Gram per deciliter
Gms	Grams
H&E	Hematoxylin and eosin
HA	Haemagglutination
HAU	Haemagglutination unit
Hb	Haemoglobin
HI	Haemagglutination Inhibition test

HPLC	High Performance Liquid Chromatography
HPTLC	High Performance Thin Layer chromatography
i.e.	That is
i.p	Intraperitoneally
IU/L	International unit per liter
Kg	Kilogram
Km	Kilometer
MAb	Monoclonal antibody
MCH	Mean Corpuscular Heamoglobin
MCHC	Mean Corpuscular Heamoglobin Concentration
MCV	Mean Corpuscular Volume
mg	Milligram
mg/dl	Milligram per deciliter
mg/kg	Milligram per kilogram
mg/L	Milligram per litre
Min	Minutes
MLA	Methylene blue agar
mZN	Modified Zeihl Neelsen
NCD	Newcastle disease
nm	Nanometer
OIE	Office International des Epizooties
os	Per os
PBS	Phosphate Buffered Saline
PCT	Proximal Convulated Tubule
PCV	Packed Cell Volume
PDA	potatoes dextrose agar
pg	pictogram
ppb	Parts per billion
ppm	Parts per million
PPV	Pigeon pox virus
PVDF	Polyvinylidene Difluoride
RBCs	Red blood cells
rpm	revolution per minute
rRNA	Ribosomal ribose nucleic acid

SCID	Severe combined immunodeficient
SE	Standard Error
spp.	Species
STEC	Shiga toxin- producing Escherichia coli
TEC	Total Erythocyte Count
TLC	Total Leukocyte Count
TNF	Tumour Necrotic Factor
UV Radiation	Ultraviolet Radiation
v/v	volume per volume
viz.,	Videlicet (namely)
XLD	Xylose lysine deoxycholate agar

INTRODUCTION

The rock pigeon, *Columba livia,* is essentially a free-living and cliff-dwelling granivorous species, but which is also a direct predecessor of the domestic subspecies *C. l. domestica*. The domesticated pigeon has been around man for thousands of years. Evidence for domestication extends back to 4500 BC in Mesopotamia (modern Iraq) where the oldest known figurines, mosaics, and coins portraying domesticated pigeons have been found in archaeological digs. For the ancient Egyptians, pigeons have been an important food source (Patzke, 2009). During the Middle Ages, nearly every manorial estate in Europe had a dovecote population specifically kept for the use as food. The use of pigeons for courier purposes is also a subject of historical record, dating back to the earliest assignment of carrier pigeons at around 2500 BC, the time of King Dojoiser in Egypt. The British and French governments even awarded honours to pigeons that "served" as a messenger in the time of war (Haag-Wackernagel 1998).

Through millennia of selective breeding, pigeon keepers managed to raise, aside from homing pigeons, various fancy breeds, such as tumblers and pouters. Today, there are almost 800 breeds and 250 species of pigeons, all of which are suspected to have ascended from the rock dove. Today, society does no longer rely on the homing abilities of pigeons to relay information from one place to another. However, this ability gave rise to the sport of pigeon racing employing a whole industrial branch.

Pigeons are amongst the most prevalent and readily observable birds in all provinces of India. Besides constituting a small part of human food, they are used for ornamental or appearance purposes (fancy pigeons) as well as pets, human sport (racers and performers), for biological and medical experimentations, and for teaching the art of taxidermy. Pigeons in this part of the world also have a rich historical and anecdotal background.

Jammu region is traditionally home to many pigeon fanciers who rear pigeons for recreation and sports. Due to the fact that flocks of rock pigeons have adapted so well to life in association with human habitation (Sari *et al*., 2008), they become pests

in domestic, commercial and public premises. More importantly, pigeons pose a serious health threat to millions of people and some of their economic animals.

Wherever found across the globe, pigeons might be potential carriers of numerous other harmful pathogens and therefore a habitual tool to contaminate food and water and circulate illnesses such as psittacosis (ornithosis), histoplasmosis, aspergillosis, cryptococcosis, toxoplasmosis, tuberculosis, vibriosis, encephalitis, Q fever, pox, staphylococcosis, and listeriosis. They thus constitute a major source of infection and transmission of diseases (Marques *et al*. 2007) some of which may contribute to serious public health hazards (Whitman and Grant, 2000). Besides, they themselves are subject to contracting many serious diseases, produced by viruses, rickettsiae, bacteria, fungi, protozoa, helminths and arthropods. Several health problems can affect pigeons, but parasitic infections have been identified to play a major role (Musa *et al.*, 2011). The effects of parasitism on birds are often severe, including retarded growth, low egg production and susceptibility to other infections (Dranzoa *et al.*, 1999).

Pigeons are seen in most regions of the world except in the poles. Pigeons live side by side with human and other animal species in nature and they are bred as a source of food, a hobby, and symbol, for experimental aims (Cooper, 1984; Harlin, 1994). Pigeons are probably the most common nuisance bird. They have adapted to life in the city, and they seem to be everywhere in urban environments. Unfortunately, the bird lovers of the world feed them, and they have developed a dependence upon people, thus reinforcing their dependency upon urban areas. They roost on signs, ledges, almost anywhere, and they bring nesting material and leave droppings everywhere. Pigeons, as everyone knows are swimming with filth and disease (Balicka *et al*., 2007; Rehman, 1993). Those who watch these birds can barely imagine how detrimental their disorderly reproduction may be and how many risk they cause to human health (Tietz-Marques et al., 2007). It interacts with man and other domestic and wild birds portend it as a potential carrier of zoonotic parasites (Adang, 1999). Several health problems can affect pigeon, but parasite infections play a major role. Information on the parasitic infection of domesticated pigeon in different countries appears to be poorly documented (Radfar *et al*., 2011).

While pigeons are commonly kept around the world, pigeon fanciers rarely seek veterinary advice. While in part this is often a commercial decision, based on the value of a racing pigeon, there is also a strong feeling that veterinarians don't understand pigeons (and perhaps pigeon fanciers). Thus this work seeks to redress this situation by making veterinarians aware of the health requirements and diseases of pigeons.

Although mortality amongst pigeons is common due to a variety of disease conditions, however, the disease status of the birds in this region is largely unknown and unreported. As no systemic study was previously carried out in these birds, it is thus envisaged, that through the present study, an investigation of the various pathological, microbiological or parasitic diseases will assist in identification of various pathogens prevalent amongst domestic pigeons of this region. Besides, the study may also aid in formulating appropriate strategies and prophylactic measures to overcome the various diseases, and pave the way for further studies and research on similar health aspects.

In view of the above, the present study has been planned with following objectives:

(i) To survey prevalent disease conditions amongst domestic pigeons in Jammu region through clinical and necropsyexamination as and when available.

(ii) To conduct a detailed necropsyexamination of pigeon carcasses died of natural causes, or biopsy specimens during clinical examination, and record the various gross and microscopic pathologicalchanges.

(iii) To identify both external and internal parasites found during clinical examination, faecal screening and at necropsy and attempt to identify microbial agents from appropriate lesions, if any.

2.2 VIRAL DISEASES

2.2.1 Newcastle disease

Mangat et *al*. (1988) reported an outbreak of paramyxovirus encephalomyelitis (New Castle disease) in racing pigeons. The virus was isolated from pigeons (Singh *et al*., 1989) and pathogenesis of the chicken strain of the virus was experimentally studied in pigeons by Mishra *et al*. (2000). Geetha *et al*. (2014) isolated NDV from cloacal swabs/droppings of pigeons and highlighted the importance of free flying birds in NDV dissemination.

Fagbohun *et al.* (2000) conducted a survey for antibodies to Newcastle disease virus in cattle egrets, pigeons and Nigerian laughing doves at Faculty of Veterinary Medicine, University of Ibadan, Nigeria and reported that all birds are susceptible with more severity in chickens and turkeys compared to ducks and pigeons (Munjeri, 1996). Antibodies to Newcastle disease virus (NDV) were detected in 20% of 15 serum samples of cattle egrets (*Ardeola ibis*), 16.7% 30 sera samples of Nigeran laughing doves (*Streptopelia senegalensis*) and none from sera of 30 pigeons (*Columba livia*) screened for antibodies to NDV using haemagglutination-inhibition (HI) test. The result of HI test on the sera Out of the 15 sera samples screened for NDV antibodies in cattle egrets, a total of 3 representing 20% were positive for NDV-HI antibodies 5 out of 30 sera samples (16.7%) were positive for the same antibody in Nigeria laughing doves. None of the sera sample from pigeons was positive for antibodies to NDV.

Mubarak (2000) demonstrated the pathogenicity of New Castle disease in pigeons by conducted a survey in Faisalabad, Pakistan, to study clinical signs, gross and histopathological lesions in pigeons with naturally occurring Newcastle disease. 14 out of 30 lofts showed clinical signs including greenish white mucoid diarrhoea and nervous signs with high morbidity and mortality. Postmortem examination of affected birds showed lesions in brain, liver, kidneys and spleen and typified in histopathological studies. The study highlighted the widespread prevalence of

Newcastle disease virus in pigeons locally to cause heavy mortality (Shaheen *et al*., 2005).

Liu *et al.* (2006) demonstrated genotypes VIb and VII virus as the main cause of ND in pigeons in China. The emergence of genotype VII virus in pigeons shocked the world, because it was the predominant pathogen in chickens and regarded as the major pathogen causing the fourth panzootic of ND all over the world. The strains causing enzootic ND in pigeons were obtained by collecting the pigeon-origin strains isolated from sick pigeons in China between 1996 and 2005. The majority of the isolates were clustered into a single genetic lineage, termed genotype VIb, and which were typical pigeon PPMV-1, whereas a small number of recent isolates (three strains) were grouped into genotype VIId, a predominant genotype responsible for most Newcastle disease outbreaks in chickens.

Mushtaq *et al.* (2006) experimented on Newcastle disease virus to study various liver enzymes and associated pathological changes in experimentally infected pigeons. One group of pigeons were vaccinated with ND vaccine (LaSota strain) intraocularly after 14 days of procurement, while the other two groups served as vaccinated and non-vaccinated controls. Birds of these two groups were challenged with velogenic strain of field isolate of NDV seven days post-vaccination and kept under observation for 15 days post challenge. Haemorrhages and congestion were observed in trachea, lungs, liver, proventriculus and intestine of pigeons infected with NDV. Concentrations of AST, ALT and ALP did not differ among pigeons of the three groups.

Alexander *et al.* (2011) reported ND viruses virulent for chickens, wild birds, domesticated pigeons and poultry responsible for epizootic in racing pigeons is termed as pigeon avian paramyxovirus type 1, which form the genetic group 4b (VIb) first seen in Europe in 1981, continued during 2000 to 2009, and the virus is probably enzootic in racing pigeons in some EU countries. This virus appears to have spread regularly to wild birds, especially those of the Columbidae family, and has been the cause of significant outbreaks in poultry.

Uthrakumar *et al* (2013) observed a Thermo-stable Newcastle disease virus isolated from Pigeon after exposure to 56 ^{o}C at tenth passage and fifteenth passage to study the variations at molecular level. In the HN gene sequence of progenitor and

thermo-stable strain, substitution of K373I, F374L, M516R, D517V were considered to contribute to the increase in the stability of the protein. In the L gene of the thermo stable strain, variations were observed at many positions and among these the substitutions at position P675H K677R, K893D, R1132K, had charged amino acids, and at L656A, F657V, F869L, T886I, M899I, G1131V, V1675L, had hydrophobic amino acids that could be related to increased stability of L protein at high temperatures. The changes in amino acid sequence in HN and L gene of the thermo-stable strain might render structural variations that might have contributed to the stability of the strain at higher temperature. However, as the passage level increased there was an increase in the time taken to kill the embryos as evident from the increased mean death time.

Carrasco *et al* (2015) conducted an experimental infection with Brazilian Newcastle disease virus strain in pigeons and chickens to study the virus epidemiology, interspecies transmission and virus-host relationships. Four experimental models have been used to analyze the hemagglutination inhibition and reverse transcriptase polymerase chain reaction for detection of virus shedding. These techniques revealed that both avian species, when previously immunized with a low pathogenic Newcastle disease virus strain (LaSota), developed high antibody titres that significantly reduced virus shedding after infection with a highly pathogenic Newcastle disease virus strain. Infected pigeons shed the pathogenic strain, which was not detected in sentinel chickens. In tissue sample analysis by RT-PCR, in both species, the virus was most frequently found in the spleen.

Wang *et al* (2015) conducted an experimental study on Genomic Characterizations and sequencing of Six Pigeon Paramyxovirus Type 1 viruses isolated from Live Bird Markets in China during 2011 to 2013. Phylogenetic analysis based on sequences of complete genomes and six genes revealed that all isolates belonged to genotype VI in class II, but at least 2 sub-genotypes were identified. These results provided the evidence that PPMV-1 could be detected from healthy pigeons.

2.2.2 Pigeon pox

Manuel *et al. (2004*) found two diseased young white-tailed laurel-pigeons (*Columba junoniae*) in Canary Islands Spain. Severe cutaneous yellowish nodular

lesions in feathered and unfeathered areas and depression were observed in affected birds. On histopathological examination, presence of epidermal hypertrophy, hyperplasia in cutaneous lesions and several acidophilic Intracytoplasmic inclusions (Bollinger bodies) was appreciated in affected epithelial cells.

Mohan *et al*. (2008) examined two local breed of pigeons brought by local people to the veterinary dispensary Puducherry (India) and found to be dehydrated and emaciated with Several coalescing, round, yellowish, superficially ulcerated, rough and firm masses (0.5- 1 cm diameter) on the eyelids, beak, and the mouth. Microscopically, skin lesions consisted of swollen and pale keratinocytes with a foamy, vacuolated cytoplasm and single, round, dense eosinophilic Intracytoplasmic viral inclusions (Bollinger bodies) was observed.

Siddique *et al.* (2011) conducted a study to find out the host specificity of pigeon pox virus-1 (PPV-1) and fowl pox virus-2 (FPV-2) following cross infection with field strains from Bangladesh. The cross infection was investigated in five groups (n=5) of pigeons and seven groups of chickens (n=5) four weeks of age. Irrespective of route of inoculation each bird received either 0.1 mL of PPV-1 or FPV-2 having a virus concentration of $10^{6.2}$ EID_{50} and $10^{6.25}$ EID_{50} per 0.1 mL chorioallantoic membrane (CAM) suspension respectively. A group of uninfected control birds were maintained in both cases. All pigeons infected either orally or intravenously did not respond to infection with FPV-2 and did not manifest any pox lesion similarly chickens infected with PPV-1 by oral, intravenous (i.v) or wing-web puncture (WWP) routes did not show any pox lesions except for a “take reaction” at the inoculation site. On the other hand, dispersed pox lesions were noticed in chickens exposed to FPV-2 by all three routes. The severity of infection in experimental birds was manifested with a descending magnitude after i.v, oral and WWP inoculation. Thus it could be concluded that the field isolates of PPV-1 and FPV-2 manifested considerable host specificity to pigeons and chickens respectively.

Pandey *et al.* (2014) confirmed an outbreak of Pox virus infection in pigeons by Polymerase Chain Reaction with P4b gene specific primers to evaluate the virulence characteristics of recently isolated Tanzanian strains of fowl pox virus (FWPV) and pigeon pox virus (PGPV) in chickens

Bwala *et al.* (2015) Isolated pox like lesions from rock pigeon (*Columba guinea*) in the Faculty of Veterinary Science, University of Pretoria, South Africa. At necropsy, coalescing masses of yellowish nodular cutaneous tumour-like lesions principally on the featherless areas were noticed on the dead pigeon's head as well as the beak. Histological examination of the sampled skin lesions revealed multifocal areas of hypertrophic and hyperplastic epidermal epithelial cells with eosinophilic intracytoplasmic inclusion bodies (Bollinger bodies). Extract from the lesion was processed and inoculated on the chorioallantoic membranes (CAM) of 11-day-old embryonated chicken eggs and pock lesions on one of the CAM at day 7 post-inoculation was observed.

Kabir *et al. (2015)* conducted the study for the isolation and molecular detection of recently circulating fowl pox (FP) and pigeon pox (PP) viruses in Bangladesh. Isolation of the viruses was done via CAM route of avian embryos inoculation. Out of 40 FP suspected field samples, 27 (67.5%) were found positive and 13 (32.5%) were negative. Similarly, out of 40 PP suspected field samples, 30 (75%) were positive and 10 (25%) were negative. Results of molecular detection of FP suspected field samples 32 (80%) were positive and 8 (20%) were negative. On the contrary, out of 40 PP suspected samples 35 (87.5%) were positive and 5 (12.5%) were negative by PCR. Rate of molecular detection of avi-pox viruses from recent outbreak found higher than that of virus isolation in avian embryos.

Masola *et al.* (2015) demonstrated gross examination of CAMs and chicken embryos and revealed haemorrhage, thickening and development of pock lesions on CAMs of ECEs inoculated with PGPV REV-free FWPV and REV-integrated FWPV strains. Embryos of ECEs inoculated with PGPV, REV-free FWPV and REV-integrated FWPV strains were haemorrhagic. No clinical signs were observed in chickens in control and those which were inoculated with PGPV.

2.3.1 Aspergilosis

Ramirez *et al.* (1976) isolated fourteen species of fungus from the lower digestive tract of 69 of 80 pigeons in the El Paso Texas Erea USA. Sixteen pigeons had concurrent isolations while two harbored three species. Fungi isolated were *Allescheria boydii, Aspergillus* spp., *Candida krusei, Chrysosporium* spp., *Geotrichum candidum, Mucor* Spp., *Paeciliomyces* spp., *Penicilhum* spp., *Rhizopus*

spp., *Rhodotorula* Spp., *Scopulariopsis* Spp., *Streptomyces* spp., and *Trichosporon cutaneuın.*. A total of 14 fungal species were isolated. Fifty-one of the 80 feral pigeons examined were positive for at least one fungus. Two different fungi were isolated from 16 pigeons and three or more fungi were isolated from only two pigeons.

Tokarzewski *et al.* (2007) reported an aspergillosis outbreak in a flock of near 350 pigeons and conducted examination of moribund pigeons, their bedding, and fodder for mycological diagnostics. The affected pigeons showed dyspnoea, depression, rattling, and dyskinesia, and numerous cases of death were noted. The mycological examinations demonstrated the presence of *Aspergillus fumigatus* in swabs from the beak cavity of living birds, and in the lungs and air sacks during post mortem. The presence of *Candida albicans* and single isolates of *Penicillium* sp. and *Scopulariopsis* sp. were also detected in the beak cavity. The dominant presence of *A. fumigatus* and some colonies of *Mucor* sp., *Acremonium* sp., and *Trichoderma* sp. were recorded. Histopathological analysis of the affected organs displayed multifocal areas of necrosis, inflammatory infiltration, and the presence of fungal hyphae, giant cells, and fibrous tissue proliferation at the periphery of the nodules were noted.

Beernaert *et al.* (2010) conducted a study of in-vivo modelling of aspergillosis in birds and host pathogen interactions to study the impact of the use of different inoculation routes and immunosuppressant on the course of an infection with aspergillus fumigatus in racing pigeons (Columba livia domestica). A. fumigatus conidia were inoculated in the thoracic air sac, lung or trachea in immunocompetent or immunosuppressed pigeon squabs. Pigeons inoculated in the lung or inoculated intratracheally after immunosuppressant developed an aspergillosis with a slower course of disease and more prominent clinical symptoms.

2.3.2 Mycotoxin

Hadley *et al.* (2010) conducted study on Aflatoxin B1 to establish an acute model for hepatotoxicosis and decreased hepatic function in the white Carneaux pigeon (Columbia livia) via oral administration of Aflatoxin B_1 dissolved in dimethyl sulfoxide at a dose of 3 mg/kg to 3 group pigeons after every 24 hour for 2, 4 and 6 consecutive days respectively. Significant Histopathologic lesions were observed in

hepatic tissue from each group after aflatoxin exposure (P<.05) and increased liver enzyme activity in hepatocellular tissue was also reported.

Antonissen *et al.* (2016) conducted a study on Seed-based pigeon diets and revealed exposure of pigeons to mycotoxins such as deoxynivalenol (DON). Ingestion of low to moderate contamination levels of DON may impair intestinal health, immune function and/or pathogen fitness, resulting in altered host-pathogen interactions and thus different outcome of infections. DON was one of the most frequently detected mycotoxins in seed-based racing pigeons feed, contaminating 5 out of 10 samples (range 177±1,466 μg/kg). Feeding pigeons a DON contaminated diet resulted in an increased percentage of pigeons shedding *Salmonella* compared to birds fed control diet, 87 ± 17% versus 74 ± 13%, respectively. The increasing number of pigeons shedding *Salmonella* suggested that DON can promote the spread of the bacterium within pigeon populations.

2.4. BACTERIAL DISEASE

Kimpe *et al* (2002) isolated thirty-three *Streptococcus gallolyticus*, 60 *Escherichia coli* and 18 *Salmonella enterica* serotype from pigeons (*Columba livia*). They observed antimicrobial susceptibility in pigeons and found. Aminoglycosides (gentamicin and kanamycin), trimethoprim and flumequine relatively inactive against the streptococci tested. Acquired tetracycline resistance amounted to 85%, and lincomycin and macrolide (erythromycin) resistance to 48% and 45%, respectively. Fluoroquinolone (enrofloxacin) resistance was found in four *S. gallolyticus* strains. All strains were susceptible to ampicillin with E. *coli* strains were resistant to all antibiotics tested.

Tanaka *et al.* (2005) reported bacterial contaminations in fecal samples from feral pigeons in 7 prefectures. They isolated *Salmonella typhimurium* and *S. cerro* from 17 (3.9%) of 436 samples, as well as *Mycobacterium* spp. including *M. avium-intracellulare* complex from 29 (19.0%) of 153 samples. The polymerase chain reaction detected *Chlamydia psittaci* and *C. pecorum* in 106 (22.9%) of 463 samples, but *E. coli* O-157 was not isolated from any of the samples.

Pedersen *et al.* (2006) conducted an experimental study to determine the prevalence of shiga toxin– producing Escherichia coli (STEC) and *S. enterica* in

pigeons. They estimated the prevalence of STEC and *S. enterica* by bacteriologic culture of cloacal swabs collected from pigeons trapped at urban and dairy locations in and around Fort Collins, Colorado. Presumptive E. *coli* isolates were tested for the presence of virulence genes SLT-1, SLT-2, eae, hlyA, K1, CNF-1, CNF-2, and LT using polymerase chain reaction. They suggested that pigeons may acquire S. enteric from cattle and play a role in recirculation and persistence of the microorganism at dairies.

Pasmans *et al.* (2007) observed paratyphoid infection as a main bacterial disease in pigeons caused by *Salmonella enterica* subsp. *enterica* serovar Typhimurium. They suggested that the persisting ability of *Salmonella* serovar Typhimurium intracellularly inside pigeon macrophages to development of chronic carriers is responsible for the maintainance the infection in the flock

Dutta *et al.* (2013) suggested that antimicrobial-resistant pathogenic *E.coli* is present in pigeons around greater Guwahati. Out of 150 pigeons subjected to microbiological investigation, they found 91(60.67 %) samples were positive for E. coli. The most frequently occurring serotypes were O157 (9.89%), followed by O68, O121 (7.69%), O9, O75, O131 (5.49%), O2, O13, O22 (3.30%). Antibiogram investigation of the isolates revealed that 91 isolates (100%) exhibited resistance against Ampicillin followed by Nitro-furantoin (73.62%), Tetracycline (65.93 %), Oxytetracycline (62.63 %) and Streptomycin (61.54). Gross changes of some pigeons showed fibrinous pericarditis and perihepatitis and coligranuloma in different organs like liver and serosal surface of intestine. Microscopically, they observed severe congestion and haemorrhages in different organs such as liver, kidney, lung and intestine. In some cases thick layer of fibrinous exudates with large number of heterophills over the surface of liver and heart with early degenerative changes as well as focal necrosis.

Murakami *et al.* (2014) collected 549 samples of pigeon droppings from 14 locations in Kyushu, Japan, to isolate Shiga toxin 2f-producing Escherichia coli (STEC2f) and to investigate characteristics of the isolates. They detected shiga toxin stx2f gene fragments by PCR in 16 (2.9%) of the 549 dropping samples across four of the 14 locations. They also obtained 23 STEC2f-isolates from seven of the original samples and from three pigeon dropping.

2.5 PARASITIC DISEASES

2.5.1. Haemoproteosis

Dey *et al.* (2010) studied the prevalence and pathological changes of blood protozoa by random selection of seventy five pigeons from different areas of Mymensingh district of Bangladesh. About 33 (44%) pigeon were found to be infected with blood protozoa. Two types of protozoa were identified such as *Haemoproteus* sp. (20%) and *Leucocytozoon* sp. (24%). Prevalence of blood protozoa in male birds was higher (28%) than female birds (16%). The calculated odd ratio showed that male pigeons were 2.57 times more susceptible than the female pigeon. Microscopically, degeneration and dissolution of vascular endothelial cells in the heart was seen in case of *Leucocytozoon* infection. Comma shaped organism were detected in both cases and also infiltration of inflammatory cell. Schizonts were observed in liver parenchyma.

Opara *et al.* (2012) conducted a study to determine the haematological and biochemical indices and the naturally occurring haemo and gastrointestinal microbes of 150 matured street pigeons in Owerri, Imo State, Nigeria. Out of 150 street pigeons examined for prevalence of parasites, 70 (46.70%) of them were infected with gastro-intestinal parasites of which 30 (42.93%) were males and 40 (57.1%) were females. Four gastro-intestinal parasites were identified with *Trichomonas sp*. giving the highest prevalence rate (42%), followed by *Eimeria sp.* (28%), and whereas *Coccidia sp*. and *Ascaridia sp*. returned the least with each having the prevalence rate of (14%). Haemo -parasitological examination of thin blood smears revealed haematozoa of two genera: *Haemoproteus sp.* with prevalence rate of 40 (66%) for the male and 70 (87%) for the female pigeon's whileas *Plasmodium sp.* with prevalence of 20 (33%) and 10 (12%) in male and female pigeons respectively.

Abdul *et al.* (2014) investigated some parasites infecting pigeons and demonstrated the histopathological changes of the intestine and liver of parasitized pigeons. Ninety five pigeon were examined for blood parasites out of which twenty eight (29.47%) were found positive for blood parasites **(***Haemoproteus spp*), 63

pigeon (66.31%) were parasitized with tape worms 19(20%) belongs to *Cotugnia spp*, and 44 (46.31%) belongs to *Raillietina spp*. 37(38.94%) with nematodes (*Ascaridia spp*.) 10(10.52%) with *Trichomonas* and 7(7.36%). Histopathological study showed ulceration and sloughing of epithelial lining of intestine mucosa, distraction and degeneration of villi. Desquamation of epithelium, destruction of secretary glands, infiltration of inflammatory cells and atrophy of villi were observed. Liver showed severe necrosis, infiltration of inflammatory cells, vaculation of hepatocytes, congestion, hyperplasia of hepatocytes and some fatty changes.

Doosti *et al. (2014)* conducted the study to determine the prevalence of *Haemoproteus columbae* in Iranian pigeons by a molecular technique (PCR). A total of 220 blood samples studied and 51 (23.18%) cases were identified to be positive for *H. columbae* infection. Analysis of PCR products for the presence of *H. columbae* on 1% agarose gel revealed 207 bp fragments.

2.5.2. Ectoparasite and endoparasite

Rodriguez et al (1997) observed intestinal cryptosporidiosis in three young pigeons (Columba livia) from the Canary Islands characterized by diarrhea and body weight loss. During necropsy carcasses of all pigeons were anemic and dehydrated. The gastrointestinal tracts were diffusely reddened and dilated and contained yellowish fluid. Histologically, large numbers of cryptosporidia were present within the brush border of the intestinal mucosa lining the small intestine, cecum, colon, cloaca, and epithelium of the bursa of Fabricius. Organisms were basophilic, spherical, 4-6 µm in diameter, and present on most epithelial surfaces. Hyperplasia of the intestinal crypts and moderate inflammatory infiltration in lamina propria was also observed.

Bandyopadhyay *et al* (2006) found a new species of *Eimeria* from the faeces of the Blue Rock Pigeon (*Columba livia*) by examined 145 adult specimens of *Columba livia* from west Bengal, India. Out of which 42 (28.96%) had coccidian oocysts. Morphological comparison of oocysts revealed differences between them and those of other *Eimeria* spp. Sporulation is exogenous and fully developed oocysts are ellipsoidal, 24.3µm x 19.8µm; the shape index (length/width ratio) is 1.2. There was no micropyle or oocyst residuum, but a prominent spherical polar granule found. Sporocysts are pyriform, 12.06µm x 10.1µm; the shape index is 1.2µm. A large and

prominent stieda body was present. The sporocyst residuum is present with numerous, nearly uniform granules. Sporozoites are banana-shaped lying lengthwise head to tail inside the sporocyst.

Sari *et al.* (2008) isolated four coccidian and four helminth species from faecal samples of both domestic and wild pigeons. Infection was found quite higher in domestic pigeons (81/136) 59.6% compared to wild pigeons (35/115) 30.4%. *Eimeria labbeana* and *E. columbarum* were found to be the most common species in domestic pigeons and *E. labbeana* and *Isospora* sp. were the most common species seen in the faecal samples of wild pigeons. Eggs of *Capillaria* sp. in both domestic and wild pigeons were also observed. In the domestic pigeons, maximum infection rate was recorded in October (73.9%) and minimum rate in November (46.2%). The infection rate in autumn in domestic pigeons was found to be rather high compared to the infection rate of wild pigeons.

Borghare *et al* (2009) found helminthic infection in captive wild pigeons (*Columba livia*) at Maharajbagh Zoo Nagpur. All the 30 samples examined were found positive either with single or mixed helminthic infections. The incidence of *Capillaria sp*, *Ascaridia sp* and *Hetarakis sp*. were 56.66%, 76.66%, 16.66% respectively. Mixed parasitic infection was recorded in around 17 samples with either *Ascaridia sp.* and C*apillaria sp* or with *Ascaridia sp*. and *Heterakis sp*.

Elisabeth *et al.* (2009) observed Coccidia as common pathogenic parasites in pigeon (Columba livia) with young being more susceptible than adult birds. Infections in domestic pigeon are typically mixed and commonly include *Eimeria columbarum* and *Eimeria labbeana*. Prevalence of infection was reported between 51%-71.9% and worldwide mortality in juvenile pigeon varies from 5% to 70%, with most death occurring in the third and fourth month of life.

Abreu-Acosta *et al* (2009) demonstrated the presence of *Cryptosporidium hominis* in pigeons for the first time. Previously, *C. hominis* had been cited in another bird species, *Branta canadiensis*. They observed that pigeons may act as mechanical vectors for this protozoan. In two of the 34 pigeons analyzed (5.9%), *Cryptosporidium* sp. oocysts were detected using the staining method. Previously, *Cryptosporidium* had been found in pigeons (Borodina *et al*. 1994, Ozkul and Aydin

1994, Rodríguez *et al*. 1997). However, in none of the cases it was identify to specific level.

Bahrami *et al.* (2011) conducted a survey to determine egg per gram (EPG) parasite ovum in pigeons by collected 250 faecal samples of pigeons from mixed companion birds kept in the cages. Faecal samples were examined by direct smear method where as egg per gram (EPG) was counted by modified McMaster technique and centrifugal flotation method using Sheather's saturated sugar solution. *Raillietina* spp, *Tetramers, Sygnamus, Capillaria, Ascaridia colombae* and *oocyst protozoa, Phthiraptera, Ceratophyllus columbae* contamination were found to be 24%, 8%, 9%, 14%, 4%, 7%, 8% and 6% respectively. They compared mixed parasitic infections with chicken then pigeons were less susceptible to as to chickens. Eectoparasites including feather lice (*Phthiraptera*) and pigeon fleas (*Ceratophyllus columbae*) was also observed.

Radfar *et al.* (2011) conducted study to determine the prevalence intensity and species of internal and external parasites in pigeon in Khorasan, by collected samples from 102 pigeon (44 nestling and 58 adults). Species of nematodes and cestodes collected from elimentary canals were *Ascardia colombae* (16.66%). *Hadjelia trauncata* (1.96%), *Cotugnia dignopora* (13.79%), and examined through centrifugal flotation method using sheather's saturated sugar solution for diagnosis of *Eimeria* sp. 54 species of ectoparasite were collected from feathers *Psedolynchia canariensis* (63.725), *Columbicola columbae* (79.41%), *Menopen galline* (44.11%). Subcutaneous nodules: *Laminosioptes cysticola* (1.96%).

Al-Barwari *et al* (2012) reported the prevalence and intensity of various parasitic infections from pigeons in Iraq. Twenty-seven species of parasites were identified comprising 1 Fungi, *Candida* sp.; 2 Protozoa, *Eimeria labbeana*, *Trichomonas gallinae*, *Haemoproteus columbae* and *Plasmodium* sp.; 3 Cestoda, 4 of each of the genera *Cotugnia* and *Raillietina*; 4 Nematoda, *Ascaridia columbae*, *A. galli*, *Capillaria obsignata* and *Synhimantus spiralis*; and 5. Arthropoda, the commonest of which were the wing and tail feather louse *Columbi cola* sp. and the pigeon louse fly *Pseudolinchia canariensis*.

Bahrami *et al.* (2012) conducted a study to determine the pathological effect of parasitism in racing pigeons with an indication of its effects on community health.

A total of 250 blood and faecal samples were randomly collected from suspected pigeons (mostly young) and 25 specific free pathogen birds were kept as control. Tissue samples of both infected and control birds were collected for histopathological examination. The data indicate prevalence rate of various helminthes including *Raillietina achinobothridia* (10.4%), *Syngamus trachea* (8.4%), *Capillaria colombae* (6%) and *Ascaridia colombae* (8.4%). The results reveal some porotozan infections including *Haemoproteus colombae* (20.8%), *Trichomonas gallinae* (26.8%) *Cryptosporidium* sp. (1.2%) and *Eimeria* sp. (21.6%*)* and also ectoparasites including *Lipeurus* sp. (3.2%), *Menopen gallinae* (15.2%), *Ceratophyllus colombae* (10.4%) and *Louse fly* (12%). Multiple infections observed with internal parasites were 19/4%. However, co-infection of internal and external parasites was 24.4%.

Dandapat *et al.* (2012) surveyed about 8,000 pigeons from urban and 2,000 birds from semi-urban area to find the prevalence of different diseases in pigeons around Kolkata. Star gazing, diarrhea and pox were the major infections observed. Examination of about 5,000 fecal specimens showed protozon parasites (coccidian oocysts) and helminthic infection (*Capillaria* and *Ascaridia* sp.).

Elaph *et al.* (2012) recorded the prevalence of pigeon coccidiosis in Baghdad city. Out of 40 birds 14 (35%) were infected with *Eimeria* spp. Insignificant effects on the body weight gain was recorded between the infected birds (234.78 ± 6.32g) and non infected once (258.461 ± 9.2g).

Jamriska *et al (*2012) observed new species of eimerid coccidia from the Common Wood Pigeon (*Columba palumbus).* Sporulated oocysts of *Eimeria Columba palumbi sp*. were ellipsoidal 24–17 × 18–15 μm and two irregularly shaped polar granules present in the oocyst. Thirty six out of 96 (37.5%) Common Wood Pigeons were positive and shed unsporulated coccidian oocysts, which appeared to represent a single species of *Eimeria*. Intracytoplasmic endogenous stages were found developing within the epithelial cells of jejunum, and the macrogamonts were observed.

Nayyef (2012) conducted histopathological study in Pigeons infected with *Raillietina spp* in Baghdad. About 47 pigeons (*Columbidae* family) and two hunted species of pigeon were collected from different areas (group A, B). Histopathalogical changes observed in group A revealed an increase in number of goblet cells,

enlargement of columnar epithelial cell and villi in the intestine, while in kidney and liver, no significant changes were observed. In group B hydropic degenerations in the liver tissue in addition to mononuclear cell infiltration in the portal region with scattered necrosis of the hepatocytes and congestion in some cases was appreciated. In kidneys there were sloughing in the epithelial cells of proximal convoluted tubules, dilatation of glomeruli and dilated distal convoluted tubules, while in the intestine, there was infiltration of mononuclear cells and increase in the number of goblet cells

Bahrami *et al.* (2013) revealed that para-clinical tests and gross lesions play important roles in identifying parasitic disease as all organs of pigeon such as skin, eyes, kidneys, liver and digestive tube can be affected by the parasites. Faecal samples were examined by direct smear method whereas egg per gram (EPG) was counted by modified McMaster technique and centrifugal flotation method using Sheather's saturated sugar solution. In their study, *Raillietinaspp*, *Tetramers*, Sygnamus, Capillaria, *Ascaridiacolombae* and oocyst protozoa, *Phthiraptera*, *Ceratophylluscolumbae* contamination were found to be 48(24.24%),16 (8.08%), 18(9.09%),28 (14.14%),8 (4.04%), 14(7.07%), 16(8.08%) and 12(6.06%) respectively and 38(19.19%) of pigeon had multiple infection. They observed the birds above two years 83 (41.91%) showed more resistance against worm' infestation than young birds below two years115 (58.08%). The PCV, WBC, MCV, MCH, Neutrophil and lymphocytes' values of the infected pigeons were significantly ($p<0.05$) different from the non infected pigeons. Histopathological changes including degenerative changes in the epithelial tissues of the intestine were observed in pigeons below 2 years old in comparison with above 2 years old birds.

Abed *et al.* (2014) conducted a study to investigate the histopathological changes in intestine and liver from parasitized pigeons. They examined 95 pigeon for blood parasites and GIT parasites respectively, 28/95(29.47%) with blood parasites **(***Haemoproteus spp*), 63/95 (66.31%) were parasitized with tape worms 19/95 (20%) and 44/95 (46.31%) belongs to *Raillietina spp*., 37/95(38.94%) with nematodes (*Ascaridia spp*.), 10/95(10.52%) with *Trichomonas* and 7/95(7.36%) were observed. Histopathological examination revealed that ulceration and sloughing of epithelial lining of intestinal mucosa, distraction and degeneration of villi, destruction of secretary glands, infiltration of inflammatory cells and atrophy of villi. Liver of

pigeon showed severe necrosis and infiltration of inflammatory cells with vacoulation, congestion, hyperplasia of hepatocytes.

Ghosh *et al.* (2014) conducted a study on 100 pigeons to assess the prevalence of ecto and gastrointestinal parasitic infections in domestic pigeons (*Columba livia*) in Chittagong Bangladesh. The investigation revealed the overall prevalence of ecto–parasitic infestation was 67%. Among 6 different ecto–parasites, the highest infestation was caused by *Pseudolynchia canariensis* (43%). pediculosis was found common problem in the study population where *Lipeurus caponis* (28%) *and Goniodes gallinae* (28%) occurred more frequently as compared to *Menopon gallinae* which constituted the lowest 13%. Further, adult pigeons (86%) were more prone to ecto–parasitic infections in compare to squabs (48%), Among GI parasites, occurrence of *Ascaridia galli* (32%) and *Capillaria* sp infections (26%) were more common in adult pigeon where as *Raillietina* sp (0%) and *Syngamus trachea* infections (2%) were less frequent in squabs.

Koompapong *et al.* (2014) conducted molecular identification of Cryptosporidium spp. from animal samples around the country by collecting and investigating the faeces of seagulls (*Chroicocephalus brunnicephalus* and *Chroicocephalus ridibundus*), domestic pigeons (*Columba livia domestica*). Seagull and pigeon samples were collected at the seaside and on the riverside to evaluate their potential for waterborne transmission. Ten pigeon samples were combined into one set, and a total of seven sets were collected. Seventy seagull samples were combined into one set, and a total of 13 sets were collected. *C. meleagridis* was found *in* pigeons.

Parsani *et al.* (2014) conducted a study to assess the prevalence of helmith parasites of domestic, wild and zoo pigeons in Gujarat, India. Qualitative examination of 78 faecal samples revealed 71 (91%) with parasitic infections of nematodes (85%), cestodes (31%) and *Eimeria* sp (77%). During post-mortem examination, 85% had parasitic infections of nematodes (75%), cestodes (69%) and *Eimeria* sp (58%). Two species of nematodes (*Ascaridia columbae* and *Capillaria obsignata*) and five species of three genera of cestodes (*Raillietina echinobothridia, R. tetragona, R. cesticillus, Cotugnia digonophora* and *Hymenolepis* sp) were identified.

Ramisz *et al.* (2014) identified Coccidiosis as a common parasitic disease in pigeons caused by *Eimeria* sp. A total number of 330 faecal samples were investigated with Willis- Schlaaf's (qualitative) and McMaster's (quantitative). Three species of protozoa were isolated: *Eimeria labbeana*, *E. columbarum*, *E. columbae*, and the infections were mixed. The occurrence of *E. labbeana* was most commonly reported with 89–93% in young pigeons and 63–55% in adults. The species *E. columbarum* and *E. columbae* were found less frequently.

Sivajothi *et al.* (2015) observed the prevalence of gastrointestinal parasitic infections in domestic pigeons (*Columba livia*) in Andhra Pradesh India by examined 132 pigeons from four different farms. Faecal samples were collected from individual birds and processed by gross examination, direct smear examination, flotation and sedimentation techniques. Overall 72.7 % of the birds harboured parasites including *Ascaridia colombae* (33.3%), *Eimeria spp* (31.0%), *Capillaria colombae* (17.4%) and *Raillietina* (9.0%). Most of the pigeons were infected by mixed parasitic infections (36.6%). A relation between the occurrences of gastrointestinal parasitic infections with the age of the pigeons showed that high prevalence in adults (75%) as compare to squabs (64.2%). *Eimeria spp*. was found to be higher in squabs than compare with adults.

Nisar *et al.* (2015) observed histopathological changes in intestines of *Columba liviaw* artificially infected with *C. digonopora* and *C. cuneata* in Pakistan. In *C. digonopora* infested pigeon infiltration of inflammatory cells in lamina propia were noticed and some portion of worm were seen in muscular layer. Serosa was necrotic. In *C.cuneata* infested pigeon, migratory tunnels formed along with fibrosis, necrosis and villous atrophy. Parasites were infiltrated the muscular layer. Sometime portion of parasites remained in muscular layer.

2.6 HAEMATOLOGICAL CHANGES

Al-Bayati (2011) conducted study to identify different cestodes (*Aporina delafondi* , *Cotugnia intermedia* and *Raillientina microcantha)* infecting pigeons from various regions in Diyala province by Parasitological examination of feces and guts and revealed that the infected birds had significant decrease in P.C.V. (20.93%), TEC (2.28 c*10/mm) and HB concentration (5.88 gm/100ml) in birds especially in severe (heavily) infections with

cestodes. Non significant increase in total white blood cells (leucocytosis) specifically eosinophils (22.03 c*10/mm) in infected pigeons was also observed.

Opara *et al*. (2012) conducted study to determine the haematological and biochemical indices and the naturally occurring haemo and gastrointestinal microbes of 150 matured street pigeons in owerri, imo state Nigeria. The PCV, WBC, MCV values of male and female pigeon were significantly ($p<0.05$) different from the male counterpart.

MATERIALS AND METHODS

The research work was carried out at R.S. Pura, Jammu in the Division of Veterinary Pathology, Faculty of Veterinary Sciences and Animal Husbandry (FVSc & AH) of Sher-e-Kashmir University of Agricultural Sciences and Technology of Jammu during the year 2015-2016.

3.1 STUDY AREA

The study was conducted in and around Jammu. A total of twelve areas were surveyed where the pigeon population was particularly abundant.

S. No.	Area/village	Location
1.	Ranbir Singh Pura town area	RS Pura, Jammu
2.	Dyanghrah	RS Pura, Jammu
3.	Banota	RS Pura, Jammu
4.	Gagian	RS Pura, Jammu
5.	SuchetGarh	RS Pura, Jammu
6.	Khadapur	RS Pura, Jammu
7.	Tonkaliala	RS Pura, Jammu
8.	KapurPur	RS Pura, Jammu
9.	Biaspur	RS Pura, Jammu
10.	Rangpur	RS Pura, Jammu
11.	Peer Meetha	Jammu city
12.	Panjtirthi	Jammu city

3.2 CLINICAL EXAMINATION OF BIRDS

Pigeons amongst fanciers and breeders, local poultry market and slaughterhouses housing pigeons were visually screened for prevalent disease conditions. A clinical health assessment was made by physical examination of the birds. A general history of the flock was taken from the owners stating approximate

flock size, mortality and observed abnormal behavior or activities in the flock. Suspected birds were isolated and signs were recorded.

Faecal and blood samples were collected for laboratory analysis. Biopsy and microbiological samples were taken from the birds whenever warranted. Some pigeons were brought to Division of Veterinary Pathology for close observation of clinical signs.

3.3 PATHOLOGICAL STUDIES

3.3.1 Necropsy examination of birds

Pigeons that were incidentally found dead or submitted for necropsy examination to the Division of Veterinary Pathology, were examined thoroughly as per the routine necropsy protocol prescribed by Jones and Gleiser (1954). A detailed record of gross pathological lesions was maintained for corroboration with clinical and laboratory findings.

3.3.2 Histopathological examination

The tissue pieces from liver, kidney, intestine, pancreas, gizzard and brain were collected in 10% formal saline solution. Formalin fixed tissues were dehydrated in increasing strength of alcohol, cleared in xylene and embedded in paraffin blocks. Paraffin embedded sections were cut at 4-5 micrometer thickness and stained with hematoxylin and eosin as per standard protocol (Luna, 1968). Fungal elements in tissue sections were demonstrated with Grocott'smethenamine silver (GMS) stain (Luna, 1968).

3.4 HAEMATOLOGICAL STUDIES

Blood samples were collected in anticoagulant coated bottles containing (EDTA@1mg/ml blood) from the wing vein using 24 gauge needle for haematological and haemoprotozoal examination. Thin films of each of the blood samples were air dried and fixed in absolute methanol. They were then stained with Giemsa’s stain for 45 mins and examined under a light microscope.

Haematological parameters included Total Erythrocyte Count (TEC) and Total Leucocyte Count (TLC) were determined according to the method of Natt and Herrick

(1952) using poultry blood diluting fluid; Packed Cell Volume (PCV); Hemoglobin (Hb) estimated as per Jain (1986);Differential Leukocyte Count (DLC) as described by Lucas and Jamroz (1961).

Haemoprotozoa were identified according to Valkiunas (2005).

Serum was separated from whole blood collected from clinically ill birds and kept at -20°C for serological studies.

3.5 SEROLOGICAL STUDIES

Haemagglutination (HA) and Haemagglutination Inhibition (HI) assayswere done according to OIE (2012) for detection of Newcastle disease virus titre in suspected birds. The test was done on V-bottomed microwell plastic plates (V Bottom Micro test plate, TARSONS, India). Unvaccinated and virtually NCD-free chicken RBC were collected and washed three times in isotonic PBS (0.01 M; pH 7.0–7.2) before use as a 1% (packed cell v/v) suspension in an equal volume of Alsever's solution. Positive and negative control antigens and antisera were run with each test, as appropriate. Commercial Live Newcastle disease vaccine (LaSota strain) was used as positive control antigen (VentriBiologicals, India). High titred positive serum was kindly supplied by Dr. P. Roychodhury, Central Agricultural University, Aizawl, Mizoram, India.

3.5.1 HaemagglutinationAssay

i) 0.025 ml of PBS is dispensed into each well of a plastic V-bottomed microtitre plate.

ii) 0.025 ml of the tissue suspension (virus) or vaccine virus was placed in the first well.

iii) Two-fold dilutions of 0.025 ml volumes of the virus suspension are made across the plate.

iv) A further 0.025 ml of PBS is dispensed to each well.

v) 0.025 ml of 1% (v/v) chicken RBCs is dispensed to each well.

vi) The solution is mixed by tapping the plate gently. The RBCs are allowed to settle for about 60 minutes at 4°C till control RBCs settle to a distinct button.

vii) HA was determined by tilting the plate and observing the presence or absence of tear-shaped streaming of the RBCs. The titration was read to the highest dilution giving complete HA (no streaming); this represents 1 HA unit (HAU) calculated from the initial range of dilutions.

3.5.2 Haemagglutination inhibition Assay

i) 0.025 ml of PBS is dispensed into each well of a plastic V-bottomed microtitre plate.

ii) 0.025 ml of test serum is placed into the first well of the plate.

iii) Two-fold dilutions of 0.025 ml volumes of the serum are made across the plate.

iv) 4 HAU virus/antigen in 0.025 ml were added to each well and the plate was left for 60 minutes at 4°C.

v) 0.025 ml of 1% (v/v) chicken RBCs was added to each well and, after gentle mixing, the RBCs are allowed to settle for about 60 minutes at 4°C, when control RBCs settle to a distinct button.

vi) The HI titer is the highest dilution of serum causing complete inhibition of 4 HAU of antigen. The agglutination was assessed by tilting the plates. Only those wells in which the RBCs stream at the same rate as the control wells (containing 0.025 ml RBCs and 0.05 ml PBS only) were considered to show inhibition.

vii) The validity of results was assessed against a negative control serum with titre<1/4, and a positive control serum.

3.6 MICROBIOLOGICAL STUDIES

3.6.1 Isolation and identification of bacteria

Samples were collected aseptically with the help of sterile cotton swabs from the liver and heart blood and placed in sterile container, taking all precautions to

avoid contamination. Impression smears from visceral organs were stained with Grams stain for demonstration and identification of bacteria. The procedure for isolation and identification of coliform bacterial culture was followed as per the standard protocols (Quinn *et al.,* 1993).

For confirming *Escherichia coli* organisms, swabs from heart blood and liver were streaked on MacConkey agar and incubated at 37°C for 24 hours. The pink lactose fermenting colonies were further streaked on to Eosin Methylene Blue (EMB) agar and incubated at 37°C for 24 hours. Isolates showing characteristic metallic sheen were confirmed by Gram's staining, catalase and oxidase test.

For isolation of *Salmonella* organisms, sterile swab from liver was inoculated on MLA agar. It was further grown on selective Salmonella Shigella Agar (HiMedia, M1032, India) and confirmed by biochemical tests- Indole, Methylene blue, VogesProskeur and Citrate utilization tests using biochemical kit (HiMedia, KB001 HiIMViC^{TM} Biochemical Kit, India). Morphological characteristics of bacteria were studied with Grams stain (Cruickshank *et al*., 1975).

3.6.2 Isolation and identification of fungi

Tracheal and lung swabs were collected at necropsy from pigeons suspected to have died from fungal infections. Swabs were cultured on Potato dextrose agar (PDA) (HiMedia, M096, India) and also on Aspergillus differential agar (ADA) (HiMedia, M1127, India) at room temperature for 5-7 days. Identification of fungi was done with smears prepared with lactophenol cotton blue stain (Cruickshank *et al*., 1975).

Isolation of fungus was also done from moldy feed grains on the same media.

3.6.2.1 Fluorescent screening of fungal culture isolates for aflatoxin production

Aflatoxin-producing molds were identified as gray or black colonies under UV photography, when culture plates were irradiated with long-wave UV light (365 nm) from a UV lamp as described by Yabe *et al*. (1987).

3.6.3 Isolation of pigeon pox virus and inoculation in embryonated chicken egg via CAM route

Pigeon pox virus (PPV) isolates were obtained from clinical cases of naturally infected pigeons showing characteristic pox lesions. The isolation of PPV from clinical specimens was done in embryonated egg via CAM route as described in OIE (2010). Tissue homogenate from skin lesion was filtered through 0.45 µm PVDF membrane (Millex HV, Millipore) and approximately 0.1 ml was inoculated on to the chorioallantoic membranes (CAMs) of 9–12-day-old developing chicken embryos and incubated at 37°C. Eggs were periodically candled. After 5 days of inoculation eggs were opened and examined for focal white pock lesions or generalised thickening of the CAMs.

3.7 PARASITOLOGICAL STUDIES

3.7.1 Collection and preservation of ectoparasites

Body coats of pigeon were examined for the presence of ectoparasites from both live and dead birds. Pigeon houses were also screened for the presence of ectoparasites and were identified by using standard protocols (Soulsby, 1982).Likewise, skin scrapping preparations were made from birds with dermal lesions (Soulsby, 1982).

Each bird was carefully examined. The wings were fully stretched and examined, and all over the body, the feathers were separated so as to expose the skin. The ectoparasites were collected and preserved in 70% alcohol for subsequent processing and examination at the laboratory.

3.7.2 Collection of gastrointestinal parasites

Gastrointestinal parasites were accessed at necropsy. After opening the birds the gastrointestinal tract was placed in a clean dissecting tray and intestine was made free from the mesentery using a pair of scissors. Before cutting each portion was tied with twine on either ends to prevent the mixing of contents with those of other parts. Different segments of the gastrointestinal tract viz. oesophagus, gizzard, duodenum, small intestine and large intestine were cut and placed in separate dissecting trays and again cut into manageable lengths. Each segment was opened with the help of scissors

and washed with running tap water in a small dissecting tray. The washed intestinal tract was scraped gently to remove any worm embedded in the intestinal mucosa. Then each part of intestine was scraped and the contents were collected in the same tray. Then the contents were mixed with water and the suspension was decanted number of times till the clear sediment was visible. The parasites visible to the naked eye were picked up with help of a clean hair brush and placed in a petridish containing normal saline solution. The keratinized layer of the gizzard was peeled off in order to look for the possible nematodes embedded in the muscular layer. Helminths from each segment of the gastrointestinal tract were collected in separate petridishes, fixed (10 per cent formalin), preserved and identified. Nematodes collected from the gastrointestinal tract were put in glycerine alcohol (10 parts glycerol: 90 parts alcohol) for clearing; cestodes were pressed gently between the two glass slides and fixed in 10% formalin and stained with aqueous borax carmine and mounted for identification as described by Soulsby (1982).

3.7.3 Collection of faecal samples

A total of six pigeon coops/ lofts were selected from different localities and faecal samples were pooled and examined during each of the four seasons for prevalence of different helminthic parasites. A total of 24 pooled faecal samples were thus examined from July 2015 to June 2016 during the four seasons (http://www.fallingrain.com/world/IN/12/Jammu.html)*viz*. monsoon (July 2015-September 2015), post-monsoon (October 2015 to November 2015), winter (December 2015 to February 2016), and summer/pre-monsoon (March 2016 to June 2016). The load of infection for different parasites was self-designated arbitrarily from none (0) to very severe (4) depending on the presence of parasitic eggs per low-power (10x) field of observation.

Designation	**Eggs per field (10x)**	**Designation**
None	0	0
Low	1-2	1
Mild	3-5	2
Heavy	6-10	3
Severe	10-15	4

3.7.3.1 Examinationof faecal samples

Macroscopic examination: Samples were examined macroscopically for the presence of proglottids of cestodes and/or immature and adult nematodes.

Microscopic examination: It was carried out by direct smear method, floatation and sedimentation methods (Soulsby, 1982).

(a) Direct smear method: A small quantity of faeces was placed on a glass slide, mixed with a drop of water, spread out, covered with a coverslip and examined directly under the microscope (10X).

(b) Saturated salt floatation method: About 2 to 3 g of faeces was mixed with water in pestle and mortar and put in a wide mouthed short bottle. Then a small amount of filtered faeces was taken in a test tube and rest of test tube was filled with saturated salt solution. After that a cover slip was placed over the tube avoiding air bubbles in between. After 25-30 minutes, the coverslip was drawn upwards gently and placed on a glass slide and examined under microscope for different gastrointestinal parasitic eggs.

(c) Sedimentation method: Approximately 2 to 3 g of faeces was mixed with water in pestle and mortar and put in a wide mouthed short bottle. Then a small amount of filtered faeces was taken in a test tube and left in test tube rack. After 25-30 minutes, the supernatant was thrown and sediment was examined under microscope for different gastrointestinal parasitic eggs.

(d) For detection of Cryptosporidian agents, direct faecal smears were stained with modified Ziehl-Neelsen stain as described in OIE (2012).

3.8 TOXICOLOGICAL ANALYSIS

3.8.1 Toxicological analysis of feeds

3.8.1.1 Chromatographic method

Feed samples suspected for presence of mycotoxins were pooled and collected. Approximately 500g of each feed sample was send to Pharmacovigilance Laboratory for Animal Feed and Food Safety (PLAFFS), Tamil Nadu University of Veterinary and Animal Sciences (TANUVAS), Chennai for mycotoxin screening

using High Performance Thin Layer chromatography (HPTLC) and estimation of mycotoxin using High Performance Liquid Chromatography (HPLC).

3.8.1.2 Fluorescence method

For rapid detection of mycotoxtoin contamination in feeds ultra violet (UV) light of 365nm wavelength was used to view both crushed and uncrushed grains. Bright greenish yellow fluorescence from the feed samples corresponded to the presence of aflatoxin as described by Hesseltine and Shotwell (1973).

3.8.2 Toxicological analysis of tissues by chromatographic method

Approximately 200g of fresh pooled tissues from kidneys, lungs and livers each were collected and sent in saturated salt solution (sodium chloride) to Pharmacovigilance Laboratory for Animal Feed and Food Safety, TANUVAS, Chennai for mycotoxinscreening using High Performance Thin Layer chromatography (HPTLC) according to Romer (1975). Estimation of mycotoxinwas done at PLAFFS using High Performance Liquid Chromatography (HPLC) as per Ramesh *et al*. (2013).

RESULTS

In the present study, a total of approximately 3980 domestic pigeons belonging to various pigeon fanciers were screened for clinical cases of disease affection. The birds were reared by their owners for the purpose of pigeon racing and sports activities. Most birds were housed on rooftops/terraces in a wire-mesh enclosed area with a run, including shelters made from wooden boxes for laying and brooding. The top of the wired enclosure were often left open for the birds to fly in or out (Fig. 4.1). A horizontal perch is often an indication of a pigeon loft and can be recognized over buildings from a distance. The pigeons were fed in captivity with cereal grains including wheat, maize, bajra, and occasionally with rice, etc. Water was provided *ad libitum*, and medicines and vitamin supplementations were also added as and when needed.

A total of twelve areas were selected for the survey, out of which ten were in the RS Pura sector and two were within the Jammu city limits. The areas near RS Pura sector were very near to the International Indo-Pakistan border (ranging approximately between 1-10 km in distance), and birds were often found to fly across each country.

4.1 CLINICALLY AFFECTED BIRDS

Out of the population of pigeons observed, a total of 608 birds were found to be clinically affected with some form of clinical disease or other, based on flock history, clinical examination and laboratory investigation. The percentage of clinically affected birds in different areas where they were reared is presented in Table 4.1. The overall estimate of disease prevalence amongst pigeons was observed at 15.28%, with the highest prevalence in Banota area and least in Ranbir Singh Pura town area.

Whenever warranted, clinical samples were collected from suspected birds showing symptoms or lesions of specific disease for pathological, microbiological or parasitological examination. The various signs and symptoms are discussed under specific disease headings. Dead birds were collected for detailed necropsy examination in the laboratory. Reported mortality by owners was not accounted for, as the data was very arbitrary and vague. Mortality was accounted only for birds that were accessed for necropsy examination.

A total of sixty pigeons were necropsied in the Division of Veterinary Pathology from July 2015-June 2016. Out of the total estimated population of birds surveyed, the overall mortality accounted through necropsy examination is 1.51% (60 of 3980 birds).

Table 4.1: Study area with number of birds reared and affected with clinical disease

S.No.	Area/village	Total birds reared (approximate)*	Clinically affected (approximate)	Per cent affected (%)
1	Ranbir Singh Pura town area	650	58	8.92
2	Dyanghrah	150	35	23.33
3	Banota	250	80	32.00
4	Gagian	270	45	16.67
5	Suchet Garh	120	30	25.00
6	Khadapur	300	40	13.33
7	Tonkaliala	90	15	16.67
8	KapurPur	80	15	18.75
9	Biaspur	170	50	29.41
10	Rangpur	700	80	11.43
11	Peer Meetha	200	40	20.00
12	Panjtirthi	1000	120	12.00
	Total	**3980**	**608**	**15.28**

** Total number of birds varied due to a semi-domesticated system of rearing*

4.2 CAUSE OF MORTALITY

The predominant cause of death as diagnosed by necropsy examination and confirmed by laboratory methods was due to protozoal hepatitis and pneumonia accounting to 45.00% mortality, followed by Newcastle disease (20.00%) and mycotoxicosis (13.33%). These three causes accounted for approximately 78.00% mortality amongst the birds. The other etiopathological causes of mortality are represented in Table 4.2.

Figure 4.1: A typical pigeon loft on the terrace near the International Indo-Pakistan border, Jammu. Note the covered area for nesting and brooding, and a wired enclosure or run with an open hath in the middle. The horizontal perch is often an indication of a pigeon loft and can be recognized over buildings from a distance. The international border is visible in the background.

Table 4.2: Cause of mortality in pigeons due to various pathological conditions and disease affection

S.No.	Pathological conditions/ disease	Number of birds affected	Per cent (%) affected
1	Haemoproteosis	27	45.00
2	Newcastle disease	12	20.00
3	Mycotoxicosis	8	13.33
4	Aspergillosis	5	8.33
5	Traumatic injury	4	6.67
6	Pigeon pox	2	3.33
7	Salmonellosis	1	1.67
8	Colibacillosis	1	1.67
Total		**60**	**100.00**

4.3 INFECTIOUS DISEASES

4.3.1 VIRAL DISEASES

4.3.1.1 Newcastle disease

Sporadic outbreaks of suspected Newcastle disease (ND) infection have been occasionally presented to Division of Veterinary Pathology. Clinical signs and symptoms observed in the flocks were predominantly neurological. They included depression, mild to severe tremors, torticollis, incoordination, unilateral or bilateral paresis with paralysis of wings or limbs (Fig. 4.3-A), head pressing, circling and terminal coma. Sick birds were unthrifty and anorexic, often emaciation and dehydrated. Some birds were often found to void greenish-watery excreta.

Necropsy examination of twelve birds variously showed petechial haemorrhages on proventricular mucosa particularly at the junction with the gizzard with ulcerations (Fig. 4.2- A,B), serosa and mucosa of the ventriculus (Fig. 4.2-C), on the crop, including catarrhal to haemorrhagic enteritis (Fig. 4.2- D), congestion and haemorrhages on the trachea and lungs, pancreas (Fig. 4.2- E), epicardium (Fig. 4.2-F), congestion of meninges and brain (Fig. 4.3- B). Ulceration was also visible on the

crop, gizzard and intestines. In a severe case of NCD affection, a large haematoma was seen in the left cerebral hemisphere (Fig. 4.3- C).

Microscopically, congestion, oedema, haemorrhage in trachea and lungs were seen. In the intestines, haemorrhagic and ulcerative lesions were seen. The sub mucosa was filled with infiltrating cells. Necrosis of lymphoid follicles in the intestine was also seen.

In the nervous system, non-suppurative encephalitis was observed in all cases affected with neuronal signs. The predominant microscopic lesion was congestion and haemorrhages in the meninges and parenchyma (Fig. 4.3 D). Most parts of the neuronal tissue were degenerated or necrosed (Fig. 4.3- E, F). Someimes, meningeal oedema was also observed (Fig. 4.3- G). There was also extensive malacia (Fig. 4.3- H) and demyelination (Fig. 4.3- I, J). In malacic lesions, there was frank destruction of neurons and the surrounding neuropil was oedematous. Demyelinating lesions seen mainly in the midbrain and brain stem were characterized by small to medium sized foci of vacuolation giving a spongy appearance. Marked multifocal perivascular cuffing with lymphocytes, plasma cells and microglia-like cells were observed. Oedema and perivascular rarefication could also be discerned. Satellitosis, microgliosis and gitter cell infiltration were also seen (Fig. 4.3- K, L).

Serum samples collected from 10 out of 12 affected pigeons were found positive by haemagglutination inhibition test (Table 4.3) by detection of high titres (1/32 to 1/64) of circulating antibodies greater than 2^4 or Log_2 4 against 4 HAU of paramyxovirus antigen.

Based on history of typical signs and post-mortem lesions, and HA and HI assay (Fig. 4.4), a diagnosis for Newcastle disease was made.

Table 4.3: Haemagglutination Inhibition (HI) test on suspected clinical samples of Newcastle Disease (NCD) in pigeons

Number of serum samples from suspected cases of NCD	HI positive (>2^4 or Log_2 4 against 4 HAU Ag)	Percent positive (%)
12	10	83.33

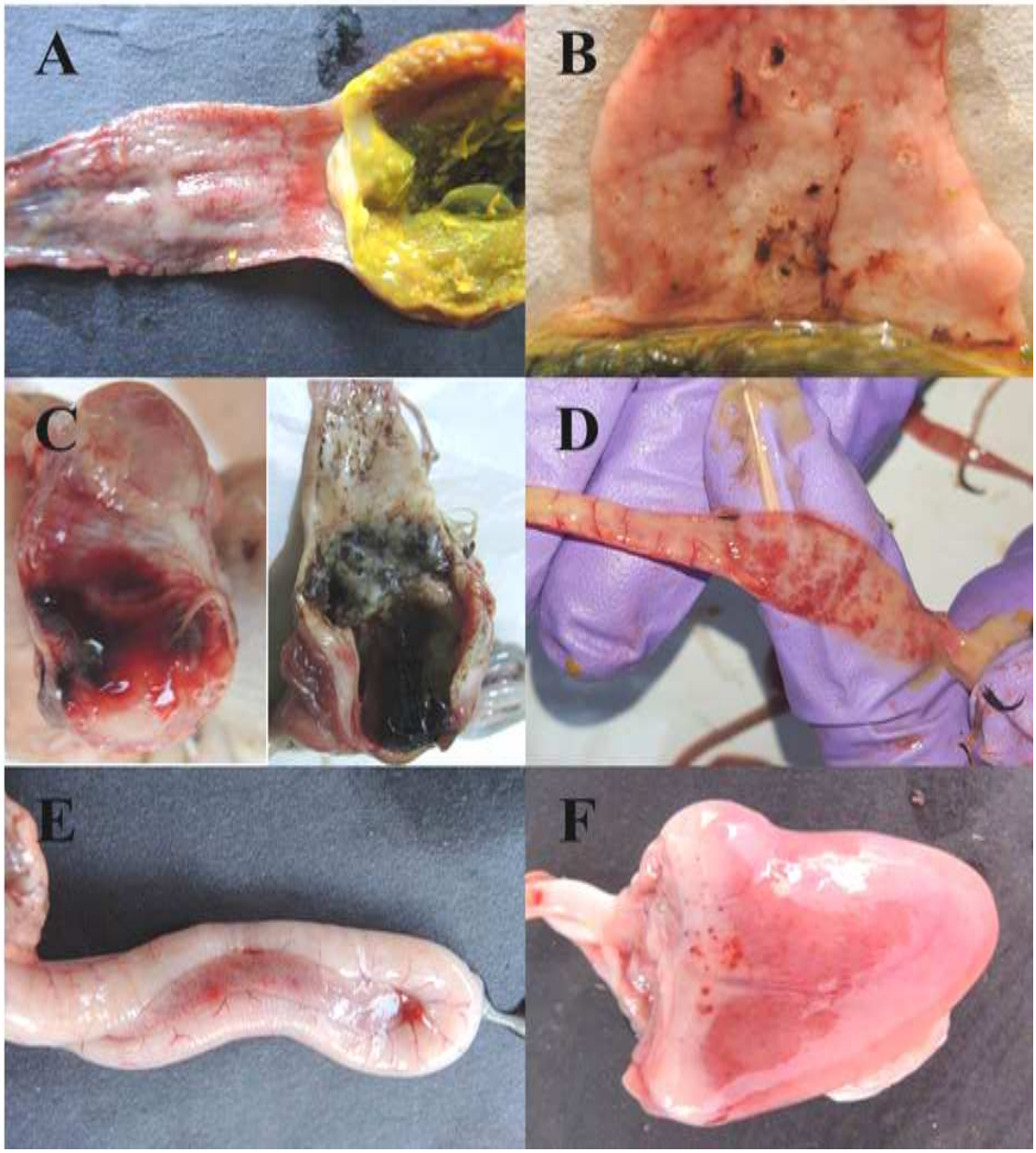

Figure 4.2: Lesions of Newcastle disease in various visceral organs of affected pigeons (*Columba livia*) (A) Mucosal congestion, catarrhal inflammation and haemorrhages in proventriculus; (B) Petechial heamorrhages and ulcers on proventriculus; (C) Petechial haemorrhages on proventriculus and massive haemorrhage in the gizzard serosa (left) and mucosa (right); (D) Petechial and paint-brush haemorrhages on small intestinal mucosa; (E) Congestion and haemorrhage on pancreas; (F) Petechial haemorrhages on epicardium.

Figure 4.3: Neural lesions of Newcastle disease in affected pigeons (*Columba livia*) (A) Neurological signs manifested include- severe torticollis, leg and wing paralysis in pigeon; (B) Congestion of blood vessels in meninges and brain; (C) Unilateral hematoma in left cerebral hemisphere; (D). Meningeal congestion and haemorrhage in brain. H&E, 10x.; (E) Diffuse lesions of neuronal degeneration in cerebrum. H&E, 10x; (F) Focal neuronal degeneration of brain. H&E, 10x.

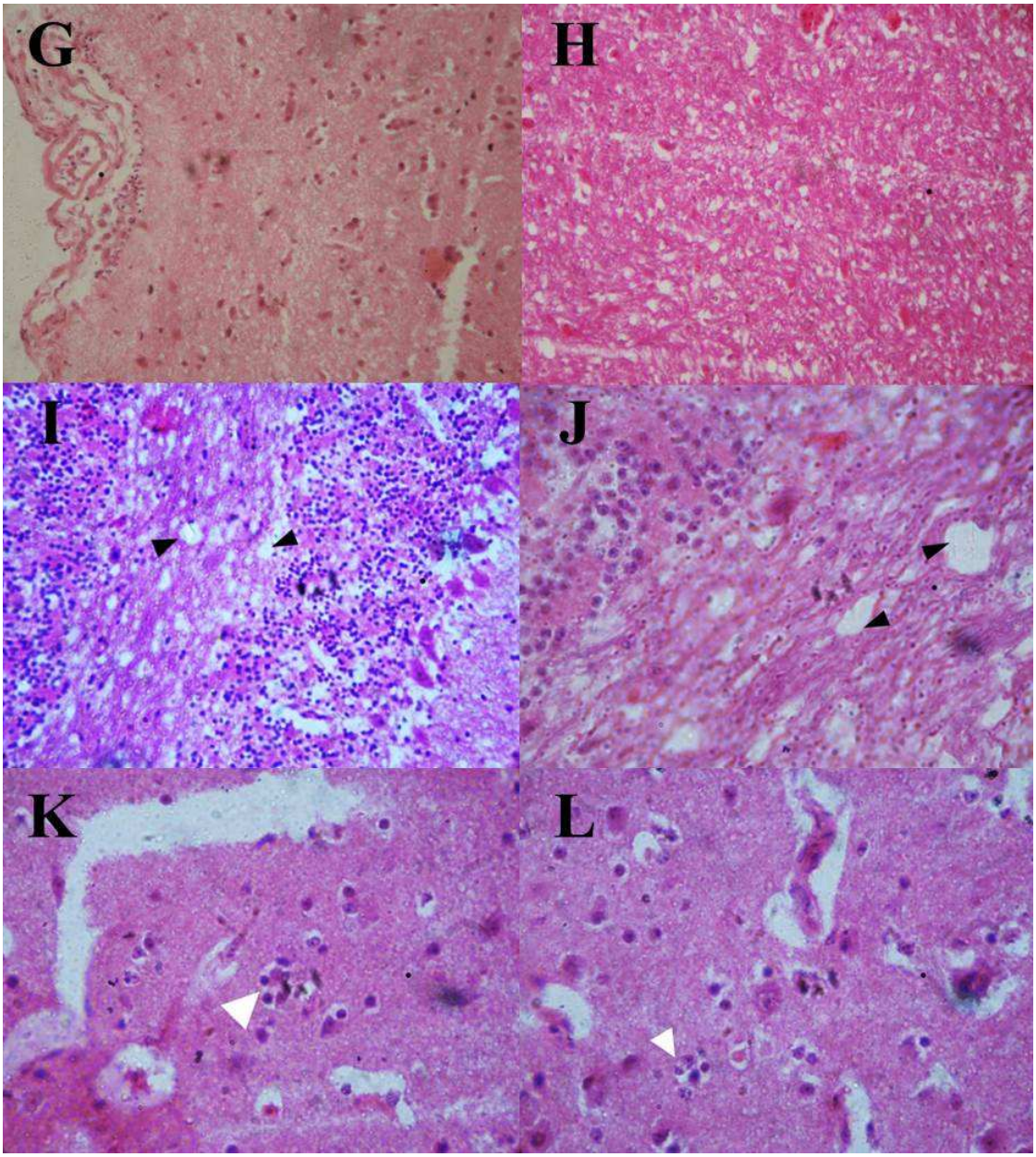

Figure 4.3.1 (Contd.): Neural lesions of Newcastle disease in affected pigeons (*Columba livia*) (G) Sub-meningeal oedema. H&E, 10x; (H) Encephalomalacia. H&E, 10x.; (I) Demyelination of cerebellar nerve tracts resembling spongiosis. H&E, 10x; (J) Demyelination of cerebellar nerve tracts in brain stem resembling vacuolation. H&E, 40x.; (K) Satellitosis and neuronophagia (arrowhead). H&E, 40x.; (L) Microgliosis (arrowhead). H&E, 40x.

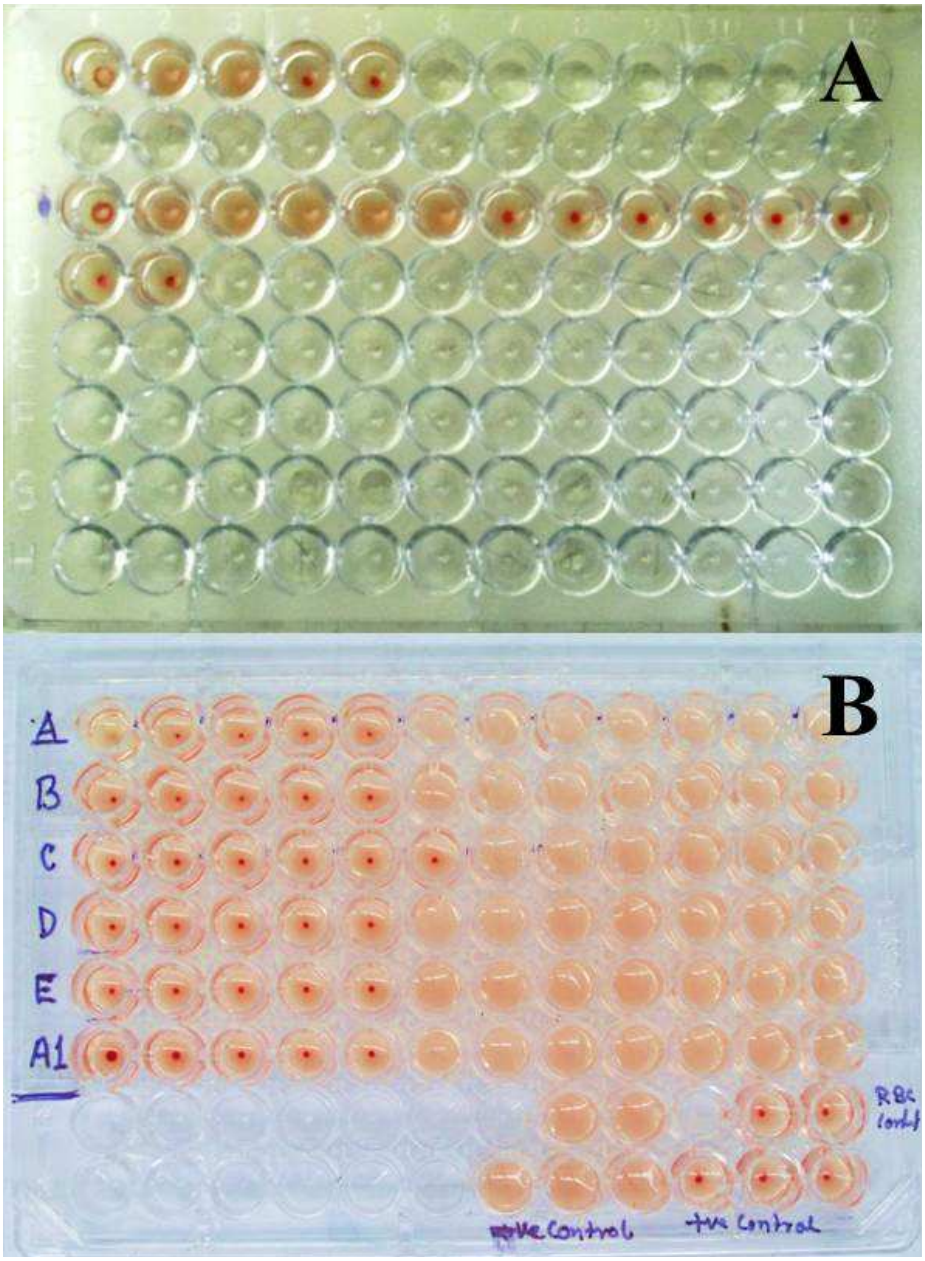
A
B
A
B
C
D
E
A1
RBC control
-ve Control
+ve Control

4.3.1.2 Pigeon pox

The affected birds were emaciated and anorectic. Easily recognizable scabby lesions were found on the unfeathered parts of the body especially the beak and eyelids in the cutaneous form of the disease amongst many pigeons. Only two mortalities amongst young birds were observed with both cutaneous and a severe diptheritic form of the disease (Fig. 4.5- A).

Grossly, on the mucous membrane of the mouth and oesophagus, a yellow, cheesy, necrotic and diphtheric membrane was observed. Peeling the membrane exposed a raw bleeding surface. In one of the squabs, cutaneous scab lesions below the eye have also been observed.

Histological changes found in the skin surrounding the cutaneous lesions consisted of varying degrees of proliferative epithelium under a crust consisting of keratin and proteinaceous fluid debris and surface bacteria was present in most lesions (Fig. 4.5- B). The typical lesion was characterized by ballooning degeneration of keratinocytes containing pale vacuolated cytoplasm (Fig. 4.5- C). Numerous keratinocytes were enlarged, rounded and, frequently, contained eosinophilic A-type intracytoplasmatic inclusions with central unstained zones distending the cytoplasm (Fig. 4.5- D). All proliferative changes were found in the epidermis, although some cells from the granular layer were ruptured, creating small vesicles. Moderate dermal oedema and congestion, with superficial infiltrates of lymphocytes, were observed. Infiltrates extended to underlying dermis, forming focal accumulation of lymphoid cells around the dermal blood vessels and connective tissue of the dermis. Histologically, lymphocytes were the predominant inflammatory cell, with scattered heterophils seen occasionally.

In the oesophagus, severe sloughing of the mucosa and covered with fibrinous debris admixed with necrotic cells and erythrocytes were observed.

Isolation of *Pigeon pox* virus attempted on 14th day developing chicken embryo revealed pock lesions on the chorioallantoic membrane (CAM) characterized by small white raised foci (Fig. 4.5- E, F).

4.3.2 BACTERIAL DISEASES

4.3.2.1 Colibacillosis

One pigeon that had died due to severe diarrhoea had gross lesions showing severe enteritis with presence of petechial haemorrhages on the intestinal mucosa, including petechiae on the pancreatic surface (Fig. 4.6- A). Air sacs were thickened and cloudy (Fig. 4.6- B). The lungs were severely congested. Fibrinous pericarditis was also seen. All visceral organs were congested. Liver was enlarged with mild fibrinous deposits on the surface.

Microscopically, liver showed degeneration with occasional dilatation of hepatic sinusoids. Fatty changes and cellular swelling with extensive engorgement and disintegration of sinusoids also observed. Focal heterophlic infiltrationwas seen in the liver parenchyma.

Severe desquamation was also observed in the intestinal mucosa and congested submucosa. The capillaries in the lungs were congested and the air spaces were filled with fluid.

Liver impression smears and microbial culture from heart blood and liver revealed typical Gram '–ve' bacilli. Based on culture, morphological characteristics and biochemical confirmation, the organisms were identified as *Escherichia coli* (Fig. 4.6- C, D).

4.3.2.2 Salmonellosis

A pigeon was presented with severe diarrhoea, weight loss, anorexia and emaciation. The bird exhibited weakness, lameness and considerable dyspnoea. After sometime, the bird succumbed with terminal shivering and exudation of serous fluid from its mouth. Necropsy examination revealed pneumonia and severe congestion of lungs, catarrhal and haemorrhagic enteritis. The air-sacs appeared cloudy and mild fibrinous pericarditis was apparent. Liver was congested with grey-white focal areas of degeneration (Fig. 4.7- A). The ovaries appeared small, misshapen and haemorrhagic and associated with catarrhal salphingitis. Degenerative foci were also visible on the kidneys.

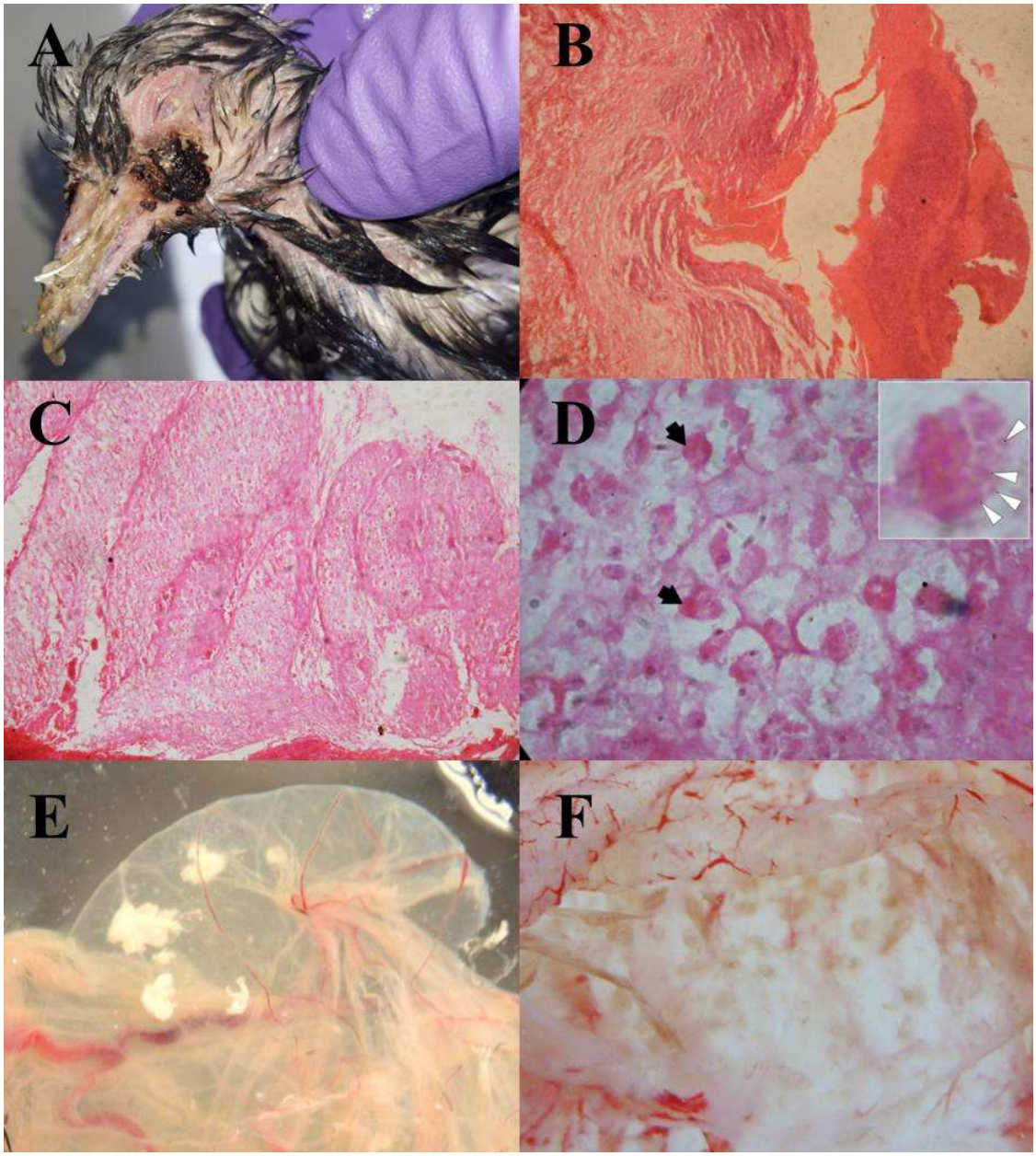

Figure 4.5: Pigeonpox lesions in affected pigeons (*Columba livia*) (A) Cutaneous and diptheritic pigeon pox; (B) Cutaneous pock lesion of pigeon pox showing vacuolated prickle cells and shedding of necrotic scab containing dead, degenerated cells and often containing bacteria. H&E, 10x; (C) Cutaneous pock lesion of pigeon pox showing vacuolated prickle cells and Intracytoplasmic eosinophilic inclusions. H&E, 10x; (D) Vacuolated prickle cells and Intracytoplasmic eosinophilic inclusions or Bollinger bodies (black arrow) containing Borell bodies (inset- white arrowhead) of pigeon pox (H&E, 40x; inset 100x); (E) Pock lesions on CAM of 19 day developing chicken embryo inoculated with pigeon pox tissue homogenate.

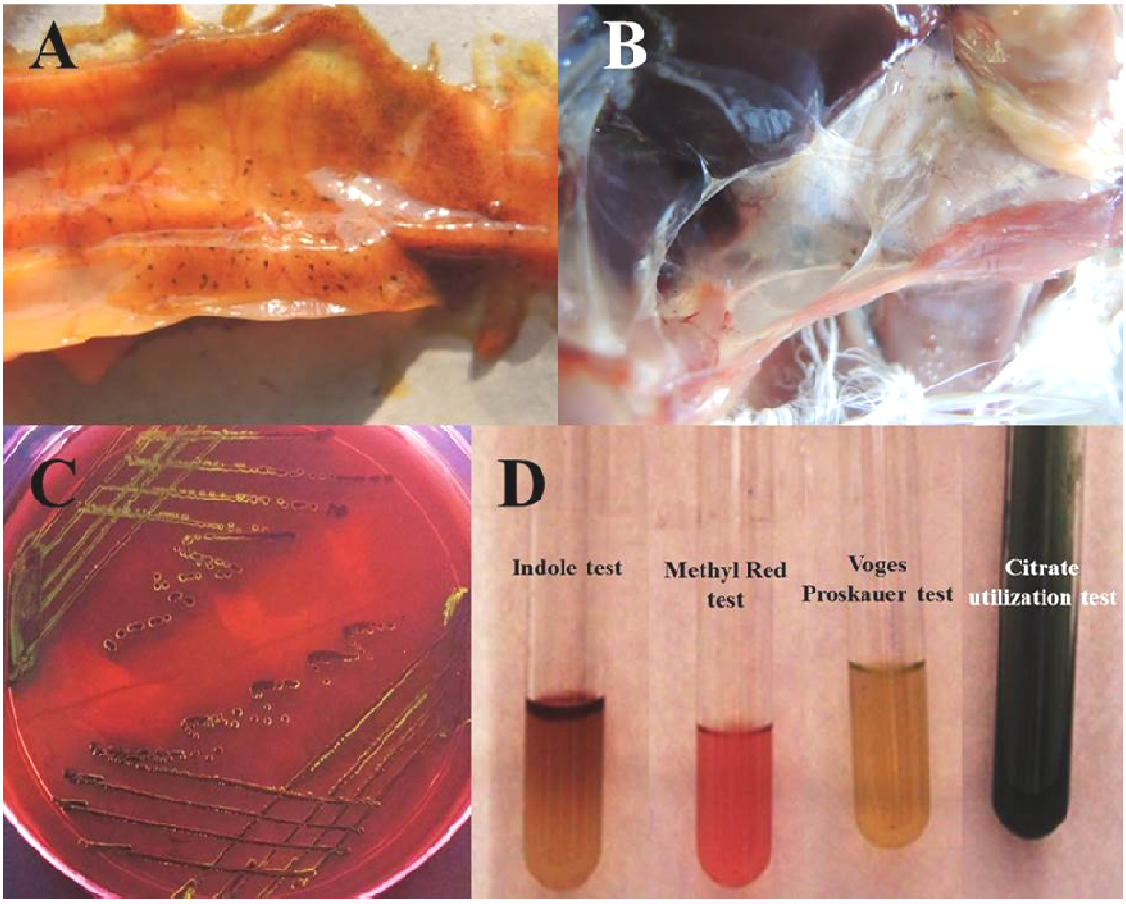

Figure 4.6: Lesions observed in pigeon (*Columba livia*) colibacillosis, culture of *Escherichia coli* and biochemical characteristics for confirmation of *E coli* (A) Petechial haemorrhages on intestine and pancreas; (B) Fibrinous air sacculitis; (C) Colonies of *E. coli* on Eosin-Mthylene Blue agar; (D) IMVIC pattern of E.Coli

Microscopically, severe congestion and haemorrhages caused disruption of hepatic parenchyma and distortion of hepatocytes and sinusoids. Focal aggregation of mononuclear cells and varying degenerative changes of the hepatocytes were observed. Congestion and haemorrhages in the serosa of intestines with degeneration and desquamation of enterocytes were also marked. Leucocytic infiltration could be observed in the submucosa.

Liver impression smears and microbial isolation from the heart blood and liver showed Gram–ve bacillus. Confirmation of the culture grown on BGA medium and XLD media with biochemical tests (Fig. 4.7- C, D) and morphological characteristics confirmed the isolates as *Salmonella* sp.

4.3.3 FUNGAL DISEASES

4.3.3.1 Aspergillosis

In an outbreak of aspergillosis affecting both young and old pigeons in one loft, clinical signs discernible were gasping and accelerated breathing, inappetance, emaciation, depression, rattling, dyskinesia and considerable mortality particularly in young birds.

Post-mortem examination revealed that aspergillosis caused both pulmonary and systemic affections. In the uncomplicated pulmonary form lungs appeared congested and oedematous. In severe cases the lungs revealed a granulomatous pneumonia with white to yellowish opaque raised plaques. Air sacs were cloudy and thickened often showing plaque-like yellowish nodules (Fig. 4.8- A). In a very severe form of pulmonary affection, sporulated forms of the fungal organism, appearing as a dark greenish-greyish growth with white tufts of mycelium were observed (Fig. 4.8- B). Considerable thickening of the membranes and adhesions to viscera and thoracic wall were also observed. Mucopurulent exudation was seen in the upper respiratory tract of one case.

In the systemic form, yellowish-white nodules were seen attached to the viscera including, the ribcage (Fig. 4.8- C), intestinal serosa and kidneys (Fig. 4.8- D).

Microscopically, a lymphohistiocytic granulomatous pneumonia was observed (Fig. 4.8- E). Granulomas had a necrotic centre containing inflammatory and cellular

debris and surrounded by epitheloid macrophages and lymphocytes, and fibrous tissue proliferation at the periphery of the nodules (Fig. 4.8- F). Non-viable septate hyphae were observed in necrotic areas and in the vicinity of epitheloid cells. Sporulation was seen in the bronchial mucosa and lumen of the airways (Fig. 4.8- G, H). The granulomatous tissue expanded and compressed the adjacent alveoli. Air sacs also showed a granulomatous airsacculitis with massive thickening and infiltration with heterophils, macrophages and lymphocytes. Germinating conidia were also sometimes observed. These fungal bodies were found to invade through the parenchymatous tissue. In other organs, a similar granulomatous reaction was observed. Long branching septate fungal elements were readily discernible with Grocott's methenamine silver stain**,** and were found to be indistinguishable from *Aspergillus fumigatus*.

Impression smears from the mouldy growth stained with lactophenol cotton-blue revealed characteristic conidial heads radiating in columns (Fig. 4.8- I).

Tracheal and lung swabs from affected birds collected and grown on Potato dextrose agar (PDA) revealed fungal growth after 7 days of culture showing characteristics morphological features (Fig. 4.8- J). Luxuriant growth was observed in PDA (Fig. 4.8- K, L). Culture on Aspergillus differential agar (ADA) showed absence of intense yellow orange colour at the base of the colonies thus differentiating it from *A. flavus*.

4.3.4 MYCOTOXICOSIS

Two outbreaks of mycotoxicosis were suspected amongst pigeons, showing non-specific clinical signs such as emaciation, anorexia and greenish diarrhoea. The birds appeared unthrifty with considerable mortality reported by the owners.

Necropsy examination of eight pigeons from these two lofts revealed consistent yellow-greenish discoloration of the liver with visible fatty change (Fig. 4.9- A) and multiple haemorrhages in the parenchyma. Concurrently, renal degeneration and haemorrhages were also sometimes observed. Affected kidneys were pale and enlarged and together with the ureters showed distinct urate deposits (Fig. 4.9- B). Other concomitant lesions were mild air sacculitis, hydropericardium,

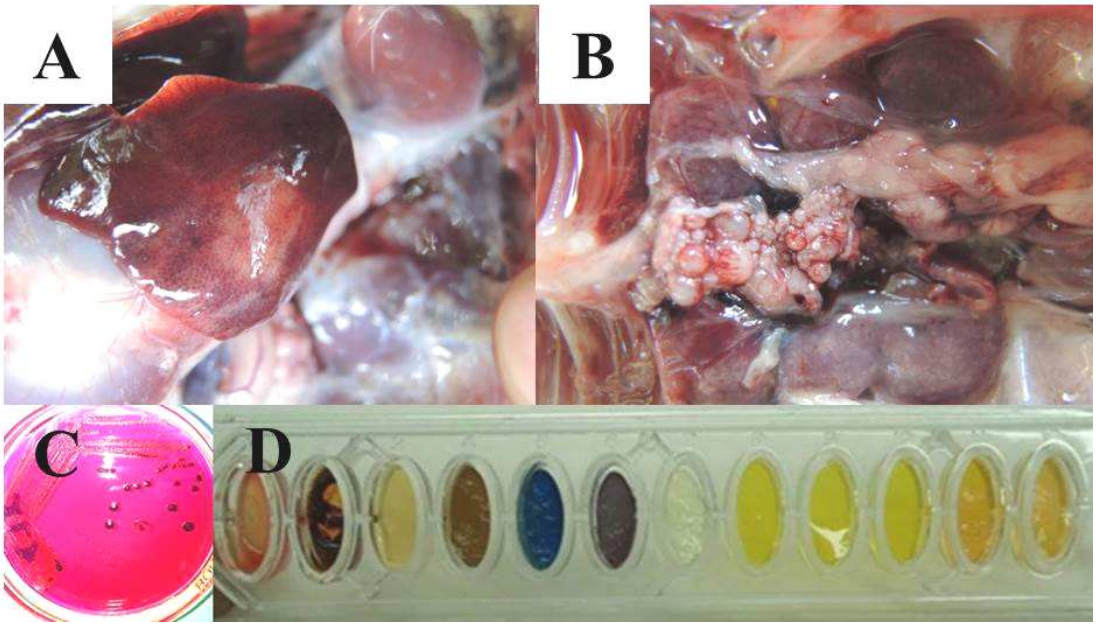

Figure 4.7: Lesions observed in pigeon (*Columba livia*) salmonellosis, culture of *Salmonella* and biochemical characteristics for confirmation of *Salmonella* sp. (A) Focal areas of hepatic degeneration and mild fibrinous pericarditis can be seen; (B) Oophoritis and necrotic foci on kidneys; (C) Red colonies of *Salmonella* with black centre on XLD media; (D) IMVIC pattern of *Salmonella* sp.

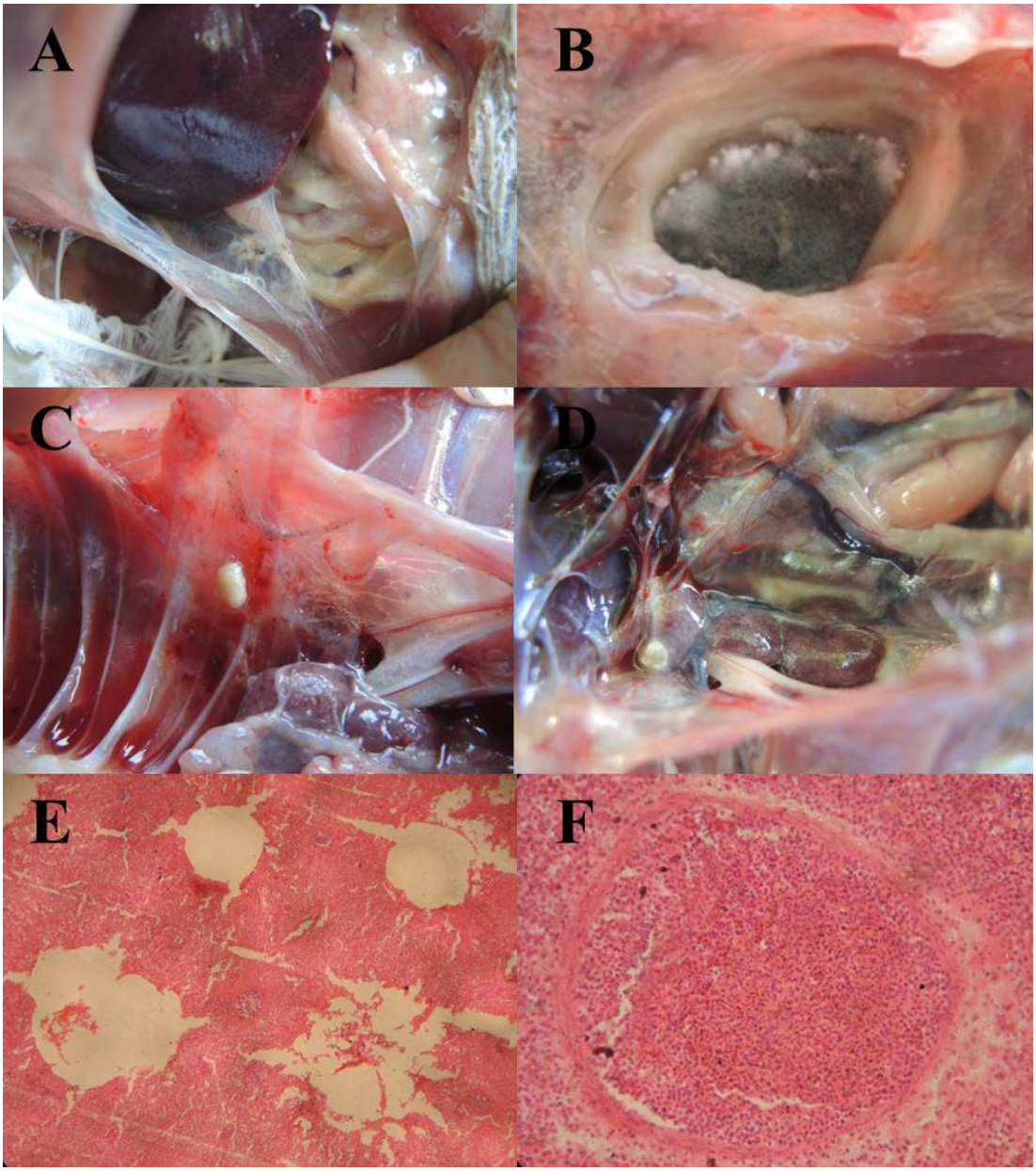

Figure 4.8: Lesions of aspergillosis caused by *Aspergillus fumigatus* in affected pigeons (*Columba livia*) (A) Yellowish plaque-like thickenings on abdominal air sacs; (B) Fungal nodules in lungs with white tufts of mycelium; (C) Whitish nodules of fungus on rib cage; (D) Yellowish fungal nodules on kidney; (E) A typical granulomatous pneumoniacould be seen. H&E, 4x; (F) Granulomas had a necrotic centre containing inflammatory and cellular debris and surrounded fibrous tissue proliferation at the periphery of the nodules. H&E, 10x.

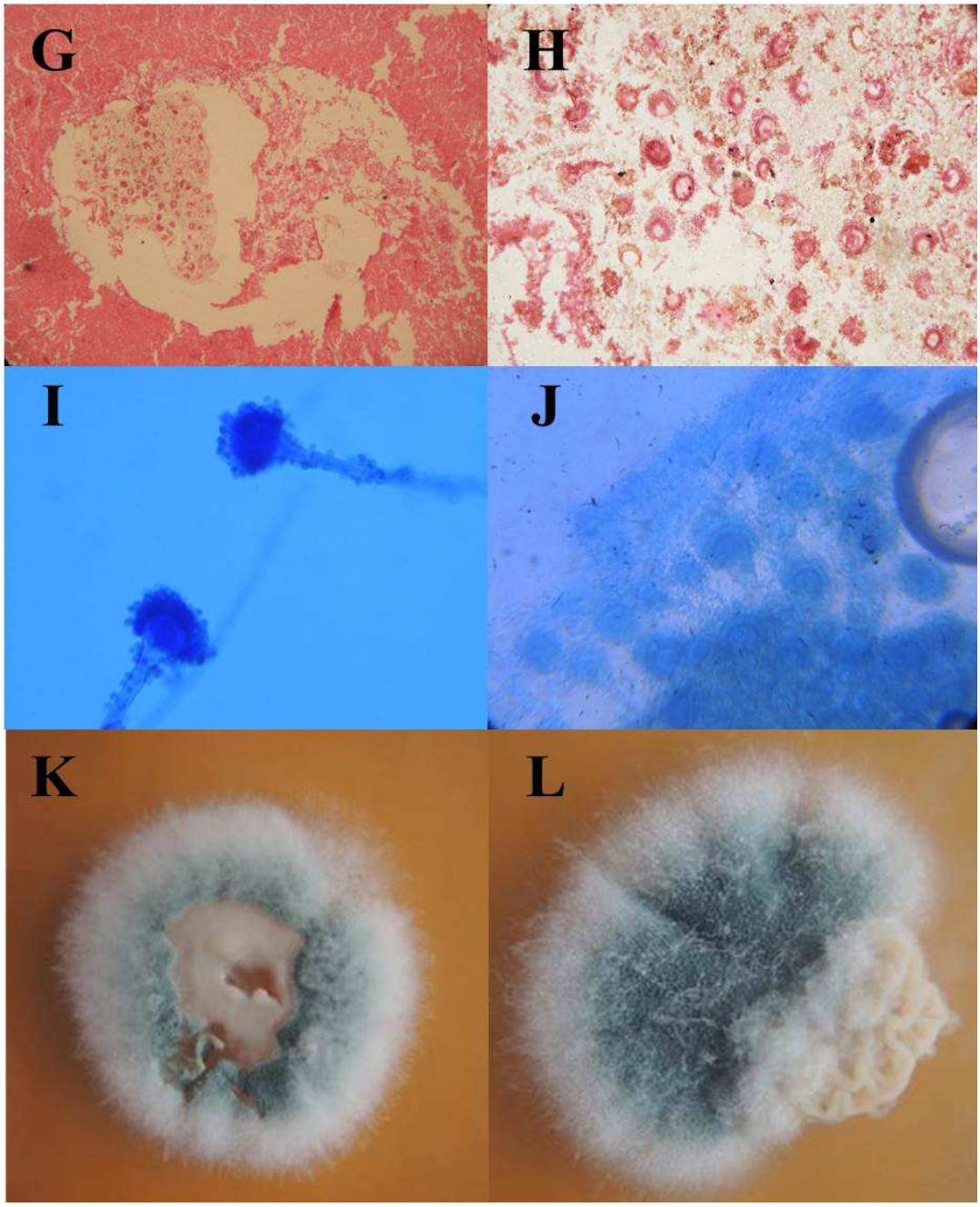

Figure 4.8.1 (Contd.): Lesions of aspergillosis caused by *Aspergillus fumigatus* in affected pigeons (*Columba livia*) (G) Non granuloma infiltrative lesions caused by invasive fungal elements in lungs tissue. H&E, 10x; (H) Fungal elements, consisting of germinating conidia in lumen of the parabronchi. H&E, 40x; (I) Typical conidial heads of *Aspergillus fumigatus* in fresh smear preparations. Lactophenol cotton blue, 40x; (J) *Aspergillus fumigatus* smear prepared from culture in Potato Dextrose Agar (PDA). Lactophenol cotton blue, 40x.; (K, L) Luxuriant growth of *Aspergillus fumigatus* in culture on Potato Dextrose Agar (PDA).

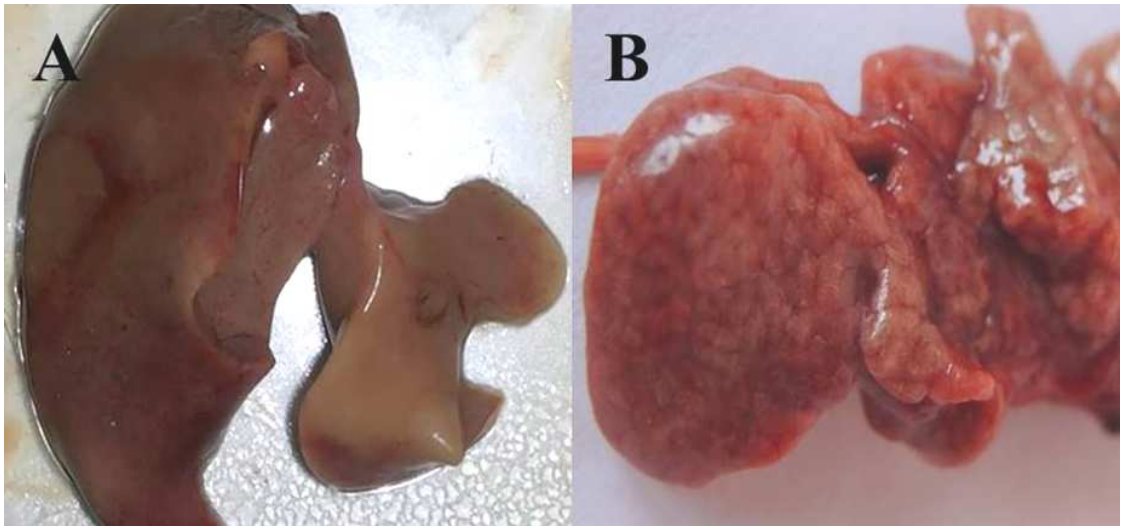

Figure 4.9: Hepatic and nephritic lesions associated with spontaneous mycotoxicosis in pigeons (*Columba livia*) (A) Fatty degeneration and yellow-greenish discoloration of the liver; (B) Pale and enlarged kidney with ureters showing distinct urate deposits.

massive haemorrhages in lungs with emphysematous patches and sloughing of gizzard lining.

Microscopic examination revealed cytoplasmic vacuolation of the hepatocytes indicating fatty change. In some instances there was proliferation of the bile ducts with mild infiltration by heterophils in the triad areas. In the kidneys, tubular epithelial degeneration and necrosis was observed. In the collecting tubules prominent casts were seen.

Feed grains were screened for mouldy growth. It was observed that pigeons were in almost all cases fed with a poor quality grains that were mouldy and stored in the open. Traditionally it was a habit of all pigeon fanciers to rinse the cereal grains before feeding. Excess feed and leftover grains were sometimes noticed to be mouldy.

4.3.4.1 Mycotoxin analysis in feed and tissues of affected pigeons

Feed and tissue samples send for mycotoxin detection and quantification revealed that all samples were positive (Table 4.4). Aflatoxin B1 was found in both feed and tissue samples while as citrinin and ochratoxin was also found in feed samples.

Table 4.4: Mycotoxin analysis of feed and tissue samples of pigeons (PLAFFS, TANUVAS, Chennai)

S. No.	Lab No.	Type of specimen	Analyte Result
1.	1383	Liver	Aflatoxin B1 – 5ppb (Ochratoxin A, Penicillic acid, Citrinin, T2 toxin Not detected)
2.	1385	Kidney	Aflatoxin B1 – 5ppb (Ochratoxin A, Penicillic acid, Citrinin, T2 toxin Not detected)
3.	1387	Lungs	Aflatoxin B1 – 5ppb (Ochratoxin A, Penicillic acid, Citrinin, T2 toxin Not detected)
4.	1389	Feed	Aflatoxin B1 – 25ppb Ochratoxin A – 40ppb Citrinin – 60ppb (Penicillic acid, T2 toxin Not detected)

4.3.4.2 Isolation of fungus from feed samples

Fungus isolated from suspected mouldy feeds and grown on Aspergillus differential agar (Fig. 4.10- A) showed luxuriant fungal growth by 5 days and presence of intense yellow orange colour at the base of the colonies (Fig. 4.10- B), a characteristic differential feature of *Aspergillus flavus* species.

4.3.4.3 Detection of aflatoxin production by ultraviolet light

Fungal cultures of *Aspergillus flavus* grown on Aspergillus Differential Agar (ADA) were observed under UV light to demonstrate black colonies and confirmed for the production of aflatoxin in the media (Fig. 4.10- C). Sample feed grains accessed under ultraviolet light (365 nm) to detect mycotoxin production showed positive levels of aflatoxin. Whole grains of corn and wheat showed mild greenish-golden fluorescence (Fig. 4.10- D), however grounded grains showed maximum greenish fluorescence (Fig. 4.10- F) indicating presence compounds associated with aflatoxin.

4.3.5 PARASITIC DISEASES

4.3.5.1 Ectoparasites

Both live and dead pigeons were examined externally revealed numerous ectoparasites including lice, flies, mites from skin scrapings and mosquitoes in the lofts and their relative prevalence is depicted in Table 4.5. The slender pigeon louse *Columbicola columbae* was consistently associated with all birds and found embedded in the feather shafts. The hippoboscid pigeon fly (*Pseudolynchia canarensis*) was commonly found in all pigeon lofts and a nuisance for the pigeons. The fly was found to bury deeply between the feathers and very hard to access.

As many as six species of ectoparasites were collected from the pigeons or their lofts. Four of them were insects, two belonging to Mallophaga, namely, the wing and tail feather chewing lice *Columbicola columbae* (Fig. 4.11- A, B) and the small pigeon louse *Campanulotes bidentatus* (Fig. 4.11- C); one belonging to Diptera, namely, the pigeon flatfly or louse fly *Pseudolynchia canariensis* (Fig. 4.11- D), and one belonging to Siphenoptera, tentatively identified as *Ctenocephalides* sp. (Fig. 4.11- F). Besides, there were many mosquito and fly species which were not

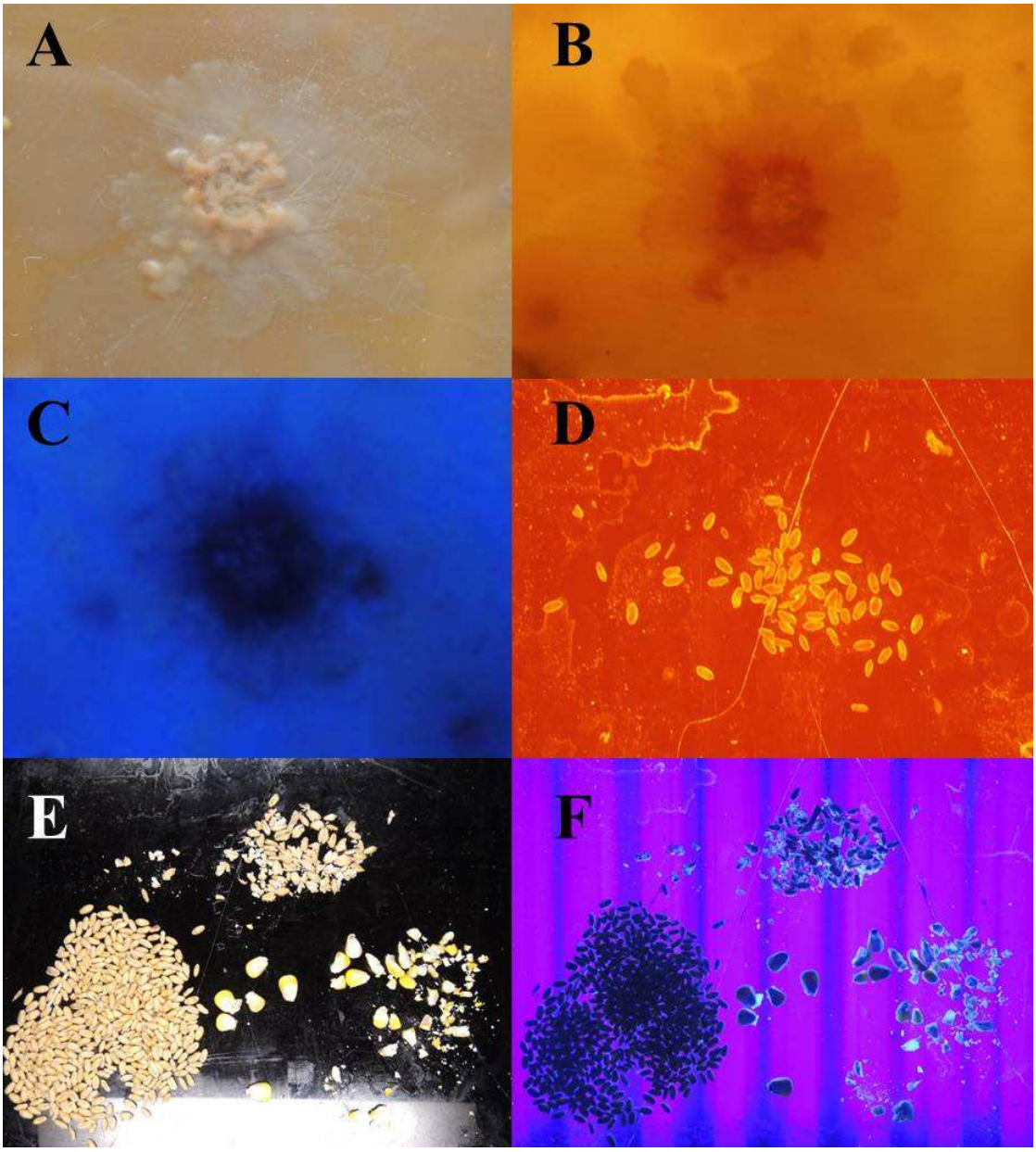

Figure 4.10: Fungal culture from feeds and detection of aflatoxin in fungal culture and feed grains by UV light (A) Culture of *Aspergillus flavus* from feed grains on Aspergillus differentiation agar (ADA); (B) same as A, with *Aspergillus flavus* showing characteristic intense orange colour at the base of the colonies (ADA) observed from below; (C) *Aspergillus flavus* culture on ADA showing aflatoxin production indicated by black fungal colonies detected under ultraviolet light (365 nm) photography; (D) Gold fluorescence of whole wheat under reflected ultraviolet light (365 nm) showing presence of aflatoxin; (E) Whole and grounded cereal grains under reflected white light; (F) same as E, with feed grains observed under transmitted ultraviolet light (365 nm) showing aflatoxin production through greenish fluorescence by broken kernels.



Figure 4.11: Different ectoparasites recovered from pigeons (*Columba livia*) (A) *Columbicola columbae*, slender pigeon louse; (B) *Columbicola columbae.* Unstained, 40x*;* (C) *Campanulotes bidentatus*, small pigeon louse. Unstained, 40x; (D) *Pseudolynchia canariensis*, hippoboscid pigeon fly; (E) *Psoroptes* sp. mite. Unstained, 40x; (F) A composite photomicrograph of a flea tentatively identified as *Ctenocephalides* sp.

identified. The other ectoparasite found belonged to Arachnida, comprising Acarina, namely, *Psoroptes* sp. Fig. 4.11- E)

Table 4.5: Relative prevalence of different pigeon ectoparasites

Parasite	Location	Remarks
Columbicola columbae	Feathers	Consistent finding in all pigeons
Campanulotes bidentatus	Feathers, skin	Detected in 20 pigeons
Flea, tentatively identified as *Ctenocephalides* sp.	Feathers	Found only once
Pseudolynchia canariensis	Body and tail Feathers	Abundant, seen regularly
Psoroptes mite	Skin	Detected twice in skin scrapings
Mosquito, unidentified	Pigeon loft	Common in loft that suck pigeon blood
Flies, unidentified	Lofts and surroundings	Ubiquitously present

4.3.5.2 Endoparasites

4.3.5.2.1 Metazoan enteric parasites recovered at necropsy

In the present study a total of 60 gastrointestinal tracts (GIT) of domesticated pigeons were examined from the different areas in Jammu district, of which 22 (36.67%) were found infected with parasites in different parts of GIT. The different species of enteric parasites recorded are depicted in Table 4.6.

The tapeworm *Raillietina* sp. belonged to the family Davaineidae, and was mostly recovered from the ileal part of the small intestine (Fig. 4.12- A). The vast majority of their specimens were attached to the mucosa through their scolices (Fig. 4.12- B, C) and probably enforced their anchoring by a cushion-shaped rostellar apparatus. Speciation was not attempted, but generic identification was possible upon close examination of their scolices and comparison with the published descriptions and illustrations. Sometimes, when scolices were missing, examination and morphometrics of the strobilae, proglottids and ova (Fig. 4.12- D) of these tapeworms

were not always sufficient for a definite identification. Sometimes the cestode infestations were overwhelming, often causing partial impaction of the intestinal tracts (Fig. 4.12- E).

Two species of nematode parasites were found in this study. They comprise of the large roundworm *Ascaridia* sp. and the hairworm *Capillaria* sp. Both these parasites were found to inhabit the small intestine.

Table 4.6: Helminthic parasites recovered from GIT of pigeons in Jammu region

Parasite	Location	Prevalence (%)
Ascaridia sp.	Intestine	3/60 (5%)
Capillaria sp.	Intestine	4/60 (6.67%)
Raillietina sp.	Intestine	15/60 (25%)

4.3.5.2.2 Protozoan infections

The relative prevalence of protozoan parasites in pigeons is represented in Table 4.7. Coccidian, cryptosporidian parasites and haemoprotozoal schizogony tissue stages were detected in cloacal and tissue samples from post-mortem materials, while clinical blood samples were collected to identify gametocytes of haemoprotozoa.

Table 4.7: Relative prevalence of protozoan parasites in pigeons from clinical and post-mortem samples

Protozoa	Sample	Prevalence (%)
Eimeria sp.	Cloacal content	35/60 (58.3)
Cryptosporidium sp.	Cloacal content	5/10 (50)
Haemoproteus columbae	In blood smears (live birds)	8/30 (26.6)
	In tissues (necropsy)	27/60 (45.0)

4.3.5.2.2.1 Coccidiosis

Coccidiosis in pigeon was an incidental finding with birds showing occasional diarrhoea and pasting of the vents. Out of the 60 carcasses observed, 35 cloacal faecal contents showed presence of coccidial oocysts.

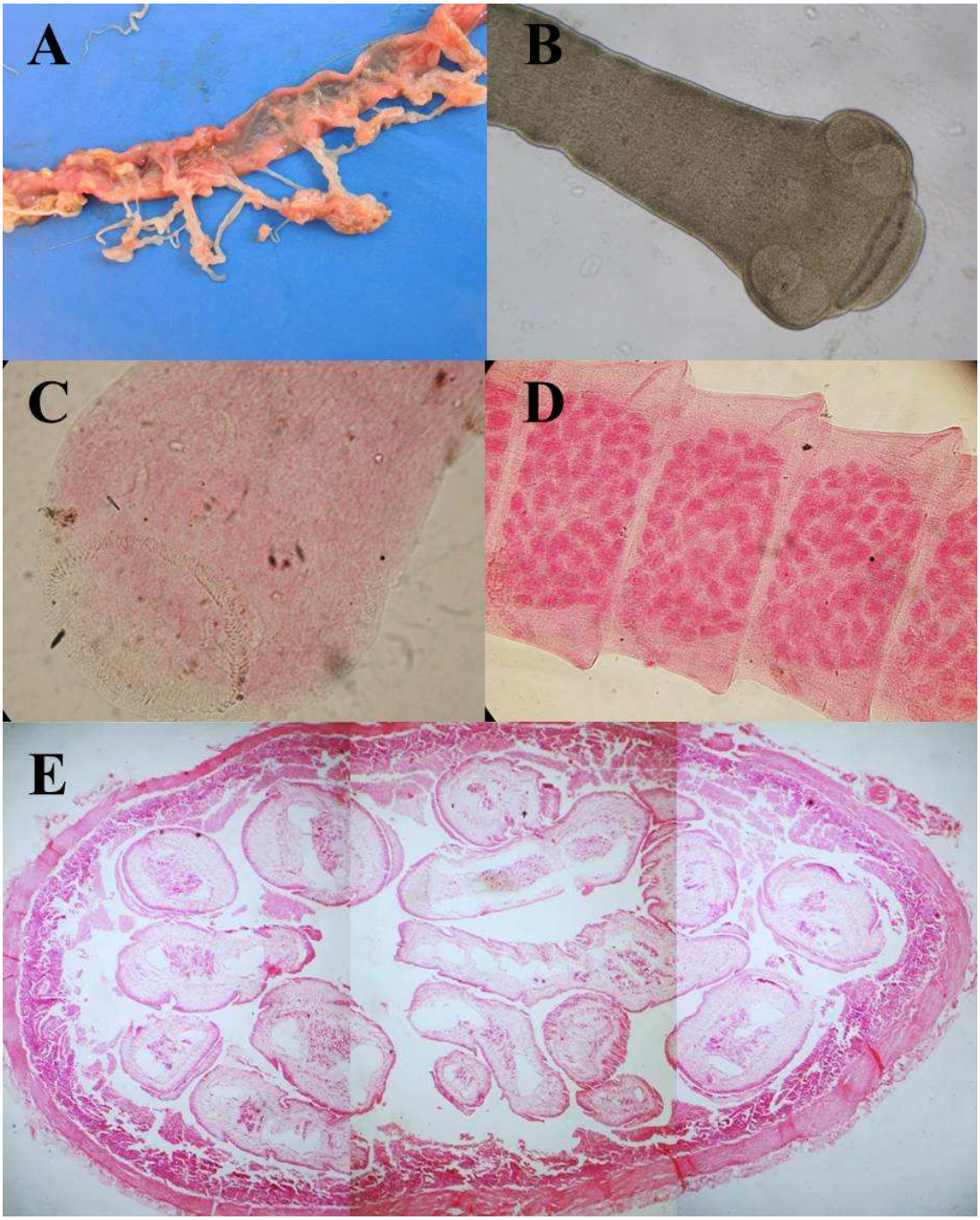

Figure 4.12: Cestodes recovered from intestine of pigeons (*Columba livia*) (A) *Raillietina* sp. partially impacting intestinal lumen; (B) *Raillietina* sp. scolex detail, fresh mount, 10x; (C) *Raillietina* sp. mounted specimen showing armed rostellum and sucker, borax carmine stain, 10x; (D) *Raillietina* sp. mounted specimen showing detail of gravid segments and eggs, borax carmine stain, 10x; (F) A composite photomicrograph of a cross section of the small intestine, showing partially impacted intestinal lumen with *Raillletina* parasite. H&E, 4x.

Catarrhal enteritis with congestion and occasional petechial haemorrhages on the intestinal mucosa was noticed. Intestinal scrapings revealed necrotic and inflammatory cells and unsporulated Eimerian oocytes. Different species of the protozoa were appreciated which varied in shape from spherical to ovoid, with size ranging between 18-27 µm in length to 14-20 µm in width.

Sporulation time varied from 7-10 days showing typical Eimerian characteristics with a thick outer shell containing 4 sporocysts, each with 2 sporozoites,

4.3.5.2.2.2 Cryptosporidiosis

Faecal smears stained with Ziehl-Neelsen's stain revealed acid-fast organisms indistinguishable from *Cryptosporidium* sp. from cloacal faecal content from 5 out of 10 bird carcasses observed. The oocysts appeared as spherical, irregularly spherical or slightly elongated (Fig. 4.13) measuring from approximately 4-6 µm in diameter.

4.3.5.2.2.3 Haemoproteosis

In a severe disease outbreak high mortality was reported amongst pigeons. Clinically, signs of severe respiratory distress, anorexia, and malaise, loss in body weight, dehydration, stupor and heavy mortality were noticed (Fig. 4.14- A). A total of 27 bird carcasses were necropsied which all had severe and consistent hepatic and pneumonic lesions. The liver appeared congested, with miliary pinpoint grey–white foci throughout the parenchyma (Fig. 4.14- B). Hydropericardium was noticed in three birds (Fig. 4.14- C). Lungs were sometimes haemorrhagic (Fig. 4.14- D) or severely congested and consolidated (Fig. 4.14- E). Sometimes, subcutaneous haemorrhage was noted beneath the skin of the cervical region (Fig. 4.14- F). The spleen was enlarged and the kidneys were pale with visible distension by urates.

Microscopically, lung tissue of the infected pigeons revealed various stages of protozoan parasite development. Severe congestion and consolidation was seen in the lung tissue (Fig. 4.14- G). Pulmonary blood vessels which were dilated and congested and schizonts could be detected within the endothelial lining that invaded the lung parenchyma into the alveoli destroying their wall and interstitium (Fig. 4.14- H). Most of the pulmonary alveoli were collapsed, while few were dilated with destruction of their wall and lysis of their endothelial lining. Areas of complete destruction of the

lung parenchyma or marked dilatation of the pulmonary alveoli with lacking of their endothelium were observed. There was severe infiltration by mononuclear cells in the interstitium. Typical round cell granuloma could be seen around blood vessels.

Histopathological examination of the liver showed multifocal and coalescing lesions of subacute hepatic necrosis with marked infiltrates of macrophages, lymphocytes, fewer plasma cells and scanty heterophils concentrated around the perivascular spaces around protozoal stages in the portal area (Fig. 4.14- I), sinusoids (Fig. 4.14- J,K) and central vein (Fig. 4.14- L). The predominantly infiltrative round cell was characteristic. Parasitic schizonts were also seen invading the portal blood vessels, central vein and the endothelial lining of the hepatic sinusoids. Schizonts were seen to invade through the endothelial lining and into the liver parenchyma. Within the hepatic parenchyma, areas of hepatocyte degeneration with vacuolated cytoplasm and pyknotic nuclei were frequently detected Small round cell granulomas could also be observed especially near areas of massive hepatocyte degeneration. In some cases fragmented and round forms of cellular debris was observed, which were indistinguishable from apoptotic bodies.

Haemoprotozoans were detected in the blood smears of sick or apparently normal birds within RBCs, where the intra-corpuscular gametocytes were elongated and crescent shaped. Of the 30 domestic pigeons examined, 8 (26.6%) were found to be infected with haemoprotozoa in the peripheral blood smears (Table 4.7). Out of positive samples, 5 smears were from male (62.5%) and 3 from female (37.5%) pigeons. The complete haematological profiles between infected and non-infected pigeons are statistically compared represented in Table 4.8.

They were found to partially encircle the nucleus of the host cell. Microgametocytes (10-12 x 1.5-5 μm) were stained violet with Giemsa stain while macrogametocytes (13-15 x 3.5-6 μm) were stained with a darker shade. Within the erythrocytes, haemozoin pigments derived from haemoglobin digestion were found that appeared as refractile, golden brown granules. Schizonts were not seen in the peripheral blood smears. Based on morphological characteristics, the haemoprotozoans were identified as *Haemoproteus columbae*. The concentration of the parasite was sparse (1–2 pars/100 RBC) but occasionally they were found to be more abundantly present within groups.

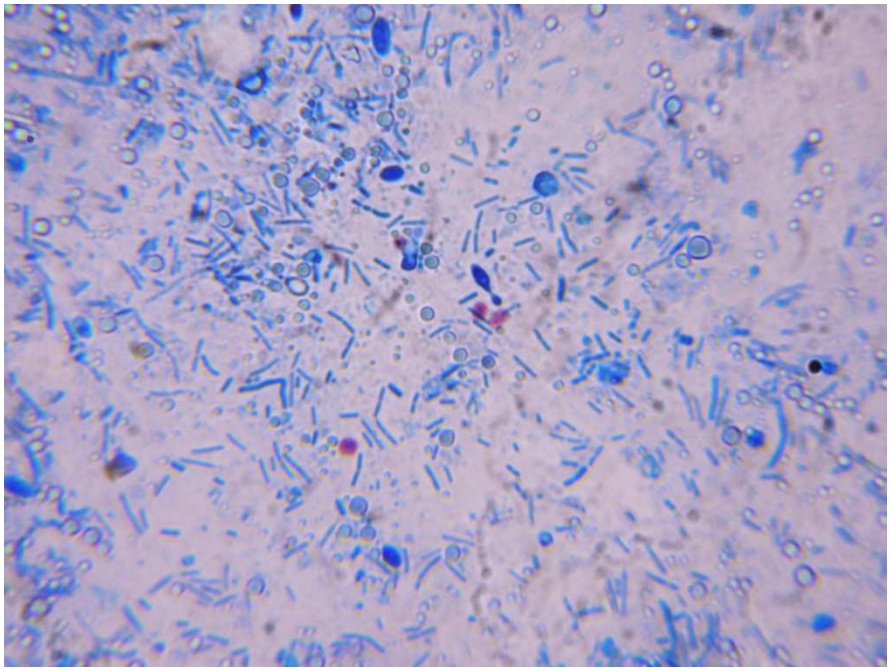

Figure 4.13: *Cryptosporidium* sp. observed from cloacal content of pigeons (*Columba livia*). Acid-fast (ZN) stain, 100x.

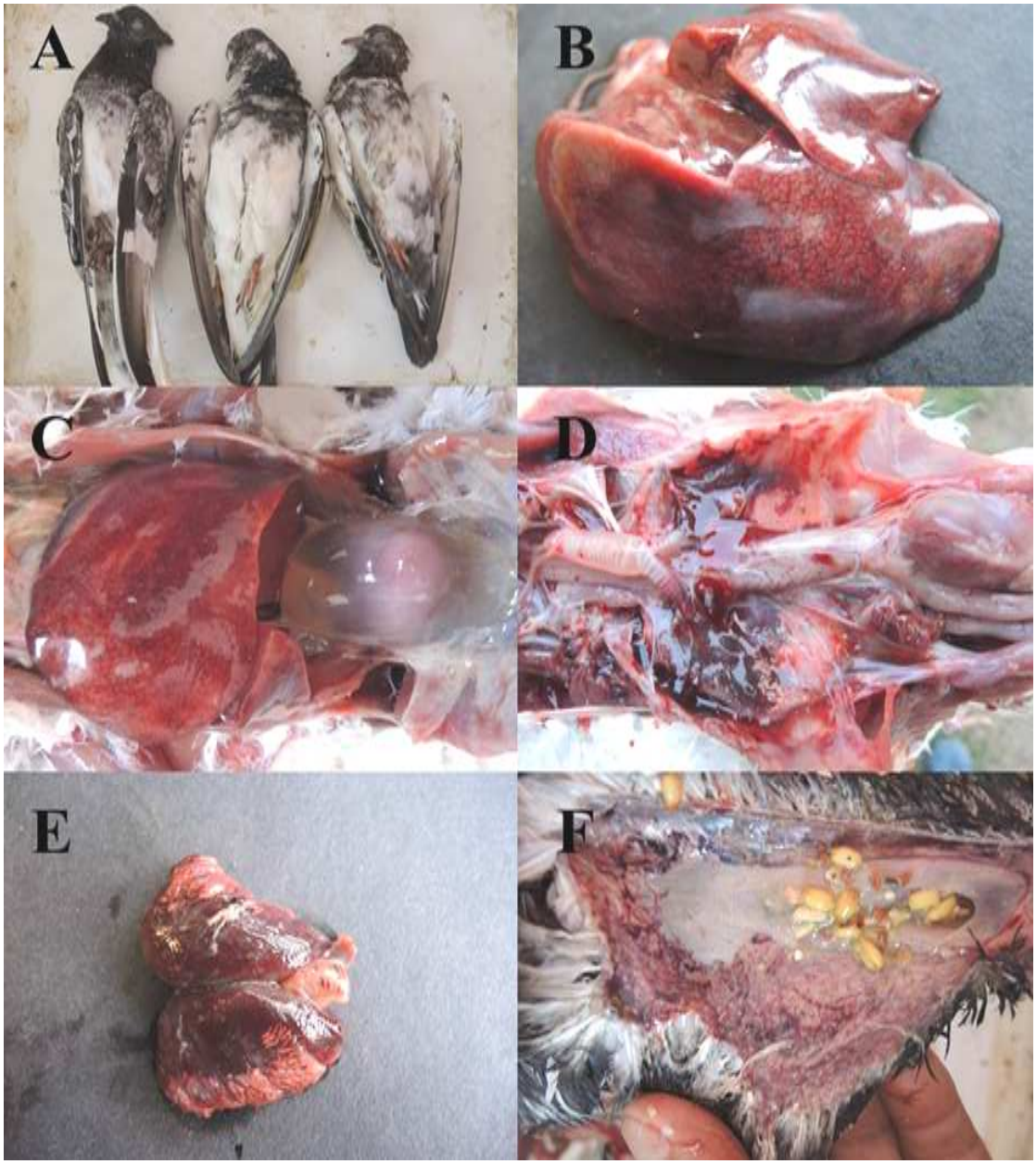

Figure 4.14: Tissue pathology of *Haemoproteus columbae* infection in pigeons (*Columba livia*) (A) Carcasses suspected for protozoal infection; (B) Congested liver, with milliary pinpoint grey–white foci in the parenchyma; (C) Congested liver and hydropericardium; (D) Severe haemorrhages in lungs; (E) Congestion and consolidation in lungs; (F) Haemorrhages beneath the skin in the cervical region.

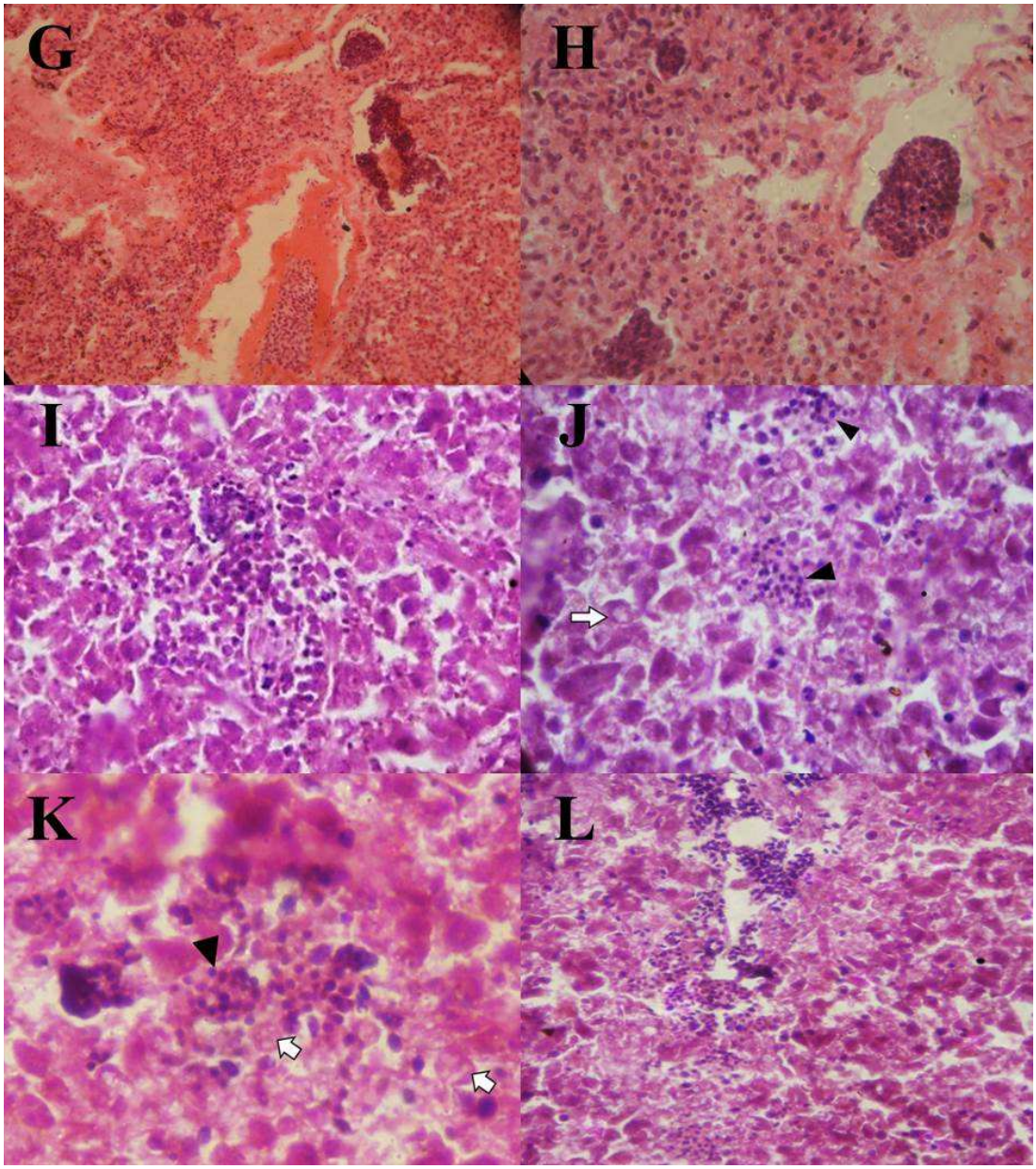

Figure 4.14.1 (Contd.): Tissue pathology of *Haemoproteus columbae* infection in pigeons (*Columba livia*) (G) Severe congestion and consolidation was seen in the lung tissue, H&E, 10x; (H) Pulmonary blood vessels were dilated and schizonts could be detected within the endothelial lining. H&E, 40x: (I) Developing schizonts in the portal vascular endothelium of liver; (J) Developing schizonts (black arrowhead) in hepatic sinusoids. Adjacent hepatocytes are vacuolated (white arrow); (K) Developing schizonts (black arrowhead) in hepatic sinusoids. Adjacent hepatocytes are vacuolated (white arrow); (L) Developing schizonts in endothelium of central vein of liver.

Mature gametocytes: Mature forms could be differentiated into microgametocytes (Fig. 4.15- A,B) with polar granules and nucleus diffused with the cytoplasm and macrogametocytes (Fig. 4.15- C-G) with randomly scattered granules and nucleus with clear margins.

Macrogametocytes were broadly sausage shaped, slightly halteridial and usually situated lateral to the erythrocytic nucleus. The fully grown parasite reached the poles of the infected erythrocyte and encircled its nucleus. The margins were mostly smooth and rarely amoeboid. Variations in the shape of macrogametocytes were quite evident. The granules were median or small sized and dispersed randomly in the whole cytoplasm. When the granules were small and their number was higher. Granules were black to yellow- brown in color.

Microgametocytes were slightly smaller than macrogametocytes, slightly halteridial and usually lateral to the host cell nucleus as macrogametocytes. The ends of the parasites are usually rounded and the margin entire. The gametocytes almost adhere to the host cell membrane at the polar zones but sometimes, in the central zones as well.

Immature and mature gametocytes: Young and immature gametocytes (Fig. 4.15- H) were visible in blood films developing lateral to the host cell nucleus with no contact with the host cell membrane or the host cell nucleus.

Extra-corpuscular forms of macrogametocytes (Fig. 4.15- I) could be seen lying free in the plasma. The extra-corpuscular forms lying in the plasma were irregular shaped. Cytoplasm was granular, granules being dispersed throughout the parasite.

Haematological parameters: Blood collected for screening of haemoprotozoan parasites from apparently healthy and sick pigeons were also subjected to evaluation of haematological profile. A significant variation ($p<0.05$) was observed in Hb, PCV and eosinophils between *Haemoproteus* infected and non-infected pigeons. However, a non-significant variation ($p<0.05$) was observed in heterophils, monocytes and basophils as depicted in Table 4.8.

Table 4.8: Haematological indices of domestic pigeons affected by various disease (*Columba livia*) in Jammu region (Mean ± S.E.)

Parameters	Non infected (n=22)	Infected (n=8)
PCV (%)	41.08 ± 0.32[a]	32.79 ± 0.52[b]
Hb (g/ dl)	11.73 ± 0.4[a]	8.08± 0.30[b]
Heterophils (%)	52.00 ± 0.47	50.00 ± 0.87
Lymphocytes (%)	35.00 ± 0.34	34.83 ± 0.60
Monocytes (%)	8.70 ± 0.35	8.50 ± 0.26
Eosinophils (%)	2.50 ± 0.15[a]	5.50 ± 0.39[b]
Basophils (%)	1.91 ± 0.19	1.16 ± 0.32

[ab]*Means within a row with different superscripts are significantly different at p<0.05*

4.3.5.3 Seasonal prevalence of endoparasites based on faecal examination.

During the study period (July 2015 – June 2016) a total of 24 pooled faecal samples examined from six select villages of Jammu district in the four recognized seasons revealed presence of different parasitic ova. The load of infection was designated arbitrarily from none (0) to very severe (4) and the mean parasitic egg load calculated for each parasite during the four prevalent seasons (Table 4.9) and graphically represented in Figure 4.16. The results showed that Ascarid eggs were least prevalent whereas, prevalence of *Eimeria* sp. was highest amongst all parasitic eggs and had a particular higher prevalence in the winter season.

Amongst the nematodes, *Ascaridia* eggs (Fig. 4.17- A) were not consistently seen, and its occurrence was sporadic with a particular prevalence in the monsoon and post monsoon period. *Capillaria* eggs (Fig. 4.17- B) were relatively abundant with no particular seasonal prevalence. *Eimeria* sp. (Fig. 4.17- C) after *in vitro* sporulation typically contained four sporocysts containing a pair of sporozoites each (Fig. 4.17- D). Cestodiasis with *Raellietina* sp. (Fig. 4.17- E) was the most common metazoan enteric infestation but its observed prevalence apparently was lowered in the peak summers. Many parasitic ova could not be identified (Fig. 4.17- F).

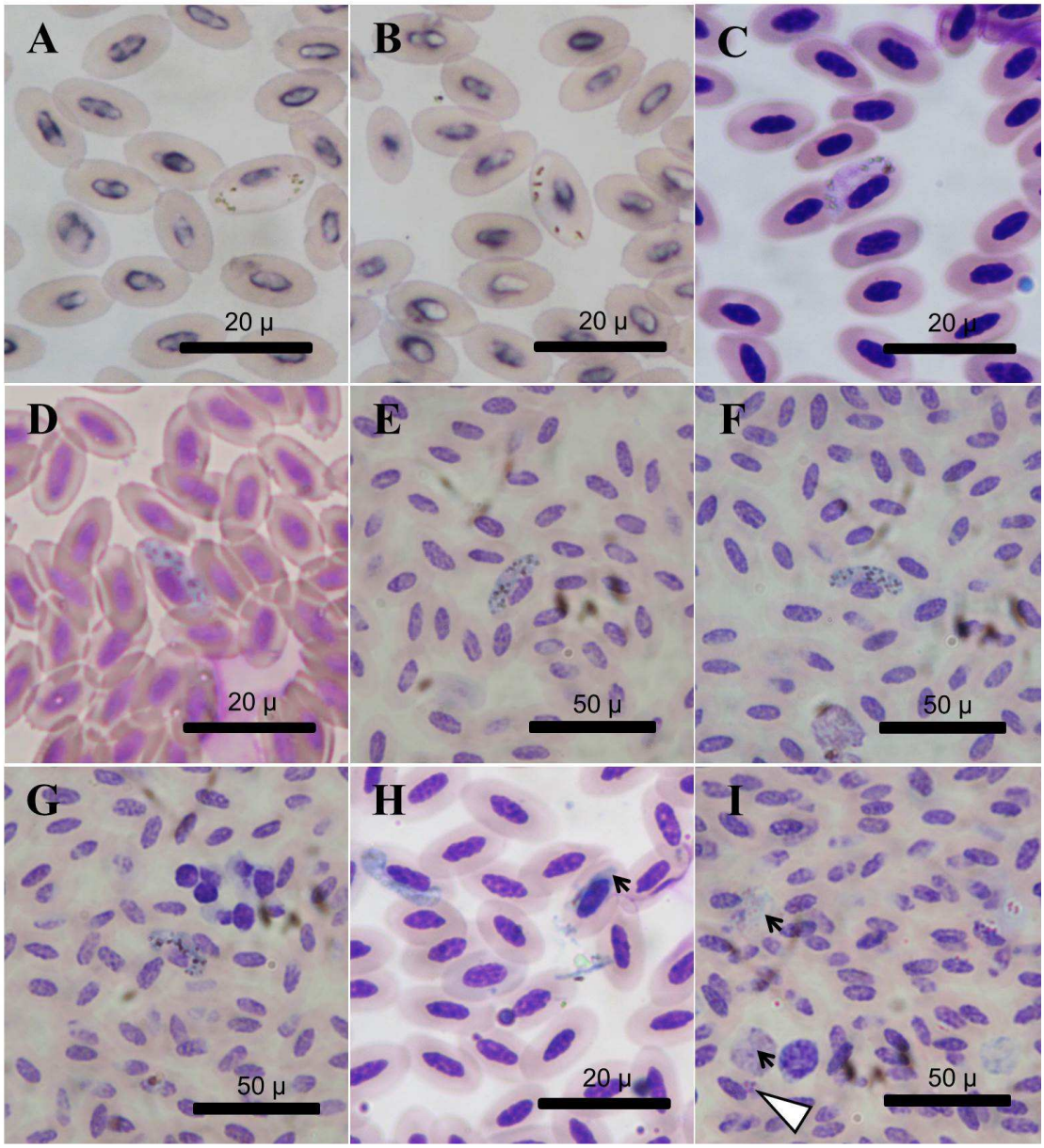

Figure 4.15: Peripheral blood smears of pigeons (*Columba livia*) showing *Haemoproteus columbae* gametocytes within erythrocytes (A, B**)** Microgametes with polar granules and nucleus diffused with the cytoplasm. Giemsa stain, 40x; (C-F) Macrogametes with randomly scattered granules and nucleus with clear margins, Giemsa stain, C-D 40x, E-F 10x; (G) Halter-shaped macrogamete reaching beyond the poles of the erythrocyte. Giemsa stain, 10x; (H) Immature gametocyte (black arrow), Giemsa stain, 40x; (I) Immature gametocyte (white arrow head) and extra-corpuscular macrogametocytes (black arrows). Giemsa stain, 10x.

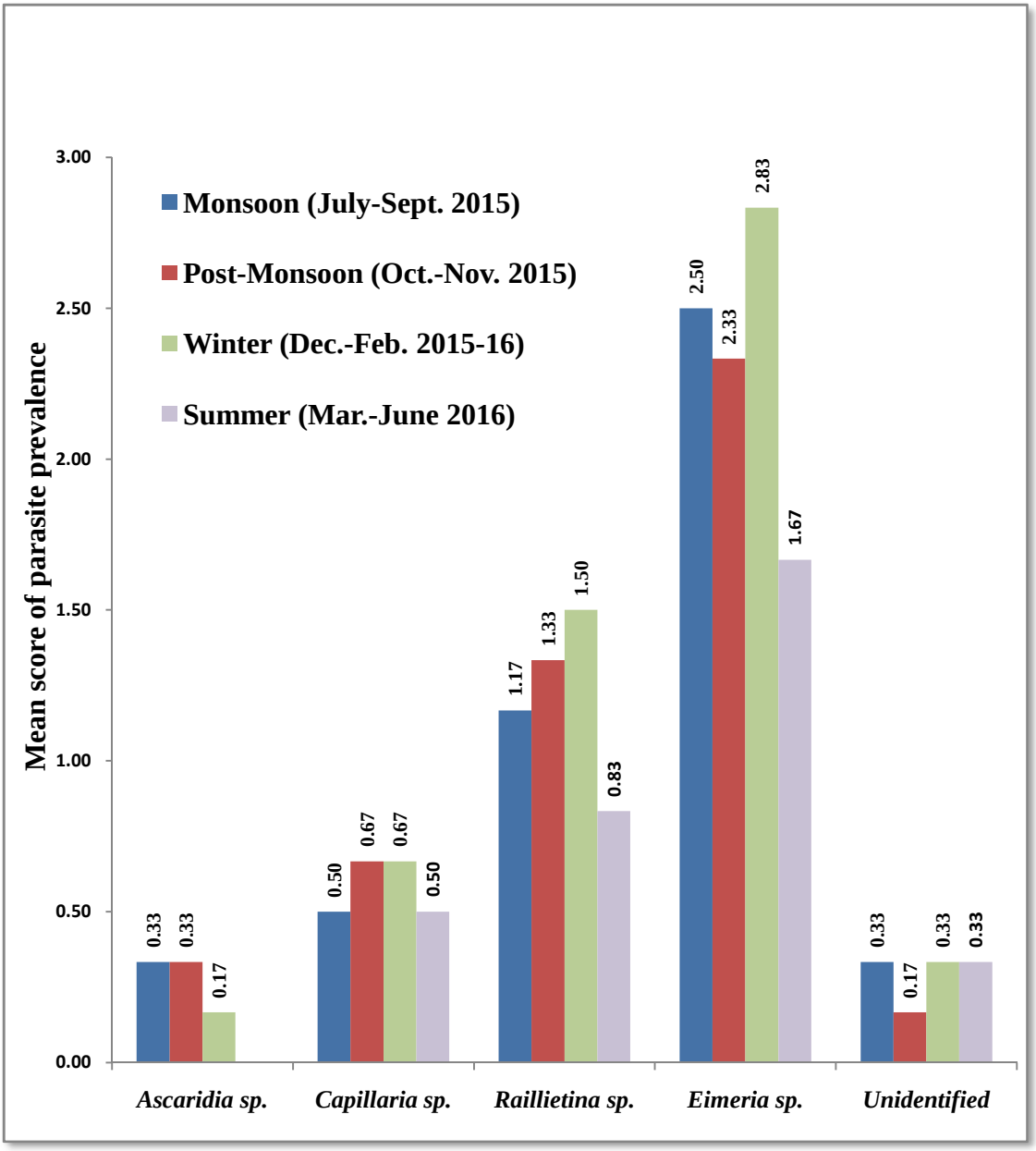

Figure 4.16: Mean seasonal prevalence (on a relative scale ranging from 0-4) of different parasites in faecal samples of pigeon (*Columba livia*)

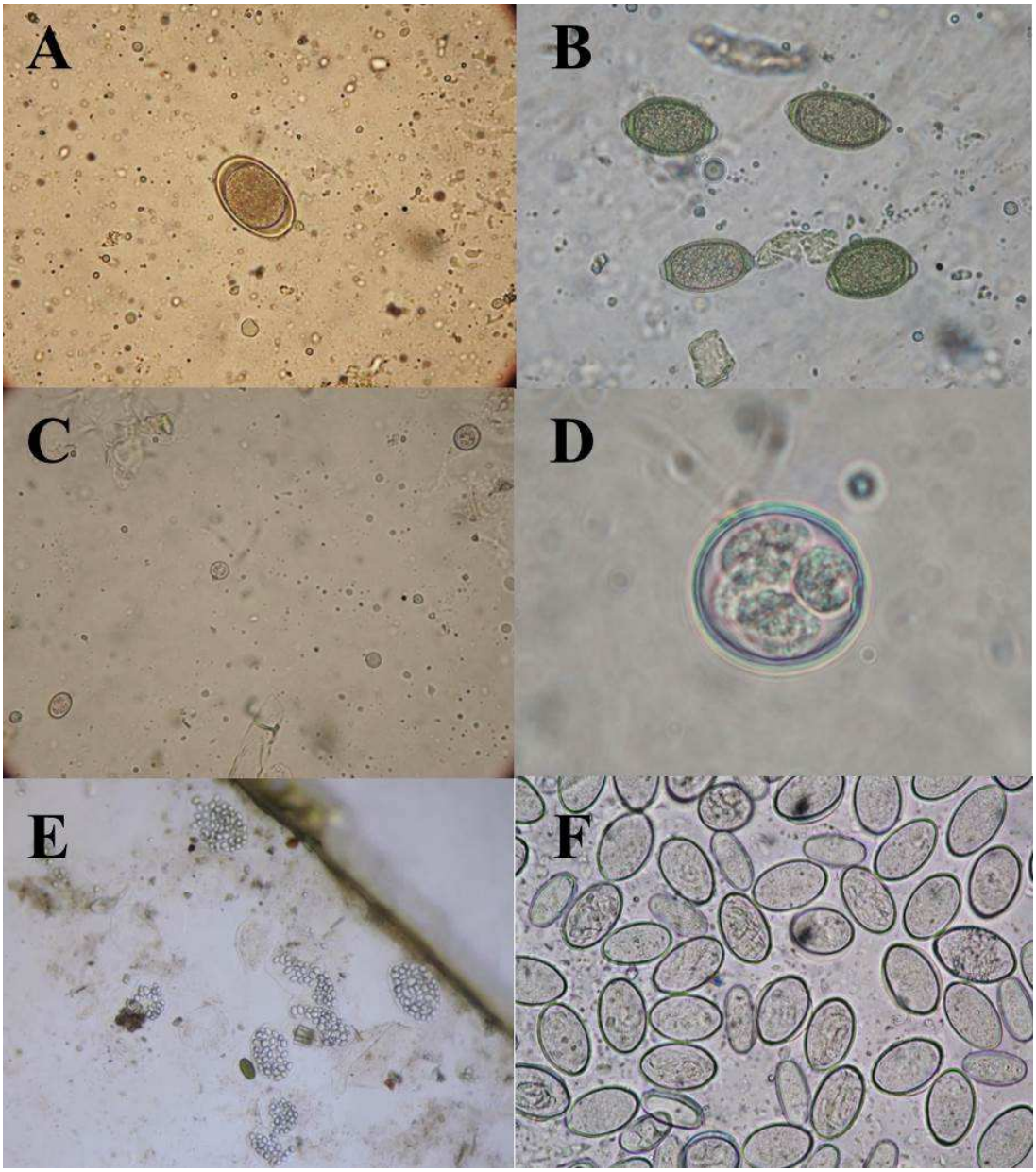

Figure 4.17: Parasitic ova prepared from pooled faecal samples of pigeons (*Columba livia*) (A) *Ascaridia* sp. egg. Unstained, 40x; (B) *Capillaria* sp. egg. Unstained, 40x; (C) Different unsporulated eimerian oocysts. Unstained, 10x; (D) *Eimeria* sp. Sporulated oocyst. Unstained, 100x; (E) *Raillietina* sp. egg. Unstained, 10x; (F) Unidentified eggs. Unstained, 40x

Table 4.9: Seasonal prevalence of parasitic load in pooled faecal samples from pigeons of six different villages

Season	Area	*Ascaridia* sp.	*Capillaria* sp.	*Raillietina* sp.	*Eimeria* sp.	Unidentified
Monsoon (July-Sept. 2015)	Kotli	0	2	1	2	0
	Banota	0	0	1	3	0
	Suchetgarh	1	0	2	2	1
	Rangpur	0	0	0	2	0
	Biaspur	1	1	1	2	0
	RS Pura	0	0	2	4	1
Mean		**0.33**	**0.50**	**1.17**	**2.50**	**0.33**
Post-Monsoon (Oct.-Nov. 2015)	Kotli	1	2	2	2	1
	Banota	0	0	1	3	0
	Suchetgarh	0	1	1	2	0
	Rangpur	0	0	1	2	0
	Biaspur	1	1	1	2	0
	RS Pura	0	0	2	3	0
Mean		**0.33**	**0.67**	**1.33**	**2.33**	**0.17**
Winter (Dec.-Feb. 2015-16)	Kotli	0	1	1	2	0
	Banota	0	0	1	4	0
	Suchetgarh	0	1	1	2	0
	Rangpur	0	1	3	3	0
	Biaspur	1	1	1	2	0
	RS Pura	0	0	2	4	2
Mean		**0.17**	**0.67**	**1.50**	**2.83**	**0.33**
Summer (Mar.-June 2016)	Kotli	0	1	1	2	0
	Banota	0	0	1	2	0
	Suchetgarh	0	1	1	2	2
	Rangpur	0	0	1	1	0
	Biaspur	0	1	0	1	0
	RS Pura	0	0	1	2	0
Mean		**0.00**	**0.50**	**0.83**	**1.67**	**0.33**

Arbitrary designation of parasitic load: 0=none; 1=low; 2=mild; 3=heavy; 4=severe

4.4 TRAUMATIC INJURY

Amongst those necropsied, four birds were found to have died due to fatal traumatic and haemorrhagic injury caused probably by infighting. Necropsy in one

bird revealed a pointed injury in the cervical region with rupture of the carotid artery (Fig. 4.18- A). Another bird was found to be preyed by a raptor *Accipiter badius* in mid-flight and for some reason abandoned the half eaten carcass (Fig. 4.18- B).

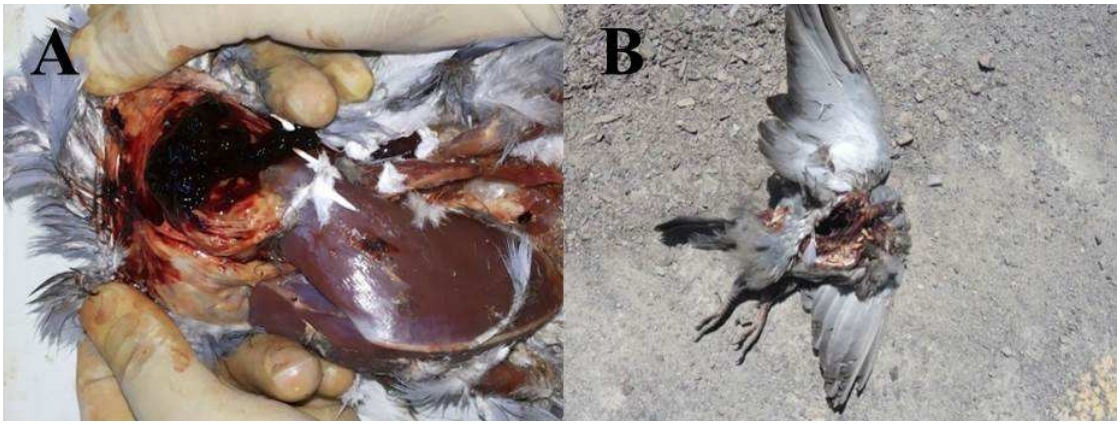

Figure 4.18: Mortality of pigeons (*Columba livia*) due to traumatic injury(A) Rupture of cervical blood vessels of a pigeon due to infighting; (B) Pigeon killed by the raptor bird *Accipiter badius*

DISCUSSION

The present study to record the various pathological conditions affecting the domestic pigeon (*Columba livia*) in Jammu region is probably the first attempt in the region to realize such a survey. A total of approximately 3980 domestic pigeons belonging to various pigeon fanciers were screened for clinical cases of disease affection. Out of these, a total of 608 birds were found to be clinically affected based on flock history, clinical examination and laboratory investigation. Although the exact figures could not be ascertained, it was always a calculated guess for the owners when keeping a daily record of their flock size in the coops or lofts. This is due to the nature of the rearing of the pigeons as racers, where the birds are let loose only to find their way back to each other's lofts as part of the sport. The flock size is therefore always variable and not constant at any given period of observation. The population figure therefore represents an average number of birds during the study period. Apart from these limitations, keeping track of affected birds also becomes difficult. Except for very sick and resident brooding birds, the flock is largely mobile. At best, an overall calculated evaluation of the clinically affected birds was estimated at 15.28%. The higher prevalence in certain areas represents severe outbreak of diseases amongst the birds.

In the present study, on the basis of clinical, necropsy results, histopathologic observations and laboratory diagnosis, several affections were observed in pigeons including viral, bacterial, fungal, parasitic and toxicologic affections amongst pigeons. In most cases, disease affections were associated with varying fatalities. Owner reported mortality figures although recorded, were very arbitrary and vague and have not been shown. Mortality was accounted only for birds that were accessed for necropsy examination. Overall mortality figures of 1.51% out of the estimated population of birds surveyed therefore may not be a true epidemiological representation.

Representation of mortality figures and aetiopathology of death was based on necropsy and laboratory confirmation only. The predominant affection of the birds was due to an endemic and severe outbreak of haemoproteal pneumonia and hepatitis.

Evidently, protozoal pneumonia with hepatitis, Newcastle disease and mycotoxicosis are the three main etiological causes of mortality, accounting for 78.00% deaths amongst the birds. The significance of each of the disease conditions are discussed under appropriate headings.

VIRAL DISEASES

New Castle Disease

Newcastle disease is a serious problem in pigeons caused by avian paramyxovirus-1 (APMV-1). Fairly high morbidity and mortality rate due to its infection in pigeons was observed within the lofts in the present study. Mangat *et al.* (1988) reported 50 to 70% morbidity in an outbreak of PMV-1 in racing pigeons in India. They further reported mortality around 60% in field outbreaks. In the present study, greenish white diarrhoea and nervous signs were more frequently observed. Barton *et al.* (1992) also observed diarrhoea and nervous signs associated with ND in racing pigeons. Paralysis of wings and legs in the present study and reported by many other workers stated above could be due to lesions of peripheral nerves. Fischer (1986) observed mainly degenerative lesions in peripheral nerves in 46% of the cases and postulated that these degenerative lesions accompanied inflammatory lesions of the nervous system. Khan (1968) reported paralysis of legs and wings in 80 and 60 percent experimentally infected pigeons, respectively which are fairly high than those observed in the present study. Severe respiratory signs were observed in the present study. Contrarily, Khan (1968) did not observe any respiratory signs in field outbreaks or experimentally inoculated pigeons but laboured breathing and respiratory distress was reported in pigeons kept in a cage adjoining experimentally infected pigeons. In this study, visceral lesions recorded are in sharp contrast to findings of Eisa and Omer (1984) and Maeda *et al.* (1987) who reported no gross lesions in natural outbreaks of ND in pigeons. However, the observed lesions were quite consistent to others, such as El-Mubarak *et al.* (1990) recording congestion of viscera and catarrhal enteritis in experimentally infected pigeons with paramyxovirus-1; Mubarak (2000) observing haemorrhages and leucocytic infiltration in lungs; Fischer (1986), El-Mubarak *et al.* (1990) and Barton *et al.* (1992) describing brain lesions and a non-purulent meningo-encephalitis; Mangat *et al.* (1988) and Ecco *et al.* (2011) describing neuron degeneration, neuronophagia, gliosis, endothelial cell proliferation and severe

degeneration of Purkinje cells in field outbreaks. The degenerative, malacic and demyelinative neuronal lesions were remarkably similar to observations of Bhaiyat *et al.* (1994). The present observations of severe clinical lesions leaves no doubt on the highly pathogenic and virulence potential of the prevalent pigeon paramyxovirus. Together with its high morbidity, it causes severe economic losses to the fanciers. Because the pigeon and chicken strains are related and similar, both belonging to APMV-1, cross-transmission between the species is a possibility. Besides, pigeons as a reservoir of infection for ND viral transmission and dissemination are a matter of serious concern. It is postulated that regular vaccination of farm and commercial chicken is a must. However, vaccination of pigeons with oil based vaccines cultured from PMV-infected pigeons can only be fully protective, instead of live, water based LaSota vaccine strains (Stone, 1989).

Pigeon Pox

Pigeon pox is a serious issue in pigeons resulting in tremendous economic loss to pigeon fanciers in India and worldwide (Bwala *et al.*, 2015). In the present study several cases of pox infections were brought to Division of Veterinary Pathology was diagnosed by the presence of scaby lesions on the head and unfeathered parts of body and confirmed by histopathogical observations. Presence of epidermal hypertrophy, hyperplasia in cutaneous lesions and several acidophilic intracytoplasmic inclusions observed on histopathological examination have been classically described in the literature (Mohan *et al.*, 2008; OIE, 2010) and inclusion bodies were consistent in appearance with Bollinger bodies (Riddell, 1987; Randall & Reece, 1997).

Pox infection usually occurs through the mechanical transmission of the virus to injured skin and also the bite of mosquitoes or mites (Tripathy, 1991). Despite the variety of hosts, avian poxvirus infection is manifest either cutaneously or diptheritically, and both forms of the disease may occur in the same bird (Fallavena *et al.*, 1993). In the cutaneous form, the proliferative lesions are primarily confined to featherless areas of skin; while in the more lethal diphtheritic form, the lesions may be found in the upper digestive and respiratory tracts (Tripathy *et al.*, 2000). In the mild cutaneous form of pox disease, flock mortality is usually low, but it may be high when the infection is of a generalized or diphtheritic form and also when the flock is

affected by a secondary infection, usually in poor environmental conditions (Gorta´zar *et al.*, 2002).

Virulence of the virus strain, susceptibility of the host and route of transmission are contributing factors influencing the degree and form of infection. Death due to viraemia has also been described but this form is mainly restricted to canaries (Johnson and Castro, 1986; Tripathy, 1993; Phalen, 1997). Nevertheless, occasional cases of systemic disease are also seen in some psittacine birds (Tsai *et al.*, 1997).

Pock lesions on the CAM of 14-day developing chicken embryo in the present study were similar to observations by Bwala *et al.* (2015) at day 7 post-inoculation in embryonated 10–11 day old chicken eggs. van Riper III and Forrester (2007) recommends that isolation via the propagation of virus on chorioallantoic membranes of chicken embryos should be used as the definitive diagnosis of choice, with the cautionary remark that some strains of avian poxvirus in wild birds do not grow readily in chicken embryos.

For pigeons, a live modified virus vaccine has been recommended to prevent disease manifestations in homing and meat-type pigeons (Bolte *et al.*, 1999).

BACTERIAL DISEASES

Pigeons are widely distributed in urban and rural areas and often come in close contact with humans at several public places and recent increase in pigeon population has raised certain public health concerns by being potential reservoirs for several pathogenic microorganisms including *Chlamydia* sp., *Salmonella* sp., *E. coli* and *Mycobacterium* sp. (Haag *et al.*, 2004) and *Nocardia* sp. (Darzi *et al.*, 2012). The zoonotic concern for *Salmonella* and *E. coli* isolates may be highlighted, while also disseminating the agents in the spread of colibacillosis and paratyphoid infection in domestic poultry.

Colibacillosis

The lesions observed were similar to those observed in colibacillosis in pigeons (Phangcho, 2001; Dutta *et al.*, 2013a) and chicks (Gurumurthy and Rao, 1962; Cheville and Arp, 1978) and turkey poults (Kaura *et al.*, 1988).

Salmonellosis

Gross lesions and microscopic lesions associated with salmonellosis were akin to those described in pigeons by Phangcho (2001) and Dutta *et al.* (2013b). The morphological alterations reflect an acute nature of the salmonellosis.

Paratyphoid caused by *Salmonella enterica* subsp. *enterica* serovar Typhimurium (variant Copenhagen PT2 or PT99 strains) is reportedly the main bacterial disease in pigeons. Its ability to persist intracellularly inside pigeon macrophages results in the development of chronic carriers, which maintain the infection in the flock (Pasmans *et al.*, 2003, 2008). The typhoid caused by these strains results in gastroenteritis, arthritis, oophoritis or orchitis, granulomatous inflammation in all possible organs, and high mortality (Faddoul and Fellows, 1965). Pigeons kept in groups in pigeon lofts, facilitate the long-term maintenance of a *Salmonella* infection. Although vaccination is a valuable part of a control program, it does not eliminate the possibility of a clinical infection in a pigeon aviary but mainly reduces clinical symptoms and mortality (Uyttebroek *et al.*, 1991; Proux *et al.*, 1998). Antimicrobial treatment is often used as an aid to control salmonellosis in the aviary. However their widespread use could lead to antibacterial resistance as cautioned by Dutta *et al.* (2013b). Morever, *Salmonella* bacteria may persist inside pigeon macrophages, a niche in which these microorganisms are well protected from most antimicrobial agents (Pasmans *et al.*, 2003). It has been suggested previously, but not clearly proven, that antimicrobial treatment may promote the carrier state (van Duijkeren and Houwers, 2000).

FUNGAL DISEASES

Fungi are commonplace in the environment and some are even considered normal inhabitants of skin, gastrointestinal tract and other mucus membrane surfaces in humans and animals including birds. Aspergillus elements in birds enter via inhalation (Oglesbee, 1997), and because the spores are small some are able to reach the lungs and air sacs (Fedde, 1998). The air sacs are usually the primary infection sites (Nardoni *et al.*, 2006) and in the lung parenchyma, spores get embedded in the atria and parts of the infundibula in the parabronchus and are engulfed by phagocytic epithelial cells (Maina, 2002). As observed in the present study, sporulation

reportedly may occur in the lungs and air sacs (Nardoni *et al.*, 2006; Cacciuttolo *et al.*, 2009) which may penetrate the air sacs, causing serositis and superficial necrosis in the adjacent organs (Tsai *et al.*, 1992). These could be a basis disseminated mycosis and direct extension of the infection through the air sac wall.

The signs and lesions observed in the study were similar to reports of Tokarzewski *et al.* (2007) during an aspergillosis outbreak in a flock of near 350 pigeons. Of the two types of tissue reaction recognized in aspergillosis (Beernaert, *et al.*, 2010) - the granulomatous or deep nodular form, and the infiltrative or superficial diffuse form, the lesions in the present study resembled both types. In contrast to the granulomatous encapsulated reaction type developing in both non-aerated and aerated organs (Nardoni *et al.*, 2006; Femenia *et al.*, 2007; Cacciuttolo *et al.*, 2009), the fungus in non-encapsulated infiltrative type frequently invades blood vessels in aerated organs such as the lungs and the air sacs, and form aggregates of radiating hyphae containing large numbers of conidiophores and conidia while a structured granuloma formation may be absent (Nardoni *et al.*, 2006; Cacciuttolo *et al.*, 2009). Mixed type composed of both tissue reactions in the same tissue section is also reportedly possible (Tsai *et al.*, 1992; Atasever and Gümüssoy, 2004).

A common practice observed amongst the pigeon rearers during the present study was to wash and soak the grains in order to soften them before feeding. In most cases the grains are soaked and stored in lots for subsequent batches of feeding. This could one reason which favours the growth of fungus. Besides, almost all rearers maintained the lofts very poorly with no periodic disposal of wastes and litter. The interiors were very dark and shabby, all favourable conditions for mouldy growths and their persistence. These conditions can also be compounded by other factors such as stress amongst the birds, including physical, environmental and climatic stressors, predisposing diseases, dust and ammonia generation, etc. that may compromise the respiratory functions. There is also an opinion amongst some (Toth, 2000; Maina, 2002; Tell, 2005) that birds are more susceptible to aspergillosis than mammalian counterparts due to differences in anatomical, physiological and respiratory immune system characteristics.

Taking into account the fact that mycotic infections (in most cases) are rated among the contagious but not transmissible diseases, and the major source of flock

infection is its surrounding environment and feeds. Therefore, a crucial role in the control of mycoses proves to play the recognition and elimination of the infection source by the disinfection with specific antifungal preparations (Ziółkowska and Tokarzewski, 2006).

MYCOTOXICOSIS

The toxic effect of mycotoxins depends on the toxicity of the mycotoxin, the extent of exposure, age and nutritional status of individuals. (Peraica *et al.*, 1999). In most cases of the present study, the presence of moulds on feed grains had been observed. The fanciers fed the birds on poor quality grains in the economical perspective. Sometimes, very inferior and rejected grains were made available to the birds. The pigeons by part foraged outside their lofts. Besides, the owners had the faulty practice of softening the grains by soaking in water. These practices probably predispose to production of mycotoxins. Although many conditions including temperature, moisture, aeration, substrate characteristics, etc. need to be favourable for toxin production, the presence of moulds on food items may not always imply the presence of toxins (O'Neil *et al.*, 2001). Mycotoxicosis has always been considered a threat to captive birds (Campbell, 1986) and amongst all the demonstrated mycotoxins, aflatoxin B_1 is one of the most potent carcinoges and environmental mutagen (O'Neil *et al.*, 2001). Aflatoxins have been known to cause severe hepatic damage, including fatty degeneration, bile duct hyperplasia and massive necrosis (Schroeder *et al.*, 1972; Intarakamhaeng *et al.*, 2002; Majeed Saleh *et al.*, 2016) as has been amply demonstrated in the present findings. Likewise, literature (Tessari *et al.*, 2006, Majeed Saleh *et al.*, 2016) also supports the observed tubular degenerative lesions in the kidneys. These findings are in agreement with (Hadley *et al.*, 2010) and (Ramirez *et al.*, 1976) who also reported haemorrhages in lungs with emphysematous patches, air sacculitis and sloughing of gizzard lining.

Although the exact exposure of toxins from feed, period of exposure and their accumulation in the tissues would be difficult to work out, however it is presumed that the continued and prolonged access to contaminated feeds may have sufficiently achieved the bio-accumulative lethal dose leading to the fatalities. In experimental studies, moderate to severe toxicosis have been achieved via oral administration of Aflatoxin B1 at a dose rate of 3 mg/kg b.wt. for two consecutive days (Hadley *et al*,

2010). In another experimental study, El Boraay *et al.* (2004) observed that pigeons fed on aflatoxin B1contaminated feed at low levels (100 ppb) for six weeks showed no obvious clinical signs but compromised protective ability against infection, while co-infection with *Salmonella haardt* results in aggravated clinical manifestations and mortalities No literature support was accessible for chronic doses in pigeons.

Mycotoxin analysis in feeds and tissues

Most mycotoxins are usually associated with cereal grains which of course are the main food of pigeons. Each mycotoxin has a different level of what is considered safe, and is based on their toxicity, which in turn establishes minimum acceptable levels which diagnostic labs need to be able to detect. These levels are different for each mycotoxin, and sometimes differ depending on the sample being tested. In most case therefore it would be safe to analyses across a broad range of probable mycotoxins in feeds as in the present case. It is also recommended that the feed grains be routinely screened for the welfare of the birds. While screening for mycotoxins, Aflatoxins and Ochratoxin A should be included in the panel as they are the most common and toxic.

The tissue concentration of mycotoxins in the present study were probably first reports in pigeons. Although, toxicological analysis of the feed and tissue samples have indicated the presence of toxins, their exact prevalence and exposure in the birds could vary because the both samples were pooled. The presence of B1 in both feed and tissues is a concern and indicates that pigeons are susceptible.

Detection of aflatoxin by UV light

For the detection of aflatoxins on agar plates, fluorescence is visualized under UV light (de Vogel *et al.*, 1965; Bennett and Goldblatt, 1973; Hara *et al.*, 1974). This screening method had been modified by Yabe *et al.* (1987) using UV photography, because the absorbance spectra of aflatoxins produced by the moulds show peaks of around 362-nm wavelength (Cole and Cox, 1981). In the UV photographs, aflatoxin-producing strains are observed as grey or black colonies, indicating that these colonies absorbed radiated UV light, while the strains that do not produce aflatoxin form white colonies, indicating that most of the UV light is reflected by the mould mycelium (Yabe *et al.*, 1987). This method is a simple system without tedious extraction and

purification stages and is very safe, because throughout the study moulds under test are fixed on an agar plate and the results can be obtained after a short incubation time.

PARASITIC INFECTION

Pigeons are a cosmopolitan group of birds with abundant parasitic fauna including arthropoda, protozoa and helminths. The parasitological findings seem to validate a fair approximation of the health status of the pigeons. Such a situation may be explained by a number of interrelated factors. For example, suitable climatic conditions from the parasite aspect, and from the host aspect poor sanitation, crowding, low-energy food, interspecific and intraspecific competitions for resources (Al-Barwari and Saeed, 2012). These parasites decrease host survival and breeding success and also affect population dynamics of pigeons (Hudson *et al.,* 1992). The presence of ecto and endoparasitism in pigeons could be attributed to poor and unorganized management and contaminated feed.

Ectoparasites

The pigeon flatfly *P. canariensis* was previously observed on pigeons in this region (Borkataki *et al*, 2015). This louse-like dipteran fly feeds on blood and develops especially in juvenile birds. It also contributes in spreading the obligate blood parasites *Haemoproteus* sp. and *Leucocytozoon* sp. (Bennett *et al.,* 1993; Sol *et al.,* 2000). Furthermore, a number of lice and mites species are believed to have evolved a phoretic association with this particular species of hippoboscid fly (Dranzoa *et al*., 1999). They normally do not feed on these flies but rather may use them for transport from one bird individual to another.

Metazoan endoparasites

With regard to the tapeworms, the present findings suggest the existence of many interspecific similarities for the members of both of the genera *Cotugnia and Raillietina*. This is in agreement with Sawada *et al*. (1990) and Dranzoa *et al*. (1999), the information gathered from the study of ova and gravid proglottids from the host's excrement may be useful but often not sufficient for their definite diagnosis. The identification of a species level among these cestodes is best made by detecting the parasites' strobilae and scolices among the scrapings of the intestinal mucosa and carefully analysing the characteristics revealed by the microscopic inspection. The

present observation would be helpful in providing information relevant to the ecology and life histories of the pigeon tapeworms and very useful in order to investigate systematically their epidemiology and control. Elsewhere, these parasites were shown to have evolved indirect cycles whereby the ova develop into infective larvae (cysticercoids) in the tissues of some invertebrates (McDougald, 2003). The identity of these intermediaries may vary with the tapeworm species but it often comprises one or other of such insects as houseflies and allied dipterans, some hymenopterans such as ants (Nashiruddullah *et al*., 2016), and some beetle species.

Nematode infestation recorded in the present study was mild. Al-Barwari and Saeed (2012) suggests that only those infections that become too severe are dangerously harmful, which are frequently found in disabled, weakened or senile hosts. Both nematode parasites that were identified in this study have a direct life cycle, which means that the ova are passed in faeces and under favourable environmental factors (especially high temperature and adequate humidity) they develop into infective stage. Control of parasitism in such cases becomes favourable with regular deworming schedules.

Protozoan infection

Several health problems can affect pigeons but parasitic infections play a major role. Protozoan blood parasites are common in passerine birds. Protozoal affections in pigeons cause not only economically important changes such as impaired growth, poor food utilization and depigmentation but also produces change in the metabolism and dietary requirement.

Coccidiosis:

The oocysts of *Eimeria* were not only consistently present in most cloacal faecal contents of necropsied birds, but also was common parasitic ova in most faecal examination of pigeons. This has led to summarily conclude that perhaps *Eimeria* sp. is a common and ubiquitous infestation in the pigeon. This has also been amply supported in the literature (Ramisz and Pilaczyk, 2014) and are thought to be commonly transmitted and found in otherwise intact pigeons without gross pathological manifestations of acute gastroenteritis (Koroglu and Simsek, 2001). Their presence in low infection have been thought to be beneficial and may even be

protective by boosting the immune responses against further infections, as is the case with poultry (Kaufmann, 1996; McDougald, 2003). However, when large numbers of mature and sporulated oocysts are ingested, especially by the susceptible and debilitated birds, inevitably profound immunosuppression will have the upper hand which leads to the development of a true coccidiosis (Soulsby, 1982).

The prevalence of coccidiosis amongst pigeons has been variously depicted. On one hand, no oocysts could be detected among the intestinal material of the rock pigeons from Uganda (Dranzoa *et al.*, 1999), whereas infection rates of 77% was observed from India (Parsani *et al.*, 2014), 68.8%, from Cuba (Boado *et al.*, 1992), 63.3%, from Spain (Martinez-Moreno *et al.*, 1989), 25.0% from Italy (Catelli *et al.*, 1999), 24.2% from Yugoslavia (Kulisic, 1988), 21.3% from Iraq (Al-Barwari and Saeed, 2012) and 15.1% from Turkey (Koroglu and Simsek, 2001), all obtained from specimens of the same host. Although speciation was not confirmed in the present study, two coccidian species- *E. labbeana* and *E. columbarum*, have been more often found by these workers. In the domestic pigeon (*Columba livia*), Elisabeth *et al.* (2009) opined that coccidiosis is common pathogenic parasites in young pigeons and reported 5.1%-71.9% prevalence of infection with worldwide mortality varying from 5% to 70% amongst juvenile pigeon, with most death occurring in the third and fourth month of life. The difference in infection rates can be presumed to vary because the observations were made from birds in the wild, whereas in the present study, the birds were confined in lofts where dissemination of the parasite within, and between lofts by visiting birds was possible. Thus, coccidiosis in pigeons reared for sports may prove to be highly endemic, unless regular control measures are not undertaken.

Cryptosporidiosis:

Cryptosporidiosis had been observed as an incidental finding in 5 out of 10 cloacal faecal screening. Cryptosporidiosis is one of the main protozoan infections in birds that manifests as either a respiratory or a digestive illness, and it affects a very large number of avian species across several continents (Nakamura and Meireles, 2015). Ryan (2010) opined that although the oocysts of some species present distinct morphology and morphometry, microscopic analysis does not allow species characterization because small variations exist in these parameters, and in many cases, the oocysts may be identical between different species or genotypes. However, a

presumptive diagnosis of gastric, intestinal or respiratory/ bursal/ cloacal cryptosporidiosis in birds can be accomplished by the presence of ellipsoidal oocysts measuring 7.5-8.5 × 6.0-6.4 µm; spherical, irregularly spherical or slightly elongated oocysts measuring 4.5-6.0 × 4.2-5.3 µm; or ovoid oocysts measuring 6.0-7.5 × 4.8-5.7 µm, respectively (Current *et al*., 1986; Lindsay *et al*., 1989; Ryan, 2010), and since the present observations were morphometrically within the described dimensions, the oocysts were diagnosed as *Cryptosporidium* sp. Although, its detailed pathology was not studied, there are reports of signs characterized by diarrhoea and body weight loss in intestinal cryptosporidiosis observed in young pigeons (Rodriguez *et al.,* 1997). Other signs described include depression, decreased activity, ruffled feathers, and faecal material adhering to vent feathers, and characterized by lesions in the intestinal tract consisting of mild hyperaemic segments distended with typical green watery ingesta with organisms adhered to atrophic and misshapen villi of the small intestine (Özkul and Aydin, 1994). The organisms are demonstrable using the ZN staining. Since the signs and lesions could be misinterpreted with other disease conditions, Özkul and Aydin (1994) suggested that cryptosporidiosis be included when differentiating with disease affections causing diarrhoea, weight loss and death in pigeons, and isolation and specification of *Cryptosporidium* sp. be attempted and reported.

Haemoproteus infection:

The study demonstrated different stages of *Haemoproteus columbae* in the blood of live birds screened, and in the liver and lungs of the necropsied pigeons. Asexual development of the parasite *Haemoproteus columbae* occurs in the peripheral blood of the birds and sexual development in the vector louse fly; *Pseudolynchia canarensis* (Adriano and Cordeiro, 2001; Sá, 2011). The parasites of genera *Haemoproteus*, *Plasmodium*, and *Leucocytozoon* are well-known avian *haematozoa* and can cause declined productivity and high mortality in wild birds (Elahi *et al.*, 2014). Diagnosis of *Haemoproteus* infection is generally accomplished by microscopic examination of a Giemsa-stained peripheral blood smear. Organisms may appear similar to *Plasmodium*, but the pigment within the intra-erythrocytic gametocytes is more dispersed and schizonts are not seen in the peripheral blood smears. These pigment granules (haemozoin) are derived from the digestion of haemoglobin found within the host's erythrocytes and appear as refractile, yellow to

brown granules within the host's erythrocyte (Friend and Franson, 1999). The *Haemoproteus* gametocytes partially encircle the erythrocyte nucleus forming a halter-shape and often occupy over one half of the erythrocyte cytoplasm causing slight enlargement of the infected host cells and displacement of the red blood cell nucleus to one side (Samani *et al*., 2013). These criteria are in agreement with our study where almost mature forms displaced the host nucleus towards one pole, and mature forms occupied the major part of the infected erythrocytes. As *Haemoproteus* infection invades hepatocytes, infection with this genus is sometimes known as pseudomalaria because of its similarities with *Plasmodium* species; however, in case of *Plasmodium* gametocytes are only present within erythrocytes (Gupta *et al.*, 2011). Based on the above morphological characters, the genus of the current study was identified as Haemoproteus (Kruse and Blutparasiten, 1890).

Parasitaemia due the haemoprotozoan *H. columbae* has been recorded previously in rock pigeons approximate infection incidence and intensity of 26.7% from Spain (Martinez-Mareno *et al.*, 1989), 73.0% from South Africa (Earle and Little, 1993), and 76.5% from Uganda (Dranzoa *et al*., 1999). In domestic pigeons approximate infection incidence of 39% and 23% in Iraq (Al-Janabi *et al*., 1980; Zangana, 1982), and 43.2% and 18.8% from Turkey (Gulander *et al*., 2002; Senlik *et al*., 2005), 20% from Bangladesh (Dey *et al.*, 2010) have been reported. Previous reports of the parasite in Jammu region have been estimated at 61.33% (Borkataki *et al*., 2015).

Together with *H. columbae*, co-infection with *Plasmodium* parasites was recorded in rock pigeons of Uganda in 29.4% cases by Dranzoa *et al.* (1999) and co-infection with *Leucocytozoon* sp. parasites in 24% cases in domestic pigeons of Bangladesh by Dey *et al*. (2010). It is opined that these blood parasites are related in many characters and considered by many to be either benign or of mild effect (Earle and Little, 1993; Sol *et al.*, 2000). They are continually circulated around the world and any variations in their prevalence, intensity and health impact, whether sex-related, seasonal-related or spatial-related, might depend on the susceptibility of the host species involved, their ages, habitats, as well as congruence, transmission, density and feeding habits of their vectors (Al-Barwari and Saeed, 2012). Since the incriminated vectors of these parasites are prevalent in this region including a number of mosquitoes of the genera *Culex* and *Aedes* for *Plasmodium*, and flies of the genera

Hippoboscid and *Phlebotomus*, and midges of the genus *Culicoides* for *Haemoproteus* sp., respectively, the possibility of co-infection and prevalence of other haemoprotozoan agents cannot be ruled out.

In contrast to the findings of Earle and Little (1993), male pigeons in this study were found more prone than females to infection by *H. columbae*. On the other hand, Senlik et al. (2005) were unable to detect a significant difference in the infection rate of this parasite in terms of host sexuality, but they found that such an infection was a subject of marked seasonal variation. Several endogenous and exogenous factors may have an accumulative influence on the parasitisation of both sexes of the pigeons by these parasites, such as host's hormones and humoral compounds, age and nutritional state, behaviour and habits, as well as the season of the year and ecological and physical features of the regions (Al-Barwari and Saeed, 2012).

In the current study, the parasitic forms encountered in tissues have been identified as those of *Haemoproteus columbae* from the circumstantial demonstration of numerous gametocytes in the peripheral blood of infected pigeons. In the liver and the lungs, the endothelium of the blood vessels was the main target of the parasite. In cases of high infection, round cell granuloma and massive destruction of the parenchyma of these organs occurred leading to sever illness or even death of the pigeons as has been reported by Hussein and Abdelrahim (2016).

The observed *Haemoproteus* schizonts in the studied tissues were thin walled and irregular in shape resembling the schizont morphology of *Haemoproteus* species described by others (Mubarak and Abed, 2005; Archawaranon and Subinprasert, 2005; Hussein and Abdelrahim, 2016). In the present study, the histopathological changes observed may have been due to the tissue reaction against merozoites or invading schizonts into the parenchyma, as evident from extravascular cellular reaction and erosion of pulmonary, hepatic sinusoids and portal blood vessels. This has been consistent to findings by earlier workers (Dey *et al*, 2010; Mubarak and Abed, 2005; Hussein and Abdelrahim, 2016)

In the liver, in addition to erosion of its blood vessels by schizont invasion, infiltration by round inflammatory cells and formation of round cell granuloma especially around the portal areas were the most prominent findings as has been

observed by earlier workers (Mubarak and Abed, 2005; Hussein and Abdelrahim, 2016).

The findings of various parasitic developmental stages of *Haemoproteus*, including exo-erythrocytic stages (schizonts, merozoites) and erythrocytic stages (gametocytes) in the examined pulmonary and hepatic tissues, establishes them as primary target organs of *Haemoproteus* sporozoites and a major site of schizogony.

Haematological parameters:

A significant variation ($p<0.05$) was observed in Hb, PCV and eosinophils between *Haemoproteus* sp. infected and non-infected pigeons. This variation in blood profile (PCV, Hb and eosinophils) could be attributed to high parasitic load and may contribute to the development of anaemia. The findings of this study clearly show that infection with *Haemoproteus columbae* in pigeons may promote the development of anaemia as evident by the significant fall in PCV and haemoglobin values. Similar results were observed by Razavi *et al*. (2016). Besides, the degree of tissue parasitism in the infected birds may be the cause of eosinophilia. Al-Bayati (2011) similarly reports significant decrease in PCV, TEC and Hb concentration, a non-significant leucocytosis with eosinophilia in cestode infected pigeons. Bahrami *et al*. (2013) observed that the PCV, WBC, MCV, MCH, neutrophil and lymphocyte values of the pigeons were significantly ($p<0.05$) different in gastrointestinal parasitism between infected and non-infected birds. There also seems to be sex variations in haematological parameters with a significant ($p<0.05$) decrease in PCV, WBC, MCV values between male and female pigeons (Opara *et al.*, 2012).

Seasonal prevalence of endoparasites based on faecal examination

During the study period, pooled faecal samples examined revealed presence of different parasitic ova with variable prevalence in the four recognized seasons. Ascarid eggs were least prevalent whereas prevalence of *Eimeria* sp. was highest amongst all parasitic eggs and had a particular higher prevalence in the winter season. The highest prevalence of coccidian parasites in winter season could be attributed to close confinement of pigeons and favourable temperature for proliferation and sporulation. Similar opinion was forwarded by Sivajothi *et al.* (2015). The infection intensity and egg count are dependent on various factors related the environment

(Richard and Zimmerman, 1992; Vincente *et al*., 2005), season (Shaw and Moss, 1989; Theodoropoulos *et al*., 1998; Kumba *et al*., 2003), phase of the parasitic infection (Giver *et al*., 2000), and even hour of sampling (Villanúa *et al*., 2006).

Although, identification of parasites is difficult based on egg morphology alone, correlation with necropsy retrieval of select specimens aided in their generic classification. In certain cases, some eggs could not be identified. The data generated may be helpful in at least estimating the faunistic prevalence of different parasites and also help in the strategic management of parasitic load during various seasons.

SUMMARY AND CONCLUSION

In the present study, a total of approximately 3980 domestic pigeons belonging to various pigeon fanciers were screened for clinical cases of disease affection. The birds were reared by their owners for the purpose of pigeon racing and sports activities. A total of twelve areas were selected for the survey, out of which ten were in the RS Pura sector and two were within the Jammu city limits. The areas near RS Pura sector were very near to the International Indo-Pakistan border (ranging approximately between 1-10 km in distance), and birds were often found to fly across each country.

Out of the population of pigeons observed, a total of 608 birds were found to be clinically affected with some form of clinical disease or other, based on flock history, clinical examination and laboratory investigation. The overall estimate of disease prevalence amongst pigeons was observed at 15.28%, with the highest prevalence in Banota area and least in Ranbir Singh Pura town area.

Dead birds were collected for detailed necropsy examination in the laboratory. Reported mortality by owners was not accounted for, as the data was very arbitrary and vague. Mortality was accounted only for birds that were accessed for necropsy examination. A total of sixty pigeons were necropsied in the Division of Veterinary Pathology from July 2015-June 2016. Out of the total estimated population of birds surveyed, the overall mortality accounted through necropsy examination is 1.51% (60 of 3980 birds).

The predominant cause of death as diagnosed by necropsy examination and confirmed by laboratory methods was due to protozoal hepatitis and pneumonia accounting to 45.00% mortality, followed by Newcastle disease (20.00%) and mycotoxicosis (13.33%). These three causes accounted for approximately 78.00% mortality amongst the birds.

Clinical signs and symptoms observed in Newcastle disease (ND) infection were predominantly neurological and included depression, mild to severe tremors, torticollis, and incoordination, unilateral or bilateral paresis with paralysis of wings or limbs, head pressing, circling and terminal coma. Necropsy examination of twelve birds (20.00%; 12/60) variously showed petechial haemorrhages on proventricular

mucosa particularly at the junction with the gizzard with ulcerations, serosa and mucosa of the ventriculus, on the crop, including catarrhal to haemorrhagic enteritis, congestion and haemorrhages on the trachea and lungs, pancreas, epicardium, congestion of meninges and brain. Ulceration was also visible on the crop, gizzard and intestines. Microscopically, congestion, oedema, haemorrhage in trachea and lungs were seen. In the nervous system, non-suppurative encephalitis was observed in all cases affected with neuronal signs. The predominant microscopic lesion was congestion and haemorrhages with extensive malacia and demyelination. Satellotosis, microgliosis and gitter cell infiltration were also seen. Serum samples collected from 10 out of 12 affected pigeons were found positive by haemagglutination inhibition test by detection of high titres (1/32 to 1/64) of circulating antibodies. Based on history of typical signs and post-mortem lesions, and HA and HI assay, a confirmatory diagnosis for Newcastle disease was made.

Pigeon pox (3.33%; 2/60) was easily recognizable with scabby lesions were found on the unfeathered parts of the body especially the beak and eyelids in the cutaneous form of the disease amongst many pigeons. Two mortalities amongst young birds were observed with both cutaneous and a severe diptheritic form of the disease. Grossly, on the mucous membrane of the mouth and oesophagus, a yellow, cheesy, necrotic and diphtheric membrane was observed. Histological changes found in the skin surrounding the cutaneous lesions consisted of varying degrees of proliferative epithelium under a crust consisting of keratin and proteinaceous fluid debris and surface bacteria was present in most lesions. The typical lesion was characterized by ballooning degeneration of keratinocytes containing pale vacuolated cytoplasm contained eosinophilic A-type intracytoplasmatic inclusions with central unstained zones distending the cytoplasm. Isolation of *Pigeon pox* virus attempted on 14th day developing chicken embryo revealed pock lesions on the chorioallantoic membrane (CAM) characterized by small white raised foci.

Colibacillosis (1.67%; 1/60) was diagnosed in one pigeon that had died due to severe diarrhoea had gross lesions showing severe enteritis with presence of petechial haemorrhages on the intestinal mucosa, including petechiae on the pancreatic surface. Air sacs were thickened and cloudy and the lungs were severely congested. Fibrinous pericarditis was also seen. All visceral organs were congested. Liver was enlarged with mild fibrinous deposits on the surface and microscopically showed degeneration

with occasional dilatation of hepatic sinusoids. Fatty changes and cellular swelling with extensive engorgement and disintegration of sinusoids also observed. Focal heterophlic infiltrationwas seen in the liver parenchyma. Liver impression smears and microbial culture from heart blood and liver revealed typical Gram '–ve' bacilli. Based on culture, morphological characteristics and biochemical confirmation, the organisms were identified as *Escherichia coli.*

A pigeon died due to salmonellosis (1.67%; 1/60) with severe diarrhoea, weight loss, anorexia and emaciation, weakness, lameness and considerable dyspnoea. Necropsy examination revealed pneumonia and severe congestion of lungs, catarrhal and haemorrhagic enteritis. The air-sacs appeared cloudy and milfd fibrinous pericarditis was apparent. Liver was congested with grey-white focal areas of degeneration. The ovaries appeared small, misshapen and haemorrhagic and associated with catarrhal salphingitis. Degenerative foci were also visible on the kidneys. Microscopically, severe congestion and haemorrhages caused disruption of hepatic parenchyma and distortion of hepatocytes and sinusoids. Liver impression smears and microbial isolation from the heart blood and liver showed Gram –ve bacillus. Confirmation was made after culture, biochemical tests and morphological characteristics confirmed the isolates as *Salmonella* sp.

In an outbreak of aspergillosis (8.33%; 5/60) affecting both young and old pigeons in one loft, clinical signs discernible were gasping and accelerated breathing, inappetance, emaciation, depression, rattling, dyskinesia and considerable mortality particularly in young birds. Post-mortem examination revealed that aspergillosis caused both pulmonary and systemic affections. In severe cases the lungs revealed a granulomatous pneumonia with white to yellowish opaque raised plaques. Air sacs were cloudy and thickened often showing plaque-like yellowish nodules. In a very severe form of pulmonary affection, sporulated forms of the fungal organism, appearing as a dark greenish-greyish growth with white tufts of mycelium were observed. Microscopically, a lymphohistiocytic granulomatous pneumonia was observed. Granulomas had a necrotic centre containing inflammatory and cellular debris and surrounded by epitheloid macrophages and lymphocytes, and fibrous tissue proliferation at the periphery of the nodules. Sporulation was seen in the bronchial mucosa and lumen of the airways. Long branching septate fungal elements were readily discernible with Grocott's methenamine silver stain**,** and were found to be

indistinguishable from *Aspergillus fumigatus*. Impression smears from the mouldy growth stained with lactophenol cotton-blue revealed characteristic conidial heads radiating in columns. Tracheal and lung swabs from affected birds collected and grown on Potato dextrose agar (PDA) revealed fungal growth typical of *Aspergillus fumigatus*.

Two outbreaks of mycotoxicosis (13.33%; 8/60) were suspected amongst pigeons, showing non-specific clinical signs such as emaciation, anorexia and greenish diarrhoea. The birds appeared unthrifty with considerable mortality reported by the owners. Necropsy examination of eight pigeons from these two lofts revealed consistent yellow-greenish discoloration of the liver with visible fatty change and multiple haemorrhages in the parenchyma. Concurrently, renal degeneration and haemorrhages were also sometimes observed. Affected kidneys were pale and enlarged and together with the ureters showed distinct urate deposits. Microscopic examination revealed cytoplasmic vacuolation of the hepatocytes indicating fatty change. In some instances there was proliferation of the bile ducts with mild infiltration by heterophils in the triad areas. In the kidneys, tubular epithelial degeneration and necrosis was observed. In the collecting tubules prominent casts were seen. Feed grains were screened for mouldy growth and successfully cultured for *Aspergillus flavus*. Aflatoxin B1 was found in both feed and tissue samples while as citrinin and ochratoxin was also found in feed samples. Feed samples were also demonstrated to contain aflatoxins by UV light.

Four birds were found to have died due to fatal traumatic (6.67%; 4/60) and haemorrhagic injury caused by infighting and preyed on by raptors.

Haemoproteosis (45.00%; 27/60) caused a severe disease outbreak with high mortality amongst pigeons. Clinically, signs of severe respiratory distress, anorexia, and malaise, loss in body weight, dehydration, stupor and heavy mortality were noticed. Necropsy revealed severe and consistent hepatic and pneumonic lesions. The liver appeared congested, with miliary pinpoint grey–white foci throughout the parenchyma. Hydropericardium was noticed in three birds. Lungs were sometimes haemorrhagic or severely congested and consolidated. The spleen was enlarged and the kidneys were pale with visible distension by urates. Microscopically, lung tissue of the infected pigeons revealed various stages of protozoan parasite development.

Severe congestion and consolidation of lung tissue with presence of schizonts detected within the endothelial lining that invaded the lung parenchyma into the alveoli destroying their wall and interstitium. Areas of complete destruction of the lung parenchyma or marked dilatation of the pulmonary alveoli with lacking of their endothelium were observed. There was severe infiltration by mononuclear cells in the interstitium. Typical round cell granuloma could be seen around blood vessels. Liver showed multifocal and coalescing lesions of subacute hepatic necrosis with marked infiltrates of macrophages, lymphocytes, fewer plasma cells and scanty heterophils concentrated around the perivascular spaces around protozoal stages in the portal area, sinusoids and central vein around parasitic schizonts. The predominantly infiltrative round cell was characteristic. In some cases fragmented and round forms of cellular debris was observed, which were indistinguishable from apoptotic bodies.

Both live and dead pigeons were examined externally revealed numerous ectoparasites including lice, flies, mites from skin scrapings and mosquitoes in the lofts. As many as six species of ectoparasites were collected from the pigeons or their lofts. Four of them were insects, two belonging to Mallophaga, namely, the wing and tail feather chewing lice *Columbicola columbae* and the small pigeon louse *Campanulotes bidentatus*; one belonging to Diptera, namely, the pigeon flatfly or louse fly *Pseudolynchia canariensis*, and one belonging to Siphenoptera, tentatively identified as *Ctenocephalides* sp. Besides, there were many mosquito and fly species which were not identified. The other ectoparasite found belonged to Arachnida, comprising Acarina, namely, *Psoroptes* sp.

A total of 60 gastrointestinal tracts (GIT) of pigeons were examined of which 22 (36.67%) were found infected with parasites in different parts of GIT. The tapeworm *Raillietina* sp. (25%; 15/60) belonged to the family Davaineidae, and was mostly recovered from the ileal part of the small intestine. Two species of nematode parasites were found in this study. They comprise of the large roundworm *Ascaridia* sp. (5%; 3/60) and the hairworm *Capillaria* sp. (6.67%; 4/60) both found to inhabit the small intestine.

Coccidian (58.3%; 35/60), cryptosporidian parasites (50.0%; 5/10) and haemoprotozoal schizogony tissue stages (45.0%; 27/60) were detected in cloacal and tissue samples from post-mortem materials, while clinical blood samples were

collected to identify gametocytes of haemoprotozoa (26.6%; 8/30). Different *Eimeria* sp. with sporulation time varying from 7-10 days was detected. *Cryptosporodium* sp. oocysts appeared as spherical, irregularly spherical or slightly elongated measuring from approximately 4-6 µm in diameter. Haemoprotozoan gametocytes were detected in the blood smears of sick or apparently normal birds within RBCs, where the intra-corpuscular gametocytes were elongated and crescent shaped. Mature macrogametocytes, microgametocytes, immature stages and even extra-corpuscular stages were detected in the blood. Blood collected for screening of haemoprotozoan parasites from apparently healthy and sick pigeons were also subjected to evaluation of haematological profile. A significant decrease ($p<0.05$) was observed in Hb, PCV and increase in eosinophils between *Haemoproteus* infected and non-infected pigeons.

Twenty-four pooled faecal samples examined from six select villages of Jammu district in the four recognized seasons revealed presence of different parasitic ova. The results showed that Ascarid eggs were least prevalent whereas, prevalence of *Eimeria* sp. was highest amongst all parasitic eggs and had a particular higher prevalence in the winter season. Besides, *Ascaridia* eggs were not consistently seen, and its occurrence was sporadic with a particular prevalence in the monsoon and post monsoon period. *Capillaria* eggs were relatively abundant with no particular seasonal prevalence. *Eimeria* sp. was consistently present in faecal samplings. Cestodiasis with *Raellietina* sp. was the most common metazoan enteric infestation but its observed prevalence apparently was lowered in the peak summers.

From the present study it can be concluded that-

i) Pigeons are susceptible to various disease conditions and may harbor many infectious agents that can be disseminated in the environment and spread disease to susceptible hosts, including zoonotic agents.

ii) The pigeons in this region fly freely between political borders and are potential carriers of Trans boundary disease agents.

iii) Hamoproteosis although mild and asymptomatic, may cause severe fatalities when the parasites under schizogony in the tissues. Lungs and liver are the primary target organs of parasitic development with extensive vascular and

tissue reaction. Control of the parasite can be managed by checking the vector *Pseudolynchia canarensis* or yet undiscovered arthropod agents.

iv) Newcastle disease is very common and endemic in pigeons and because the poultry strain is related, genetic re-assortment of strains may cause the evolution of virulent strains to which both domestic poultry and pigeons are unprotected. The pigeon should always be treated as a carrier agent harbouring the paramyxovirus. Vaccination with pigeon paramyxovirus strains is recommended.

v) Prevalence of aspergillosis reflects the poor management and hygiene in rearing the birds. Likewise, colibacillosis and salmonellosis signify poor management. Other fungal agents like histoplasmosis in the birds and the surroundings are dangerous for humans with the potential to cause severe allergies or the common ‘Pigeon fancier’s lung disease’.

vi) Mycotoxicosis is prevalent in the resident pigeons and is a local problem and reflects poor management by the owners due to feeding of poor quality feed grains.

vii) Pigeonpox is a host specific disease confined to pigeons alone and does not have any remedy. The disease is self-limiting, but diptheritic form particularly in young birds may prove fatal.

viii) Parasites prevalent in the pigeon are manageable with regular deworming and control of vectors such as in cestodiasis.

BIBLIOGRAPHY

Abdul, A.; Abed, A.; Naji, H.A. and Rhyaf, A.G. (2014). Investigation study of some parasites infected domestic pigeon (*Columba livia domestica*) in Al-Dewaniya city. *IOSR Journal of Pharmacy and Biological Science.* 9(4): 13-20.

Abreu-Acosta, N.; Foronda-Rodríguez, P.; López, M. and Valladares, B. (2009). Occurrence of *Cryptosporidium hominis* in pigeons (*Columba livia*). Stefañski Institute of Parasitology, PAS Acta Parasitologica, 54(1): 1–5.

Adriano, E.A. and Cordeiro, N.S. (2001). Prevalence and intensity of *Haemoproteus columbae* in three species of wild doves from Brazil. Mem. Inst. Oswaldo. Cruz., 96: 175-178.

Adang, K.L.; Oniye SJ.; Ezealor, A.U.; Abdand, PA. and Ajanusi, O.J.(2008) Ectoparasite of domasticated Pigeon (Columba livia domestica), Research Journal of Parasitology, 3: 79-84.

Al-Barwari, S. and Saeed, I. (2012). The parasitic communities of the rock pigeon *Columba livia* from Iraq: component and importance. *Turkiye Parazitol. Derg*. 36: 232-239.

Al-Bayati, N.Y. (2011). A study on pigeons (*Columba livia*) cestodes infection. Diyal Agricultural Science Journal, 3(2): 1-12.

Alexander, Dennis J,(2011): Newcastle disease in the European Union 2000 to 2009. *Avian Pathology* 40(6), 547_558.

Al-Janabi, B.M.; Al-Sadi, H.I. and Hayatee, Z.G. (1980). Some parasites of pigeons from Mosul province. J Coll Vet Med., 1: 15-26.

Antonissen, G..; Haesendonck, R..; Devreese, M.; Broekaert, N.; Verbrugghe, E. and De Saeger, S. (2016). The Impact of Deoxynivalenol on Pigeon Health: Occurrence in Feed, Toxicokinetics and Interaction with Salmonellosis, *Plos One*. 11(12): 1-14.

Archawaranon M. and Subinprasert S. (2005). Bird-parasite relations: A hill mynah case study, Journal of Entomology, 2: 112-116.

Atasever, A. & Gu¨mu¨ssoy, K.S. (2004). Pathological, clinical and mycological findings in experimental aspergillosis infections of starlings. *Journal of Veterinary Medicine. A, Physiology, Pathology Clinical Medicine,* 51, 19_22.

Bahrami, A. M. Monfared, A. L., Razmjoo, Mo., (2012) Pathological study of parasitism in racing pigeons : An indication of its effects on community health. *African Journal of Biotechnology* 11 (59):12364-12370.

Bahrami, A. M.; Razmjoo, M.; Hafaziahmadi, M. R.; Louei, M. A. and Hosseini E. (2013). Histo-pathological effects of different arthropoda, oocyste and worms infestation on the wild pigeon. *European Journal of Experimental Biology*. 3(1):411-416.

Bahrami, A.; Omran, A. N.; Asbchin, S. A., Doosti, A., and Monfared, A. L., (2011): Survey of egg per gram (EPG) parasite ovum in pigeon*International Journal of Molecular and Clinical Microbiology* 1:103-106.

Bahrami, A.M.; Hosseini, E. and Razmjo, M. (2013). Important parasite in pigeon, its hematological parameter and pathology of intestine. World Applied Sciences Journal 21(9): 1361-1365.

Balicka, R. A.; Tomza, M, B.; Pilarczyk, M.; Wieczorek-Dabrowska and Bakowska, M. (2007). Intestinal parasites of parrots, *Wiad Parazytol*. 53(2):129-32.

Bandyopaadhyay, P.K; Bhakta, J.N. and Shukla, R. (2006). A new *eimeria* species (protozoa: apicomplexa: sporozoea) from the blue rock pigeon *columba livia* (aves: columbidae). *Zoos' Print Journal* 21(9): 2386-2387.

Barton, J.T.; Bicford, G.T.; Cooper, B.R.; Carlton and Cardona, C.J. (1992). Avian paramyxovirus type-1 infection in racing pigeons in California. Clinical signs, pathology and serology. *Avian Disease*. 36: 463-468.

Beernaert, L.A.; Pasmans, F.; Van Waeyenberghe, L.; Haesebrouck, F. and Martel, A. (2010). Aspergillus infections in birds: a review, *Avian Pathology*, 39(5): 325-331,

Bennett, G.F.; Peirce, M.A. and Ashford, R.W. (1993). Avian haematozoa: Mortality and pathogenicity. J Nat Hist., 27: 993-1001.

Bennett, J. W. and Goldblatt, L.A. (1973). The isolation of mutants of *Aspergillius flavus* and *A. parasiticis* with altered aflatoxin producing ability. Sabouraudia, 11: 235-241.

Bhaiyat, M.I.; Ochiai, K.; Itakura, C.; Islam, M.A. and Kida, H. (1994). Brain lesions in young broiler chickens naturally infected with a mesogenic strain of Newcastle disease virus, *Avian Pathology*, 23:4, 693-708.

Boado, E.; Zaldivar, L. and Gonzalez, A. (1992). Diagnosis, report and incidence of diseases of the pigeon (*Columba livia*) in Cuba. Rev Cubane Cien Avicola, 19: 74-8.

Bolte, A.L.; Meurer, J. and Kaleta, E.F. (1999). Avian host spectrum of avipoxviruses, *Avian Pathology*, 28(5): 415-432.

Borghare, A. T.; Bagde, V. P.; Jaulkar, A. D.; Katre, D. D.; Jumde, P. D.; Maske, D. K and Bhangale, G. N. (2009). Incidence of Gastrointestinal parasitism of Captive Wild Pigeons at Nagpur. *Veterinary World*. 2(9):343.

Borkataki, S.; Katoch, R.; Goswami, P.; Godara, R.; Khajuria, J.K.; Yadav, A.; Kour, R. and Mir, I. (2015). Incidence of *Haemoproteus columbae* in pigeons of Jammu district. J Parasit Dis., 39(3): 426-428.

Bwala, D. G; Fasina, F. O; and Duncan, N. M, (2015). Avian poxvirus in a free-range juvenile speckled (rock) pigeon (*Columba guinea*)', *Journal of the South African Veterinary Association* 86(1):1259.

Cacciuttolo, E.; Rossi, G.; Nardoni, S., Legrottaglie, R. and Mani, P. (2009). Anatomopathological aspects of avian aspergillosis. *Veterinary Research Communications*, 33, 521-527.

Campbell, T.W. (1986). SEleceted blood biochemicall tess used to detect the presence of hepatic disease in birds. Proceedings Annual Conference Association of Avian Veterinarians. Pp. 43-51.

Carrasco, T.; Oliveira, A.; Christina, M; Lucas, J.; Ikeda, P; and Augusto, A. (2015): Experimental infection with Brazilian Newcastle disease virus strain in pigeons and chickens. *Brazilian Journal of Microbiology*. 4 7. 231–242.

Catelli, E.; Poglayen, G.; Terregino, C.; Orlando, C.; Tonelli, A. and Issa-Gadale, O. (1999). Survey of endoparasites of the digestive tract of *Columba livia* (Gmelin, 1789) in Florence. Selez Vet., 2: 75-85.

Cheville, N.F. and Arp, L.H. (1978). Comparative pathological findings of *E. coli* infection in birds. *Journal of American Veterinary Medical Association*, 173: 584-587.

Cole, R.J. and Cox, R.H. (1981). Handbook of toxic fungal metabolites. Academic Press, Inc., New York.

Cooper, J. E. (1984) A veterinary approach to pigeons. *Journal of Small Animal Practace* 25(5): 505-516.

Cruickshank, R; Duguid, J.P.; Marmon, B.P. and Swani, R.H.A. (1975). Medical Microbiology, Vol.II (12th edition). Churchill, Livingstone, Edinburgh, London, New York.

Current, W.L.; Upton, S.J. and Haynes, T.B. (1986). The life cycle of *Cryptosporidium baileyi* n. sp. (Apicomplexa, Cryptosporidiidae) infecting chickens. *J Protozool.*, 33(2): 289-296.

Dandapat, D.K.; Mukhopadhayay, S.K.; Ganguly, S.; Dhanalakshmi, S and Kar, I. (2012): Diseases of pigeon in and around Kolkata, India. *Journal of Parasitic Diseases*, 36(1): 99–100.

Darzi, M.M.; Mir, M.S.; Nashiruddullah, N. and Kamil, S.A. (2006). Nocardiosis in domestic pigeons (*Columba livia*). *Veterinary Record*, 158: 834-836.

de Vogel, P.; van Rhee, R. and Koelensmid. W.A.A.B. (1965). A rapid screening test for aflatoxin-synthesizing aspergilli of the *flavus-orylae* group. J. Bacteriol., 28: 213-220.

Dey, A. R; Begum, N; Paul, S. C; Noor, M; and Islam, K. M, (2010) prevalence and pathology of blood protozoa in pigeons reaered at Mymensingh district, Bangladesh. *International Journal of Biology Research*. 2 (12): 25-29.

Doneley Bob, BVSc, FACVSc (2006) (Avian Health) West Toowoomba Vet Surgery Toowoomba, Queensland, Australia: *The North American Veterinary Conference*

Doosti, A.; Ahmadi, R.; Mohammadalipour, Z andZohoor, A. (2014). Detection of Haemoproteus columbae in Iranian pigeons using PCR. International Conference on Biological, Civil and Environmental Engineering. 17-18.

Dranzoa, C.; Ocaido, M. and Katete, P. (1999). The ecto-, gastro-intestinal and haemo parasites of live pigeons (*Columba livia*) in Kampala, Uganda. *Avian Pathology*, 28: 119-124.

Dutta, P.; Borah, M.K.; Sarmah, R. and Gangil, R. (2013a). Isolation, histopathology and antibiogram of *Escherichia coli* from pigeons (*Columba livia*). *Veterinary World*, 91-94.

Dutta, P.; Borah, M.K.; Sarmah, R. and Gangil, R. (2013b). Isolation of *Salmonella* Typhimurium from pigeons (*Columba livia*) in Greater Guwahati, its histopathological impact and antibiogram. *Comparative Clinical Pathology*, 22: 147–150.

Earle, R.A. and Little, R.M. (1993). Haematozoa of feral rock doves and rock pigeons in mixed flocks. S Afr J Wildl Res., 23: 98-100.

Ecco, R.; Susta, L.; Afonso, C.L.; Miller, P.J. and Brown, C. (2011). Neurological lesions in chickens experimentally infected with virulent Newcastle disease virus isolates.*Avian Pathology*. 40(2): 145-152.

Eisa, M. and E. A. Omer, 1984. A natural outbreak of Newcastle disease in pigeons in Sudan. *Veterinary Rec*, 114: 297.

El Boraay, I.M.; Saad, A.E. and Eman, A.H. (2004). Interaction of aflatoxin B1 and/or *Salmonella haardt* on immunized pigeons by locally prepared

inactivated pigeon paramyxovirus type-1 (pPMV-1) vaccine. Benha Vet. Med. J., 15(2): 159-171.

Elahi R., Islam A., Hossain M. S., Mohiuddin K., Mikolon A., Paul S. K., Hosseini P. R., Daszak P., and Alam m. S. (2014). Prevalence and Diversity of Avian Haematozoan Parasites in Wetlands of Bangladesh, Hindawi Publishing Corporation, J. Parasit. Res., Article ID 493754, 12 pages.

Elaph, M. F; Al-rubaie, and Haidar M .A, (2012) Study the Prevalence of Pigeon Coccidiosis in Baghdad City.*The Iraqi Journal of Veterinary Medicine; 37(1): 106 – 108.*

Elisabeth, M.; Junghanns, K.; Zebisch, R. and Schmid, V. (2009). Prevalence and treatment of coccidiosis in domestic pigeon (*Columba livia*) with particular emphasis on Tortazuril. *Journal of Avian Medicine and Surgery*, 23(1): 15.

El-Mubarak, A. K.A.; Elzein, A. I. A.; Elgasim, E. M. E.; Abu Elzein and Elgasim. (1990). Note on the pathology of experimental infection of pigeons by the pigeon paramyxovirus type-1 (PPMV-1). Revue-d'Elevage-et-de-Med. *Veterinary Des-Pays-Tropica*, 43: 441-444

Faddoul, G. P., and G. W. Fellows. 1965. Clinical manifestations of paratyphoid infection in pigeons. *Avian Disease*. 9:377-381.

Fagbohun, O. A.; Oluwayelu, D. O.; Owoade, A .A and Olayemi, F. O. (2000). **S**urvey for antibodies to newcastle disease virus in cattle egrets, pigeons and nigerian laughing doves. *African Journal of Biomedical Research. 3; 193-194.*

Fallavena, L.C.B.; Rodrigues, N.C.; Scheufler, W.; Martins, N.R.S.; Braga, A.C.; Salle, C.T.P. and Moraes, H.L.S. (1993). Atypical fowlpox in broiler chickens in southern Brazil. *The Veterinary Record*, 132, 635.

Fedde, M.R. (1998). Relationship of structure and function of the avian respiratory system to disease susceptibility. *Poultry Science*, 77. 1130-1138.

Femenia, F., Fontaine, J., Lair-Fulleringer, S., Berkova, N., Huet, D., Towanou, N., et al. (2007). Clinical, mycological and pathological findings in turkeys

experimentally infected by Aspergillus fumigatus. *Avian Pathology*, 36, 213_219.

Fischer, E., 1986. Pathology of spontaneous paramyxovirus-1 infection in pigeons. Inaugural- Dissertation Fachbereich Veterinarmedizin Justus- Liebig-Universitat, Giessen, German Federal Republic, pp: 84 (Poult. Abst., 13: 1917, 1987).

Friend M., Franson J. (1999). Parasitic diseases, In: Field manual of wildlife diseases: general field procedures and diseases of birds, US Geological Survey, Reston, pp 193–262.

Geetha, M.; Gunaseelan, L.; Ganesan, P.I.; Kumanan, K. and Selvaraju, G. (2014). Role of free living birds as reservoirs of Newcastle disease virus infection. *International Journal of Science, Environment and Technology*, 3(4): 1450-1454.

Ghosh, K. K.; Islam, M. S.; Sikder, S.; Das, S.; Chowdhury, S and Alim, M. A. (2014) Research Article Prevalence of Ecto and Gastrointestinal Parasitic Infections of Pigeon at Chittagong Metropolitan Area Bangladash. *The Journal Of Advance In Parasitology.* 1 (1): 9-11.

Gorta´zar, C.; Milla´n, J.; Ho¨fle, U.; Buenestado, F.J.; Villafuerte, R. and Kaleta, E.F. (2002). Pathology of avian pox in wild red-legged partridges (Alectoris rufa) in Spain. *Annals of New York Academy of Sciences*, 96(9), 354_357.

Gulander A, Tuzer E, Cetinkaya H. (2002). Haemoproteus columbae infections and *Pseudolynchia canariensis* infestations in pigeons in Istanbul, Turkey. Istanbul Univ Vet Fak Derg Istanbul., 28: 227-229.

Gupta D. K., Jahan N., Gupta N. (2011). New records of Haemoproteus and Plasmodium (Sporozoa:Haemosporida) of rock pigeon (Columba livia) in India, J. Parasit. Dis., 35(2),155–168.

Gurumurthy, V. and Rao, P.P. (1962). Colibacillosis in brooder chicks. *Indian Veterinary Journal*, 39: 66-69.

Haag-Wackernagel, D. (1998): Die Taube. Vomheiligen Vogel der Liebesgöttinzur Strassentaube. Verlag Schwabe & Co. AG, Basel.

Hadley, T.L.; Grizzle, J.; Rotstein, D.S.; Perrin, S.; Gerhardt, L.E.; Beam, J.D.; Saxton, A.M.; Jones, M.P. and Daniel, G.B. (2010). Determination of an Oral Aflatoxin Dose That Acutely Impairs Hepatic Function in Domestic Pigeons (*Columba livia*). *Journal of Avian Medicine and Surgery*, 24(3): 210-221.

Hara, S.; Fennell, D.I. and Hesseltine. C.W. (1974). Aflatoxin producing strains of *Aspergillus flavus* detected by fluorescence of agar medium under ultraviolet light. Appl. Microbiol., 27: 1118-1123.

Harlin, R.W. (1994) Pigeons the veterinary clinics of North Amirica. Journal of Small Animal Practice, 44 pp 157-173.

Hesseltine, C.W. and Shotwell, O. (1973). New methods for rapid detection of aflatoxin.*Pure and Applied Chemistry*, 35(3): 259-266.

Hr, Parsan.i; Rr, Momin and Lateef, A. S. (2014) Gastro-intestinal helminths of pigeons (*Columba livia*) in Gujarat , India *Egyptain Journal of Biology*, 16: 63-71.

Hudson, P.J., Newborn, D. &Dobson A.P., (1992). Regulation and stability of free-living host-parasite system. *Trichostrongylustenuis* in red grouse. Monitoring and parasite reduction experiments. *The Journal of Animal Ecology,61*, 477-486.

Hussein, N.M. and Abdelrahim, E.A. (2016). *Haemoproteus Columbae* infection and its phistopathological effects on Pigeons in Qena Governorate, Egypt. IOSR Journal of Pharmacy and Biological Sciences (IOSR-JPBS), 11(1): 79-90.

Intarakamhaeng, M.; Sodsee, P.; Mendech, P.; (2002). Histochemistry and Histoenzymatic studies of liver after a single oral dose of aflatoxin B1 in broiler chicks. *Thai Journal Veterinary Medicine*. 32: 35-44

Jain, N.C. (1986). Schalm's Veterinary Haematology. 4th Edition. N.C Jain (Editor), Lea and Febiger, Phidadelphia. Pp. 1221.

Jamrika, J and Modry D., (2012): A New Species of *Eimeria Schneider*, 1875 (Apicomplexa: Eimeriidae) from the Common Wood Pigeon *Columba palumbus* Linnaeus, 1758 (Aves: *Columbidae*). *Acta Protozool*, 5(1): 329–333.

Johnson, B.J. and Castro, A.E. (1986). Canary pox causing high mortality in an aviary. *Journal of American Veterinarian Medical Association, 189*, 1345–1347.

Jones, T.C. and Gleiser, C.A. (1954): Veterinary Necropsy Procedure. J.B. Lippincott Company, Philadelphia.

Kabir, L.; Haque, E and Borty, S. C. (2015) Isolation and Molecular detection of fowl pox and pigeon pox viruses from recent outbreak in Bangladesh, *Indian Journal of Life Science.* 5(1): 1-7, 2015

Kaufmann, J. (1996). Parasitic Infections of Domestic Animals: A Diagnostic Manual. Berlin: Birkhauser Verlag1996.

Kaura, Y.K.; Bharagava, D.N.; Purtha, A.K. and Prasad, S. (1988). Pathology and isolation of multiple antibiotic resistant strains of *E. coli* from an outbreak of colibacillosis in turkey poults. *Indian Veterinary Journal*, 23: 9-13.

Khan, M. A., (1968). Epizootiology of Newcastle disease in wild birds. MSc. Thesis, Deptt. Microbiol., West Pakistan Agriculture University Lyallpur, Pakistan.

Kimpe, A.; Decostere, A.; Martel, A.; Haesebrouck, F. and Devriese, L.A. (2002). Prevalence of antimicrobial resistance among pigeon isolates of Streptococcus gallolyticus , Escherichia coli and *Salmonella enterica* serotype *Typhimurium*, *Avian Pathology*, 31:4, 393-397,

Koompapong, K.; Mori, H.; Thammasonthijarern, N.; Prasertbun. R.; Pintong, A.; Popruk, S.; Rojekittikhun, W.; Chaisiri, K.; Sukthana, Y and Mahittikorn, A. (2014). Molecular identification of *Cryptosporidium* spp. in seagulls, pigeons, dogs, and cats in Thailand. Parasite. 21: 52.

Koroglu, E. and Simsek, S. (2001). The prevalence of Eimeria species in pigeons (*Columba livia*) in Elazig. Firat Univ Saglik Bil Derg, 15: 401-404.

Kruse, W. and Blutparasiten, U. (1890). Virchows. Arch. Path. Anat. Physiol., 121, 359–372.

Kulisic, Z. (1988). Endoparasite fauna of pigeons (*Columba livia*) as detected in the city of Belgrade. Acta Vet Beograd, 38: 37-42.

Lindsay, D.S.; Blagburn, B.L. and Sundermann, C.A. (1989). Morphometric comparison of the oocysts of *Cryptosporidium meleagridis* and *Cryptosporidium baileyi* from birds. *Proc Helminthol Soc Wash*., 56(1): 91-92.

Liu, H.; Wang, Z.; Song, C., Wang, Y.; Yu, B. I. N.; Zheng, D.; Sun, C. and Wu, Y. (2006) characterization of pigeon-origin Newcastle disease virus isolates in China. Summarized from Avian Diseases, 50 (4):636–640.

Luna, L.G.(1968). Manual of Histologic Staining Methods of the Armed Forces Institute of Pathology (3rd edition). McGraw Hill Book Co., New York.

Maeda, M., S.; Koizumi and Yachi M. (1987). Histopathological changes in Newcastle disease affecting racing pigeons in Japan. *Japanese Journal of Veterinary Science*. 49: 217-223.

Maina, J.N. (2002). Some recent advances on the study and understanding of the functional design of the avian lung: morphological and morphometric perspectives. *Biological Reviews of the Cambridge Philosophical Society*, 77, 97-152.

Majeed Saleh, K.; Al-Sereah Bahaa, A. and Yasir Iman, H. (2016). Toxicological pathology of aflatoxin B1 in local pigeon mainly in liver, kidney and heart. Journal of International Academic Research for Multidiciplinary, 4(3): 218-227.

Mangat, A. P. S., G. Singh and B. S. Gill, 1988. An outbreak of paramyxovirus encephalomyelitis in racing pigeons in India. *Veterinary Rec*., 123: 496.

Mangat, A.P.S.; Singh, G. and Gill, B.S. (1988). An outbreak of paramyxovirus encephalomyelitis in racing pigeons in India. *Veterinary Record*, 123: 496.

Manuel, F., Ramírez, G. A; Hernández, A, (2004) Journal of Wildlife Diseases, *Journal of Wildlife Diseases,*40(2):351-355.

Marques, S.M.; Quadros, R.M.; Da-Silva, C.J. and Baldo, M. (2007): Parasites of pigeons (*Columba livia*) in urban areas of Langes, Southern Brazil. *Parasitology Latino American*, 62: 183-187.

Martinez-Moreno, F.J.; Martinez-Mareno, A.; Becerra-Martell, C.; Martinez-Cruz, M. de S. (1989). Parasitic fauna of pigeons (*Columba livia*) in Cordoba Province, Spain. Rev Iber Parasitol., 49: 279-81.

Masola, S N.; Mzula, A.; Kasanga, C J and Wambura, P N, (2015): Evaluation of Virulence of Tanzanian Strains of Fowlpox and Pigeonpox Viruses in Chickens. *British Biotechnology Journal 10(1): 1-10.*

McDougald, L.R. (2003). Protozoal Infections. In: Diseases of Poultry. 11th ed., Saif, Y.M.; Barnes, H.J.; Glisson, J.R.; Fadly, A.M. McDougald, L.R. and Swayne, D.E. (Editors). Ames, IA: Iowa State Press, Blackwell Publishing Company.

Mishra, S.; Kataria, J.M.; Sah, R.L.; Verma, K.C. and Mishra, J.P. (2000). Pathogenesis of Newcastle disease virus isolates in pigeon. *Indian Journal of Animal Science*, 70: 1125-1126.

Mohan, M. and Fernandez, T. F. (2008). A case report of Pigeon Pox-Histopathologic Diagnosis**.** *Veterinary World*, 1(4): 117-118.

Mubarak M., and Abed G. H. (2005). Pathological changes of lung tissues of pigeons (*Columba livia domestica*) infected with *Haemoproteus columbae* (Haemosporina: Haemoproteidae). Journal of Biological Sciences, 5(5): 536–541.

Mubarak, A. (2000). Pathogenicity of Newcastle disease virus (chicken) in pigeons. MSc. Thesis, Department of Veterinary Pathology, Univ. Agri., Faisalabad, Pakistan.

Mubarak, A. (2000). Pathogenicity of Newcastle disease virus (chicken) in pigeons. MSc. Thesis, Department of Veterinary Pathology University of Agriculture Faisalabad Pakistan.

Mubarak, M. and G. H. Abed. (2005). Pathological changes of lung tissues of pigeons (*Columba livia domestica*) infected with *Haemoproteus columbae* (Haemosporina: Haemoproteidae). *Journal of Biological Sciences*, 5(5): 536-541.

Munjeri, N. (1996): An antigen ELISA for the detection of Newcastle disease virus. *Zimbabwe Veterinary Journal*, Vol. 7, No. 2.

Murakami, K.; Etoh, Y.; Ichihara, S.; Maeda, E. and Takenaka, S. (2014): Isolation and Characteristics of Shiga Toxin 2f-Producing Escherichia coli among Pigeons in Kyushu, Japan, PLoS 9(1): 1-12.

Musa, S.; Afroz, S.D. and Khanum, H. (2011): Occurrence of ecto- and endo parasites in pigeon (*Columba livia* Linn.). *University Journal of Zoology Rajshahi University*, 30: 73-75.

Mushtaq, I; Rizvi, F; and Ullah, M S, (2006) effect of pigeon origin newcastle disease virus on various liver enzymes and associated pathological changes in experimentally infected pigeons. *Pakistan Veterinary Journal*, 2006, 26(4): 171-175.

Nakamura, A.A. and Meireles, M.V. (2015). *Cryptosporidium* infections in birds - a review. Braz. J. Vet. Parasitol., 24(3): 253-267.

Nardoni, S.; Ceccherelli, R.; Rossi, G. and Mancianti, F. (*2006*). *Aspergillosis* in *Larus cachinnans micaellis*: survey of eight cases. Mycopathologia, 161: 317-321.

Nashiruddullah, N.; Ahmed, J.A.; Borkataki, S.; Pathak, A.K.; Goswami, P. and Choudhary, A.R. (2016). Cestodiasis in scaly-bellied woodpeckers (*Picus squamatus*) of Kashmir. *Bhartiya Krishi Anusandhan Patrika*, 31(1): 74-77.

Natt, M.P. and Herrick, C.A. (1952). A new blood diluent for counting the erythrocytes and leucocytes of the chicken. *Polutry Science*, 31(4): 735-738.

Nayyef, H.J. (2012). Histopathological Study for some infected Pigeons with *Raillietina* spp. in Baghdad. *Al-Mustansiriya Journal of Science*, 23(1): 18-19.

Nisar, S.; Khan, M. F.; Khan, A.; Azmi, M. A. and Raza, A., (2015): Histopathological changes of intestine of pigeon (*Columba livia*) artificially infected with *C. digonopora* and *C. cuneata*. International Journal of Fauna and Biological Studies 2015; 2 (3): 36-39.

O'Neil, M.J.; Smith, A.; Heckman, P.E.; Budavari, S. (2001). The Merck Index: An Encyclopedia of Chemicals, Drugs, and Biologicals. 13th Edition. Whitehouse Station, NJ: Merck and Company. Pp. 34-35.

Oglesbee, B.L. (1997). Mycotic diseases. In R.B. Altman (Ed.). Avian Medicine and Surgery 1st edn (pp. 323_361). Philadelphia, PA: W.B. Saunders Company.

OIE (2010). Fowl Pox. *In: Manual of Diagnostic Tests and Vaccines for Terrestrial Animals* (OIE Terrestrial Manual, 2010).

OIE (2012). Cryptosporidiosis. *In: Manual of Diagnostic Tests and Vaccines for Terrestrial Animals* (OIE Terrestrial Manual, 2012).

OIE (2012). Newcastle Disease (Infection with Newcastle Disease Virus). *In: Manual of Diagnostic Tests and Vaccines for Terrestrial Animals* (OIE Terrestrial Manual, 2012).

Olias, P.; Gruber, A. D.; Kohls, A.; Hafez, H. M, and Heydorn, A. O. (2010): Sarcocystis Species Lethal for Domestic Pigeons. Emerging Infectious Diseases. 16(3)

Olias, P.; Gruber, D. A.; Hydorn, O. A.; Kohls, A.; Mehlhorn, H.; Hefez, M. H, and Lierz, M, (2009). A novel Sarcocystis-associated encephalitis and myositis in racing pigeons. *Avian Pathology* 38(2), 121_128.

Olias, P; Meyer, A.; Klopfleisch, R.; Lierz, M.; Kaspers, B and Gruber, A. D. (2013): Modulation of the host Th1 immune response in pigeon protozoal encephalitis caused by Sarcocystis calchasi. *Veterinary Research* 2013 44:10.

Opara, M. N.; Ogbuewu, I P.; Iwuji, C T.; Njoku.; Ihesie, E K. and Etuk, I F. (2012): Blood characteristics, microbial and gastrointestinal parasites of street pigeons

(*Columba Livia*) in Owerri Imo State, Nigeria. *Scientific Journal of Animal Science* 1(1) 14-21.

Özkul, I.A. and Aydin, Y. (1994). Small-intestinal cryptosporidiosis in a young pigeon, Avian Pathology, 23:2, 369-372.

Pandey, M.; Ghosh, R.C.; Behera, P.; Gupta, V.; Tripathi, S.K.; Jolhe, D.K.; Kshirsagar, A.A. and Khan, F.F. (2014). Detection of Pox virus in domestic pigeon. *Indian Journal of Veterinary Pathology*, 38(2): 139-140.

Parsani, H.R.; Momin, R.R.; Lateef, A. and Shah, N.M. (2014). Gastro-intestinal helminths of pigeons (*Columba livia*) in Gujarat, India. *Egyptian Journal of Biology*, 16: 63-71.

Pasmans, F. F.; van Immerseel, M.; Heyndrickx, A.; Martel, C.; Godard, C.; Wildemauwe, R.; Ducatelle and Haesebrouck, F. (2003). Host adaptation of pigeon isolates of Salmonella enterica subsp. enterica serovar Typhimurium variant Copenhagen phage type 99 is associated with enhanced macrophage cytotoxicity. *Infectious. Immunology.* 71:6068-6074.

Pasmans, F.; Baert, K.; Martel, A.; Bousquet-melou, A.; Lanckriet, R.; Boever, S. D.; Immerseel, F. V.; Eeckhaut, V.; Backer, P. D. and Haesebrouck, F., (2007):Induction of the Carrier State in Pigeons Infected with *Salmonellaenterica*. 31 (7):200-208.

Pasmans, F.; Baert, K.; Martel, A.; Bousquet-Melou, A.; Lanckriet, R.; De Boever, S.; Van Immerseel, F.; Eeckhaut, V.; de Backer, P. and Haesebrouck, F. (2008). Induction of the Carrier State in Pigeons Infected with *Salmonella enterica* Subspecies *enterica SerovarTyphimurium* PT99 by Treatment with Florfenicol: a Matter of Pharmacokinetics . *Antimicrob Agents Chemother*, 52(3): 954–961.

Patzke, N. (2009): Olfaction based navigation in pigeons (*Columba livia*): Examination of the neuronal substrates and their asymmetries. Doctoral Dissertation, Ruhr-University at Bochum, Germany.

Pedersen, K.; Clark, L.; Andelt, W. F.; Salman, M. D. and Collins, F. (2006): prevalence of shiga toxin–producing *escherichia coli* and *salmonella enterica*

in rock pigeons captured in fort collins, colorado. *Journal of Wildlife Diseases*, 42(1):46-55.

Pedersen, K.; Clark, L.; Andelt, W. F.; Salman, M. D. and Collins, F. (2006). prevalence of shiga toxin–producing *escherichia coli* and *salmonella enterica* in rock pigeons captured in fort Collins, Colorado. *Journal of Wildlife Diseases*, 42(1):46-55.

Phalen, D.N. (1997). Poxviruses. In R.B. Altman, S.L. Clubb, G.M. Dorrestein & K. Quesenberry (Eds.), *Avian Medicine and Surgery* (pp. 300–304). Philadelphia: W.B. Saunders Company.

Phangcho CV (2001) Etiopathological studies on the prevailing diseases of domestic pigeons (Columba livia). PhD thesis, AssamAgriculture. University Guwahati, India.

Proux, K., F. Humbert, M. Guittet, P. Colin, and G. Bennejean. 1998. Vaccination of pigeon by Salmonella typhimurium. *Avian Pathology*, 27:161-167.

Quinn, P.J.; Carter, M.E.Markey, B. and Carter, G.R. (1993). Clinical Veterinary Microbiology. Mosby.

Radfar, M.H.; Fathi, S.; Asl, E.N.; Dehagi, M.M. and Seghinsara, H.R. (2011). A survey of parasites of domestic pigeons(*Columba livia domestica*) in South Khorasa, Iran. *Veterinary Research*, 4(1): 18-23.

Ramesh, J.; Sarathchandra, G. and Sureshkumar, V. (2013). Analysis of feed samples for aflatoxin B1 contamination by HPTLC - a validated method. *Int. J. Curr. Microbiol. App. Sci.*, 2(5): 373-377.

Ramirez, R.; Robertstad, G.W.; Hutchinson, J.R. and Chavez, J. (1976). Mycotic flora in the lower digestive tract of feral pigeons (*Columba livia*) in the EI Paso , TEXAS area. *Journal of Wild Disease*, 12(1): 83-85.

Ramisz, B.A. and Pilarczyk, B. (2014). Occurrence of coccidia infection in pigeons in amateur husbandry, diagnosis and prevention. *Annals of Parasitology*. 60(2), 93–97.

Randall, C.J. and Reece, R.L. (1997). Color Atlas of Avian Histopathology. London: Mosby-Wolfe Publishing.

Razavi, S.M.; Nazifi, S.; Afsar, M.; Yazdanpanah, Z. and Rakhshandehroo, E. (2016). Evaluation of the blood oxidant-antioxidant interactions in pigeons naturally infected with *Haemoproteus columbae*. Veterinarski Arhiv, 86(3): 395-405.

Rehman, R., 1993. A study on the prevalence of Ascaridiagalliand the effects of experimental infection on various blood parameters and body weight in chicken.M.Sc. (Hons) Thesis, University. of Agriculture. (CVS), Faisalabad-Pakistan.

Riddell, C. (1987). Avian Histopathology. American Association of Avian Pathologists. Lawrence: Allen Press Inc.

Rodriguez, F.; Oros J.; Rodriguez J.L.; González J.; Castro P., Fern ánd ez A. (1997). Intestinal cryptosporidiosis in pigeons (*Columba livia*). *Avian Diseases*, 41, 748.750.

Romer, T.R. (1975). Screening method for the detection of aflatoxins in mixed feeds and other agricultural commodities with subsequent confirmation and quantitative measurement of aflatoxins in positive samples. *Journal-Association of Official Analytical Chemists*, 58(3):500-506.

Ryan, U. (2010). *Cryptosporidium* in birds, fish and amphibians. *Exp Parasitol.*, 124(1): 113-120.

Sá, M.R. (2011). Studies of avian malaria and Brazil in the international scientific context (1907-1945). Hist. Cienc. Saude. Manguinhos. 18: 499-518.

Sari, B.; Karatepe, B.; Karatepe, M. and Kara, M. (2008): Parasites of domestic pigeon (*Columba livia domestica)* and wild (*Columba livia livia*) pigeons in Niğde, Turkey.*Bulletin Veterinary Institute Pulawy*, 52: 551-554.

Sawada, I.; Molan, A.L. and Saeed, I.S. (1990). Further studies on avian cestodes in Iraq. Jpn J Parasitol., 39: 36-41.

Schroeder, E. C.; Nair, K.P.C.; Cardeilhac, P.T. (1972). Response of broiler chicks to a single dose of aflatoxin. *Poultry Science*. 47:1552-1556.

Senlik B, Gulegen E, Akyol V. (2005). Prevalence and intensity of *Haemoproteus columbae* in domestic pigeons. Indian Vet J., 82: 998-999.

Shaheen, S.; Anjum, A.D. and Rizvi, F. (2005). Clinico-pathological observations of pigeons (*Columba livia*) suffering from Newcastle disease. *Pakistan Veterinary Journal*, 25(1): 5-8.

Siddique, A. B; Hossain, F. M. A; Zinnah, M. A, (2011) Determination of host specificity of pigeon pox and fowl pox viruses isolated from a field outbreak . *Bulgarian Journal of Veterinary Medicine* (2011), **14**, No 4, 209−214.

Singh, G.; Mangat, A.P.S. and Gill, B.S. (1989). Isolation of Newcastle disease virus (avian paramyxovirus-1) from pigeons (*Columba livia*) in India. *Current Science*, 58: 154-155.

Sivajothi, S.; Reddy, B. and Sudhakara. (2015) A Study on the Gastro Intestinal Parasites of Domestic Pigeons in YSR Kadapa District in Andhra Pradesh, India. *Journal of Dairy Veterinary Animal Research* 2(6): 00057.

Smith. H. J.; Neill, G. J. P.; Dillard, A. E and Box D. E. (1990). Pathology of Experimental Sarcocystis falcatula Infections of Canaries (*Serinus canarius*) and Pigeons (*Columba livia*). *The Journal of Parasitology*, 76(1): 59-68.

Sol D, Jovani R, Torres J. (2000). Geographical variation in blood parasites in feral pigeons: The role of vectors. Ecography. Pattern Divers Ecol., 23: 307-314.

Soulsby, E.J.L. (1982). Helminths, Arthropods and Protozoa of Domesticated Animals (7th edition). The English Language Book Society and Bailliere, Tindall and Cassell, London.

Stone, H.D. (1989). Efficacy of oil-emulsion vaccines prepare with pigeon paramyxovirus-1, Ulster, and La Sota Newcastle disease viruses. *Avian Disease*, 33(1): 157-162.

Tanaka, C.; Miyazawa, T.; Watarai, M. and Ishiguro, N. (2005): Bacteriological Survey of Feces from Feral Pigeons in Japan. *Journal of Veterinary Medical. Science.* 67(9): 951–953,

Tell, L.A. (2005). Aspergillosis in mammals and birds: impact on veterinary medicine. Medical Mycology Supplement, 1, S7_S73.

Tessari, E.N.; Oliveria, C.A.; Cardoso, A.L.; (2006) Effects of aflaoxin B1 and fumonisin B1 on body weight, antibody titres and histology of broiler chick. Br. Poult. Sci. 47:357-364.

Tokarzewski, S.; Ziółkowska, G.; Łopuszyński, W. and Nozdryn-Płotnicki, Z. (2007). *Aspergillus fumigatus* infection in a pigeon flock. Bull Vet Inst Pulawy, 51: 563-567.

Toth, T.E. (2000). Nonspecific cellular defence of the avian respiratory system: a review. Developmental and Comparative Immunology, 24, 121_139.

Tripathy, D.N. (1991). Avian Pox. In: Diseases of Poultry. B.W. Calnek, H. Barnes, C.W. Beard, W.M. Reid and H.W. Yoder (Eds.). Ames: Iowa State University Press. Pp. 583-596.

Tripathy, D.N. (1993). Avipox viruses. In: Virus Infections of Vertebrates. J.B. McFerran & M.S. McNulty (Eds.). Amsterdam: Elsevier Science Publishers. Pp. 5–15

Tripathy, D.N.; Schnitzlein, W.M.; Morris, P.J.; Janssen, D.L.; Zuba, J.K.; Massey, G. and Atkinson, C.T. (2000). Characterization of poxviruses from forest birds in Hawaii. *Journal of Wildlife Diseases.* 36, 225_230.

Trupkiewicz, G.J.; Calero Bernal, R.; Verma, K.S.; Mowery, J.; Davison, S.; Habecker, P.; Georoff, A.T.; Ialeggio, M.D. and Dubey P.J. (2016). Acute, fatal *Sarcocystis calchasi* associated hepatitis in Roller pigeons (*Columba livia*) at Philadelphia Zoo 216 ,52–58.

Tsai, S.S.; Chang, T.C. and Yang, S.F. (1997). Unusual lesions associated with avian poxvirus infection in rosy-faced lovebirds (*Agapornis roseicollis*). *Avian Pathology*, *26*, 75–82.

Tsai, S.S.; Park, J.H.; Hirai, K. and Itakura, C. (1992). Aspergillosis and candidiasis in psittacine and passeriforme birds with particular reference to nasal lesions. *Avian Pathology*, 21, 699_709.

Uthrakumar, A.; Vijayarani, K.; Kumanan, K. and Thiagarajan, V. (2013) Molecular Characterization of Thermostable Newcastle disease virus Isolated from Pigeon. Indian J. Virol. 24(1):42–47.

Uyttebroek, E. L. A.; Devriese, D.; Gevaert, R.; Ducatelle, J.; Nelis, and Haesebrouck, F. (1991). Protective effect of vaccines against experimental salmonellosis in racing pigeons. Veterinary Rec. 128:152-153.

Valkiunas, G. (2005). Avian malaria parasites and other haemosporidia. CRC Press, Boca Raton, Florida.

van Duijkeren, E. and D. J. Houwers. (2000). A critical assessment of antimicrobial treatment in uncomplicated *Salmonella enteritis*. *Veterinary Microbiology*, 73:61-73.

van Riper III, C. and Forrester, D.J. (2008). Fowl Pox. In: Infectious Diseases of Wild Birds. Thomas, N.J.; Hunter, D.B. and Atkinson, C.T. (Editors). Blackwell Publishing.

Wang, J.; Liu, H.; Wei; Z D.; Zhao, Y. and Li, Y. (2015): Genomic Characterizations of Six Pigeon Paramyxovirus Type 1 Viruses Isolated from Live Bird Markets in China during PLoS ONE, 10(4): 1371.

Whitman, C.T. and Grant, C.M. (2000): Control of health hazards associated with bird and bat droppings. Bulletin of the New Jersey Department of Health and Senior Services, Public Employees Occupational Safety and Health (PEOSH) Program.http://www.state.nj.us/health/eoh/peoshweb/pigeon.pdf

Yabe, K.; Ando, Y.; Ito, M. and Terakado, N. (1987). Simple Method for Screening Aflatoxin-Producing Molds by UV Photography. Applied and Environmental Microbiology, 53(2): 230-234.

Zangana, M.F. (1982). Study on the Parasites of Domestic Pigeon Columba livia domestica in Nineveh and Some Areas of Erbil and Dohuk Provinces. M.Sc. Thesis, Mosul University, Iraq.

Ziółkowska, G. and Tokarzewski, S. (2006). Determination of antifungal activity of Enizol: a specific disinfecting preparation. *Medycyna Wet*, 62: 792-796.

VITA

Name of the Student	**:**	Syed Mehmood
Father's Name	**:**	Syed Hadi
Mother's Name	**:**	Archo Leela
Nationality	**:**	Indian
Permanent Home	**:**	V.P.O:- Taiket Khandi, Tehsil: Sankoo District: Kargil
Telephone No.	**:**	9419575974
Email Id	**:**	drrizvi406@gmail.com

EDUCATIONAL QUALIFICATION

Bachelor Degree	**:**	B.V.Sc. and A.H.
University	**:**	SKUAST-Kashmir
Master Degree	**:**	M.V.Sc. (Veterinary Pathology)
OGPA	**:**	7.7/10

Appendix-I

Modified Ziehl-Neelsen (mZN) containing strong carbolfuchsin, decolourized with 1% acid methanol and counter stained with methylene blue.

Basic fuchsin	20 g
Absolute ethanol	200 ml
Liquid phenol (Carbolic acid)	125 ml
Distilled water	1675 ml

Filtered through Whatman No.1 filter paper.

Phosphate buffered saline (PBS) 10x PBS, 1L:

NaCl	80 g
KCl	2 g
Na_2PO_4	11.45 g
KH_2PO_4	2.4 g

Dissolve everything in 800 ml of distilled water, then fill up to 100 ml, store at room temperature.

Alsever's solution is a saline liquid solution containing. This product is composed of (in g/L)

Dextrose	2.05 %
Sodium citrate	0.8 %
Citric acid	0.005 %
Sodium chloride	0.42 %

The solution is placed in a refrigerator at 2-8 ^{o}C for 2 weeks.

CERTIFICATE- IV

Certificate that all the necessary correction as suggested by the external examiner /evaluator and the advisory committee has been duly incorporated in the thesis entitle **"Pathological Conditions Affecting the Domestic Pigeons (*Columba livia*) in Jammu Region"** submitted by **Mr. Syed Mehmood,** Regd. **No. J-14-MV-406**

31/3/17

Dr. NawabNashiruddullah
(Major Advisor)

No: AU/FVSJ/VPP/16-17/550

Date: 31.03.2017

31-3/17

Dr. Shagufta Azmi
Head of the Division VPP