PATHOLOGY OF CAPRINE PULMONARY AFFECTIONS WITH SPECIAL REFERENCE TO PNEUMONIA

Thesis

SUBMITTED IN PARTIAL FULFILMENT OF
THE REQUIREMENTS FOR THE DEGREE

OF

Master of Veterinary Science

IN

VETERINARY PATHOLOGY

BY

Lt. Col. N. S. Kanwar

Roll No. 3536

TO

DEEMED UNIVERSITY

INDIAN VETERINARY RESEARCH INSTITUTE

IZATNAGAR – 243122 (U.P.), INDIA

1996

Computerised

D. O.

636.39089624107
K139P

44139 pathology

NLVS/IVRI
44139

to....

my

Beloved Parents

Dr. O.P. PALIWAL
Ph.D., FRVC (Sweden)
Principal Scientist

Division of Pathology
Indian Veterinary Research Institute
Izatnagar - 243 122 (U.P.)

Dated the 31st August, 1996

CERTIFICATE

Certified that the research work embodied in the thesis entitled ***"PATHOLOGY OF CAPRINE PULMONARY AFFECTIONS WITH SPECIAL REFERENCE TO PNEUMONIA"*** *submitted by* ***Dr. N.S. Kanwar*** *for the award of* ***Master of Veterinary Science Degree*** *of Indian Veterinary Research Institute, Izatnagar is the original work carried out by the candidate himself under my supervision and guidance.*

It is further certified that ***Dr. N.S. Kanwar*** *has worked for more than 24 months in the Institute and has put in more than 150 days attendance under me from the date of his registration for the* ***Master's Degree*** *of the University as required under the relevant ordinance.*

Opaliwal
31/8/96

[O. P. PALIWAL]
SUPERVISOR

CERTIFICATE

Certified that the thesis entitled "**PATHOLOGY OF CAPRINE PULMONARY AFFECTIONS WITH SPECIAL REFERENCE TO PNEUMONIA**" submitted by **Dr. N.S. Kanwar** in partial fulfilment of the M.V.Sc. Degree of Indian Veterinary Research Institute, Izatnagar embodies the original work done by him. The candidate has carried out his work sincerely and methodically.

We have carefully gone through the contents of the thesis and are fully satisfied with the work carried out by the candidate which is being presented by him for the award of M.V.Sc. Degree of this Institute.

It is further certified that the candidate has completed all the prescribed requirements governing the award of the M.V.Sc. Degree of the Indian Veterinary Research Institute, Izatnagar.

22/10/96

Signature of the External Examiner

[O.P. PALIWAL]
Chairman

MEMBERS OF THE STUDENT'S ADVISORY COMMITTEE

1. **Dr. Ram Kumar**
2. **Dr. A. K. Sharma**
3. **Dr. N.C. Srivastava**
4. **Dr. A. A. Kumar**

ACKNOWLEDGEMENTS

I wish to place on record my deep sense of gratitude to my venereable teacher Dr. O.P. Paliwal, Principal Scientist, Division of Pathology, IVRI, Izatnagar (U.P.) for bringing out the best in me under challenging situations. No words can possibly measure up to the feeling I have for his relentless efforts, able guidance and critical appreciation throughout the course of present investigation.

I am equally indebted to the members of my advisory committee, Dr. Ram Kumar, Sr. Scientist and Dr. A.K. Sharma, Sr. Scientist, Division of Pathology, Dr. N.C. Srivastava, Principal Scientist and Dr. A.A. Kumar, Sr. Scientist, Division of Bacteriology and Mycology for their valuable help and cooperation in the pursuit of the study.

I thankfully acknowledge the help of Dr. S.K. Chattopadhyay, Principal Scientist and Dr. R. Somvanshi, National Fellow (ICAR), Division of Pathology for the valuable suggestion in this investigation.

I express my sincere thanks to Dr. T.R. Rao and Dr. R.L. Sharma, Division of Parasitology for their help in identification of Parasites in this study.

I am grateful to Director, Joint Director (Academic) and Head, Division of Pathology for extending the necessary facilities.

I am thankful to Addl. DGRVS (AHQ), New Delhi for having permitted me to pursue this study.

I sincerely acknowledge the homely cooperation extended by the supporting staff of Division of Pathology especially S/Shri Shyam Singh, Md. Yamin, Suresh Kumar and Late Chet Ram.

Cooperation extended by Shri Anirudh and Shri B.N. Pal for preparing this manuscript is gratefully acknowledged.

Where the emotions are involved, words cease to mean, there are no words to express my deep concern about my better half and my sons Luv Kush and TITO who had to bear my separation while living under one roof during the entire period of research.

In the end, I salute to all "the creatures of lesser God" who sacrified themselves to achieve the operational targets.

[N.S. KANWAR]
Lt. Col.

CONTENTS

		Page
I	INTRODUCTION	1-4
II	REVIEW OF LITERATURE	5-27
III	MATERIALS AND METHODS	28-31
IV	RESULTS	32-64
V	DISCUSSION	65-73
VI	SUMMARY AND CONCLUSIONS	74-78
	BIBLIOGRAPHY	i-xxiii

oOo

INTRODUCTION

INTRODUCTION

Among the developing countries, in a agriculture based economy like India, the importance of animal husbandry in the economic upliftment cannot be ignored. In animal husbandry development programmes, the goats occupy an unique position and contribute substantially to the income of marginal and landless farmers. Goats are known for their high production rates, early maturity, tasty meat, rich milk, adaptability to harsh climate and utilization of scrub land for human food production. They are therefore known as 'Poor man's cow' (Acharya, 1982). India has 118.34 million goats out of the world population of 609.43 million. Out of world's total milk production of 506.5 million tonnes, goats have been estimated to share 8.8 million tonnes. Goats are the major source of meat and contribute 410 x 1000 metric tonnes of total world's meat production of 2605 x 1000 metric tonnes (Anon, 1992 and FAO, 1994).

Realising the importance of goat in the rural economy, Indian Council of Agricultural Research (ICAR) has established Central Institute of Research on Goats (CIRG) at Makhdoom, Mathura (U.P.) for meat, milk and fibre research. Fifth international conference was organised at New Delhi during March 1992 which re-

viewed different aspects of advances in goat research. It was emphasized that for optimum production, efficient health care, nutrition and management play a significant role. Moreover as goat meat is commonly used for human consumption, it also assumes added importance in public health hazards of zoonotic infections.

Respiratory ailments in goats leading to high morbidity and mortality are known to cause heavy production and economic losses. The physioanatomical features of the lungs imparts them direct access to the external environment and predispose them to almost all fatal diseases in addition to the primary respiratory diseases. In addition to the possibility of infectious agents acting as primary pathogens, various other factors like low plane of nutrition, inclement weather, exhaustion, cachexia, overcrowding and other forms of stress suitably alter the environment for the less pathogenic or opportunistic organisms (Jubb et al., 1993).

Lung acts as a gate to the blood and hence has an impact on the circulating system of the entire body. The pulmonary circulation exerts an important control over biologically active substances in blood apart from its respiratory and filtering functions. Thus the lung has been considered an immunologically and biochemically oriented apparatus for understanding the pathogenesis and pathology of innumerable mysterious maladies with interplay of extrinsic and intrinsic factors in diversified manner.

The surveillance on causes of goat mortality during last twenty years revealed respiratory disorders to the tune of 0.56 to 60.6% (Banerjee & Gupta, 1978/1979, Srivastava et al., 1985 and Alka Sharan et al., 1986). Pneumonia being the commonest

and most significant affection of lung with varied incidence 2.11 to 68% (Sadana et al., 1979; Datta, 1983; Patnaik, 1985; Srivastava et al., 1985; Koul, et al., 1988; Upadhyaya and Rahman, 1993) has been recorded and classified largely on the basis of etiology and morphologic alterations. This classification alone is not sufficient, as similar lesions may be produced by the different agents (Stamp and Nisbet, 1963; Stamp, 1968 and Stevenson, 1969). Therefore, based exclusively on a single criterion either anatomical, etiological, morphological, clinical or based on type of inflammatory exudate may not hold good to give a satisfactory understanding of common pulmonary infections and would leave confusion at one stage or the other. The classification based on the histopathological tissue reaction to injury in the lung by different types of inflammatory phenomenon would be more appropriate as suggested by Rajya (1964).

On perusal of the available literature, it appears that voluminous work has been published yet the battle against the respiratory diseases has not been won. On account of the enormous and injudicious use of chemotherapeutics such as antibiotics, cortisones etc. intake of insectisides and poisonous chemicals through adultrated feeds and affected shrubs and increasing levels of atmospheric and industrial pollutants, the change in incidence, pattern and type of pathological conditions involving respiratory tract is bound to occur. Thus, the study of spontaneously occuring lung lesions is expected to provide some valuable information on the etiogenesis as well as pathomorphological alterations in the disease spectrum.

Keeping in view the above facts the present investigation was undertaken with the following objectives:-

1. To study the occurrence and magnitude of spontaneous pulmonary affections/pneumonia in goats.

2. To classify various forms of pneumonias encountered in goats based on pathomorphological lesions i.e. gross and histopathological examination.

3. Isolation and identification of the possible etiological agents (Bacteria) from such pneumonic lesions.

4. Correlation of pathological lesions with possible causative agent(s), if any.

REVIEW OF LITERATURE

REVIEW OF LITERATURE

Published literatures have revealed high morbidity and mortality due to respiratory disorders and pneumonia, in particular among goats. The prevalence of respiratory disorders varied from 0.56 to 60.6% reported by various workers. (Banerjee and Gupta, 1978/1979; Srivastava, et al., 1985 and Alka Sharan et al., 1986). The incidence of pneumonia reported by various workers in India varied from 2.11 to 68.0 per cent (Dwivedi, 1971, 1974; Bhagwan and Singh, 1972; Sadana et al., 1979; Sambyal et al., 1980; Datta, 1983; Upadhyaya et al., 1983; Patnaik, 1985; Srivastava et al., 1985; Koul et al., 1988; Naik et al., 1991a and Upadhyaya and Rahman, 1993) and mortality varied from 3.75 to 80.00 per cent (Sarkar and Bhattacharya, 1975; Sambyal et al., 1980; Chawla et al., 1982; Sri-Raman et al., 1982; Kaushik and Kalra, 1983; Patnaik, 1985; Kumar and Prasad, 1986; Vihan et al., 1986; Uppal et al., 1987; Koul et al., 1988; Mishra, 1992; Vihan and Singh, 1992; Ram Kumar and Paliwal, 1995; Sawargaonkar et al., 1996). In order to have a glance at global horizon, the incidence of pneumonia reported by different workers varied from 0.23 to 90.00 per cent (Bakr et al., 1980; Mohan and Uzoukwu, 1985; Ashraf et al., 1986; Zamri-Saad et al., 1987; Metin et al., 1988; Abu et al., 1990; Fordor et al., 1990 and AlDarraji and AlJoboury, 1993) and the mortality

varied from 10.00 to 100.00 per cent (Masiga and Rurangirwa, 1979; Bolske et al., 1983; Nascimento et al., 1986; Buddle et al., 1990).

The pathological lesions of lung have been classified in a diversified manners and varied considerably in their macroscopic and microscopic alterations depending upon the etiological agents/ factor(s). Types of pneumonias classified on the basis of histopathological studies by different workers included acute bronchopneumonia, fibrinous bronchopneumonia, necrotizing pneumonia, haemorrhagic pneumonia, chronic bronchopneumonia, suppurative pneumonia, interstitial pneumonias, granulomatous pneumonia including tuberculous and mycotic pneumonias, verminous pneumonias, pulmonary adenomatosis and mycoplasmal pneumonias etc. (Rajya, 1964; Bhagwan and Singh, 1972; Dwivedi, 1974; Banerjee and Gupta, 1979; Masiga and Rurangirwa, 1979; Bakr et al., 1980; Hordagoda et al., 1981; Bolske et al., 1983; Goncalves, 1983; Datta, 1983; Upadhyaya et al., 1983; Patnaik and Nayak, 1984; Ahuja et al., 1985; Patnaik, 1985; Mohan and Uzoukwu, 1985; Sharma et al., 1985; Srivastava et al., 1985; Alka-Sharan, 1986; Nascimento et al., 1986; Zamri-Saad et al., 1987; Metin et al., 1988; Mukherjee et al., 1988, 1989; Ivetic et al., 1989; Mukherjee et al., 1990; Buddle et al., 1990; Rahman and Singh, 1990b; Naik et al., 1991a; Mishra, 1992; Upadhyaya and Rahman, 1993; AlDarraji and AlJoboury, 1993 and Singh et al., 1995).

Various types of pneumonias were broadly reviewed under the following main categories inclusive of their further divergence on the basis of characteristic inflammatory response.

1. BRONCHOPNEUMONIA

A. Acute form :

(i) Catarrhal bronchopneumonia
(ii) Fibrinous bronchopneumonia.
(iii) Haemorrhagic bronchopneumonia
(iv) Necrotizing bronchopneumonia

B. Chronic form :

(i) Chronic nonsuppurative bronchopneumonia

2. SUPPURATIVE PNEUMONIA

(i) Acute suppurative pneumonia
(ii) Chronic suppurative pneumonia

3. INTERSTITIAL PNEUMONIA

A. Acute interstitial pneumonia
B. Chronic interstitial pneumonia

4. SPECIAL PNEUMONIA

(i) viral pneumonia
(ii) Pulmonary adenomatosis
(iii) Mycoplasmal pneumonia
(iv) Verminous pneumonia

5. GRANULOMATOUS PNEUMONIAS

(i) Pulmonary aspergillosis
(ii) Pulmonary tuberculosis

6. OTHER PULMONARY AFFECTIONS

(i) Pulmonary oedema
(ii) Pulmonary haemorrhage
(iii) Brown induration
(iv) Pulmonary emphysema
(v) Hydatidosis

1. BRONCHOPNEUMONIA

1. Acute form :

(i) Catarrhal bronchopneumonia :

Acute catarrhal bronchopneumonia is the commonest type of pneumonia described in goats and its incidence varied from 22.4 to 32.5 per cent (Abu Bakr et al., 1981; Upadhyaya, 1983; Alka Sharan et al., 1986; Naik et al., 1991a and Upadhyaya and Rahman, 1993).

Macroscopically, the lesions were characterized by exudation and consolidation chiefly the anteroventral parts of the lungs viz. apical, cardiac, intermediate and diaphragmatic lobes. Microscopically, the lesions consisted of severe engorgement of blood vessels in the bronchial wall and in the interstitial tissue. Good number of alveoli contained serous exudate and the bronchiolar lumen had

mucus mixed with leucocytes and desquamated cells. Focal hyperplasia, degeneration and often desquamation of bronchial and bronchiolar lining epithelium along with peribronchiolar and perivascular lymphocytic infiltration were observed (Ramachandran and Sharma, 1969; Hardagoda et al., 1981; Ashraf et al., 1986; Almieda et al., 1987; Naik et al., 1991a and Upadhyaya and Rahman, 1993).

The precise nature of the inflammatory response varies with the causal agent, although in all cases, the initial reaction is of catarrhal type. A wide variety of organisms incriminated were Pasteurella spp., Corynebacterium aureus, Staphylococcus pyogenes, Pseudomonas aeruginosa, E. coli, Klebsiella pneumoniae, Streptococcus sp., Proteus vulgaris and Salmonella sp. (Pillai et al., 1979; and Sharma et al., 1991).

(ii) Fibrinous bronchopneumonia :

The incidence of acute fibrinous bronchopneumonia varied from 14.00 to 48.24 per cent (Bakr et al., 1980; Ashraf et al., 1986; Metin et al., 1988; Sharma et al., 1991, Hafez et al., 1991; Upadhyaya and Rahman, 1993 and AlDarraji and AlJoboury, 1993).

Macroscopically, there were patchy areas of consolidation involving bilateral apical, cardiac and anteroventral portion of diaphragmatic lobes with extensive deposition of fibrinous mass. Microscopically, extensive serofibrinous exudation in pleura interlobular and interalveolar septae with engorgement of blood vessels and infiltration of neutrophils and oat shaped cells usually in the alveoli were predominent features observed due to Pasteurella sp. (Hardagoda and Wettimunny, 1980; Coussement et al., 1980; Ngatia et al., 1986, 1989; Fordor et al., 1990 and Dubey et al., 1992).

Chattopadhyay et al. (1987) described lesions of acute fibrinous bronchopneumonia due to Pasteurella sp. in goats. They observed large number of pulmonary lesions superimposed by suppuration indicating that Pasteurella not only act as primary etiological factor but is also responsible in developing suppuration in later stage of ailment.

P. haemolytica alone can produce lesions of fibrinous pneumonia although herpes virus proliferates in the upper respiratory tract but its role in producing pneumonia in goats remains uncertain (Buddle et al., 1990). Pathogenic P. haemolytica does not necessarily evoke total condition of fibrinous pneumonia but predisposing factor are important in evoking the lesions due to P. haemolytica infection (Ngatia et al., 1989).

Fordor et al. (1990) while investigating diseases caused by P. haemolytica in Hungarian goat herds observed fibrinous pneumonic lesions along with fibrinous pleuritis in severe cases.

Mishra (1992) observed 21.2 per cent mortality in goats in Sikkim due to Pasteurella pneumonia either alone or in association with other bacterial complications.

Zamri-Saad et al. (1994) reported the role of concurrent haemonchosis in the development of pneumonic pasteurellosis. They observed that the pneumonic lesions due to experimentally induced pasteurella infections were more severe in the animals which were exposed to Haemonchus contortus infection than the animals which were not exposed. They further opined that haemonchosis though mild, was enough to induce sufficient immunosuppression to allow

development of pneumonic pasteurellosis. Their observation was in agreement with the observations of Baskerville (1981). Dungworth (1985) reported that pneumonic pasteurellosis was commonly caused by P. haemolytica which is a part of the normal flora of the nasopharynx and oropharynx. The environmental stresses and respiratory diseases cause immunosuppression leading to the proliferation of P. haemolytica in respiratory tract.

Mycoplasma sp., also known to produce the lesions which were characterized macroscopically congestion, oedema and consolidation most frequently in cardiac lobes followed by apical and diaphragmatic lobes. The pleura was invariably thickened, haemorrahgic, oedematous and at places covered with fibrin. Interlobular septa were prominent and on sectioning the lung had marbled appearance. Microscopically, the lesions were characterized by the thickening of pleura and interlobular septa with serofibrinous exudation and infiltration of polymorphs and mononuclear cells with varying degree of interstitial pneumonia and mild lymphangitis. The alveoli in the consolidated foci were dilated and severely packed with agregates of neutrophilic leukocytes. (Kasali and Ojo, 1981; Rosendal, 1981, 1984; Goncalves, 1984; Konsan et al., 1989; Srivastava, et al., 1989; Rahman and Singh, 1990a and Kumar et al., 1994).

(iii) Haemorrhagic bronchopneumonia :

Acute haemorrhagic bronchopneumonia is commonly observed in acute toxaemic, septicaemic and viraemic conditions. The incidence varied from 3.06 to 11.5 per cent (Kolte, 1963; Bhagwan and Singh, 1972; Upadhyaya, 1983; Alka-Sharan et al., 1986; Naik et al., 1991b and Upadhyaya and Rahman, 1993). Macroscopically,

it has a characteristic pattern of multiple, small bright red foci with feathery or indistinct borders, most commonly subpleural in the apical and cardiac lobes of the lungs. Microscopically, multifocal bronchiolitis, diffuse accumulation of erythrocytes in alveolar spaces and interstitial tissues along with a few mononuclear cells and varying engorgement of blood vessels were the common features. Macrophages laden with crystals of haemosiderin pigment either in alveolar lumina or in the peribronchial areas were also observed. Organisms isolated from haemorrhagic lesions were Pasteurella sp. (Ramachandran and Sharma, 1969; Banerjee, 1978; Naik et al., 1991b). E. coli (Banerjee, 1978); C. pseudotuberculosis and Muellerius sp. (Young and Griffith, 1985).

(iv) Necrotizing bronchopneumonia :

The incidence of acute necrotizing bronchopneumonia varied from 0.82 to 10 per cent (Ahuja et al., 1985 and Naik et al., 1991a). Macroscopically, the lesions were characterized by wide areas of coagulative necrosis which appeared as irregular but sharply demarcated boundaries with cavitation and crumbly deep red central zones. Microscopically, the lesions consisted of wide areas of necrosis containing large number of bacteria particularly at the margins of the lesions. The inflammatory cells with elongated nuclei as oat shaped cells alongwith the fibrin were observed in alveoli. It was commonly observed as a result of rapid and massive proliferation of organisms like Pasteurella sp. and Spherophorus necrophorus which cause extensive necrosis due to the production of endotoxins and leukotoxins in animals whose pulmonary defence has been compromised by various environmental stresses and often a predisposing viral infection (Runnels et al., 1965; Young and Griffith, 1985; Fordor et al., 1990; Dubey et al., 1992 and Jubb et al., 1993).

Goncalves (1984) also reported lesions of necrotizing pleuropneumonia in a goat associated with Mycoplasma mycoides subsp. mycoides (LC) type infection.

B. **Chronic form :**

(i) Chronic non-suppurative bronchopneumonia :

Acute bronchopneumonia becomes chronic when the causal agents elicit inadequate response by the body, not sufficient to eliminate the irritant though it weakens the irritant. Such an agent continues to act in subdued manner and the reaction goes into chronic stage. Its incidence varied from 5.31 to 60.00 per cent as reported by various workers (Banerjee, 1978; Abubakr et al., 1981; Naik et al., 1991b and Upadhyaya and Rahman, 1993). Macroscopically, the lungs showed areas of grey hepatization along with the presence of exudate in the bronchial lumen. The lung gave the feeling of a contracted and indurated structure. Microscopically, the lesions were characterized by the thickening of the interalveolar/interlobular septa, proliferation of fibroblast and infiltration of lymphocytes, plasma cells and macrophages. A wide variety of organisms have been incriminated in the development of the chronic lesions viz. Staphylococcus aureus and Streptococcus sp.. (Abubakr et al., 1981); E. coli (Upadhyaya and Rahman, 1993), Pasteurella sp.. (Ola Cjo, 1976 and Dubey et al., 1992). Ivetic et al. (1989) while examining lung sections of 5 pneumonic goats. observed one case of exudative pneumonia having giant cells in the exudate.

2. SUPPURATIVE PNEUMONIA

(i) Acute suppurative bronchopneumonia :

It was mostly encountered in apical, cardiac and antero-ventral diaphragmatic lobes and its incidence varied from 0.15 to 88.5 per cent as reported by various workers (Bhagwan and Singh, 1972; Banerjee et al., 1984; Garg, et al., 1985; Alka-Sharan et al., 1986; Naik et al., 1991b and AlDarraji and AlJoboury, 1993). Macroscopically, multiple white foci to small abscesses of varying size mostly at the cardiac, apical and in the extreme cases, the entire lobes of the lung converted into a large abscess. On cutting revealed greenish-yellow cheesy pus. Microscopically, lesions consisted of suppurative areas having central zone of necrosis, caseation with dead and disintegrated neutrophils surrounded by polymorphs and occasionally mononuclear cells. The architecture of the lung parenchyma was lost. Blood vessels in the vicinity of the affected areas were congested. A large number of Gram positive pleomorphic coccobacilli were found in and around necrotic zones viz. Corynebacterium sp., Eicherchia coli, Staphylococcus sp., Klebsiella sp. (Sambyal et al., 1980); Corynebacterium pyogenes (Ugochukwu, 1983); Corynebacterium sp., Pasteurella haemolytica (Young and Griffith, 1985); Staphylococcus aureus, E. coli (El. Mahdi and Bakier 1985).

(ii) Chronic suppurative bronchopneumonia :

Macroscopically, the lung contained multiple abscesses of varying size along with adhesion to pleura mostly at the antero-ventral portion of the lung. In general, the lung had a lumpy and nodular sensation on palpation. Microscopically, suppurative areas

were surrounded by a zone of extensive fibrous tissue reaction and mononuclear cell infiltration. Bronchi, bronchioles, alveoli and interstitial tissue spaces showed heavy infiltration of mononuclear cells admixed with neutrophils. In some cases, perivascular and peribronchiolar lymphoid aggregations were also noticed (Sarkar and Bhattacharya, 1975; Kaushik and Kalra, 1983; Young and Griffith, 1985 and AlDarraji and AlJoboury, 1993). A variety of pyogenic microorganisms isolated from such lesions by different workers were Klebsiella pneumoniae type 24 (Kaushik and Kalra, 1983); Corynebacterium ovis (Garg et al., 1985; Young and Griffith, 1985; AlDarraji and AlJoboury, 1993); Corynebacterium pyogenes (Ugochukwu, 1983); Pasteurella haemolytica (Ola Ojo, 1976); Pasteurella multocida (Ramachandran and Sharma, 1969); Staphylococcus aureus and E. coli (El-Mahdi and Bakier, 1985).

3. INTERSTITIAL PNEUMONIA

A. Acute form :

Diffuse or patchy injury to alveolar septa is the essential feature of interstitial pneumonia. The acute pulmonary injury usually associated with conditions such as viral pneumonia, chemical lung injury, shock and septicemia. Acute interstitial pneumonia is a common condition in goats and the lesions have been described by a number of workers who recorded its incidence varying from 1.22 to 41.00 per cent (Bhagwan and Singh, 1972; Bakr et al., 1980; Alka-Sharan et al., 1986; Ashraf et al., 1986; Metin et al., 1988; Naik et al. 1991(b) and Upadhyaya and Rahman, 1993). Macroscopically, the lungs were voluminous and granular with grey hepatization. The lesions were distributed widely throughout the lungs, often

with greater involvement of dorsocaudal regions. Microscopically, the lesions consisted of the thickening of interalveolar septa with engorgement of blood vessels and infiltration of mononuclear cells and polymorphs in the alveolar interstitium were the main features. Alveolar macrophages alongwith serous exudation was invariably present in alveolar spaces (Gupta and Rajya, 1969; Banerjee and Gupta, 1978/1979; Patnaik and Nayak, 1984 and Jubb et al., 1993).

Afshar and Terleck, 1979; Obi, 1984; Lamontague et al., 1985 and Obi and Ibu, 1990 described the lesions produced by para-influenza type 3 virus in goat lungs and characterized them to acute interstitial pneumonia type. Hyperplasia of alveolar and bronchiolar epithelium along with syncytial type multinucleated giant cells in their epithelium were noticed.

Mycoplasma sp. caused lesions of acute interstitial pneumonia along with the exudative changes in alveoli and bronchioles. The lesions of interstitial pneumonia described by various workers were patchy to diffuse consolidation showing grey and red hepatization in apical, cardiac and diaphragmatic lobes. Plasma was thickened and covered with fibrinous mass along with the prominence of interlobular septa. Microscopically, the lesions were characterized by thickening of alveolar septa due to proliferation of mononuclear cells at places and interlobular septa thickening due to fibrinous exudate and perivascular and peribronchial accumulation of lymphoid cells. At places neutrophilic infiltration was also seen in air spaces. (Sharma and Bhalla, 1962; Sharma et al., 1978; Nayak and Bhowmik, 1988; 1990; Chaturvedi et al., 1991 and Kumar et al., 1994).

B. Chronic form :

Maedi -

Rajya and Singh (1964) suspected the case of maedi in goats for the first time in the country. The incidence varied from 0.5 to 4.09 per cent and has been recorded by various workers (Bhagwan and Singh, 1972; Smith et al., 1972; Dwivedi, 1971, 1974; Bloom and Jackson, 1975; Fiocre et al., 1980; Dawson, 1980; Nandi and Sarkar, 1981; Datta, 1983; Upadhyaya, 1983; Banerjee et al., 1984; Gueraud, 1984; Alka-Sharan et al., 1986; Mukherjee et al., 1989 and Randall et al., 1991). Macroscopically, lungs were bluish-grey enlarged, heavy and rubbery in consistency having rib indentations. Microscopically, thickening of alveolar walls with mesenchymal cells proliferation by forming lymphoid follicles along with perivascular and peribronchiolar lymphoid cuffing in a follicular pattern were the striking features. Intracytoplasmic inclusions were occasionally seen in alveolar macrophages and bronchial epithelial cells.

Chronic lymphocytic interstitial pneumonia due to ovine progressive pneumonia (O.P.P.) virus in a goat was also recorded by Randall et al. (1991). The lesions were characteristic of O.P.P. as in sheep. Dadhich and Sharma (1995) described the lesions of maedi in goats which revealed thickening of alveolar walls due to infiltration of lymphocytes and reticulum cells and causing sometimes fibrosis and the formation of nodules/aggregates in septal tissue around peribronchiolar and perivascular areas.

4. SPECIAL PNEUMONIA

(i) Viral Pneumonia (PI-3 type pneumonia) :

Rajya and Singh (1964) suspected the cases of PI-3 infection in goats. Subsequently, several workers reported viral pneumonias, under the heading 'Giant cell pneumonia' in various species without pinpointing the exact etiology. Banerjee and Gupta (1978/1979) reported the cases of viral pneumonia in goats and mentioned about the possibility of PI-3 viral involvement. Thereafter Afshar and Terlecki (1979) successfully produced the infection experimentally in goats with PI-3 virus of specifc species origin. Later on, a number of workers recorded the lesions of viral PI-3 type pneumonia in goats and recorded the incidence varying from 3.35 to 17.96 per cent (Obi, 1985; Lamontague et al., 1985; Obi and Ibu, 1990; Rahman and Singh, 1990b and Naik et al., 1991a). Macroscopically, the antero-ventral lobes mostly the apical, cardiac and diaphragmatic lobes were found consolidated with red to grey hepatization, on incision a few foci revealed muco-purulent exudate.

Microscopically, interstitial inflammatory reaction characterised by proliferation of septal cells, variable alveolar epithelialisation, perivascular and peribronchiolar lymphoid cuffing and hypertrophy and hyperplasia of bronchiolar epithelial cells were observed by various workers (Chauhan and Singh, 1972; Banerjee and Gupta, 1978/1979; Afshar and Terlecki, 1979; Rahman and Singh, 1990b and Naik et al., 1991a).

Afshar and Terlecki (1979) described the lesions of non-suppurative pneumonia with the lesions of interstitial pneumonia, giant cell bronchiolitis and pathognomonic inclusions in the bronchial epithelium.

Hyperplasia of alveolar and bronchiolar epithelium along with syncytial or multinucleated giant cells and intra cytoplasmic eosinophilic inclusions were noticed by Obi and Ibu (1990) and Naik et al. (1991a).

Rahman and Singh (1990b) described the microscopical lesions which revealed epithelialization and septal cell proliferation with both intracytoplasmic and intranuclear inclusions.

PI-3 virus was important as a initiating factor in the causation of pneumonia, but incapable of inducing pneumonia by itself and only in association with Pasteurella haemolytica was a major cause of pneumonia in goat (Obi, 1984 and Sarr et al., 1984).

(ii) Pulmonary adenomatosis (Jaagziekte) :

Ramachandran (1959) reported that pulmonary adenomatosis was communicable to goats under natural conditions from sheep. Dwivedi (1971, 1974), Bhagwan and Singh (1972), Banerjee and Gupta (1978/1979), Sri-Raman et al. (1982), Datta (1983), Metin et al. (1988), Naik et al. (1991a) and Dadhich and Sharma (1995) recorded the lesions of pulmonary adenomatosis in goats and its incidence varied from 0.13 to 1.5 percent.

Macroscopically, the lesions were mostly confined to lungs featuring nodular to diffuse consolidation of various lobes specially the caudal angle of diaphragmatic lobes. The lesions were harder in consistency, greyish-white in colour and excessively moist containing granular material inside. Microscopically, multicentric foci of cuboidal to columnar alveolar cell lining with papilliform pro-

jections along with bronchial and bronchiolar epithelial hyperplasia were the common features. Intracytoplasmic inclusion bodies in the alveolar macrophages and exfoliated cells arranged in bundles were also noticed (Damodaran, 1960; Rajya and Singh, 1964; Rahman and Iyer, 1979; Banerjee and Gupta, 1979, Dubey et al., 1985; Naik et al., 1991a and Upadhyaya and Rahman, 1993).

Datta (1983) and Dadhich and Sharma (1995) observed interstitial pneumonia along with the presence of alveolar epithelial metaplasia forming glandular structures.

(iii) Mycoplasmal pneumonia :

Longley (1940) was the first to reproduce the disease in goats by inoculating the pneumonic lung emulsion from CCPP cases. The mycoplasmal pneumonic lesions have been recorded by various workers (Iyer, 1966; Iyer et al., 1968; Sharma et al., 1978; Bolske et al., 1983; Gupta and Verma, 1984; Gupta et al., 1984, 1988; Mohan and Uzoukwu, 1985; Nascimento et al., 1986; Uppal et al., 1987; Mukherjee et al., 1990 and Brandao, 1995) and their incidence varied from 9.94 to 30.00 per cent and mortality recorded was from 80 to 100 per cent.

Macroscopically, straw coloured fluid with flakes of fibrin in the thoracic cavities along with thickened pleura and fibrinous adhesions were encountered. Pneumonic consolidation in almost all the lobes in form of red and grey hepatization with prominently thickened interlobular septa which imparted marbled appearance to lungs on cutting were commonly noticed. Microscopically, pleura and interlobular septa revealed edema, fibrinoid thickening of stromal

tissue and engorged blood vessels and lymphatics. Proliferative changes of the intersititium, peribronchial lymphoid tissue and mucosal epithelial lining of the bronchi and bronchioles were noticed. Alveoli and interalveolar, interlobular septa were dilated with serofibrinous exudate and mononuclear cells infiltration (Sharma and Bhalla, 1962; Sharma et al., 1978; Goncalves, 1984; Guha and Verma, 1987; Nayak and Bhowmik, 1988, 1990; Bolske et al., 1989; Chaturvedi et al., 1989, 1994; Srivastava et al., 1989; Rahman and Singh, 1990a; Mukherjee et al., 1990; Basanti et al., 1992; Thiarcourt et al., 1992; Weronga et al., 1993; Kumar et al., 1994; Bhowmik et al., 1995 and Brandao, 1995). Nayak and Bhowmik (1990) reported that goat flea (order Siphonaptera) act as a possible vector for the transmission of caprine mycoplasmosis.

Martrenchar et al. (1995) isolated M. mycoides subsp. mycoides LC and M. ovipneumoniae from goats for the first time in Northern Cameroon. Experimental inoculation with M. mycoides subps. mycoides L.C. induced death in inoculated goats with pneumonic symptoms, whilst M. ovipneumoniae was not pathogenic despite its multiplication in the upper respiratory tract (nasal sinuses). Necropsy observations of infected animals included areas of pulmonary hepatization with macroscopic thickening of the interlobular septa in one goat while invasion of the lungs by numerous small abscesses with no macroscopic thickening of the interlobular septa in the other animals.

(iv) Verminous pneumonia :

Lung-worm infestation was generally recognized as a contributory factor for certain percentage of mortality in goats in

different parts of the world particularly during winter months (Kolte, 1963; Tiwari et al., 1975; Sadana et al., 1979; Upadhyaya et al., 1983; Goltz, 1986; Metin et al., 1988; Naik et al., 1991 and Singh et al., 1995). The incidence recorded varied from 6 to 16.32 per cent (Banerjee et al., 1984 and Alka-Sharan et al., 1986). Macroscopicaly, wedge shaped greyish-white areas varying in number were seen on the dorsal surface and posterior border of diaphragmatic lobe. Microscopically, the worms and larvae with cellular debris were seen in large bronchioles and parasitic larvae and embryonating eggs were seen in the alveoli and smaller bronchioles. Alveolar walls were thickened due to infiltration of mononuclear cells especially eosinophils and fibroblastic proliferation in some cases. At places, bronchiolar epithelium was slightly hyperplastic. Peribronchiolar lymphoid hyperplasia along with infiltration of macrophages and foreign body giant cells around intact or degenerated ova were commonly present. In most of the cases, the causative parasites identified were mainly Dictyocaulus filaria, Muellerius sp. and Protostrongylus sp. (Sambyal et al., 1980; Upadhyaya et al., 1983; Alka-Sharan et al., 1986; Sharma, 1994 and Singh et al., 1995).

Ivetic et al. (1989) while examining the lungs of goats that died in cooperative farms in Bosnia and Herzegovina found lung-worm lesions, larvae and eggs in 74 per cent of pneumonic lungs. Sharma (1994) observed the prevalence of parasitic bronchitis to the tune of 18.7 to 47.6% in different regions of Himalayas (J&K, HP and UP). Main parasites identified were Dictyocaulus filaria, Mullerius sp. and Protostrongylus sp.

5. GRANULOMATOUS PNEUMONIA

(i) *Pulmonary Aspergillosis :*

Granulomatous pneumonias due to Aspergillosis and their lesions have been described by number of workers and the incidence varied from 0.29 to 1.53 per cent (Chauhan and Dwivedi, 1974; Sharma and Dwivedi, 1977; Emaneulson et al., 1978; Ikede, 1978; Singh, 1979a, 1979b; Lal Krishna and Kulshrestha, 1984; Chattopadhyay et al., 1986, 1992; Sikdar et al., 1989 and Jubb et al., 1993). Macroscopically, the lesions varied from single or multiple millet to almond sized greyish-white nodules deeply seated in lung parenchyma which on cutting revealed thick discoloured pus. Microscopically, the lesions consisted of short celled, swollen and branching hyphae surrounded by polymorphonuclear cells, cellular debris, macrophages, epithelioid and giant cells with fibrous connective tissue at periphery of nodules. In few cases hyphae were found in pleural and peritoneal membranes. Singh et al. (1995) described the granulomata formation in pulmonary aspergillosis which was infiltrated with mononuclear cells and macrophages but rare giant cells.

Emaneulson et al. (1978) reported granulomatous fungal diseases in a Tur goat.

Ikede (1978) observed that Aspergillus organisms were the potent invadors of lung parenchyma in Niegerian goats along with other conventional pneumonic agents.

Chandler et al. (1980) while discussing the pathogenesis of aspergillosis mentioned that tissues reponses in primary and secon-

dary invasive aspergillosis were generally purulent inflammation and necrotising reaction. They opined that extensive necrosis occured in aspergillosis, probably due to both vascular destruction and toxin production by the invading organisms.

(ii) Pulmonary tuberculosis :

Tuberculosis is a rare disease in goats but the lesions of pulmonary tuberculosis have been recorded by various workers (Iyer, 1932; Sahai and Dhanda, 1942; Nanda and Singh, 1943; Radhey Mohan, 1950; Charan et al., 1973; Sharma and Dwivedi, 1978; Singh, 1979a; Sharma et al., 1985; Mukherjee et al., 1988 and Bernabe et al., 1990; and the incidence varied from 0.62 to 2.04 per cent. Macroscopically, the lesions described were single to multiple, greyish-white, slightly raised caseous/caseocalcified nodules ranging from pea to walnut size in various lobes of both lungs. Few cases had pleural adhesions. Microscopically, nodular lesions revealed central area of caseative necrosis, occasional calcification infiltration of lymphocytes, macrophages, Langhan's type giant cells surrounded by connective tissue proliferation forming capsule. In some cases cavitation was observed in bronchial and bronchiolar walls which formed ulcers and exudate in the bronchial lumen. The lesions of the lungs revealed presence of acid-fast bacilli indistinguishable from Mycobacterium tuberculosis.

6. OTHER PULMONARY AFFECTIONS

(i) Pulmonary oedema :

Pulmonary oedema was frequently seen as a result of cardiac abnormalities or in the terminal stages of illness and in hypoproteinaemia, shock etc. (Runnels et al., 1965).

Macroscopically, the lungs were enlarged, heavier than normal and contained large amount of blood, especially when passive hyperaemia was present. On incision white foamy fluid oozed out from the cut surfaces. Microscopically, the transudate was accumulated in bronchi/bronchioles and alveoli with occasional trapped air bubbles (Runnels et al., 1965; Naik et al., 1991a and Jubb et al., 1993).

Pulmonary oedema in goats was induced experimentally by I/V infusion of 3-methyl indole. This substance caused glycogen accumulation in alveolar type II cells and this defect might interfere with surfactant production and cause pulmonary oedema (Atwal and Bray, 1981).

(ii) Pulmonary haemorrhages :

Haemorrhages occurred in the interstitial tissue, alveoli bronchioles and bronchi. These were caused in a variety of pathological conditions like infarction, ruptured aneurysms and trauma (Jubb et al., 1993). During slaughter, haemorrhages occurred in the upper respiratory tract and inhaled and filled the alveoli and bronchioles/bronchi with blood (Runnels et al., 1965).

Macroscopically, the haemorrhagic lesions had a characteristic pattern of multiple small bright red foci with feathery or indistinct borders to wide irregular areas (Jubb et al., 1993). Microscopically, the alveoli, bronchioles and bronchi contained a large number of erythrocytes along with the accumulation of erythrocytes in interstitial spaces (Runnels et al., 1965 and Naik et al., 1991a).

Ramachandran and Sharma (1969) observed petechial to echymotic haemorrhages in experimental pneumonic lesions caused by pasteurella sp.

(iii) Brown induration :

Chronic passive congestion often produced brown induration (Hemosiderosis) of the lung (Jones and Hunt, 1983).

Macroscopically, the lungs were indurated and hard in consistency, enlarged and dark red in colour. On incision, the blood oozed from the cut surface. The cut surfaces were dark red, smooth and moist. Microscopically, the capillaries were distended and engorged with blood in the interalveolar septa and interstitial spaces. Alveoli were filled with macrophages containing haemosiderin and often fibrosis of alveolar septa was noticed (Naik et al., 1991a).

(iv) Pulmonary emphysema :

Emphysema in its widest sense refered to the tissue puffed up by air or gas. Generally two forms occurred, the alveolar emphysema, where the excessive amount of air was found within the alveo-

lar spaces and the interstitial emphysema where the air was found within the interlobular, subpleural and other major interstitial areas of the lung tissue (Jubb et al., 1993). The incidence of emphysema recorded was 5.10 and 4.40 per cent by Alka-Sharan et al., 1986 and Naik et al., 1991a respectively. Macroscopically, the lungs were enlarged and voluminous, paler than normal having indentation of ribs. There were crepitating sounds on handling and lungs had a smooth dry cut surfaces. Microscopically, the greatly enlarged alveoli, formation of giant alveoli with very thin alveolar walls and a mild bronchitis with hyperplasia of the lymphoid tissue were noticed (Carlson et al., 1975; Eigenmann et al., 1979, Alka-Sharan et al., 1986 and Naik et al., 1991a).

(v) Hydatidosis :

Bhalerao (1935) was the first worker to report on hydatid cysts of goats in undivided India. Subsequently, the condition was described by various workers (Kolte, 1963; Banerjee, 1978; Dada and Belino, 1979; Aul and Islam, 1981; Upadhyaya et al., 1983; Naik et al., 1991 b and Sharma, 1994). Upadhyaya et al. (1983) and Naik et al. (1991b) reported 7.5 and 9.39 per cent incidence of this condition, respectively. Macroscopically, the affected lungs showed pea to walnut size single to multiple cystic structures, mostly in the diaphragmatic lobes of lungs. The cysts were elevated, glistening, whitish coloured, fluctuating on palpation and contained clear or watery fluid. Microscopically, the main lesions characterised by a central laminated cyst wall and necrotic zone infiltrated with polymorphs, eosinophils mononuclear cells, epitheloid cells and Langhan's type giant cells surrounded by fibrous connective tissue reaction.

MATERIALS AND METHODS

MATERIALS AND METHODS

A total of 9432 lungs from goat carcasses were screened for pathomorphological alterations in the present study during the period from March, 1995 to May, 1996. These animals were slaughtered at army and civil abattoirs, Bareilly (U.P.), Delhi, Jodhpur (Rajasthan), Palampur, Dharamsala, Yol, Dagshai and Solan (Himachal Pradesh), Siliguri, Bagdogra, Jalpaiguri (West Bengal) and Gaya, Danapur (Bihar) (Table 1). Lungs of goat carcasses received for necropsy examination at the postmortem room of Division of Pathology, IVRI, Izatnagar (U.P.) were also incorporated in the study.

The lungs were examined for gross abnormalities and observations as regards to type and extent of the lesion, their colour and consistency, type and nature of exudate and characteristic features of the cut surfaces were recorded. Tissue pieces from the affected lungs were collected in 10% neutral formol saline for histopathological studies. Representative tissue pieces suspected for mycoplasma cases were collected in vandegrift's solution for demonstration of Mycoplasma. Smears from selected cases were prepared from the cut surfaces of lesions to demonstrate etiological

Table 1 : Goat lungs examined and collected from different places

Sl. No.	Place	Lungs Examined	Specimens collected
1.	BIHAR		
	Gaya/Danapur	1188	25
2.	CHANDIGARH	341	9
3.	DELHI	1884	43
4.	HIMACHAL PRADESH	988	56
	Dagshai/Solan	223	11
	Dharamsala/Yol Camp	155	11
	Palampur/Holta Camp	610	34
5.	RAJASTHAN		
	Jodhpur	366	24
6.	UTTAR PRADESH		
	Bareilly	3880	243
7.	WEST BENGAL		
	Siliguri/Bangdubi Jalpaiguri	785	29
	Total	9432	429

agent(s) by special staining techniques viz. Gram's method for gram positive and gram negative bacteria, Giemsa's method for Chlamydia and Ziehl Neelsen's method for acid fast bacteria.

Suitable materials from the affected lungs were also collected under aseptic conditions for isolation of bacteria and mycoplasma if any.

A. Histopathological Study :

Tissues preserved in 10% formol-saline solution were processed, washed thoroughly under running water for several hours, dehydrated in ascending grades of alcohol, cleared in turpentine oil and embeded in paraffin wax (melting point 60°C) for making tissue blocks. Sections (4-5 microns thickness) were cut and stained with haematoxylin and eosin technique for histopathological examination (Culling, 1963). Wherever necessary, duplicate sections were subjected to the following special staining procedures to demonstrate various etiological agents viz. bacteria : Gram's method, MacCallum Good pasture's method, Brown and brenn method, Giemsa's method, mycoplasma : modified Brown and brenn method, Giemsa's method mycotic : Periodic acid Schiff (PAS) method, Gridley's method and Grocott's silver methanamine method and viral inclusions : Shorr's method (Luna, 1972).

As and when required duplicate sections were also stained with Perl's staining for the demonstration of haemosiderin pigment or with Masson's trichome staining for the demonstration of Fibrous connective tissue, reticulum fibres etc. (Luna, 1972).

B. Microbiological study :

(i) Isolation of Bacteria :

For isolation of bacterial organisms, specimens were processed and inoculated on Nutrient broth blood agar and Mac Conkey Agar plates and incubated at 37°C for 24-42 hours. The colonies suspected for bacterial organisms were transferred on blood agar plates for purification of culture. The isolates were identified on the basis of morphology and biochemical properties using standard technique as recommended by Cruickshank (1965) and Cowan et al. (1974).

(ii) Isolation of Mycoplasma :

The specimens were processed for the isolation of Mycoplasma organisms on liquid as well as on solid mycoplasma medium. These were incubated at 37°C and observed daily for the presence of growth. The growth of Mycoplasma was suspected when the liquid medium showed a change in pH towards acidic side (Change in colour from red to yellow with very slight turbidity) and fried egg like colonies on solid mycoplasma medium. The isolates were identified on the basis of various biological and biochemical characteristics using standard techniques (Alluotto, et al., 1970).

RESULTS

RESULTS

INCIDENCE:

In the present investigation, 9432 goat lungs were screened at different places of North and Eastern regions of the country, out of which, 429 specimens showed gross pulmonary lesions indicating an overall incidence of 4.55%. The details of animals showing lung affections of different places are summarised in Table 2.

Various types of pulmonary affections were categorized based on pathomorphological examination of 429 lung specimens and their distribution presented in Table 3. Out of 429 cases, 374 specimens revealed various pneumonic lesions (3.97%) comprising of bronchopneumonia in 211 (49.18%); suppurative pneumonia in 64 (14.92%); interstitial pneumonia in 26 (6.06%); special pneumonias in 68 (15.85%) and granulomatous pneumonia in 5 cases (1.16%). The area wise occurrence and details of various pulmonary conditions is depicted in Table 4. It is evident from the above Table (4) that the occurrence of acute fibrinous pneumonia was almost similar in U.P., Rajasthan, Himachal Pradesh, West Bengal and Bihar; suppu-

rative pneumonia more prevalent in Delhi and Bihar in comparison to North Bengal, Himachal Pradesh and Rajasthan; verminous pneumonia higher in H.P. and Pulmonary adenomatosis more in Delhi.

BACTERIOLOGICAL STUDIES :

Thirty four lung specimens suspected to be of bacterial involvement were subjected to bacteriological study. The morphological and biochemical characteristics of the isolates recovered from pulmonary affections are presented in Table 5. The bacterial isolates from different pneumonic conditions are summarised in Table 6.

21 specimens were processed for the isolation of Mycoplasma organisms. Two of these samples showed change in pH towards acidic side on liquid medium and fried egg colonies on solid media. The cultures did not revert back to bacteria when subcultured successively on mycoplasma liquid medium without inhibition and was found to be sensitive to digitonin. On the basis of various biological and biochemical tests both the cultures were found to be of 'genus Mycoplasma'. The two organisms when put to growth inhibition test using disc impregnated with the antisera of M. capri, M. ovipneumoniae, M. agalactiae, M. arginine, M. alkalisens, M. mycoides (LC type), M. capricolum, Mycoplasma F-38 and M. conjunctivae did not show any zone of inhibition. Thus, out of 21 samples processed, only two cases (RPNS - 200 and RPNS - 216) revealed Mycoplasma sp. which could not be further typed with the serotypes available with the National Mycoplasma Referal Laboratory at IVRI Izatnagar (U.P.)

Table 2 : Number of goat lungs examined at different abattoirs.

Sl. No.	Place	Lungs examined	Lungs showing gross lesions	Incidence percentage
1.	BIHAR			
	Gaya/Danapur	1188	25	2.10
2.	CHANDIGARH	341	9	2.64
3.	DELHI	1884	43	2.28
4.	HIMACHAL PRADESH	988	56	5.67
	Dagshai/Solan	223	11	4.93
	Dharmsala/Yol Camp	155	11	7.10
	Palampur/Holta Camp	610	34	5.57
5.	RAJASTHAN			
	Jodhpur	366	24	6.56
6.	UTTAR PRADESH			
	Bareilly	3880	243	6.26
7.	WEST BENGAL			
	Siliguri/Bangdubi/ Jalpaiguri	785	29	3.69
	Total collected	9432	429	
	Overall incidence	9432	429	4.55

Table 3 : Incidence of various histopathological conditions encountered among goats

Sl. No.	Type of conditions	No. of animals showing lesions	Percentage
1.	BRONCHOPNEUMONIA	211	49.18
A.	Acute non suppurative	188	43.82
	i. Catarrhal bronchopneumonia	58	13.52
	ii. Fibrinous bronchopneumonia	99	23.08
	iii. Haemorrhagic bronchopneumonia	10	2.33
	iv. Necrotizing bronchopneumonia	21	4.89
B.	Chronic non suppurative bronchopneumonia	23	5.36
2.	SUPPURATIVE PNEUMONIA	64	14.92
A.	Acute suppurative pneumonia	24	5.60
B.	Chronic suppurative pneumonia	40	9.32
3.	INTERSTITIAL PNEUMONIA	26	6.06
A.	Acute interstitial pneumonia	7	1.63
B.	Chronic interstitial pneumonia	19	4.43
4.	SPECIAL PNEUMONIAS	68	15.85
	i. Viral pneumonia (PI-3 type)	27	6.29
	ii. Pulmonary adenomatosis	8	1.86
	iii. Mycoplasmal pneumonia	7	1.63
	iv. Verminous pneumonia	25	5.82
	v. Giant cell pneumonia	1	0.23
5.	GRANULOMATOUS PNEUMONIA	5	1.16
A.	Pulmonary Aspergillosis	1	0.23
B.	Pulmonary Tuberculosis	4	0.93
6.	OTHER PULMONARY AFFECTIONS	55	12.82
	i. Pulmonary oedema	4	0.93
	ii. Pulmonary haemorrhage	9	2.09
	iii. Brown induration (Haemosiderosis)	1	0.23
	iv. Pulmonary Emphysema	5	1.16
	v. Hydatidosis	36	8.39

Table 4 : Distribution of various pulmonary affections in different areas among goats

Sl. No.	Type of conditions	U. P.		Delhi		Rajasthan		Chandigarh		Himachal Pradesh		West Bengal		Bihar	
		No.of animals showing lesions	Per-centage	No.of animals showing lesions	Per-centage	No.of animals showing lesions	Per-centage	No.of animals showing lesions	Per-centage	No.of animals showing lesions	Per-centage	No.of animals showing lesions	Per-centage	No.of animals showing lesions	Per-centage
1.	BRONCHOPNEUMONIA														
A.	Acute non-suppurative														
i.	Catarrhal bronchopneumonia	38	15.64	1	2.31	4	16.69	1	11.11	6	10.71	7	24.14	1	4.00
ii.	Fibrinous bronchopneumonia	65	26.75	1	2.32	6	25.00	4	44.44	12	21.43	6	20.69	5	20.00
iii.	Haemorrhagic bronchopneumonia	5	2.06	1	2.32	-	-	-	-	2	3.57	2	6.90	-	-
iv.	Necrotising bronchopneumonia	13	5.35	2	4.65	2	8.33	-	-	1	1.78	-	-	3	12.00
B.	Chronic non-suppurative bronchopneumonia	13	5.35	3	6.98	2	8.33	-	-	2	3.57	2	6.90	1	4.00
2.	SUPPURATIVE PNEUMONIA	12	4.94	9	20.9	-	-	1	11.11	-	-	2	6.90	-	-
A.	Acute suppurative	25	10.29	2	4.65	1	4.17	-	-	5	8.93	1	3.45	6	24.00
B.	Chronic suppurative	-													
3.	INTERSTITIAL PNEUMONIA	4	1.65	1	2.32	-	-	-	-	1	1.78	1	3.45	-	-
A.	Acute interstitial	11	4.53	-	-	1	4.17	-	-	4	7.14	2	6.90	1	4.00
B.	Chronic interstitial														
4.	SPECIAL PNEUMONIA	16	6.58	3	6.98	2	8.33	2	22.22	4	7.14	-	-	-	-
i.	Viral pneumonia (PI-3 type)	-	-	6	13.95	-	-	-	-	-	-	1	3.45	1	4.00
ii.	Pulmonary adenomatosis	5	2.06	-	-	-	-	-	-	1	1.78	1	3.45	-	-
iii.	Mycoplasmal pneumonia	5	2.06	2	4.65	2	8.33	-	-	15	26.78	1	3.45	-	-
iv.	Verminous pneumonia	1	0.41	-	-	-	-	-	-	-	-	-	-	-	-
v.	Giant cell pneumonia														

Continued.....

Sl. No.	Type of conditions	U. P.		Delhi		Rajasthan		Chandigarh		Himachal Pradesh		West Bengal		Bihar	
		No.of animals showing lesions	Per-cen-tage	No.of animals showing lesions	Per-cen-tage	No.of animals showing lesions	Per-cen-tage	No.of animals showing lesions	Per-cen-tage	No.of animals showing lesions	Per-cen-tage	No.of animals showing lesions	Per-cen-tage	No.of animals showing lesions	Percen-tage
5.	GRANULOMATOUS PNEUMONIA														
A.	Pulmonary Aspergillosis	1	0.41	-	-	-	-	-	-	-	-	-	-	-	-
B.	Pulmonary tuberculosis	2	0.82	-	-	-	-	-	-	-	-	-	-	2	8.00
6.	OTHER PULMONARY AFFECTIONS														
i.	Pulmonary oedema	-	-	2	4.65	-	-	1	11.11	1	1.78	-	-	-	-
ii.	Pulmonary haemorrhage	2	0.82	5	11.63	1	4.17	-	-	-	-	1	3.45	-	-
iii.	Brown Induration (Haemosiderosis)	1	0.41	-	-	-	-	-	-	-	-	-	-	-	-
iv.	Pulmonary emphysema	2	0.82	2	4.65	1	4.17	-	-	-	-	-	-	-	-
v.	Hydatidosis	22	9.05	3	6.98	2	8.33	-	-	2	3.57	2	6.90	5	20.00
TOTAL PULMONARY AFFECTIONS		243		43		24		9		56		29		25	-

Table 5 : Morphological and biochemical characteristics of isolates recovered from various pulmonary affections

Sl. No.	Sample No.	Gram's stain	Mort-ality	Oxi-dase	Cata-lase	Indole	MR	VP	Cit-rate	Ure-ase	Nit-rate	Gela-tine	Glu-cose	Lac-tose	Mani-tol	Suc-rose	Sali-cin	Sorb-itol	Arabi-nose	Malt-tose	Xyl-ose	Fruc-tose	Growth on Mac-Conkey	Results
1.	1/98	+ve rods	-	-	-	-	-	-	-	-	-	+	+	+	-	-	+	-	+	+	+	+	NA	Corynebacterium Pyogenes
2.	2/91	-ve rods	-	+	+	+	-	-	-	-	+	-	+	-	+	+	-	+	-	-	+	+	-	Pasteureila multocida
3.	3/106	-ve rods	-	+	+	+	-	-	-	-	+	-	+	-	+	+	-	+	-	-	+	+	-	-do-
4.	4/122	+ve cocci	-	-	+	-	+	+	-	+	+	-	+	+	+	+	+	-	+	+	-	+	NA	Staphylococcus aureus
5.	5/126	-ve rod	+	-	-	-	-	-	+	+	+	+	-	-	-	-	-	-	-	-	-	-	NA	Pseudomonas aeroginosa
6.	6/176	-ve rod	-	+	+	+	-	-	-	-	+	-	+	-	+	+	-	+	-	-	+	+	-	Pasterella multocida
7.	7/177	-ve rod	-	+	+	+	-	-	-	-	+	-	+	-	+	+	-	+	-	-	+	+	-	-do-
8.	8/182	-ve rod	-	+	+	+	-	-	-	-	+	-	+	-	+	+	-	+	-	-	+	+	-	-do-
9.	9/183	-ve rod	-	+	+	+	-	-	-	-	+	-	+	-	+	+	-	+	-	-	+	+	-	-do-
10.	10/186	+ve rod	-	-	+	+	-	-	-	-	-	+	+	+	+	-	+	+	+	+	-	+	NA	Corynebacterium Pyogenes and Pasteurella haemolytica
11.	11/190	-ve rod	+	-	-	+	+	-	-	-	+	-	+	+	+	+	-	+	+	+	-	+	-	Eicherchia Coli

Continued.....

Sl. No.	Sample No.	Gram's stain	Mort-ality	Oxi-dase	Cata-lase	Indole	MR	VP	Cit-rate	Ure-ase	Nit-rate	Gela-tine	Glu-cose	Lac-tose	Mani-tol	Suc-rose	Sali-cin	Sorb-itol	Arabi-nose	Malt-tose	Xyl-ose	Fruc-tose	Growth on Mac-Conkey	Results
12.	12/191	+ve rod	-	-	-	-	-	-	-	-	-	+	+	+	-	-	+	-	+	+	+	+	NA	Corynebacterium Pyogenes
13.	13/192	+ve rod	-	-	-	-	-	-	-	-	-	+	+	+	-	-	+	-	+	+	+	+	NA	-do-
14.	14/193	+ve rod	-	-	-	-	-	-	-	-	-	+	+	+	-	-	+	-	+	+	+	+	NA	Corynebacterium Pyogenes
15.	15/200	+ve rod	-	-	-	-	-	-	-	-	-	+	+	+	-	-	+	-	+	+	+	+	NA	-do-
16.	16/201	+ve rod	-	-	-	-	-	-	-	-	-	+	+	+	-	-	+	-	+	+	+	+	NA	-do-
17.	17/203	+ve rod	-	-	-	-	-	-	-	-	-	+	+	+	-	-	+	-	+	+	+	+	NA	-do-
18.	18/204	-ve rod	+	-	-	-	-	-	+	+	+	+	+	-	-	-	-	-	-	-	-	-	NA	Pseudomonas aeroginosa
19.	19/212	+ve cocci	-	-	+	-	+	+	-	+	+	-	+	+	+	+	+	+	-	+	+	-	NA	Staphylococcus aureus
20.	20/223	-ve rod	-	+	+	+	-	-	-	-	+	-	+	-	+	+	-	+	-	-	+	+	-	Pasteurella multocida
21.	21/217	+ve cocci	-	-	+	-	+	+	-	+	+	-	+	+	+	+	+	+	-	+	+	-	NA	Staphylococcus aureus
22.	22/218	+ve cocci	-	-	+	-	+	+	-	+	+	-	+	+	+	+	+	+	-	+	+	-	NA	-do-
23.	23/243	+ve cocci	-	-	+	-	+	+	-	+	+	-	+	+	+	+	+	+	-	+	+	-	NA	-do-

Continued.....

Sl. No.	Sample No.	Gram's stain	Mort-ality	Oxi-dase	Cata-lase	Indole	MR	VP	Cit-rate	Ure-ase	Nit-rate	Gela-tine	Glu-cose	Lac-tose	Mani-tol	Suc-rose	Sali-cin	Sorb-itol	Arabi-nose	Malt-tose	Xyl-ose	Fruc-tose	Growth on Mac-Conkey	Results
24.	23/233	-ve rods	-	+	+	+	-	-	-	-	+	-	+	-	+	+	-	-	-	+	+	-	-	Pasteurella multocida
25.	24/257	+ve rods	-	-	-	-	-	-	-	-	-	+	+	+	-	-	+	-	+	+	+	+	NA	Corynebacterium Pyogenes
26.	25/310	+ve rods	-	-	-	-	-	-	-	-	-	+	+	+	-	-	+	-	+	+	+	+	NA	-do-
27.	364	-ve rods	-	+	+	+	-	-	-	-	+	-	+	-	+	+	-	+	-	-	+	+	+	Pasteurella multocida
28.	365	-ve rods	-	+	+	+	-	-	-	-	+	-	+	-	+	+	-	+	-	-	+	+	+	-do-
29.	369	-ve rods	-	+	+	+	-	-	-	-	+	-	+	-	+	+	-	+	-	-	+	+	+	-do-
30.	372	-ve rods	-	+	+	+	-	-	-	-	+	-	+	-	+	+	-	+	-	-	+	+	+	-do-
31.	373	-ve rods	-	+	+	+	-	-	-	-	+	-	+	-	+	+	-	+	-	-	+	+	+	-do-
32.	375	-ve rods	-	+	+	+	-	-	-	-	+	-	+	-	+	+	-	+	-	-	+	+	+	-do-
33.	376	+ve rods	-	-	-	-	-	-	-	-	-	+	+	+	-	-	+	-	+	+	+	+	NA	Corynebacterium Pyogenes
34.	428	No significant growth obtained on BA and MacConkey.																						

Table 6 : Bacterial isolates in various pneumonic conditions

Sl. No.	Pathological Disorder	Name of Isolate	No.of cases	Specimen Nos.
1.	Acute fibrinous bronchopneumonia	Pasteurella multocida	10	RPNS - 91, 106, 176, 177, 183, 223, 233, 364, 365, 375
		Pasteurella haemolytica	1	RPNS - 186
		Corynebacterium pyogenes	2	RPNS - 186, 193
2.	Acute necrotizing bronchopneumonia	Corynebacterium pyogenes	1	RPNS - 201
		Pasteurella multocida	4	RPNS - 182, 369, 372, 373
3.	Acute suppurative bronchopneumonia	Corynebacterium pyogenes	1	RPNS - 192
		Staphylococcus aureus	3	RPNS - 122, 212, 243
		Pseudomonas aeruginosa	1	RPNS - 126
		E. coli	1	RPNS - 190
4.	Chronic suppurative bronchopneumonia	Corynebacterium pyogenes	6	RPNS - 91, 191, 203, 257, 310, 376
		Staphylococcus aureus	2	RPNS - 217, 218
		Pseudomonas aeruginosa	1	RPNS - 204
5.	Pulmonary mycosis	Corynebacterium pyogenes	1	RPNS - 98
6.	Pulmonary tuberculosis	No growth on blood agar MacConkey's Agar	1	RPNS - 428
7.	Mycoplasmal Pneumonia	Corynebacterium pyogenes	1	RPNS - 200
		Mycoplasma sp.	2	RPNS - 200, 216

PATHOMORPHOLOGICAL STUDIES :

Various types of pulmonary lesions encountered are as follows :

Bronchopneumonia :

(i) Acute catarrhal bronchopneumonia was encountered in 58 specimens - 13.52% (RPNS - 3, 4, 5, 7, 13, 14, 19, 22, 28, 30, 32, 34, 36, 39, 42, 47, 64, 66, 67, 72, 76, 77, 92, 109, 111, 117, 118, 120, 121, 127, 132, 138, 141, 142, 148, 157, 161, 165, 171, 187, 222, 225, 231, 238, 245, 252, 254, 260, 269, 275, 285, 289, 293, 294, 319, 377, 383 and 411).

Gross Pathology :

The lungs were congested with varying degree of hepatization in apical, cardiac and antero-venteral portion of diaphragmatic lobes. The consolidated areas were reddish-brown in colour and of liver like consistency. Patchy areas of emphysema were also seen in areas adjacent to the consolidated portions.

Histopathology :

The sections revealed severe engorgement of interalveolar capillaries and blood vessels. Serous exudation along with infiltration of predominantly the neutrophils and occasionally mononuclear cells was noticed in alveoli and interlobular septa. Bronchi and bronchioles contained bluish fibrinous exudate along with the presence of a large number of neutrophils and desquamated epithelial cells.

(ii) Acute fibrinous bronchopneumonia was encountered in 99 specimens - 23.08% (RPNS - 1, 8, 9, 15, 18, 20, 21, 27, 29, 31, 35, 37, 38, 43, 44, 45, 46, 65, 68, 70, 71, 74, 75, 83, 86, 91, 99, 100, 102, 103, 105, 106, 123, 124, 125, 128, 137, 139, 145, 147, 149, 166, 167, 172, 176, 177, 178, 180, 183, 184, 185, 186, 193, 195, 202, 205, 206, 214, 215, 221, 223, 228, 229, 233, 236, 237, 240, 241, 244, 246, 248, 265, 268, 270, 279, 287, 291, 292, 305, 308, 318, 357, 358, 362, 364, 365, 371, 375, 378, 381, 400, 406, 413, 414, 423, 424, 433, 441 and 445).

Gross pathology :

In general, bilateral consolidation of apical, cardiac and anteroventral part of diaphragmatic lobes and occasionally intermediate lobe was noticed. The consolidated areas had red and grey hepatization and were covered with thick greyish-white gelatinous exudate (Fig. 1). The cut surfaces revealed areas of congestion and consolidation with thickening and prominence of interlobular septa.

Histopathology :

The sections revealed thickening of interlobular septa with sero-fibrinous exudate and infiltration of polymorphs. The alveoli contained fibrinous exudate mixed with neutrophils. The bronchial and bronchiolar lumen were also filled with cellular exudate. Occasionally, the pleura was thickened with serofibrinous exudate and infiltration of neutrophils and a few mononuclear cells mainly the lymphocytes (Fig. 2). Peribronchial/peribronchiolar areas had mild to moderate mononuclear cell infiltraion in most of the cases. Fib-

rinous exudation with neutrophils and mononuclear cells along with haemorrhages and oat shaped cells were also seen in alveoli (Fig. 3). In most of the cases (48) serofibrinous exudate particularly the oat shaped cells formed whorls in the adjacent alveoli (Fig. 4 and 5) (RPNS - 9, 15, 20, 27, 31, 38, 65, 68, 83, 91, 102, 103, 105, 106, 124, 139, 166, 176, 177, 178, 180, 183, 184, 186, 195, 206, 214, 215, 221, 229, 233, 240, 241, 248, 270, 287, 305, 308, 318, 357, 364, 365, 375, 378, 400, 414, 423 and 433).

Special stained duplicate lung sections revealed [illegible] bipolar organisms morphologically indistinguishable from Pasteurella sp. (Fig. 6) in 46 cases (RPNS - 18, 27, 31, 38, 65, 68, 70, 91, 102, 103, 105, 106, 124, 139, 166, 176, 177, 178, 183, 186, 193, 195, 202, 205, 206, 214, 221, 223, 229, 233, 248, 270, 287, 305, 308, 318, 357, 362, 364, 365, 375, 378, 400, 411, 423 and 424).

Out of 34 samples, processed for bacterial isolation, 10 cases yielded pure culture of Pasteurella multocida (RPNS - 91, 106, 176, 177, 183, 223, 233, 364, 365, and 375), Corynebacterium pyogenes in one case (RPNS - 193), mixed infection of Pasteurella haemolytica and Corynebacterium pyogenes in another case (RPNS - 186).

(iii) Acute haemorrhagic bronchopneumonia was encountered in 10 specimens - 2.33% (RPNS - 110, 188, 224, 258, 281, 290, 302, 304, 324 and 325).

Gross Pathology :

The lungs were severely congested and showed patchy to diffuse areas of haemorrhages. The apical, cardiac and anterior

Fig. 1 Acute fibrinous pneumonia : Lung showing consolidation of right apical, cardiac and anteroventral diaphragmatic lobes with greyish-white exudate.

Fig. 2 Acute fibrinous bronchopneumonia : thickened pleura infiltrated with polymorphs and mononuclear cells. H & E x 63.

Fig. 3 Acute fibrinous bronchopneumonia : Haemorrhagic and fibrinous exudation in the alveoli. H & E x 100.

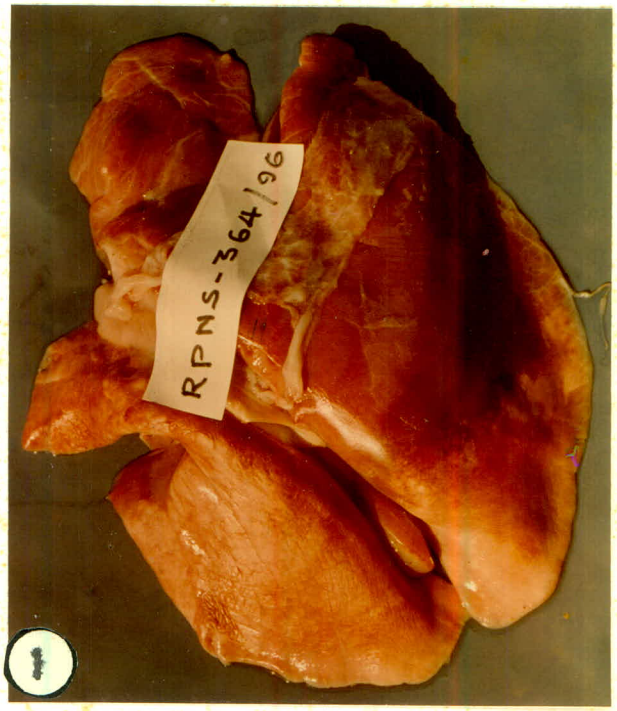
RPNS-364/96
1

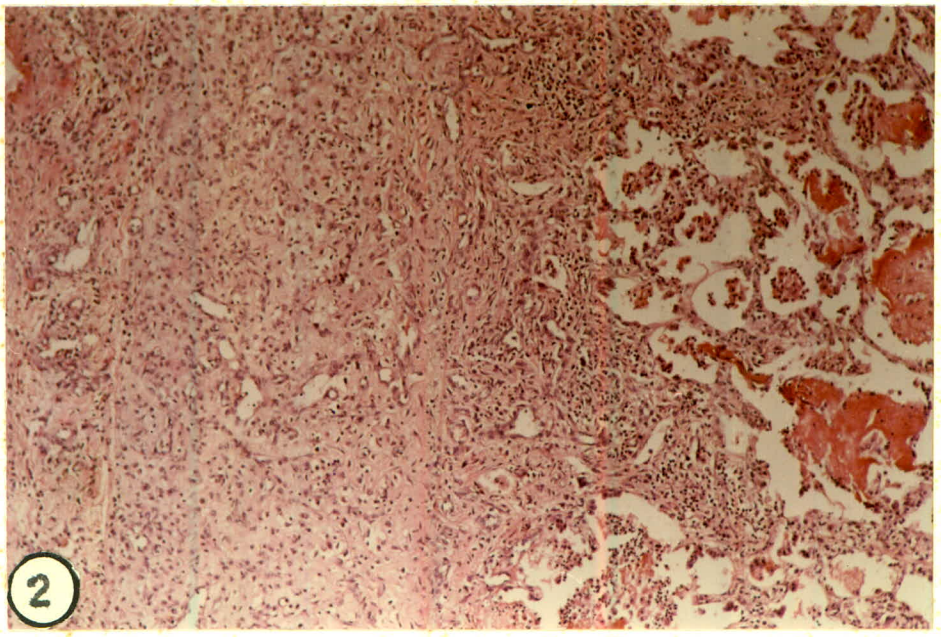
2

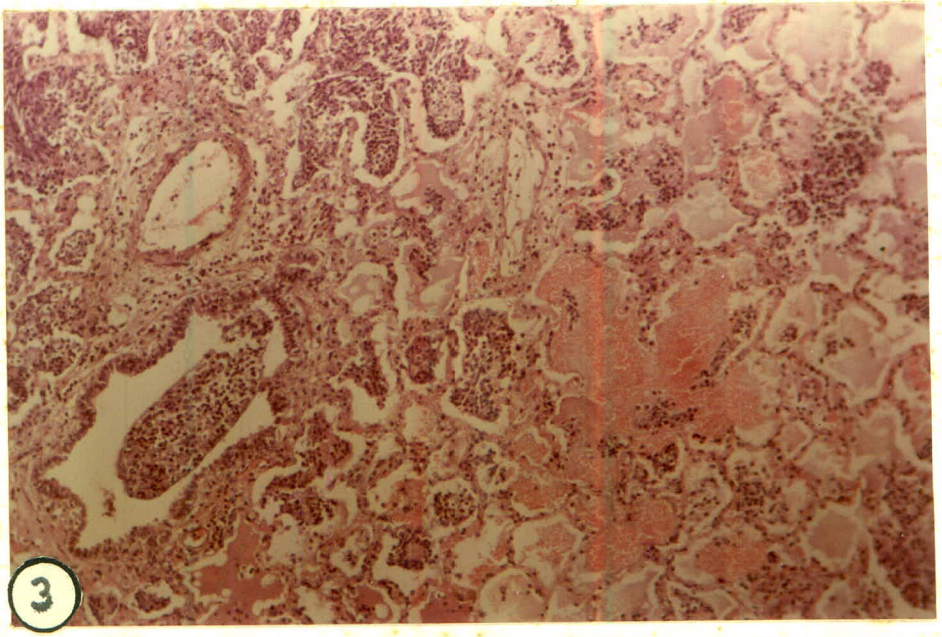
3

Fig. 4 Acute fibrinous bronchopneumonia : Fibrinous exudate with oat shape cells forming whorls in the adjacent alveoli. H & E x 100.

Fig. 5 Higher magnification of Fig. 4. H & E x 250.

Fig. 6 Biopolar pasteurella organism in lung section. Giemsa x 1000.

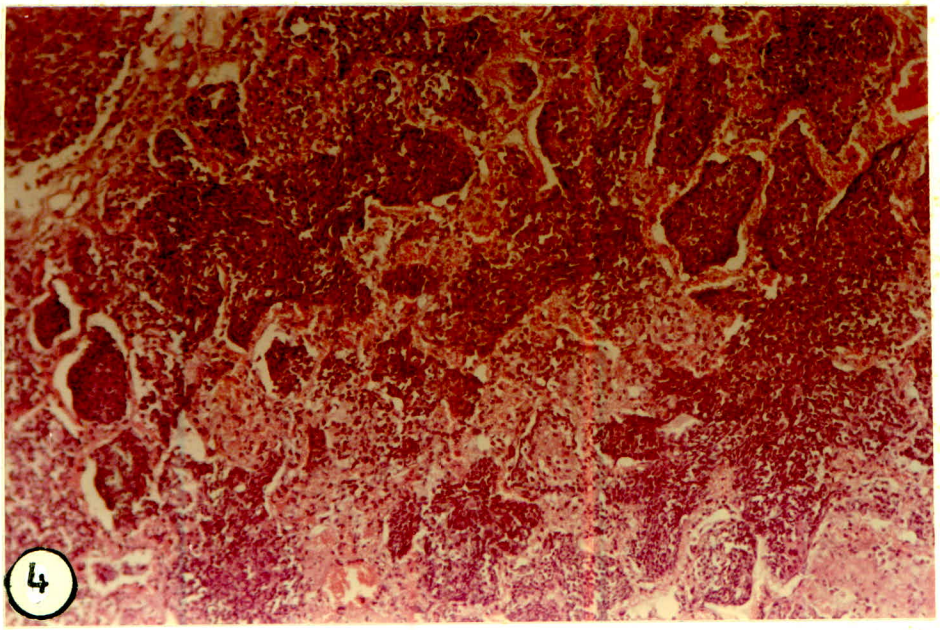
4

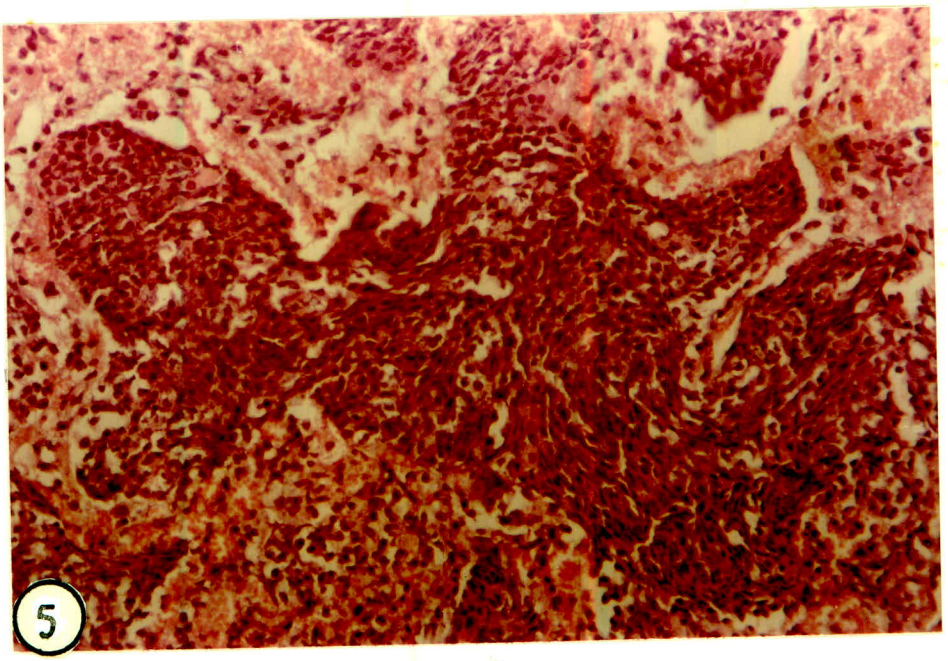
5

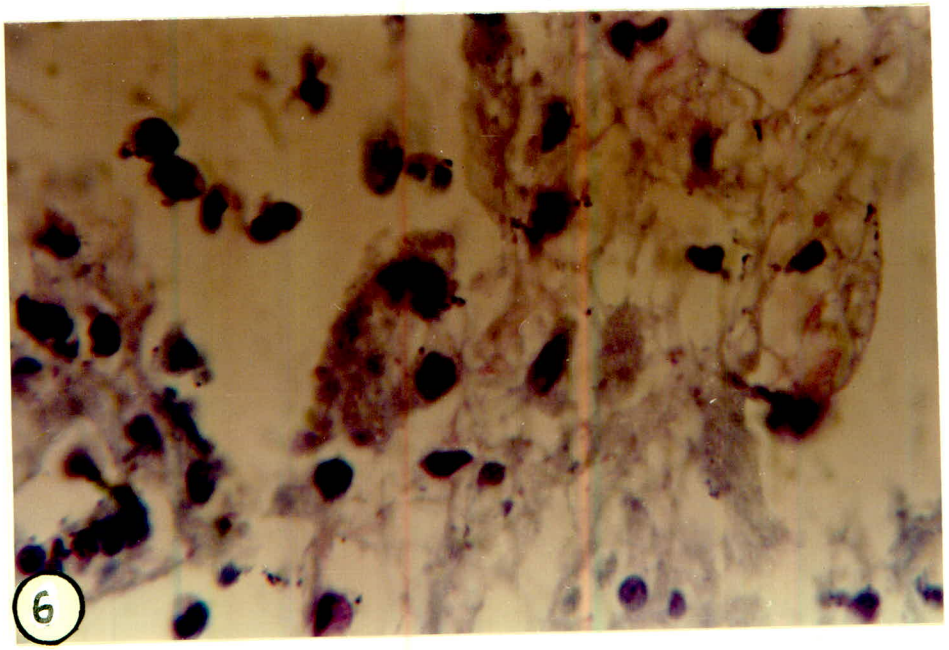
6

half of diaphragmatic lobes revealed areas of red hepatization. On incision, frothy fluid mixed with blood oozed out from the cut surfaces. The interlobular septae were prominent.

Histopathology :

The diffuse haemorhagic areas particularly in alveolar/ interlobular septa revealed engorgement of the blood vessels and extravasation of blood alongwith infiltration of neutrophils in alveoli. Bronchial and bronchiolar lumen also contained mucus exudate mixed with erythrocytes and neutrophils (Fig. 7). Five of the cases revealed fibrinous exudation with presence of RBCs and infiltration of neutrophils and mononuclear cells in the alveoli and peribronchial/ peribronchiloar areas (RPNS - 110, 224, 281, 302 and 325). bipolar organisms simulating Pasteurella sp. were demonstrated in tissue sections in one case (RPNS - 325). Bronchiolar epithelial hyperplasia along with peribronchial and peribronchiolar infiltration of polymorphs and mononuclear cells was noticed in two specimens (RPNS - 188 and 258).

(iv) **Acute necrotizing bronchopneumonia** was encountered in 21 specimens - 4.9% (RPNS - 2, 10, 136, 154, 182, 201, 213, 259, 261, 312, 350, 361, 363, 369, 372, 373, 382, 401, 402, 415 and 430).

Gross Pathology :

The red and grey hepatization was noticed in apical, cardiac and anteroventral portion of diaphragmatic lobes. On cutting, focal to diffuse irregular necrotic areas were distinct in the lung parenchyma.

Histopathology :

Wide irregular areas of necrosis with disintegrated neutrophils concentrated at the margins and the surrounding tissue revealed vascular engorgement and infiltration of polymorphs and mononuclear cells alongwith serofibrinous exudate. At places fibrinous mesh was identifiable in the necrotic area (Fig. 8). In some of the foci, the mononuclear cells assumed typical oat shaped cells in the alveoli with variable degree of degeneration and desquamation of cells in the bronchial and bronchiolar lumen was noticed. Duplicate sections in twelve cases on special staining revealed bipolar organisms indistinguishable from Pasteurella sp. (RPNS - 136, 182, 259, 261, 361, 369, 372, 373, 382, 401, 402 and 415) and bacterial isolation yielded Pasteurella multocida organisms in four cases (RPNS - 182, 369, 372 and 373) and Corynebacterium pyogenes in one case (RPNS - 201).

(v) **Chronic non-suppurative bronchopneumonia** was encountered in 23 specimens - 5.36% (RPNS - 11, 12, 16, 41, 56, 62, 81, 89, 144, 153, 169, 209, 211, 262, 267, 272, 277, 320, 327, 338, 412, 438 and 446).

Gross Pathology :

Grossly, varying degree of consolidation with grey hepatization was observed mostly in the apical, cardiac and diaphragmatic lobes. The consolidated areas were firm in consistency and cut surfaces were comparatively dry with little amount of thick fibrinous exudate.

Histopathology :

The sections revealed variable amount of fibrinous exudate in the interalveolar and interlobular septa with fibroblastic proliferation and infiltration of inflammatory cells predominantly the mononuclear cells. Occasionally, the inflammatory cells comprised of a few neutrophils, lymphocytes, macrophages and plasma cells. The bronchial and bronchiolar lumen were abundantly filled with mononuclear cells, alongwith degenerative changes in the epithelium with varying amount of fibrinous connective tissue around (Fig. 9). In ten cases, there was excessive thickening of pleura and interlobular septa due to infiltration of mononuclear cells and proliferation of connective tissues. Alveoli showed presence of fibrinous exudate and oat shaped cells (RPNS - 16, 41, 56, 89, 153, 262, 272, 277, 327 and 412).

Peribronchial and peribronchiolar mononuclear infiltration was seen in five specimens (RPNS - 56, 89, 262, 412, 438). In one case (RPNS - 446), catarrhal exudate admixed with neutrophils and mononuclear cells in bronchial lumen with connective tissue proliferation and infiltration of mononuclear cells was noticed in alveolar septa and interstitial tissue (Fig. 10). The sections stained with Giemsa technique revealed bipolar organisms morphologically indistinguishable from Pasteurella sp. in 13 cases (RPNS - 41, 56, 81, 89, 126, 169, 209, 262, 267, 272, 277, 412 and 438).

Fig. 7 Acute haemorrhagic bronchopneumonia : diffuse areas of haemorrhages with neutrophilic infiltration in the alveoli. H & E x 100.

Fig. 8 Acute necrotizing bronchopneumonia : fibrinous mesh in necrotic area. H & E x 100.

Fig. 9 Chronic nonsuppurative bronchopneumonia : Infiltration of mononuclear cells in alveoli and bronchiolar lumen and mild peribronchiolar fibrosis. H & E x 100.

Fig. 10 Chronic nonsuppurative bronchopneumonia : Catarrhal exudate, lymphocytes in the bronchial lumen and peribronchial lymphofollicular reaction. H & E x 63.

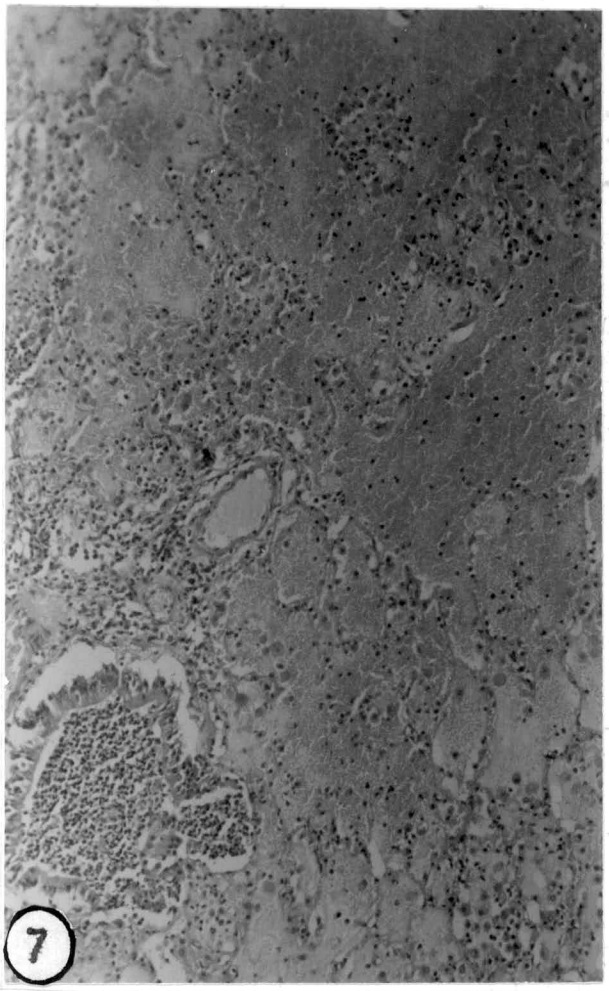
7

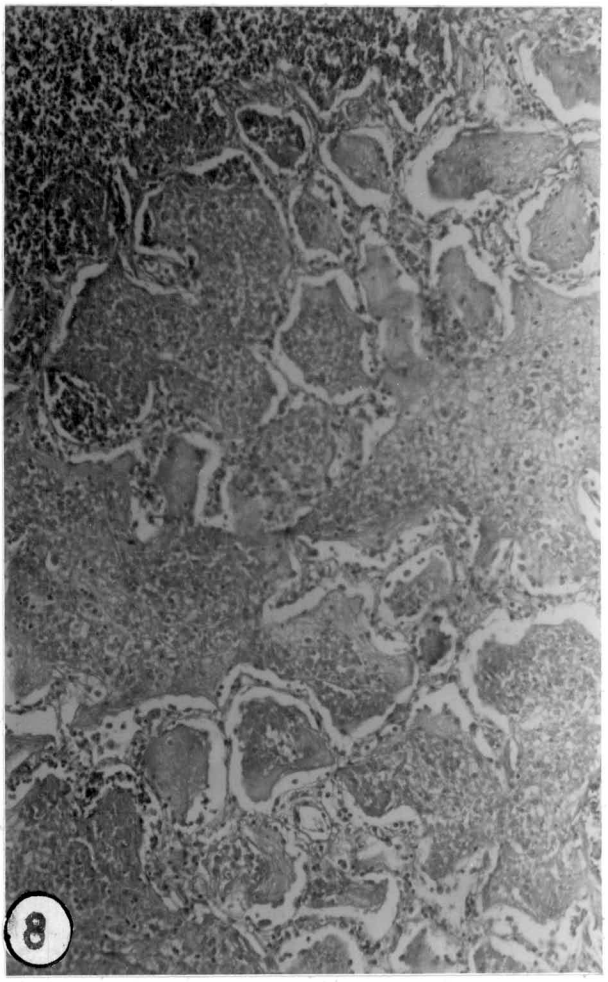
8

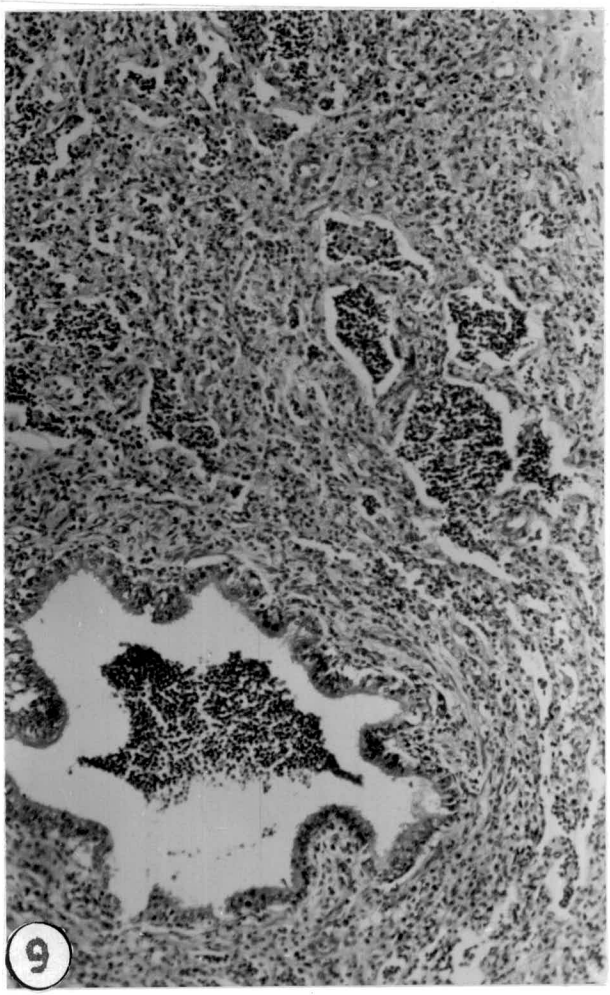
9

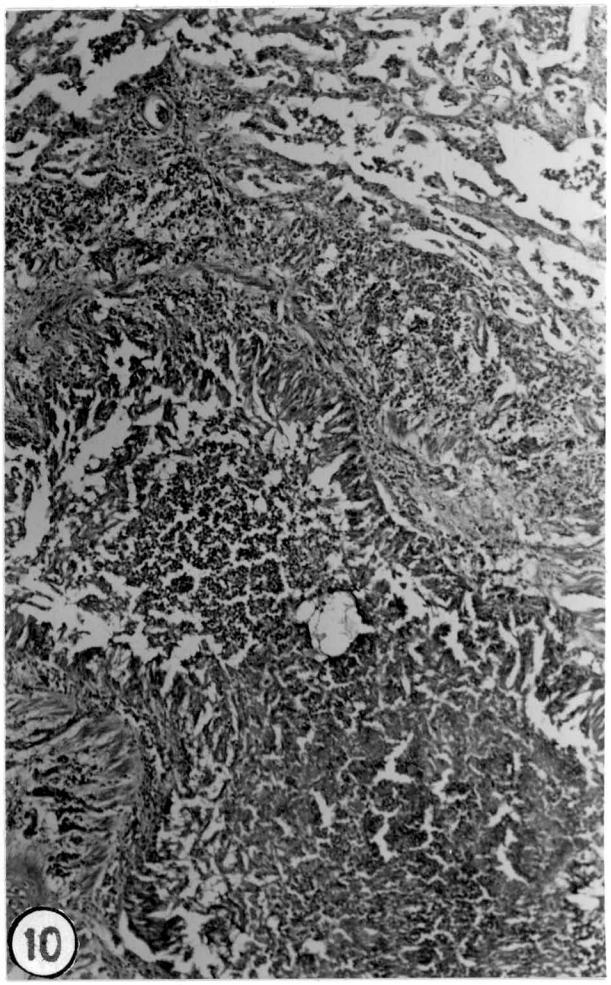
10

SUPPURATIVE PNEUMONIA

(i) **Acute suppurative pneumonia** was encountered in 24 specimens - 5.60% (RPNS - 6, 17, 116, 122, 126, 134, 190, 192, 210, 212, 243, 264, 274, 286, 329, 336, 339, 340, 346, 348, 349, 351, 353 and 370).

Gross Pathology :

The lung revealed areas of consolidation with variable sized single to multiple subpleural and deep seated abscesses in apical, cardiac and diaphragmatic lobes. On cutting, abscesses revealed creamy to greyish-yellow material of variable consistency.

Histopathology :

Sections revealed areas of necrosis with loss of architectural details and contained variable amount of the dead and distintegrated neutrophils. In the centre of the necrotic areas, bluish colonies of microorganisms were observed. The adjoining alveolar tissue revealed engorged blood vessels along with septal cell proliferation and cellular exudation of neutrophilic predominence. The epithelium of bronchi and bronchioles showed hypertrophy, hyperplasia and infiltration of neutrophils with desquamated cells in their lumen.

Duplicate sections of lung sections revealed gram positive cocci in clusters morphologically indistinguisahble from Staphylococcus sp. in 7 cases (RPNS - 17, 116, 122, 210, 212, 340 and 348), gram positive cocci in chains morphologically indistinguishable from Streptococcus sp. in 4 cases (RPNS - 6, 126, 264 and 351), gram positive cocco-bacillary organisms morphologically indistinguishable

from Corynebacterium sp. in 11 cases (RPNS - 134, 190, 192, 243, 274, 286, 329, 336, 349, 353 and 370).

Bacterial investigation revealed isolation of Staphylococcus aureus in two cases (RPNS - 122 and 212), Corynebacterium Pyogenes in one case (RPNS - 192), E. coli and Pseudomonas auruginosa in one case each (RPNS - 190 and RPNS - 126).

(ii) Chronic suppurative pneumonia was encountered in 40 specimens - 9.32% (RPNS - 50, 80, 90, 94, 101, 114, 115, 143, 159, 170, 191, 203, 204, 210, 217, 218, 227, 251, 257, 271, 303, 310, 330, 333, 367, 376, 380, 410, 418, 419, 421, 427, 429, 431, 434, 435, 439, 442, 444 and 447).

Gross Pathology :

Lungs revealed well formed abscesses of various sizes (pea to walnut) located in apical, cardiac and diaphragmatic lobes. Abscesses, on cutting, revealed thick cheesy material which was granular in 2 cases (RPNS - 101 and 170). The surface of the affected portion of lungs was bulged in superficially located and nodular in deep seated abscesses, of varying consistency depending upon the type of pus.

Histopathology :

The lung lesions revealed changes of bronchopneumonia with variable sized abscesses characterized by frank areas of caseative necrosis with dead and disintegrated neutrophils encircled by fibrous connective tissue reaction (Fig. 11). In some of the cases

, the suppurative areas were clearly demarcated by the formation of pyogenic membrane comprising of neutrophils and mononuclear cells along with fibrous connective tissue reaction (Fig. 13).

In four cases, surrounding caseative necrotic areas had infiltration of mononuclear cells, plasma cells, occasional epithelioid cells and giant cells (RPNS - 94, 115, 159 and 170). In addition to the above changes, in two cases, calcification was also noticed in the necrotic areas (RPNS - 101 and 170).

In six cases hypertrophy and hyperplasia of bronchial and bronchiolar epithelium with desquamated epithelial cells and debris in their lumen were noticed. Peribronchial and peribronchiolar areas were infiltrated with mononuclear cells, plasma cells and macrophages (RPNS - 80, 143, 227, 303, 310 and 410).

Duplicate sections stained with special staining revealed gram +ve cocco-bacillary organisms morphologically indistinguishable from Corynebacterium sp. (Fig. 12) in 19 cases (RPNS - 94, 101, 115, 159, 170, 191, 203, 227, 257, 271, 310, 330, 333, 367, 376, 410, 427, 429 and 431) and gram +ve cocci in groups morphologically indistinguishable from Staphylococcus sp. in five cases (RPNS - 114, 217, 218, 251 and 418) (Fig. 14).

Bacteriological study revealed isolation of Corynebacterium pyogenes in 5 cases (RPNS - 191, 203, 257, 310, 376), Staphylococcus aureus in 2 cases (RPNS - 217 and 218) and Pseudomonas auruginosa in 1 case (RPNS - 204).

636.3908624107
K139P
44139

Fig. 11 Chronic suppurative bronchopneumonia : Suppurative area on right upper corner with massive fibrocellular reaction. H & E x 63.

Fig. 12 Gram +ve cocco-bacilli indistinguishable from corynebacterium in tissue section. Mac-Callum Good pasture x 1000.

Fig. 13 Chronic suppurative bronchopneumonia : Suppurative areas containing pyogenic membrane and fibrocellular reaction. H & E x 100.

Fig. 14 Gram + cocci singly or in clusters indistinguishable from Staphylococcus in necrotic area. MGP x 1000.

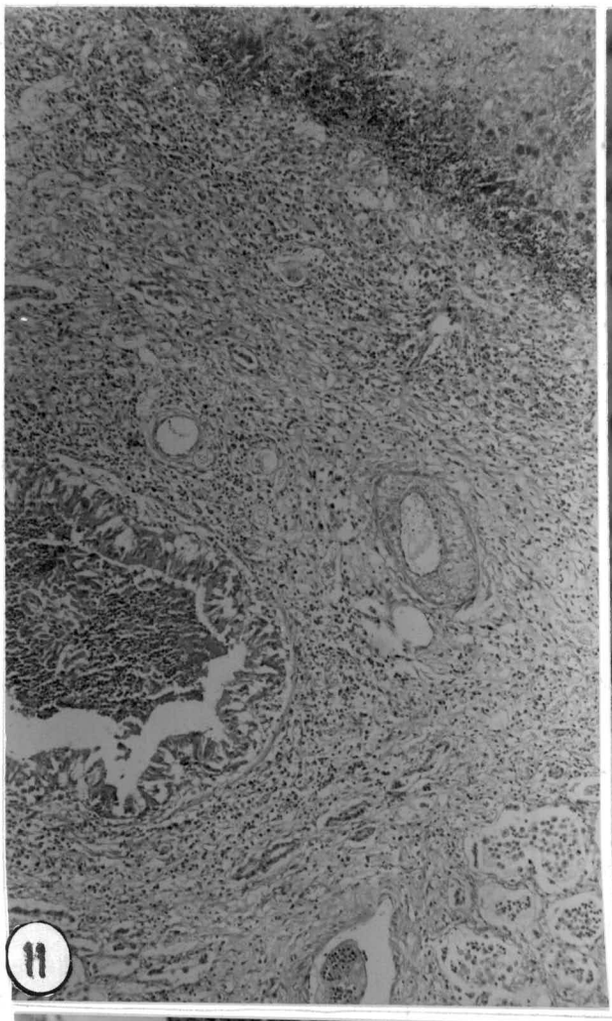
11

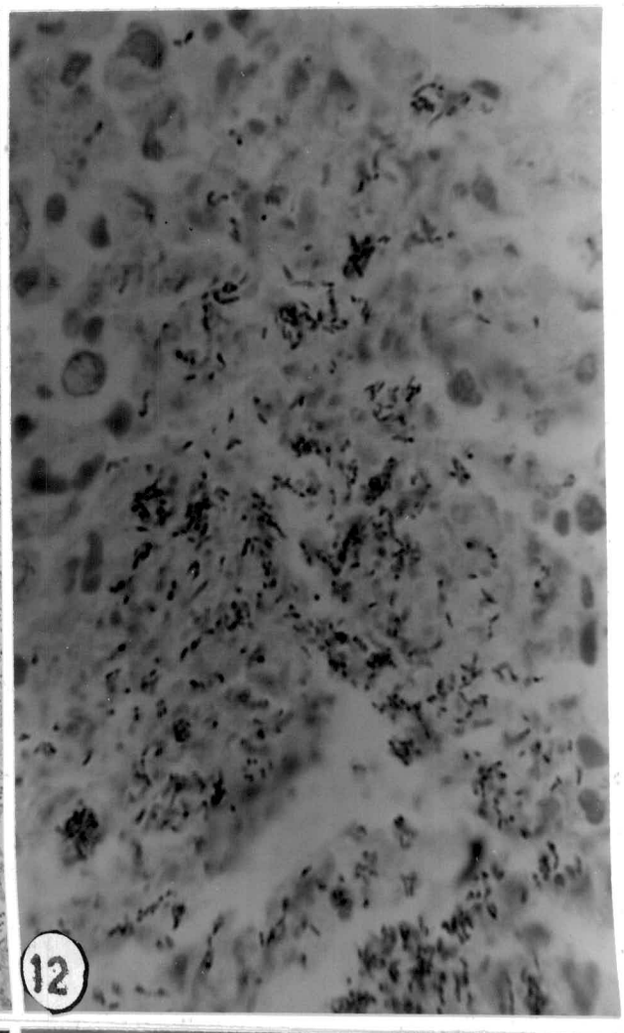
12

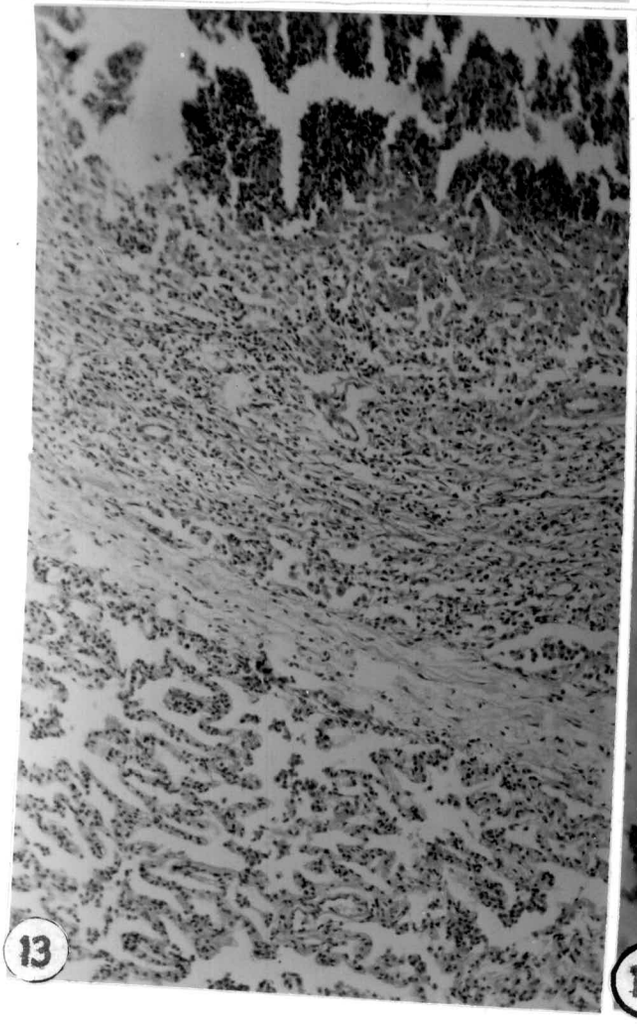
13

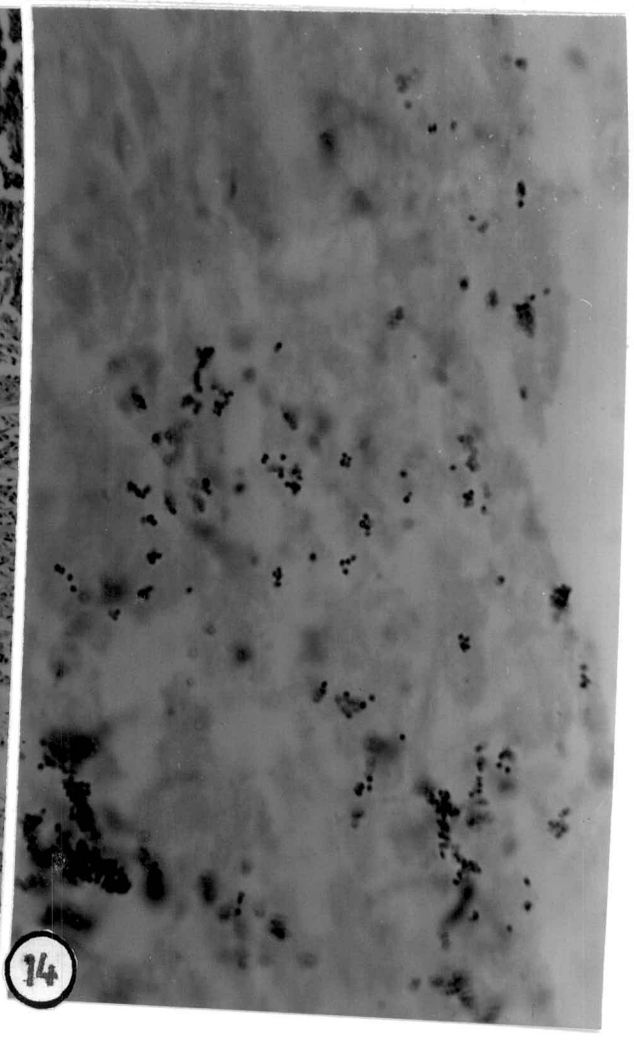
14

INTERSTITIAL PNEUMONIA

(i) Acute interstitial pneumonia was encountered in 7 cases - 1.63% (RPNS - 51, 84, 96, 247, 278, 343 and 360).

Gross Pathology :

The lungs revealed patchy to diffuse areas of congestion and consolidation in all the lobes mostly at the dorsocaudal portion of the diaphragmatic lobes with varying degree of red and grey hepatization.

Histopathology :

Sections revealed severe engorgement of interalveolar capillaries and blood vessels of interstitial tissue with proliferation of septal cells and infiltration of mononuclear cells of alveolar wall.

In addition, serous exudation with polymorphs and mononuclear cells and occasional syncytia were seen in alveoli in two cases (RPNS - 84 and 247).

(ii) Chronic interstitial pneumonia was encountered in 19 specimens - 4.43% (RPNS - 59, 61, 63, 88, 93, 108, 119, 151, 234, 280, 283, 296, 300, 311, 356, 379, 425, 436 and 440).

Gross Pathology :

The lungs in general were firm in consistency with patchy areas of consolidation and emphysema.

Histopathology :

Sections revealed thickening of interstitial tissue with septal cell proliferation and mononuclear cell infiltration. Peribronchial and peribronchiolar mononuclear cell infiltration with lympho follicular reaction was commonly observed (Fig. 15). Hyperplasia of bronchial and bronchiolar epithelial lining was also common feature. In 6 cases excessive thickening of interalveolar and interlobular septa with proliferation of septal cells, epithelialization and peribronchial and peribronchiolar infiltration of lymphocyte and plasma cells were additional features (RPNS - 61, 119, 151, 356, 425 and 440).

In two cases peribronchial areas were infiltrated with mononuclear cells, plasma cells and giant cells (RPNS - 93 and 119).

In 5 cases alveolar macrophages proliferation with serous exudation and infiltration with polymorph and mononuclear cells was observed in alveoli and bronchiolar lumen (RPNS - 80, 63, 379, 380 and 436). Muscular hyperplasia with excessive connective tissue proliferation was also seen in one case (RPNS - 300) and was demonstrated by Masson's Trichome staining.

SPECIAL PNEUMONIA

(i) Viral pneumonia (PI-3 type) was encountrered in 27 specimens - 6.29% (RPNS - 23, 24, 25, 26, 40, 52, 69, 73, 82, 107, 140, 146, 189, 230, 239, 250, 253, 255, 263, 297, 307, 322, 323, 326, 368, 374 and 432).

Gross Pathology :

Lungs revealed oedema, congestion and consolidation involving mostly apical and cardiac lobes.

Histopathology :

The sections revealed bronchointerstitial lesions comprising of infiltration of mononuclear cells, alveolar macrophages and a few neutrophils with serofibrinous exudation in interstitial tissue and alveolar spaces. The bronchioles also contained the cellular exudate (Fig. 16).

In twenty three cases, septal cell proliferation, epithelialization and intracytoplasmic eosinophilic inclusions in alveolar macrophages with occasional syncytial giant cells in the alveoli were noticed (Fig. 17, 18). Hyperplasia and hypertrophy of bronchiolar and bronchial epithelial cells with desquamation admixed with mononuclear cells in the lumen were the conspicuous features. Peribronchiolar and peribronchial infiltration of lymphocytes were also observed (RPNS - 23, 24, 26, 40, 52, 69, 107, 140, 146, 189, 230, 239, 250, 253, 255, 263, 297, 307, 323, 326, 368, 374 and 432). The eosinophilic intracytoplasmic inclusions were also seen in bronchiolar

Fig. 15 Chronic Interstitial pneumonia : peribronchiolar lympho-follicular reaction. H & E x 63.

Fig. 16 Bronchointerstitial pneumonia (PI-3 type) : Cellular exudate in bronchiolar lumen, serocellular infiltration in interstitium and alveolar spaces. H & E x 100.

Fig. 17 Viral pneumonia (PI-3 type) : Intracytoplasmic eosinophilic inclusions in alveolar macrophages (arrow). H & E x 400.

Fig. 18 Viral pneumonia (PI-3 type) : alveolar epithelialization and syncytial giant cells in the alveoli. H & E x 250.

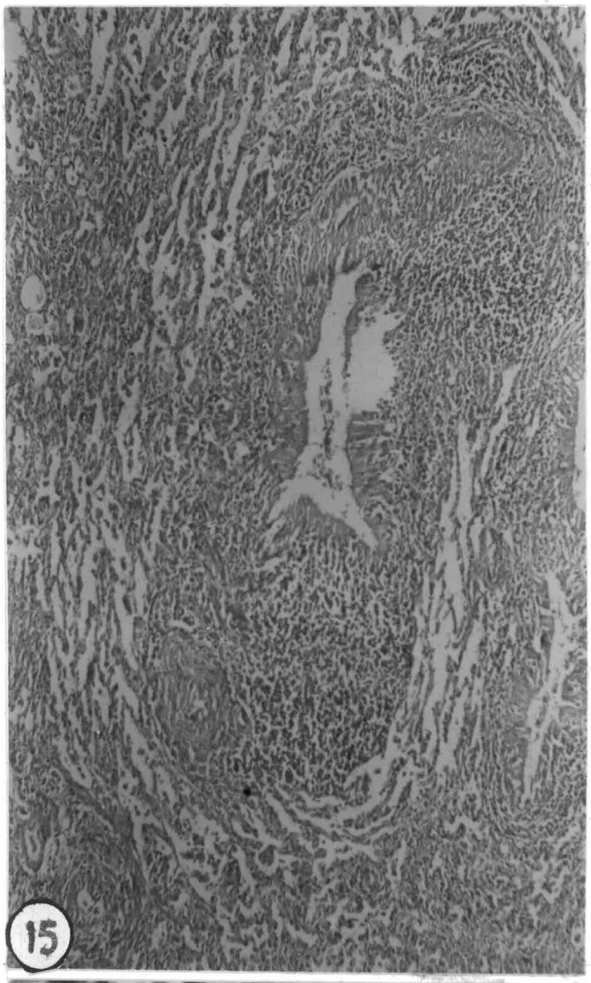

15

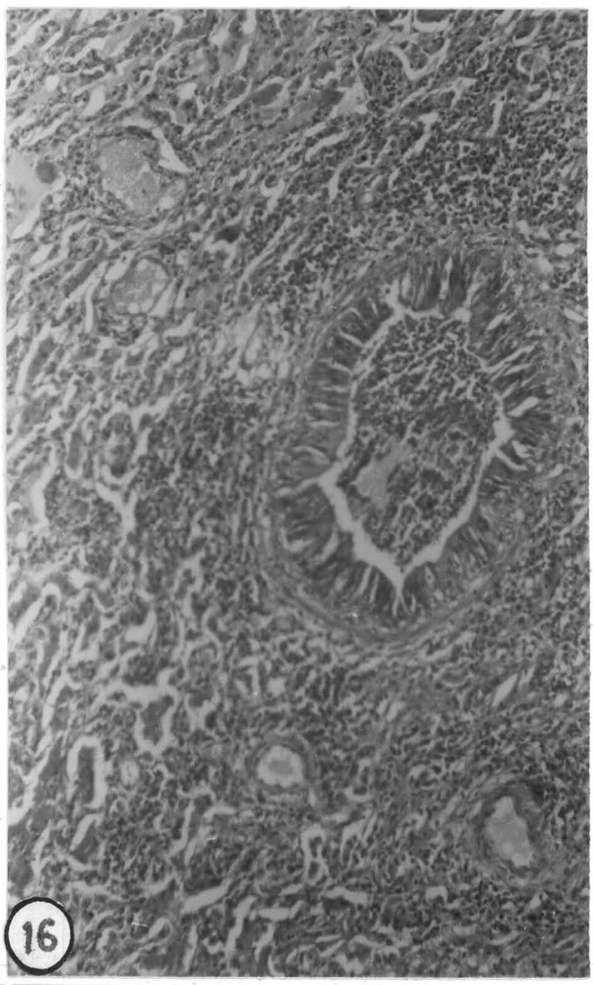

16

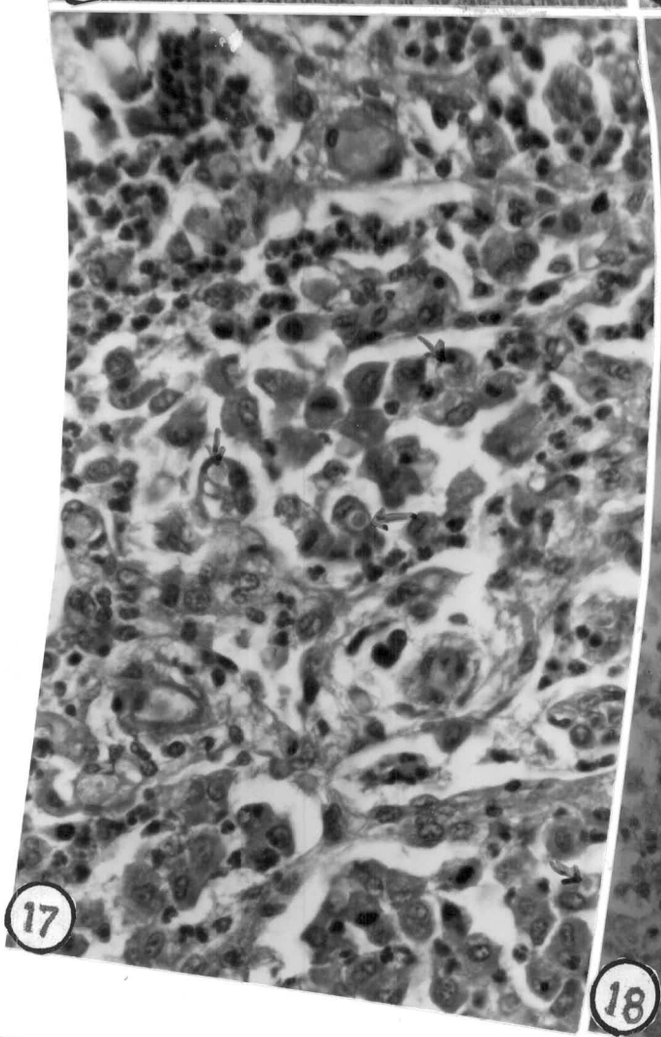

17

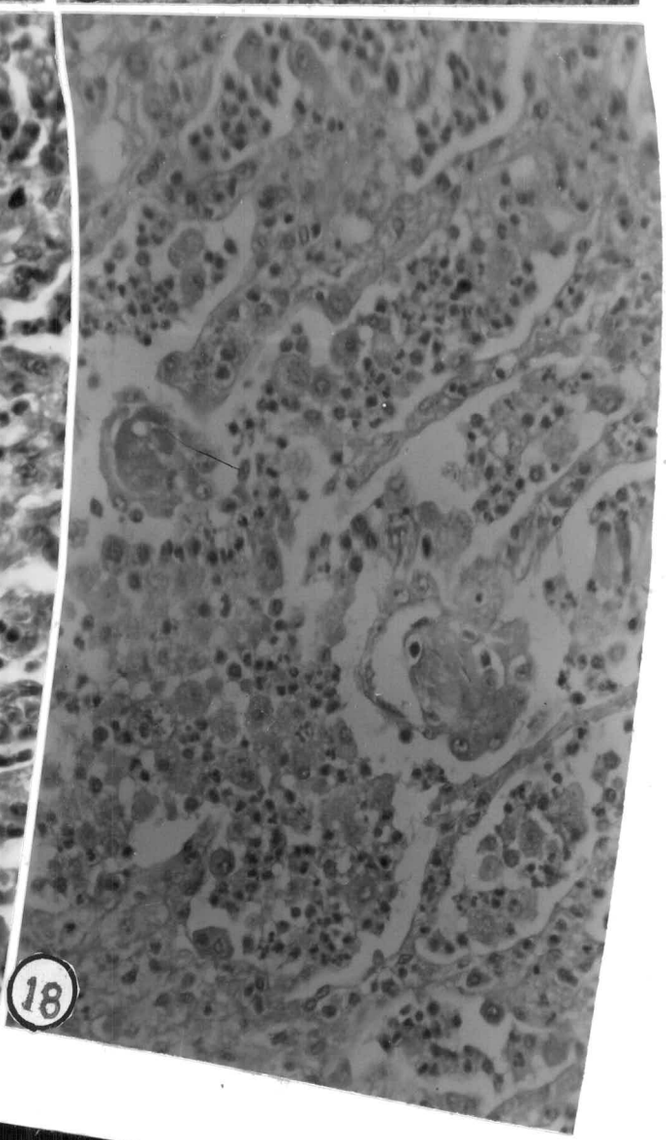

18

epithelium in 2 cases (Fig. 19 and 20) (RPNS - 146 and 307). In duplicate sections inclusions were also confirmed by Shorr's staining.

In addition to interstitial pneumonic changes, presence of typical 'Cat shaped' cell reaction in alveoli were also noticed in 4 cases. On special staining, bipolar organism morphologically indistinguishable from Pasteurella sp. were demonstrated in duplicate lung sections in all such cases (RPNS - 82, 189, 230 and 432). Suppurative areas with dead and disintegrating neutrophils surrounded by mononuclear cells were also noticed in the lung parenchyma as well as in bronchioles (Fig. 21) in 7 cases (RPNS - 107, 140, 255, 322, 323, 326 and 374). On special staining, duplicate sections revealed gram positive cocci morphologically indistinguishable from Staphylococcus sp. in three cases (RPNS - 107, 140 and 322), gram positive Cocco-bacilli morphologically indistinguishable from Corynebacterium sp. in three cases (RPNS - 255, 323, and 374) and gram positive cocci morphologically indistinguishable from Streptococcus sp. in one case (RPNS - 326) (Fig. 22).

In one case, bronchi and bronchioles were full of cellular exudate with predominence of mononuclear cells and fibroblasts proliferation which caused bronchoectasis (RPNS - 239).

(ii) Pulmonary adenomatosis was encountered in 8 specimens - 1.86% (RPNS - 276, 315, 317, 321, 331, 334, 354 and 426).

Gross Pathology :

In general the lungs were enlarged heavy and consolidated with firm consistency. Multiple nodules of varying sizes (from pea to millet size) were present in consolidated areas of diaphragmatic

Fig. 19 Viral pneumonia (PI-3 type) : Bronchiolar epithelial hyperplasia and intracytoplasmic eosinophilic inclusions.
H & E x 400.

Fig. 20 Higher magnification of Fig. 19. H & E x 1000.

Fig. 21 Viral pneumonia (PI-3 type) : Suppurative areas in lung parenchyma and bronchiole. H & E x 63.

Fig. 22 Gram + cocci indistinguishable from Streptococci in necrotic area. MGP x 1000.

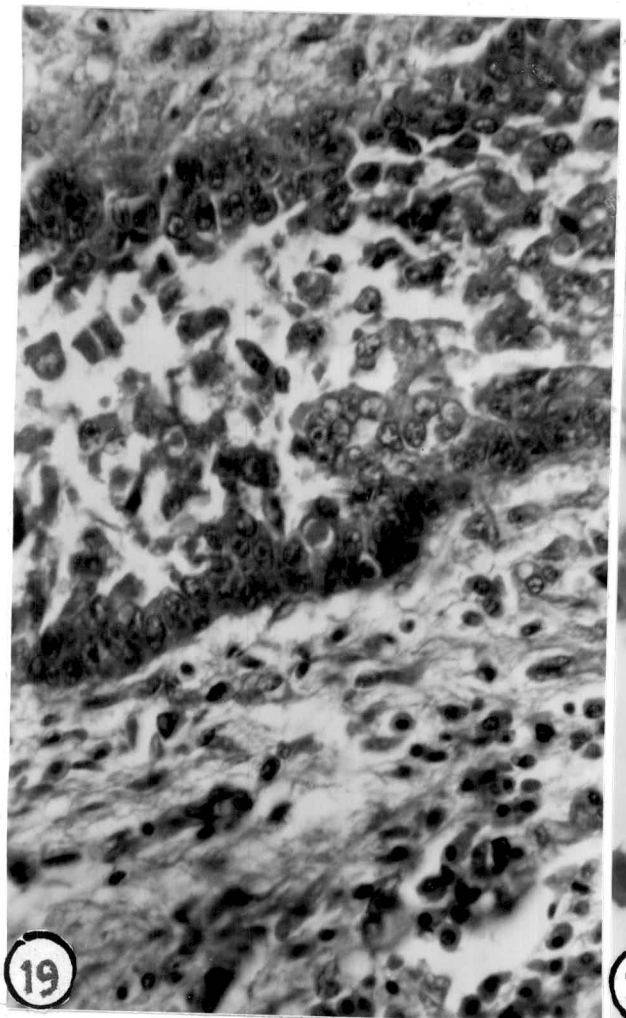
19

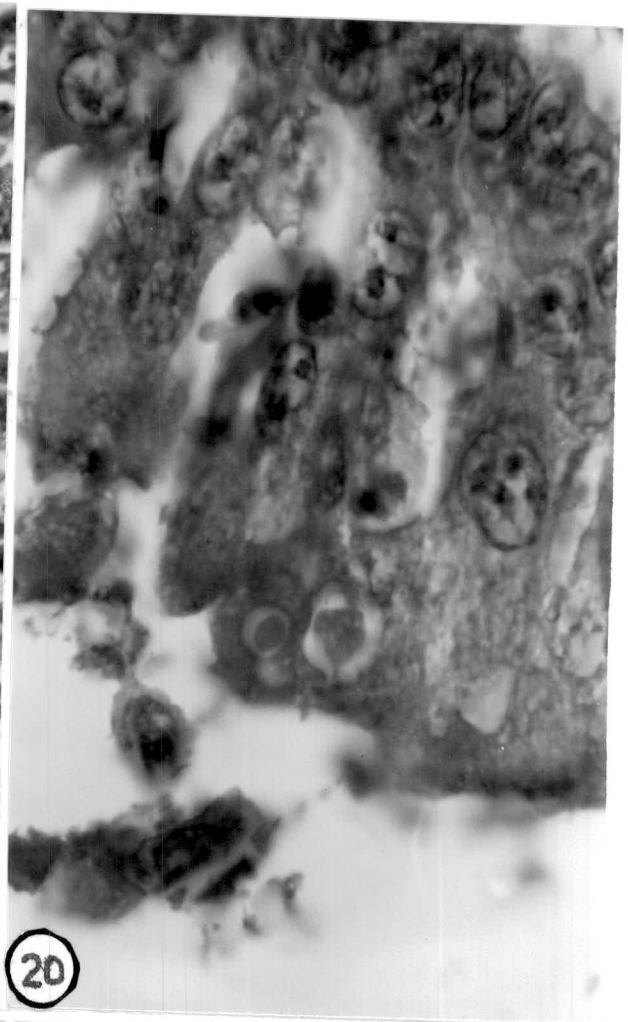
20

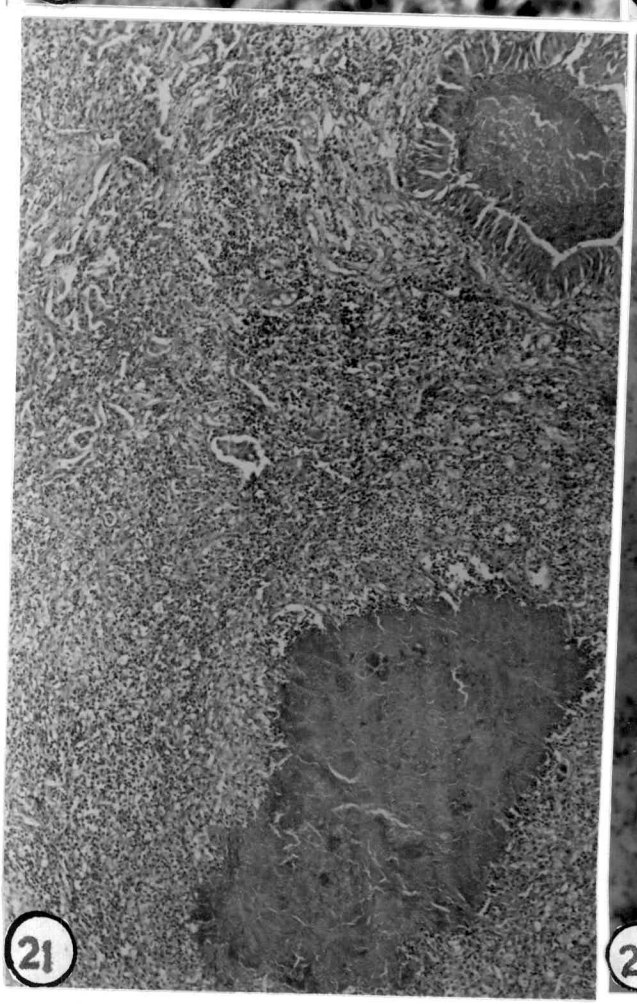
21


22

lobes. In two cases (RPNS - 331 and RPNS - 354) nodules were present in all the lobes of the lungs (Fig. 23) and a few of the nodules revealed thick cheesy greyish material on cutting.

Histopathology :

Sections revealed focal to multicentric extensive areas of adenomatosis (Fig. 24). Alveolar epithelial cells revealed proliferation and hyperplasia of the lining epithelium with papilliform projections into the alveolar lumen (Fig. 25). Bronchial and bronchiolar lining epithelium also showed hyperplasia.

In 4 cases (RPNS - 315, 317, 334 and 354), in addition to adenomatosis lesions, areas of necrosis with dead and disintegrating neutrophils surrounded by mononuclear cells, macrophages, plasma cells and fibrous connective tissue reaction at the periphery were noticed. Duplicate sections of these cases stained with MacCallum Good pasture's staining revealed gram +ve cocci morphologically indistinguishable from Staphylococcus sp. in one case (RPNS - 317) and gram +ve coccobacilli morphologically indistinguishable from Corynebacterium sp. in three cases (RPNS - 315, 334 and 354).

(iii) Mycoplasmal pneumonia was encountered in 7 specimens - 1.63% (RPNS - 58, 196, 200, 216, 288, 359 and 405).

Gross Pathology :

In general, the lungs were enlarged and heavy with areas of congestion and consolidation in apical, cardiac and diaphragmatic

Fig. 23 Pulmonary adenomatosis : Voluminous lung with multiple nodules (Arrow).

Fig. 24 Pulmonary adenomatosis : multicentric areas of alveolar cell proliferation. H & E x 63.

Fig. 25 Pulmonary adenomatosis : Papilliform projections into alveolar lumen. H & E x 250.

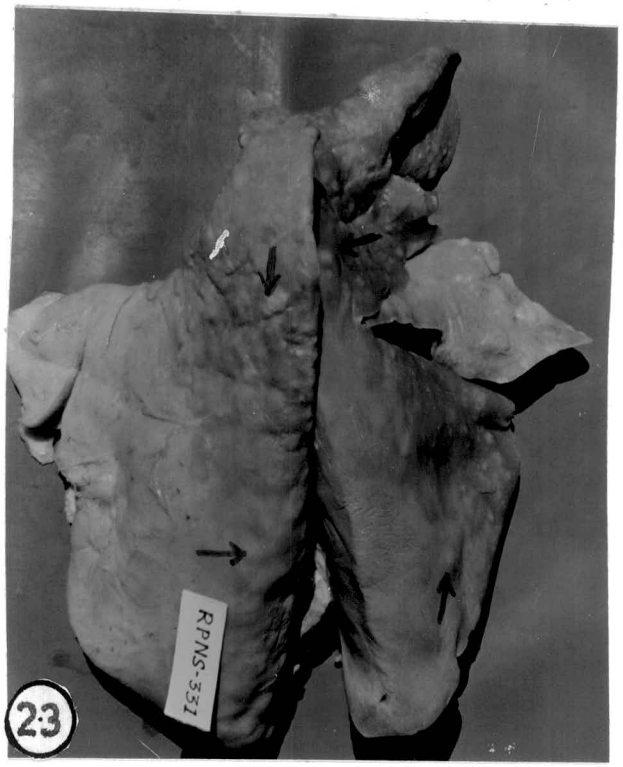
RPNS-331
23

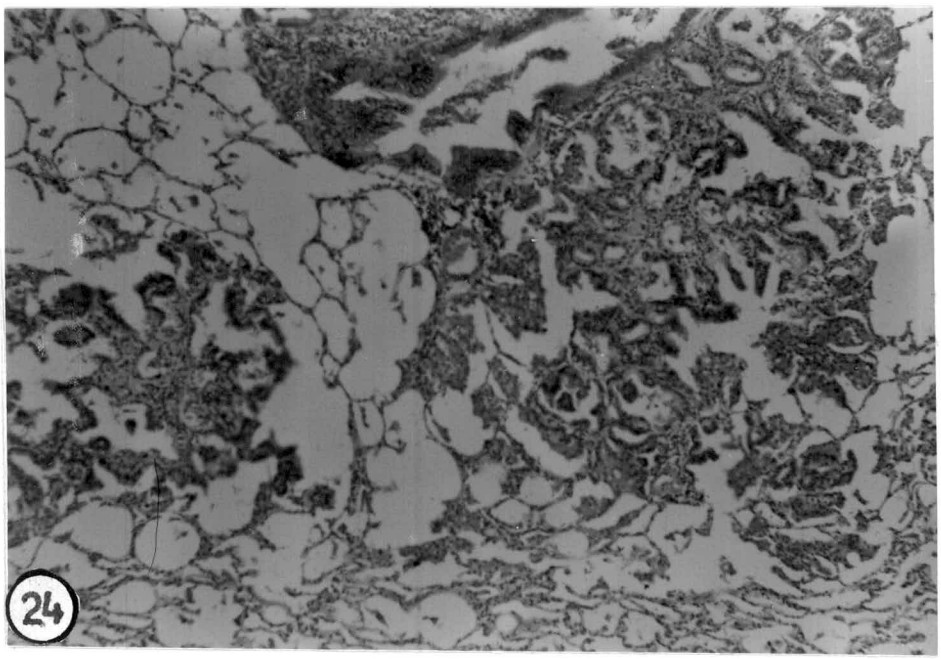
24

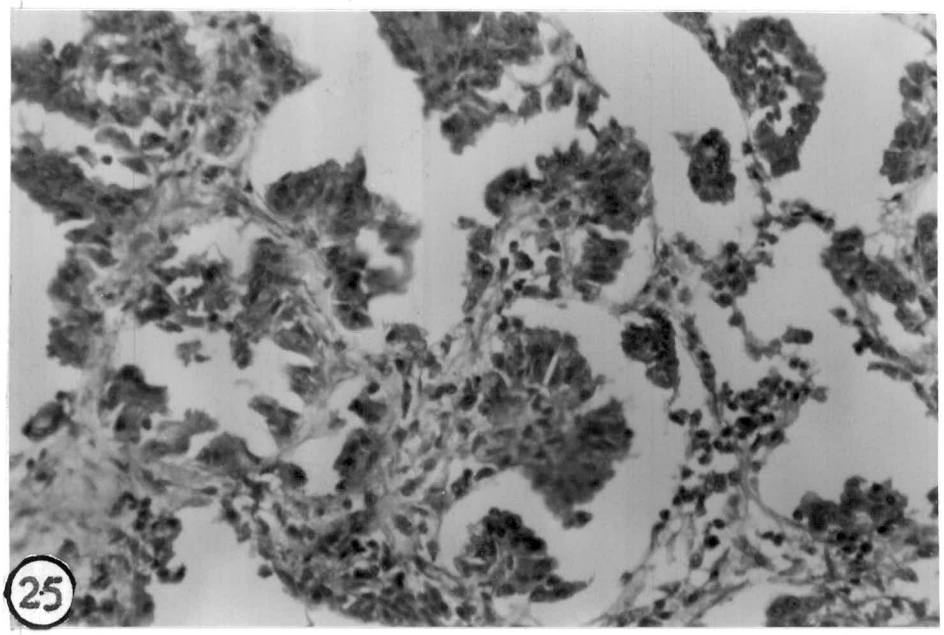
25

lobes. The consolidated areas were greyish-white and had liver like consistency. The pleura was thickened, congested and covered with thin layers of fibrinous exudate. In three cases (RPNS - 58, 196 and 359) pleura and interlobular septa were thickened and prominent. On cutting greyish-whitish marbling appearance was noticed.

In 1 case (RPNS - 216), in addition to consolidation, multiple cysts containing clear fluid were observed in diaphragmatic lobes and in another case (RPNS - 359) multiple small whitish suppurative foci were seen in the consolidated areas of lungs.

Histopathology :

The lesions in general revealed thickened, dilated pleura and interlobular septa with serofibrinous exudation and infiltration with neutrophils and mononuclear cells. Engorgement of interalveolar capillaries and blood vessels in pleura and interlobular septa was noticed (Fig. 26). Alveoli in consolidated areas were dilated with sero-fibrinous exudation and were packed with aggregates of neutrophils, mononuclear cells and alveolar macrophages. Peribronchial, peribronchiolar and perivascular lymphoid cuffing, accumulation of cellular inflammatory exudate in bronchi and bronchiolar lumen was also noticed.

Multiple hydatid cysts contained laminated wall surrounded by fibrocellular reaction were noticed in one case (RPNS - 216) and focal necrotic areas with dead and disintegrated neutrophils and oat shaped cell reaction in adjacent alveoli were seen in one case (RPNS - 359). Duplicate sections of these cases on special staining revealed organism morphologically indistinguishable from

Pasteurella sp. (RPNS - 359), and organisms morphologically indistinguishable from Mycoplasma sp. (Fig. 27) in four cases (RPNS - 200, 216, 359 and 405).

Bacterial isolation yielded pure culture of Mycoplasma sp. unidentified in one case (RPNS - 216) and mixed infection of Mycoplasma sp. (unidentified) and Corynebcterium pyogenes in another case (RPNS - 200).

(iv) Verminous pneumonia was encountered in 25 specimens - 5.82% (RPNS - 112, 158, 160, 162, 163, 164, 168, 173, 174, 175, 179, 181, 197, 199, 207, 284, 295, 298, 299, 301, 306, 309, 344, 355 and 366).

Gross Pathology :

Lungs showed pale nodular consolidation and emphysematous areas mostly in diaphragmatic lobes. On cutting consolidated areas revealed presence of fine thread like structures.

Histopathology :

Sections revealed proliferation, hyperplasia and desquamation of bronchial and bronchiolar lining epithelial cells and catahrral exudate admixed with polymorphs and mononuclear cells in their lumen. Peribronchial and peribronchiolar areas were infiltrated with lymphocytes, occasionally eosinophils and plasma cells. Cross sections of parasites larvae and eggs in bronchi, bronchioles and alveoli were the most pathognomic features (Fig. 28, 29). In some cases ova were surrounded by polymorphs, mononuclear cells, and occasional giant cells with thickening of alveolar septa.

In 6 cases, hypertrophy and hyperplasia of muscular layer and connective tissue proliferation with formation of lympho-follicular reaction in peribronchial/peribronchiolar areas were noticed. Engorgement of blood vessels with haemorrhagic and cellular exudate in the alveoli with presence of ova were the main features (Fig. 30) (RPNS - 174, 295, 298, 299, 301 and 355). In 6 cases, nodule formations around cross sections of parasites and eggs in alveoli were infiltrated by mononuclear cells, macrophages, eosinophils and surrounded by fibrocellular reaction. (RPNS - 158, 160, 162, 164, 173 and 175). Multiple granulomas around the degenerated ova and larvae were observed in one case (RPNS - 207).

In addition to the above changes multiple suppurative areas were also encountered in three cases (RPNS - 197, 306 and 366). Duplicate sections on special staining revealed gm +ve cocci morphologically indistinguishable from Staphylococcus sp. in all such cases. Parasites could be identified only in 3 cases. Two specimens revealed cut sections of adult parasites and undulating tail with terminal brown spine in pulmonary parencyma (Fig. 31) suggesting of Muellerius capillaris (RPNS - 164 and 173). The cut sections of adult parasites observed in bronchioles were identified on the basis of thickness and site of prediliction as either Varestrongylus sp. or Protostrongylus sp. (RPNS - 197).

(iv) Giant cell pneumonia was identified in 1 specimen - 0.23% (RPNS - 226).

Gross Pathology :

The affected lungs revealed small hard multiple greyish white nodules in both the diaphragmatic lobes.

Fig. 26 Mycoplasma pneumonia : Thickened and widened interlobular septa, engorgement of blood vessels and infiltration of polymorphs and mononuclear cells. H & E x 100.

Fig. 27 Mycoplasma organisms on bronchiolar epithelium.
Giemsa x 1000.

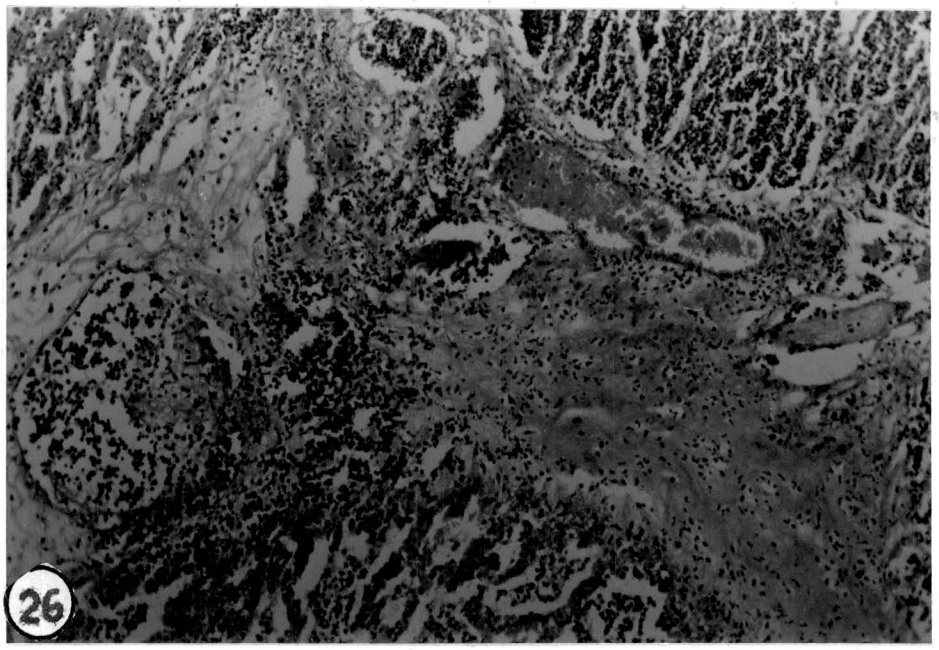
26

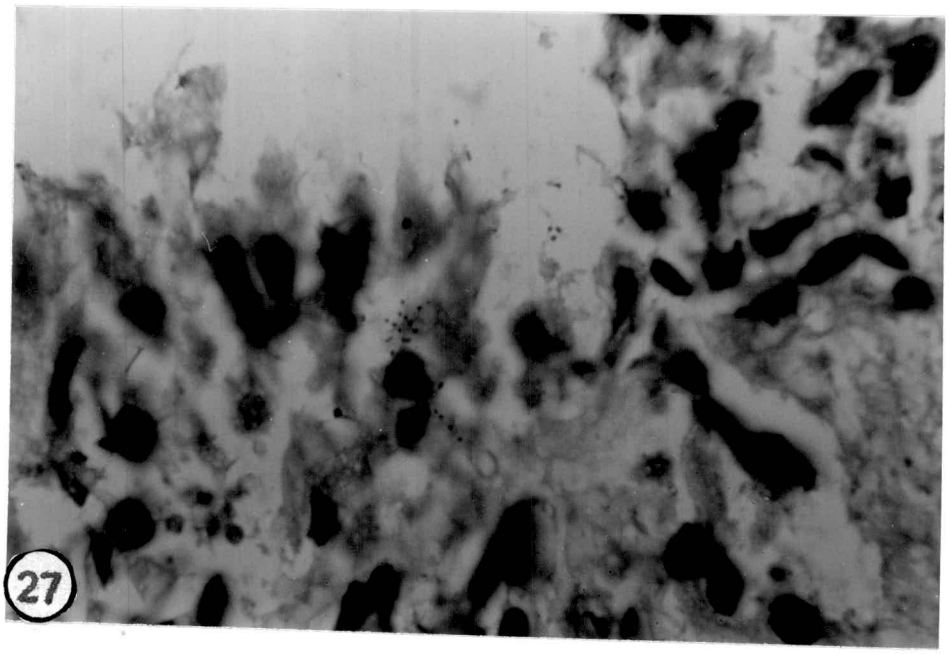
27

Fig. 28 Verminous pneumonia : Cross sections of parasite in bronchioles. H & E x 63.

Fig. 29 Verminous pneumonia : alveoli and bronchioles contained eggs and larvae. H & E x 100.

Fig. 30 Verminous pneumonia : haemorrhagic and cellular exudate in the alveoli with presence of eggs. H & E x 100.

Fig. 31 Verminous pneumonia : cut sections of Muellerius parasite, undulating tail with terminal brown spine in lung parenchyma H & E x 400.

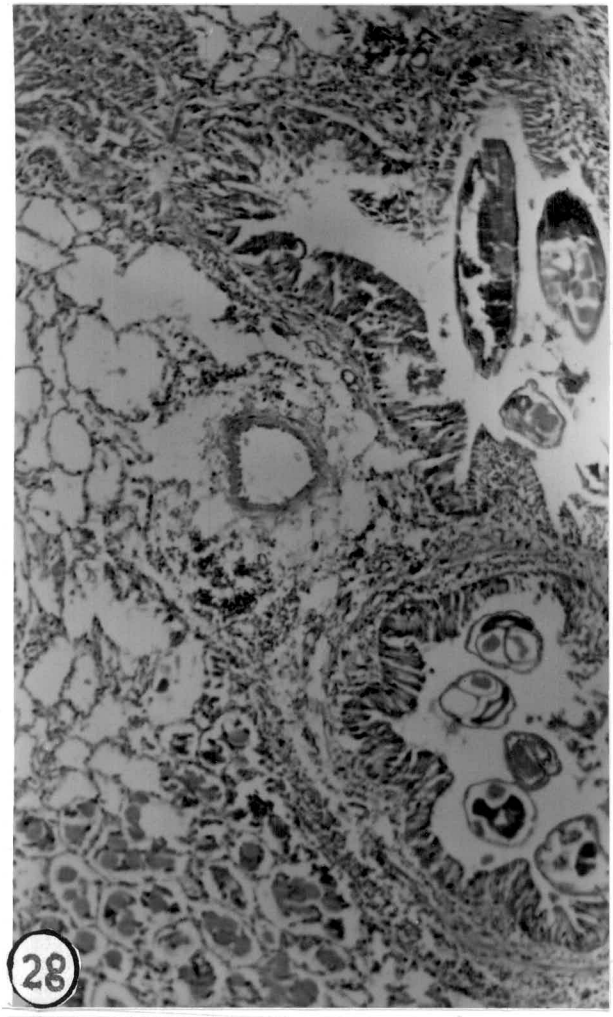
28

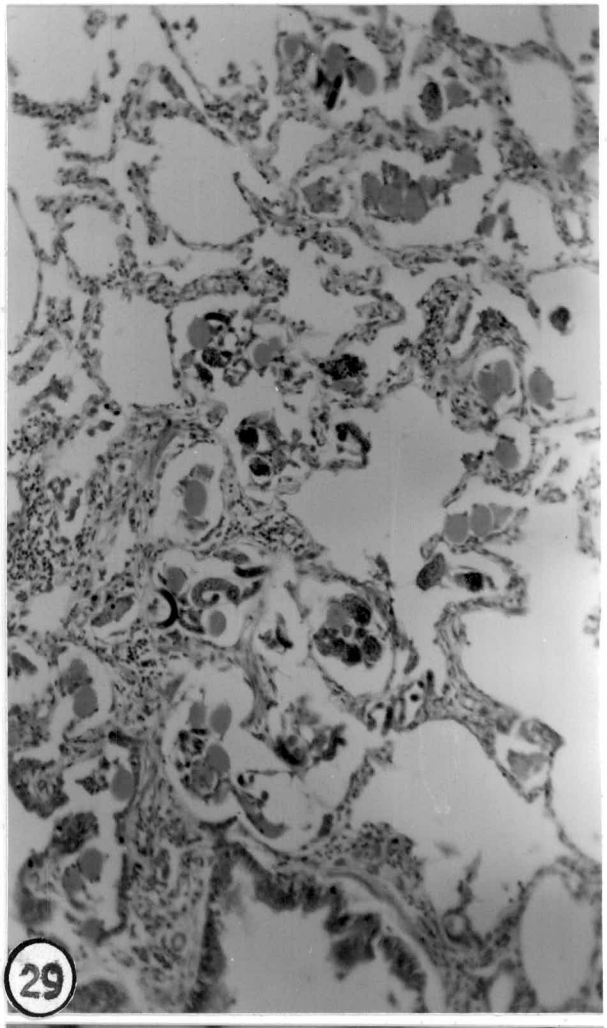
29

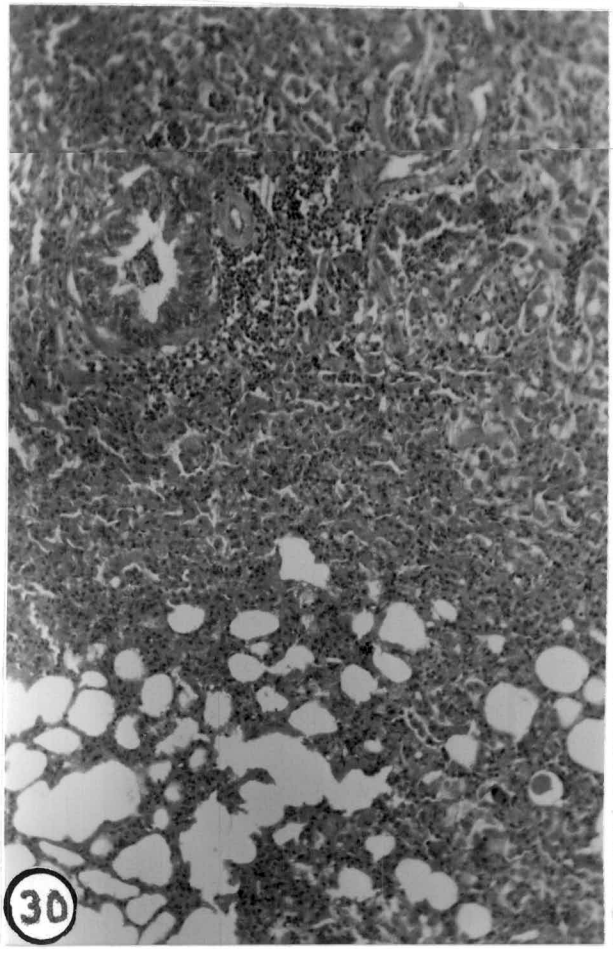
30

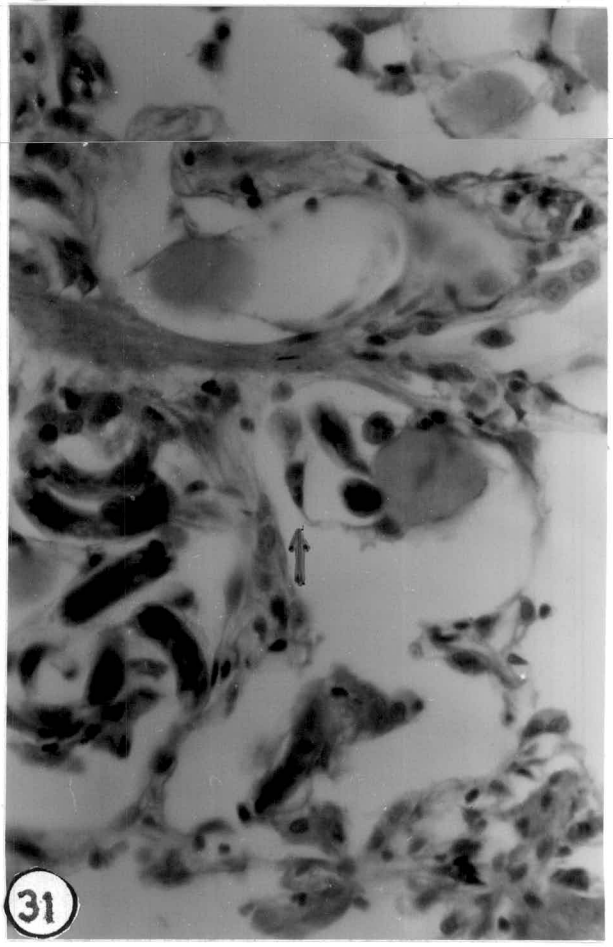
31

Histopathology :

Sections revealed multiple granulomas with presence of numerous giant cells in the lung parenchyma. The affected areas were infiltrated with mononuclear cells, plasma cells, macrophages and fibrocellular reaction (Fig. 32). Basophilic tinted structures of variable sized and shapes (Oval, circular, dumble or button size) were observed in almost all the giant cells (Fig. 33, 34). These structures could not be identified but appeared like parasitic cystic structures with parasitophorous vacuole around them.

GRANULOMATOUS PNEUMONIA

(i) Pulmonary aspergillosis was encountered in 1 specimen - 0.23% (RPNS - 98).

Gross Pathology :

The lungs were congested and consolidated with firm in texture. Small multiple whitish hard nodular foci were seen in diaphragmatic lobes of both lungs. Nodular foci on cutting revealed thick pasty mucoid exudate.

Histopathology :

Multicentric necrotic areas were characterised by the presence of mononuclear cells, macrophages, giant cells surrounded

Fig. 32 Giant cell pneumonia : granuloma with numerous giant cells and fibrocellular reaction. H & E x 100.

Fig. 33 Giant cell pneumonia : Giant cells having oval, cylindrical, dumble shape unidentified structures with parasitophorous vacuoles. H & E x 250.

Fig. 34 Giant cell pneumonia : Giant cells having structures with parasitophorous vacuoles. H & E x 400.

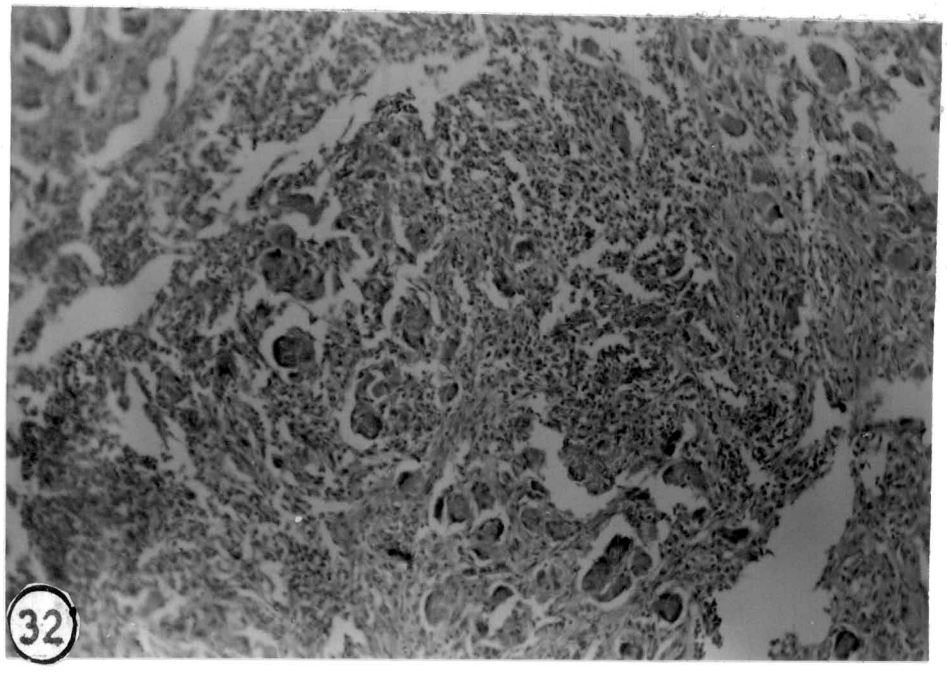
32

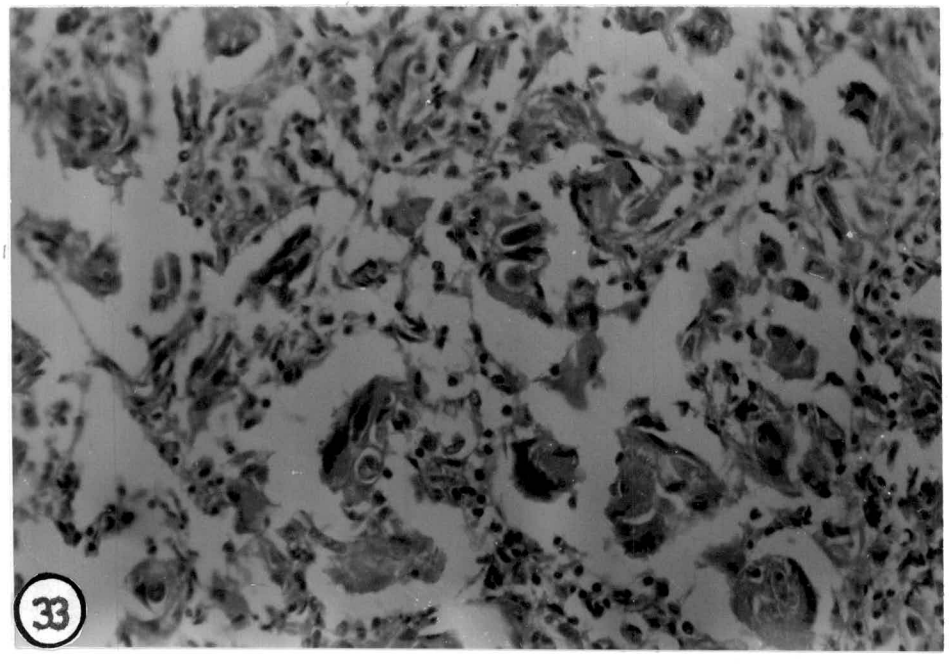
33

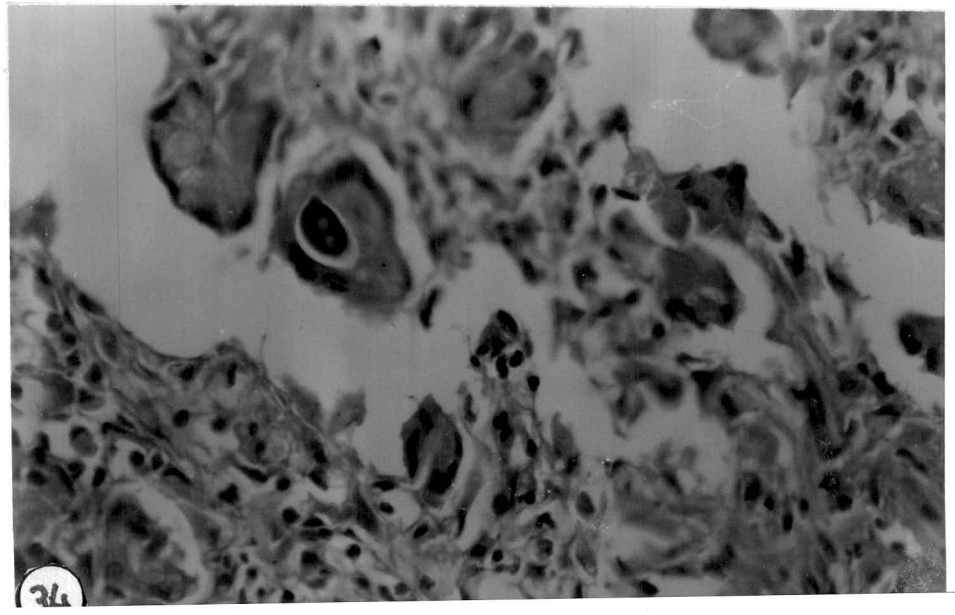
34

by fibrous connective tissue reaction forming nodule (Fig. 35). At places, branched septate hyphae and ovoid spore like structures were noticed (Fig. 36). Few of the hyphae had bud like structure giving rise to septate branches to all directions. The wall of the fungal hyphae had a basophilic tint in haemotoxylin and eosin stained sections. Fungal hyphae were PAS and Gridley's positive and their boundary wall stained pinkish red with PAS (Fig. 37); deep purple with Gridley's stain and blackish with Grocott's staining morphologically indistinguishable from Aspergillus sp.

Bronchi and bronchioles contained Catarrhal exudation mixed with mononuclear cells and desquamated epithelial cells. The peribronchial/peribronchiolar areas had infiltration of mononuclear cells. Bacterial isolation of the specimens yielded Corynebacterium pyogenes in this case.

(ii) Pulmonary tuberculosis was encountered in 4 specimens - 0.93% (RPNS - 220, 417, 428 and 437).

Gross Pathology :

The lungs were heavy, enlarged and consolidated with firm consistency. In one case (RPNS 417), there were diffuse variable sized (Pea to arecanut) greyish-white areas of suppuration in apical and diaphragmatic lobes of both lungs. On cutting, the suppurative areas revealed thick caseated pus. Bronchi contained variable amount of greyish fluid with flakes of cheesy material.

In 3 cases (RPNS - 220, 428 and 437) there were multiple greyish hard nodules of different sizes varying from pea to walnut

Fig. 35 Pulmonary aspergillosis : Nodule having lymphocytes, macrophages and giant cells surrounded by fibrocellular reaction. H & E x 100.

Fig. 36 Pulmonary aspergillosis : multicentric necrotic areas having branched septate hyphae. H & E x 250.

Fig. 37 Pulmonary aspergillosis : branched, septate hyphae and spores. PAS x 400.

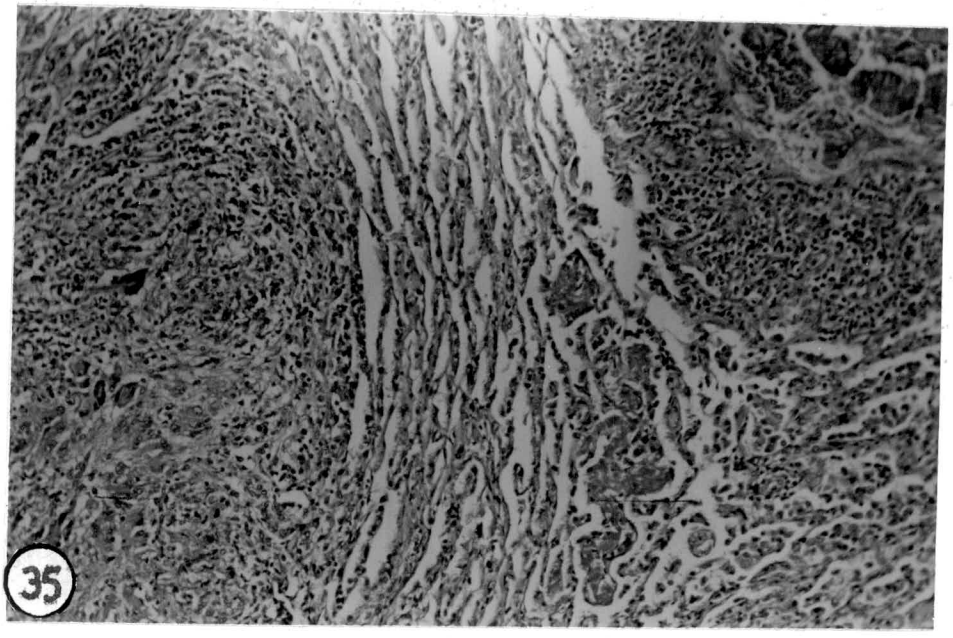
35

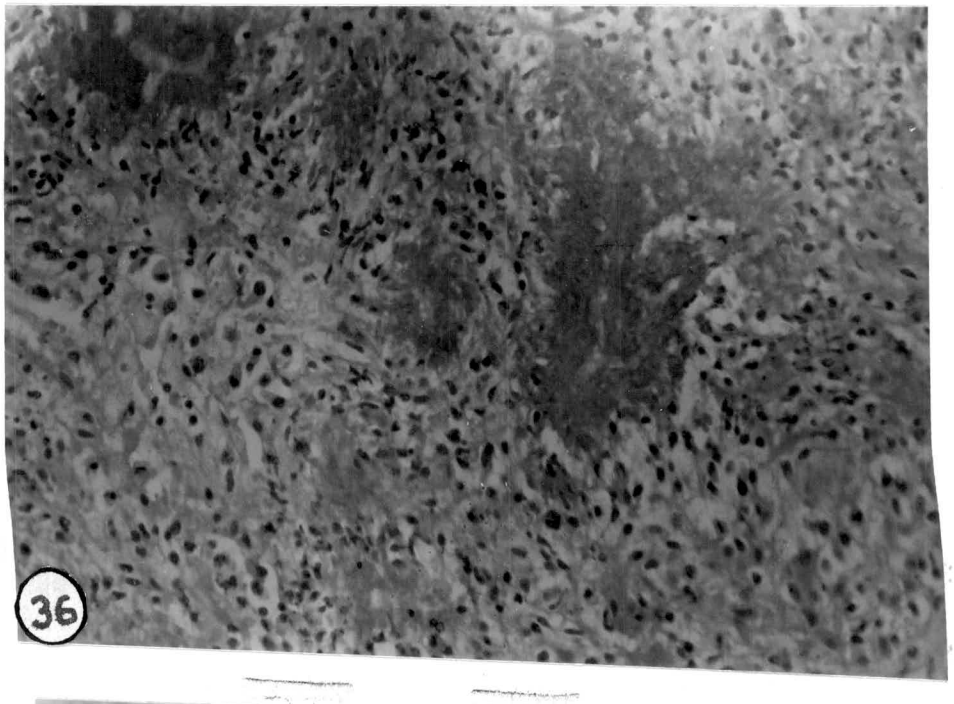
36

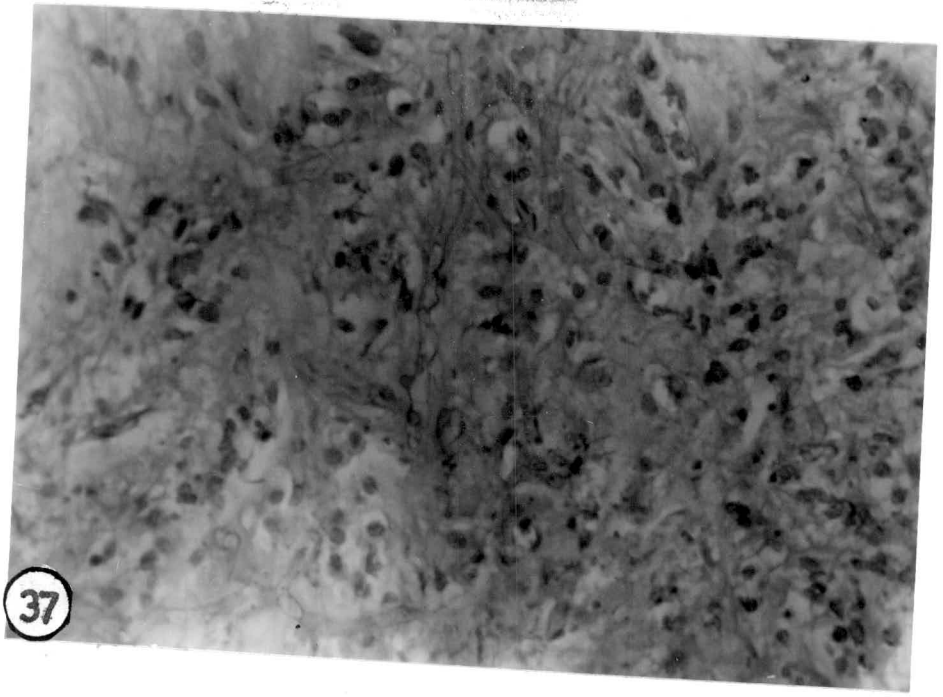
37

in diaphragmatic lobes of both lungs. The affected areas were consolidated with firm consistency. On cutting, the nodules revealed thick caseocalcarious material with gritty sound.

Histopathology :

In one case (RPNS - 417), sections revealed multicentric diffuse caseated necrotic areas infiltrated by mononuclear cells, macrophages, epithelioid and Langhans type giant cells surrounded by fibrocellular reaction (Fig. 38). Calcified stiplings were noticed in the necrotic areas. In the periphery of caseated areas, there were extensive alveolar macrophage reaction in alveoli. There was hyperplasia of peribronchial glands leading to cystic dialatation. Accumulation of extensive mucinous threads admixed with degenerated neutrophils was noticed in the bronchial lumens.

In 3 cases (RPNS - 220, 428 and 437) sections revealed multiple nodular areas with central zone of caseous necrosis along with marked calcification surrounded by lymphocytes, macrophages epithelioid cells and Langhans type giant cells encapsulated by abundant connective tissue proliferation (Fig. 39, 40). Adjacent to these pyogranulomatous lesions, areas of emphysema were also observed.

Duplicate sections on special staining (Ziehl Neelsen's) showed acid fast bacilli having beaded appearance singly and scattered in necrotic areas, morphologically indistinguishable from Mycobacterium sp. (Fig. 41) in four cases (RP NS 220, 417, 428 and 437).

Fig. 38 Pulmonary tuberculosis : Nodule showing caseative necrosis, Langhans giant cells and fibrocellular reaction. H & E x 63.

Fig. 39 Pulmonary tuberculosis : small nodule having caseative necrosis with fibrocellular reaction. H & E x 100.

Fig. 40 Pulmonary tuberculosis : nodules showing granulomatous reaction with caseation and extensive calcification. H & E x 100.

Fig. 41 Pulmonary tuberculosis : Acid fast bacilli in necrotic area. ZN x 1000.

38

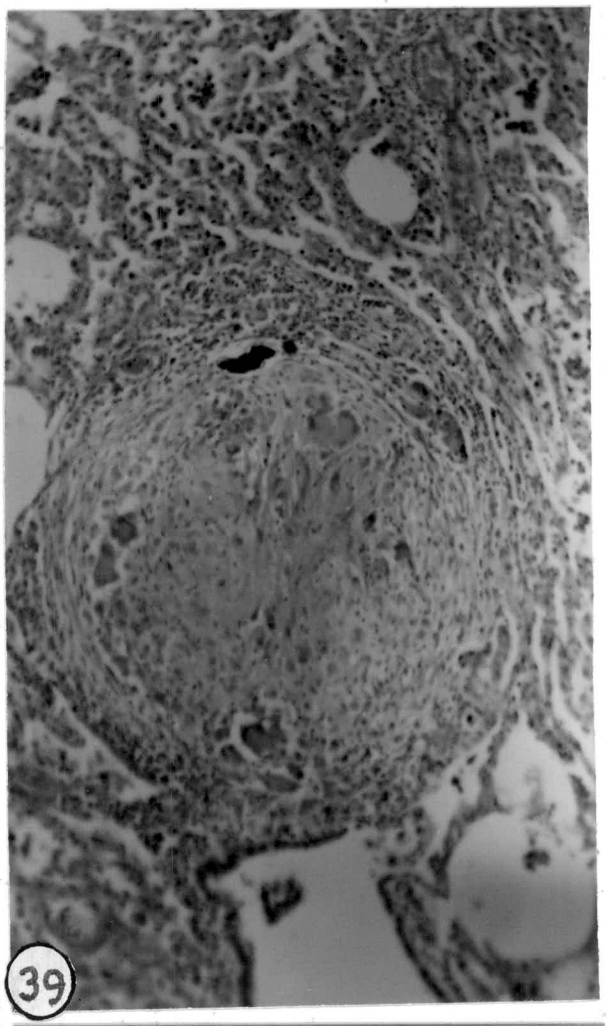
39

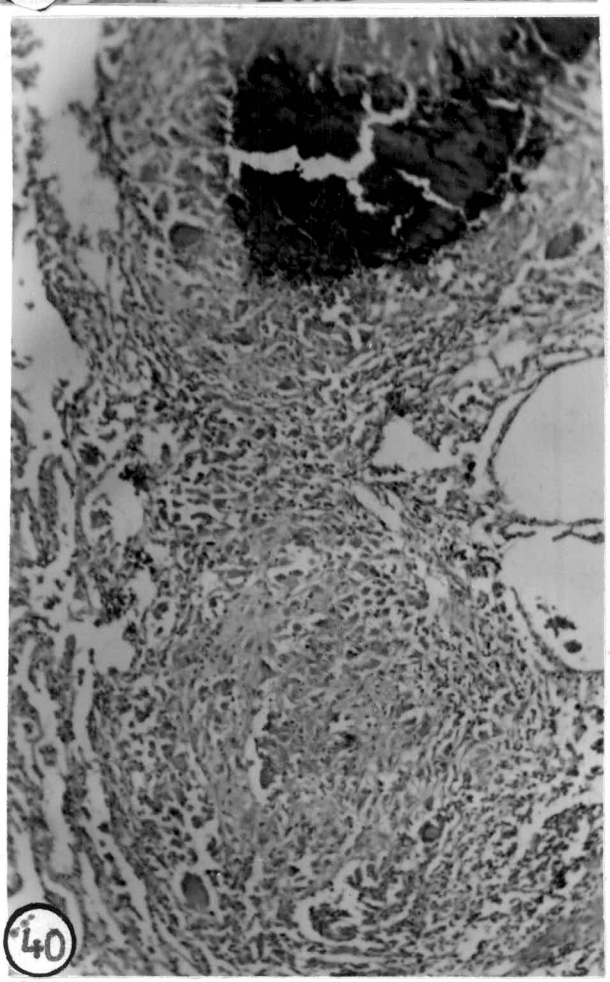
40

41

OTHER PULMONARY AFFECTIONS

(i) Pulmonary oedema was encountered in 4 specimens - 0.93% (RPNS - 242, 249, 332 and 345).

Gross Pathology

Grossly, the lungs were voluminous, oedematous and heavy with doughy consistency.

Histopathology :

Tissue sections revealed pinkish proteinaceous transudate filled in alveolar septa and alveolar spaces. Alveolar emphysema was also evident in the adjoining areas. The bronchi and bronchioles were also filled with similar type of oedematous fluid.

(ii) Pulmonary haemorrhage was encountered in 9 specimens - 2.09% (RPNS - 85, 150, 208, 282, 314, 328, 335, 341 and 342).

Gross Pathology :

Grossly, the lungs showed patchy areas of haemorrhages and congestion.

Histopathology :

The sections revealed engorgement of blood vessels in the interlobular and interalveolar septa. The alveoli were partly or completely studded with erythrocytes and at places with extra-

vasation of RBC's in different areas in the alveolar spaces (Fig. 42).

(iii) **Brown induration** was encountered in 1 specimen - 0.23% (RPNS - 104).

Gross Pathology :

The lungs were congested, slightly solid in consistency, heavy and bluish in colour.

Histopathology :

The sections revealed areas of congestion and most of the lung parenchyma showed chronic reaction, mainly characterized by fibrosis with infiltration of lymphocytes, plasma cells and macrophages. At places, macrophages were laden with golden brown haemosiderin pigment which appeared as bluish masses on perl's staining in the tissue (Fig. 43, 44).

(iv) **Emphysema** was encountered in 5 specimens - 1.16% (RPNS - 48, 87, 156, 337 and 352).

Gross Pathology :

The lungs were voluminous and pale in appearance. On pressing a crepitating sound was heard.

Histopathology :

The alveoli were distended and distrupted with presence of thin alveolar wall. The alveoli coalesced together and formed giant alveoli. Bronchi and bronchioles were also dilated at some areas.

(v) **Hydatidosis** was encountered in 36 specimens - 8.39% (RPNS - 33, 49, 57, 60, 78, 79, 95, 97, 113, 129, 130, 131, 133, 135, 152, 155, 194, 198, 219, 232, 256, 266, 273, 313, 316, 347, 484, 403, 404, 416, 420, 422, 443, 448, 449 and.450).

Gross Pathology :

In general single to multiple cystic structures, soft and fluctuating on palpation and of variable sized (pea to tennis ball) were noticed in the diaphragmatic lobes. On cutting the cystic structures revealed clear fluid except in one case (RPNS - 219) in which germinal membrane was noticed in the cystic cavity.

Histopathology :

Lung parenchyma revealed laminated cystic wall surrounded by infiltration of mononuclear cells, eosinophils with fibrocellular reaction (Fig. 45). In the cystic cavity necrotic mass was also observed. The adjoining alveolar tissue had undergone pressure atrophy and was collapsed. In majority of the cases cysts were sterile except one case (RPNS - 219) in which brood capsule was adhered to the cyst wall.

Fig. 42 Pulmonary haemorrhages : Haemorhages in the alveoli. H & E x 100.

Fig. 43 Brown induration of lung : thickening of interstitial tissue with clusters of macrophages laden with golden brown pigment. H & E x 250.

Fig. 44 Brown induration of lung : Haemosiderin pigment as bluish masses in macrophages. Perl's x 250.

Fig. 45 Hydatidosis : Hydatid cyst containing laminated cystic wall with fibro-cellular reaction. H & E x 63.

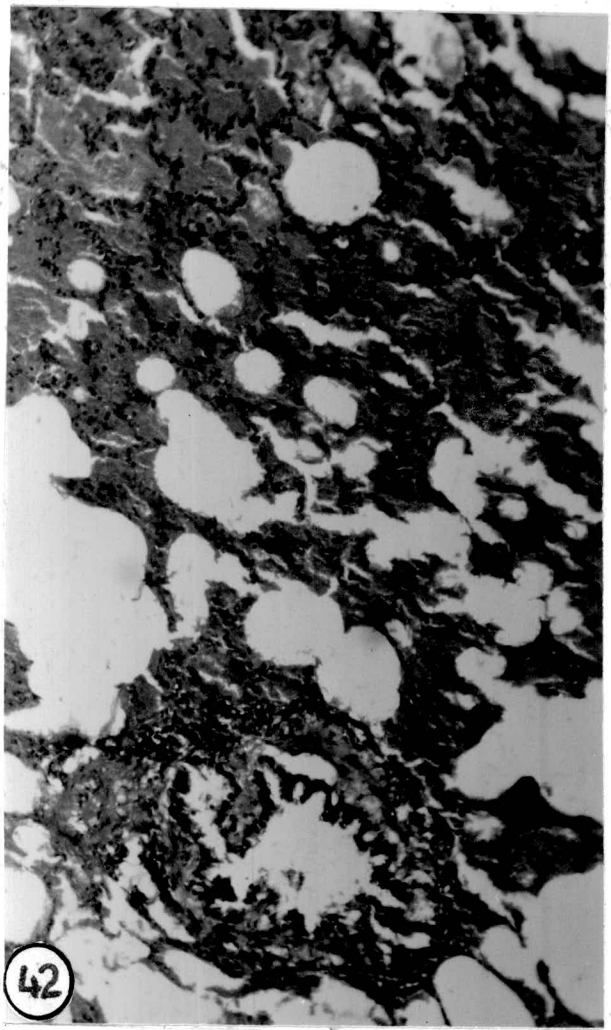
42

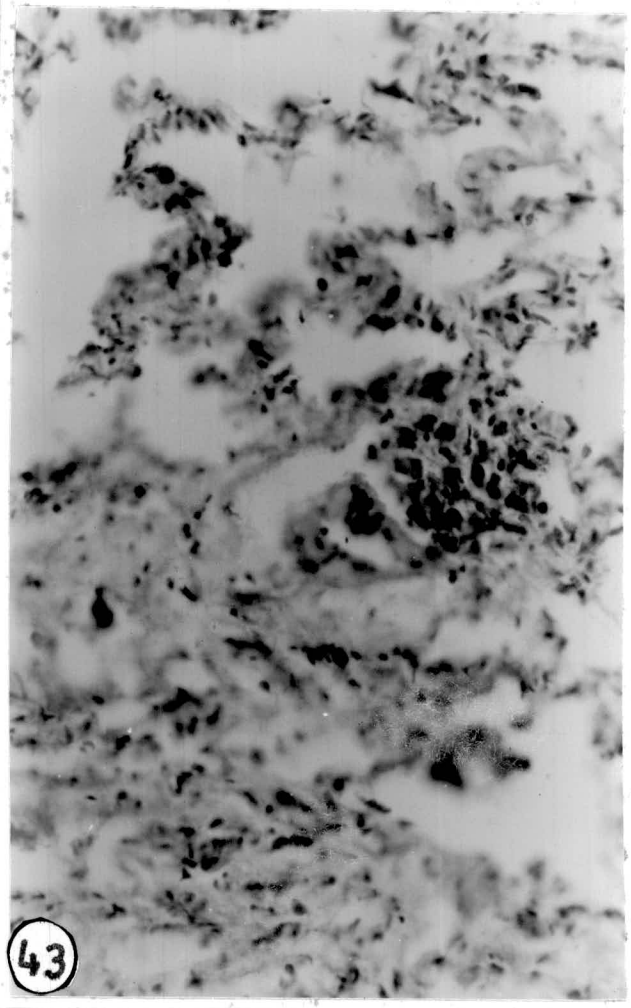
43

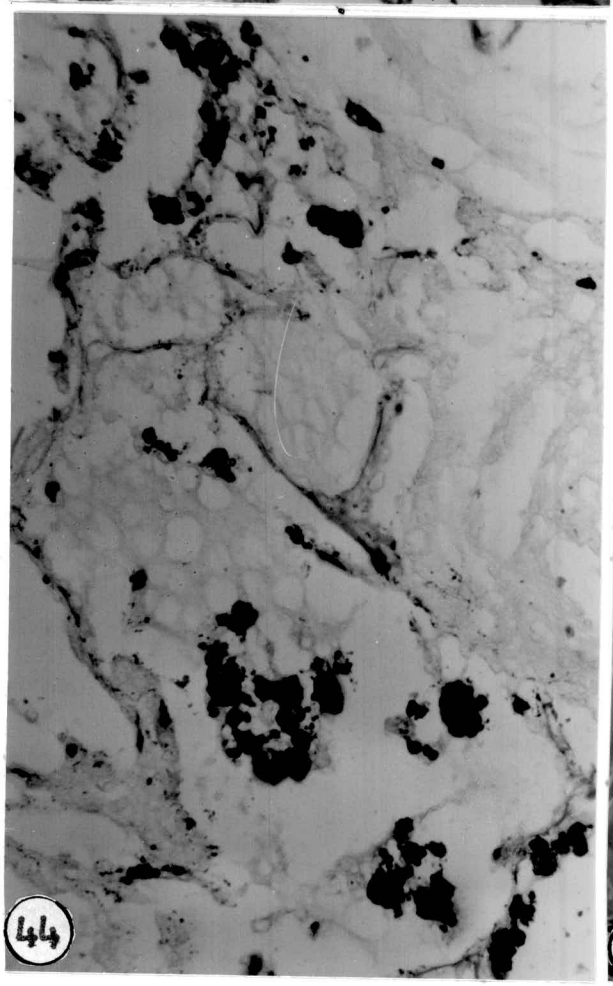
44

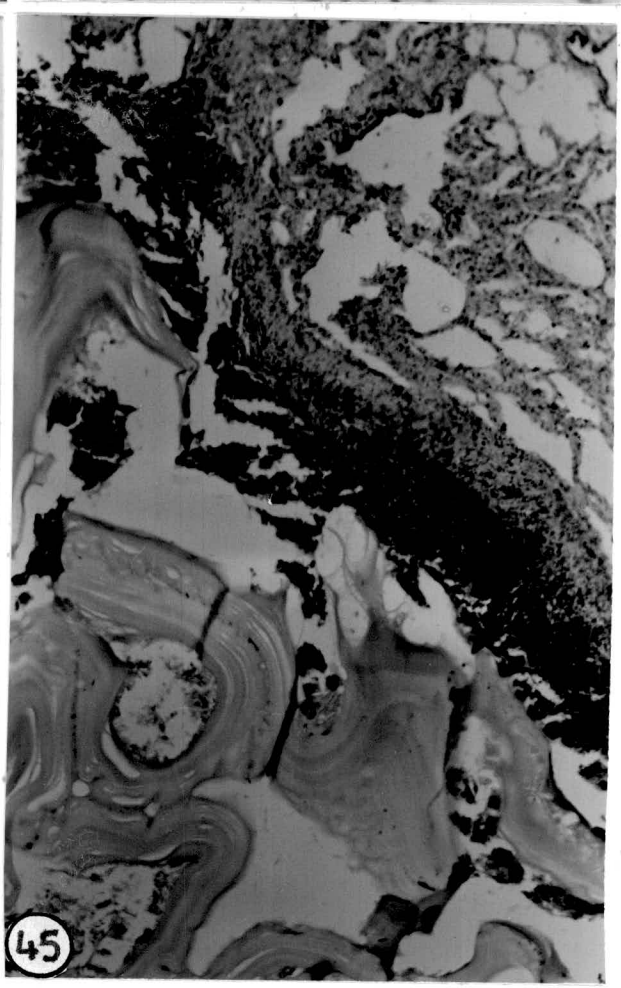
45

DISCUSSION

DISCUSSION

The present investigation was aimed to elucidate the occurrence and magnitude of the problems of pulmonary affections specially the pneumonia in goats. A total of 9432 animals were screened from various abattoirs of which 429 lungs showed gross lesions amounting to an overall incidence of 4.55% which corroborated with the observations of Naik (1989) who recorded 4.4% cases of lung lesions. The higher incidence ranging from 13.9 to 20% has been recorded by various workers (Ramachandran and Sharma, 1969; Bhagwan and Singh, 1972; Alka Sharan, et al., 1986 and Sharma et al., 1991). The lower incidence of pulmonary affections recorded presently could be ascribed to the fact, the antemortem examination was more judiciously carried out to scruitinize the animals and comparatively younger animals were slaughtered at military abattoirs to which most of the present material belonged. Further the occurrence of pneumonic lesions was noticed in 374 lungs (3.97%) of which the prevalence of bronchopneumonia was highest (49.18%) followed by special pneumonia (15.85%), suppurative pneumonia (14.92%), interstitial pneumonia (6.06%) and granulomatous pneumonia (1.16%).

The area wise distribution (Table 4) indicated that the magnitude of fibrinous bronchopneumonia due to Pasteurella sp.

was almost similar in the materials screened in slaughter houses of U.P., Rajasthan, H.P., Bihar and West Bengal and was suggestive of ubiquitous existence. Higher occurrence of suppurative pneumonia to the tune of 25% recorded in Delhi as well as in Bihar abattoirs could be due to the fact that goats are generally concentrated transitly in these areas for further trasportation to distant places for slaughter. Probably the overcrowding of animals in unhygienic conditions might have led to bacterial complications in the animals already under stress. Further higher occurrence of pulmonary adenomatosis (13.95%) noticed in Delhi could be due to the inflow of animals from disease infested areas like Rajasthan and Punjab, and lent support to the contention of earlier workers who observed that this disease was prevalent in Punjab (Banerjee and Gupta, 1979) and Rajasthan (Dadhich and Sharma, 1995). In the present investigation higher occurrence of 26% of verminous pneumonia was noticed in Himachal Pradesh which could be due to favourable climatic conditions for the propagation of lung worms as was also viewed by Sharma (1994), who recorded the prevalence of 18.7 to 47.6% in Himalayan regions of H.P., J.&.K. and U.P.

The varied incidence (22.4 to 60%) of bronchopneumonia had been reported in goats by the earlier workers (Bakr et al., 1980; Alka Sharan et al., 1986; Ashraf, et al., 1986; Naik, et al., 1991a and Upadhyaya and Rahman, 1993). Though the incidence of bronchopneumonia in this study falls within the reported incidence, yet the conditions, accounted for the majority of the lesions which might be due to predominant aerogenous portal of entry of causative agents, particularly when the animals are under environmental stress.

Among the various categories of bronchopneumonia, the occurrence of acute bronchopneumonia was observed in 43.82% cases. This incidence appeared to be higher than reported, 28%, 22.4% and 33.06% by Upadhyaya (1983), Alka Sharan et al. (1986) and Naik, et al. (1991a). Out of different categories of acute bronchopneumonia, 99 animals (23.08%) revealed the lesions of acute fibrinous bronchopneumonia which ranked the highest and was in close aggrement with the observations of Chattopadhyay et al. (1987) who recorded 28.4% and was in contradiction with the findings of Alka-Sharan et al. (1986), Naik et al. (1991b), who reported the occurrence as 2.04% and 6.94% respectively. Further, Upadhyaya and Rahman (1993) observed a quite high incidence of 48.24%. The involvement of apical, cardiac and anteroventral diaphragmatic lobes are in close proximity with those recorded by earlier workers (Metin, et al., 1988; Naik, et al., 1991a; Upadhyaya and Rahman, 1993 and AlDarraji and AlJoboury, 1993). Moreover, involvement of pleura and prominence of interlobular septae were not uncommon. Histologically, pleuritis, serofibrinous exudation in interlobular septae, neutrophilic infiltration, presence of typical oat shaped cells (46 cases) and bipolar organisms were the pathognomic lesions of Pasteurella sp. Isolation of Pasteurella multocida in 12 cases and Pasteurella haemolytica in one case further confirms the involvement of these organisms in causation of fibrinous bronchopneumonia. The presence of oat shaped cells in cases of pasteurella pneumonia is not an infrequent finding but the mechanism of its formation is not fully understood. Jubb et al. (1993) mentioned that an imbalance with increased procoagulent activity and decreased fibrinolytic activity of pulmonary leukocytes may lead to increased deposition of fibrin and decreased fibrin removal from the alveolar tissue, was responsible for 'oat shaped' cell formation.

Catarrhal and haemorrhagic bronchopneumonia in the present study was recorded 13.52 and 2.33%, respectively. The varied incidence (0.8 to 5.88%) of acute haemorrhagic bronchopneumonia has been reported by earlier workers (Alka Sharan, et al., 1986; Naik et al., 1991a; Upadhyaya and Rahman, 1993). The pathomorphological changes observed presently were in accordance with the observation of above workers. However, the precise nature of inflammatory exudation might be the initiation of the process during the course of acute fibrinous bronchopneumonia and the variation in the incidence may not be the significant observation.

Acute necrotising bronchopneumonia was seen in 21 cases (4.89%). The lesions observed were massive areas of necrosis, leukocytic infiltration and serofibrinous exudation in pleura interlobular septa and alveoli and 'oat shaped' cells with demonstration and isolation of Pasteurella multocida in four cases. Pasteurella organism is known to produce endotoxin and leukotoxin which might be attributable to vascular injury, consequent thrombosis and necrosis of lung parenchyma (Jubb et al., 1993). The present observations are in close agreement with the findings of Young and Griffith (1985) and Naik et al. (1991b).

The suppurative pneumonia was encountered in 64 cases (14.92%) as variable sized abscesses, which were noticed in the lung parenchyma and peribronchial/peribronchiolar regions. In chronic cases, these abscesses were well encapsulated. A variety of microorganisms like Corynebacterium pyogenes, Staphylococcus aureus, Streptococcus sp. were isolated and demonstrated in the sections. It is well documented that the initiating factors for the causation of pneumonia are usually either virus like PI-3 or bacteria like

Pasteurella, Mycoplasma and Chlamydia which get subsequently superimposed with the secondary pyogenic organisms leading to suppuration. Further, stress conditions like overcrowding, inclement weather may act as contributory factors for precipitating the ailment.

The prevalence of interstitial pneumonia has been noticed in 26 cases (6.06%) which is in close proximity to the observations of Ivetic et al. (1989) and Upadhyaya and Rahman (1993), who recorded the occurrence 4.1% and 6.4%, respectively. The pathomorphological lesions observed were patchy areas of consolidation at the apical, cardiac and dorsocaudal portion of diaphragmatic lobes and comprised of septal cell proliferation, infiltration of mononuclear cells and peribronchial/peribronchiolar lymphocytic cuffing which were also recorded by various other workers (Ramachandran and Sharma, 1969; Bhagwan and Singh, 1972; Alka Sharan et al., 1986 and Upadhyaya and Rahman, 1993). The lesions observed in the present study could be due to patchy or diffuse injury to alveolar septa and subsequent proliferation of septal cells as has also been suggested by Jubb et al. (1993).

In acute and chronic interstitial pneumonia though the possible etiology could not be established yet the possiblity of other viral infections can not be ruled out particularly in cases of chronic interstitial pneumonia where distinct peribronchial and peribronchiolar lymphoid cuffing and lymphoid follicles formation were observed in the present cases. Though such cases were suspected for maedi lesions by earlier workers (Rajya and Singh, 1964; Sharma 1971; Sharma et al., 1975; Banerjee and Gupta, 1979; Rahman and Iyer, 1979; Upadhyaya, 1983; Alka Sharan et al., 1986 and Naik et al. 1991a) however, there is necessity of differentiating them from

the lesions of caprine arthritis encephalitis in goats which need further elucidation.

The incidence of viral pneumonia in the present study due to PI-3 type infection was observed in 6.29% cases which is lower than recorded (14.0-17.96%) by earlier workers (Gupta and Rajya, 1969; Rahman and Singh, 1990b and Naik et al., 1991a). The involvement of apical and cardiac lobes with lesions characterized by proliferation of bronchial/bronchiolar epithelium, septal cells, alveolar epithelization, syncytia formation, presence of intracytoplasmic inclusions in alveolar macrophages and bronchiolar lining epithelium with peribronchial/peribronchiolar lymphocytic infiltration are similar to those described in PI-3 infection by earlier workers (Ramachandran and Sharma, 1969; Gupta and Rajya, 1969; Sharma, 1971; Banerjee and Gupta, 1978/1979; Upadhyaya, 1983; Alka Sharan et al., 1986 and Rahman and Singh, 1990b). Further, such lesions were usually superimposed with secondary bacterial complications like Pasteurella sp. Staphylococcus Sp., Corynebacteirum sp. masking the characteristic viral lesions, thereby giving the coveted lower incidence.

Occurrence of 1.86% of pulmonry adenomatosis was encountered in the present investigation and is in close proximity to the incidence (2.35%) reported by Upadhyaya and Rahman (1993). However, lower incidence (0.13-0.82%) of the condition has been reported by a number of workers (Bhagwan and Singh, 1972; Dwivedi, 1974; Sri-Raman et al., 1982 and Naik et al. 1991a). Pathomorphologically, the multicentric lesions of adenomatosis were identical to those described by earlier workers in such cases (Dwivedi, 1974; Mandic, 1974; Banerjee and Gupta, 1979; Mukherjee et al., 1989; Naik et al., 1991a and Dadhich and Sharma, 1995).

Lesions of Mycoplasma pneumonia were seen in 7 cases (1.63%). The main gross lesions were thickened pleura covered with fibrinous mass and prominent interlobular septae. Microscopically, serofibrinous exudation, infiltration of polymorphs, mononuclear cells in interlobular septa and alveoli with peribronchial/peribronchiolar and perivascular lymphocytic cuffing were the prominent features. These findings were in close agreement with the observations of earlier workers (Sharma et al., 1978; Nayak and Bhowmik, 1988; Rahman and Singh, 1990a; Mukherjee et al., 1990; Basanti et al., 1992 and Kumar et al., 1995). Though Mycoplasma organisms also act a primary pathogens for initiation of pneumonia, however the suprimposition of variety of other pathogens (Pasteurella sp., Corynebacterium sp. Staphylococcus sp. etc.) as also observed presently, complicate the picture, amounting to lower incidence. In 2 cases, mycoplasma organisms were isolated though, were untypable with the serotypes available in the National Mycoplasmal referal laboratory, also confirms the above observation.

The prevalence of verminous pneumonia in this study was 5.82% whereas incidence of 1.63 to 16.32% had been reported by various workers (Sadana et al., 1979; Nimmo, 1979; Upadhyaya, et al., 1983; Goltz, 1986; Metin et al., 1988; Ivetic et al., 1989 and Valero et al., 1993). In some of cases, the parasites identified were Muellerius sp. and Protostrongylus sp. or varestrongylus sp. which were in conformity to observations of different workers (Sadana et al., 1979 and Upadhyaya et al., 1983). In verminous pneumonic cases, Dictyocaulus filaria are also commonly encountered in hilly and tarai areas because of favourable climatic conditions. The Muellerius sp. is usually encountered in high altitude areas, nevertheless, identification of parasite would definitely help in formulating the prophylactic measures for controlling the infection.

In one case, lung parenchyma showed typical nodular lesions with the presence of multiple giant cells, macrophages, lymphocytes and fibrocellular reaction. Basophilic structures of variable sizes as round, oval, button or dumble shaped, giving an appearance of parasitic structures with parasitophorous vacuole around were noticed in almost each giant cell. Though these structures could not be identified, yet such an incidental findings need further indepth study to elucidate its role in causation of giant cell pneumonia formation.

Granulomatous lesions in 1.16% cases were due to pulmonary aspergillosis in one and pulmonary tuberculosis in four cases. In pulmonary aspergillois, lesions were of small greyish-white nodules in apical and diaphragmatic lobes of both the lungs. The nodules revealed multicenteric necrotic areas containing branched, septate, fungal hyphae, surrounded by infiltration of lymphocytes, macrophages, Langhan's type giant cells and fibrous connective tissue reaction. Such lesions were in accordance to the observations of previous workers (Chauhan and Dwivedi, 1974; Sharma and Dwivedi, 1978; Singh, 1979 and Singh et al., 1995). The isolation of Corynebacterium pyogenes from the lesions indicated the possible concurrent infection. Further it may not be out of place to mention that the purulent reaction may be due to Corynebacterium pyogenes and extensive necrosis might be due to vascular destruction and toxin production by the invading aspergillus organism.

Multiple nodular and diffuse types of tuberculous lesions were noticed in diaphragmatic lobes of the lung. The nodules revealed caseation, calcification, macrophages, epithelioid cells and Langhans giant cells surrounded by fibrous connective tissue reaction, where as diffuse tuberculous lesions revealed wide areas of necrosis with

calcified stiplings which lent support to the observations of Sharma and Dwivedi (1978) and is in contravention to the belief that goats are naturally immune to this disease. Further, its role in zoonotic diseases may not be undermined.

Among other pulmonary affections encountered were pulmonary oedema (0.93%); haemorrhages (2.09%) and brown induration (0.23%). The brown induration is usually recorded in chronic passive congestion (Jones and Hunt, 1983).. Further, the possibility of pulmonary haemorrhages during struggling of animals at the time of slaughter can not be ruled out.

The incidence of hydatidosis 8.39% as noted presently appeared similar to the findings of Naik, et al. (1991a) who recorded its prevalence (9.39%). In majority of cases, cystic structures having necrotic zones and fibrocellular reaction around the cysts were observed. Most of the cysts were found sterile except in one case where brood capsule attached to the cyst wall was observed which supported the findings of earlier workers (Banerjee, 1978; Upadhyaya et al., 1983 and Naik et al., 1991a).

The above study indicated that pneumonia continues to be the major problem among respiratory affections. The highest incidence of bronchopneumonia with the chief pathogen involved is Pasteurella sp. complicated with various secondary pyogenic organism. Further, the role of other agents in causation of pneumonia besides PI-3 and mycoplasma infection needs further elucidation. Though, verminous pneumonia appeared mainly as a regional problem and needs identification of parasite. Pulmonary tuberculosis inspite of lower incidence needs a further study with regards to the type of strain involved keeping in view of public health importance.

SUMMARY AND CONCLUSIONS

SUMMARY AND CONCLUSIONS

The present investigation aimed to ascertain the occurrence/magnitude of spontaneously occurring pulmonary affections and to study the pathomorphological lesions thereof and their possible correlation with the causative agent(s) in apparently healthy goats slaughtered at various abattoirs of north and eastern regions of the country. A total of 9432 lungs were screened, of which 429 specimens revealed different types of affections (4.55%) : Pneumonic (3.97%) and other pulmonary conditions (0.58%). Of 374 pneumonic lungs, 34 specimens suspected for bacterial and 21 for mycoplasmal etiology were subjected to microbiological study.

The geographical distribution revealed the incidence of pulmonary affections was more (5.67 to 6.56%) in Himachal Pradesh, Uttar Pradesh and Rajasthan than Chandigarh, Delhi, Bihar and West Bengal (2.10 to 3.69%). Among pneumonias, fibrinous bronchopneumonia due to Pasteurella sp. was uniformly present in U.P., Rajasthan, H.P., Bihar and West Bengal; Suppurative pneumonia more prevalent in Delhi and Bihar; Verminous pneumonia in H.P. and Pulmonary adenomatosis in Delhi.

The occurrence of various pneumonic conditions in the present study were : bronchopneumonia (49.18%); suppurative pneu-

monia (14.92%); interstitial pneumonia (6.06%); special pneumonia (15.85%) consisting of viral pneumonia PI-3 type (6.29%), adenomatosis (1.86%), mycoplasma pneumonia (1.63%), verminous pneumonia (5.82%) and giant cell pneumonia (0.23%), and granulomatous pneumonia 1.16% (aspergillosis - 0.23% and tuberculosis - 0.93%).

Among various form of bronchopneumonia, lesions of acute catarrhal bronchopneumonia (13.52%), acute fibrinous bronchopneumonia (23.08%), acute haemorrhagic pneumonia (2.33%) and chronic non-suppurative bronchopneumonia (5.36%) with involvement of apical, cardiac and anteroventral portions of diaphragmatic lobes were noticed. The histopathological picture varied with the nature of the exudate and type of inflammatory process in the alveoli, bronchi and bronchioles with predominence of neutrophils in acute and mononuclear cells in the chronic stages. Serofibrinous exudation with presence of oat shaped cell reaction in alveoli and the involvement of Pasteurella organisms were the main features of fibrinous bronchopneumonia. In addition, wide irregular areas of necrosis with nuclear debris at the margins were observed in necrotising bronchopneumonia.

Suppurative pneumonia of acute and chronic type were encountered in 24 and 40 specimens, respectively. Variable sized single to multiple, deep seated abscesses in apical, cardiac and diaphragmatic lobes were characterised by areas of suppuration with dead and disintegrated neutrophils along with the presence of colonies of organisms (Corynebacterium sp., Staphylococcus sp., and Streptococcus sp.) in acute cases where as in chronic cases, infiltration of mononuclear cells, plasma cells alongwith fibrous connective tissue reaction were the main lesions with the involve-

ment of similar organisms.

Acute and chronic interstitial pneumonia were observed in 7 and 19 specimens involving grossly the apical, cardiac and dorsocaudal portion of diaphragmatic lobes. Septal cell proliferation, infiltration of mononuclear cells and peribronchial/peribronchiolar lymphofollicular reaction were the salient observations. The viral pneumonitis simulating PI-3 like infection was seen in 27 specimens (6.29%). Majority of cases revealed lesions of bronchointerstitial pneumonia characterised by septa cell proliferation, serofibrinous exudation and infiltration of mononuclear cells in interalveolar septa, epithelialization, syncytial formation and eosinophilic intracytoplasmic inclusions in alveolar macrophages as well as bronchiolar epithelium. The above lesions were usually complicated with secondary bacterial organisms like Staphylococcus sp., Corynebacterium sp., Streptococcus sp. and Pasteurella sp., creating problem to differentiate them from suppurative and fibrinous bronchopneumonic lesions.

Pulmonary adenomatosis (1.86%) revealed multicentric areas of alveolar cells proliferation projecting as epithelial cell papilliform in-growths in the alveoli and hyperplasia of bronchial/bronchiolar epithelium.

Mycoplasma pneumonia was noticed in 7 cases (1.63%) and lesions were characterised by thickening of pleura, interlobular septa with serocellular exudate admixed with mononuclear cells and polymorphs in alveoli and peribronchial/peribronchiolar/perivascular lymphocytic infiltration along with the presence of Mycoplasma organisms (4) including isolation (2). Lesions of Pasteurella

pneumonia and hydatidosis were also found associated with mycoplasma pneumonia cases.

The verminous pneumonia were seen in 25 specimens (5.82%) involving mostly diaphragmatic lobes with the presence of cross sections of adult parasites, larvae and eggs admixed with catarrhal exudate, infiltration of polymorphs, occasionally eosinophils, and mononuclear cells in bronchi and lung parenchyma.

Nodular (3) and diffuse (1) types of pulmonary tuberculous lesions were noticed in diaphragmatic lobes which were characterised by typical granulomatous reaction along with the presence of acid-fast Mycobacterium organisms in necrotic areas. One case each of pulmonary aspergillosis and giant cell pneumonia were also seen.

The other pulmonary affections encountered were : oedema (0.93%), haemorrhage (2.09%), brown induration (0.23%), emphysema (1.16%) and hydatidosis (8.39%).

CONCLUSION

1. The overall incidence of pneumonia was 3.97% which is on the lower side contrary to observations of earlier reports.

2. Bronchopneumonia (49.18%) was the main pathological condition observed, of which fibrinous bronchopneumonia (23.08%) constituted the major share and Pasteurella sp. has been the main increminating pathogen.

3. Viral pneumonia (PI-3 type) and Mycoplasma were considered as primary initiating agents in causation of pneumonia.

4. Pulmonary tuberculosis and hydatidosis cases recorded were of zoonotic importance.

5. The study revealed fibrinous bronchopneumonia due to Pasteurella sp. was uniformly present in Uttar Pradesh, Rajasthan, Himachal Pradesh, Bihar and West Bengal; suppurative pneumonia more prevalent in Delhi and Bihar; verminous pneumonia in Himachal Pradesh and pulmonary adenomatosis in Delhi.

MINI ABSTRACT

The present investigation was undertaken to elucidate the occurrence/magnitude of pulmonary affections and to study the pathomorphological alteration and their possible correlation with etiological agent(s), in goats slaughtered at different abattoirs.

Out of 9432 goat lungs screened, 429 specimens (4.55%) showed pulmonary affections. Specimens suspected of bacterial (34) and mycoplasma (21) were subjected to microbiological investigations.

The histopathological study revealed various pneumonic conditions (3.97%) : acute catarrhal bronchopneumonia (13.52%), acute fibrinous bronchopneumonia (23.08%), acute haemorrhagic bronchopneumonia (2.33%), acute necrotizing bronchopneumonia (4.89%), chronic nonsuppurative bronchopneumonia (5.36%), acute and chronic suppurative pneumonia (5.60 and 9.32%), acute and chronic interstitial pneumonia (1.63% and 4.43%), special pneumonias (15.85%) comprising of viral pneumonia - PI-3 type (6.29%), Pulmonary adenomatosis (1.86%), mycoplasmal pneumonia (1.63%), verminous pneumonia (5.82%) and giant cell pneumonia (0.23%); granulomatous pneumonia (1.16%) consisting of pulmonary aspergillosis (0.23%) and tuberculosis (0.93%). Other pulmonary affections (0.58%) included pulmonary oedema (0.93%), haemorrhage (2.09%), brown induration (0.23%), emphysema (1.16%) and hydatidosis (8.39%).

Bacterial investigation revealed isolation of Pasteurella multocida (14), Pasteurella haemolytica (1), Corynebacterium pyogenes (12), Staphylococcus aureus (5), Pseudomonas sp. (2), E. coli (1) and Mycoplasma sp. (2).

लघु सारांश

प्रस्तुत अन्वेषण विभिन्न बधशालाओं में बकरियों के फुप्फसीय विकारों एवं संरचनात्मक विकृति के आघटन/परिमाण की व्याख्या करने एवं उनके कारण(णों) के अध्ययन करने के उद्देश्य से किया गया ।

कुल ९४३२ बकरी फेफड़ों को देखा गया जिसमें ४२९ नमूनों (४.५५ प्रतिशत) ने फुप्फसीय विकार दर्शाये । जीवाणुओं और माइकोप्लाज़मा संक्रमण हेतु संदिग्ध क्रमशः ३४ एवं २१ नमूनों का सूक्ष्म जीवाणु विज्ञानी अन्वेषण किया गया ।

ऊतक विकृति विज्ञानी अध्ययन द्वारा विविध निमोनिया अवस्थायें (३.९४ प्रतिशत) ज्ञात हुयी यथा - तीव्र कटरहल श्वसनी निमोनिया (१३.५२ प्रतिशत), तीव्र फिब्रिन युक्त श्वसनी निमोनिया (२३.०८ प्रतिशत), तीव्र रक्त स्रावीय श्वसनी निमोनिया (२.३३ प्रतिशत), तीव्र गलनीय श्वसनीय निमोनिया (४.८९ प्रतिशत), चिरकारी अपूयीय श्वसनीय निमोनिया (५.३६ प्रतिशत), तीव्र एवं चिरकारी सपूयीय श्वसनीय निमोनिया (५.६० और ९.३२ प्रतिशत), चिरकारी एवं अन्तरस्थलीय निमोनिया (१.६३ एवं ४.४३ प्रतिशत), विशेष निमोनिया (१५.८५ प्रतिशत) यथा विषाणु निमोनिया - पी०आई०-३ प्रकार (६.२९ प्रतिशत), फुप्फुसीय एडीनोमयता, माइकोप्लाज़मा निमोनिया (१.६३ प्रतिशत), कृमिजन्य निमोनिया (५०८२ प्रतिशत), बृहदाकार कोशिका निमोनिया (०.२३ प्रतिशत), कणिकामय निमोनिया (१.१६ प्रतिशत) जिनमें फुप्फुसीय एस्पर्जिलसता (०.२३ प्रतिशत) और क्षय रोग (०.९३ प्रतिशत) थी । अन्य फुप्फुसीय विकारों में (०.५९ प्रतिशत) फुप्फुसीय शोफ (०.९३ प्रतिशत), रक्तस्राव (२.०९ प्रतिशत), बभ्रु दृढ़ता (०.२३ प्रतिशत), वात स्फीति (१.१६ प्रतिशत) और हाइडेटिडता (८.३९ प्रतिशत) सम्मिलित थे ।

जीवाणुयीय अन्वेषणों से पास्च्युरेल्ला मल्टोसीडा (१४), पास्च्युरेल्ला हीमोलाइटिका (१), कोरायनीबैक्टीरियम पायोजेनिस (१२), स्टेफाइलोकोकस आरियस (५), सीडोमोनास प्रजाति (२) : इ० कोलाई (१) एवं माइकोप्लाज़मा प्रजाति (२) विलगित हुये ।

०००००

BIBLIOGRAPHY

BIBLIOGRAPHY

Abu Bakr, M.I., Elfaki, M.E., Abdalla, S.A. and Kamal, S.M. (1981). Pathological studies on sheep and goat pneumonia in Sudan. II. Experimental infection. Bull. Anim. Hlth. Prod. Afr. 29(1) : 85-94.

Abu-Elzein, E.M.E., Hassanien, M.M., AlAfaleq, A.I.A.B.D., Elhadi, M.A., Housanei, F.M.I. (1990). Isolation of peste des petitis ruminants from goats in Saudi Arabia. Vet. Rec. 127(12) : 309-310.

Acharya, R.M. (1982). Sheep and goat production. Role of sheep and goat diseases in causing mortality and reduced production. Inaugural address at the National Seminar on Sheep and goat diseases, C.S.W.R.I., Avikanagar, May 28-30, 1982.

Afshar, A. and Terleck, S. (1979). Experimental infection of goats with parainfluenza virus Type 3. Vet. Bull. 50, Abst. 4014.

Ahuja, A., Mathur, P.D. and Sharma, S.N. (1985). Clinical and roculgenological diagnosis of caprine respiratory diseases. Indian J. Vet. Med. 5(2) : 84-87.

Al Darraji, A.M. and Al Joboury, K.H. (1993). Incidence and pathology of bacterial pneumonia in Iraq local goats. Indian J. Anim. Sci. 63(5) : 488-491.

Alka-Sharan. (1986). Studies on the pathology of pneumonia in goats with special reference to Mycoplasma infection. Indian J. Vet. Path. 10 : 122-123.

Alka-Sharan, Thakur, N., Prasad, L.N. and Mukherjee, G. (1986). The prevalence of lung affection of goat in Bihar. Indian J. Vet. Path. 10 : 88-92.

Alluotto, B.B., Wittler, R.G., William, C.O. and Faber, J.E. (1970). Standardized bacteriological techniques for the characterization of mycoplasma species. Int. J. SYST. Bacteriol. 20 : 35-58.

Almeida, P.F., De Alves, F.S.F., Santos, L.De, F. and Rosa, J.S. (1987). Survey of bacterial agents associated with respiratory diseases of goats in North Eastern Brazil. Vet. Bull. 57(3) : 1194.

Anon (1992). Fifth International Conference on goats, New Delhi during March, 1992.

Ashraf, M., Khan, M.Z. and Chisti, M.A. (1986). Incidence and pathology of pneumonia in sheep and goats slaughtered in Faisalabad. Pakistan Vet. J. 6(2) : 55-59.

Atwal, O.S. and Bray, T.M. (1981). Glycogen accumulation in alveolar type II cells in 3-methylindole-induced pulmonary edema in goats. Am. J. Path. 105(3) : 255-263.

Aul, M. and Shamsul Islam (1981). Echinoccocosis in goats. Indian Vet. J. 58 : 999-1000.

Bakr, M.I.A., Abdalla, S.A., Faki, M.E. El and Kamal, S.M. (1980). Pathological studies on sheep and goat pneumonia in the Sudan I. Natural infection. Bull. Ani. Hlth. Prod. Afr. 28(4) : 288-293.

Banerjee, M. (1978). Studies on the incidence and etiopathology of respiratory diseases of sheep and goats with special reference to Mycoplasma isolation. M.V.Sc. Thesis Punjab Agri. Univ. Ludhiana (c.f. Upadhyaya, T.N. et al. (1983).

Banerjee, M. and Gupta, P.P. (1978/1979). Viral pneumonia in sheep and goats in Punjab. Indian J. Vet. Path. 3 : 43.

Banerjee, M. and Gupta, P.P. (1979). A note on pulmonary actinomycosis and nocardiosis in goats of Punjab. Indian J. Anim. Sci. 49 : 972-975.

Banerjee, M., Gupta, P.P. and Nem Singh (1984). Incidence and types of pulmonary affections in sheep and goats of Ludhiana (Punjab). Indian J. Anim. Hlth. 24 : 21-23.

Basanti, B.C., Pal and Singh, P.P. (1992). Pathogenecity of Mycoplasma mycoides subsp. mycoides (LC) in different hosts. Proceedings of National Symposium on Epidemiology of important livestock and Avian diseases, including molecular epidemiology and XIII Annual Conference of IAUMI 19-21 Nov. 1992, pp. 64.

Baskerville, A. 1981. Mechanism of infection in the respiratory tract. New Zealand Vet. J. 29 : 235-238.

Bernabe, A., Gomez, M.A., Navarro, J.A., Gomez, S., Sonchez, J., Sidrach, J., Menchen, V., Vera, A. and Sierra, M.A. (1990). Morphopathology of caprine tuberculosis. Anales-de-veterinaria de. Murcia 617 : 21-29.

Bhagwan, P.S.K. and Singh, N.P. (1972). Pneumonia in sheep and goats in Tarai. Indian J. Anim. Sci. 42(11) : 938-942.

Bhalerao, G.D. (1935). Helminth parasites of the domesticated animals in India. ICAR Scientific Monograph No. 6 : 365 (c.f. Upadhyaya, T.N. et al. (1983).

Bhowmik, A., Verma, B.B. and Thakur, D.K. (1995). Pathogenecity studies of M. mycoides var. mycoides (L.C.) in kids. Indian Vet. J. 72 : 811-814.

Bloom, M.E. and Jackson, T.A. (1975). Virus like particles in buffy coat cells of normal goats and goats infected with progressive pneumonia. Virus 36(6) : 789-793.

Bolske, G., Engvall, A., Renstrom, L.H.M. and Wierup, M. (1989). Experimental infection of goats with M. mycoides subsp. mycoides (LC) type. Research in Vet. Sci. 46(2) : 247-252.

Bolske, G., Wierup, M., Renstrom, L., Humlesjo, N.E. and Hammarberg, K.E. (1983). Outbreak of caprine pleuropneumonia in Sudan. Vet. Bull. 53(3) : Abst. 1717.

Chattopadhyay, S.K., Vanamayya, P.R. and Sikdar, A. (1986). Pathology of experimental respiratory aspergillosis inlamb. Compendium of National Symposium on Immune deficiencies and emerging diseases of animals and birds. Bombay Veterinary College, Bombay, Abst. No. ID-22.

Chaturvedi, V.K., Pathak, R.D., Singh, P.P. and Pal, B.C. (1991). Histopathological lesions of lungs in Mycoplasma infection. Indian J. Comp. Microbiol. Immunol. Infect. Dis. 12(1) : 59-60.

Chaturvedi, V.K., Pathak, R.C., Singh, P.P. and Pal, B.C. (1989). Histopathomorphological picture of lung in Mycoplasma infection - A comparative study. First National Congress-cum-Workshop of Indian Association of Mycoplasmologists. 20-23. April, 1989 (Abst. p. 26).

Chaturvedi, V.K., Singh, P.P., Pal, B.C. and Pathak, R.C. (1994). M. mycoides subsp. mycoides (LC). Associated arthritis and pneumonitis of kids in India. Indian J. Comp. Microbiol. Immunol. Infect. Dis. 15(3&4) : 52-53.

Chauhan, H.V.S. and Dwivedi, P. (1974). Pneumomycosis in sheep and goats. Vet. Rec. 95 : 58-59.

Chauhan, H.V.S. and Singh, C.M. (1972). Studies on pathology of pulmonary adenomatosis complex of sheep and goats. II. Viral pneumonitis (atypical pneumonia). Indian J. Anim. Sci. 41(4) : 272-276.

Brandao, E. (1995). Isolation and identification of M. mycoides subsp. mycoides (SC) strain in sheep and goats. Vet. Rec. 136 : 98-99.

Buddle, B.M., Pfeffer, A., Cole, D.J.W., Pulford, H.D. and Ralston, M.J. (1990). A caprine pneumonia outbreak associated with caprine herpes virus and P. haemolytica respiratory infection. NewZealand Vet. J. 38(1) : 28-31.

Carlson, J.R., Dickson, E., Yokoyama, M.T. and Bradley, B. (1975). Pulmonary edema and emphysema in cattle after intra-ruminal and intravenous administration of 3-methyl indole. Am. J. Vet. Res. 36 : 1341-1347.

Chandler, F.W., Kaplan, W. and Ajello, L. (1980). A colour Atlas and Textbook of the Histopathology of mycotic diseases. Wolfe Medical Publications Ltd. London.

Charan, K., Singh, S.P. and Singh, K.P. (1973). Pulmonary tuberculosis in goats. Indian Vet. J. 50(5) : 486-487.

Chattopadhyay, S.K., Parihar, N.S. and Sikdar, A. (1992). Caprine pulmonary mycosis in India : Spontaneous and experimental studies. Pre-conference Proc. Abst. Contributory Papers. Vol. 5th International Conference on Goat, New Delhi.

Chattopadhyay, S.K., Ram Kumar and Kumar, P.N. (1987). Occurrence and pathomorphology of pneumonic form of pasteurellosis in small ruminants. Indian J. Vet. Path. 11 : 33-37.

Chattopadhyay, S.K., Vanamayya, P.R. and Sikdar, A. (1986). Pathology of experimental respiratory aspergillosis inlamb. Compendium of National Symposium on Immune deficiencies and emerging diseases of animals and birds. Bombay Veterinary College, Bombay, Abst. No. ID-22.

Chaturvedi, V.K., Pathak, R.D., Singh, P.P. and Pal, B.C. (1991). Histopathological lesions of lungs in Mycoplasma infection. Indian J. Comp. Microbiol. Immunol. Infect. Dis. 12(1) : 59-60.

Chaturvedi, V.K., Pathak, R.C., Singh, P.P. and Pal, B.C. (1989). Histopathomorphological picture of lung in Mycoplasma infection - A comparative study. First National Congress-cum-Workshop of Indian Association of Mycoplasmologists. 20-23. April, 1989 (Abst. p. 26).

Chaturvedi, V.K., Singh, P.P., Pal, B.C. and Pathak, R.C. (1994). M. mycoides subsp. mycoides (LC). Associated arthritis and pneumonitis of kids in India. Indian J. Comp. Microbiol. Immunol. Infect. Dis. 15(3&4) : 52-53.

Chauhan, H.V.S. and Dwivedi, P. (1974). Pneumomycosis in sheep and goats. Vet. Rec. 95 : 58-59.

Chauhan, H.V.S. and Singh, C.M. (1972). Studies on pathology of pulmonary adenomatosis complex of sheep and goats. II. Viral pneumonitis (atypical pneumonia). Indian J. Anim. Sci. 41(4) : 272-276.

Chawla, D.S., Bhatnagar, D.S. and Misra, R.R. (1982). Factors affecting kid mortality in desi goats. Indian J. Anim. Sci. 52(3) : 166-171.

Coussement, W., Burvenich, C., Ducatelle, R. and Flooneus, J. (1980). Outbreak of pneumonia among goats in Belgium. Vet. Bull. 51(11) Abst. 6887.

Cowwan, S.R., Holt, J.G., Liston, J., Murray, R.G.E., Niven, C.F., Ravin, A.W. and Stanens, R.Y. (1974). Bergy's mannual of determinative bacteriology. 8th edn.

Cruickshank, R. (1965). Medical Microbiology. 11th Edn. London Book Society, London, U.K.

Culling, C.F.A. (1963). Handbook of histopathological technique. 2nd edn., Butterworth and Co. Ltd., London.

Dada, B.J.O. and Bellno, E.D. (1979). Prevalence of hydatidosis and cysticercosis in slaughtered livestock in Niegeria. Vet. Rec. 103 : 311-312.

Dadhich, H. and Sharma, G.D. (1995). A note on Jaagsiekte and Maedi in goats from Rajasthan. Indian J. Vet. Path. 19(2) : 140-141.

Damodaran, S. (1960). Ovine pulmonary adenomatosis. Indian Vet. J. 37(3) : 127-142.

Datta, B.M. (1983). Studies on the pathology of caprine pneumonia. Indian J. Vet. Path. 7 : 97-98.

Dawson, M. (1980). Maedi/visna : a review. Vet. Rec. 106(10) : 212-216.

Dubey, B.M., Cutlip, R.C., Brogden, K.A. and Frank, G.H. (1992). A comparison of the intra-tracheal, intravenous and intratonsellar routes of inoculation of goats with Pasteurella haemolytica. Vet. Res. Communications 18(4) : 247-251.

Dubey, S.C., Srivastava, C.P., Lonkar, P.S. and Mann, A. (1985). Prevalence of ovine adeno virus antibodies insheep and goats of semiarid Rajasthan. Indian J. Comp. Microbiol. Immunol. Infect. Dis. 6(4) : 167-169.

Dungworth, D.L. (1985). Pathology of Domestic animals. Academic Press, London : 470-471.

Dwivedi, J.N. (1971). Studies on Jaagziekte and Maedi (pulmonary adenomatosis complex) in sheep and goats. Vet. Bull. 42 : Abst. No. 4104.

Dwivedi, J.N. (1974). Studies on Jaagziekte and Maedi (Pulmonary adenomatosis complex) in sheep and goats with special reference to their infections vis-a-vis cancerous nature. U.P. College of Vet. Sci. and Anim. Husb. 52 (Vet. Bull. 45 : Abst. No. 257).

Eigenmann, U.J.E., Horber, H. and Jucker, H. (1979). Acute bovine pulmonary emphysema. A review. Vet. Bull. 50 : Abst. No. 4630.

El-Mahdi, M.M. and Bakier, A.M. (1985). Pathological studies on goat pneumonia in the United Arab Emiratus. Indian J. Vet. Path. 9 : 23-28.

Emaneulson, S., Griner, L.A., Meier, J.E. and Olsen, J. (1978). Granulomatous fungal disease in a Tur goat. J. Am. Vet. Med. Ass. 173 : 1241.

FAO (1994). F.A.O. Statistics on livestock population. Animal Health Year Book No. 34 : 144.

Fiocre, B., Perreau, P., Faye, P. and Remond, M. (1980). Participation of visna-maedi virus in respiratory disease of goats. Serological evidence and pathogenecity. Vet. Bull. 51 : Abst. No. 1630.

Fordor, L., Hajtos, I. and Glavits, R. (1990). Diseases caused by P. haemolytica in Hungarian goat herds. Vet. Bull. 61(4) : Abst. 2389.

Garg, D.N., Nair, S.P.S. and Chandramani, N.K. (1985). Isolation and characterisation of Corynebacterium ovis from sheep and goats. Indian Vet. J. 62(9) : 805-808.

Goltz, J.P. (1986). Respiratory Mycoplasmosis and lung worm (Muellerius capillaris) parasitism in goats. Dissertation Abst. International II 46(8) : 2588-2589.

Goncalves, M.R. (1983). Suspected outbreak of CCPP in Portugal Vet. Bull. 54(4) : Abst. 228.

Goncalves, M.R. (1984). Suspected outbreak of CCPP in Portugal. Vet. Bull. 54 : Abst. 1503.

Gueraud, J.M. (1984). Infectious respiratory diseases of goats in the cher region of France. Vet. Bull. 55 : Abst. 1548.

Guha, C. and Verma, B.B. (1987). Studies on pathogenecity of a local strain of M. mycoides subsp. mycoides (LC) in kids. Indian J. Anim. Sci. 57(1) : 23-26.

Gupta, M.M. and Verma, B.B. (1984). Isolation and characterisation of Mycoplasmas from the respiratory tract of kids in Bihar. Indian J. Anim. Sci. 54(1) : 58-62.

Gupta, M.M., Verma, B.B. and Chauhan, H.V.S. (1984). CCPP - studies on etiology. Indian Vet. J. 61(9) : 737.

Gupta, P.P. and Rajya, B.S. (1969). Possible occurrence of viral pneumonia in indigenous sheep and goats. A morphological study of pneumonia lung lesions. Indian Vet. J. 46 : 205-208.

Hafez, A.M., Razig, S.A., El-Amrosi, S., AlHendi, A.B. (1991). Respiratory diseases occurring in farm animals in the eastern province of Saudi Arabid. Assint Vet. Med. J. 24(48) : 188-96.

Hordagoda, N.U., Alwis, M.C.L. De., Wettimmy, S.G., De, S., Anthony, C.S.V.B. and Vipubasin, A.A. (1981). Bacteriological studies on normal and pneumonic lung of goats in Sri Lanka. Ceylon Vet. J. 29(1/4) : 12-13.

Hordagoda, N.U. and Wettimmy, S.G. De, S. (1980). Association of P. haemolytica with pneumonia in goats. Ceylon Vet. J. 28(1/4) : 66.

Ikede, B.C. (1978). The pattern of respiratory lesions in goats and sheep in Niegeria Part II. Lesions in sheep. Bull Anim. Hlth. Prod. Afr. 26(2) : 172-185.

Ivetic, V., Hadziomerovic, Z., Prasovic, S., Dzuvic, A. (1989). Pathological changes in the lungs of goats from cooperative farms in Bosnia and Herzegovina. Veterinaria Sarajevo. 38(1-2) : 147-154.

Iyer, P.K.R. (1966). Contagious caprine pleuropneumonia of goats. Indian Farming. 7 : 40-44.

Iyer, P.K.R., Sharma, G.L. and Bhalla, N.P. (1968). Caprine pleuropneumonia. I.C.A.R. Technical Bulletin No. 18.

Iyer, P.R.K. (1932). Tuberculosis in goats in India. Indian J. Vet. Sci. & A.H. 2 Part I : 41-48.

Jones, T.C. and Hunt, R.D. (1983). Vet. Pathology 5th edn., Lea and Febiger, Philadelphia, P.A. 19106, U.S.A.

Jubb, K.V.F., Kennedy, P.C. and Palmer, N. (1993). Pathology of domestic animals. Vol. II, 4th edn. pp. 632-665. Academic Press, Inc.

Kasali, O.B. and Ozo, M.D. (1981). Pathogenecity of M. mycoides subsp. mycoides for goats. International goat and sheep Res. 1(4) : 269-273.

Kaushik, R.K. and Kalra, D.S. (1983). Investigation into outbreaks of caprine pneumonia associated with Klebsiella pneumoniae type 24. Indian J. Anim. Sci. 53(3) : 275-279.

Kolte, G.N. (1963). Studies on lung lesions in slaughtered sheep and goats. M.V.Sc. Thesis Jabalpur Agriculture University, Jabalpur (c.f. Upadhyay, T.N. et al. (1983).

Konsan, G., Verma, B.B. and Thakur, D.K. (1989). Mycoplasmosis in kids. Indian J. Vet. Med. 9(1) : 38-39.

Koul, G.L., Somvanshi, R. and Biswas, T. (1988). Mortality pattern in Pashmina goats. Indian Vet. J. 65(9) : 847-849.

Kumar, H., Parihar, N.S., Charan, K. and Singh, K.P. (1995). Clinical pathology of intratracheal M. mycoides subsp. capri. infection in goats. Indian J. Anim. Sci. 65(2) : 133-136.

Kumar, H., Parihar, N.S. and Singh, K.P. (1994). Experimental mycoplasmosis in sheep due to M. mycoides subsp. Capri. Indian J. Anim. Sci. 64(6) : 600-601.

Kumar, R. and Prasad, M.C. (1986). Mortality pattern and its cases in goats. Indian Vet. J. 63(9) : 711-714.

Lal Krishna and Kulshrestha, S.B. (1984). Systemic Aspergillus terreus infection in a kid. Indian J. Anim. Sci. 54 : 308-310.

Lamontague, L., Descoleause, J.P. and Roy, R. (1985). Epizootological survey of PI-3 reovirus-3 respiratory syncytial and infectious bovine rhinotracheitis viral antibodies in sheep and goat flocks in Quebec. Canadian J. Comp. Med. 49(4) : 424-428.

Longley, E.C. (1940). Contagious pleuropneumonia of goats : Indian J. Vet. Sci. and Anim. Husb. 10 : 127-197.

Luna, L.G. (1972). Histologic staining methods of the Armed Forces Institute of Pathology. 3rd edn., McGraw-Hill Book Co., New York.

Mandic, D. (1974). Experimental infection of kids with pulmonary adenomatosis virus isolated from lambs. Vet. Bull. 28(4) : 283-287.

Martrenchar, A. Bouchel, D. and Zoyem, N. (1995). Isolation and experimental studies of M. mycoides subsp. mycoides L.C. and M. ovipneumoniae in goats in northern cameroon. Small Ruminant Res. 16(2) : 179-184.

Masiga, W.N. and Rurangirwa, F.R. (1979). An outbreak of CCPP like disease in Kenya. Bull. Anim. Hlth. Prod. Afr. 27(4) : 287-288.

Metin, N., Ozer, H. and Ciftci, M.K. (1988). Pathological studies on pneumonia in goats in Flazig. Vet. Bull. 60(7) : Abst. 4951.

Mishra, K.C. (1992). Causes of goat mortality of goats in Sikkim. Proceedings of the National Symposium on epidemiology of important livestocks and XIII Annual Conference of IAVMI (19-21 Nov. 1992) : 20.

Mohan, K. and Uzoukwu, M. (1985). Mycoplasma sp. from pneumonic goats and sheep in eastern Niegeria. Bull. Anim. Hlth. Prod. Afr. 33(3) : 235-239.

Mukherjee, S., Som, T.L. and Basak, D.K. (1988). Tuberculosis in goat : A case report. Indian J. Vet. Path. 12 : 91-92.

Mukherjee, S., Som, T.L. and Basak, D.K. (1989). Incidence of Maedi in goats in W. Bengal. VI Annual Conference of Indian Association of Vet. Pathologists (Sept. 7-9, 1989) : 13.

Mukherjee, S., Som, T.L. and Bhowmik, M.K. (1990). Caprine Mycoplasmal pneumonia in W. Bengal (India). Isolation, identification in vitro drug sensitivity and pathological studies. Indian J. Anim. Hlth. 29 : 3-4.

Naik, D. (1989). Pathological studies on caprine pneumonia with particular reference to Pasteurella haemolytica infection M.V.Sc. Thesis, IVRI Izatnagar, Bareilly (U.P.).

Naik, D., Charan, K., Chattopadhyay, S.K. (1991). (a) Pathological studies on caprine pneumonia. Indian Vet. J. 68(3) : 216-220.

Naik, D., Charan, K., Parihar, N.S., Kumar, P.N., Celly, C.S. and Kamil, S.A. (1991). (b) Caprine pneumonic pasteurellosis clinical bronchoscopic and histopathological evaluation. Indian Vet. J. 68(11) : 1015-1020.

Nanda, P.N. and Singh, G. (1943). Tuberculosis amongst goats at the Government Farm, Hisar. Indian J. Vet. Sci. & A.H. 13 Part I : 70-74.

Nandi, S.N. and Sarkar, C.R. (1981). Maedi in Black Bengal goats. Indian Vet. J. 58 : 189-190.

Nascimento, M.de.G.F., Freundt, E.A. and Anderson, M. (1986). Isolation of M. mycoides from outbreaks of caprine mycoplasmosis in Brazil. British Vet. J. 142 : 246-247.

Nayak, N.C. and Bhowmik, M.K. (1988). Pathology of spontaneous Mycoplasmal Polyarthritis in goats. Indian J. Vet. path. 12 : 1-6.

Nayak, N.C. and Bhowmik, M.K. (1990). Goat flea (Order Siphonaptera) as a positive vector for the transmission of caprine mycoplasmal polyarthritis with septicaemia. Preventive Vet. Med. 9(4) : 259-266.

Ngatia, T.A., Kimberling, C.V., Johnson, L.W., Whiteman, C.E. and Lauermann, L.H. (1989). Experimental Pasteurellosis in goats. Bull. Anim. Hlth. Prod. Afr. 37(1) : 13-19.

Ngatia, T.A., Kimberling, C.V., Johnson, L.W., Whiteman, C.E. and Lauermann, L.H. (1986). Pneumonia in goats following administration of live and heat killed P. haemolytica. J. Comp. Path. 96(5) : 557-564.

Nimmo, S.J. (1979). Six cases of verminous pneumonia (Muellerius sp.) in goats. Canada Vet. J. 20 : 49-52.

Obi, T.U. (1984). Respiratory viral infection in goats in Niegeria with emphasis on peste des petitis ruminants. Vet. Bull. 55(3) : 181.

Obi, T.U. and Ibu, J. (1990). Parainfluenza type-3 (PI-3) virus infection in goats in Niegeria Small Ruminants Res. 3(5) : 517-523.

Ola, Ozo, M. (1976). Caprine pneumonia in Niegeria. I. Epidemiology and bacterial flora of normal and diseased respiratory tracts. Trop. Anim. Hlth. Prod. 8(2) : 85-89.

Patnaik, R.K. (1985). Studies on pathology of chlamydial pneumonia in goats. Indian J. Vet. Path. 9 : 108-109.

Patnaik, R.K. and Nayak, B. (1984). Studies on pathology of Chlamydial pneumonia in goats. Indian Vet. J. 61(10) : 82-83.

Pillai, P.M., Abdulla, P.K. and Punnoose, K.T. (1979). Studies on the bacterial species associated with pneumonia in goats. Kerala J. Vet. Sci. 10(1) : 137-144 (fide Vet. Bull. 50(11) : Abst. No. 7524.

Radhey Mohan (1950). Incidence of tuberculosis in goats. Indian Vet. J. 27 : 153-157.

Rahman, T. and Iyer, P.K.R. (1979). Studies on pathology of ovine pneumonia. Indian Vet. J. 56 : 455-461.

Rahman, T. and Singh, B. (1990a). Clinicopathological features of Pulmonary Mycoplasmosis in goats. Indian Vet. J. 67(10) : 915-919.

Rahman, T. and Singh, B. (1990b). Incidence and pathology of viral pneumonia in goats. Indian J. of Anim. Sci. 60(10) : 1159-1162.

Rajya, B.S. (1964). Pathology of pneumonia and associated respiratory diseases of sheep and goats. Agra Univ. J. of Res. (Science) XIII (Part III) : 189-192.

Rajya, B.S. and Singh, C.M. (1964). The pathology of pneumonia and associated respiratory diseases of sheep and goats. I. Occurrence of Jagziekte and Maedi in sheep and goats in India. Am. J. Vet. Res. 25 : 61-67.

Ramachandran, S. (1959). Histopthological studies on pneumonia in sheep and goats. M.Sc. Thesis. University of Madras.

Ramachandran, S. and Sharma, G.L. (1969). Observation on the incidence and histopathology of pneumonia of sheep and goats in India. Indian Vet. J. 26 : 16-29.

Ram Kumar and Paliwal, O.P. (1995). Pathological conditions in mortality of goats - a retrospective study. National symposium on impact of diseases in livestock/poultry production and wild life conservation and XII Annual Convention of Indian Association of Vet. Pathologists (9-11 Nov. 1995) : 92.

Randall, C., Cutlip, R.C., Howard, D., Lehmkuhl, Kim, A., Brog-den and Mary Jo. F. Schmerr (1991). Seroprevalence of ovine progressive pneumonia virus in various domestic spp. Am. J. Vet. Res. 52(2) : 189-191.

Rosendal, S. (1981). Experimental infection of goats, sheep and calves with the LC type of M. mycoides subsp. mycoides. Vet. Pathol. 18 : 71-81.

Rosendal, S. (1984). Pathogenetic mechanisms of M. mycoides subsp. mycoides septicaemia in goats. Israel J. Med. Sci. 20(10) : 970-971.

Runnel, R.A., Monlux, W.S. and Monlux, A.W. (1965). Principles of Veterinary Pathology. 7th edn., 528-564 pp. The IOWA State Univ. Press. AMES, IOWA, U.S.A.

Sadana, J.R., Purohit, V.D. and Kalra, D.S. (1979). Incidence and pathology of verminous pneumonia in sheep and goats. Haryana Veterinarian 18(2) : 111-116.

Sahai, L. and Dhanda, M.R. (1942). Report Imperial Council of Agri-cultural Research Scheme for the investigation of tuber-culosis and Johnes disease in animals for the year 1942-43, New Delhi, ICAR.

Sambyal, D.S., Banerjee, M., Baxi, K.K. and Gupta, P.P. (1980). Bacteriology of pneumonia in sheep and goats. J. Res. Pb. Agri. Univ. 17(1) : 89-91.

Sarkar, P. and Bhattacharyya, H.M. (1975). Caprine pneumonia caused by Corynebacterium ovis. Indian J. Anim. Hlth. 14(1) : 5-6.

Sarr, J., Diop, M. and Cissokhe, S. (1984). Epidemiological situation of main respiratory viruses of small ruminants in Senegal (c.f. Obi and Ibu, 1990).

Sawargaonkar, S.P., Degloorkar, N.M., Moregaonkar, S.D., Kulkarni, G.B. and Khan, M.A. (1996). Studies on mortality pattern in caprines in Marathawada (Maharashtra). Indian Vet. J. 73 : 212-213.

Sharma, D.N. (1971). Jaagsiekte and maedi (pulmonary adenomatosis complex) in sheep and goats : epizootiological, patho-anatomical and experimental studies. Vet. Bull. 43 : 324.

Sharma, D.N. and Dwivedi, J.N. (1977). Pulmonary mycosis of sheep and goats in India. Indian J. Anim. Sci. 47(12) : 808-813.

Sharma, D.N. and Dwivedi, J.N. (1978). Pulmonary tuberculosis of sheep and goats in India. Vet. Res. Bull. 1(2) : 90-93.

Sharma, D.N., Prakash, D., Dwivedi, J.N. and Rajya, B.S. (1975). Epizootiological studies on Jaagziekte and Maedi in sheep and goats in U.P. Indian J. Anim. Sci. 45(4) : 239-241.

Sharma, G.L. and Bhalla, N.P. (1962). Vegetative endocarditis in goats experimentally infected with CCPP organism. J. Vet. Sci. 32(1) : 44-49.

Sharma, R.K., Bero, B.R. and Borah, P. (1991). Incidence of caprine pneumonia and associated bacterial species. Indian J. Anim. Sci. 61(1) : 54-55.

Sharma, R.L. (1994). Parasitic bronchitis in goats and the possible use of Dictyocaulus filaria vaccine for its control. Vet. Parasitology. 51(3/4) : 255-262.

Sharma, R.N., Francis, B.K.T., Pandey, G.S. and Chiziyuka (1985). Goat tuberculosis in Zambia. Indian J. Vet. Path. 9 : 29-32.

Sharma, S.N., Vyas, C.B., Chauhan, D.S. and Jatkar, P.R. (1978). Clinico-pathological studies on CCPP. Indian J. Vet. Sci. 48(2) : 108-112.

Sikdar, A., Chattopadhyay, S.K. and Vanamayya, P.R. (1989). Systemic aspergillosis in kids. An experimental study. Compendium of XXIV Conference of Indian Veterinary Association, Calcutta, Jan., 1989 (Abst. No. 70).

Singh, S.V. (1979a). Occurrence and Pathomorphology of pneumonia in sheep and goats. M.V.Sc. Thesis, CSA Univ. Agri. & Tech. Campus, Mathura.

Singh, S.V. (1979b). Occurrence and pathology of pneumonia in sheep and goats. Vet. Res. Bull. 2(1) : 105-106.

Singh, S.V., Sharma, D.N., Srivastava, A.K. and Singh, H. (1995). Pulmonary Aspergillosis in sheep and goats : Incidence and pathomorphology. Indian J. Vet. Path. 19(1) : 35-37.

Smith, H.A., Jones, T.C. and Hunt, R.D. (1972). Vet. Pathology. 4th edn. Lea and Febiger, Philadelphia.

Sri Raman, P.K., Rao, P.R. and Naidu, N.R.G. (1982). Goat mortality in Andhra Pradesh. Indian Vet. J. 59(2) : 96-99.

Srivastava, A.K., Patil, V.K. and More, B.K. (1985). Incidence of various disorders in local Angora and cross bred goats. Indian Vet. J. 62(11) : 935-939.

Srivastava, N.C., Sikdar, A. and Uppal, P.K. (1989). Pathogenecity of M. mycoides subsp. capri in goats by intratracheal route. Indian J. Ani. Sci. 59(5) : 491-493.

Stamp, J.T. (1968). Pneumonia of sheep. Vet. Res. 83 : 607.

Stamp, J.T. and Nisbet, D.I. (1963). Pneumonia of sheep. J. Comp. Path. 73 : 319-328.

Stevenson, R.G. (1969). Respiratory diseases of sheep. Vet. Bull. 39(11) : 747-759.

Thiarcourt, F., Breard, A., Lefevere, P.C. and Mebratu, G.Y. (1992). CCPP in Ethiopia. Vet. Rec. 131(25/26) : 585.

Tiwari, H.C., Pande, M.N. and Banset, B.M. (1975). A note on the incidence of lung worm infection in Nepal. Indian J. Anim. Sci. 45(9) : 694-695.

Ugochukwu, E.I. (1983). Pathology of bacterial pneumonia of goats in NSUKKA and Cnugu zones of Anaambra State of Niegeria. Bull. Anim. Hlth and Prod. Afr. 31(4) : 343-347.

Upadhyaya, T.N. (1983). Studies on the pathology of caprine pneumonia (Abst. of Thesis). Indian J. Vet. Path. 7 : 97-98.

Upadhyaya, T.N., Datta, B.M. and Rahman, T. (1983). Studies on the pathology of caprine pneumonia. Indian Vet. J. 60(10) : 787-790.

Upadhyaya, T.N. and Rahman, T. (1993). Prevalence and pathology of caprine penumonia in Assam. J. Assam Vety. Council. 3 : 47-50.

Uppal, P.K., Srivastava, N.C. and Kumar, A.A. (1987). Isolation of pathogenic strains of M. mycoides subsp. capri from an outbreak of CCPP in India. Israel J. Med. Sci. 23 : 531.

Valero, G., Alley, M.R. and Manktelow, B.W. (1993). Subpleural lymph nodes in goat lungs. New Zealand Vet. J. 41(2) : 69-72.

Vihan, V.S., Saini, A.L., Singh, B. and Prakash, B. (1986). Factors affecting mortality among kids of Jamunapuri goats in semi arid conditions. Indian J. Vet. Med. 6(1) : 8-11.

Vihan, V.S. and Singh, V.P. (1992). Kid mortality due to pneumonia in an organised farm - an epidemiological investigation. Indian J. Vet. Med. 12(2) : 76-78.

Weronga, H.O., Litamoi, J.K., Kagumba, M. and Wakhusama, E. (1993). Relationship between clinical signs and early lesions of CCPP caused by Mycoplasma strain F-38. Small Ruminant Res. 10(1) : 45-54.

Young, J.D. Jr. and Griffith, J.W. (1985). Spontaneous Pasteurella pneumonia in adult laboratory goats complicated by super infection with Corynebacterium, Pseudotuberculosis and Muellerius capillaries. Lab. Ani. Sci. 35(4) : 409-411.

Zamri-Saad, M., Sheik-Omar, A.R., Chool, K.F. and Chulan, U. (1987). Disease conditions of goats in serdang, Selangor, Malaysia Pertanila. 10(2) : 247-251.

Zamri-Saad, M., Subramanian, P., Sheikh Omar, A.R., Sani, R.A. and Rasedee, A. (1994). The role of concurrent haemonchosis in the development of pneumonic pasteurellosis in goats. Vet. Res. Communications. 18(2) : 119-122.

V I T A E

Name	:	***Lt. Col. N.S. Kanwar***
Date of birth	:	*18th August, 1953*
Nationality		*Indian*
Educational qualifications	:	*B.V.Sc. & A.H. (PAU, Ludhiana, Punjab) NDEHMS (IVRI, Izatnagar, U.P.)*
Permanent address	:	*Shamnagar Lower H. No. 255, Dharamsala, Distt. Kangra (H.P.) Ph. 01892-22601.*